ACTA RADIOLOGICA

FOUNDED IN 19 1 BY GÖSTA FORSSELL

PUBLISHED BY THE SOCIETIES OF MEDICAL RADIOLOGY IN DENMARK FINLAND NORWAY AND SWEDEN

DIAGNOSIS

INDICES to Vol 19 (1978)

Contents of Volume 19 (1978) — DIAGNOSIS

CONTENTS OF VOLUME 19 (1978) — DIAGNOSIS

CONTENTS OF VOLUME 19 (1978) — DIAGNOSIS

CONTENTS OF VOLUME 19 (1978) — DIAGNOSIS

Subject index to Volume 19 (1978) — Diagnosis

ROENTGEN DIAGNOSIS

Nervous system

Digestive tract (incl biliary tract and spleen)

Heart and Vessels (incl lymphatic vessels)

Lungs, Pleura Mediastinum and Chest wall

Bones and Joints (incl soft tissue)

Ear, Nose and Throat

Uro-genital system

ISOTOPES

COMPUTER TOMOGRAPHY

TECHNIQUE

Bones and Joints (incl soft tissue)

Ear Nose and Throat

Uro-genital system

List of Authors

CONTRAST MEDIA

PEDIATRIC RADIOLOGY

PROTECTION

BOOK REVIEWS

List of Supplements to Acta Radiologica

Nos 195–357

(Issued November 1978)
For Suppl Nos 1–194 inclusive see list issued December 1960 in Vol 54 fasc 6

The supplements are published from time to time and are not included in the subscription rate Prices and year of publication of numbers already issued are detailed below

195 SVEN SCHELLER Roentgenographic studies on epiphysial growth and ossification in the knee 1960 *Price Sw Kr 35*
196 K A HULTBORN and BO TÖRNBERG Mammary carcinoma The biologic character of mammary carcinoma studied in 517 cases by a new form of malignancy grading 1960 *Price Sw Kr 35*
197 LARS R HOLSTI The mitotic and radioprotective effect of cysteine and lysine in rat 1960 *Price Sw Kr 30*
198 OSBORNE BARTLEY The isometric relaxation phase of the left ventricle An electrokymographic study 1960 *Price Sw Kr 35*
199 GUNNAR WILLER VESTBY Vaso-seminal vesiculography in hypertrophy and carcinoma of the prostate with special reference to the ejaculatory ducts 1960 *Price Sw Kr 35*
200 BJORN NORDENSTRÖM Contrast examination of the cardiovascular system during increased intrabronchial pressure 1960 *Price Sw Kr 30*
201 GIOVANNI DI CHIRO RISA encephalography and conventional neuroradiologic methods A comparative study 1961 *Price Sw Kr 35*
202 LARS BJORK Velopharyngeal function in connected speech Studies using tomography and cineradiography synchronized with speech spectrography 1961 *Price Sw Kr 25*
203 BENGT O NYLEN Cleft palate and speech A surgical study including observations on velopharyngeal closure during connected speech using synchronized cineradiography and sound spectrography 1961 *Price Sw Kr 25*
204 S R KJELLBERG B NORDENSTRÖM U RUDHE V O BJÖRK and G MALMSTRÖM Cardioangiographic studies of the mitral and aortic valves 1961 *Price Sw Kr 30*
205 GUNNAR CARLBERGER Kinetics and distribution of radioactive cobalt administered to the mammalian body 1961 *Price Sw Kr 30*
206 HANS MOELL Kidney size and its deviation from normal in acute renal failure A roentgendiagnostic study 1961 *Price Sw Kr 25*
207 LEIF KULD HANSEN Micturition cystourethrography with automatic serial exposures An opinion on the value of the method 1961 *Price Sw Kr 30*
208 FINN LUNDWALL Cancer of the vulva A clinical review 1961 *Price Sw Kr 30*
209 ILMARI LINDGREN Anatomical and roentgenologic studies of tuberculous infections in BCG vaccinated and non vaccinated subjects with biophysical investigations of calcified foci 1961 *Price Sw Kr 25*
210 PER ERIK E BERGNER The significance of certain tracer kinetical methods especially with respect to the tracer dynamic definition of metabolic turnover 1962 *Price Sw Kr 30*
211 P VUORINEN P ANTTILA U WEGELIUS A KAUPPILA and E KOIVISTO Renal cortical index and other roentgenographic renal measurements 1962 *Price Sw Kr 25*
212 LARS ANDRÉN Pelvic instability in newborns with special reference to congenital dislocation of the hip and hormonal factors A roentgenologic study 1962 *Price Sw Kr 30*

236 RUNE WALSTAM Studies on therapeutic short-distance and intracavitary gamma beam techniques—Physical considerations with special reference to radiation protection 1965 (Out of print)

237 KAI SETALA Differences in pharmacodynamic response to colchicine between benign and malignant epidermal hyperplasias—An experimental study in skin tumor resistant mice 1965 *Price Sw Kr 30*

238 UNO ERIKSON Circulation in traumatic amputation stumps—An angiographical and physiological investigation 1965 *Price Sw Kr 35*

239 CARL GUSTAF STANDERTSKJÖLD-NORDENSTAM The pulmonary circulation during pneumonia—A cinedensigraphic study 1965 *Price Sw Kr 35*

240 ANTTI CEDERBERG Granulocyte distribution in bone marrow blood and different organs in whole body irradiated rats 1965 *Price Sw Kr 35*

241 KAI SETALA Decorporation of radiostrontium Radioactive assay techniques—An experimental study on mice 1965 *Price Sw Kr 30*

242 SHINJI TAKAHASHI Conformation radiotherapy—Rotation techniques as applied to radiography and radiotherapy of cancer 1965 *Price Sw Kr 40*

243 J TH VAN DER WERFF Radioactive bismuth [illegible]Bi—Experimental studies and clinical applications 1965 *Price Sw Kr 35*

244 SAMUEL S KUROHARA Effects of ionizing radiation on creatine metabolism in patients treated for malignancy and in rats 1965 *Price Sw Kr 35*

245 PER WESTLING Studies of the prognosis in Hodgkin s disease 1965 *Price Sw Kr 35*

246 SVEN GOTTMAR ERICSSON Quantitative microradiography of cementum and abraded dentine—A methodological and biological study 1965 *Price Sw Kr 35*

247 MAURI WILJASALO Lymphographic differential diagnosis of neoplastic diseases 1965 *Price Sw Kr 35*

248 SVEN SCHELLER Roentgenographic studies on the ossification of the distal femoral epiphysis 1965 *Price Sw Kr 30*

249 ROAR NISSEN MEYER Castration as part of the primary treatment for operable female breast cancer—A statistical evaluation of clinical results 1965 *Price Sw Kr 35*

250 ELIS BERVEN SVEN HULTBERG HANS LUDVIG KOTTMEIER ROLF SIEVERT LARS SANTESSON and BENGT SYLVÉN The first fifty years Radiumhemmet 1910–1937 and King Gustaf V Jubilee Clinic 1938–1960 1965 *Price Sw Kr 30*

251 MATS HAVERLING Renal phlebography—An experimental study in the pig 1966 *Price Sw Kr 30*

252 GUNNAR WESTBERG Gas myelography and percutaneous puncture in the diagnosis of spinal cord cysts 1966 *Price Sw Kr 30*

253 SVEN IVAR SELDINGER Percutaneous transhepatic cholangiography 1966 *Price Sw Kr 35*

254 FIRST NORDIC RADIATION PROTECTION CONFERENCE Proceedings Stockholm 1966 Edited by K Lidén and Erik Lindgren *Price Sw Kr 35*

255 LAWRENCE JOSEPH VAN CURA Application of digital computers in radiation dosimetry 1966 *Price Sw Kr 35*

256 HANS LUDIN Aortography Fluid dynamics and technical problems 1966 *Price Sw Kr 35*

257 HJALMAR BOLIN Contrast medium in kidney during angiography—A densitometric method for estimation of renal function 1966 *Price Sw Kr 30*

258 ELISABETH JOHANNISSON PER KOLSTAD and GUNNAR SÖDERBERG Cytologic vascular and histologic patterns of dysplasia carcinoma in situ and early invasive carcinoma of the cervix 1966 *Price Sw Kr 40*

259 PAUL EDHOLM Anatomic angles determined from two radiographic projections—Instrument description and measurement technique 1966 *Price Sw Kr 40*

260 TORSTEN ALMÉN A steering device for selective angiography and some vascular and enzymatic reactions observed in its clinical application 1966 *Price Sw Kr 40*

261 KAI SETALA BJORN LINDROOS and OTTO NYYSSONEN Cancer chemotherapy studies cytoplasmic barrier in malignant epidermal cells against the effect of colchicine—An electron microscopic study in mice 1966 *Price Sw Kr 25*

262 KLAS ROSENGREN Hyaline membrane disease—A radiological investigation in rabbits 1967 *Price Sw Kr 35*

263 JAN NILSSON Angiography in tumours of the urinary bladder 1967 *Price Sw Kr 35*

264 PER ERIK HEIKEL Postmortal changes of the lung—A roentgenographic microscopic and bacteriological follow up study on a pediatric series and on animals with experimental pneumonia 1967 *Price Sw Kr 30*

265 KAI SETALA OTTO NYYSSONEN and BJORN LINDROOS Ultrastructural changes in benign and malignant epidermal states in mice after topical beta radiation 1967 *Price Sw Kr 30*

266 GORAN NYLANDER Vascular response to vasopressin as reflected in angiography—An experimental study in the dog 1967 *Price Sw Kr 35*

267 JOHAN FOLIN Angiography in renal tumours—Its value in diagnosis and differential diagnosis as a complement to conventional methods 1967 *Price Sw Kr 35*

268 EERO TALA Carcinoma of the lung—A retrospective study with special reference to pre diagnosis period and roentgenographic signs 1967 *Price Sw Kr 35*

269 CARL O HENRIKSON Iodine 125 as a radiation source for odontological roentgenology 1967 *Price Sw Kr 35*

270 CATIONS IN INTRAVASCULAR CONTRAST MEDIA AND DEVELOPMENT OF SPECIFIC METRIZOATE FORMULAS — PHARMACOLOGIC AND CLINICAL STUDIES Proc Symposia at Copenhagen November 1964 and Sandefjord September 1966 1967 *Price Sw Kr 40*

271 ERNA TARKIAINEN Intracostal vein meningorachidography—A technical anatomic and clinical study 1967 *Price Sw Kr 35*

272 ALLAN LUNDERQUIST Arterial segmental supply of the liver—An angiographic study 1967 *Price Sw Kr 35*

273 KAI SETALA MAX SIURALA OTTO NYYSSONEN and ERNA TARKIAINEN Quantitative three-dimensional scintillography of the stomach with technetium (^{99m}Tc) 1967 *Price Sw Kr 30*

274 PER BERGSJO Radiation induced early changes in size and vascularity of cervical carcinoma—A colpophotographic and clinical study 1968 *Price Sw Kr 35*

275 SUNE ERICSON The parotid gland in subjects with and without rheumatoid arthritis 1968 *Price Sw Kr 40*

276 ROLF JENSEN Anterior teeth relationship and speech—Studies using cineradiography synchronized with speech recording 1968 *Price Sw Kr 35*

277 SVEN AHLBACK Osteoarthrosis of the knee—A radiographic investigation 1968 *Price Sw Kr 35*

278 IRÉNE SJOGREN KJELL BERGSTRÖM and HERMAN LODIN Echoencephalography in infants and children Comparison with cerebral pneumography in measuring ventricular size 1968 *Price Sw Kr 35*

279 BERTIL JARPLID Radiation induced asymmetry and lymphoma of thymus in mice 1968 *Price Sw Kr 35*

280 ERKKI M LAASONEN Information transmission in roentgen diagnostic chains—Experimental and clinical studies 1968 *Price Sw Kr 35*

281 RASMUS STENSTRÖM Arthrography of the knee joint in children—Roentgenologic anatomy diagnosis and the use of multiple discriminant analysis 1968 *Price Sw Kr 35*

282 Karl Karlstedt Carcinoma of the uterine corpus—Factors bearing on the curability 1968 *Price Sw Kr 35*

283 Leo Stjernvall Pharmacodynamic response of epidermal hyperplasias to topical vinblastine treatment 1968 *Price Sw Kr 35*

284 Hans Flodh Distribution and kinetics of labelled vitamin B_{12} 1968 *Price Sw Kr 35*

285 Erkki Koivisto Comparative study of roentgen diagnostic classifications—Computer analysis of 124 496 roentgen reports 1969 *Price Sw Kr 35*

286 Jorgen Jensen Malformations of the inner ear in deaf children—A tomographic and clinical study 1969 *Price Sw Kr 35*

287 Pentti J Taskinen Radiotherapy and TNM classification of cancer of the larynx—A study based on 1 447 cases seen at the Radiotherapy Clinic of Helsinki during 1936-1961 1969 *Price Sw Kr 35*

288 Robert T Nash Decision processes employing radioisotope scanning 1969 *Price Sw Kr 35*

289 Sirkka Wiljasalo Lymphographic polymorphism in Hodgkin s disease—Correlation of lymphography to histology and duration 1969 *Price Sw Kr 35*

290 Ulf Welander Multicolor combination images in subtraction angiography—A new photographic method and its applications 1969 *Price Sw Kr 40*

291 Ilona Schreck Purola Failure of malignant epidermal cells to respond to vinblastine sulfate—A study in skin tumor resistant mice 1969 *Price Sw Kr 35*

292 Giovanni Ruggiero Gianfranco Cristi and Claudio Trevisan Clinical aspects of encephalography 1969 *Price Sw Kr 30*

293 Pekka Virtama and Tapio Helela Radiographic measurements of cortical bone—Variations in a normal population between 1 and 90 years of age 1969 *Price Sw Kr 20*

294 L Stjernvall E E Niskanen and J Tarkkanen Penetration of cytoplasmic barrier in malignant epidermal hyperplasia by colchicine in dimethyl sulfoxide—A polarization microscopic study in skin tumor resistant mice 1969 *Price Sw Kr 20*

295 Kaarina Touri Kaisila Heart size determination by photofluorography 1970 *Price Sw Kr 35*

296 Hans Rovsing Otosclerosis—A tomographic-clinical study 1970 *Price Sw Kr 35*

297 Per Langeland Population screening for female breast tumours A clinical investigation 1970 *Price Sw Kr 35*

298 Johan Edgren Effect of cysteine on chromosome aberrations induced by radiation of human lymphocytes in vitro 1970 *Price Sw Kr 30*

299 Rune Sundgren Selective angiography of the left gastric artery 1970 *Price Sw Kr 35*

300 Niels Kroigaard The lower urinary tract in infancy and childhood—Micturition cinematography with simultaneous pressure flow measurement 1970 *Price Sw Kr 35*

301 M Viikeri Ultrasound examination of pleural plaques—Experimental pathologic and clinical studies 1970 *Price Sw Kr 35*

302 Ingemar Joelsson Radiotherapy of carcinoma of the uterine cervix with special regard to external irradiation 1970 *Price Sw Kr 35*

303 Kaarina Aantaa Location of the placenta — A comparison between radiography ultrasound thermography isotopes 1971 *Price Sw Kr 25*

304 Lennart Diener Intraosseous phlebography of the lower limb—Postmortem investigation of thrombotic venous disease 1971 *Price Sw Kr 40*

305 Berndt Stromberg The normal and diseased superficial flexor tendon in race horses—A morphologic and physiologic investigation 1971 *Price Sw Kr 35*

306 Trygve Aakhus Angiography in acute mechanical obstruction of the small intestine 1971 *Price Sw Kr 40*

259 PAUL EDHOLM Anatomic angles determined from two radiographic projections—Instrument description and measurement technique 1966 *Price Sw Kr 40*

260 TORSTEN ALMEN A steering device for selective angiography and some vascular and enzymatic reactions observed in its clinical application 1966 *Price Sw Kr 40*

261 KAI SETALA BJORN LINDROOS and OTTO NYYSSONEN Cancer chemotherapy studies cytoplasmic barrier in malignant epidermal cells against the effect of colchicine—An electron microscopic study in mice 1966 *Price Sw Kr 25*

262 KLAS ROSENGREN Hyaline membrane disease—A radiological investigation in rabbits 1967 *Price Sw Kr 35*

263 JAN NILSSON Angiography in tumours of the urinary bladder 1967 *Price Sw Kr 35*

264 PER ERIK HEIKEL Postmortal changes of the lung—A roentgenographic microscopic and bacteriological follow up study on a pediatric series and on animals with experimental pneumonia 1967 *Price Sw Kr 30*

265 KAI SETALA OTTO NYYSSONEN and BJORN LINDROOS Ultrastructural changes in benign and malignant epidermal states in mice after topical beta radiation 1967 *Price Sw Kr 30*

266 GORAN NYLANDER Vascular response to vasopressin as reflected in angiography—An experimental study in the dog 1967 *Price Sw Kr 35*

267 JOHAN FOLIN Angiography in renal tumours—Its value in diagnosis and differential diagno is as a complement to conventional methods 1967 *Price Sw Kr 35*

268 EERO TALA Carcinoma of the lung—A retrospective study with special reference to pre diagnosis period and roentgenographic signs 1967 *Price Sw Kr 35*

269 CARL O HENRIKSON Iodine 125 as a radiation source for odontological roentgenology 1967 *Price Sw Kr 35*

270 CATIONS IN INTRAVASCULAR CONTRAST MEDIA AND DEVELOPMENT OF SPECIFIC METRIZOATE FORMULAS — PHARMACOLOGIC AND CLINICAL STUDIES Proc Symposia at Copenhagen November 1964 and Sandefjord September 1966 1967 *Price Sw Kr 40*

271 ERNA TARKIAINEN Intracostal vein meningorachidography—A technical anatomic and clinical study 1967 *Price Sw Kr 35*

272 ALLAN LUNDERQUIST Arterial segmental supply of the liver—An angiographic study 1967 *Price Sw Kr 35*

273 KAI SETALA MAX SIURALA OTTO NYYSSONEN and ERNA TARKIAINEN Quantitative three dimensional scintillography of the stomach with technetium (^{99m}Tc) 1967 *Price Sw Kr 30*

274 PER BERGSJO Radiation induced early changes in size and vascularity of cervical carcinoma—A colpophotographic and clinical study 1968 *Price Sw Kr 35*

275 SUNE ERICSON The parotid gland in subjects with and without rheumatoid arthritis 1968 *Price Sw Kr 40*

276 ROLF JENSEN Anterior teeth relationship and speech—Studies using cineradiography synchronized with speech recording 1968 *Price Sw Kr 35*

277 SVEN AHLBACK Osteoarthrosis of the knee—A radiographic investigation 1968 *Price Sw Kr 35*

278 IRÉNE SJÖGREN KJELL BERGSTROM and HERMAN LODIN Echoencephalography in infants and children Comparison with cerebral pneumography in measuring ventricular size 1968 *Price Sw Kr 35*

279 BERTIL JARPLID Radiation induced asymmetry and lymphoma of thymus in mice 1968 *Price Sw Kr 35*

280 ERKKI M LAASONEN Information transmission in roentgen diagnostic chains—Experimental and clinical studies 1968 *Price Sw Kr 35*

281 RASMUS STENSTRÖM Arthrography of the knee joint in children—Roentgenologic anatomy diagnosis and the use of multiple discriminant analysis 1968 *Price Sw Kr 35*

282 KARL KARLSTEDT Carcinoma of the uterine corpus—Factors bearing on the curability 1968 *Price Sw Kr 35*

283 LEO STJERNVALL Pharmacodynamic response of epidermal hyperplasias to topical vinblastine treatment 1968 *Price Sw Kr 35*

284 HANS FLODH Distribution and kinetics of labelled vitamin B_{12} 1968 *Price Sw Kr 35*

285 ERKKI KOIVISTO Comparative study of roentgen diagnostic classifications—Computer analysis of 124 496 roentgen reports 1969 *Price Sw Kr 35*

286 JORGEN JENSEN Malformations of the inner ear in deaf children—A tomographic and clinical study 1969 *Price Sw Kr 35*

287 PENTTI J TASKINEN Radiotherapy and TNM classification of cancer of the larynx—A study based on 1 447 cases seen at the Radiotherapy Clinic of Helsinki during 1936 1961 1969 *Price Sw Kr 35*

288 ROBERT T NASH Decision processes employing radioisotope scanning 1969 *Price Sw Kr 35*

289 SIRKKA WILJASALO Lymphographic polymorphism in Hodgkin s disease—Correlation of lymphography to histology and duration 1969 *Price Sw Kr 35*

290 ULF WELANDER Multicolor combination images in subtraction angiography—A new photographic method and its applications 1969 *Price Sw Kr 40*

291 ILONA SCHRECK PUROLA Failure of malignant epidermal cells to respond to vinblastine sulfate—A study in skin tumor resistant mice 1969 *Price Sw Kr 35*

292 GIOVANNI RUGGIERO GIANFRANCO CRISTI and CLAUDIO TREVISAN Clinical aspects of encephalography 1969 *Price Sw Kr 30*

293 PEKKA VIRTAMA and TAPIO HELELA Radiographic measurements of cortical bone—Variations in a normal population between 1 and 90 years of age 1969 *Price Sw Kr 20*

294 L STJERNVALL E E NISKANEN and J TARKKANEN Penetration of cytoplasmic barrier in malignant epid rmal hyperplasia by col hicine in dimethyl sulfoxide—A polarization microscopic study in skin tumor resistant mice 1969 *Price Sw Kr 20*

295 KAARINA TOURI KAISILA Heart size determination by photofluorography 1970 *Price Sw Kr 35*

296 HANS ROVSING Otosclerosis—A tomographic-clinical study 1970 *Price Sw Kr 35*

297 PER LANGELAND Population screening for female breast tumours A clinical investigation 1970 *Price Sw Kr 35*

298 JOHAN EDGREN Effect of cysteine on chromosome aberrations induced by radiation of human lymphocytes in vitro 1970 *Price Sw Kr 30*

299 RUNE SUNDGREN Selective angiography of the left gastric artery 1970 *Price Sw Kr 35*

300 NIELS KROIGAARD The lower urinary tract in infancy and childhood—Micturition cinematography with simultaneous pressure flow measurement 1970 *Price Sw Kr 35*

301 M VIIKERI Ultrasound examination of pleural plaques—Experimental pathologic and clinical studies 1970 *Price Sw Kr 35*

302 INGEMAR JOELSSON Radiotherapy of carcinoma of the uterine cervix with special regard to external irradiation 1970 *Price Sw Kr 35*

303 KAARINA AANTAA Location of the placenta — A comparison between radiography ultrasound thermography isotopes 1971 *Price Sw Kr 25*

304 LENNART DIENER Intraosseous phlebography of the lower limb—Postmortem investigation of thrombotic venous disease 1971 *Price Sw Kr 40*

305 BERNDT STROMBERG The normal and diseased superficial flexor tendon in race horses—A morphologic and physiologic investigation 1971 *Price Sw Kr 35*

306 TRYGVE AAKHUS Angiography in acute mechanical obstruction of the small intestine 1971 *Price Sw Kr 40*

A C T A   R A D I O L O G I C A

PUBLISHED BY THE SOCIETIES OF MEDICAL RADIOLOGY IN
DENMARK FINLAND NORWAY AND SWEDEN

Vol 19
Fasc 1 A

DIAGNOSIS

1978

POSTMORTEM RADIOGRAPHY OF THE SUBARACHNOID CISTERNS

M LINDQVIST and A MÖLLER

The anatomy of the subarachnoid cisterns was described by KEY & RETZIUS (1875) DANDY (1919) outlined radiographically the cisterns after injecting air into the lumbar subarachnoid space The normal radiographic anatomy of the subarachnoid cisterns was reported in detail by LILIEQUIST (1959)

The corrosion technique has been used to reproduce anatomic structures for many years Originally injectible organic pastes were used e g mixtures of mastic and wax (HYRTL 1873) Later these were replaced by metals with low melting point (RETZIUS 1900) and celloidin (LOCKE & NAFFZIGER 1924 *HJORTSJÖ 1948*) More recently various plastics have been used predominantly (TOMPSETT 1956)

Corrosion casts suitable for radiographic examination were prepared by HJORTSJÖ who added red lead to celloidin solution and by WESTBERG (1963) who mixed barium sulphate with plastics

ARNELL (1932) carried out postmortem radiography of skulls after injecting water soluble contrast medium into the cisterna magna The contrast medium was injected with the cadavers in the lateral position and films were taken with vertical beam direction

---

From the Department of Neuroradiology (Director B Liliequist) Umeå University Hospital S-901 85 Umeå and the Department of Neuroradiology (Director T Greitz) Karolinska Sjukhuset, S-104 01 Stockholm Sweden Supported by grants from Svenska Sällskapet for Medicinsk Forskning and from the Axel och Margaret Ax:son Johnsons Stiftelse Submitted for publication 3 June 1977

# A C T A R A D I O L O G I C A

PUBLISHED BY THE SOCIETIES OF MEDICAL RADIOLOGY IN
DENMARK FINLAND NORWAY AND SWEDEN

Vol 19
Fasc 1 A

DIAGNOSIS

1978

POSTMORTEM RADIOGRAPHY OF THE SUBARACHNOID CISTERNS

M LINDQVIST and A MÖLLER

The anatomy of the subarachnoid cisterns was described by KEY & RETZIUS (1875) DANDY (1919) outlined radiographically the cisterns after injecting air into the lumbar subarachnoid space The normal radiographic anatomy of the sub arachnoid cisterns was reported in detail by LILIEQUIST (1959)

The corrosion technique has been used to reproduce anatomic structures for many years Originally injectible organic pastes were used e g mixtures of mastic and wax (HYRTL 1873) Later these were replaced by metals with low melting point (RETZIUS 1900) and celloidin (LOCKE & NAFFZIGER 1924 HJORTSJÖ 1948) More recently various plastics have been used predominantly (TOMPSETT 1956)

Corrosion casts suitable for radiographic examination were prepared by HJORTSJÖ who added red lead to celloidin solution and by WESTBERG (1963) who mixed barium sulphate with plastics

ARNELL (1932) carried out postmortem radiography of skulls after injecting water soluble contrast medium into the cisterna magna The contrast medium was injected with the cadavers in the lateral position and films were taken with vertical beam direction

---

From the Department of Neuroradiology (Director B Liliequist) Umeå University Hospital S 901 85 Umeå and the Department of Neuroradiology (Director T Greitz) Karolinska Sjukhuset S-104 01 Stockholm Sweden Supported by grants from Svenska Sällskapet för Medicinsk Forskning and from the Axel och Margaret Ax son Johnsons Stiftelse Submitted for publication 3 June 1977

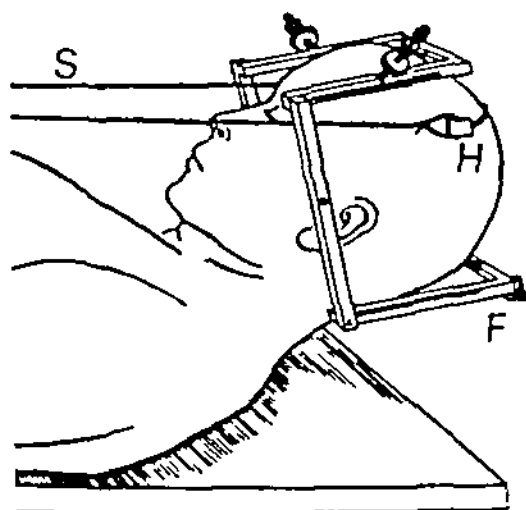


Fig 1 Sterotactic frame of Leksell (F) mounted on the head which is kept in flexed position by two strings (S) attached with hooks (H)

LILIEQUIST injected barium gelatin solutions into the subarachnoid cisterns of cadavers and examined the isolated brain cistern specimens using radiography in cluding tomography He also prepared plastic casts of the cisterns

A stereotactic technique for the evaluation of experimentally produced intra cranial expanding processes was described by GREITZ et coll (1972) This technique was used in a detailed analysis of the deformity of the fourth ventricle as a result of expanding lesions in the posterior cranial fossa (CORRALES & GREITZ 1972)

However no systematic investigation of the effects on the appearance of the *cisterns produced by expanding lesions in the posterior fossa* has been published Therefore a stereotactic technique for postmortem cisternography was elaborated permitting evaluation of the deformation of the cisterns associated with experimental space occupying lesions in the posterior fossa The results using this technique will be reported separately

Technique

Postmortem cisternography was carried out in patients without signs of intra cranial disease most of them elderly The technique required that the cisterns be demonstrated in situ before and after the introduction of an experimental balloon tumour

Preliminary experiments revealed that LILIEQUIST s technique using barium gelatin was unsuitable because the contrast material solidified too rapidly especially in narrow spaces Neither could liquid plastic material of the type used by TOMPSETT in preparing anatomic casts be employed as this material did not provide adequate radiographic contrast Attempts using plastics with barium sulphate (WESTBERG) also failed because the barium all too quickly formed a sediment in the liquid plastic

The following technique proved adequate A plastic tube (inner diameter 3 mm) was introduced into the subarachnoid space in a cranial direction via a laminectomy



Fig 2 Postmortem cisternography with water soluble contrast medium Metal co-ordinate frame for application of stereotactic methods a) A p b) lateral projection

in the upper thoracic region and a ligature fastened tightly around the dura The corpse was then placed in the supine position and a stereotactic frame (LEKSELL 1949) was mounted on the skull so that films could be taken in the lateral projection and in an almost half axial a p projection (Fig 1) A burr hole was made in the frontal bone to allow drainage of the cerebro-spinal fluid but otherwise the skull was not opened

Cisternography using water soluble contrast medium The contrast medium (ca 40 ml) was injected into the thoracic subarachnoid space and films of the skull exposed (Fig 2) For exposures at 90 kV a concentration of 150 mg I/ml was found to be optimum As a rule lateral projections gave satisfactory information about the shape of the cisterns whereas a p projections were generally less informative primarily because the stereotactic apparatus did not permit optimum half axial projection of the head

Cisternography using contrast enhanced plastic material Commercially available polymethyl methacrylate sold as Svebond Rapid (Svedia Dental Industry Enkoping Sweden) was mixed with red lead in the following proportions methacrylate powder 45 g methacrylate fluid 50 ml and red lead 20 g The freshly mixed solution has a watery consistency but becomes syrup like after ca 10 min at room temperature The solidification process which is a result of chemical reaction takes place within approximately one hour and is accompanied by a decrease in the volume of the plastic mass of about 4 per cent The time taken for solidification can be extended by storing the solution in a cold water bath The red lead gives the plastic a homogeneous attenuation which in the proportions used is approximately the same as that of the water soluble contrast medium

The freshly mixed plastic solution (40–50 ml) was injected into the subarachnoid space via the plastic tube The injection was performed slowly at a rate of about 15 ml/min More rapid injection sometimes resulted in a subdural deposit of plastic




Fig 3 Postmortem cisternography with plastic red lead mixture Lateral view a) before and b) after the introduction of balloon tumour

solution probably due to a rupture of the arachnoid membrane of the cisterna magna The radiographic images of the cisterns were identical to those obtained when using water soluble contrast medium (Fig 3)

Plastic casts When the injected plastic solution had solidified the posterior fossa and its contents were removed in one piece as described by GREPE (1975) and then immersed in concentrated sodium hydroxide solution After 3 to 4 days satisfactory maceration of skeletal and soft tissue had occurred to allow the intact cast to be removed rinsed in running water and finally in dilute hydrogen peroxide solution The resulting plastic cast could be examined directly as well as by radiology including tomography (Fig 4)

Evaluation of cistern deformation by experimental balloon tumours The subarachnoid space in the posterior fossa and the ventricular system were first filled with water soluble contrast medium The position of the balloon tumour was chosen on the basis of information obtained from a p and lateral films and its co ordinates determined The water soluble contrast medium was then drained and replaced by the plastic red lead solution and a p and lateral films were exposed (Fig 3 a) A balloon catheter was then immediately introduced into the posterior fossa to the previously determined position using the stereotactic technique of LEKSELL as described by GREITZ et coll The balloon was inflated with air (20 ml) resulting in a balloon tumour with about 3 cm diameter A p and lateral projections were again exposed (Fig 3 b) within 8 to 10 min following injection of the plastic solution Water soluble contrast medium was necessary for the initial part of the procedure because calculation was so time-consuming as to allow the plastic solution to solidify before the balloon could be positioned After one hour the posterior fossa and its contents were taken out in one piece and the plastic model of the cisterns deformed by the balloon tumour was prepared



a



b

Fig 4 Lateral views of plastic cast a) Photograph b) Radiographic appearance

SUMMARY

A technique has been developed for stereotactic postmortem cisternography using water soluble contrast medium and plastic material with enhanced attenuation by the addition of red lead The latter technique can be used for the preparation of plastic casts of the cisterns accessible for analysis by radiologic means as well as by direct inspection

ZUSAMMENFASSUNG

Eine Technik zur postmortalen stereotaktischen Zisternographie unter Verwendung eines wasserloslichen Kontrastmittels und eines Plastmaterials mit erhohter Absorption durch Zusats von Meninge wurde entwickelt Diese Technik kann verwendet werden um Plast formen der Zisternen herzustellen die fur radiologische und direkte Inspektion geeienet sind

RÉSUME

Les auteurs ont mis au point une technique de cisternographie stereotaxique post mortem utilisant un moyen de contraste hydrosoluble et une matière plastique dont l atténuation est augmentee par addition de minium rouge Cette technique peut etre utilisee pour la préparation de moulages plastiques des citernes utilisables pour l étude par les moyens radiologiques ainsi que par l inspection directe

REFERENCES

ARNELL S Encephalography with solutions of contrast-salts Acta radiol 13 (1932) 43
CORRALES M and GREITZ T Fourth ventricle II Tumours of the cerebellum Acta radiol Diagnosis 12 (1972) 241
DANDY W E Roentgenography of the brain after injection of air into the spinal canal Ann Surg 70 (1919) 397
GREITZ T CORRALES M and MOLLER A Stereotaxic methods in the investigation of experimentally produced intracranial displacements Acta radiol Diagnosis 12 (1972) 776
GREPE A Anatomy of the cranial nerves in the basal cisterns A radiologic post mortem investigation Acta radiol Diagnosis 16 (1975) 17
HJORTSJO C H Die Anatomie der intrahepatischen Gallengange beim Menschen mittels Rontgen und Injektionstechnik studiert C W K Gleerup Lund 1948
HYRTL J Die Corrosionsanatomie und ihre Ergebnisse Braumuller Wien 1873
KEY A und RETZIUS G Studien in der Anatomie des Nervensystems und des Bindegewebes Vol 1 P A Norstedt & Soner Stockholm 1875
LEKSELL L A stereotaxic apparatus for intracerebral surgery Acta chir scand 99 (1949) 229
LILIEQUIST B The subarachnoid cisterns An anatomic and roentgenologic study Acta radiol (1959) Suppl No 185
LOCKE C E and NAFFZIGER C H The cerebral subarachnoid system Arch Neurol Psychiat 12 (1924) 411
RETZIUS G Die Gestalt der Hirnventrikel des Menschen nach Metallausgussen Biol Untersuch 9 (1900) 45
TOMPSETT D H Anatomical techniques E & S Livingstone London 1956
WESTBERG G Anatomic casts made by a corrosion method Acta radiol Diagnosis 1 (1963) 946

Book review

COMPUTED BRAIN AND ORBITAL TOMOGRAPHY TECHNIQUE AND INTERPRETATION By Carlos F Gonzalez, Charles B Grossman and Enrique Palacios 276 pages 338 figures (933 illustrations) John Wiley & Sons New York 1976 Price $ 36 85

The arrival of a lavish new atlas-style reference for CT scanning of the brain and orbit is advertised in Europe A closer look at the product gives rise to mixed feelings

To start with the positive impressions the organization of the material on an etiologic basis offers definite advantages Features of particular merit include the use of an acronymic labeling system throughout the text and illustrations the use of at least one line diagram to indicate level and inclination of each CT section displayed on a lateral skull drawing with main topographic landmarks of the brain the graphic approach of pres*ntation with integrated t xt segments after concise introductory chapters on technique artifacts diagnostic method selection and correlative anatomy the use of correlative illustrations by conventional neuroradiologic methods as well as brain specimens Almost all of the CT s*ctions apply the 160 160 matrix

The authors avoid the widespread misuse of the term density for attenuation value and have chosen the abbreviation *Vat* which is used throughout the book

On the negative side the following points may be noted The labeling of the illustrations is not of professional standard—coarse uneven black and white lines (apparently drawn by hand on the copies like many arrows and other symbols) traverse the images to reach the region to be labeled The letters on the anatomic specimen images are often indistinct or defective These would be only marginal comments but for the fact that the lab ling is extensive even to the point of making some illustrations virtually unreadable In particular the CT sections in the chapter on anatomy give the impression of lettered porcupines disastrous for the didactic message

The addition of angiographic and pneumographic information to the CT sections pres*nted is often helpful for a thorough understanding of intricate details in a given case but for some reason correlation with isotope scintigraphy has not been included (with but one exception)

The size of the conventional radiographic illustrations in general appears unnecessarily large at the expense of the CT images which could actually be improved by some enlargement In the chapter on the diagnostic approach no less than 9 pages are taken up by conventional radiographic case illustrations without any accompanying CT sections or references to other parts of the book Structured information on the authors collective experience of more than 20 000 CT procedures is not easy of access too often hidden at random in the legends of the atlas section if available at all Consistent information on contrast enhancement is not given and num*rical information on attenuation levels is scarce

The section on orbital pathology is disappointing More illustrations or another presentation might have improved the situation

The initial text section is brief The value of the book as a source of reference in the daily routine would have been enhanced considerably by pertinent discussions of problems such as measuring errors caused by beam geometry and physical factors dose considerations the trade-off situation of information versus dose differential diagnostic problems and the praxis of contrast enhancement to mention a few

To sum up this book is a no quite successful marriage between the atlas format and the ambition to offer a concise report on the present state of the art of CT examination of the head Unfortunately it has too little to offer the specialist in the field while the information is neither structured nor comprehensive enough to satisfy the radiologist in training

Ulf Bergvall

FROM THE DEPARTMENT OF DIAGNOSTIC RADIOLOGY UNIVERSITY OF LINKÖPING S 581 85
LINKÖPING SWEDEN

ANGIOGRAPHIC LOCALIZATION OF PARATHYROID ADENOMAS

G FAGERBERG

Primary hyperparathyroidism is caused by adenomas or less frequently hyper plasia of the parathyroid glands The treatment is surgical and requires removal of all pathologic tissue Unfortunately not a few patients have more than one lesion and in primary neck dissection an identification of all parathyroids must be aimed at The normal glands are small as pathologic glands also are occasionally and fre quently they vary in location A thorough neck dissection may be a frustrating task even in experienced hands Reliable methods for preoperative localization of para thyroid adenomas have long been desired and angiographic localization of these tumours has become a challenge

Anatomy The parathyroid glands form bean shaped structures 4 to 6 mm in size usually situated two on each side in close proximity to the posterior surface of the thyroid gland Only 2 or 3 or as many as 5 or 6 glands may be present in up to 20 per cent of cases The position may vary considerably especially that of the lower glands Embryologically the lower glands arise from the third pharyngeal pouch as does the thymus which they accompany for a varying distance on its way towards the mediastinum The upper parathyroid glands arising from the fourth pouch have a more constant position at the level of the cricoid cartilage HALSTED & EVANS (1907) investigated the normal vascular anatomy of the parathyroid glands in autopsy specimens Each gland was found to be supplied by one minute artery passing into the gland through a distinct hilum The lower glands when situated in an ordinary position were as a rule supplied by short branches of the inferior thyroid artery

Submitted for publication 13 May 1977

Parathyroids caudally to the lower margin of the thyroid might have feeding arteri s several centimeters in length The upper parathyroids were invariably fed by short branches of the inferior thyroid artery or from anastomosing branches joining the inferior and superior thyroid arteries Thus the inferior thyroid artery appeared to be the main feeding artery of all parathyroid glands

The inferior thyroid artery normally forms a branch of the thyreocervical trunk which usually arises from the subclavian artery about one cm distal to the vertebral artery It runs a typical S shaped course the first loop being directed cranially The caudal loop reaches the dorsal surface of the thyroid where it divides into cranial and caudal branches

However considerable variations exist in this gross vascular anatomy (DASLLER & ANSON 1959 ZACHRISSON 1976) In about 17 per cent the thyreocervical trunk is not developed The inferior thyroid artery may then originate directly from the sub clavian artery in rare cases from the vertebral or common carotid arteries or from the brachiocephalic trunk Rarely the inferior thyroid artery may be absent and then replaced by a thyroid ima artery which may originate from the aortic arch or any of its larger branches

Previous investigations The first preoperative angiographic localization of para thyroid adenomas was reported by SELDINGER (1954) The presence of a parathyroid tumour was inferred by an observed displacement of branches from the inferior thyroid artery NEWTON & EISENBERG (1966) described the angiographic findings in 14 patients with primary hyperparathyroidism By selective angiography of the in ferior thyroid artery and by subclavian angiography they correctly diagnosed ade nomas in 6 patients In 4 cases richly vascularized glands with abnormal vessels besides displacement of arteries were demonstrated DOPPMAN et coll (1969) em phasized the diagnostic value of accumulation of contrast medium in parathyroid adenomas which could be achieved by selective injection in the inferior thyroid artery They also recommended routine use of the subtraction technique KUNTZ & GOLDSMITH (1972) examined 21 patients with selective inferior thyroid angiography prior to surgery Out of 21 operated adenomas 12 were accurately demonstrated angiographically and by comparison with thyroid scans another 4 adenomas could be located They concluded that displacement of arteries was unreliable in lateralizing parathyroid adenomas no hyperplastic glands were encountered An ectopic adenoma in the anterior mediastinum diagnosed by selective internal mammary angiography was reported by DODDS et coll (1968)

Angiographic technique The first 22 patients with clinical diagnosis of primary hyperparathyroidism submitted to preoperative angiography were catheterized by the axillary route with the purpose of obtaining selective injection in the inferior thyroid artery However for reasons that will be discussed later this m thod was abandoned The following technique has been found to be the most suitabl•

Table

Operative and angiographic findings in 35 patients with primary hyperparathyroidism

	Operation	Angiography		Accuracy (per cent)
		Pos	Neg	
Total material (35 patients)				
Adenomas	28	21	7	75
Hyperplasia	16	3	13	
Primary operation (26 patients)				
Adenomas	20	14	6	71
Hyperplasia	14	3	11	
Re-operation (9 patients)				
Adenomas	8	7	1	87
Hyperplasia	-	0	2	

The procedure is carried out in general anaesthesia. Catheterization is performed by the femoral route with a Cook H catheter (HINCK et coll. 1967). The side to be injected is turned upwards for an oblique a.p. view and a tourniquet is placed on the upper arm. For examination of the right side the tip of the catheter is placed in the proximal part of the subclavian artery or in the brachiocephalic trunk. In order to fill the subclavian as well as the common carotid artery 30 ml of contrast medium is injected. On the left side the tip of the catheter is placed in the proximal part of the subclavian artery before the origin of the vertebral artery. In this position 20 ml of contrast medium is injected. To achieve filling of the left superior thyroid artery 12 ml of contrast medium is injected selectively into the left common carotid artery. In some older patients the femoral approach failed because of tortuosity of the vessels and the axillary route was used. In such cases the left common carotid artery was punctured percutaneously. In the brachiocephalic trunk and subclavian artery Isopaque Coronar (Nyegaard) containing 370 mg I/ml was injected at a rate of 10 to 15 ml/s, in the common carotid artery Isopaque Cerebral (Nyegaard) containing 280 mg I/ml at a rate of 12 ml/s. Each series contained 18 films exposed at 0.5 s intervals. Stereoscopic views were obtained with double tube alternate exposures.

Material and Results

In the total series of 39 patients 4 were excluded due to incomplete preoperative angiography or incomplete neck exploration. The assessable material thus consisted of 35 patients, 8 males and 27 females, with symptoms and signs of primary hyperparathyroidism in whom 81 angiographies were performed. In 70 of these the injection was performed in the subclavian artery or in the brachiocephalic trunk and in 4 selectively into the inferior thyroid artery. Left common carotid angiography


Fig 1 a


Fig 1 b


Fig 2

Fig. 1 Solid parathyroid adenoma weight 0 153 g Proximal right subclavian artery injection femoral approach oblique view (general anaesthesia) Early homogeneous accumulation of contrast medium in the small adenoma with a typical elongated shape

Fig 2 Solid parathyroid adenoma weight 1 33 g Semi-selective right inferior thyroid artery injection femoral approach oblique view (general anaesthesia) Extremely elongated adenoma (↔) with early accumulation of contrast medium Branches from the inferior thyroid artery (→) are stretched and displaced by the enlarged thyroid lobe

was performed in 7 patients In 22 patients the axillary route was used and in 13 the femoral

No serious complications were encountered With the axillary approach ha ma tomas of notable size sometimes developed but no symptoms or signs of brachial plexus injury Neither cerebral nor spinal complications occurred In 2 cas s small subintimal deposits of contrast medium were observed

Twenty six patients were explored and 20 adenomas and 14 hyp rplastic glands were found at the operation A correlation between angiography and surgery is given in the Table Of these 34 lesions 17 were demonstrated at angiography 14 were adenomas Five patients in this group had more than one lesion at op ration Thus in 2 cases an adenoma was combined with a hyperplastic gland One patient had 2 and another 3 hyperplastic glands The fifth patient had one adenoma and 3 hyper plastic glands In these 5 cases of multiple lesions angiography disclos d one lesion in each of 3 patients one adenoma and two hyperplastic glands

Nine patients were submitted to angiography before re op ration Of these 5 had previously been explored for primary hyperparathyroidism but symptoms and signs of the disease still remained while partial thyroidectomy for thyroid disease had been performed in 4 patients At re operation an adenoma was found in 8 patients in this group the remaining patient had two hyperplastic glands At angiography 7 of the adenomas but none of the hyperplastic glands were demonstrated



Fig 3



Fig 4

Fig 3 Cystic parathyroid adenoma (→) situated high in the neck Selective injection of the left inferior thyroid artery axillary approach (local anaesthesia) In spite of a large feeding branch from the inferior thyroid artery irregular early accumulation of contrast medium in the parathyroid adenoma less intense than in the thyroid by selective injection Artifact in the subtraction film is due to movements of the larynx caused by the injection of contrast medium

Fig 4 Cystic parathyroid adenoma Right subclavian artery injection femoral approach oblique view (general anaesthesia) Highly vascular adenoma (→) with irregular early accumulation and early venous drainage to inferior thyroid vein (↔)

Angiographic appearances

Adenomas The typical angiographic appearance of a solid parathyroid adenoma is a homogeneous tumour with smooth regular margins and accumulation of contrast medium in the early arterial phase before the normal thyroid accumulation phase of long duration and of remarkable intensity in relation to the volume of the lesion Normally single tumour vessels cannot be identified within solid parathyroid adenomas They often have a distinct ovoid or elongated shape (Figs 1 2)

Three adenomas were cystic As might be expected in 2 of these the accumulation of contrast medium was irregular and so were the outlines of these adenomas One cystic adenoma was ectopic in a high cervical position below the mandibular angulus it had been overlooked at two consecutive surgical explorations In spite of its high position it was supplied by a branch from the inferior thyroid artery (Figs 3 4) Another cystic adenoma was found at operation to be supplied by the superior thyroid artery At angiography peripheral branches from this artery were spread apart but no accumulation of contrast medium occurred and the angiographic appearances were considered to be secondary to an enlarged thyroid With the exception of this case displacement of arteries was found to be of no diagnostic value and all diagnoses were based upon the direct demonstration of a tumour

Three adenomas were angiographically located to the upper—anterior—mediastinum One was situated behind the left manubrio clavicular joint one in the mid line just inferior to the jugular incisura and one at the origin of the right common carotid artery (Fig 5) They were all evident only on the subtraction films Especially in this last case of ectopic adenoma stereoscopy was fundamental for the localization



Fig 1 a



Fig 1 b



Fig 2

Fig 1 Solid parathyroid adenoma weight 0 153 g Proximal right subclavian artery injection femoral approach oblique view (general anaesthesia) Early homogeneous accumulation of contrast medium in the small adenoma with a typical elongated shape

Fig 2 Solid parathyroid adenoma weight 1 33 g Semi selective right inferior thyroid artery injection femoral approach oblique view (general anaesthesia) Extremely elongated adenoma (↔) with early accumulation of contrast medium Branches from the inferior thyroid artery (→) are stretched and displaced by the enlarged thyroid lobe

was performed in 7 patients In 22 patients the axillary route was used and in 13 the femoral

No serious complications were encountered With the axillary approach haema tomas of notable size sometimes developed but no symptoms or signs of brachial plexus injury Neither cerebral nor spinal complications occurred In 2 cases small subintimal deposits of contrast medium were observed

Twenty six patients were explored and 20 adenomas and 14 hyperplastic glands were found at the operation A correlation between angiography and surgery is given in the Table Of these 34 lesions 17 were demonstrated at angiography 14 were adenomas Five patients in this group had more than one lesion at operation Thus in 2 cases an adenoma was combined with a hyperplastic gland One patient had 2 and another 3 hyperplastic glands The fifth patient had one adenoma and 3 hyper plastic glands In these 5 cases of multiple lesions angiography disclosed one lesion in each of 3 patients one adenoma and two hyperplastic glands

Nine patients were submitted to angiography before re op ration Of these 5 had previously been explored for primary hyperparathyroidism but symptoms and signs of the disease still remained while partial thyroidectomy for thyroid disease had been performed in 4 patients At re operation an adenoma was found in 8 patients in this group the remaining patient had two hyperplastic glands At angiography 7 of the adenomas but none of the hyperplastic glands were demonstrated



Fig. 6



Fig. 7

Fig. 6 Hyperplastic parathyroid gland, weight 0 182 g Left subclavian artery injection, axillary approach (local anaesthesia) The gland (→) cannot be differentiated from a parathyroid adenoma at angiography

Fig. 7 Small thyroid adenoma Proximal subclavian artery injection, femoral approach, oblique view (general anaesthesia) The tumour has the same early homogeneous accumulation of contrast medium but not the typical elongated shape of a parathyroid adenoma

artery is desirable With this technique adenomas may be demonstrated in about 60 to 80 per cent of cases (NEWTON & EISENBERG DOPPMAN et coll 1969 KUNTZ & GOLDSMITH WELLS et coll 1973 EFSEN et coll 1975) Without doubt a selective injection of the inferior or superior thyroid arteries is superior to a non selective injection and better demonstrates structures supplied by those arteries The experience with parathyroid angiography in this department goes back to 1972 Selective catheterization was sometimes found to be difficult to perform mainly because of individual variations in the vascular supply tortuosity of vessels atheromathosis etc Furthermore a selective injection may give an undesirable early and high contrast of the thyroid (Fig 3) which might obscure small parathyroid lesions In addition it excludes demonstration of other possible ways of arterial supply Even if the inferior thyroid artery is assumed to be the main feeding artery of the parathyroids this is obviously not always the case In patients previously operated upon for thyroid or parathyroid disease the inferior thyroid artery may have been ligated and the normal vascular anatomy be deranged Furthermore the parathyroid glands may have an abnormal vascular supply

A selective angiography of the inferior thyroid artery is thus insufficient in some cases and has to be supplemented by other selective injections or injections into the subclavian and common carotid arteries In the literature spinal complications following subclavian angiography or selective injections in its branches have rarely been reported (EDERLI et coll 1962) For anatomic reasons the risks of injury to the cervical spinal cord will probably be greater when selective injections are attempted (ZACHRISSON)

For these reasons non selective angiography of the brachiocephalic trunk or the subclavian artery appeared more attractive By using the femoral approach the risk of injury to the brachial plexus is avoided and both sides may be examined with the

same catheter However in a few patients tortuosity of the large vessels made catheterization from the femoral artery impossible and the axillary approach had to be chosen

Displacement of arteries was found to be of little diagnostic value Displacement of the inferior thyroid artery or its branches is insignificant for the diagnosis of parathyroid lesions as it may be and in the present material in fact often was secondary to an enlarged thyroid gland In any case it seems improbable that small lesions would cause an evident displacement In patients with previous surgery of the neck displacement of vessels must be an unreliable sign The only way to locate a parathyroid adenoma at angiography is the demonstration of tumour circulation which means that subtraction films of high quality are of paramount importance The arterial injection of contrast medium in the cervical region not infrequently elicits movements of the larynx and pharynx interfering with evaluation of some films This is prevented if general anaesthesia is used which allows for good fixation of the patient The injections and film exposures were performed in apnoea In retrospect examinations performed in general anaesthesia did not increase the number of *lesions detected compared with those carried out with local anaesthesia* However the evaluation was more accurate the lesions better seen and the anatomic structures better defined Some ectopic lesions would probably have been overlooked without good subtraction films

With the technique used the diagnostic accuracy of adenomas was 75 per cent The reason why some adenomas accumulate contrast medium to a lesser degree than others when factors such as localization size and vascularity as found at operation seem equivalent is uncertain It is well known that in primary hyperparathyroidism periods of high hormonal production alternate with periods of lower activity (ALMQVIST et coll 1975) It may be that the accumulation of contrast medium in an adenoma to a certain extent reflects its endocrinic activity

Differentiation between thyroid and parathyroid adenomas is difficult and may sometimes be impossible In thyroid adenomas arteries are as a rule arched around the tumour which often has an irregular accumulation of contrast medium (WICKBOM et coll 1967 ZACHRISSON) These characteristics are quite contrary to the findings in parathyroid adenomas Usually no single vessel is seen in the tumour and the homogeneity of contrast is a striking feature Small thyroid adenomas may however display a similar vascularity In these cases the shape of the lesion may be of value in the differentiation parathyroid adenomas appear ovoid or elongated while thyroid adenomas tend to be spherical This disparity might be due to differences in tissue *composition The parathyroids are soft the longish spaces of the neck might possibly* influence their shape

A preoperative angiography of the neck in patients not previously operated upon will be of limited value as the multiplicity of the disease makes an exploration and identification of all glands necessary On the other hand in patients submitted to re-exploration a preoperative knowledge of the residual vascular anatomy may be

most helpful The angiographic localization of an adenoma in such cases may allow a less extensive exploration and will probably contribute to a decreased morbidity At this department parathyroid angiography is now generally confined to patients previously operated upon for parathyroid or thyroid disease It may also be performed in patients with primary hyperparathyroidism and complicating diseases which make a limited exploration desirable

SUMMARY

The angiographic and operative findings in 35 patients with primary hyperparathyroidism were compared A non selective angiography is proposed The appearance of solid and cystic parathyroid adenomas is described and the differentiation between parathyroid and thyroid adenomas outlined An overall diagnostic accuracy of 75 per cent was achieved The indications for parathyroid angiography are discussed

ZUSAMMENFASSUNG

Die angiographischen und operativen Befunde von 35 Patienten mit primarem Hyper parathyreoidismus werden verglichen Eine nicht selektive Angiographie wird empfohlen Das Bild von soliden und zystischen Parathyreoidea Adenomen wird beschrieben und die Abgrenzung zwischen Adenomen der Parathyreoidea und Thyreoidea wird diskutiert Eine gesamt-diagnostische Genauigkeit von 75 Prozent wurde erreicht Die Indikationen zur Angiographie der Parathyreoidea werden diskutiert

RESUME

L auteur a comparé les signes angiographiques et les constatations opératoires chez 35 malades atteints d hyperparathyroïdisme primaire Il propose une angiographie non selective Il decrive l aspect des adénomes parathyroidiens solides et kystiques et insiste sur la différen ciation entre adénome parathyroidien et thyroidien Il a eu dans l ensemble 75% de diag nostics exacts Il étudie les indications de l angiographie parathyroidienne

REFERENCES

ACKERMAN N B and WINER N Evaluations of methods for localizing parathyroid tumours Amer J Surg 122 (1971) 669

ALMQVIST S HJARN B and WASTHED B The diagnostic value of a radioimmunoassay for parathyroid hormone in human serum Acta endocr 78 (1975) 493

BILEZIKIAN J P DOPPMAN J L POWELL D WELLS S A HEATH D A KETCHAM A S MONCHIK J MALETTE L E POTTS JR J T and AURBACH G D Preoperative localiza tion of abnormal parathyroid tissue Cumulative experience with venous sampling and arteriography Amer J Med 55 (1973) 505

BLATT LYON B ASSER HANSEN B and MYGIND T Peripheral nerve injury as a complica tion of axillary arteriography Acta neurol scand 51 (1975) 29

DASELER E H and ANSON B J Surgical anatomy of the subclavian artery and its branches Surg Gynec Obstet 108 (1959) 149
DODDS W J NEWTON T H and ENLOE L J Parathyroid adenoma of anterior mediastinum demonstrated by preoperative selective arteriography Radiology 91 (1968) 923
DOPPMAN J L HAMMOND W G MELSON G L EVENS R G and KETCHAM A S Staining of parathyroid adenomas by selective arteriography Radiology 92 (1969) 527
— WELLS S A SHIMKIN P M PEARSON K D BILEZIKIAN J P HEATH D A POWELL D KETCHAM A S and AURBACH G D Parathyroid localization by angiographic techniques in patients with previous neck surgery Brit J Radiol 46 (1973) 403
EDERLI A SASSAROLI S and SPACCARELLI G Vertebral angiography as cause of necrosis of the cervical spinal cord Brit J Radiol 35 (1962) 261
EFSEN F BRUUN E LOCKWOOD K and HASNER E Arteriographic exposition of the para thyroids Brit J Surg 62 (1975) 96
EISENBERG H PALOTTA J and SHERWOOD L M Selective arteriography venography and venous hormone assay in diagnosis and localization of parathyroid lesions Amer J Med 56 (1974) 810
HALSTED W S and EVANS H M The parathyroid glandules Their blood supply and their preservation in operation upon the thyroid gland Ann Surg 46 (1907) 489
HINCK V C JUDKINS M P and PAXTON H D Simplified selective femorocerebral angiography Radiology 89 (1967) 1048
KUNTZ C H and GOLDSMITH R E Selective arteriography of parathyroid adenomas Radiology 102 (1972) 21
MCGARITY W C MILES A E and HOFFMAN J C Angiographic diagnosis and localization of endocrine tumours Ann Surg 173 (1971) 583
NEWTON T H and EISENBERG E Angiography of parathyroid adenomas Radiology 86 (1966) 843
SELDINGER S I Localization of parathyroid adenomata by arteriography Acta radiol 42 (1954) 353
WELLS S A DOPPMAN J L BILEZIKIAN J P SHIMKIN P M POWELL D KETCHAM A S and AURBACH G D Repeated neck exploration in primary hyperparathyroidism Localization of abnormal glands by selective thyroid arteriography selective venous sampling, and radioimmunoassay Surgery 74 (1973) 678
WICKBOM I ZACHRISSON B F and HEIMANN P Thyroid angiography Acta radiol Diagnosis 6 (1967) 497
ZACHRISSON B F Thyroid angiography Acta radiol (1976) Suppl No 350

FROM THE DEPARTMENT OF RADIOLOGY AND RADIOLOGIC RESEARCH LABORATORY (DIRECTOR PROF H W FISCHER) UNIVERSITY OF ROCHESTER SCHOOL OF MEDICINE AND DENTISTRY ROCHESTER NEW YORK 14642 U.S.A

RENAL CIRCULATION AFTER CARDIAC ARREST

Angiography and microangiography

SHU REN LIN and MARTTI KORMANO

Ischemia of sufficient duration will cause acute renal failure which today is commonly associated with transplanted kidneys Investigations of the effects of normovolemic hypotension or ischemia on intrarenal hemodynamics as evaluated using histologic methods radioactive gas wash out techniques microsphere distribution analyses or nephroangiography have however arrived at widely divergent conclusions

Hemorrhagic hypotension has invariably caused marked radiographic cortical perfusion defects (KUPIC & ABRAMS 1968 KOROBKIN 1972 LAVENDER & SHERWOOD 1972) Similar impairment of cortical perfusion after normovolemic hypotension was reported by others after temporary arterial occlusion (SELKURT 1945 FRIEDMAN et coll 1954 SEEHAN & DAVIS 1959 HINSHAW et coll 1963 MCNAY & ABE 1970 STEIN et coll 1971 SUMMERS & JAMISON 1971 DIETHELM & WILSON 1971 BRODMAN et coll 1974) However other authors have suggested that renal blood flow returns promptly to control levels after similar periods of ischemia (PHILLIPS & HAMILTON 1948) Recently normal cortical perfusion following 2 or 3 hours of arterial clamping (RILEY et coll 1975 BEST et coll 1976) after normovolemic hypotension (SHANSER et coll 1975) or after ischemia preceding transplantation (VINIK et coll 1969) has been reported

---

Submitted for publication 11 February 1977

DASELER E H and ANSON B J Surgical anatomy of the subclavian artery and its branches Surg Gynec Obstet 108 (1959) 149

DODDS W J NEWTON T H and ENLOE L J Parathyroid adenoma of anterior mediastinum demonstrated by preoperative selective arteriography Radiology 91 (1968) 923

DOPPMAN J L HAMMOND W G MELSON G L EVENS R G and KETCHAM A S Staining of parathyroid adenomas by selective arteriography Radiology 92 (1969) 527

— WELLS S A SHIMKIN P M PEARSON K D BILEZIKIAN J P HEATH D A POWELL D KETCHAM A S and AURBACH G D Parathyroid localization by angiographic techniques in patients with previous neck surgery Brit J Radiol 46 (1973) 403

EDERLI A SASSAROLI S and SPACCARELLI G Vertebral angiography as cause of necrosis of the cervical spinal cord Brit J Radiol 35 (1962) 261

EFSEN F BRUUN E LOCKWOOD K and HASNER E Arteriographic exposition of the parathyroids Brit J Surg 62 (1975) 96

EISENBERG H PALOTTA J and SHERWOOD L M Selective arteriography venography and venous hormone assay in diagnosis and localization of parathyroid lesions Amer J Med 56 (1974) 810

HALSTED W S and EVANS H M The parathyroid glandules Their blood supply and their preservation in operation upon the thyroid gland Ann Surg 46 (1907) 489

HINCK V C JUDKINS M P and PAXTON H D Simplified selective femorocerebral angiography Radiology 89 (1967) 1048

KUNTZ C H and GOLDSMITH R E Selective arteriography of parathyroid adenomas Radiology 102 (1972) 21

MCGARITY W C MILES A E and HOFFMAN J C Angiographic diagnosis and localization of endocrine tumours Ann Surg 173 (1971) 583

NEWTON T H and EISENBERG E Angiography of parathyroid adenomas Radiology 86 (1966) 843

SELDINGER S I Localization of parathyroid adenomata by arteriography Acta radiol 42 (1954) 353

WELLS S A DOPPMAN J L BILEZIKIAN J P SHIMKIN P M POWELL D KETCHAM A S and AURBACH G D Repeated neck exploration in primary hyperparathyroidism Localization of abnormal glands by selective thyroid arteriography selective venous sampling and radioimmunoassay Surgery 74 (1973) 678

WICKBOM I ZACHRISSON B F and HEIMANN P Thyroid angiography Acta radiol Diagnosis 6 (1967) 497

ZACHRISSON B F Thyroid angiography Acta radiol (1976) Suppl No 350

Table 1

Distribution of material

Duration of arrest	Duration of maintenance	Nephro-angiography	Micro-angiography	Histology
Control	5 h	+3	–	+*
Control	5 h	-3	–	
Control	5 h	+3	–	
Control	5 h	3	–	*
Control	5 h	3	+	–
Control	5 h	3	-	
Control	5 h	–	+	–[1]
3 min	4 h	3		–
6 min	5 h	-3		–
7 min	4 h	3	–	+
7½ min	5 h	+4	–	+
8 min	5 h	4	–	–
8 min	4 h	3	–	+*[2]
8½ min	3 h	+2	–	+*
9 min	5 h	+3	+	+
11 min	5 h	3	–	+
11 min	10 min	–	–	*
12 min	5 h	2	+	+
12 min	5 h	3		+
14 min	30 min	–	–	+
14 min	5 h	3	–	+[3]

[1] Significant hemorrhage blood pressure maintained with Aramine
[2] Five mg of Aramine given imm diately after recovery
[3] Two mg of Aramine given ½ hour after resuscitation
* Animals marked with asterisk were given 15 ml kg of 1 Trypan blue in saline 10 min before killing in order to demonstrate eventual blood brain barrier damage

mine) administration was needed in 3 cases to raise and maintain blood pressure at a minimum of 100 mmHg All animals except one which developed post arrest hyper tension had blood pressures of 100 to 200 mmHg throughout the post arrest period the pressure deviated less than 25 per cent from the pre arrest level

Nephroangiography A polyethylene (6 5 French) catheter was introduced through the other femoral artery Selective angiography of one kidney was performed before the arrest and 1 to 3 h and 4 to 5 h after arrest Angiography was done in the supine position using 2× magnification technique Seven ml of meglumine diatrizoate (Hypaque 60) was injected in one second with a Cordis injector Focus to film dis tance was 1 m focal spot 0 3 mm A program of 2 exposures per s for 3 s and 5 exposures per s for 5 s was employed using the Siemens Elema film changer

Table 2

Angiographic findings in control and after cardiac arrested kidneys (mean scores ± SD)

No of animals		Parameters (score range)	Baseline	1–3 h	4–5 h
6	Control	Demarcation of cortex and medulla (3 to 1)	2 8±0 4	2 5±0 5	2 8±0 4
		Cortical perfusion (4 to 1)	3 3±1 2	3 3±1 2	3 3±1 2
		Nephrographic effect (4 to 1)	2 3±0 5	2 3±0 5	2 5±0 8
		Arterial diameter (interlobar artery) (mm)	2 5±0 3	2 4±0 3	2 4±0 3
		Arterial phase (s)	1 7±0 2	1 6±0 2	1 7±0 2
		Venous phase (s)	2 3±0 3	2 3±0 4	2 4±0 5
2	Short arrest 3 and 6 min	Demarcation of cortex and medulla (3 to 1)	2 5±0 7	2 5±0 7	2 0±0
		Cortical perfusion (4 to 1)	3 5±0 7	3 5±0 7	3 5±0 7
		Nephrographic effect (4 to 1)	2 0±0	2 0±0	2 5±0 7
		Arterial diameter (interlobar artery) (mm)	2 0±0	2 0±0	2 0±0
		Arterial phase (s)	1 5±0	1 5±0	1 5±0
		Venous phase (s)	2 5±0 7	2 7±1 0	1 7±0 3
10	Long arrest 7 to 14 min	Demarcation of cortex and medulla (3 to 1)	3 0±0	1 8±0 6	1 5±0 9
		Cortical perfusion (4 to 1)	3 6±0 5	2 5±1 3	2 6±1 4
		Nephrographic effect (4 to 1)	2 8±0 6	1 9±0 7	1 7±0 6
		Arterial diameter (interlobar artery) (mm)	2.2±0 6	1 8±0 8	1 8±0 8
		Arterial phase (s)	1 7±0 2	2.7±2 4	2 5±1 7
		Venous phase (s)	2 5±0 4	3 7±1 8	5 0±2 4

Immediately after each injection the renal catheter was placed at the lower abdominal aorta and was constantly infused with heparinized saline solution

The films were evaluated by three radiologists unaware of the individual experimental procedure using the following grading scale (1) demarcation of cortex and medulla (2) cortical perfusion (3) degree of nephrographic effect (4) diameters of an interlobar artery (5) duration of the arterial phase and (6) time of first venous return

(1) Demarcation of the cortex and the medulla 3+ sharp demarcation 2+ partially blurred 1+ no difference between the cortex and medulla

(2) Cortical perfusion Scales for estimating extent of nonperfusion in the cortex were as follows 4+ normal perfusion of contrast medium to the entire cortex 3+ perfusion defect of less than 1/4 of the total cortex 2+ perfusion defect of more than 1/4 but less than 1/3 of the total cortex 1+ perfusion defect of more than 1/3 but less than 1/2 of the total cortex

(3) Scale for the nephrographic effect 4+ contrasting effect of cortex higher than in adjacent pedicles 3+ contrasting effect of cortex similar to that in adjacent pedicles 2+ the cortical attenuation the same as in adjacent ribs yet less than in pedicles 1− less than adjacent ribs

(4) Arterial diameter was measured in an interlobar artery 2 to 2 5 cm from its take off

(5) Duration of arterial phase the duration of visible interlobar arteries

(6) Venous return from the filling of interlobar arteries to the appearance of con trast medium in the renal vein

Each evaluation was compared with the baseline of the same animal At the end the dogs were killed by injecting potassium chloride into the heart The kidneys were removed for fixation in 10 per cent buffered formaldehyde and stained with hematoxylin and eosin for microscopic examination

Microangiography In 8 dogs microangiography was performed following the last angiography In order to detect any inhomogeneity in the perfusion of the kidney but not to complete filling of the capillary bed the following technique was used 1 000 ml of a 15 per cent saline suspension of barium sulfate (Micropaque Damancy & Co) at 37 was introduced into the ascending aorta through a large femoral catheter The first infusion was followed by 1 000 ml of 15 per cent Micropaque sus pended in buffered 4 per cent formaldehyde The infusion pressure was maintained slightly higher than the animal s systolic pressure Femoral vein catheters were opened to avoid excessive overloading of the vascular bed Cardiac function con tinued up to the end of the saline suspension The degree of capillary filling was advertently compromized by introducing the barium sulfate suspension into the ascending aorta instead of the renal artery in order to provide more physiologic distribution of the contrast medium during the infusion of the anesthetized animal It was also possible to maintain the normal blood pressure during barium sulfate in fusion until the animal died when the formaldehyde suspension was infused

After completion of the Micropaque infusion the kidneys were removed fixed in formaldehyde for 5 days and cut into 1 and 2 mm cross sections The sections were sealed with paraffin wax to prevent drying and immediately exposed in contact with Kodak High Resolution Plates using a Faxitron apparatus at 45 kV for microscopic observation of the kidney vascularity

Results

The angiographic findings in control and after cardiac arrest groups are sum marized in Table 2

Animals maintained without cardiac arrest The 3 angiographies performed for each of the 6 control dogs during the 5 hour maintenance period demonstrated that no significant change in the angiographic appearance occurred during the main

Table 2

Angiographic findings in control and after cardiac arrested kidneys (mean scores ± SD)

No of animals		Parameters (score range)	Baseline	1–3 h	4–5 h
6	Control	Demarcation of cortex and medulla (3 to 1)	2 8±0 4	2 5±0 5	2 8±0 4
		Cortical perfusion (4 to 1)	3 3±1 2	3 3±1 2	3 3±1 2
		Nephrographic effect (4 to 1)	2 3±0 5	2 3±0 5	2 5±0 8
		Arterial diameter (interlobar artery) (mm)	2 5±0 3	2 4±0 3	2 4±0 3
		Arterial phase (s)	1 7±0 2	1 6±0 2	1 7±0 2
		Venous phase (s)	2 3±0 3	2 3±0 4	2 4±0 5
2	Short arrest 3 and 6 min	Demarcation of cortex and medulla (3 to 1)	2 5±0 7	2 5±0 7	2 0±0
		Cortical perfusion (4 to 1)	3 5±0 7	3 5±0 7	3 5±0 7
		Nephrographic effect (4 to 1)	2 0±0	2 0±0	2 5±0 7
		Arterial diameter (interlobar artery) (mm)	2 0±0	2 0±0	2 0±0
		Arterial phase (s)	1 5±0	1 5±0	1 5±0
		Venous phase (s)	2 5±0 7	2 7±1 0	1 7±0 3
10	Long arrest 7 to 14 min	Demarcation of cortex and medulla (3 to 1)	3 0±0	1 8±0 6	1 5±0 9
		Cortical perfusion (4 to 1)	3 6±0 5	2 5±1 3	2 6±1 4
		Nephrographic effect (4 to 1)	2 8±0 6	1 9±0 7	1 7±0 6
		Arterial diameter (interlobar artery) (mm)	2 2±0 6	1 8±0 8	1 8±0 8
		Arterial phase (s)	1 7±0 2	2 7±2 4	2 5±1 7
		Venous phase (s)	2 5±0 4	3 7±1 8	5 0±2 4

Immediately after each injection the renal catheter was placed at the lower abdominal aorta and was constantly infused with heparinized saline solution

The films were evaluated by three radiologists unaware of the individual experimental procedure using the following grading scale (1) demarcation of cortex and medulla (2) cortical perfusion (3) degree of nephrographic effect (4) diameters of an interlobar artery (5) duration of the arterial phase and (6) time of first venous return

(1) Demarcation of the cortex and the medulla 3+ sharp demarcation 2+ partially blurred 1+ no difference between the cortex and medulla

(2) Cortical perfusion Scales for estimating extent of nonperfusion in the cortex were as follows 4+ normal perfusion of contrast medium to the entire cortex 3+ perfusion defect of less than 1/4 of the total cortex 2+ perfusion defect of more than 1/4 but less than 1/3 of the total cortex 1+ perfusion defect of more than 1/3 but less than 1/2 of the total cortex

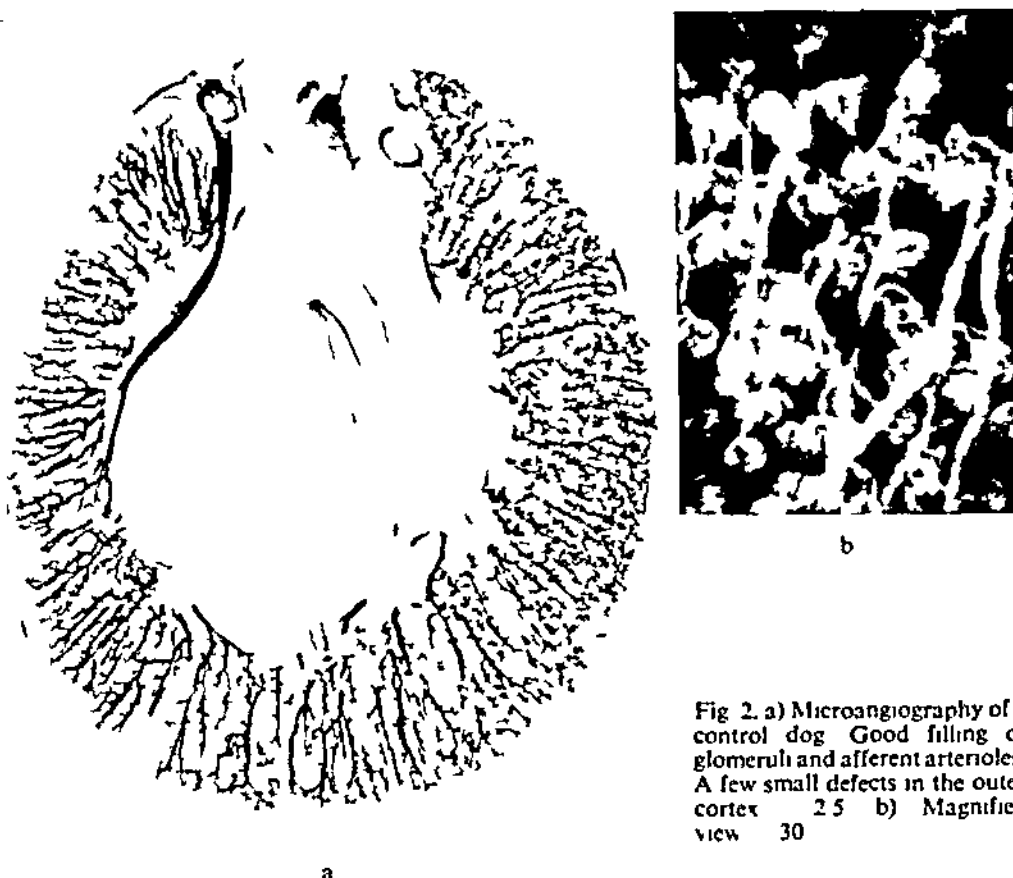


Fig 2. a) Microangiography of a control dog Good filling of glomeruli and afferent arterioles A few small defects in the outer cortex 2 5 b) Magnified view 30

Some tendency towards decrease of creatinine clearance in the control animals was found but the variation was wide and no significant change in average creatinine clearance appeared within 5 hours

Animals resuscitated after various periods of cardiac arrest The baseline score of angiographic findings of the experimental animals did not differ from the control animals (Table 2)

The duration of the arterial and venous phases in relation to the duration of the cardiac arrest and the changes in the estimated scores of renal cortical perfusion appear in Table 2 and Figs 3 and 4

It is evident that great variation between individual animals appeared after arrest Greatest variation occurred both in the duration of arterial and venous phases and also in the degree of cortical malperfusion

The two animals subjected to the shortest periods of arrest (3 and 6 min) had no change from the baseline at angiography Microangiographic filling of the glomeruli in 6 min arrested animals was similar to the controls but the interlobular arteries were unusually narrow suggesting severe vasoconstriction

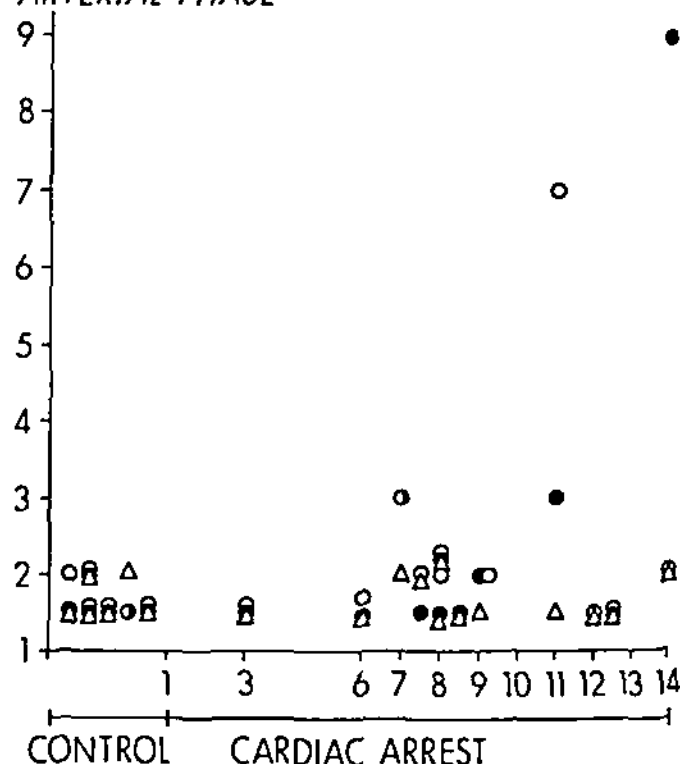


Fig 3 Duration of arterial phase (in s) in relation to cardiac arrest (in min) as seen at various phases of the experiment in each dog △ = Baseline ● = 1 to 3 h ○ = 4 to 5 h ◑ = overlap of the ○ and ● circles

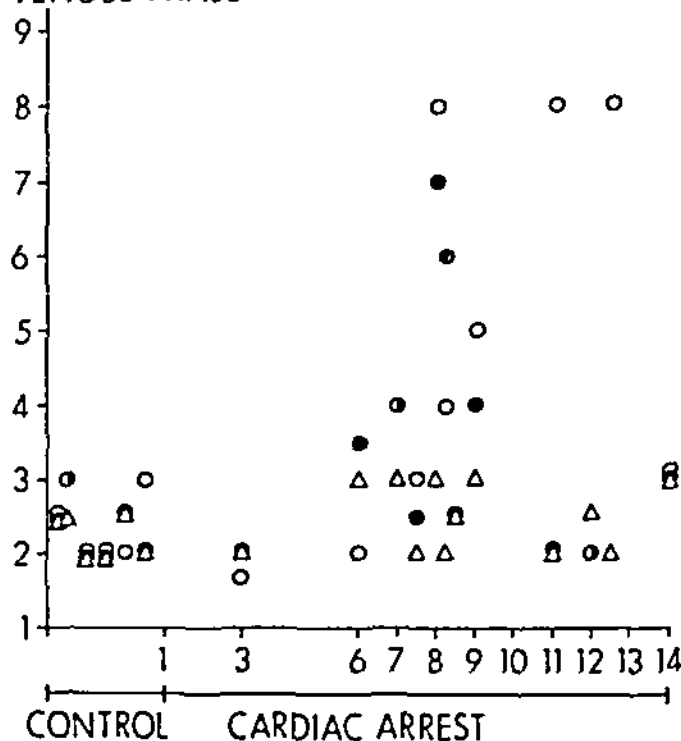


Fig. 4 Duration of venous phase (in s) in relation to cardiac arrest (in min) at various phases of the experiment in each dog. △ = Baseline ● = 1 to 3 h ○ = 4 to 5 h ◑ = overlap of the ○ and ● circles




Fig 5 a) Nephroangiography of a dog 2 h after recovery from 8 min of cardiac arrest Diffuse segmental spasm of the interlobar arteries Loss of demarcation between the cortex and the medulla marked decrease of nephrographic effect in the cortex venous return markedly delayed (not shown) b) Microangiography Diffuse arterial spasm and complete absence of glomerular filling 40

After cardiac arrest periods of 7 min and more angiography demonstrated poor demarcation of cortex and medulla impairment of cortical perfusion or slow down of the renal circulation

A certain degree of vasoconstriction was present in all arrested animals In the 2 dogs which in addition received metaraminole to elevate the blood pressure generalized vasoconstriction occurred as well as impairment of the renal perfusion after the drug A clear improvement occurred at 5 hours probably because of disappearance of the drug effect

In 4 other animals also extensive spasm of the interlobar arteries occurred 1 or 2 hours after recovery from circulatory arrest When such spasm was evident marked delay in the venous return up to 8 seconds occurred (Fig 5 a) Delayed venous return was always accompanied by faint demonstration of the renal vein In all 4 cases there was progressive impairment of cortical medullary demarcation perfusion of cortex and nephrography Cortical defects were increased in number or larger as compared to individual baseline examinations In one animal spasm of the interlobar arteries disappeared at 4 hours during the recovery period and at which time the interlobar arteries were dilated (3 mm in diameter) and a marked delay in the venous return (8 s) was noticed (Fig 6)



a



b



c



d

Fig 6 (For l gend see opposite page)



a



b

Fig. 7 A dog revived from 9 min cardiac arrest and resuscitated for 5 h. a) Nephroangiography nephrographic phase Diffuse cortical defects One area of contrast stasis in the interlobar artery (+→) The renal vein is barely visible (→) b) Microangiography of the cross section Large and small cortical filling defects × 2 25

Progressive loss of demarcation of the cortex to the medulla decreased perfusion of cortex and decreased nephrography was also found in the group with less extensive renal vasoconstriction During maintenance cortical defects generally increased in number and size (Fig 7 a) except in 2 animals where defects were diminished at 4 hours

Microangiography was performed on 3 animals which were arrested over 7 min Perfusion defects were also documented in microangiography (Fig 7 b) even if lobar arteries were extensively dilated in one kidney Diffuse arterial spasm and poor or absent glomerular filling was found in the 2 other pairs of specimens both from animals arrested for 12 min (Fig 5 b)

In order to determine the cause of the perfusion defects which appeared in the

---

Fig 6 A dog revived from 11 min cardiac arrest a b) One h after resuscitation a) 3 s after injection Normal arterial appearance with several large cortical defects Still good demarcation of the cortex to the medulla b) After 4 s Venous return as fast as in the baseline angiography c d) 4 h post arrest Subtraction c) 1 5 s after injection Prolonged hold up of medium in the dilated interlobar arteries poor demarcation of the cortex to the medulla d) After 3 s Contrast medium more homogeneously distributed throughout the entire kidney Slow venous return (not shown) The cortical defects no longer present

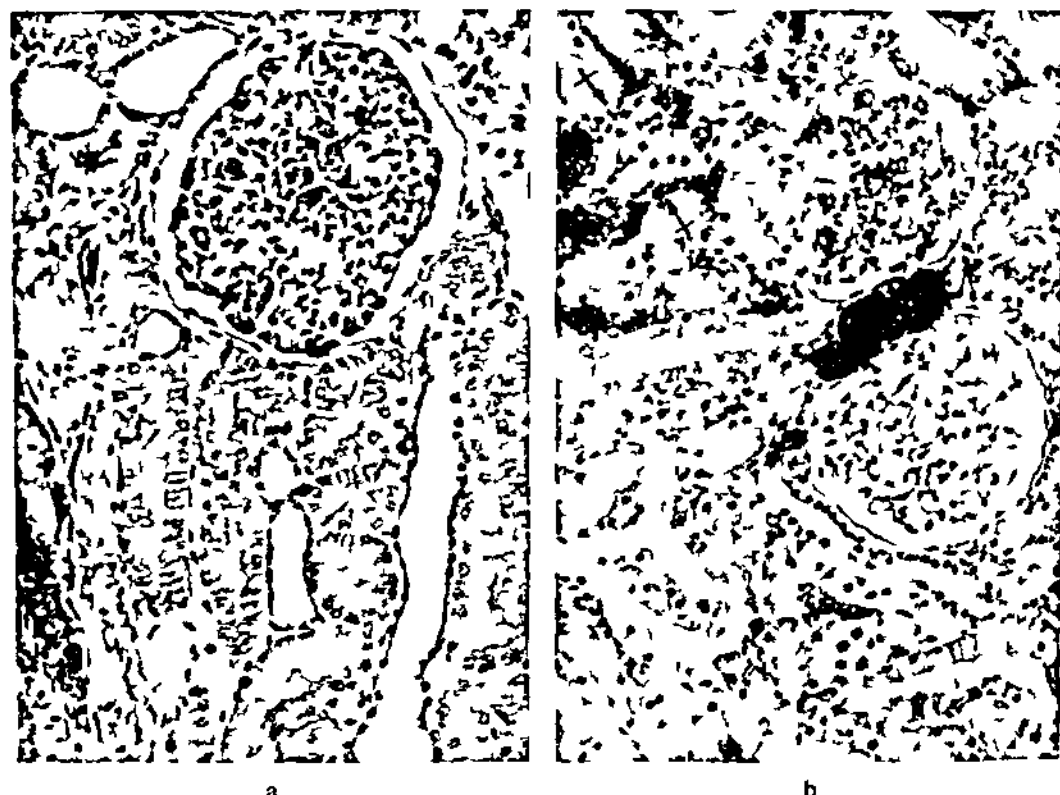


Fig 8 a) Section of a kidney after a 12 min cardiac arrest and 5 h resuscitation Glomerular hyperemia partial obliteration in an afferent arteriole due to a thrombus in the lower left corner (→) × 180 b) Section of another animal Red blood cell aggregation in afferent arteriole (→) and hyperemia of peritubular capillaries (↔) × 180

kidneys after cardiac arrest microscopic examination of defect areas in 3 kidneys examined with microangiography was performed In areas which presented as defects some degree of red blood cell aggregation in afferent arterioles and glomerular hyperemia was found (Fig 8) Microscopy of numerous kidneys not examined with microangiography was also performed without evidence of red blood cell aggregation or thrombi in the kidneys removed 10 or 30 min after cardiac arrest Later small areas of red blood cell aggregation were detected in the renal cortex and also in the vasa recti The kidneys used for angiography were microscopically similar to the ones not examined with angiography Thus there was convincing evidence that some degree of vascular occlusion appears in the kidneys following circulatory arrest However the extent of histologic obliterative changes was not closely related to angiographically observed large perfusion defects since perfusion defects were relatively larger

Definite tendency towards a decrease of creatinine clearance was seen following an arrest of 7 min or more but individual variations were large

Discussion

The investigation demonstrates that maintenance in the present experimental design itself does not cause significant changes in the angiographic appearance of the kidneys However sometimes dog kidneys have cortical defects They are most likely local vasoconstrictive phenomena since histology was unable to prove true vascular occlusion Sometimes these defects disappear within a few hours of observation Such defects in nephroangiography have been demonstrated by SHANSER et coll They found slight defects in control animals and more extensive defects when blood pressure was decreased in the kidney Observations by BURGENER & FISCHER (1975) from this laboratory also indicate that such defects may appear in normal dog kidneys and that they are not necessarily related to blood pressure but possibly to dehydration The present experiments with dogs not subjected to angiography but microangiography and dogs with only angiography and histology show that these defects were not due to barium sulfate which is known to cause platelet aggregation and microemboli in lungs (BO et coll 1974) A complete filling of the postglomerular bed in microangiography is achieved only with a highly unphysiologic way of isolated perfusion and was not attempted However the efferent vessels were filled in the small defect areas That indicates that some flow into these segments occurred during perfusion

The series of films of each animal show changes mainly in the blood flow to the renal cortex Cortical perfusion defects caused by cardiac arrest show little or no reversibility a finding which differs from the small perfusion defects seen in some control animals

The failure of blood flow to return to the kidney following a transient period of ischemia has long been recognized To cause a significant transient effect upon the glomerular filtration and renal plasma flow a minimum of 10 min of renal artery occlusion is a prerequisite period (SELKURT) To produce so-called no reflow phenomenon in the kidney a minimum of one hour or longer of complete occlusion of both renal arteries or minimum 2 hours occlusion of one side of the renal artery was found to be necessary by those who have been able to demonstrate such a phenomenon (CUPPAGE et coll 1967) The present histologic findings show some similarity to those of SHEEHAN & DAVIS (1959) who described a no reflow phenomenon in the rat kidney after 2 hours of ischemia

It is evident that cardiac arrest causes a severe impairment of the renal circulation Arterial constriction certainly is a significant component of this phenomenon The angiographic abnormalities suggest that a primary event takes place in the outer cortical vascular bed Microangiography also demonstrated narrow arteries and afferent arterioles as well as generalized decreased filling of glomeruli consistent with angiographic findings Such vasoconstriction may also involve the interlobar arteries The prolonged circulation time occasional dilatation of interlobar arteries and reflux of the contrast medium into the abdominal aorta are probably secondary

effects of cortical ischemia Red blood cell aggregation and possible platelet thrombi in glomerular capillaries and preglomerular vessels is a part of this phenomenon and seems not to be easily reversible The deleterious but reversible effect of vasoconstrictive drugs on renal circulation was also clearly demonstrated Infusion of norepinephrine epinephrine and angiotensin has been shown to produce similar progressive cortical ischemia starting in the outer cortex (DANIEL et coll 1952 CARRIERE et coll 1966)

The angiographic findings observed in the present experiments where there is no blood pressure and circulation are not specific and may occur in other conditions like hemorrhagic shock and hypotension (KUPIC & ABRAMS ELKIN et coll 1971 LAVENDER & SHERWOOD)

Angiography of the entire kidney even with highest resolution is not a reliable means of demonstrating complete cortical perfusion Perfusion defects totaling up to 50 per cent may be hidden by superimposition of well perfused segments and only demonstrated by cross sectional examination (GRIFFITHS et coll 1977) A discrepancy between angiographic findings and functional examinations as reported by BEST et coll (1976) therefore needs a conservative evaluation as substantial local defects may have remained unnoticed

Acknowledgements

The authors are grateful to H W Fischer Department Chairman for his encouragement and support in part of this investigation to E Lipchik and F Burgener for their valuable angiographic analysis and to the technical staff P Harnish R Kummler M Cutt and D Kornbrust for their assistance Part of this investigation was supported by USPHS General research support grant No RR05403 14

SUMMARY

Renal circulation following 3 to 14 min of cardiac arrest was investigated in 21 mongrel dogs by angiography microangiography and histology Arrest longer than 7 min caused variable degrees of abnormal angiographic findings after resuscitation (1) segmental perfusion defects and cortical areas without nephrographic effect (2) loss of demarcation of cortex and medulla (3) decreased nephrography (4) faint and delayed filling of the renal veins (5) diffuse segmental spasm of the interlobar arteries with delayed emptying Microangiography demonstrated non filling of glomeruli in segmental areas of renal cortex diffuse malperfusion and vasoconstriction as well as obliteration of afferent arterioles due to red blood cell aggregation No tendency toward recovery within the 5 hour resuscitation period

ZUSAMMENFASSUNG

Die Zirkulation im Anschluss an eine 3 bis 14 minutige Unterbrechung der Herzfunktion wurde bei 21 mischrassigen Hunden durch Angiographie Mikroangiographie und Histologie untersucht Eine Unterbrechung länger als 7 Minuten verursachte verschiedene Grade

von abnormalen angiographischen Befunden nach Beheben des Herzstillstandes (1) Segmentare Durchblutungsdefekte und kortikale Gebiete ohne Kontrastaufladung (2) Verlust der Demarkation zwischen Kortex und Medulla (3) verminderte Nephrographie (4) schwache und verzogerte Fullung der Nierenvenen (5) diffuse segmentare Spasmen der interlobalen Arterien mit einer verzogerten Entleerung Die Mikroangiographie zeigte Fullungsdefekte der Glomeruli in segmentaren Abschnitten der Nierenkortex eine generell verminderte Durchblutung und Vasokonstriktion sowie Obliteration der afferenten Arteriolen infolge Aggregation von roten Blutzellen Keine Tendenz einer Erholung innerhalb einer 5 stundigen Wiederbelebungsperiode wurde beobachtet

RÉSUMÉ

Les auteurs ont étudié sur 21 chiens bâtards par angiographie micro-angiographie et histologie la circulation rénale après un arret cardiaque de 3 à 14 minutes Un arret cardiaque supérieur à 7 minutes cause des degrés variables d anomalies angiographiques apres reanimation (1) défaut de perfusion segmentaire et absence d urographie dans des regions corticales (2) disparition de la démarcation entre cortex et médullaire (3) diminution de la néphrographie (4) opacification faible et retardée des veines rénales (5) spasme segmentaire diffus des artères interlobaires avec retard de leur evacuation La microangiographie a montré un défaut de remplissage des glomérules dans des régions segmentaires du cortex rénal une mauvaise perfusion diffuse et une vasoconstriction ainsi qu une oblitération d artérioles afférentes due à l agrégation d hématies Il n y a pas de tendance à la réparation dans une période de 5 heures après la réanimation

REFERENCES

Best J Lavender J P Russell S and Sherwood T Preservation of normal cortical vasculature in ischemic renal failure in the dog Nephron 16 (1976) 188

Bo G Hognestad J and Vaage J The role of blood platelets in pulmonary responses to microembolization with barium sulphate Acta physiol scand 90 (1974) 244

Brodman R F Hackett R L Finlayson B and Pfaff W W Microangiography of the renal vasculature following total renal artery occlusion Surgery 5 (1974) 734

Burgener F A und Fischer H W Selektive Nierenangiographie mit fraktionierter Kontrastmittelinjektion Fortschr Rontgen tr 123 (1975) 334

Carriere S Thorburn G D O Morchoe C C C and Barger A C Intrarenal distribution of blood flow in dogs during hemorrhagic hypotension Circ Res 19 (1966) 167

Cuppage F E Neagoy D R and Tate A Repair of the nephron following temporary occlusion of the renal pedicle Lab Invest 17 (1967) 660

Daniel P M Peabody C N and Pritchard M M L Cortical ischemia of the kidney with maintained blood flow through the medulla Quart J exp Physiol 37 (1952) 11

Diethelm A G and Wilson S J Obstruction to the renal microcirculation after temporary ischemia J surg Res 11 (1971) 265

Elkin M Meng C H and Mendez L Angiographic appearance of the canine kidney in acute hemorrhagic shock modification by saline infusion THAM infusion and reinfusion of blood Amer J Roentgenol 111 (1971) 716

Friedman S M Johnson R L and Friedman C I The pattern of recovery of renal function following renal artery occlusion in the dog Circ Res 2 (1954) 231

GRIFFITHS G J KORMANO M and MORRIS T The effect of perfusion pressure on the microcirculation of the isolated canine kidney Brit J Surg 12 (1977) 338

HINSHAW L B PAGE B B BRAKE C M EMERSON T E JR Mechanisms of intrarenal hemodynamic changes following acute arterial occlusion Amer J Physiol 205 (1963) 1033

KOROBKIN M Reversal of oliguria and renal cortical ischemia of hemorrhagic shock in the dog with tris (hydroxymethyl) amino methane (THAM) Arteriographic studies Invest Radiol 7 (1972) 455

KUPIC F A and ABRAMS H L Renal vascular alterations induced by hemorrhagic hypotension Preliminary observations Invest Radiol 3 (1968) 345

LAVENDER J P and SHERWOOD T The renal circulation in hemorrhagic hypotension In vivo renal micro angiography in the dog Brit med Bull 28 (1972) 241

LIN S R Angiographic studies of cerebral circulation following various periods of cardiac arrest A preliminary study in the dog Invest Radiol 9 (1974) 374

— Cerebral circulation after cardiac arrest Angiographic and carbon black perfusion studies Radiology 117 (1975) 627

— and KORMANO M Cerebral circulation after cardiac arrest Microangiographic and protein tracer studies Stroke 8 (1977) 182

MCNAY J L and ABE Y Redistribution of cortical blood flow during renal vasodilatation in the dog Circ Res 27 (1970) 1023

PHILLIPS R A and HAMILTON P B Effect of 20 60 and 120 minutes of renal ischemia on glomerular and tubular function Amer J Physiol 152 (1948) 523

RILEY A L ALEXANDER E A MIGDAL S and LEVINSKY N G The effect of ischemia on renal blood flow in the dog Kidney Internat 7 (1975) 27

SELKURT E E The changes in renal clearance following complete ischemia of the kidney Amer J Physiol 144 (1945) 395

SHANSER J D KOROBKIN M SEIDLITZ L CARLSON E L and SHAMES D M The effect of decreased renal artery perfusion pressure on intrarenal hemodynamics in the dog Invest Radiol 10 (1975) 569

SHEEHAN H L and DAVIS J C Renal ischemia with failed reflow J Path Bact 78 (1959) 105

STEIN J H FERRIS T F HUPRICH J E SMITH T C and OSGOOD R W Effect of renal vasodilatation on the distribution of cortical blood flow in the kidney of the dog J clin Invest 50 (1971) 1429

SUMMERS W K and JAMISON R L The no reflow phenomenon in renal ischemia Lab Invest 25 (1971) 635

VINIK M SMELLIE W A B FREED T A HUME D M and WEIDNER W A Renal ischemia and homograft rejection Preliminary angiographic data in the dog Invest Radiol 4 (1969) 252

FROM THE RESEARCH LABORATORIES DEPARTMENT OF DIAGNOSTIC RADIOLOGY AND THE DEPARTMENT OF CLINICAL CHEMISTRY MALMÖ ALLMANNA SJUKHUS UNIVERSITY OF LUND S 214 01 MALMÖ SWEDEN

PROTEINURIA FOLLOWING NEPHROANGIOGRAPHY

II Influence of contrast medium and catheterization in dogs

S HOLTÅS T ALMEN and L TEJLER

A commonly performed diagnostic procedure such as nephroangiography should ideally be riskfree but there are reports of renal failure following this examination (STARK & COBURN 1966 SIDD & DECTER 1967 MCEVOY et coll 1970 PORT et coll 1974 ANSARI & BALDWIN 1976 OLDER et coll 1976 TEJLER et coll 1977 b) Proteinuria sometimes massive resulting from increased glomerular permeability is frequent after nephroangiography using metrizoate as contrast medium (TEJLER et coll 1977 a) Massive proteinuria might be one factor in the development of postangiographic renal failure as precipitation of proteins in the renal tubuli could possibly obstruct urinary flow This would be analogous to acute renal failure following urography in patients with myelomatosis believed to be caused by intratubular precipitation of proteins (PERILLIE & CONN 1958 LASSER et coll 1966 LASSER 1967)

To avoid postangiographic proteinuria the causal factors must be explored Therefore an animal experimental model was sought that would be suitable for the investigation of proteinuria following nephroangiography and also for determination of whether such proteinuria is caused by the catheterization procedure or by the contrast medium

Material and Methods

Mongrel dogs weighing on the average 20 kg (range 10 to 41 kg) anesthetized with intravenous Mebumal (pentobarbitone) and spontaneously breathing through

Submitted for publication 24 January 1977

3 – 785849

Table 1

Dose and iodine concentration of different solutions injected selectively into one of the renal arteries of dogs in groups I–VI and the catheterization procedures undertaken in groups VII–VIII

Group	No of dogs	Test solution	Dose ml/20 kg	Iodine content mol/l (mg/ml)
I	6	Urografin	10	2 9 (370)
II	*6*	*Urografin*	*2 5*	*2 9 (370)*
III	9	Urografin	1 25	2 2 (280)
IV	11	Urografin	2 0	1 34 (170)
V	6	Isopaque Cerebral	1 25	2 2 (280)
VI	7	Perfadex	5 0	0
VII	3	No inj Catheterization of one renal artery only	0	0
VIII	9	No inj Catheterization of bladder only	0	0

Urografin Sodium meglumine-diatrizoate The solutions with iodine contents 2 2 and 1 34 mol l were dilutions in distilled water of the original solution with an iodine content of 2 9 mol l

Isopaque Cerebral Meglumine calcium metrizoate

Perfadex Dextran (mean molecular weight 40 000) 50 g/l Ions (mmol/l) Na 138 K 6 Mg 1 Cl 142 SO_4^- 0 8 and $H_2PO_4^-$ 0 8

an endotracheal tube had a transurethral catheter placed in the bladder A polyethylene catheter (OD 2 2 mm ID 1 45 mm) was introduced percutaneously into the femoral artery and the catheter tip was placed in one of the renal arteries The different test solutions were injected by hand under fluoroscopy and the catheter tip was then immediately withdrawn into the aorta where blood samples were taken

The dogs were divided into 8 groups (I–VIII) in which the concentrations of urinary albumin were determined following (1) injection of different contrast medium solutions (groups I–V) (2) injection of a test solution assumed to be inert (group VI) (3) catheterization of a renal artery without injection (group VII) and (4) repeated urine sampling from the bladder without catheterization of a renal artery (group VIII) The number of dogs in each group and the type dose and iodine concentration of the injected test solutions are presented in Table 1 When test solutions containing no iodine were injected and when catheterization of a renal artery was performed without injection the position of the catheter tip supposed to be in the renal artery was indicated with lead strips on the dog after urine sampling was completed the catheter tip was replaced in the indicated position and the location within the renal artery was confirmed by contrast medium injection

Sampling and analysis Urine samples were obtained by manual external compression of the dog's bladder. If macroscopic hematuria developed the dog was excluded from the final material. Blood samples were taken from the intra-aortic catheter into tubes containing EDTA. Plasma and urine samples were frozen and kept at −20 C until analysis. The following samples were taken:

Group I Urine samples were taken before and 30 min after the renal artery injection from all dogs and in 3 of the 6 dogs also 2 days later.

Groups II–V A blood sample was taken before and urine samples before and 15, 30, 45 and 60 min after the injection. Blood and urine samples were also obtained 2 days after the injection in 27 of the 32 dogs examined.

Group VI and VII A blood sample was taken before and urine samples before, 15 and 30 min after the injection or catheterization without injection.

Group VIII A urine sample was taken immediately after the introduction of the transurethral catheter and thereafter at 10 min intervals during observation times ranging from 30 to 60 min.

The concentrations of albumin were determined by the radial immunodiffusion technique of MANCINI et coll. (1965) using a monospecific rabbit anti-canine albumin antiserum produced at the laboratory. Pooled canine plasma was used as standard. It was assigned a concentration value of 100 arbitrary units of albumin per liter (U/l). Creatinine analyses were carried out by the Technicon method in Auto Analyzer II (plasma samples) or manually (urine samples). The concentration of albumin in urine was expressed in arbitrary units (U) per gram creatinine, thereby relating albumin excretion to glomerular filtration rate. The ratio between the maximum post-procedure value and the pre-procedure value was calculated in each animal to estimate the degree of influence on urinary albumin concentration from the various procedures undertaken in the different experimental groups. For this ratio the term relative increase of urinary albumin was used.

Differences were considered significant when p values < 0.05 were obtained by the Mann-Whitney rank sum test (one tail test) or Wilcoxon's test for paired observations.

Results

In 27 of the 38 dogs (groups I–V) in which contrast medium was injected into one of the renal arteries the relative increase of urinary albumin was more than 10 and in 9 of them more than 100 (Table 2). Injection of Perfadex into one of the renal arteries (group VI) or catheterization without injection (group VII) resulted in a small increase in the concentration of albumin in urine. When the relative increases in these groups were compared with those obtained in group VIII, where a transurethral catheter was placed in the bladder with no arterial catheterization or injection, no significant difference was observed.

Table 2

Number of dogs in the different experimental groups and those reacting with relative increases of urinary albumin exceeding 10 and 100 respectively

Group	No of dogs	Relative increase	
		10	~100
I	6	6	6
II	6	5	2
III	9	5	1
IV	11	7	0
V	6	4	0
VI	7	0	0
VII	3	0	0
VIII	9	0	0

In the dogs subjected to bladder catheterization only (group VIII) microscopy of the immediately taken urine sample failed to reveal microscopic hematuria and it was therefore taken as representative for the theoretical pre-procedure urine However after 30 min a slight but statistically significant increase in urinary albumin due to microscopic hematuria was observed

The results in the different groups are summarized in Tables 2 and 3 In 25 of the 32 dogs in groups II–V the maximum urinary albumin concentration was found in one of the urine samples taken within 45 minutes In 13 dogs this maximum occurred as soon as in the first sample i e 15 min after the injection

The maximum concentration of albumin in urine after injection of a contrast medium varied widely and in some dogs reached values as high as 50 per cent of that in plasma The injection of 10 ml/20 kg Urografin with an iodine content of 2 9 mol/l (group I) into one of the renal arteries resulted in relative increases of urinary albumin which were significantly higher than those obtained after injection of the lower doses and concentrations of Urografin in groups II–IV No significant difference was found between relative increases of urinary albumin when comparing the 3 groups II IV Nor was any significant difference in this respect found between the two groups (III and V) where the contrast media Urografin and Isopaque Cerebral were employed at equal dose and iodine concentrations Significant differences were found when the relative increases of urinary albumin after injection of contrast medium into one renal artery were compared with those observed after injection of *Hexabrix No significant difference could be demonstrated between pre-injection* concentrations of albumin in ... concentration values 2 days after the injection in the do... II–V ... ps the mean pre-experimental plasma con

Table 3

Median and range of albumin concentration in pre procedure urine samples and in the post procedure samples with maximum albumin concentration Median and range of the relative increases also given Concentrations of albumin in urine are expressed in arbitrary units/g creatinine

Group	Concentration of albumin in urine		Relative increase of albumin in urine
	Pre procedure	Max post procedure	
I	0 28 (0 097-1 0)	260 (66-680)	860 (150 5 400)
II	0 16 (0 048-3 2)	25 (1 7-82)	64 (7 4-1 700)
III	0 40 (0 13-2 4)	4 2 (1 1-210)	12 (2 8-120)
IV	0 43 (0 12-1 3)	5 1 (1 2-36)	13 ([illegible] 2-92)
V	0 32 (0 11-5 1)	5 9 (1 9-21)	17 (2 2-100)
VI	0 33 (0 092-4 1)	2 2 (0 11-7 7)	4 8 (1 [illegible]-7 6)
VII	0 83 (0 74-1 1)	1 3 (1 3-1 3)	1 6 (1.2-1 8)
VIII	0 22 (0 078-0 44)	0 43 (0 092-1 1)	2 5 (1 0-6 4)

Significant difference in relative increases between the groups (Mann-Whitney) I-II $p<0\ 05$ I-III I-IV and I-V $p<0\ 005$ II-VI $p<0\ 005$ III-VI IV-VI and V-VI $p<0\ 025$

centrations of albumin and creatinine were 73 U/l (range 50 to 133) and 93 μmol/l (range 65 to 124) respectively No significant change was found in these plasma values during the experiments

Discussion

The experiments conducted clearly demonstrate that albuminuria is common subsequent to nephroangiography in dogs when Urografin or Isopaque Cerebral is employed as contrast medium Theoretically the irritation accompanying transurethral catheterization could cause bleeding and albuminuria Dogs developing macro scopic hematuria were therefore excluded from the final material Catheterization of the bladder did result in a slight increase in urinary albumin after 30 minutes but as this factor was present in all groups it constitutes a systematic error Furthermore the high concentrations of urinary albumin in most dogs following angiography

Table 2

Number of dogs in the different experimental groups and those reacting with relative increases of urinary albumin exceeding 10 and 100 respectively

Group	No of dogs	Relative increase	
		10	>100
I	6	6	6
II	6	5	2
III	9	5	1
IV	11	7	0
V	6	4	0
VI	7	0	0
VII	3	0	0
VIII	9	0	0

In the dogs subjected to bladder catheterization only (group VIII) microscopy of the immediately taken urine sample failed to reveal microscopic hematuria and it was therefore taken as representative for the theoretical pre procedure urine However after 30 min a slight but statistically significant increase in urinary albumin due to microscopic hematuria was observed

The results in the different groups are summarized in Tables 2 and 3 In 25 of the 32 dogs in groups II–V the maximum urinary albumin concentration was found in one of the urine samples taken within 45 minutes In 13 dogs this maximum occurred as soon as in the first sample i e 15 min after the injection

The maximum concentration of albumin in urine after injection of a contrast medium varied widely and in some dogs reached values as high as 50 per cent of that in plasma The injection of 10 ml/20 kg Urografin with an iodine content of 2 9 mol/l (group I) into one of the renal arteries resulted in relative increases of urinary albumin which were significantly higher than those obtained after injection of the lower doses and concentrations of Urografin in groups II–IV No significant difference was found between relative increases of urinary albumin when comparing the 3 groups II–IV Nor was any significant difference in this respect found between the two groups (III and V) where the contrast media Urografin and Isopaque Cerebral were employed at equal dose and iodine concentrations Significant differences were found when the relative increases of urinary albumin after injection of contrast medium into one renal artery were compared with those observed after injection of Perfadex No significant difference could be demonstrated between pre injection concentrations of albumin in urine and concentration values 2 days after the injection in the dogs in groups II–V In these groups the mean pre-experimental plasma con-

minuria were encountered Consequently individual factors not yet defined seem to be important However after injection of the highest dose (group I) all dogs reacted with albuminuria which was significantly higher than that occurring in the other groups (II–V)

No significant difference in the degree of albuminuria was found when comparing groups III and IV in which the same number of contrast medium molecules were injected but in different concentrations The osmolality of the contrast medium solution thus does not seem to exert any decisive influence on the ensuing albuminuria

Postangiographic proteinuria in man and animals has been reported when older types of contrast media such as acetrizoate and iodopyracet were used (IDBOHRN & BERG 1954 IDBOHRN 1956 KIRKLAND 1959 KIRKLAND & HASLOCK 1961) Investigations of possible side effects including proteinuria of nephroangiography employing modern contrast media such as diatrizoate and iothalamate have been performed in man and dogs but postangiographic proteinuria was not found (KONG et coll 1963 TALNER et coll 1972) The reason why such proteinuria has escaped notice is not clear The protein assay and the time for urine sampling are probably critical if the proteinuria is to be detected

Intratubular protein precipitates may form when protein concentration in urine is high (BERDON et coll 1969) Such precipitates may lead to intratubular blockage of urinary flow This possibility is supported by the recent observations of OLDER et coll (1976) They found that a prolonged nephrographic effect probably indicative of urinary stasis frequently occurred at nephroangiography in man In addition a transient elevation of plasma creatinine was found in 10 per cent of their patients Therefore it seems desirable to minimize the risk of intratubular protein precipitation postangiographically by for example reducing the albuminuric effect of the contrast solutions

The dog seems suitable as an experimental model for future investigations in this field since postangiographic proteinuria in the dog has many characteristics in common with that in man (TEJLER et coll 1977 a) i e it occurs in high frequency has a rapid onset and is of a transient nature In addition wide variations in the degree of postangiographic proteinuria occur in the dog as well as in man

Acknowledgements

This investigation was supported by grants from the Medical Faculty University of Lund the Swedish Medical Research Council (Project No 3483) the Segerfalk foundation and the Larsson Svensson and Wiberg foundations

The expert technical assistance of Anita Burnett Birgitta Sparre and Gail Åkerman is gratefully acknowledged

SUMMARY

Major increases of urinary albumin were common following nephroangiography in dogs using Urografin (diatrizoate) or Isopaque Cerebral (metrizoate) as contrast medium Neither

the catheterization procedure nor the injection of a supposed inert solution resulted in significant albuminuria but following injection of contrast medium albuminuria commenced within a few minutes normalization occurred within 2 days Higher doses of contrast medium induced massive albuminuria than lower ones

ZUSAMMENFASSUNG

Nephroangiographie mit Urografin (Diatrizoat) oder Isopaque Cerebral (Metrizoat) als Kontrastmittel verursachte Albuminurie bei Hunden Weder die Katheterisierung noch die *Injektion einer vermutlich inerten Losung fuhrte zu einer signifikanten Albuminurie* Diese trat jedoch nach Injektion von Kontrastmitteln innerhalb von wenigen Minuten auf und normalisierte sich innerhalb von 2 Tagen Hohere Dosen von Kontrastmitteln fuhrten zu einer kraftigeren Albuminurie als niedrigere Dosen

RESUME

Une augmentation importante de l albumine urinaire est frequente après nephroangiographie chez des chiens au moyen d Urografin (diatrizoate) ou d Isopaque cérébral (metrizoate) utilisés comme moyen de contraste Ni le cathetérisme ni l injection d une solution supposee inerte ne donnent une albuminurie importante mais après injection de moyens de contraste l albuminurie commence au bout de quelques minutes la normalisation se produit en deux jours Des doses plus fortes de moyen de contraste entrainent une albuminurie plus forte que des doses faibles

REFERENCES

ANSARI Z and BALDWIN D S Acute renal failure due to radio-contrast agents Nephron 17 (1976) 28

BERDON W E SCHWARTZ R H BECKER J and BAKER D H Tamm Horsfall proteinuria Radiology 92 (1969) 714

IDBOHRN H Tolerance to contrast media in renal arteriography Acta radiol 45 (1956) 141

— and BERG N On the tolerance of the rabbit s kidney to contrast media in renal angiography Acta radiol 42 (1954) 121

KIRKLAND J Massive albuminuria following aortography Lancet 2 (1959) 1144

— and HASLOCK M Transient proteinuria following injection of contrast media Lancet 1 (1961) 693

KONG T MEANEY T DUSTAN H and SONES F Safety of selective renal arteriography Amer J med Sci 246 (1963) 527

LASSER E C Dynamic factors in roentgen diagnosis 1st edition pp 49 110 Williams & Wilkins Baltimore 1967

— LANG J H and ZAWADSKI Z. A Contrast media Myeloma precipitates in urography J Amer med Ass 198 (1966) 945

MANCINI G CARBONARA A O and HEREMANS J F Immunochemical quantitation of antigens by using single radial immunodiffusion Immunochemistry 2 (1965) 235

McEVOY J McGEOWN M G and KUMAR R Renal failure after radiological contrast media Brit med J 4 (1970) 717

OLDER R., MILLER J JACKSON D JOHNSRUDE I and THOMPSON W Angiographically induced renal failure and its radiographic detection Amer J Roentgenol 126 (1976) 1039

PERILLIE P E and CONN H O Acute renal failure after intravenous pyelography in plasma cell myeloma J Amer med Ass 167 (1958) 2186

PORT F K WAGONER R D and FULTON R E Acute renal failure after angiography Amer J Roentgenol 121 (1974) 544

SIDD J and DECTER A Unilateral renal damage due to massive contrast dye injection with recovery J Urol 97 (1967) 30

STARK F and COBURN J Renal failure following methylglucaminediatrizoate (Renografin) aortography Report of a case with unilateral renal artery stenosis J Urol 96 (1966) 321

TALNER L RUSHMER H and COEL M The effect of renal artery injection of contrast material on urinary enzyme excretion Invest Radiol 7 (1972) 311

TEJLER L ALMÉN T and HOLTÅS S (a) Proteinuria following nephroangiography I Clinical experiences Acta radiol Diagnosis 18 (1977) 634

— EKBERG M ALMÉN T and HOLTÅS S (b) Proteinuria following renal arteriography Report of two cases Acta med scand 202 (1977) 131

FROM THE ROENTGEN DIVISION DEPARTMENT OF ORTHOPAEDICS AND TRAUMATOLOGY, HELSINKI UNIVERSITY CENTRAL HOSPITAL SF 00260 HELSINKI FINLAND

EMERGENCY ANGIOGRAPHY IN EXTREMITY TRAUMA

Prognostic aspects

E M LAASONEN

Early reconstructive surgery of vascular lesions following trauma is the best guarantee for a good end result in many centres this has led to a policy of immediate reconstruction of the arterial lesion (MORTON et coll 1966 KOSKINEN 1967 SACKS 1969 MANDAL et coll 1976) It would seem that angiography would delay surgery and this is perhaps why emergency angiography is only mentioned in passing in reports dealing with extremity trauma (LUMPKIN et coll 1958 LOVE & BRAUN 1968 GIRL 1971 PIYACHON & ARTACHINTA 1973) On the other hand there is evidence that detailed preoperative information on the vascular condition is of the utmost importance for planning the operation (LARENA & SCHMUCKER 1972 WENZ 1972 ENGE et coll 1975 MCDONALD et coll 1975)

The early circulatory abnormalities in the dog leg following fractures and soft tissue injuries have been recently presented in a series of publications (SANDEGÅRD & ZACHRISSON 1975 a b LEWIS et coll 1975 a b) The temporal changes in arterial diameter blood flow and vascular peripheral resistance were the main subjects in these reports

The present report analyses the findings and the prognostic information provided by emergency angiography following trauma to the extremities

Submitted for publication 10 October 1976

Table 1

Traumatic occlusion in 13 patients

	Extremity	
	Saved	Amputated
Flow to occlusive segment 1 5 cm/s or more		
Present	3	0
Absent	1	6
Distinct outline of injured artery		
Present	5	2
Absent	2	4
Efficient non sclerotic arterial collaterals		
Present	5	3
Absent	1	3
Arteriosclerosis		
Pres nt	0	3
Absent	7	3

Material and Methods

Emergency angiographies performed 1968–1975 on 36 patients aged 3 to 76 years (mean 34 8 years) 33 men and 3 women were analysed in retrospect Twenty six had sustained traffic accidents The injury was blunt trauma in 34 patients 23 of them had fractures 10 had soft tissue lesions such as lacerations contusions or compressions one had bilateral frostbite of the feet In the remaining 2 the injury consisted of shooting accidents

The angiography was performed within 24 hours of the accident in 30 patients in 6 it was delayed for 3 to 7 days The delay usually was ascribed to unsatisfactory results of a treatment intended to relieve the circulatory disturbance The angiographies were evenly distributed over the 24 hours Catheterization angiography was made in 23 patients and direct puncture angiography with a plastic cannula in 13 including the 5 patients examined in another department

Eighteen patients were operated upon 16 reconstructions and 2 ligations of the artery In 13 patients the surgery was not aimed at the artery itself 8 had reduction of fracture and 5 primary amputations of the extremity No particular therapy was administered to 5 patients A late amputation became necessary in 6 patients 5 belonging to the reconstruction group and one to the fracture reduction group

Results

The trauma involved the brachial (6) femoral (9) popliteal (11) and tibial (7) arteries Axillary iliac and radial arteries were affected in one patient each



Fig. 1



Fig. 2

Fig. 1 Good prognosis Well delineated occlusion by intimal tear Collaterals fill the artery distal to the occlusion Extremity saved after arterial repair

Fig. 2. Unfavourable prognosis Gradual dilution of the contrast medium above the occlusion muscle arteries but no collaterals Primary arterial repair did not prevent late amputation

Occlusion of a major artery was present in 13 patients—3 of them caused by an intimal tear in 9 patients a narrowing of the main artery was found—1 of them by an intimal tear and 3 by spasm One patient had a pseudoaneurysm and an arteriovenous fistula In 4 patients extravasation of contrast medium from small arteries occurred and in 3 the major artery was displaced by a haematoma No arterial abnormalities were apparent in 6 patients in another 6 atheromatosis was evident in the region of the trauma

Prognostic significance of angiography In 6 of 13 patients with occlusion of the major artery the extremity could not be saved although 2 patients had primary arterial reconstruction

The following angiographic features seemed to indicate a good prognosis (Table 1) (a) an apparent speed of the contrast medium in the major artery determined 10 20 cm above the occlusion—1 5 cm/s or more (b) distinct delineation of the artery above the occlusion the contrary being an unsharp outline of the vessel attributed

Table 2

Traumatic narrowing in 9 patients

	Extremity	
	Saved	Amputated
Severely disturbed distal circulation		
Present	1	4
Absent	3	1
Narrowing of the main artery by more than 50 of transverse diameter		
Present	1	4
Absent	3	1
Narrowing in an artery without collaterals		
Present	1	3
Absent	3	2

to gradual incomplete mixing of the contrast medium with stagnant blood (c) non atheromatotic collaterals effectively carrying the contrast medium beyond the occlusion (Figs 1 2)

Atheromatosis at the site of trauma had a poor prognosis In all 3 patients affected amputation of the extremity became necessary The extremities of the 2 patients with all 3 favourable findings present were saved as well as the extremities of 3 of the 4 patients with 2 favourable findings and without evidence of atheromatosis

Narrowing of the major artery had similar significance as occlusion Thus 5 of 9 patients had amputation performed 4 of them following a primary reconstruction of the artery A normal or only slightly disturbed distal filling should be regarded as indicating a good prognosis (Table 2) Narrowing of the artery or arteries by more than 50 per cent of the transverse diameter indicates a bad prognosis (Fig 3) as well as absence of collaterals The extremity of the one patient in the group with narrowed arteries and atheromatosis could be saved

Arterial reconstruction saved the extremity in a patient with a ps udoaneurysm and arteriovenous fistula after a shooting accident Only lesions of a major artery led to amputation of an extremity Extravasation of contrast medium from small arteries and displacement of the major artery by a haematoma were not detrimental to a favourable outcome

Discussion

Three basic indications for primary angiography of extremities injured by trauma are distal arterial insufficiency expanding haematoma and bruit or thrill at the site of trauma (SINKLER & SPENCER 1960 MCDONALD et coll) Bruit and thrill were



Fig 3 Unfavourable prognosis a) Multiple constrictions due to spasm intimal lesions and possibly also intimal thrombi b) Inefficient collaterals Primary arterial repair did not prevent late amputation

absent in the present material as were to a large extent the pertinent lesions – *pseudoaneurysms and arteriovenous fistulas* (*Love & Braun Enge et coll*, *Mc* Donald et coll) The type of injury mainly present in the material was the one resulting from blunt trauma which does not seem to give rise to pseudoaneurysms or arteriovenous fistulas (cf Smith et coll 1969)

Two additional (relative) indications which did not appear in this material were either a neurologic disturbance attributable to a level at which the nerve and the artery run together or a penetrating injury near a major artery but without symptoms or signs (Lumpkin et coll)

Lewis et coll (1975 a) reported an increase of the peripheral vascular resistance on the traumatized extremity in dogs at 2 hours Although the angiographies in the present series were usually performed within 4 hours of admittance of the patients to the hospital only some fell within this time limit of 2 hours In 6 patients not belonging to this series immediate surgery was considered mandatory and no angiography was performed

The final decision to undertake primary amputation of the extremity was mainly based on clinical considerations. Four of five patients in this group presented grave lesions on angiography. They were considered to have poor prognosis and angiography greatly supported the surgical decision.

It may well be that a narrowing of a major artery at angiography performed early does not reflect the final extent of the lesion being occlusion of the artery. This would explain why *non obstructive flow of the contrast medium towards the occluded* segment and beyond it by way of collaterals carried with it a better prognosis than mere constriction of the artery and no collaterals. The impression is that the potential or not of development of efficient collaterals has to be considered in detail before attempts at arterial reconstruction are made. Atheromatosis is one unfavourable factor in this respect.

SUMMARY

Emergency angiography was carried out on 36 patients following mainly a blunt trauma to the extremities. Factors of significance for the ultimate prognosis of the injury revealed by angiography are discussed.

ZUSAMMENFASSUNG

Eine Notfallsangiographie wurde bei 36 Patienten im wesentlichen nach einem stumpfen Trauma der Extremitaten vorgenommen. Die Faktoren von Bedeutung fur die schliessliche Prognose die bei der Angiographie entdeckt wurde werden diskutiert.

RÉSUME

Une angiographie d urgence a été faite chez 36 blesses à la suite le plus souvent d un traumatisme ferme des membres. L auteur examine les facteurs importants pour le pronostic eloigne du traumatisme qui sont révelés par l angiographie.

REFERENCES

ENGE I, AAKHUS T and EVENSEN A. Angiography in vascular injuries of the extremities. Acta radiol Diagnosis 16 (1975) 193

GIRL J. Arteriography in arterial gunshot wounds. Acta radiol Diagnosis 11 (1971) 78

KOSKINEN E V S. Restoration of blood flow in severely injured limbs by direct surgical techniques. Vasc Surg 1 (1967) 60

LARENA A und SCHMUCKER K. Indikationen zur Angiographie bei gleichzeitigen Arterien und Knochenverletzungen der Extremitaten. Radiologe 12 (1972) 303

LEWIS D H, SANDEGÅRD J, SEEMAN T and ZACHRISSON B E (a). Effects of intraarterial injection of contrast medium on regional circulation in soft tissue trauma. Acta radiol *Diagnosis 16 (1975) 373*

— RYBECK B, SANDEGÅRD J, SEEMAN T and ZACHRISSON B E (b). Circulatory disturbances following missile wounding of soft tissue. Acta radiol Diagnosis 16 (1975) 481

LOVE L and BRAUN T. Arteriography of peripheral vascular trauma. Amer J Roentgenol 102 (1968) 431

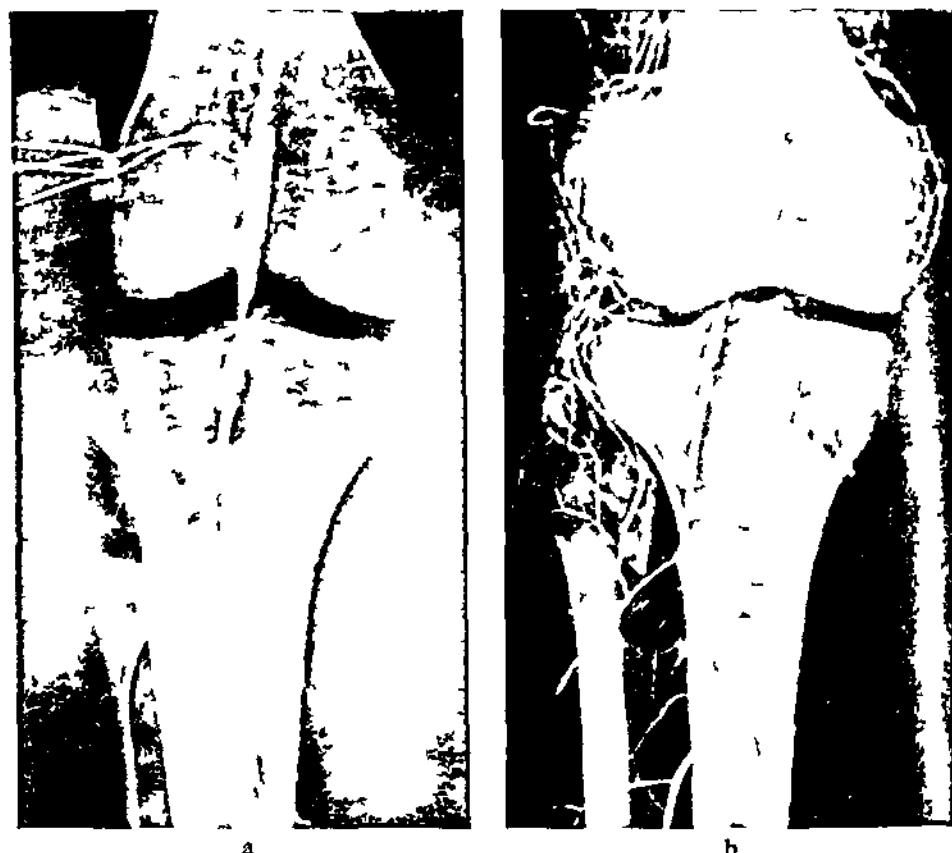


Fig 3 Unfavourable prognosis a) Multiple constrictions due to spasm intimal lesions and possibly also intimal thrombi b) Inefficient collaterals Primary arterial repair did not prevent late amputation

absent in the present material as were to a large extent the pertinent lesions—pseudoaneurysms and arteriovenous fistulas (LOVE & BRAUN ENGE et coll MC DONALD et coll) The type of injury mainly present in the material was the one resulting from blunt trauma which does not seem to give rise to pseudoaneurysms or arteriovenous fistulas (cf SMITH et coll 1969)

Two additional (relative) indications which did not appear in this material were either a neurologic disturbance attributable to a level at which the nerve and the artery run together or a penetrating injury near a major artery but without symptoms or signs (LUMPKIN et coll)

LEWIS et coll (1975 a) reported an increase of the peripheral vascular resistance on the traumatized extremity in dogs at 2 hours Although the angiographies in the present series were usually performed within 4 hours of admittance of the patients to the hospital only some fell within this time limit of 2 hours In 6 patients not belonging to this series immediate surgery was considered mandatory and no angiography was performed

FROM THE UROLOGICAL UNIVERSITY CLINIC (DIRECTOR: PROF. L. GIULIANI), I-16132
GENOA, ITALY

CYANOACRYLATES IN TRANSCATHETER RENAL EMBOLIZATION

G. CARMIGNANI, E. BELGRANO, P. PUPPO and L. GIULIANI

Cyanoacrylates are the commonly used fluid plastic agents for producing emboli. They were first introduced as tissue adhesives and as hemostatic agents. Later they were applied in neurosurgery in the treatment of cerebrospinal fluid rhinorrhea and as embolic material of aneurysms and arteriovenous malformations.

The acrylic compounds most often used are methyl methacrylate, N-butyl-2-cyanoacrylate (NBC, Histoacryl Braun) and Isobutyl-2-cyanocrylate (IBC, Bucrylate Ethicon). Methyl methacrylate was found to pass through the capillary filter and into the veins because of its slow polymerization, involving a high risk of pulmonary emboli.

The purpose of this communication is to report the experience of the use of IBC and NBC in transcatheter renal embolization based on animal experiments and on preoperative embolization in 2 patients with malignant tumor in the kidney.

Animal experiments

Material and Methods. Thirty Wistar rats weighing 250 to 300 g were used. Under ether anesthesia the left renal artery was selectively catheterized by a thin catheter (OD 0.5 mm) introduced into the left common iliac artery which was surgically exposed and distally ligated. Embolization of the kidney was achieved by injection of 0.05 to 0.08 ml of IBC or NBC. The injection must be carefully performed to avoid reflux into the aorta; even a small amount of the agent would cause a massive thrombosis, as actually occurred in 3 rats. On the other hand, a slow injection leads

Submitted for publication 7 February 1977.

4 – 785849

LUMPKIN M B LOGAN W D COUVES C M and HOWARD J M Arteriography as an aid in the diagnosis and localization of acute arterial injuries Ann Surg 147 (1958) 353

MANDAL A K BOITANO M A MAXWELL T M LOU M A and ALEXANDER J L Ninety eight penetrating vascular injuries A review of a two and one half year experience J Trauma 16 (1976) 354

McDONALD E J GOODMAN P C and WINESTOCK D P The clinical indications for arteriography in trauma to the extremity A review of 114 cases Radiology 116 (1975) 45

MORTON J H SOUTHGATE W A and DEWEESE J A Arterial injuries of the extremities Surg Gynec Obstet 123 (1966) 611

PIYACHON C and ARTACHINTA S Arteriography in trauma of the extremities Amer J Roentgenol 119 (1973) 580

SACKS R P The arteriographic evaluation of military vascular trauma Amer J Roentgenol 106 (1969) 394

SANDEGÅRD J and ZACHRISSON B E (a) Circulatory disturbances after experimental fracture Acta radiol Diagnosis 16 (1975) 181

— — (b) Angiography and hemodynamic measurements in extensive soft tissue trauma *to the extremity Acta radiol Diagnosis 16 (1975) 279*

SINKLER W H and SPENCER A D The value of peripheral arteriography in assessing acute vascular injuries Arch Surg 80 (1960) 300

SMITH R F SZILAGYI E and ELLIOT J P Jr Fracture of long bones with arterial injury due to blunt trauma Principles of management Arch Surg 99 (1969) 315

WENZ W Angiographie in einem traumatologischen Zentrum Radiologe 12 (1972) 264

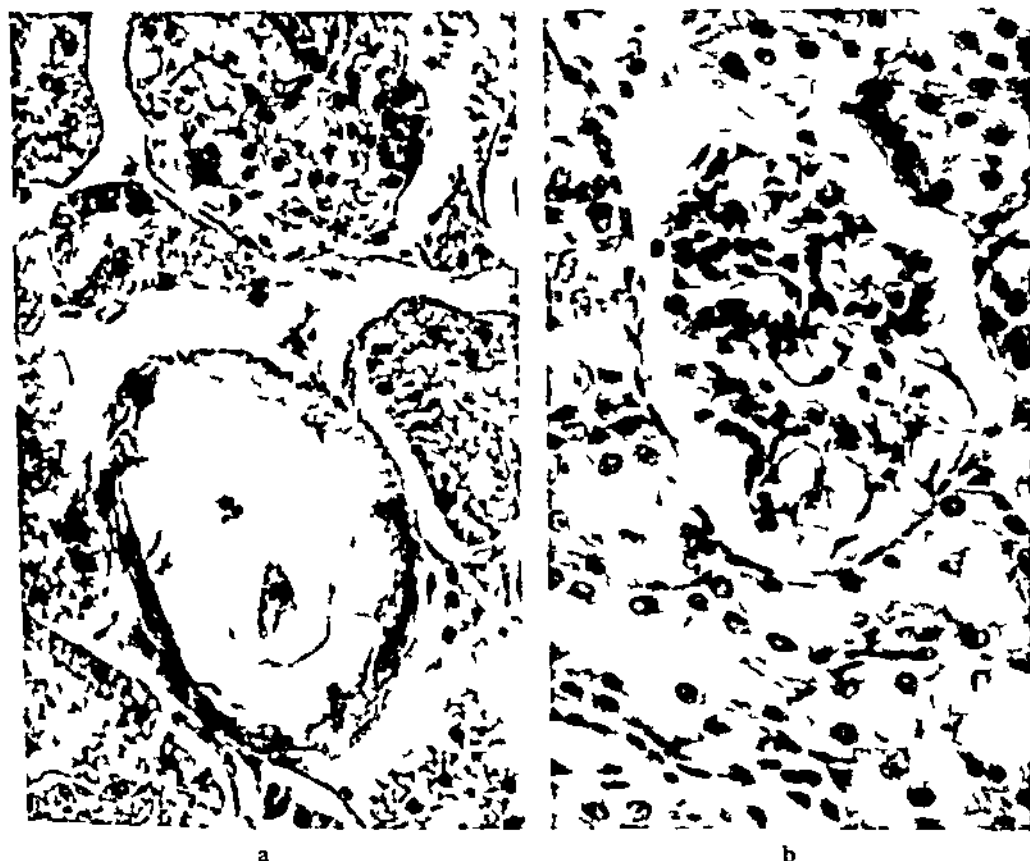


Fig 2 a) IBC thrombus in the renal artery (rat) b) NBC in glomeruli

the peripheral branches and appeared in the glomeruli (Fig 2 b) Several factors may influence the distribution of the emboli rate of injection amount used present blood flow and the perfusion of the kidney immediately before embolization IBC and NBC as opposed to methyl methacrylate do not pass through the capillary filter due to their instant polymerization and were never found in the veins The walls of the embolized arteries were without evident abnormality IBC and NBC remained intact and unmodified in the arteries even in the kidneys of the animals killed on day 21 In all cases the parenchyma appeared ischemic (Fig 3 a) in no case was any evidence of revascularization found The parvicellular and macrophagic infiltration was not higher than that in 3 control rats whose left renal artery was surgically ligated (Fig 3 b)

IBC and NBC had very similar characteristics Both were effective but difficult to handle IBC caused a higher mortality rate than NBC but many factors influence the survival of the rats (anesthesia septic complications etc) The experiments were too few to allow a definite conclusion that IBC has higher toxicity




Fig 3 a) Microscopic appearance of the kidney 21 days after embolization with evidence of NBC in small vessels b) Parvicellular and macrophagic infiltration

Clinical material

IBC was used in 2 cases with malignant renal tumors 63 and 65 years of age respectively In the first one with two arteries supplying the kidney 0 9 ml IBC was injected in one and Gelfoam in the other artery (Fig 4) In the second case 1 ml IBC was injected in the renal artery (Fig 5)

The technique used in these two cases differs only in some details from that normally used in embolization of renal tumors (GIULIANI et coll 1977 CARMIGNANI et coll 1977) The diagnostic 6 F (2 mm) catheter is replaced by a 7 F (2 3 mm) no-tip catheter which allows a coaxial 3 F (1 mm) polyethylene catheter to be easily passed With the aid of a 5 mm guide the inner catheter is advanced to a point about 2 cm beyond the outer catheter (Fig 6) A coaxial system is essential when IBC is used due to its instant polymerization which may spread also to the catheter obstructing it irreversibly It is important that the inner catheter can be easily removed immediately after embolization and that the outer one maintains its lumen to allow angiography after the embolization Continuous flushing of the interspace between

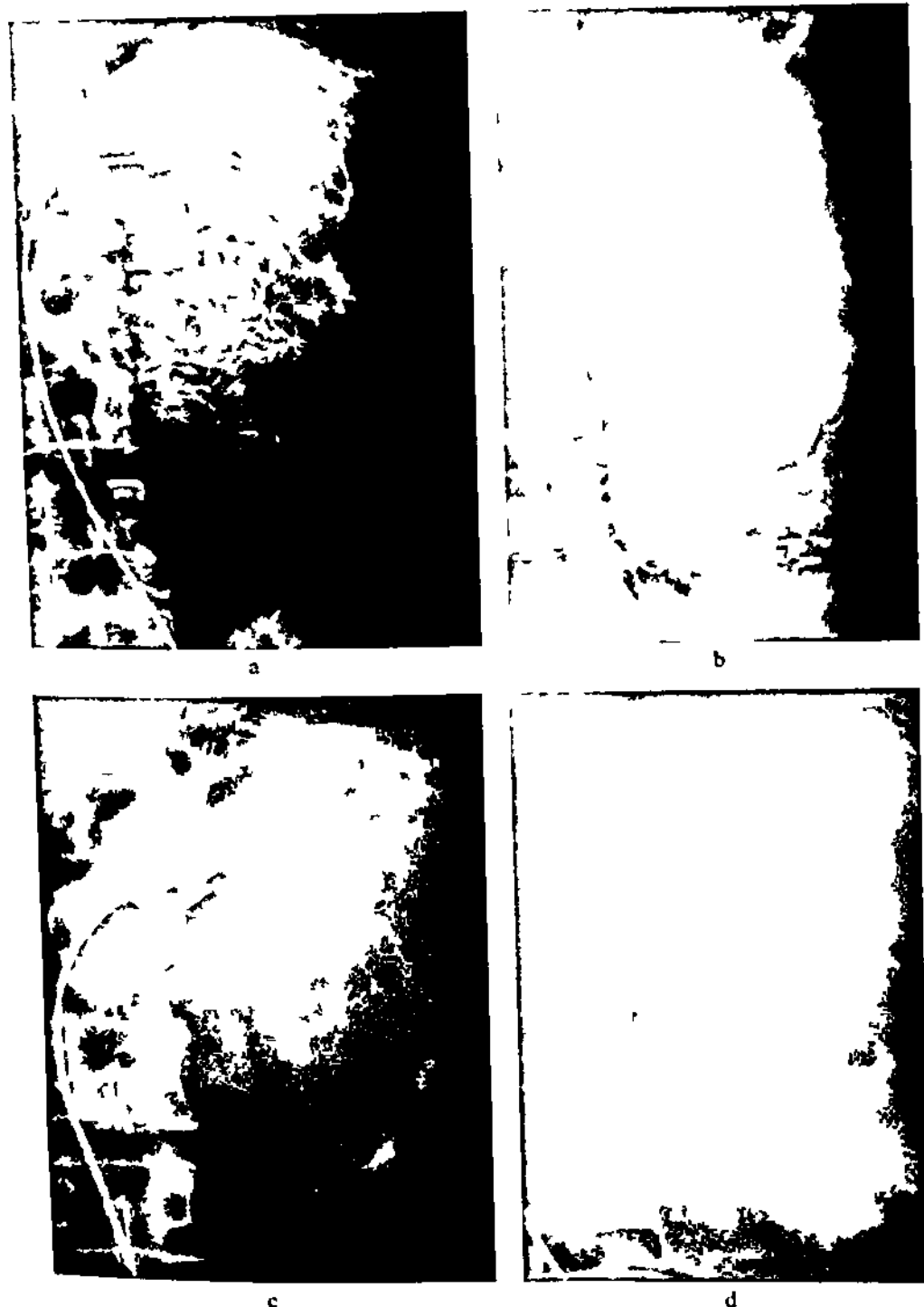


Fig 4 Selective angiography of a renal tumor Two renal arteries Injection into a) the upper and b) the lower artery Circulation stopped after embolization of c) the upper artery with IBC and d) the lower one with Gelfoam




Fig 5 a) Right renal carcinoma b) After embolization with IBC

the catheters with 5 per cent dextrose in water solution and washing of the inner catheter with this solution before injection of IBC is recommended

In both cases a massive embolization of the renal arteries was obtained The renal arteries injected with IBC were occluded already from the origin contrary to when Gelfoam was used The microscopic examination of the specimen confirmed the experimental results No complications occurred

Discussion

Preoperative transcatheter embolization of renal carcinomas has become a common practice Its purpose is to reduce the hypervascularity thus making the surgery easier and to reduce the possibility of metastatic dissemination during the surgical procedure

Since the majority of renal carcinomas should be operated upon embolization not followed by operation is uncommon (GIULIANI et coll 1977 GOLDSTEIN et coll 1975) Embolization with fluid materials is rare With IBC DOTTER et coll (1975) embolized a hypogastric artery in a case of massive vaginal bleeding due to pelvic carcinomatosis and both renal arteries in a patient on chronic renal dialysis in too poor condition for nephrectomy

IBC has never been used for embolization of renal carcinomas only NBC in a patient with widespread renal malignancy (THELEN et coll 1976)



Fig 6 Coaxial catheterization

IBC and NBC produce an efficient embolization and without doubt an irreversible one Their main disadvantages are difficulty in handling possible risk to the patient and difficulty in determining the correct amount of agent

It is necessary to prevent the acrylic compounds from coming into contact with the blood before the embolization as otherwise the risk of catheter occlusion is high The instant polymerization and irreversible arterial occlusion make IBC and NBC potentially dangerous even minimum spill over would produce irretrievable damage Finally the most critical factor is the determination of the correct amount The best results are obtained when the agent injected fills the catheterized artery only in such a way is a distal and complete embolization obtained The injection of an excessive quantity may lead to spill over and to a chemical injury to the arterial wall on the other hand an insufficient amount could lead to an incomplete occlusion of some arteries It is impossible to perform the injection gradually as is usually done with Gelfoam in acrylic embolization the amount must be exact for the size and flow of the artery the volume and the vascularity of the organ to be embolized

It may be pointed out that among the advantages of IBC and NBC besides their great efficiency is the fact that being fluid substances they can be injected through thin catheters and therefore used in superselective embolization of small arteries

IBC and NBC may be used as alternative materials both in preoperative and in therapeutic embolization In the former case they guarantee a surgical occlusion of the renal artery making the operation easier and theoretically possibly avoiding preliminary surgical ligation of the renal artery In the latter case their use is suitable because they are the only substances able to ensure a lasting embolization without evident side effects provided that only the tumor vessels are embolized

SUMMARY

Isobutyl 2-cyanoacrylate and N butyl 2-cyanoacrylate were used in experimental trans catheter embolization of rat kidneys and in two patients as preoperative embolization of

renal carcinoma The agents produced an efficient and lasting embolization with no evident complication however their usage is difficult and an appropriate dosage is also difficult

ZUSAMMENFASSUNG

Isobutyl 2 Cyanoacrylat und N butyl 2 Cyanoacrylat wurden zur experimentellen Trans katheter Embolisierung von Rattennieren und bei 2 Patienten zur postoperativen Emboli sierung von Nierentumoren verwendet Die Substanzen riefen eine effektive und anhaltende Embolisierung hervor ohne offenbare Komplikationen Der Gebrauch und die angemessene Dosierung sind jedoch schwierig

RESUME

L isobutyl 2-cyanoacrylate et le N butyl 2 cyanoacrylate ont ete utilisés en embolisation experimentale par cathéter sur des reins de rats et chez deux malades comme embolisation *pre opératoire de carcinome du rein Ces substances ont donné une embolisation efficace* et durable sans complication évidente cependant leur utilisation est difficile et le dosage approprie est lui aussi difficile

REFERENCES

ALMGÅRD L E FERNSTRÖM I HAVERLING M and LJUNGQVIST A Treatment of renal adenocarcinoma by embolic occlusion of the renal circulation Brit J Urol 45 (1973) 474

CARMIGNANI G GIULIANI L BELGRANO E PUPPO P e MARTORANA G L embolizzazione dell arteria renale nei tumori del rene Valutazione di una tecnica (In Italian) Poli clinico Sez chir In press

CLARISSE J GOZET G CORNIL J P JOMIN M DELANDSHEER J M et LAINE E Les em boles plastiques fluides J Neuroradiol 2 (1975) 29

DOTTER C T GOLDMAN M L and ROSCH J Instant selective arterial occlusion with isobutyl 2-cyanoacrylate Radiology 114 (1975) 227

GIULIANI L CARMIGNANI G BELGRANO E and PUPPO P Therapeutic embolization of renal cell carcinoma Europ Urol 3 (1977) 197

— — — — L embolizzazione preoperatoria dei tumori del rene (In Italian) Atti S I U — XLIX Congress — Ferrara 1976 In press

GOLDSTEIN H M MEDELLIN H BEYDOUN M T WALLACE S BEN MENACHEM Y BRA CHIS R B and JOHNSON D E Transcatheter embolization of renal cell carcinoma Amer J Roentgenol 123 (1975) 557

KELÂMI A Tissue adhesives Their use in urology Europ Urol 2 (1976) 182

MATSUMOTO T NEMHAUSER G M and SOLOWAY H B Cyanoacrylate tissue adhesives an experimental and clinical evaluation Milit Med 134 (1969) 247

THELEN M BRUHL F GERLACH H und BIERSACK H J Katheterembolisation von metasta sierten Nierenkarzinomen mit Butyl 2 Cyanoacrylat Fortschr Rontgenstr 124 (1976) 232

ZANETTI P H and SHERMAN F E Experimental evaluation of a tissue adhesive as an agent for the treatment of aneurysms and arteriovenous anomalies J Neurosurg 36 (1972) 72

FROM THE DEPARTMENT OF THORACIC RADIOLOGY KAROLINSKA SJUKHUSET S 104 01
STOCKHOLM SWEDEN

ANTERIOR BORDER OF THE LEFT ATRIUM ON CONVENTIONAL HEART FILMS

ALFRED SZAMOSI


The posterior wall of the intrapericardiac ascending aorta has recently been suggested for use in determination of the extension of the left atrium anteriorly at conventional roentgen examination of the heart (BERGSTRAND & SZAMOSI 1976) It was pointed out that the posterior aortic wall is directly continuous with the anterior mitral leaflet and hence adjacent to the left atrial wall at this level However difficulties arise when the left atrium is severely dilated it may then overlap the aorta on either side Occasionally the anterior left atrial wall has been observed on lateral chest films on segments other than those delineated by the ascending aorta This has been further investigated and the results are now reported

Materials and Methods

Lateral chest films of 32 patients were used With the exception of one adolescent all were adults and referred to chest examination because of clinically diagnosed heart disease Angina pectoris was present in one patient mitral valve disease of various aetiology either isolated or dominating in the remaining patients Left ventricular angiography was performed in 19 patients partly with demonstration of the left atrium In 10 patients the outlines of the right atrium were demonstrated by injection of contrast medium into the inferior vena cava right atrium or right ventricle (with reflux) The lateral chest films were compared with the lateral angio-

Submitted for publication 4 January 1977





a Fig 1 b

Fig 1 The enlarged left atrium bulging laterally on each side is outlined partly by aerated lung tissue and partly by its increased attenuation as compared with the surroundings Rheumatic mitral stenosis



Fig 2

Fig. 2 The dilated left atrium is outlined posteriorly by the oesophagus and anteriorly by a narrow layer of tissue with low attenuation (→) probably intra pericardial fat Congenital mitral insufficiency

grams Also in cases in which the patients were subsequently operated with insertion of valve prosthesis into the mitral or aortic orifice the pre operative chest films were compared with the post-operative ones The techniques for obtaining full size chest films as concerning equipment material processing etc were described in detail in the previous report (BERGSTRAND & SZAMOSI) In the present material the exposure times were somewhat longer as the hearts were generally enlarged The tube potential was kept at 170 to 190 kV the FFD was constant 2 m and the size of the focal spot 2 mm Biplane angiocardiography was performed with the use of a pair of 23 cm (9 inch) caesium iodide image intensifiers on 35 mm cine film




Fig 3 a) Periaortic fat outlines the anterior and posterior wall of the ascending aorta (→) Anterior wall of dilated left atrium outlined by fat (↔) overlapping the aorta Mitral insufficiency b) Frame of 35 mm left ventricular cineangiography lateral view The overlapping of the left atrium and aorta is evident

Results

In 17 patients a smoothly curved anteriorly convex area of lower attenuation appeared on the lateral view of the heart Its localisation and course closely resembled the anterior border of the left atrium (Figs 2–4) On cardioangiography with filling of the left ventricle left atrium or both the finding was confirmed in all cases The oesophagus was displaced posteriorly at the same level as the anterior border giving the enclosed area the characteristic shape of the dilated left atrium

In 10 patients a straightened Z like area but with smooth rounded course appeared from the area around the aortic orifice downward and posteriorly towards the area of junction between the inferior vena cava and the right atrium In shape and localisation it displayed striking resemblance to the segment of the posterior right atrial wall between the vena cava (Figs 5 6) Right atrial contrast injection was performed in 8 of these cases When the left atrium was filled its anterior wall invariably turned out to bulge into the same area In 5 patients elements of both contours were observed simultaneously i e on the same film

When the position of the mitral orifice was marked by calcifications or valve prosthesis it was invariably seen anteriorly to the structure resembling the right atrial border When the anterior left atrial border was outlined the mitral orifice was projected within 0 5 to 2 cm from it (direct measurement on the film) the distance obviously being dependent upon such factors as the degree of left atrial dilatation or the rotation of the heart around the vertical axis (Fig 7 a b) In one case of marked



Fig 1

Fig 1 The enlarged left atrium bulging laterally on each side is outlined partly by aerated lung tissue and partly by its increased attenuation as compared with the surroundings Rheumatic mitral stenosis



Fig 2

Fig 2 The dilated left atrium is outlined posteriorly by the oesophagus and anteriorly by a narrow layer of tissue with low attenuation (→) probably intra pericardial fat Congenital mitral insufficiency

grams Also in cases in which the patients were subsequently operated with insertion of valve prosthesis into the mitral or aortic orifice the pre operative chest films were compared with the post operative ones The techniques for obtaining full size chest films as concerning equipment material processing etc were described in detail in the previous report (BERGSTRAND & SZAMOSI) In the present material the exposure times were somewhat longer as the hearts were generally enlarged The tube potential was kept at 170 to 190 kV the FFD was constant 2 m and the size of the focal spot 2 mm Biplane angiocardiography was performed with the use of a pair of 23 cm (9 inch) caesium iodide image intensifiers on 35 mm cine film



a



b

Fig 3 a) Periaortic fat outlines the anterior and posterior wall of the ascending aorta (→) Anterior wall of dilated left atrium outlined by fat (↦) overlapping the aorta Mitral insufficiency b) Frame of 35 mm left ventricular cineangiography lateral view The overlapping of the left atrium and aorta is evident

Results

In 17 patients a smoothly curved anteriorly convex area of lower attenuation appeared on the lateral view of the heart Its localisation and course closely resembled the anterior border of the left atrium (Figs 2–4) On cardioangiography with filling of the left ventricle left atrium or both the finding was confirmed in all cases The oesophagus was displaced posteriorly at the same level as the anterior border giving the enclosed area the characteristic shape of the dilated left atrium

In 10 patients a straightened Z like area but with smooth rounded course appeared from the area around the aortic orifice downward and posteriorly towards the area of junction between the inferior vena cava and the right atrium In shape and localisation it displayed striking resemblance to the segment of the posterior right atrial wall between the vena cava (Figs 5 6) Right atrial contrast injection was performed in 8 of these cases When the left atrium was filled its anterior wall invariably turned out to bulge into the same area In 5 patients elements of both contours were observed simultaneously i e on the same film

When the position of the mitral orifice was marked by calcifications or valve prosthesis it was invariably seen anteriorly to the structure resembling the right atrial border When the anterior left atrial border was outlined the mitral orifice was projected within 0 5 to 2 cm from it (direct measurement on the film) the distance obviously being dependent upon such factors as the degree of left atrial dilatation or the rotation of the heart around the vertical axis (Fig 7 a b) In one case of marked



Fig 4




Fig 5a

Fig 4 The anterior contour of the moderately enlarged left atrium is outlined by a thin layer of low attenuation tissue Mitral stenosis



Fig 5b

Fig 5 a) Anterior border of the enlarged left atrium is outlined by a contour of low attenuation resembling the postero-medial wall of the right atrium (→) The intracardiac part of the ascending aorta (↔) is just discernible Mitral stenosis b) Frame of 35 mm cineangiography The postero medial wall of the right atrium delineated by slow infusion of contrast medium

left atrial enlargement the anterior wall of the left atrium overlapped the intrapericardiac part of the ascending aorta (Fig 3) In 2 other cases such overlapping of still greater degree was evident on the angiogram the aorta was however not outlined on the full size chest films

When several films of the same patient were available the visibility of the features under discussion showed inconstancy or considerable fluctuations even when the films were taken on the same day



a



b

Fig 6 a) The anterior wall of the left atrium is bordered by a narrow layer of low attenuation resembling the postero-medial wall of the right atrium Mitral stenosis b) Frame of cineangiography The right atrium is demonstrated The bulging of the left atrium into the posteriorly concave dorsal right atrial wall is evident

Discussion

The anterior wall of the left atrium can be loosely defined as that sector of its circumference which is directed anteriorly and is adjacent to the left ventricle the right atrium and the ascending aorta being enclosed between them The spatial relations between these four structures have long been well established A few aspects of the anatomy particularly relevant to the present argumentation are discussed and illustrated by McAlpine (1975) and Walmsley & Watson (1966) At the level of the aortic orifice the anterior wall of the left atrium is approximately parallel to the frontal plane and curves posteriorly on the right side as it turns into the interatrial septum When the left atrium is not or is only moderately enlarged the anterior wall is projected within a narrow area on the lateral film The severely dilated left atrium may on the other hand overlap and partly envelope the posterior aspects of the left ventricle right atrium or both The projection of the anterior wall may in such cases extend over a broader area the size of which will depend on the spatial orientation of the wall as well as on the left to-right extension of the atrium The projection of any point on the anterior wall e g as measured on its distance to the sternum will then vary according to the localisation of this point on the left–right axis



Fig 7 The same patient as in Fig. 1 after insertion of mitral valve prosthesis The effect of rotation of the patient on the relation between the anterior wall of the left atrium and the mitral orifice a) Left side and b) right side of the patient turned anteriorly

From a radiologic point of view the heart is usually considered as a homogereous organ The attenuation coefficients for heart muscle blood and pericardium differ very little from each other and consequently these tissues cannot presently be discriminated on a roentgen film of the chest However this does not necessarily mean that the radiologic image of the heart must in all circumstances appear homogeneous The muscular bulk of the heart is surrounded by two kinds of tissue which give diagnostically useful contrast against it viz aereated lung tissue and epicardial fat A contour may appear anywhere within the outlines of the heart wherever the boundary between heart muscle and lung or fat respectively is tangentially oriented relative to the central beam of the radiation A third factor which contributes to the creation of contrast is the varying thickness of the heart at different levels If the change in thickness as reflected in local attenuation is sudden from one part of the heart to another the contrast between the two areas can be perceived as a borderline

The evaluation of Fig 1 as the left atrium being surrounded by aereated lung tissue and having increased attenuation as compared with the surroundings seems to be a straightforward matter So is the evaluation of Figs 2–4 in which a continuous s-gment of the anterior left atrial wall is obviously outlined by a thin layer of epicardial fat As for the cases in which a feature resembling the postero-medial outlining of the right atrium is apprrent more than one interpretation is sometimes

possible In some cases the resemblance may be striking at contrast filling of the right atrium In other cases the possibility arises that what is seen is actually a compound image of structures situated at different depth i e the posterior outlining of the inferior v cava anterior outlining of the left atrium plus the posterior wall of the ascending aorta and is not primarily made out of the postero-medial right atrial border This distinction does not seem to have any practical consequence as the anterior left atrial border is outlined in any case

The delineation of the left atrium anteriorly even when faint and limited to certain segments has obvious diagnostic implications Its size can more accurately be assessed even when other cardiac chambers are enlarged Mitral valve calcifications are more easily detected and correctly interpreted as the search for them can be limited to specified smaller areas The false impression of left atrial enlargement created by the posterior deviation of the oesophagus caused by irrelevant factors is avoided by the observation of the true level of the atrium at a different height

Considering previous reports on the visibility of the intrapericardiac part of the ascending aorta (BERGSTRAND & SZAMOSI) and the appearance of the right coronary sulcus (SZAMOSI & JEREB 1977) on full size lateral chest films it appears that the radiologic image of the heart may contain more diagnostically useful information than is generally appreciated The information created in the moment of attenuation is often lost partly because of the movements of the heart and partly because it is not usual to look for it It may be assumed that the exposure times presently employed are still inadequate to prevent blurring due to the cardiac contractions Also the rotational component of the heart contractions may cause boundary surfaces between tissues or areas of different attenuation phasically to turn into and out of planes in which they could be demonstrated sharply enough for perception at low contrast levels The presently employed technique for obtaining chest films involves the exposure being made in a haphazard way with respect to the cardiac phases Possibly the delineation of these faint countours can more often be observed by the use of an ECG triggered exposure device and by further reduced exposure time

The limited size of the present material does not permit estimations of the frequency with which the left atrium can be delineated While the appearance on the lateral chest films of the ascending aorta in adults is a common phenomenon the visibility of other segments of the left atrial wall seems to be less common However this difference has bearings only in cases in which the left atrium is severly dilated

SUMMARY

The appearance of the anterior left atrial wall on conventional lateral chest films is presented The position of this structure is often marked by fatty tissue surrounding the posterior wall of the ascending aorta A markedly enlarged left atrium may overlap the aorta The delineation of the anterior border is still sometimes possible by observing a layer of epicardial fat surrounding the atrial wall or the interatrial sulcus The importance of short exposure time as well as the use of the findings in practical diagnostic work is discussed

ZUSAMMENFASSUNG

Das Aussehen der vorderen linken Wand des Atriums auf gewohnlichen seitlichen Thoraxfilmen wird beschrieben Die Position dieser Struktur ist oft durch Fettgewebe bezeichnet das die hintere Wand der Aorta ascendens umgibt Ein wesentlich vergrosserter linker Atrium kann auf die Aorta uberlappen Die Abgrenzung der vorderen Kante ist jedoch manchmal moglich durch Beachtung einer Schicht von Epikard Fett das die Atriumwand des interatrialen Sulcus umgibt Die Bedeutung einer kurzen Exponierungszeit sowie der Gebrauch der Befunde bei der praktischen diagnostichen Arbeit werden diskutiert

RESUME

L auteur decrit l aspect de la paroi anterieure de l oreillette gauche sur les radiographies simples de profil du thorax La position de cette structure est souvent marquée par un tissu adipeux qui entoure la paroi posterieure de l aorte ascendante Une oreillette gauche très augmentee de volume peut se superposer à l aorte La délimitation du bord antérieur est encore quelquefois possible en observant une couche de graisse épicardique qui entoure la paroi auriculaire ou le sillon inter auriculaire L auteur insiste sur l importance d un temps de pose court et examine l utilisation de ce signe dans la pratique du diagnostic

REFERENCES

BERGSTRAND G and SZAMOSI A Visibility of the intrapericardiac segment of the ascending aorta on conventional lateral chest films Acta radiol Diagnosis 17 (1976) 425

MCALPINE A W Heart and coronary arteries Springer Berlin Heidelberg & New York 1975

SZAMOSI A and JEREB M The appearance of the right coronary sulcus at conventional roentgen examination of the heart Acta radiol Diagnosis 18 (1977) 445

WALMSLEY R and WATSON H The medial wall of the right atrium Circulation 34 (1966) 400

FROM THE DEPARTMENTS OF DIAGNOSTIC RADIOLOGY AND MEDICAL PHYSICS HUDDINGE SJUKHUS S 141 86 HUDDINGE, THE DEPARTMENT OF MEDICAL PHYSICS DANDERYDS SJUKHUS S 182 03 DANDERYD AND THE DEPARTMENT OF FORENSIC MEDICINE KAROLINSKA INSTITUTET S 104 01 STOCKHOLM SWEDEN

UPTAKE OF $^{99}Tc^m$ GLUCONATE AND EARLY HISTOLOGIC FINDINGS IN INDUCED MYOCARDIAL INFARCTS IN DOGS

N E AHLBERG I BOIS SVENSSON B CALISSENDORFF R LEWANDER
H LUNDQUIST and J RAJS

Interest in radionuclides for detection of myocardial infarcts has increased rapidly during recent years Three different principles for uptake in the myocardium have been utilized Nuclides of potassium or its chemical analogues (cesium rubidium thallium) accumulate in normal myocardium proportionally to the blood flow (ROMHILT et coll 1973 ZARET et coll 1973 MARTIN et coll 1974) Using these nuclides an infarct is demonstrated as an area with a reduced uptake (cold spot) A second approach initiated by MALEK et coll (1963) is the use of $^{99}Tc^m$ tetracycline which concentrates in infarcted heart tissue (HOLMAN et coll 1973 1974) A third method is based on the localization of calcium ions in the mitochondria of myocardial cells in steroid induced focal necrosis (D AGOSTINO 1964) The calcium seemed to be incorporated within a crystalline structure believed to be hydroxyapatite (D AGOSTINO & CHIGA 1970) SHEN & JENNINGS (1972) found that intracellular calcium in the myocardium was accumulated following irreversible acute ischaemia

These observations indicated that it should be possible to use radioactive com

Submitted for publication 31 March 1977

pounds of a similar metabolic behaviour to detect acute infarcts as hot spots which are generally considered to be easier demonstrated than cold spots Consequently bone scanning agents as $^{99}Tc^m$ stannous pyrophosphate are now widely used for the purpose (BONTE et coll 1974) as well as $^{99}Tc^m$ stannous glucoheptonate (FINK BENNET et coll 1974 ROSSMAN et coll 1975)

In forensic pathology there is a great need for methods which allow an accurate post mortem identification of early stages of myocardial ischaemia The conventional routine histologic techniques are of limited value and fail to provide a diagnosis if a lethal complication occurs within six to nine hours after the onset of ischaemia In 1971 LIE et coll introduced a new staining technique the hematoxylin basic fuchsin picric acid method (HBFP) for demonstration of early abnormalities in myocardial ischaemia However opinions differ about the reliability of this technique (RAJS & JAKOBSSON 1976) and definitive assessment should await further experiences

The aim of this report is to evaluate the possibilities of using $^{99}Tc^m$ stannous gluconate so far not tested for detection of infarcts It is supposed to have affinity to intracellular hydroxy apatite For this reason animal experiments were performed to correlate the isotope uptake in early phases of induced myocardial infarction with the microscopic appearance with special regard to the findings at HBFP staining

Material and Methods

Radiopharmaceutical procedure The gluconate complex of $^{99}Tc^m$ was prepared by reacting calcium gluconate with tin reduced pertechnetate according to a method described by BOYD et coll (1973) Ten mg of the anhydrous $SnCl_2$ flakes was dissolved in 20 ml of sterile pyrogen free calcium gluconate solution The mixed stannous gluconate solution was purged with nitrogen through a 0 22 micron membrane sterile filter for two minutes and was then dispensed into 10 ml sterile and pyrogen free vials The vials were capped sealed and immediately frozen to be stored for the labelling procedure with $^{99}Tc^m$ pertechnetate The labelling efficiency exceeds 99 per cent

Procedure of occlusion of the coronary artery Nine adult mongrel dogs weighing between 10 and 30 kg were anesthetized with intravenous phenobarbital The intubated dogs were ventilated in an Aga respirator with O_2 and N_2O in combination with neuroleptanalgesia Muscle relaxation was achieved with pancuron bromide Following pericardotomy infarction of the myocardium was induced in 2 dogs by surgical ligature of the anterior interventricular branch of the left coronary artery The effect of the occlusion was checked with ECG recording and on visual inspection In 5 dogs the occlusion was nonsurgical and produced by application of a modification of the technique described by SZAMOSI (1972) Following catheterization of the left coronary artery performed via the right carotid artery and angiography of the left coronary artery a soft teflon-coated guide wire was inserted into its anterior

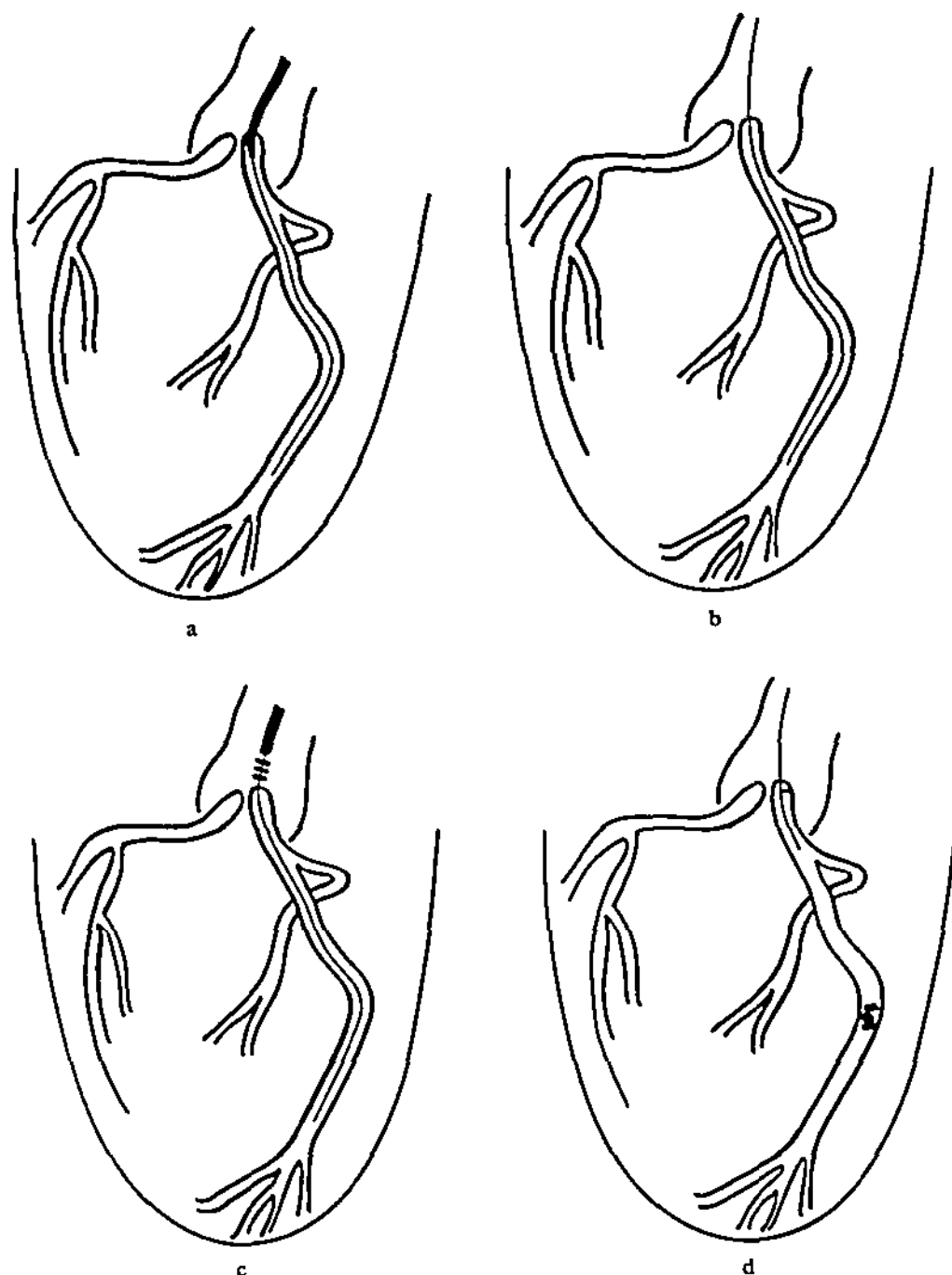


Fig 1 Drawing of occlusion procedure a) Left coronary artery catheterized with guide wire inserted into the anterior interventricular branch b) Catheter withdrawn c) Application of the rings d) Vessel embolized with rings Catheter and guide wire withdrawn

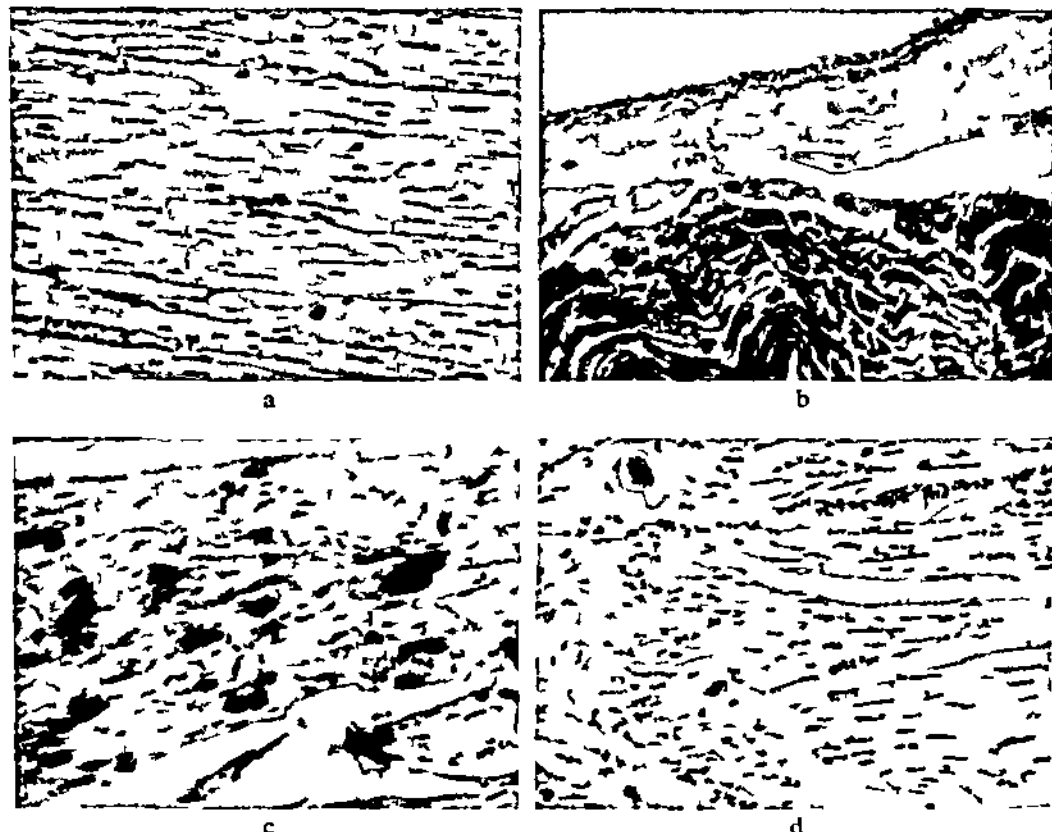


Fig 2 Grades of early stages of myocardial ischaemia induced by occlusion of coronary arteries in dogs HBFP staining method 33 a) Grade 0 Photomicrograph of a section from the myocardium of a control dog demonstrating ordinary appearance of regularly configurated myofibres originally stained light brown by the picric acid No uptake of basic fuchsin b) Grade I Dog killed 2 hours after the coronary artery occlusion Immediately beneath the endocardium (above) grey originally light brown stained Purkinje fibres In the inferior part wavy black (originally crimson red) stained typical heart muscle fibres c) Grade II 12 hours after coronary artery occlusion The myofibres swollen and distorted some of them necrotic and many of them black (originally crimson red) due to uptake of the basic fuchsin d) Grade III Myocardial infarct of a dog killed 19 hours after the occlusion of the anterior interventricular branch of the left coronary artery The blood vessels distended and interstitial haemorrhages on the right side On the left side necrotic myofibres and a polymorphonuclear leucocytic reaction Some myofibres adjacent to the necrotic zone stained black (originally crimson red) as a sign of a minimal uptake of the basic fuchsin stain

interventricular branch The catheter then was withdrawn and 6 to 8 rings of 2 mm length each cut from the same type of catheter were threaded on the guide wire The rings were pushed down to the proximal part of the arterial branch using a soft polyethylene catheter (Fig 1) The catheter and the guide wire were then removed Two further coronary angiographies were performed one immediately after the occlusion and the other one one hour later in order to check the effect of the occlusion The cardiac function was continuously checked with ECG recordings in all dogs The remaining 2 dogs served as controls consequently no infarction was induced but otherwise they were run identically with the other dogs

Table 1

Ratios of activities of ^{99}Tc^{m} gluconate measured in vitro in infarct blood normal myocard liver and lung

Dog (hours between coronary occlusion and killing)	Infarct/blood	Infarct/normal myocard	Normal myocard blood	Liver/blood	Lung blood
2	5	2	3	19	9
5	13	4	3	40	20
12	108	14	8	72	10
12	79	13	6	131	12
12	135	30	4	73	8
14	85	55	2	35	5
19	—	16	—	—	—
Controls	—	—	4	34	12

Isotope administration In the 2 dogs with surgical ligature 2 mCi ^{99}Tc^{m} gluconate was injected intravenously immediately after the occlusion of the coronary artery The dogs were killed 2 and 5 hours later In the nonsurgical group 10 mCi ^{99}Tc^{m} gluconate was injected 3 to 4 hours after the arterial occlusion these dogs were killed 10 to 19 hours after the occlusion

Uptake measurements All dogs were rapidly killed following interruption of the artificial respiration 2 to 19 hours after coronary occlusion and the heart was immediately removed from the thoracic cavity In the following all dogs are referred to as to the time (in hours) that elapsed between the coronary artery occlusion and their killing The infarct region was cut out using the epicardial branches of the occluded artery as a guide and divided into small central and peripheral blocks Blocks from the border region of the infarct and from adjacent apparently normal myocardium were also saved The blocks were weighed separately and a section was preserved for microscopy The activity of the myocardial blocks and samples from the lung liver and blood was measured in a NaI (Tl) well detector The detector was calibrated with a ^{99}Tc^{m} source standardized relative to the amount of active solution injected into the dogs

Histologic procedure and grading of the appearances in the myocardium The myocardial blocks saved for microscopic examination were fixed in 10 per cent neutral formalin for one to three days and embedded in paraffin Sections of 3 to 5 μm thickness from the whole block were stained with hematoxylin eosin (HE) and van Gieson as routine methods phosphotungstic acid hematoxylin (PTAH) to demonstrate early myocardial cell necrosis (Armed Forces Institute of Pathology 1960) and acid

Table 2

Ratios of activities of • Tc^{m} gluconate measured in vitro in infarct part of maximum uptake to normal myocardium

Dog (hours between coronary occlusion and killing)	Ratio
2	2 1
5	5 1
12	29 1
12	29 1
12	41 1
14	104 1
19	19 1
Controls	1 1

fuchsin stain according to POLEY et coll (1964) to demonstrate prenecrotic changes in myofibres Two to four parallel sections from each block were stained with hematoxylin–basic fuchsin picric acid (HBFP) according to LIE et coll (1971) The staining technique and mode of interpretation of results when using the two latter methods were performed as described by RAJS & JAKOBSSON

The microscopic appearances were graded as follows (Fig 2)

Grade 0 No abnormalities with routine staining methods No uptake of basic or acid fuchsin

Grade I Hypereosinophilia of myofibres but no other abnormalities with routine staining methods Uptake of basic fuchsin in at least one region consisting of several myofibres or in large areas demonstrable as crimson red coloured cytoplasma

Grade II Hypereosinophilia of myofibres appearance of single necrotic myofibres interstitial haemorrhages and polymorphonuclear leucocytes in the routine stained sections Uptake of basic fuchsin in myofibres close to necrotic fibres easily demonstrable in widespread areas

Grade III Widespread areas of necrotic myofibres and abundant polymorphonuclear leucocyte reaction as well as patchy areas of nonaltered myofibres Uptake of basic fuchsin present only in single myofibres

Grade 0 was considered as negative and grades I–III as positive for myocardial ischaemia

Extension of ischaemic lesions in the myocardium The extension of the ischaemic injury in each tissue block was classified in 5 groups according to the extension of the microscopic appearances in the sections 0 = 0 % extension = factor 0 1 = 1–25 extension = factor 0 25 2 = 26–50 extension = factor 0 50 3 = 51–75 % extension = factor 0 75 4 = 76–100 % extension = factor 1

The net weight of the infarct was estimated as the product of the weight of the myocardial block and the corresponding extension factor

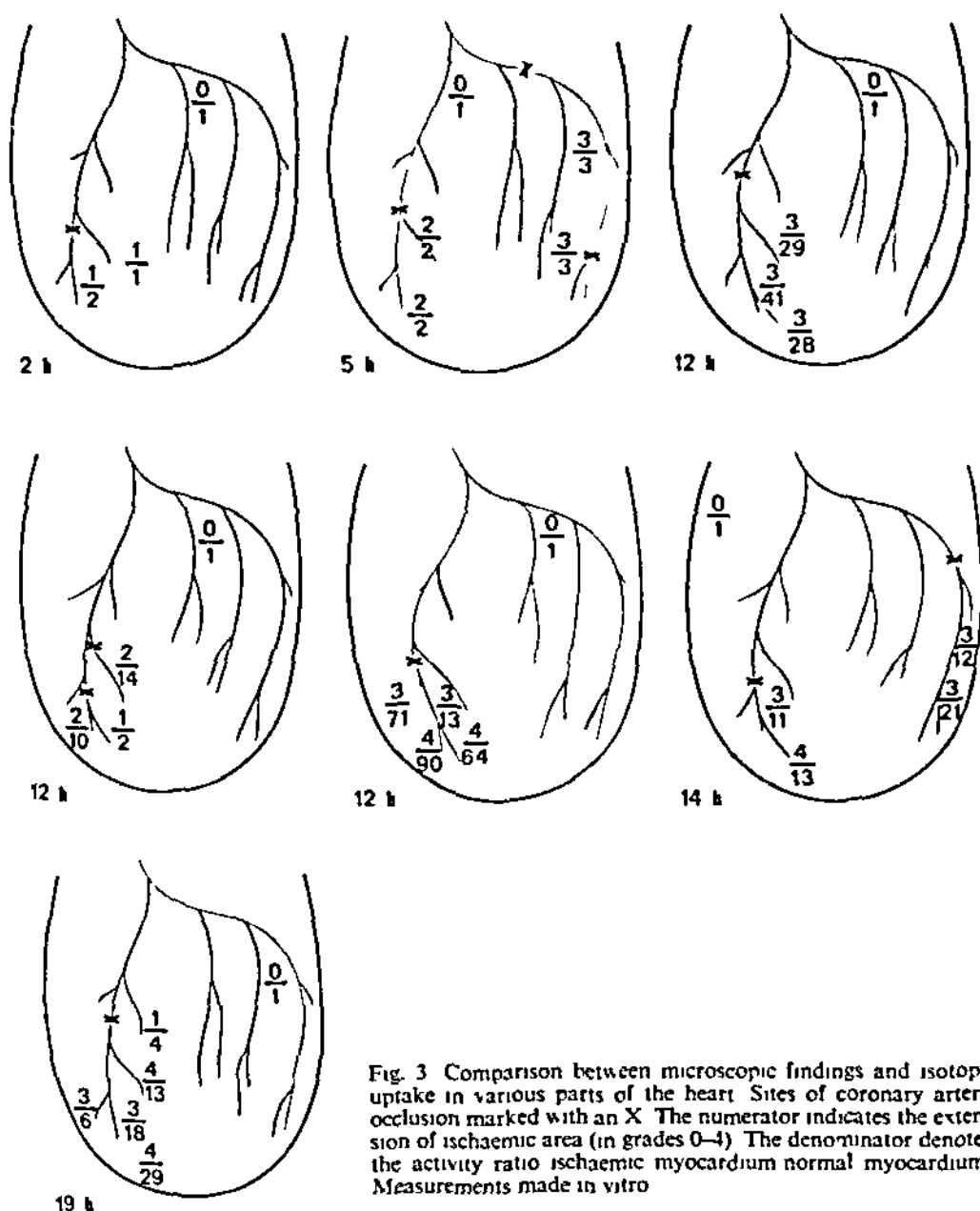


Fig. 3 Comparison between microscopic findings and isotope uptake in various parts of the heart Sites of coronary artery occlusion marked with an X The numerator indicates the extension of ischaemic area (in grades 0–4) The denominator denotes the activity ratio ischaemic myocardium normal myocardium Measurements made in vitro

Results

Uptake measurement An increased uptake of ^{99}Tc^{m} gluconate was demonstrated in all animals with induced myocardial infarction No increased isotope uptake was obtained in the 2 controls The results are presented as ratios i e activity/g myocardial block with the infarcted tissue related to activity/g blood normal myocardium

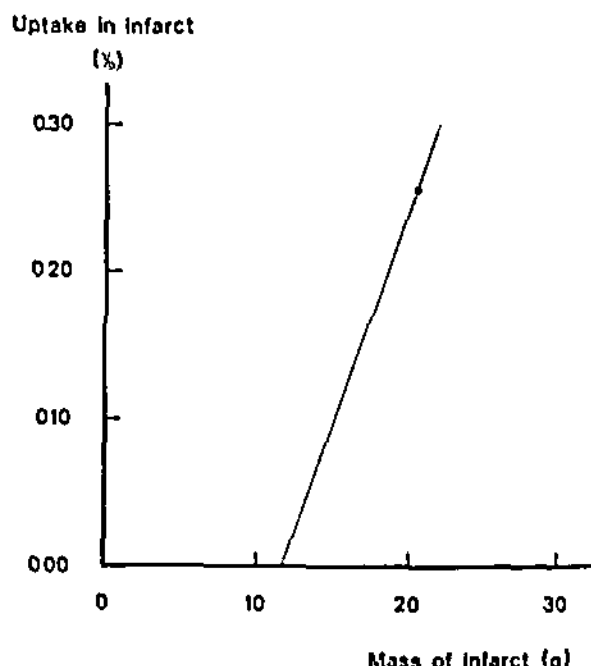


Fig 4 Correlation between uptake of $^{99}Tc^m$ gluconate and infarct mass in 12–14 hour dogs The infarct mass is calculated as the product of weight and extension of the infarction (●) No correction for extension of the infarct is made (○) Measurements in vitro

liver and lung (Table 1) In all dogs the ratio between activities of $^{99}Tc^m$ gluconate measured in vitro in the infarct and the normal myocardium varied from 2 to 55 and between infarct and blood from 5 to 135 In the 12–14 hour dogs the figures were 13 to 55 (mean 31) and 79 to 135 (mean 102) respectively (Table 1) When examining the central parts of the infarct still higher activities could be demonstrated (Table 2) In one dog the activity ratio central infarct/normal myocardium reached 104 A close correlation existed in the blocks between the extent of the ischaemic lesions and the isotope uptake (Fig 3) Similarly there was a clear correlation between the net infarct weight and the isotope uptake (Fig 4) No correlation was found between the weight of the excised infarct block of myocardium and the isotope uptake The ratio between the isotope uptake in liver and blood varied from 19 to 131 In 6 animals the ratio infarct/blood exceeded the ratio liver/blood In one 12 hour dog *the reversed relationship was found This animal had a macroscopic liver congestion*

Microscopy The 2 and 5 hour dogs had abnormalities of grade I in the infarct region (Fig 2) In the same myofibres an uptake of acid fuchsin sometimes occurred Occasionally waviness of the myofibres stained with HBFP method was demonstrated (BOUCHARDY & MAJNO 1971) However waviness was also observed in regions not stained with HBFP stain The infarcts of the 12-14 hour dogs mainly demonstrated lesions of grade II and the 19 hour dog of grade III No convincing uptake of basic fuchsin was noted in the Purkinje fibres not even in the area close to the intensively stained typical heart muscle fibres The uptake of basic fuchsin was at its maximum in the 5 and 12-14 hour dogs and was less marked in the 19

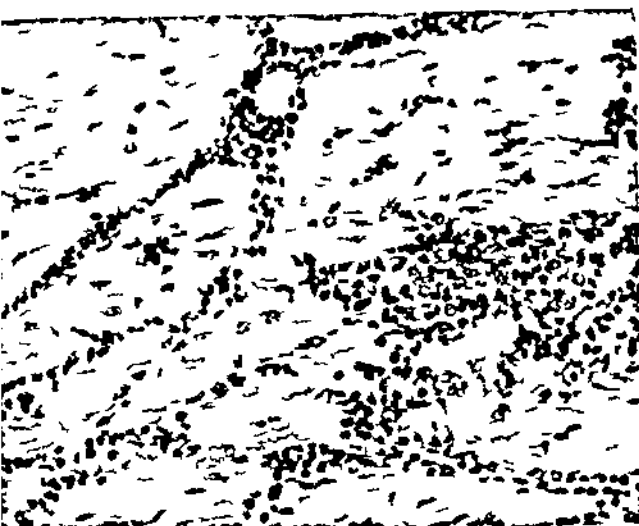


Fig 5 Myocardial section from a control dog not subject to infarction Accidentally a subacute myocarditis was found *but no uptake of basic fuchsin* HBFP 49

hour dog No microscopic alterations of ischaemic type were found in the hearts of the 2 control dogs therefore classified as grade 0 However minimal areas with uptake of basic fuchsin were noted at the margins of the blocks The same observation was also made in sections from non infarcted regions of the hearts *In* one of the controls a subacute myocarditis was found (Fig 5)

Discussion

The results indicate that ^{99}Tc^{m} gluconate like the analogue agent ^{99}Tc^{m} glucoheptonate accumulates in high concentration in ischaemic myocardial cells Since the relative distribution of the isotope between the infarct and the adjacent tissue should provide more pertinent information than the absolute infarct uptake the results are presented as ratios This would eliminate errors due to variation in weight of the hearts

The variation in ratio measurements (activity infarct/normal myocard and activity infarct/blood) may be explained by the fact that the isotope uptake is an active process leading to a maximum after a certain time following coronary artery occlusion The accumulation of the isotope in ischaemic myocardial cells is supposed to be caused by a redistribution of electrolytes beginning 3 to 4 hours after occlusion (SHEN & JENNINGS 1972) However in the present experiments isotope uptake has been detected already after 2 hours FINK BENNET et coll (1974) found the highest uptake in the margins of the infarct region 24 hours after coronary artery occlusion ROSSMAN et coll (1975) have shown that the maximum isotope uptake is located to areas with preserved although reduced blood flow In the present investigation all animals demonstrated the highest isotope uptake in the central part of the infarct indicating

that a central necrosis had not developed and that the lesion represented an early phase Thus when the infarct area was cut out by guidance of the epicardial vascular network both ischaemic and normal myocardium would appear in the block Depending on the topography of the vessels the weight of the block would give a higher value than that of the infarct To reduce this error the weight of the sample was corrected with a factor reflecting the microscopic extension of the infarct It was only after this correction that a close correlation appeared to the isotope uptake (Fig 4) These observations raise the question whether the correlation should be expressed as a straight line or a curve in the coordinate system where the x and y axes represent infarct weight and isotope uptake respectively Postulating a linear relationship the correlation line would intersect origo However in the present investigation the intersection is shifted to the right This may be explained by a systematic error in assessment of the extension of the infarct When calculating the net infarct weight the correction factor for extension will consequently reach too high a value because the factor expresses the maximum value in each group Thus an adequate method should be based on a more accurate planimetric evaluation of serial sections of the block Another possibility is that the relationship is not linear but a function of second degree the curve starting at origo with a slowly rising slope before it approximates to a straight line If this hypothesis be valid the uptake of the isotope and the basic fuchsin would have different time relationships

It has been demonstrated that $^{99}Tc^{m}$ gluconate like its analogue $^{99}Tc^{m}$ glucoheptonate accumulates in the liver (ROSSMAN et coll 1975) The dogs killed 2 and 5 hours after coronary artery occlusion had a higher activity ratio liver/blood than infarct blood indicating a faster accumulation of the isotope in the liver than in the ischaemic myocardium The reverse relationship was demonstrated in animals killed 12–19 hours after occlusion of the coronary artery (Table 1) However the rule did not apply in one animal with congestion of the liver demonstrated at autopsy It is not known whether the injury of the liver may account for the discrepancy

Microscopically the early ischaemic myocardial lesions were evaluated on the basis of uptake of basic fuchsin and the findings corresponded well with the results of isotope accumulation Other staining techniques—HE van Gieson PTAH and Poley s acid fuchsin—were of no value for detection of the ischaemic lesion in the 2 and 5 hour dogs HBFP staining of human myocardial sections is impaired by uncertainties due to post mortem autolytic changes fixation time thickness of the specimens and sensitivity of the staining procedure (RAJS & JAKOBSSON) However in these experiments performed under controlled conditions the HBFP staining method has been reliable and allowed detailed assessment of the extent of the ischaemic lesion

According to LIE et coll the uptake of the basic fuchsin is probably due to its binding to an unstable protein complex in the acutely ischaemic myocardium a mechanism which differs from that of the uptake of the isotope Although the present investigation does not disclose the nature of the mechanism resulting in a positive

HBFP stain it demonstrates that a correlation exists between the uptake of basic fuchsin and ^{99}Tc^{m} gluconate in the early phase of induced infarctions

Animals without induced infarction but otherwise examined identically were used as controls Microscopy of one of the controls revealed myocarditis but no increased isotope uptake was found in the corresponding parts of the myocardium (Fig 5) It seems that an inflammatory reaction in the heart will not cause an increased isotope uptake which supports the specificity for the uptake mechanism of the isotope

^{99}Tc^{m} gluconate appears to be a suitable agent for detection of early myocardial infarctions and with the HBFP staining technique the extension of the injury may be determined These results are guiding an in vivo investigation to follow with gamma camera imaging of animals with induced myocardial infarction

SUMMARY

A *new isotope ^{99}Tc^{m} gluconate for detection of myocardial infarction has been in*vestigated experimentally Great differences in isotope uptake between infarcted myocardium and normal myocardium were found in dogs A close correlation was found between *the isotope uptake and the uptake of basic fuchsin (HBFP) at microscopy in early* myocardial infarcts

ZUSAMMENFASSUNG

Eine neue Isotopenverbindung ^{99}Tc^{m} Gluconat wurde zur Feststellung des Myokardinfarktes *experimentell untersucht Grosse Unterschiede wurden in der Isotopenaufnahme* zwischen dem Infarktmyokard und dem normalen Myokard bei Hunden gefunden Eine enge Korrelation bestand zwischen der Isotopenaufnahme und der Aufnahme von basischem Fuchsin (HBFP) bei der Mikroskopie von fruhzeitigen Myokardinfarkten

RESUME

Les auteurs ont fait une etude expérimentale d un nouvel agent isotopique le gluconate de ^{99}Tc^{m} pour la détection de l infarctus du myocarde Ils ont trouve sur des chiens une fixation tres differente de cet isotope dans le myocarde infarci et le myocarde normal Il y a une corrélation etroite entre la fixation de l isotope et la fixation de la fuchsine basique (HBFP) a l *examen microscopique dans les infarctus du myocarde au stade precoce*

REFERENCES

Armed Forces Institute of Pathology Manual of histological and special staining technique 2nd ed McGraw Hill *New York 1960*

BONTE F J PARKEY R W GRAHAM K D and MOORE J G Distribution of several agents useful in imaging myocardial infarcts J nucl Med 16 (1975) 132

— — — — and STOKELY E M A new method for radionuclide imaging of myocardial infarcts Radiology 110 (1974) 473

BOTVINIK E H SHAMES D LAPPIN H TYBERG J V TOWNSEND R and PARMLEY W W Noninvasive quantitation of myocardial infarction with 99Tcm pyrophosphate Circulation 52 (1975) 909

BOUCHARDY B and MAJNO G A new approach to the histologic diagnosis of early myocardial infarcts Cardiology 56 (1971) 327

BOYD R E ROBINSON J HUNT F C SORBY P J MURRAY J P C and MCKAY W J 99Tcm gluconate complexes for renal scintigraphy Brit J Radiol 46 (1973) 604

BUJA M PARKEY R W DEES J H STOKELY E M HARRIS R A BONTE F J and WILLERSON J T Morphologic correlates of technetium 99m stannous pyrophosphate imaging of acute myocardial infarcts in dogs Circulation 52 (1975) 596

DEWANJEE M K and PRINCE E W Cellular necrosis model in tissue culture uptake of 99Tcm tetracycline and the pertechnetate ion J nucl Med 15 (1974) 577

D AGOSTINO A N An electron microscopic study of cardiac necrosis produced by 9α fluorocortisol and sodiumphosphate Amer J clin Pathol 45 (1964) 633

— and CHIGA M Mitochordrial mineralization in human myocardium Amer J clin Pathol 58 (1970) 820

FINK BENNET D DWORKIN H J and LEE Y H Myocardial imaging of the acute infarct Radiology 113 (1974) 449

FLEISCH H MAERKI J and RUSSEL R G Effects of pyrophosphate on dissolution of hydroxyapatite and its possible importance in calcium homeostasis Proc Soc exp Biol 122 (1966) 317

HOLMAN B L DEWANJEE M K IDOINE J FLIEGEL C P DAVIS M A TREVES S and ELDH P Detection and localization of experimental myocardial infarction with 99Tcm tetracycline J nucl Med 14 (1973) 595

— LESCH M ZWEIMAN F G TEMTE J LOWN B and GORLIN R Detection and sizing of acute myocardial infarcts with 99Tcm (Sn)-tetracycline New Engl J Med 291 (1974) 159

JUNG A BISAZ S and FLEISH H The binding of pyrophosphate and two diphosphonates by hydroxyapatitecrystals Calc Tissue Res 11 (1973) 269

LIE J T HOLLEY K E KAMPA W R and TITUS J L New histochemical method for morphologic diagnosis of early stages of myocardial ischemia Mayo Clin Proc 46 (1971) 319

MALEK P KOLC J ZASTAVA V ZATC F and PELESTRA B Fluorescence of tetracycline analogues fixed in myocardial infarction Cardiologia (Basel) 42 (1963) 303

MARTIN N D ZARET B L MCGOWEN R L WELLS H P and FLAMM M D Rubidium 81 a new myocardial scanning agent Radiology 111 (1974) 651

— — STRAUSS H W WELLS H P and ALBERS J Myocardial imaging using 43K and the γ-camera Radiology 112 (1974) 446

POLEY R W FOBES C D and HALL M J Fuchsinophilia in early myocardial infarction Arch Pathol 77 (1964) 325

RAJS J and JAKOBSSON S Experiences with the hematoxylin basic fuchsin picric acid staining method for morphologic diagnosis of myocardial ischemia—an experimental study in forensic pathology Forens Sci 8 (1976) 37

ROMHILT D W ADOLPH R J SODD W J LEVENSON N J AUGUST L S NISHIYAMA H and BERKE R A Cesium 129 myocardial scintigraphy to detect myocardial infarction Circulation 49 (1973) 1242.

ROSSMAN D J ROULEAU J STRAUSS H W and PITT B Detection and size estimation of acute myocardial infarction using 99Tcm glycoheptonate J nucl Med 16 (1975) 980

— STRAUSS H W., SIEGEL M E and PITT B Accumulation of 99Tcm glucoheptonate in acutely infarcted myocardium J nucl Med 16 (1975) 875

SHEN A. and JENNINGS R., Kinetics of calcium accumulation in acute myocardial ischemic injury. Amer. J. Pathol. 67 (1972) 441.
STOKELY E. M., BUJA L. M., LEWIS S. E., PARKEY R. W., BONTE F. J., HARRIS R. A. and WILLERSON J. T., Measurement of acute myocardial infarcts in dogs with ^{99m}Tc-stannous pyrophosphate scintigrams. J. nucl. Med. 17 (1976) 1.
SZAMOSI A., Experimental occlusion of the coronary arteries in the closed-chest dog. A selective method. Acta radiol. Diagnosis 12 (1972) 545.
ZARET B., STRAUSS H. W., MARTIN N. D., WELLS H. P. and FLAMM M. D., Noninvasive regional myocardial perfusion with radioactive potassium. Study of patients at rest, with exercise and during angina pectoris. New Engl. J. Med. 288 (1973) 809.
ZWEIMAN F. G., HOLMAN B. L., O'KEEFE A. and IDOINE J., Selective uptake of ^{99m}Tc-complexes and ^{67}Ga in acutely infarcted myocardium. J. nucl. Med. 16 (1975) 975.

BOTVINIK E H SHAMES D LAPPIN H TYBERG J V TOWNSEND R and PARMLEY W W Noninvasive quantitation of myocardial infarction with ^{99}Tc^{m} pyrophosphate Circulation 52 (1975) 909

BOUCHARDY B and MAJNO G A new approach to the histologic diagnosis of early myocardial infarcts Cardiology 56 (1971) 327

BOYD R E ROBINSON J HUNT F C SORBY P J MURRAY J P C and MCKAY W J ^{99}Tc^{m} gluconate complexes for renal scintigraphy Brit J Radiol 46 (1973) 604

BUJA M PARKEY R W DEES J H STOKELY E M HARRIS R A BONTE F J and WILLERSON J T Morphologic correlates of technetium 99m stannous pyrophosphate imaging of acute myocardial infarcts in dogs Circulation 52 (1975) 596

DEWANJEE M K and PRINCE E W Cellular necrosis model in tissue culture uptake of ^{99}Tc^{m} tetracycline and the pertechnetate ion J nucl Med 15 (1974) 577

D AGOSTINO A N An electron microscopic study of cardiac necrosis produced by 9α fluorocortisol and sodiumphosphate Amer J clin Pathol 45 (1964) 633

— and CHIGA M Mitochordrial mineralization in human myocardium Amer J clin Pathol 58 (1970) 820

FINK BENNET D DWORKIN H J and LEE Y H Myocardial imaging of the acute infarct Radiology 113 (1974) 449

FLEISCH H MAERKI J and RUSSEL R G Effects of pyrophosphate on dissolution of hydroxyapatite and its possible importance in calcium homeostasis Proc Soc exp Biol 122 (1966) 317

HOLMAN B L DEWANJEE M K IDOINE J FLIEGEL C P DAVIS M A TREVES S and ELDH P Detection and localization of experimental myocardial infarction with ^{99}Tc^{m} tetracycline J nucl Med 14 (1973) 595

— LESCH M ZWEIMAN F G TEMTE J LOWN B and GORLIN R Detection and sizing of acute myocardial infarcts with ^{99}Tc^{m} (Sn) tetracycline New Engl J Med 291 (1974) 159

JUNG A BISAZ S and FLEISH H The binding of pyrophosphate and two diphosphonates by hydroxyapatitecrystals Calc Tissue Res 11 (1973) 269

LIE J T HOLLEY K E KAMPA W R and TITUS J L New histochemical method for morphologic diagnosis of early stages of myocardial ischemia Mayo Clin Proc 46 (1971) 319

MALEK P KOLC J ZASTAVA V ZATC F and PELESTRA B Fluorescence of tetracycline analogues fixed in myocardial infarction Cardiologia (Basel) 42 (1963) 303

MARTIN N D ZARET B L MCGOWEN R L WELLS H P and FLAMM M D Rubidium 81 a new myocardial scanning agent Radiology 111 (1974) 651

— — STRAUSS H W WELLS H P and ALBERS J Myocardial imaging using ^{43}K and the -camera Radiology 112 (1974) 446

POLEY R W FOBES C D and HALL M J Fuchsinophilia in early myocardial infarction Arch Pathol 77 (1964) 325

RAJS J and JAKOBSSON S Experiences with the hematoxylin basic fuchsin picric acid staining method for morphologic diagnosis of myocardial ischemia—an experimental study in forensic pathology Forens Sci 8 (1976) 37

ROMHILT D W ADOLPH R J SODD W J LEVENSON N J AUGUST L S NISHIYAMA H and BERKE R A Cesium 129 myocardial scintigraphy to detect myocardial infarction Circulation 49 (1973) 1242

ROSSMAN D J ROULEAU J STRAUSS H W and PITT B Detection and size estimation of acute myocardial infarction using ^{99}Tc^{m} glycoheptonate J nucl Med 16 (1975) 980

— STRAUSS H W SIEGEL M E and PITT B Accumulation of ^{99}Tc^{m} glucoheptonate in acutely infarcted myocardium J nucl Med 16 (1975) 875

satory Each curve contains an apical vertebra which is located in the part of the curve farthest from the median plane of the body it is the vertebra the axis of which is most nearly parallel with the median plane Transitional vertebrae are located one at each end of a curve and mark the transition to another curve—that is where there is a change in the direction of curvature

Before the proposed new definition is presented a number of other measurement techniques will be described

The Cobb Method The method for measuring scoliotic curves which is in most common use is that made familiar by COBB whose name it now bears (Fig 1) On an a p film of the spine lines are drawn parallel to the superior and inferior surfaces of the cranial and caudal transitional vertebrae of the curve The angle formed by the lines then provides a measure of the angle between the planes of the superior and inferior surfaces or between the axes of the vertebral bodies Drawing of the necessary line demands that the superior or inferior surfaces of the vertebral bodies be projected as lines i e they must be parallel to the projecting rays This is usually not the case They form a small angle with the projecting rays and these surfaces are then depicted as figures mostly resembling deformed ellipses It is difficult to draw a line on the film that is parallel to such a surface The examiner usually draws a line parallel to the major axis of the elliptical figure thus introducing a small error

The Cobb angle is defined as an angle between two lines drawn on the film It is not an angle in the anatomy of the patient that is measured There is certainly a relationship between the measured angle on the film and the spine deformity This relationship is however not defined and it varies with the position of the patient and of the film and the direction of the projecting rays

The Ferguson Method The next most commonly used method is that introduced by FERGUSON in the twenties Here the centres of the bodies of the apical and the transitional vertebrae are marked on an a p film of the spine The angle between the lines joining the centres is then measured The centre of a vertebral body is usually taken as the intersection of the diagonals of the body as demonstrated on the film Though this is not an anatomically defined point it may still be used when only one a p projection is taken

The Ferguson angle is easy to construct and it is usually smaller than the Cobb angle for the same curve

The two methods both have the shortcoming that they define the scoliosis angle as an angle measured on a film It would have been more satisfactory if the definition of the angle were based on the anatomic deformity The measurements on the films would then be recognized as an attempt to measure this angle The merits of different methods for measuring this angle could then be discussed and compared with each other

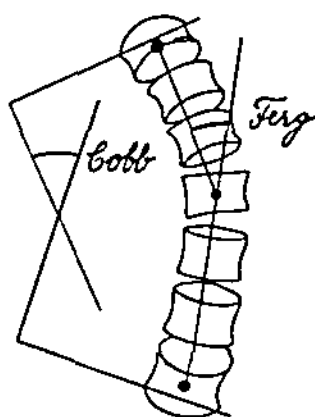


Fig 1




Fig 2

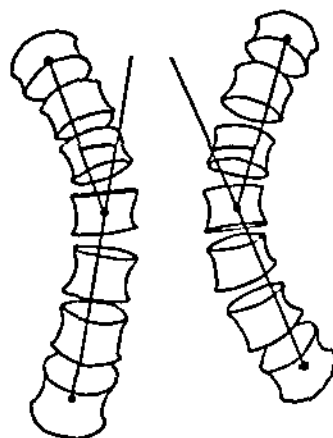


Fig 3

Fig 1 Scoliotic angles measured by the Cobb and Ferguson methods A p projection

Fig 2 Registration of scoliotic angles by the Tidestrom method

Fig 3 The solid angle or maximum scoliosis angle of Lindahl and Movin in antero posterior (left) and lateral (right) projections

The Tidestrom Method In 1964 TIDESTRÖM reported a method in which a series of Cobb angles—one for each surface of the vertebral body—represents the curvatures in the spinal column as a whole The angles are plotted in a diagram (Fig 2) Such a diagram for an a p and a lateral projection provides a complete picture of the *curvature of the spinal column but it is subject to the same objections as apply to the* Cobb angles

The Lindahl Movin Method (solid angle or maximum scoliosis angle) In 1968 LINDAHL & MOVIN showed that variations in the Ferguson angle due to the projection can arise if the patient is not positioned identically at different examinations This is particularly the case for a kyphoscoliotic angle in which the kyphosis is predominant If the patient stands with a slightly different degree of rotation on different occasions of examination there may be a considerable difference in the scoliosis angle on the a p film

If instead the solid angle is calculated the reproducibility will be better The solid angle is the anatomic angle between the lines joining the centres of the apical and transitional vertebral bodies in the scoliotic curve—that is a Ferguson angle in space (Fig 3) *To calculate the solid angle two projections are required It is then* possible to use the stereo instrument designed by Edholm (1966) for determining the anatomic angle from two projections LINDAHL & MOVIN also described another procedure In fluoroscopy the patient is turned until the spinal column is projected straight on the fluoroscopic screen With the patient in this position a film is exposed perpendicular to this projection

If as a measure of the scoliotic deformity the solid angle is used which in most

cases is a kyphoscoliotic angle a pure measure of the actual deformity—the scoliosis—is no longer obtained It is true that additional information on the position of the plane of the solid angle gives an impression of the magnitude of the scoliotic part of the deformity but if the plane of the angle changes position between examinations the scoliotic component of the solid angles will be difficult to estimate

Photogrammetric Method Hindmarsh (1973) described an experimental method in which the position of the vectors of the vertebral bodies in space is determined by means of a photogrammetric technique These vectors are defined as the lines joining the centres of gravity of the bases of the arches and the centres of gravity of the vertebral bodies On stereo projections of the vertebral column the points defining the vectors are marked The space coordinates of the points are measured in a stereo comparator and these are then entered in a coordinate system the vertical axis is defined by the upper and lower transitional vertebrae in the curve and the sagittal axis is approximately parallel to the sagittal plane The transverse axis therefore corresponds largely to a transverse axis in the body

Changes in the position of the vertebral bodies and their degree of rotation can be examined to an acceptable level of accuracy over the whole scoliotic curve The method provides a detailed description of the complete scoliotic deformity A special advantage of this method is that it enables the degree of rotation of the vertebral bodies to be estimated The procedure is complicated however and unsuitable for clinical use The method is not based on measurement of scoliotic angles but on determination of the relative position of the vertebral bodies

Concept of scoliosis

The median plane in a symmetric human body is the only plane which has a natural definition It is the plane of symmetry The transverse axis is perpendicular to the median plane and may also be regarded as a naturally defined axis The spinal column has a varying degree of kyphosis and lordosis but over its whole length the normal vertebral column lies in the sagittal plane The vertebrae and the spinal column are thus normally angled only forwards and backwards In scoliosis the vertebral column and the vertebrae are also inclined laterally

The present definition of the scoliosis angle is vague and based on different methods of measurement It would be more satisfactory to have a definition based on the anatomy of the patient and not on the measurements on the films A good definition should also give an angle that is proportional to what is intuitively understood as a scoliotic deformity i e the lateral deviation of the spine This angle should also be independent of the normal curves of the spine in the median plane

The easiest way out would seem to be to define it backwards so that the definition completely agrees with the Cobb angle or the Ferguson angle which ever one prefers The definition could be based on the angles the spine makes with the long

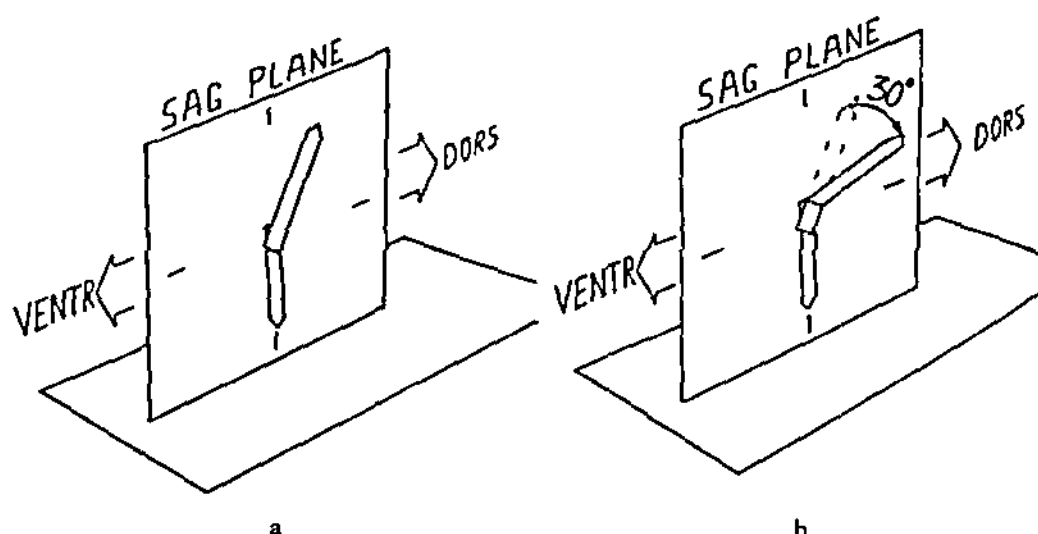


Fig 4 Clock face model a) before and b) after the hour hand has been bent out from the plane of the face through an angle of 30 The hands symbolize the arms of the scoliotic angle a) Lordotic angle and b) lordotic and scoliotic angle of 30

axis of the body projected on the frontal plane The weak points in this definition are that the long axis and the frontal plane have no exact definition that is they are difficult to define in relation to the anatomy If the long axis is defined as a vertical axis in a standing patient its position relative to the anatomy will vary according to how the patient is positioned A scoliosis angle according to this definition will also vary with the natural curvatures of the spine in the median plane

Proposal for an anatomic basis for measurement of scoliosis It seems possible to find a definition that fulfils the requirements mentioned if the scoliotic deviation is defined as a deviation from the median plane of the body This definition makes the scoliosis angle independent of the natural curves of the spine in the median plane and also independent of the technique of measurement

The Cobb angle should then be defined as the combined inclination of the two transitional vertebrae with the median plane The measurement performed on an a p film is then seen as an attempt to measure this angle In the case in which the two transitional vertebrae are parallel with the film it is an exact measurement In the same way the Ferguson angle should be defined as the sum of the two angles formed by the lines from the apical vertebrae to the two transitional vertebrae with the median plane The measurement on an a p film is an attempt to measure the angle so defined In the case in which the two lines are parallel to the film it is an exact measurement of the defined angle

Thus if the Cobb angle and the Ferguson angl are re defined according to the proposed anatomic basis they would give values that in the special case are

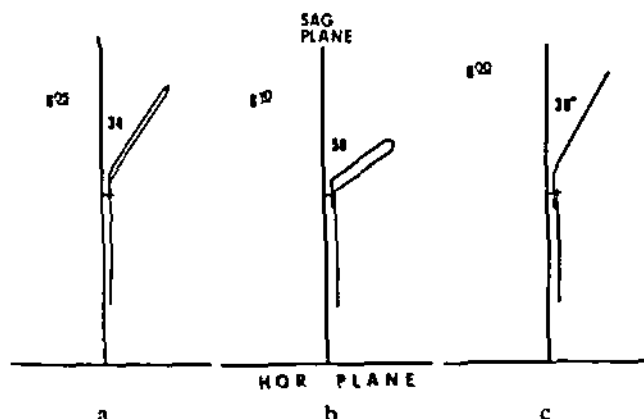


Fig 5 a) The model seen from the ventral side corresponding to an a p projection The 30 scoliotic angle is projected as 34 b) The upper hand has been rotated from 5 to 10 min past the hour The projected scoliotic angle is then increased to 50 c) The scoliotic angle of 30 is correctly reproduced only when the upper hand is at 12 o clock —that is when the plane containing the arms of the angle is parallel to the image plane

identical with the values of angles measured according to the old definition The proposed new definition of these angles can therefore be considered as an extension of the previous ones

Discussion

The proposed new definition is illustrated by the following example A clock face is illustrated in Fig 4 a with the hands pointing to 5 minutes past 6 Let the plane of the clock face a sagittal plane and the hands be the two lines joining the centres of the three vertebral bodies In this model of the spinal column the angle between the hands represents a lordotic angle However there is no scoliotic angle because the hands are parallel to the sagittal plane In Fig 4 b a scoliotic angle has been introduced by bending the minute hand outwards from the sagittal plane through an angle of 30 The scoliotic angle between the lines (the hands) will thus be 30 since the lower line (one hand) is still parallel to the sagittal plane

In Fig 5 a an a p film of the model of the vertebral column appears Here the 30 scoliotic angle is projected as an angle of 34 a value that would be obtained from a measurement performed with the Ferguson method If the lordosis in the model increases so that the hands are at 10 min past 6 the Ferguson angle increases to 50 (Fig 5 b) Only when the minute hand is turned to 12 is the scoliotic angle correctly projected (Fig 5 C) the two lines are then parallel to the frontal plane on which the angle is projected The difference between the Cobb and the Ferguson angles measured on the a p film and the corresponding angles measured by the method now proposed is quite moderate as long as neither of the lines containing the scoliotic angle makes a larger angle than about 10 with the frontal plane

Hypothetical representation of the angles of all the vertebrae with the sagittal plane

The angle that a line makes with the sagittal plane of the body will be correctly represented by an a p projection irrespective of the angle that the line makes with

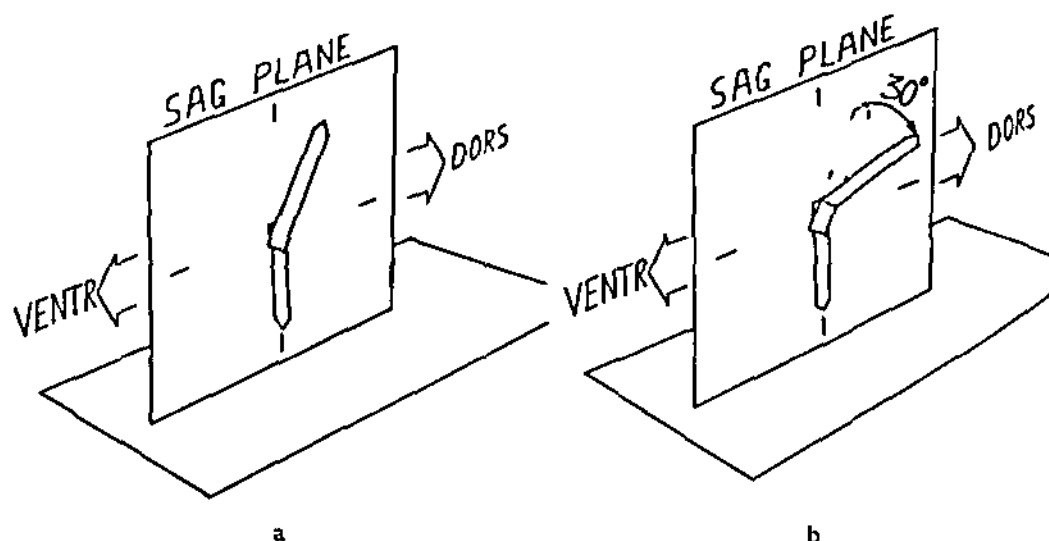


Fig 4 Clock face model a) before and b) after the hour hand has been bent out from the plane of the face through an angle of 30 The hands symbolize the arms of the scoliotic angle a) Lordotic angle and b) lordotic and scoliotic angle of 30

axis of the body projected on the frontal plane The weak points in this definition are that the long axis and the frontal plane have no exact definition that is they are difficult to define in relation to the anatomy If the long axis is defined as a vertical axis in a standing patient its position relative to the anatomy will vary according to how the patient is positioned A scoliosis angle according to this definition will also vary with the natural curvatures of the spine in the median plane

Proposal for an anatomic basis for measurement of scoliosis It seems possible to find a definition that fulfils the requirements mentioned if the scoliotic deviation is defined as a deviation from the median plane of the body This definition makes the scoliosis angle independent of the natural curves of the spine in the median plane and also independent of the technique of measurement

The Cobb angle should then be defined as the combined inclination of the two transitional vertebrae with the median plane The measurement performed on an a p film is then seen as an attempt to measure this angle In the case in which the two transitional vertebrae are parallel with the film it is an exact measurement In the same way the Ferguson angle should be defined as the sum of the two angles formed by the lines from the apical vertebrae to the two transitional vertebrae with the median plane The measurement on an a p film is an attempt to measure the angle so defined In the case in which the two lines are parallel to the film it is an exact measurement of the defined angle

Thus if the Cobb angle and the Ferguson angle are re defined according to the proposed anatomic basis they would give values that in the special case are

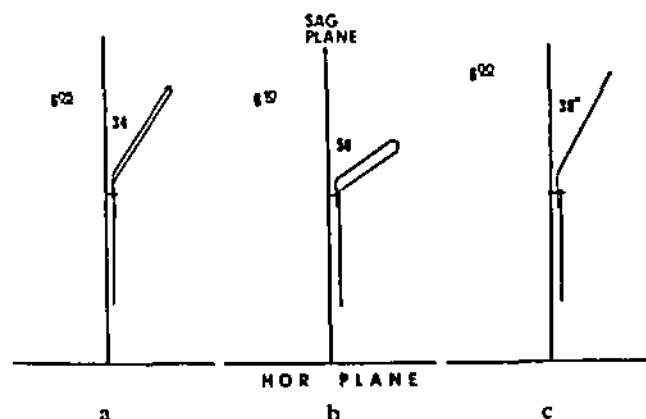


Fig 5 a) The model seen from the ventral side corresponding to an a p projection The 30 scoliotic angle is projected as 34 b) The upper hand has been rotated from 5 to 10 min past the hour The projected scoliotic angle is then increased to 50 c) The scoliotic angle of 30 is correctly reproduced only when the upper hand is at 12 o clock —that is when the plane containing the arms of the angle is parallel to the image plane

identical with the values of angles measured according to the old definition The proposed new definition of these angles can therefore be considered as an extension of the previous ones

Discussion

The proposed new definition is illustrated by the following example A clock face is illustrated in Fig 4 a with the hands pointing to 5 minutes past 6 Let the plane of the clock face a sagittal plane and the hands be the two lines joining the centres of the three vertebral bodies In this model of the spinal column the angle between the hands represents a lordotic angle However there is no scoliotic angle becaus• the hands are parallel to the sagittal plane In Fig 4 b a scoliotic angle has been introduced by bending the minute hand outwards from the sagittal plane through an angle of 30 The scoliotic angle between the lines (the hands) will thus be 30 since the lower line (one hand) is still parallel to the sagittal plane

In Fig 5 a an a p film of the model of the vertebral column appears Here the 30 scoliotic angle is projected as an angle of 34 a value that would be obtained from a measurement performed with the Ferguson method If the lordosis in the model increases so that the hands are at 10 min past 6 the Ferguson angle increases to 50 (Fig 5 b) Only when the minute hand is turned to 12 is the scoliotic angle correctly projected (Fig 5 C) the two lines are then parallel to the frontal plane on which the angle is projected The difference between the Cobb and the Ferguson angles measured on the a p film and the corresponding angles measured by the method now proposed is quite moderate as long as neither of the lines containing the scoliotic angle makes a larger angle than about 10 with the frontal plane

Hypothetical representation of the angles of all the vertebrae with the sagittal plane

The angle that a line makes with the sagittal plane of the body will be correctly represented by an a p projection irrespective of the angle that the line makes with

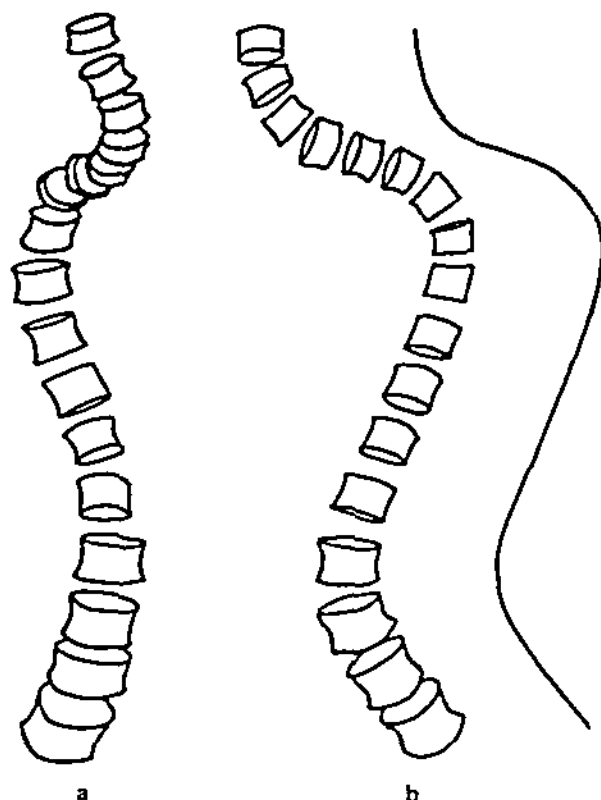


Fig. 6 a) A. p and b) lateral projections of a model of the vertebral column Dorsal to the vertebral column in the lateral projection there is a hypothetical image surface This is curved exactly as the curvature of the kyphosis-lordosis

the vertical axis provided that the image surface is parallel to the line in question and perpendicular to the sagittal plane

The axis of a vertebral body may be defined with acceptable accuracy as a line through the centre of the vertebral body parallel to the line joining the adjacent upper and lower vertebral bodies

If the centre of each vertebral body is thus marked on a curved image surface of which the axes of the vertebral bodies are tangents it will be possible to measure on the image surface the angle that each vertebral body axis makes with the sagittal plane and the angles that any lines joining the centres of the bodies make with the sagittal plane—for example Ferguson lines The curvature of the image plane must be exactly similar to that of the kyphosis lordosis

Fig 6 shows a hypothetical vertebral column in frontal and lateral projections The lateral projection also shows the curvature of such a hypothetical image surface reproducing the angle that each vertebra makes with the sagittal plane The beam is assumed to consist of parallel rays (Fig 7 a) With a divergent beam the image surface will be as demonstrated in Fig 7 b i e the whole curve is enlarged but remains similar in shape to the kyphosis-lordosis of the patient Fig 8 illustrates the manner in which the centres of the vertebral bodies would be projected on such

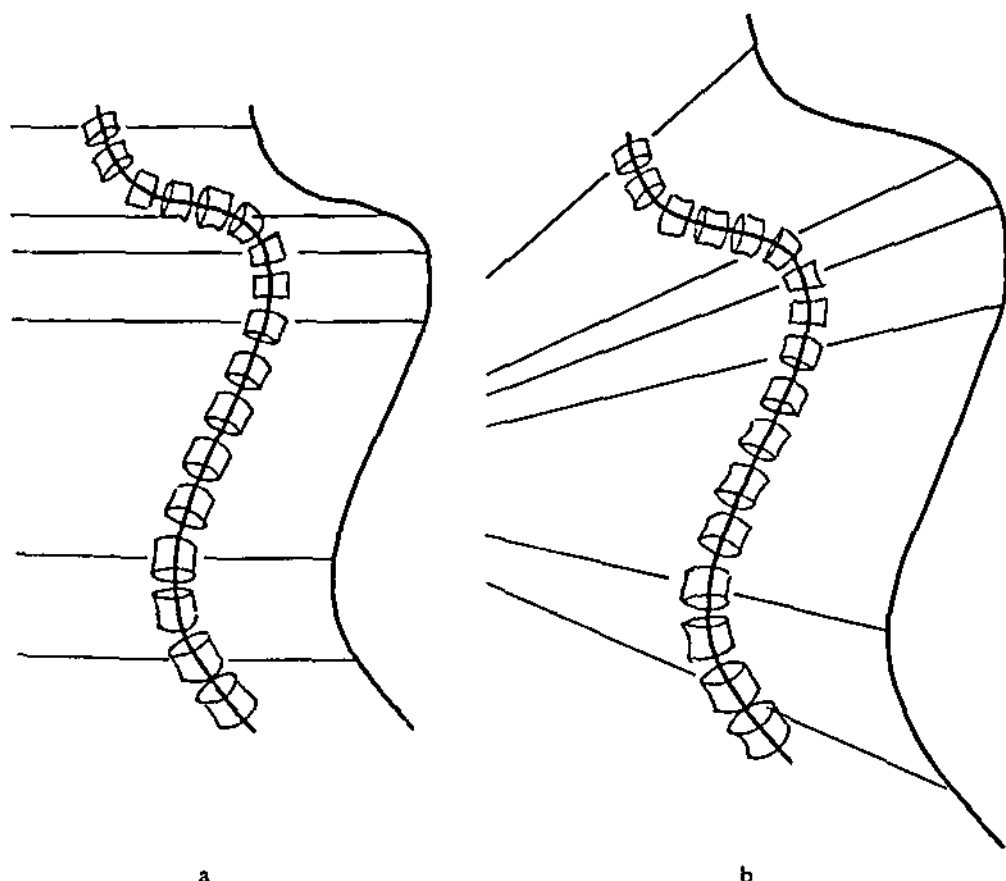


Fig 7 a) With a parallel beam the shape of the image surface and the extent of the image are the same as for the object the kyphosis lordosis b) With a divergent beam the extent of the image is enlarged but the shape of the image is the same as that of the object the kyphosis lordosis

a curved image surface and Fig 9 this image surface when the curve has been straightened out

An image is then obtained from which the angle that each axis of a vertebral body makes with the sagittal plane can be measured In Fig 10 an ordinary a p projection is demonstrated together with an a p projection on an image surface that had been curved similar to the lordosis of the spine and then straightened out to give a flat image plane In this model which has purposely been given a marked thoracic kyphosis the scoliotic angle as measured by the Ferguson method would be 53 and as measured in accordance with the new definition 33 a difference of 20 This scoliosis angle is always projected larger than it is in reality

The projection described is an example of how the scoliotic curves in the spine can be demonstrated on a plane image area independent of the kyphosis and scoliosis of the patient It may be called a rectified orthogonal projection In such a projec

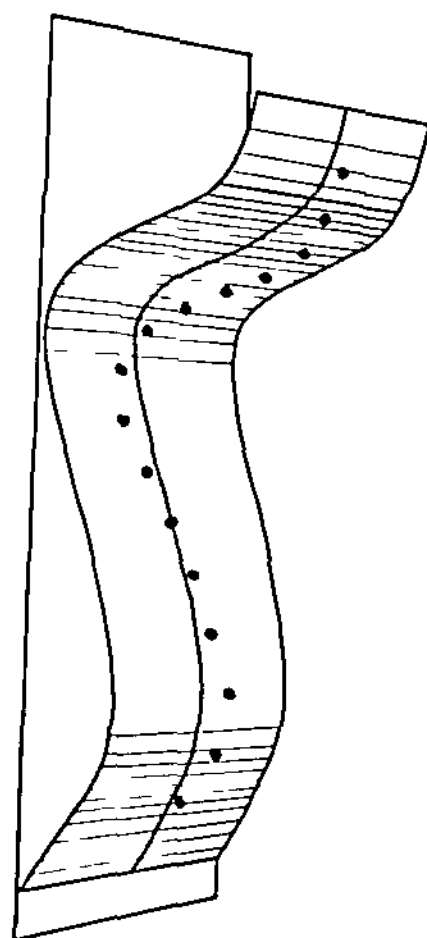
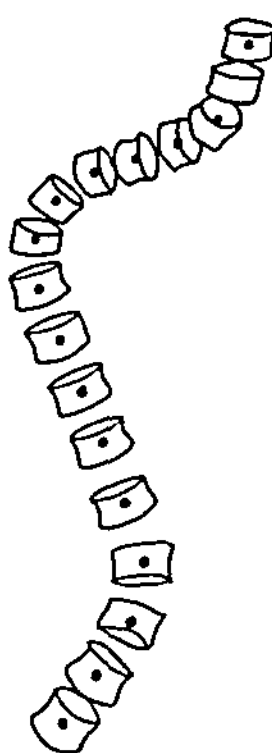



Fig 8

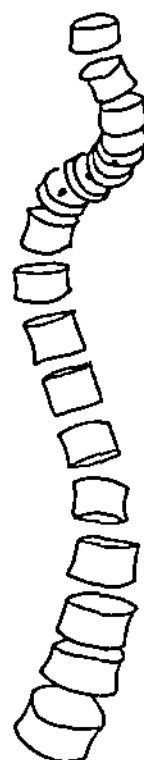


Fig 9

Fig 8 Centres of vertebral bodies projected on the hypothetical curved image surface

Fig 9 The ordinary a p projection compared with the rectified projection of the centres of the vertebral bodies

tion the Cobb and Ferguson angles according to the proposed new definition can also be measured

If the concept of kyphosis and lordosis is given a similar anatomic basis—that is as deviations in relation to the frontal plane—it is possible to construct corresponding lateral projections in a similar way The kyphosis and lordosis of the patient could be analysed independent of the scoliosis of the patient

Such projections are obtained if the positions of the centres of the vertebral bodies are measured on two projections On the basis of these measurement values a computer can be programmed to mark with its pen writer the centres of the vertebral bodies in any projection including this hypothetical projection

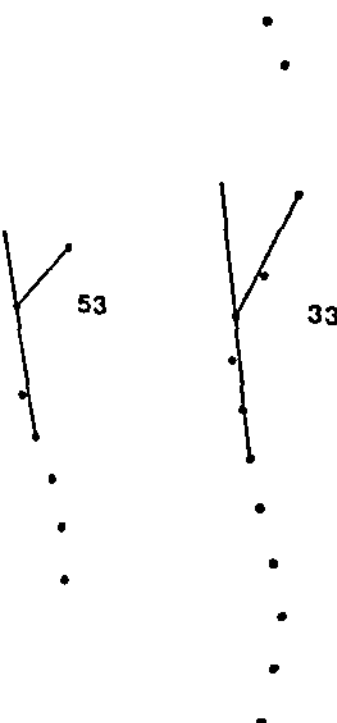


Fig 10 The same projections as in Fig 9 but with only the centres of the vertebral bodies marked thus simplifying the comparison A Ferguson angle measured on two projections can be compared The angle measured on the rectified projection has no projection errors

SUMMARY

The most commonly used methods of assessing the scoliotic deviation measure angles that are not clearly defined in relation to the anatomy of the patient In order to give an anatomic basis for such measurements it is proposed to define the scoliotic deviation as the deviation the vertebral column makes with the sagittal plane Both the Copp and the Ferguson angles may be based on this definition The present methods of measurement are then attempts to measure these angles If the plane of these angles is parallel to the film the measurement will be correct Errors in the measurements may be incurred by the projection A hypothetical projection called a rectified orthogonal projection is presented which correctly represents all scoliotic angles in accordance with these principles It can be constructed in practice with the aid of a computer and by performing measurements on two projections of the vertebral column a scoliotic curve can be represented independent of the kyphosis and lordosis

ZUSAMMENFASSUNG

Die am meisten verwendeten Methoden um eine skoliotische Abweichung festzustellen messen Winkel die nicht klar in Relation zur Anatomie des Patienten definiert sind Um eine anatomische Basis fur derartige Messungen zu geben wird vorgeschlagen die skoliotische Abweichung als die Abweichung der Wirbelsaule die diese zur sagittalen Ebene

macht zu definieren Sowohl der Copp- als auch der Ferguson Winkel können auf der Basis dieser Definition verwendet werden Die vorliegenden Methoden fur eine Messung sind dann Versuche diese Winkel festzustellen Falls die Ebene dieser Winkel parallel zu dem Film lauft sind die Messungen richtig Fehler bei den Messungen konnen durch die Projektion hervorgerufen werden Es wird eine hypothetische Projektion als berichtigte orthogonale Projektion bezeichnet vorgestellt die alle skoliotischen Winkel in Überein stimmung mit diesen Prinzipien korrekt wiedergibt Diese kan in der Praxis mit Hilfe eines Komputors oder dadurch, dass Messungen in zwei Projektionen der Wirbelsaule vorge nommen werden, konstruiert werden eine skoliotische Kurve kann unabhangig von der Kyphose und Lordo e dargestellt werden

RESUME

Les methodes le plus souvent utilisees pour determiner la deviation scoliotique mesurent des angles qui ne sont pas clairement definis par rapport a l anatomie du malade Pour donner une base anatomique à ces mesures l auteur propose de définir la deviation scoliotique comme la deviation que la colonne vertébrale fait avec le plan sagittal Les angles de Copp et de Ferguson peuvent etre bases sur cette definition Si le plan de ces angles est parallele au film la mesure sera correcte La projection peut entrainer des erreurs dans les mesures L auteur presente une projection hypothetique qui represente correcte ment tous les angles scoliotiques conformement a ces principes projection appelee projection orthogonale rectifiee Elle peut etre construite en pratique avec l aide d un ordinateur et en faisant des mesures sur deux projections de la colonne vertebrale Une courbe scoliotique peut etre representee independamment de la cyphose et de la lordose

REFERENCES

COBB J R Outline in the study of scoliosis Instructional Course Lectures Amer Acad orthop Surg 5 (1948) 261

EDHOLM P Anatomic angles determined from two radiographic projections Acta radiol (1966) Suppl No 259

FERGUSON A B Roentgen diagnosis of the extremities and spine Paul B Hoeber New York 1949

HINDMARSH J Roentgen stereophotogrammetry for evaluating the effect of scoliosis treat ment A methodological study Thesis Karolinska Institutet Stockholm 1973

LINDAHL O and MOVIN A Measurement of the deformity in scoliosis Acta orthop scand 39 (1968) 291

TIDESTRÖM F En metod for jamforbara registreringar av scolioser och kyfoser lordoser (In Swedish.) Nord Med 71 (1964) 159

FROM THE DEPARTMENTS OF RADIOLOGY (DIRECTOR PROF P VIRTAMA) TURKU UNIVERSITY HOSPITAL AND PHYSICS (DIRECTOR PROF M BRENNER) ÅBO ACADEMY SF 0570 TURKU FINLAND

IMMERSION TECHNIQUE IN SOFT TISSUE RADIOGRAPHY OF THE HANDS

P MAKELA and J O HAASLAHTI

Soft tissue radiography has been most highly developed in mammary radiography The important principles for radiologic demonstration of soft tissues are resolving power and the optimization of contrast difference between structures representing fat and water densities by *using low voltage radiation* (MELSON et coll 1973)

This technique has also been adapted for demonstration of early soft tissue and bone abnormalities in erosive joint diseases (FISCHER 1973 REICHMANN et coll 1974) Fine detail radiography provides better demonstration of early bone pathology than a conventional radiographic technique using ordinary film screen combination Optic magnification can also be used in scrutinizing fine detail films (MALL et coll 1974)

Use of a combination of fine detail radiography and immersion in water has made *possible* the demonstration of lesions in joint capsules skin and subcutaneous tissues as well as *early bone erosions* (WALKER 1964)

Changes in joint swelling oedema of subcutaneous tissues and the number of erosions in the hands of patients with active rheumatoid arthritis over a three month period were demonstrated by using a combination of the technique used in mammary radiography and an *immersion technique* (MAKELA & HAATAJA 1976)

The effect of the immersion technique upon resolution and contrast differences between various tissues in soft tissue radiography of the hands is analysed in the present report

Submitted for publication 18 March 1977

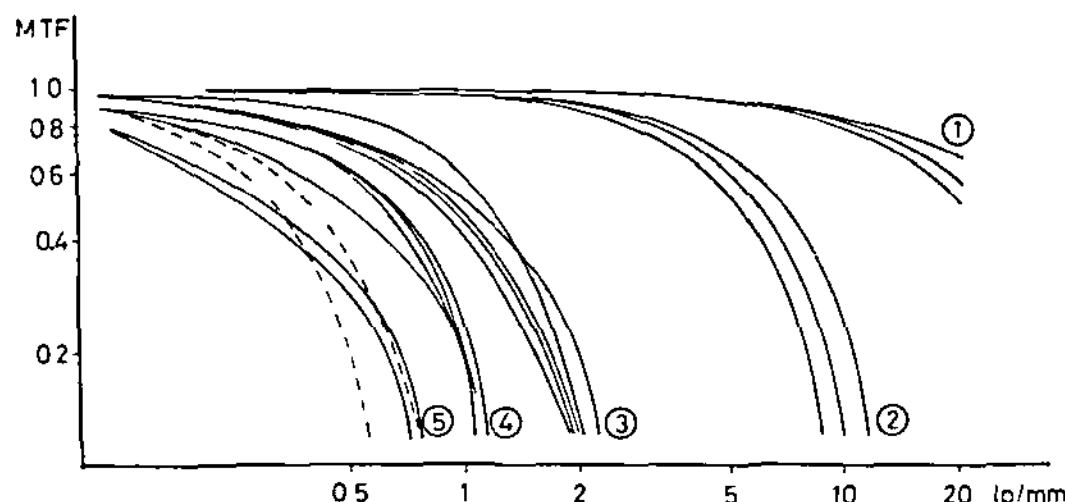


Fig 1 Modulation transfer function (MTF) in various systems Group 1 characterizes the photographic system group 2 contains the curves obtained by using an immersion technique (ethanol ethanol-water 1 1 water from right to left) The curves in groups 3 to 5 are examples of MTF from different screen film and spot film systems obtained by using the same phantom and the same microphotometer analysis

Methods

A Senographe the CGR breast radiography apparatus with a stationary molybdenum anode focus 0 6 mm and 0 03 molybdenum filtration was used applying a focus film distance of 40 cm with a standard square cone in the apparatus Exposures were made on Kodak PE 4006 (X omat MA) films which were developed for 3 5 min in a roll film processor (Pakorol) using 3M chemicals Exposure factors were constantly 30 kV 120 mAs

The effect of immersion on resolution was examined using an MTF split wedge phantom with the greatest linear density 10 lp/mm This phantom was placed 2 5 cm from the bottom of the immersion tray made of 2 mm perspex plates Films of the phantom were exposed without any fluid in the tray and with a 2 5 cm layer of different immersion fluids ethanol 96 a mixture containing 1 1 water and ethanol and pure water

A double beam recording microphotometer IFO-451 and a correction applying Fourier transformation were used for construction of MTF curves for the different immersion systems

In order to demonstrate the effect of different immersion fluids on the contrast difference between various soft tissue parts the hands of a 52 year old healthy female were depicted using the different immersion systems as in the phantom experiments The immersion tray was sufficiently long to accommodate the whole forearm with the wrist extended (thus avoiding flexion and distortion in the wrist area) The depth of the immersion fluid was kept constant using a 2 5 cm high partition allowing excess fluid to overflow into another compartment of the tray



Fig 2 Proximal phalanx of the index finger from left to right without immersion with immersion in ethanol ethanol-water 1 1 water

In the films thus obtained two perpendicular scan paths of every proximal and middle phalanx of fingers II–V were examined by the recording microphotometer The greatest available density span for the photometer was 2 5 density units and this scale was used throughout the experiments Differences in photographic density between various tissue regions were measured from the photometric curves and were statistically analysed using the t test

Results

The modulation transfer function (MTF) in systems using various immersion fluids is expressed in Fig 1 It is obvious that the resolution is much higher in non screen systems and that an increase of the immersion fluid density has only a slight effect on the resolution In the immersion systems used the resolution is close to 10 lp/mm in the mammary radiography system without immersion it is still better

Table

Differences in measured density of various regions Means (ranges standard deviations)

Regions	Immersion		
	Ethanol 96	Water ethanol 1 1	Water
Background—skin (n = 32)	0 54 (0 70 – 0 44 SD 0 07)	0 17 (0 25 – 0 12 SD 0 03)	0 05 (0 10 – 1 00 SD 0 02)
	Differences between various groups highly significant p < 0 001		
Skin—subcutis (n = 3?)	0 11 (0 19 – 0 05 SD 0 04)	0 13 (0 25 – 0 05 SD 0 05)	0 18 (0 35 – 0 04 SD 0 08)
	Difference between various groups not significant		
Background—bone (n = 16)	1 53 (1 56 – 1 51 SD 0 02)	0 98 (1 05 – 0 87 SD 0 01)	0 91 (1 10 – 0 80 SD 0 03)

The density difference between bone and background was over 2 5 DU without immersion
Densities for cutaneous and subcutaneous regions could not be measured from photometric curves

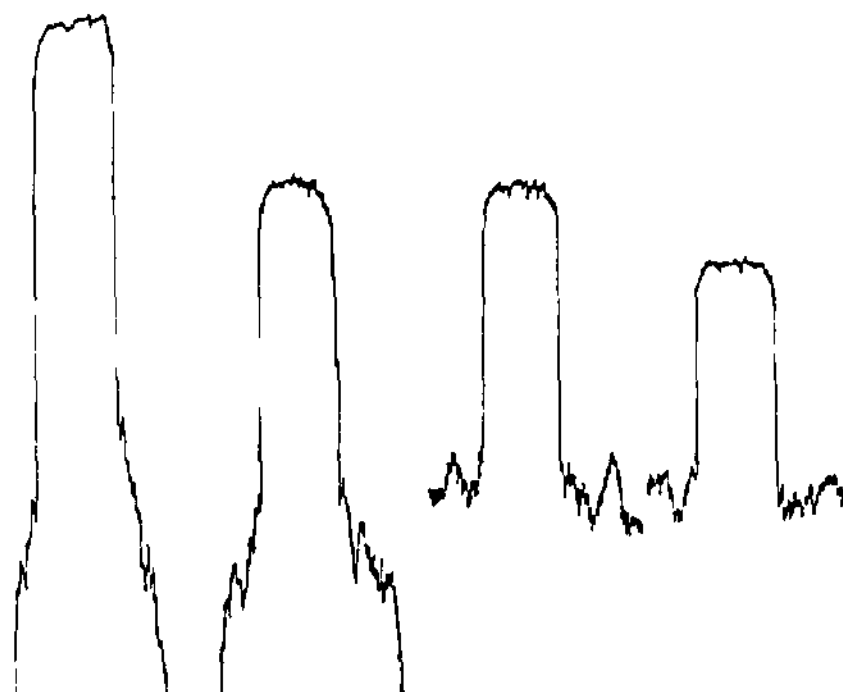


Fig 3 Microphotometric curves from the films in Fig 2

The deterioration of MTF when using immersion fluids would appear to be caused by secondary radiation from the layer between the object and the film On the other hand the interposition of a 2 5 cm fluid layer of water or ethanol between the object and the film has an evident effect on the MTF of the system

In Fig 2 the proximal phalanx of the index finger has been exposed both without immersion and with the three immersion fluids The skin and subcutaneous structures are most clearly demonstrated with the ethanol–water immersion pure ethanol immersion is the second best Without immersion it is possible to obtain better soft tissue demonstration by reducing the exposures however in previous experiments several exposures for different parts of the hands have been necessary for optimum demonstration of soft tissue structures (FISCHER REICHMANN et coll)

The surface of the skin and the subcutaneous structures were not clearly demonstrated when water immersion was used This is evidently due to a slight deterioration in resolution—it would appear that a resolution close to 10 lp/mm is the minimum requirement for a clear demonstration of soft tissue structures

In Fig 3 appears the microphotometry of the films in Fig 2 the curves represent scan paths perpendicular to the diaphysis The curve on the left is obtained without immersion The background density is over 2 5 density units The skin does not cause any identifiable deflection of the photometric curve The other curves obtained with immersion demonstrate the extent of decrease of the total density scale with the increase in immersion fluid density The skin region appears as a definite peak and the



Fig. 4 Rheumatoid arthritis a, b) Soft tissues of the hand using conventional film-screen without immersion c, d) Using mammary radiography equipment and immersion in ethanol-water Copies have been reproduced using logetronic techniques for better demonstration of soft tissue parts This procedure has resulted in marked deterioration of bone structure detail.

subcutaneous tissue as a notch in the densitometric curves The density levels of the subcutaneous and background regions approximate each other in the water–ethanol immersion the subcutaneous tissue level obtained when water immersion was used is lower than the background density level

The means and ranges ± standard deviations of the measured density differences between background skin subcutis and bone using different immersion fluids are given in the Table The density differences from skin to background when using different immersion fluids is highly significant. The whole density scale covers 2.5 density units (DU) in the films without immersion about 1.5 DU in the ethanol immersion and about 1 DU in the water and water–alcohol immersions The density difference between skin and subcutaneous tissue is not significantly affected by changing the immersion fluid although it appears to be somewhat higher in the water immersion than in the ethanol immersion In Fig 4 the hands of a patient with

rheumatoid arthritis are demonstrated in 4 a and b without immersion using a conventional screen film system and in 4 c and d using equipment for mammary radiography and water-alcohol immersion

Discussion

Technical difficulties in estimating local changes in bone mineral content make early structural abnormalities such as trabecular and cortical loss and erosion the most important bone pathology to demonstrate in the early radiologic diagnosis of rheumatoid arthritis (YOUNG 1960) Fine detail radiography has been proven to provide adequate resolution for clinical purposes and improvement in resolution does not greatly change the image quality of the bone structures It has been suggested that further improvement of skeletal imaging may be achieved by increasing the image contrast using either higher gradient films or lower tube potential (DOI et coll 1975) This may explain why the mammary radiographic technique has been proven to be of value in the demonstration of minute cortical lesions in rheumatoid arthritis and hyperparathyroidism (MEEMA et coll 1972 WEISS 1972) Excessive background density in the hand films obtained in this way makes the evaluation of soft tissue detail very difficult Increasing the background illumination does not solve the problem since the eye of the observer is then blinded by the light appearing through the bright areas of the films with the result that small contrast differences and fine detail structures cannot be distinguished in the dark background The optimum background density for the demonstration of fine detail with small contrast differences appears to be near 1 (0 2 to 1 6) units of density (KANAMORI 1966)

By using a convenient immersion technique in combination with a mammary radiography system the total density scale span in hand films may be reduced from more than 2 5 to about 1 DU without excessive deterioration in resolution A 2 5 cm immersion layer of 1 1 water-ethanol mixture for soft tissue radiography of the hands produces films that are easy to examine with easily demonstrable findings Pure water immersion has two disadvantages namely the resolution deteriorates and the surface of the skin is not sufficiently clearly defined Using pure 96 per cent ethanol produces film background which are slightly too dark The water-ethanol relationship and the thickness of the immersion layer fluid may be adjusted to accommodate the needs of the individual observer Adequate demonstration of periarticular oedema and also atrophy of the soft tissue structures is important as they appear to be of value when assessing the activity of rheumatoid processes (MÄKELÄ & HAATAJA 1976 1978) The immersion technique cannot be used in combination with oblique and lateral projections of hands and the central bony parts tend to be under exposed It is therefore evident that the conventional radiologic technique in examination of the hands cannot be replaced by this method However the immersion method may be a useful complement in the early diagnosis of erosive arthritis and in the estimation of the activity of the disease in the hands These particular aspects need

to be evaluated more closely for no imaging system can be considered apart from the use to which it will be put and the conclusion that the system having the greatest capacity to transmit detail is the better one may not be correct when the information capacity is so great that it is no longer the factor that limits decision making (KUNDEL et coll 1972)

SUMMARY

Soft tissue radiography of hands using the technique of mammary radiography and immersion in a 2 5 cm layer of 1 1 water-ethanol solution is evaluated Using immersion the average background density decreases with a factor of about 2 5 1 with little deterioration in resolution (MTF) The immersion procedure makes the demonstration and evaluation of soft tissue swelling and periarticular oedema easier

ZUSAMMENFASSUNG

Die Weichgewebe Rontgenuntersuchung der Hände unter Verwendung der Technik der Mammaradiographie und dem Eintauchen in eine 2 5 cm dicke Schicht von 1 1 Wasser–Äthanol Losung wird ausgewertet Durch Eintauchen sinkt die mittlere Hintergrundsdichte um einen Faktor von etwa 2 5 1 mit einer geringeren Verschlechterung der Auflosung (MTF) Das Eintauchen Verfahren macht den Nachweis und die Auswertung von Weichgewebe Anschwellung und periartikularem Ödem leichter

RESUME

Les auteurs étudient la radiographie des parties molles des mains par une technique de radiographie mammaire et l immersion dans une couche de 2 5 cm d un melange a parties egales d eau et d éthanol Quand on utilise l immersion la densité moyenne du fond est divisee par environ un facteur de 2 5 avec une legère detérioration de la resolution (FTM) La technique d immersion rend plus facile la mise en evidence et l evaluation de l augmentation d epaisseur des parties molles et de l oedème périarticulaire

REFERENCES

DOI K., GENANT H K and ROSSMANN K Effect of film graininess and geometric unsharpness on image quality in fine detail skeletal radiography Invest Radiol 10 (1975) 35

FISCHER E Die röntgenologische Weichteildiagnostik der rheumatischen Arthritis (Weichstrahlaufnahmen der Hand) *In* Klinisch radiologisches Seminar Band 3 p 17 Georg Thieme Verlag Stuttgart 1973

KANAMORI H Determination of optimum film density range for roentgenograms from visual effects Acta radiol Diagnosis 4 (1966) 463

KUNDEL H L. REVESZ G ZISKIN M C and SHEA F J The image and its influence on quantitative radiological data Invest Radiol 7 (1972) 187

MAKELA P and HAATAJA M Soft tissue radiography of the hands in the rheumatoid arthritis Scand J Rheum 5 (1976) 113

— — Soft tissue radiography for evaluating clinical activity of rheumatoid arthritis To be published in Acta radiol Diagnosis 1978

MALL J C GENANT H K SILCOX D C and MCCARTHY D J The efficacy of fine-detail radiography in the evaluation of patients with rheumatoid arthritis Radiology 112 (1974) 37

MEEMA H E RABINOVICH S MEEMA S LLOYD G J and OREOPOULOS D G Improved radiologic diagnosis of azotemic osteodystrophy Radiology 102 (1972) 1

MELSON G L STAPLE T W and EVENS R G Soft tissue radiographic technique Sem Roentgenol 8 (1973) 19

REICHMANN S DEICHGRABER E STRID K G HEYMAN F and STRAND T Soft tissue radiography of finger joints Acta radiol Diagnosis 15 (1974) 439

WALKER B Q Use of high-definition films and immersion technic in early diagnosis of metabolic and systemic disorder Cleveland Clin Quart 31 (1964) 227

WEISS A A technique for demonstrating fine detail bones of the hands Clin Radiol 23 (1972) 185

YOUNG A C *Early radiographic signs of rheumatoid disease Proc roy Soc Med* 53 (1960) 208

FROM THE DEPARTMENTS OF PAEDIATRICS (DIRECTOR B LINDQUIST) ORTHOPAEDIC SURGERY (DIRECTOR G BAUER) ANATOMY (DIRECTOR C H HJORTSJÖ) AND DIAGNOSTIC RADIOLOGY (DIRECTOR O OLSSON) UNIVERSITY HOSPITAL S-221 85 LUND SWEDEN

ROENTGEN STEREOPHOTOGRAMMETRY FOR DETERMINATION OF DAILY LONGITUDINAL BONE GROWTH IN THE RABBIT

A S ARONSON L I HANSSON and G SELVIK

Various roentgen methods have been used for long term investigations into the growth of the long bones Many of the problems of simple planimetric determinations can be overcome with roentgen stereophotogrammetry (HALLERT 1970) With a double image of the object the spatial relation between different points is determined with high accuracy (SELVIK 1974) Intravital implant markings with lead or other materials have been used to increase the accuracy of measurements (SARNAT 1968) Growth disturbances from these markers have sometimes invalidated their use (LACROIX 1951 RYÖPPY 1965 HANSSON 1967 HEDSTRÖM 1969) Tantalum markers about 1 mm long have for more than 20 years been used in clinical dental practice (BJORK 1968) and give no or only slight and transient growth disturbance (ARONSON & HANSSON 1976)

In the present investigation the longitudinal bone growth of the rabbit tibia, marked with tantalum indicators was measured by roentgen stereophotogrammetric records made at 1 to 7 days interval

Material and Methods

Nineteen rabbits from 4 litters aged 30 days were used The group I litter was of chinchilla race the others were of albino race Some rabbits in Groups II and III had

Submitted for publication 25 October 1976

MALL J C GENANT H K SILCOX D C and MCCARTHY D J The efficacy of fine detail radiography in the evaluation of patients with rheumatoid arthritis Radiology 112 (1974) 37

MEEMA H E RABINOVICH S MEEMA S LLOYD G J and OREOPOULOS D G Improved radiologic diagnosis of azotemic osteodystrophy Radiology 102 (1972) 1

MELSON G L STAPLE T W and EVENS R G Soft tissue radiographic technique Sem Roentgenol 8 (1973) 19

REICHMANN S DEICHGRABER E STRID K G HEYMAN F and STRAND T Soft tissue radiography of finger joints Acta radiol Diagnosis 15 (1974) 439

WALKER B Q Use of high definition films and immersion technic in early diagnosis of metabolic and systemic disorder Cleveland Clin Quart 31 (1964) 227

WEISS A A technique for demonstrating fine detail bones of the hands Clin Radiol 23 (1972) 185

YOUNG A C Early radiographic signs of rheumatoid disease Proc roy Soc Med 53 (1960) 208

FROM THE DEPARTMENTS OF PAEDIATRICS (DIRECTOR B LINDQUIST) ORTHOPAEDIC SURGERY (DIRECTOR G BAUER) ANATOMY (DIRECTOR C H HJORTSJÖ) AND DIAGNOSTIC RADIOLOGY (DIRECTOR O OLSSON) UNIVERSITY HOSPITAL S 221 85 LUND SWEDEN

ROENTGEN STEREOPHOTOGRAMMETRY FOR DETERMINATION OF DAILY LONGITUDINAL BONE GROWTH IN THE RABBIT

A S ARONSON L I HANSSON and G SELVIK

Various roentgen methods have been used for long term investigations into the growth of the long bones Many of the problems of simple planimetric determinations can be overcome with roentgen stereophotogrammetry (HALLERT 1970) With a double image of the object the spatial relation between different points is determined with high accuracy (SELVIK 1974) Intravital implant markings with lead or other materials have been used to increase the accuracy of measurements (SARNAT 1968) Growth disturbances from these markers have sometimes invalidated their use (LACROIX 1951 RYÖPPY 1965 HANSSON 1967 HEDSTRÖM 1969) Tantalum markers about 1 mm long have for more than 20 years been used in clinical dental practice (BJORK 1968) and give no or only slight and transient growth disturbance (ARONSON & HANSSON 1976)

In the present investigation the longitudinal bone growth of the rabbit tibia marked with tantalum indicators was measured by roentgen stereophotogrammetric records made at 1 to 7 days interval

Material and Methods

Nineteen rabbits from 4 litters aged 30 days were used The group I litter was of chinchilla race the others were of albino race Some rabbits in Groups II and III had

Submitted for publication 25 October 1976

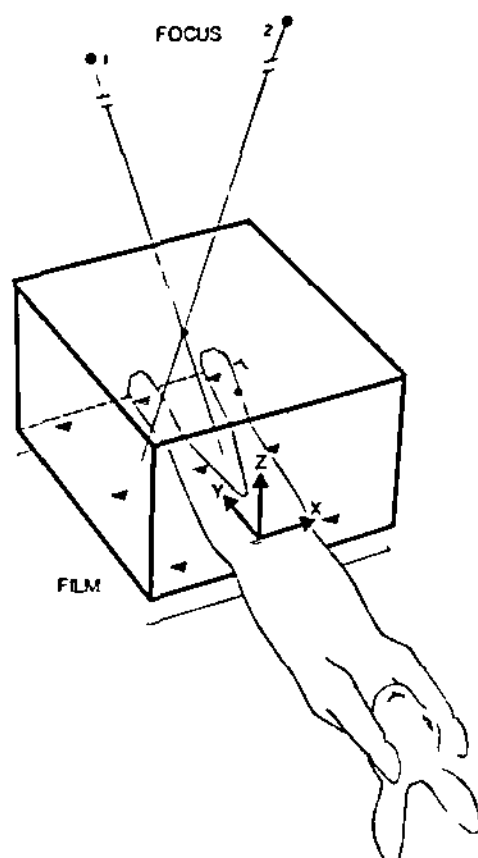


Fig. 1 Stereophotogrammetric recording of a rabbit for bone length measurements The rabbit lying with its legs in the test cage of glass is simultaneously exposed from 2 roentgen tubes (Focus 1 and 2) Reference markers of known location in the cage lid (●) and in the cage bottom (▼) and also bone markers in the right leg (—) are recorded on the film under the cage The spatial location of these bone markers is further analysed and expressed as three-dimensional Cartesian co-ordinates origin in the bottom reference point as shown

diarrhoea during the investigation Intraosseous markers of tantalum were applied and the increasing distances between these markers w re determined by roentgen stereophotogrammetry

Grouping of animals Groups I and II consisted of one litter each and Group III of rabbits from two litters The grouping was based on differences in the marking technique according to the following scheme

Group I (7 animals) Large pins (0 50 mm × 1 5 mm) proximal and distal epiphyses right tibia

Group II (4 animals) Small pins (0 37 mm × 1 2 mm) proximal and distal epiphyses bilaterally

Group III (8 animals litter a 2 and litter b 6) Tantalum balls (diameter 0 50 mm) proximal and distal epiphyses bilaterally

Marking technique A special instrument for percutaneous implantation was used (ARONSON et coll 1974) Markers were inserted under neuroleptanalgesia Fluanizon and Phentanyl 6 and 0 12 mg/kg body weight respectively (Hypnorm)

Table 1

Statistical analysis of growth recordings

	Group I		II		III	
Marker mm	0 50	1 2	0 37	1 2	0 50	
Number of animals	7	7	4	4	8	8
Mean length of intervals days	1 0	6 7	1 0	5 0	1 0	5 5
Unilateral bilateral marking	uni	uni	bi	bi	bi	bi
Number of observation intervals	1	3	4	3	3	3
Number of double determinations	7	21	32	24	48	48
SE for growth over whole interval μm						
Error in film measurement	15	13			13	13
Total error			43	40	30	31
SE for growth rate μm day	15	2	43	8	30	6

SE is based on the following formula

$$SE = \sqrt{\frac{\sum_{i=1}^{n} (R_{i_1} - R_{i_2})^2}{2 \times n}}$$

where R_1 and R_2 are the growth as computed by separate determinations and n is the number of double determinations

For Group I R_1 and R_2 were obtained by a second appraisal of the same films only (error of film measurement) but for Group II R_1 and R_2 were obtained from two complete recordings (total error) For Group III both techniques were applied

Recordings The stereophotogrammetric recording of the legs was made as a double exposure (see further the normal case HALLERT and model 1 A SELVIK) Simultaneous exposure of the rabbit with two roentgen tubes focus size about 1 0 mm × 1 0 mm was used distance between the foci about 40 cm and focus film distance 100 cm The animal lay supine unanaesthetized lightly fixed in a test cage of Plexiglas or mirror glass (Fig 1) This cage contained reference markers of tantalum with known spatial location The exposed film thus contained a double set of these reference markers and also the markers in the leg From measurements on the films using an A8 Autograph (Wild Heerbrugg Switzerland) the three dimensional coordinates for leg markers and also their mutual distances were calculated by a computer (SELVIK) The measuring instrument was of high precision and calibrated to give an error less than 10 μm for a calibration scale of 200 mm

Time schedule All litters were exposed on the day of marker insertion and during the next three weeks according to the following schedule

Group I Day 0 7 14 20 21

Group II Day 0 1 2 7 8 9 14 15 20 21

Group III Day 0 1 2 5 7 8 9 14 15 21 22 (day 9 only for litter a)

Table 2

Difference in growth left–right tibia mean and SEM

	Group			
	II		III	
Number of animals	4	4	8	8
Number of observation intervals	4	3	3	3
Length of intervals days	1 0	5 0	1 0	5 5
Difference in growth for interval				
Left–right tibial bone mean μm	15	−7	4	−5
SEM μm	11	12	6	6

SEM is based on total error SE for growth obtained from Table 1 for the respective columns This is adjusted by dividing SE with the square root of the product of the number of animals and by the number of observation intervals and by multiplying with $\sqrt{2}$ because it is based on a difference in two growth values (left and right) and finally by dividing with $\sqrt{2}$ as the mean of two separate growth determinations is utilized (R_1 and R_2 Table 1)

For example for Group II first column the SEM –

$$\frac{SE\ \sqrt{2}}{\sqrt{4\ \ 4}\ \sqrt{2}} = \frac{43\ \sqrt{2}}{\sqrt{4\ \ 4}\ \sqrt{2}} = 11\ \mu m$$

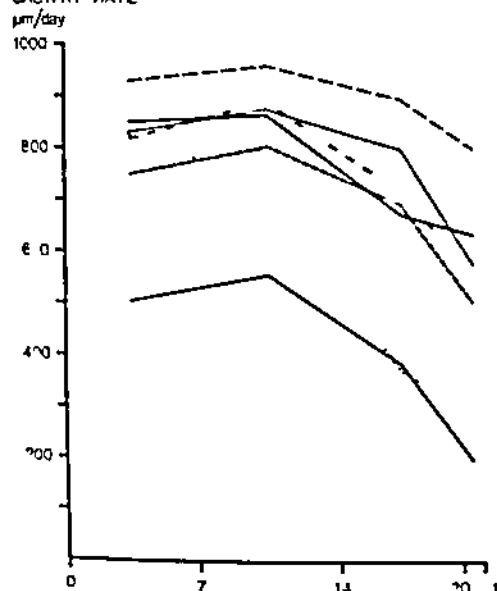
Analyses of methodologic errors (1) Error of film measurement For determination of the methodologic errors films were re assessed in Groups I and III Thus the growth (length differences) was obtained from double evaluations of the same film The precision of the measuring technique was expressed as the standard error SE using the formula in Table 1

(2) Total error For Groups II and III two separate recordings were made on each occasion beginning on day 2 After the first exposure the rabbits were removed from the test cage The entire recording procedure was repeated for the second exposure 10 min later The SE was computed from these recordings made on day 2 and thereafter using the formula in Table 1

(3) Left and right leg comparison In Groups II and III the difference in growth between the right and left leg was estimated as the difference between the arithmetic means for the legs (Table 2) The SEM was based on the corresponding methodologic error the SE being found at repeated measurements for the group as described

Results

Analysis of measuring errors (1) Error of film measurement The standard error at repeated measurements on the same sets of film (Group I large pins) was 15 and 13 μm for the two time intervals of 1 and 6 7 days corresponding to 15 and 2 μm/



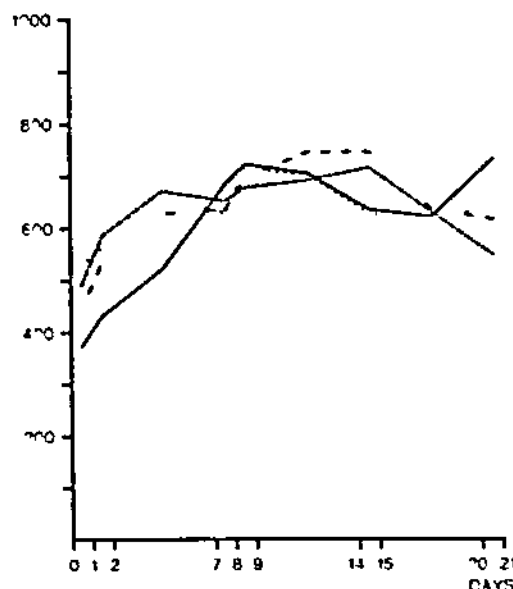


Fig 2

Fig 3

Fig 2 Group I Daily growth rate of right tibia of 7 rabbits growth curves after insertion of large tantalum pins (0 50 mm 1 2 mm) in the proximal and distal epiphysis

Fig 3 Group II Daily growth rate of tibia of 4 rabbits with small tantalum pins (0 37 mm 1 2 mm) in the proximal and distal epiphysis of the right and left tibiae Growth values expressed as mean rate for the two sides

day (Table 1) Similar results were obtained at revaluing films for Group III balls SE being 13 µm per time interval

(2) Total error A much larger error was found when repeated measurements were based on entirely different recordings (Table 1) For the tested intervals it was 43 µm for 1 0 day and 40 µm for 5 5 days for small pins a lower SE (30 and 31 µm) being obtained for balls

(3) Left and right leg comparison The mean growth differences between the left and right legs varied from −7 to +15 µm over the test periods (Table 2) This dif ference is not statistically significant (compare with the reported SEM)

Individual growth of rabbits The rabbits had an individual variation in growth (Figs 2 to 5) Group I (Fig 2) had a tendency for growth rates to increase during the registration period This was even more evident in Group II (Fig 3) In Group III the two rabbits of litter a (Fig 4) showed a very uniform growth variation whereas the growth rate of litter b (Fig 5) varied considerably

Discussion

The present investigation used a combination of inert markers and roentgen stereophotogrammetry for longitudinal bone growth determinations in the rabbit

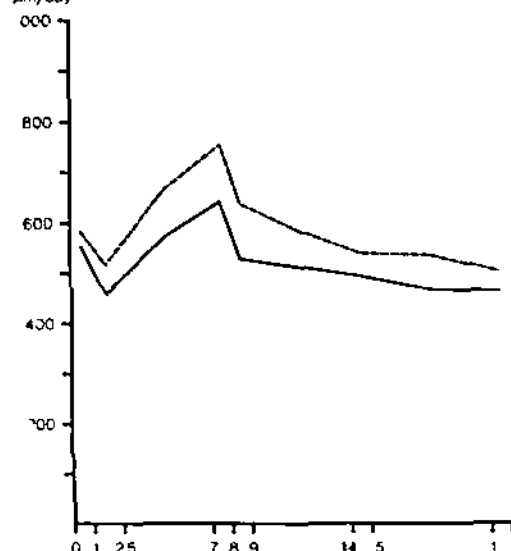


Fig 4

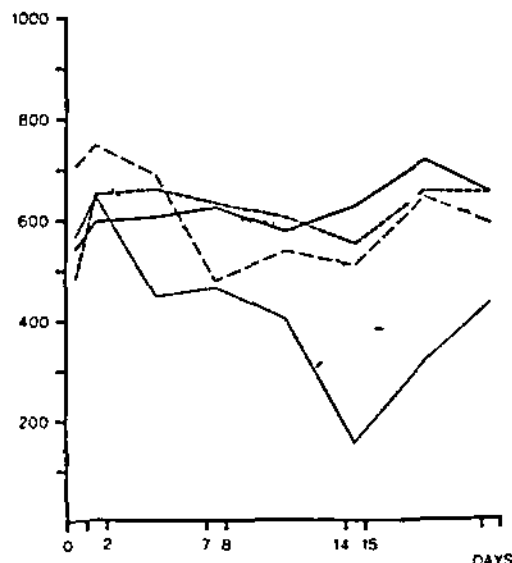


Fig 5

Fig 4 Group III litter a Daily growth rate of tibia in 2 rabbits marked in both right and left tibia with tantalum balls (0 50 mm diameter) Growth rate expressed as mean rate for right and left leg

Fig 5 Group III litter b Daily growth rate of tibia in 6 rabbits marked in both right and left tibia with tantalum balls Growth rate expressed as mean rate for right and left leg

The inertness of the markers to tissue have been evaluated separately (ARONSON & JONSSON 1977) The tetracycline method (ARONSON & HANSSON) revealed minute local growth disturbances in the marking technique when growth of the marked right leg was compared with that of the left unmarked leg

The methodologic error of the technique was analysed The measuring accuracy of the method using large pins and balls amounts to 13 to 15 μm per measured interval of growth This result is consonant with the calibration measurements with the same technique on a test rod with tantalum pin markers of known internal length differences (ARONSON & SELVIK 1977 b SELVIK) Measurements on this rod gave a length error $< 10\ \mu m$ corresponding to a growth error of $\sqrt{2} \times 10 < 15\ \mu m$ per interval The error was essentially the same both for film re appraisal and for repeated measurements on two films

A considerably larger methodologic error was obtained when complete re appraisals were made (total error) For small pins it was about 40 μm and for balls about 30 μm The larger error for the pins may be partly explained by the pins in the rabbit not always being ideally placed for projection for film measurements Thus it was not always possible as in the test rod to place the pins absolutely parallel to each other in the leg The pin directions sometimes deviated and when projected the

points of the pins were seen foreshortened thus increasing the uncertainty in the measuring process

Although this problem of unfavourable pin projection was overcome by using ball markers the error of about 30 μm was still considerably larger than for the test rod (~15 μm) The increased error has thus to be sought in factors unrelated to the recording and measuring technique e g biologic factors One such factor could be that the markers are slightly movable in the bone Such minute movements are fully possible despite the lack of tissue reactions around the tantalum markers which felt firmly anchored to the bone (ARONSON & JONSSON 1977) It is also possible that the legs are not completely rigid Thus when the bones are fixed an unequal stretching of the bone between different recording procedures will cause minute length differences between the markers due to elasticity in the growth zone and bone tissue

The equality of growth rates for the two tibial bones is biologic evidence of accuracy for the growth method It is also further evidence in support of the previous findings that the insertion of tantalum markers is inert and only transiently and slightly disturbs the growth (ARONSON & HANSSON) If the process of marker application was more traumatic it could cause greater growth disturbances whose effect would not necessarily be equal in both extremities and would therefore be disclosed by unequal growth of the extremities

Compared with conventional planimetric roentgen methods the stereophotogrammetric method has some definite advantages It has a much greater degree of accuracy of 30 to 43 μm compared with the methodologic error for planimetric methods of 0 1 to 1 mm for rabbits and 1 to 10 mm for man (HANSSON) The recordings are much simpler to make as the stereophotogrammetric method is not affected by a parallax phenomenon between object and film Thus quality does not depend on how well the standardized focus rabbit film positions are obtained which is so critically important in conventional planimetric measurements

The method is highly suitable for longitudinal growth determinations of the rabbits It should be noted that the method can disclose differences in the individual growth in long term measurements

It is interesting to note how the general condition of the rabbits is reflected in their growth rates Groups I and III (litter a) were in excellent condition Group II had just recovered from a period of diarrhoea Group III (litter b) had diarrhoea during the investigation This may explain the notable increase in growth for Group II and the great variation of growth in Group III (litter b) Spontaneous and similar variations of unknown cause are shown by the two animals in litter a of Group III Group I illustrates a variation of growth of rabbits in a litter as expected from previous investigations (HANSSON)

Clinical implication Apart from contributing to animal radiology this roentgen stereophotogrammetric method is currently under clinical trial in children with growth diseases In hypopituitarism with growth retardation the method proved

highly valuable in monitoring growth stimulating hormonal therapy (ARONSON & SELVIK 1977 a) and in severe renal insufficiency with growth failure it could show dietary treatment effects on skeletal growth (ARONSON et coll 1975)

Acknowledgement

This investigation was assisted by the staffs of the laboratories of Experimental Radiology and Experimental Orthopaedics and the Department of Anatomy Economic support was obtained from Landstinget M län Funds from the University of Lund and from Stiftelsen Svensk Naringsforskning

SUMMARY

The spatial location of points in an object can be determined by roentgen stereophotogrammetry A technique of high accurary was applied in a determination of the daily skeletal growth of young rabbits The tibia was labelled with tantalum markers on each side of the growth zones and the increasing distance between these markers due to longitudinal bone growth was measured Three different types of markers were tested and the methodologic error was estimated It varied between 30 and 43 μm for one growth interval depending on the type of marker used The method has clinical implications currently under investigation

ZUSAMMENFASSUNG

Die raumliche Lokalisation von Punkten in einem Objekt kann durch Rontgen Stereo photogrammetrie festgestellt werden Eine Technik von hoher Genauigkeit zur Bestimmung des taglichen Skelettzuwachses von jungen Kaninchen wurde verwendet Die Tibia wurde mit Tantalum Markierung auf beiden Seiten der Zuwachszone gezeichnet und der steigende Abstand zwischen diesen Markierungen infolge des longitudinalen Knochenzuwachses ge messen Es wurden drei verschiedene Typen von Markierung untersucht und der methodo logische Fehler festgestellt Dieser schwankte zwischen 30 und 43 μm fur ein Zuwachsintervall in Abhangigkeit vom verwendeten Typus der Markierung Die Methode hat klinische Be deutung die zur Zeit untersucht wird

RESUME

La localisation spatiale dans un objet peut être déterminée par stéreophotogrammétrie radiologique Une technique de haute precision a été appliquée a la determination de la croissance squelettique quotidienne de jeunes lapins Le tibia a ète marqué avec des mar queurs en tantale de chaque coté des zones de croissance et la distance croissante entre ces marqueurs due à la croissance longitudinale de l os a été mesurée Trois types differents de marqueurs ont ete essayés et l erreur méthodologique a ete évaluée Elle a varié entre 30 et 43 μm pour un intervalle de croissance dependant du type de marqueur utilisé Cette méthode a des implications cliniques qui sont actuellement etudiées

REFERENCES

ARONSON A S and HANSSON L I Tantalum pins as skeletal markers Effect on longi tudinal bone growth as measured with the tetracycline method To be published in Acta orthop scand 1976

— and JONSSON N Tantalum markers for X ray studies histological investigation To be *published* 1977
— and SELVIK G (a) X ray stereophotogrammetric determination of endochondral growth Clinical application in hypopituitarism To be published in Pediat Res 1977
— — (b) An X ray stereophotogrammetric method for measuring length To be published 1977
ARONSON A S HOLST L and SELVIK G An instrument for insertion of radiopaque markers Radiology 113 (1974) 733
— FURST P KUYLENSTIERNA B and NYBERG G Essential amino acids in the treatment of advanced uremia Twenty two months experience in a 4-year-old girl Pediatrics 56 (1975) 538
BJORK A The use of metallic implants in the study of facial growth in children method and application Amer J phys Anthropol 29 (1968) 243
HALLERT B X ray photogrammetry Elsevier Amsterdam 1970
HANSSON L I Daily growth in length of diaphysis measured by oxytetracycline in rabbit normally and after medullary plugging Acta orthop scand (1967) Suppl No 101
HEDSTRÖM Ö Growth stimulation of long bones after fracture or similar trauma a clinical and experimental study Acta orthop scand (1969) Suppl No 122
LACROIX P The organization of bones Churchill London 1951
RYOPPY S Transplantation of epiphyseal cartilage and cranial suture Experimental studies on the preservation of the growth capacity in growing bone grafts Acta orthop scand (1965) Suppl No 82
SARNAT B G Growth of bones as revealed by implant markers in animals Amer J phys Med 29 (1968) 255
SELVIK G A roentgen stereophotogrammetric method for the study of the kinematics of the skeletal system AV-centralen Lund 1974

FROM THE DEPARTMENT OF DIAGNOSTIC RADIOLOGY III (DIRECTOR DOCENT C-G HELANDER) SAHLGRENSKA SJUKHUSET S 411 32 GOTHENBURG SWEDEN

TESTING OF ROENTGEN FILM QUALITY

S Reichmann K Åstrand and Gisela Kunz

Roentgen films are marketed by means of a set of vague descriptive terms referring to film quality Well known from advertisements are terms like brilliant images excellent clarity superb rendering of detail etc When the interested reader tries to get behind these terms in order to find out the objective basis for their application a brochure is received from the manufacturer containing further examples of this confusing terminology and a characteristic curve for a given type of development This curve represents objective information Unfortunately it is not easy to transfer the shape of this curve into the visual impression of good or bad quality obtained in practical clinical use This may be illustrated by an example When a film is developed without prior exposure to light or roentgen rays a certain blackening will always be present viz the basal fog It is well known that even surprisingly low levels of this fog will considerably impair image quality This impairment is subjectively experienced as decreased contrast Imagine that a choice between two different films has to be made One has a basal fog level of 0 19 and a maximum gamma value (contrast index) of 2 5 and the other 0 25 and 3 0 respectively No generally accepted method exists for the choice since the interaction between the different parameters of the characteristic curve is largely unknown The parameters just mentioned are not the only ones Exposure latitude maximum photographic density gamma value in different parts of the curve also have to be considered Finally it may be added that most parameters may be altered within a fairly wide range by means of differing development

Submitted for publication 19 January 1977

It may be safely concluded that an objective way of comparing different films without scrutinizing images made on the films in qu stion does not exist Whether inspection should really be considered objective is a matter open to discussion In any case even the purchase of large quantities of film is usually based on this type of quality evaluation Usually the testing of a new film consists of a comparison with the one used in daily routine Often then the new film is used instead of the old one for a certain time and a general impression is obtained at the end of the test period This procedure really makes the user wide open to any kind of suggestive influence from the sales representatives of the new film The lack of reference images obtained with the old film makes this test more than doubtful Safer and more reproducible results may be expected if identical exposures are made with both films However even this technique is not free from sources of error One important condition must be met in order to make this test procedure discriminative as regards film quality The film must be at least part of the set up of physical factors limiting image quality if not a good film will give as bad images as a bad one Since this condition is fundamental and yet not generally realised some practical examples of this type of error may be justified

The basal fog which strongly influences image quality is mainly caused by radiation on the film during the time between manufacture and development (LUNDH 1968) This radiation derives from cosmic radiation radioactive substances in building materials etc If two films are tested in a type of examination where the screening of secondary radiation from the patient is insufficient this non specific radiation may add to and predominate over the background exposure during film storage to such a degree that a difference in basal fogging is concealed Thus if a film purchase is based on image pairs produced in abdominal angiography with wide image areas and an insufficient grid (which is often used in order to increase system speed) a real difference between two films may be masked and the bad film may be chosen Another factor to be considered is the intensifying screens If they are bad the image may be distorted to a level where a good film cannot yield better results than a bad one Even the reverse may be encountered in a case where the good film displays all the defects of the screens much more clearly and disturbingly than does a bad film In such a case the bad film is easily chosen instead of changing screens and using the good film—an exchange which will give much better image quality and a lower patient dose

Unless precautions of the above mentioned kind are taken even a carefully performed double image comparison may fail to demonstrate a difference which is demonstrable by other tests In the report by BERGQUIST et coll (1973) concerning the quality of the blue Medichrome film in comparison with a black and white film it was stated that the general superiority of the blue film found by others (DE BELDER & BOLLEN 1971 REICHMANN & HELANDER 1974 SELIN & REICHMANN 1977) could not be confirmed The results of such a clinical test certainly implies advice as regards film choice for the department where it was performed Unless measures are taken

to demonstrate that film quality actually limited image quality in the test no general conclusions can be drawn about the films The most simple case where it may be demonstrated that film quality limits image quality occurs when one film yields better images than the other If this is not the case general conclusions about the relative quality of the films should be avoided

Clinical film tests should thus be performed in a routine of such high technical quality as to give a good film a proper chance to provide evidence for its superiority Since this is a condition which may be difficult to establish it might appear that visual tests should be avoided altogether However DE BELDER & BOLLEN devised a visual test based on films depicting phantoms exposed under laboratory conditions so that the quality factors beside those of the film could be controlled They found that film quality may be expressed in terms of the lowest contrast perceptible against different background densities This implies that with high film quality a greater number of low contrast structures should be visible in the image than with films of low quality regardless of the parameters of the characteristic curves for the films in question Despite the ingenuity of this test it has not been universally used It appears more than desirable that this type of information should be included in the brochures from all manufacturers Despite the existence of an excellent test method films are still purchased in large quantities without anyone knowing why the film in question was preferred Similarly films are often discarded and replaced for the same unprecise reasons

A perceptibility test is an elaborate procedure involving statistical evaluation of test results from many subjects and many different films The purpose of the present communication is to provide a simple test that is valid in relation to the visible impressions of film quality After some practice the method is rapid and convenient

The test method

Theoretical background The film should be tested in a situation where image quality is significantly limited by film quality This circumstance makes it necessary to use high definition screens Also there should be little unsharpness due to focus dimensions and object movement and absence of significant amounts of secondary radiation The sensitivity of the screen film combination should be low so that the influence of quantum mottle is avoided For the same reason soft radiation is preferable to hard radiation All these conditions prevent image quality from being mainly limited by unsharpness scattered radiation and quantum mottle giving the film a chance to demonstrate its capacity In this connection it is important to note that many screens marketed as high definition screens do not actually provide sufficient image quality due to defective coating of the crystal substance The screens used here for the testing of blue sensitive films have been chosen on the basis of previous experience (DEICHGRÄBER et coll 1975)

The test object should provide an image which is difficult for the film to record

This means that image details should be small and the contrast low These conditions imitate those encountered in everyday practice If a renal calculus is large it may be visible even in a low quality image but the smaller the stone the smaller the depicting film area and the lower the contrast the greater the difficulty in observing it Small object size and low contrast often go together in clinical radiography It has also been found that this simultaneous lowering of size and contrast will demand higher film quality than has generally been realised (SELIN & REICHMANN) Standard testing of image quality is often performed by means of lead grids having increasing numbers of lead lines per mm Funck grids The object size is smaller and smaller when the number of lines per mm is increased but the contrast remains at a clinically unrealistic level regardless of the object extent in the film plane Such high contrasts are always reproduced by the film and this type of test object gives no information of the film quality and should therefore be avoided

Another important factor was pointed out by ROSE (1973) who stated that the shape *of the object should be that of a point or a small spot in the image He demon*strated that a line can be perceived even if image quality is remarkably low while a small spot is influenced by low quality much earlier even if the size of the spot is the same as the transverse dimension of the line

Procedure Some centimetres above a conventional examination table a slit formed by two lead plates is arranged The width of the slit is about 4 cm the length being parallel to the plane of the anode disc Thus no heel effects may be expected in the area of the slit The central ray of the tube passes perpendicularly through the centre of the slit The tube collimator is adjusted to fit to the borders of the slit Underneath the slit a cassette containing double screens Kodak X omatic Fine is located Inside the cassette are placed two or three strips of the films to be compared The length of these film strips is at right angles to that of the slit Thus through the slit a part of the strips is given identical exposures The cassette is then moved so that new parts of the films are brought into the view field and exposed The front area of the cassette is covered by a suitable number of sandpaper sheets of coarse texture An increased number of sandpaper sheets each one placed on top of the other will give rise to a coarser pattern of grains of higher contrast A tube potential of 50 kV is used and the number of sandpaper sheets is adjusted so that the resultant image bears a resemblance to a somewhat high level of quantum mottle In the present experiments 4 sandpaper sheets of coarse texture were used The sandpaper sheets should before use be inspected through a magnifying glass in order to exclude those with uneven coating

It is necessary to have constant settings of tube potential and mA value during the whole series of different exposures to make possible a comparison between the films at different densities Thus in principle the exposure time should be changed the other parameters being kept constant However in most generators the mA setting is changed when the time is altered The original mA value may be rein

troduced at the control table but it remains uncertain whether the value in question is regained in the generator It may be assumed that the generator is working at an acceptably constant rate only if no settings are changed not even the exposure time This is obtained if the lowest exposure desired is repeated in steps the first film area being exposed once the second twice the third three times etc At higher exposure levels the difference between single steps may be increased to two or three of the partial exposures At the highest exposure levels this procedure may lead to a long total exposure time unless the partial exposures are made in rapid sequence Long exposure times may give rise to a spurious difference between films of the same quality if the films have markedly different Schwartzschild factors one film may lose comparatively more of its true sensitivity if very long exposure times are used To avoid this source of error the exposure may be made in the following way When the first partial exposure of a series has been made the control lever is not shifted to its original position but to an intermediate one which means that the anode is kept rotating From this position a new exposure is made without interposed deceleration and acceleration of the anode Thus a sufficiently rapid sequence of partial exposures of an acceptably constant nature may be obtained with a standard generator In generators with a falling load the tube potential may change during the exposure Therefore this type of generator should be avoided

This somewhat elaborate way of obtaining a step exposure may at first appear unnecessary but it cannot be replaced by a sandpaper exposure through an aluminium step wedge the reason being that the different steps of the wedge impose different attenuation The sandpaper located under the thickest step will be depicted by significantly harder radiation than the same paper under the thinnest one This is of no importance if the films have exactly the same characteristic curve then only such areas in the two films as have obtained the same exposure are compared However when the films differ in sensitivity it is preferable to compare areas of identical density in both films regardless of radiation dose If a step wedge is then used and the sandpaper is depicted with rays varying in hardness areas of identical density should give different depiction even if the two films of different sensitivity have exactly the same recording capacity The films should be developed in commonly used developing machines preferably with chemicals seasoned for the films in question In fact the test is valid not only for the films but for the type of development as well

Evaluation of the film strips is visual A film depicting the sandpaper grains with the greatest precision is the best one regardless of contrast basal fog etc The inspection may be carried out under different conditions each entailing its own level of precision The lowest one is obtained if the films are inspected by means of an ordinary light box with the unaided eye If stray light is removed and a strong light source is used for higher densities the conditions of inspection are improved Further improvement occurs if a magnifying glass is used Still higher precision is obtained if the inspection is carried out under strictly standardised conditions In the experiments

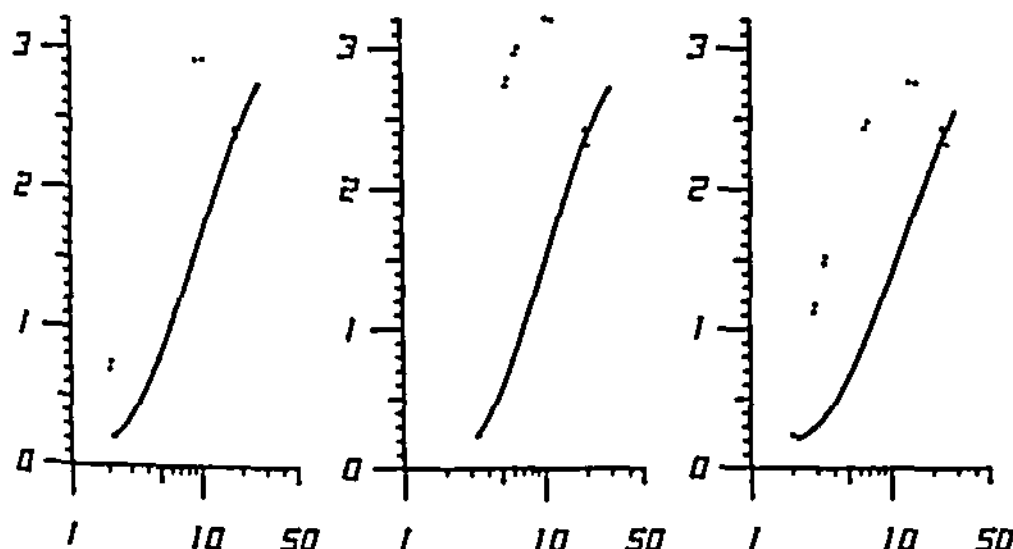


Fig. 1 Characteristic curves (continuous) and corresponding gamma values (dotted) of the three films with straight characteristic curves The x axis denotes log relative exposure and the y axis displays both density and gamma value by the same numerical scale Film B (middle) has a higher gamma value than the other two especially in the lower part of the working density range

to be presented the following after treatment of the images was applied The images were copied on to a fine grain photctechnical film (Agfa Gevaert N/33) The exposure time was guided by the density values of the original films so that all copies displayed about the same density (0 7–0 8) The film in question gives a straight characteristic curve in densities ranging from at least 0 3 to beyond 2 0 Copies having a constant density and a slightly increased contrast (gamma value = 1 4) made inspection easier A further step could be added if the copies were magnified in a standardised way For this purpose a low power photo microscope with a phototimer was used giving a magnification of ten times and high precision in the density control of the final film Hard working film was used (Agfa Gevaert Agfaortho 25) so that a further standardised increase in contrast was obtained The density differences between the original films were completely equalised and furthermore the image was magnified and the contrast improved The final films were easy to inspect and compare and the risk that the thresholds of vision might influence the evaluation of the image quality appeared to be eliminated

Clinical experiences

Three different films were compared with the film used in this department at present the latter film is in the following report called the reference film It is of a conventional type having a straight characteristic curve It was compared with two similar films of other brands and with one so called latitude film The test did not




Fig 2 High density failure of film A Magnified (×15) sandpaper images display the recording at (a) low density (D = 0 71 above fog gamma value = 2 3) and (b) high density (D = 2 42 gamma value = 2 4) In (a) a coarse granularity is seen in the form of dark and bright spots against a background of a fine grained structure The spots correspond to the sandpaper grains and the fine grained structure is caused by the graininess of the original film which has not been completely eliminated In (b) the spots are more difficult to discern in spite of identical gamma value The film graininess is more evident

only comprise the standardised procedure described but series of double images were also taken in the daily clinical routine Different types of examinations were included mostly consisting of lung and spinal examinations Lung images were obtained at 115 kV and the spinal images at 65 to 80 kV The screens were Kodak X omatic Regular The aim of the clinical part of the film comparison was to find out whether the film differences detected in the sandpaper test also existed in clinical routine The clinical films were directly inspected in the same way as is used in the daily routine by means of a standardised viewing box (Rolloscope Siemens Elema Solna Sweden) and against a strong light source with a restricted area

Densitometry of the films obtained from the sandpaper procedure made it possible to draw their characteristic curves They were constructed as third degree regression curves in a Hewlett Packard calculator 9100 B with a plotter in order to eliminate small errors of measurement The gamma value for different densities could be computed from the regression curve equation In the evaluation of the information obtainable from the characteristic curve only gamma values from such regions of the curve were used where good agreement existed between the actual measurement points and the regression curve Deviations were mainly found in the extreme end points of the curve while good coincidence was noted in those parts referring to the working range of the films The information obtained from the characteristic curve mainly in the form of the gamma value was compared with the visible information from the magnified copies of the sandpaper films




Fig. 3 The three films in Fig 1 compared at optimum density (1 08–1 09 above fog) Magnified (15) sandpaper recordings (cf Fig 2) from a) film A (gamma value 2.8) b) film B (gamma value 3 1) and c) film C (gamma value 2 6) Film C gives impaired quality in relation to A and B the latter films being practically identical despite different gamma values

When the three films having straight characteristic curves (Fig 1) were compared the following results were obtained The reference film had the lowest contrast with a maximum gamma value of 2 7 In the other two films the corresponding maximum gamma value was 2 9 (film A) and 3 2 (film B) In a previous report (SELIN & REICHMANN) it was found that the image quality of films is gradually impaired when the background density increases even if the gamma value is kept constant This phenomenon was called high density failure This type of failure was searched for in the films In the reference film and film A suitable exposures made it possible to compare an image of low density with a high density image having the same gamma value The high density failure of film A appears in Fig 2 similar results being obtained in the reference film Thus if different films are to be compared only areas of the same density should be inspected even if different densities do not impose any change of gamma value

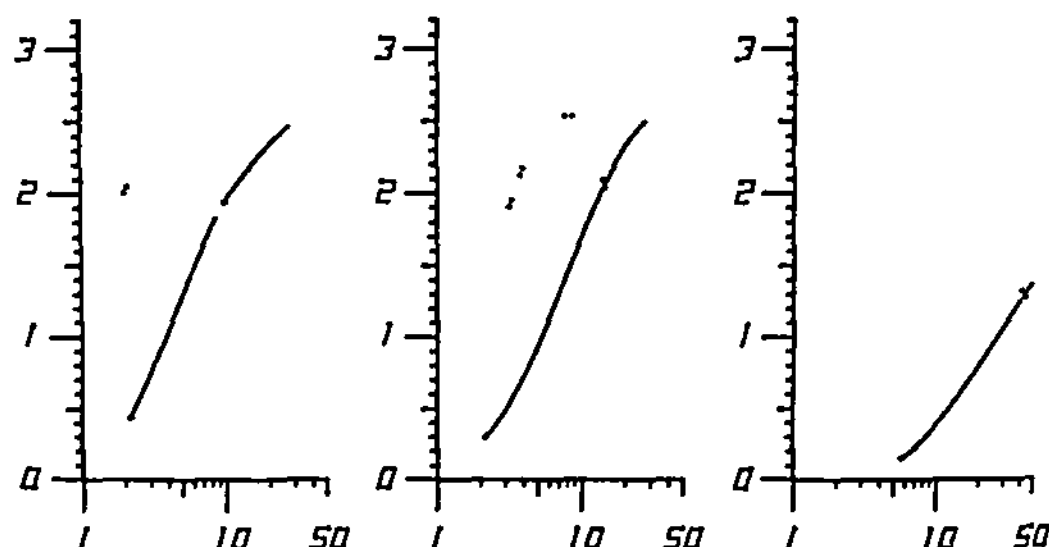


Fig 4 Characteristic curves and gamma values (cf Fig 1) of a latitude film (left) in relation to the reference film (middle) and Medichrome film developed in black and white (right) The characteristic curve of the latitude film displays a fairly sharp break at D 1 8 above fog this curve and the gamma curve have been made discontinuous at this point The Medichrome film has gamma values comparable to those of high densities in the latitude film

The three films were compared visually at the optimum density level (1 0–1 1) It is evident that the film having the highest gamma value (film B) gave a good recording of the sandpaper grains (Fig 3) However film A gave the same recording despite its lower gamma value The reference film on the other hand gave a clearly lower image quality The step in gamma value between films A and B was about the same as the step between film A and the reference film Still the first step caused no reduction of image quality while the second step gave rise to a clear impairment

In order to test the actual exposure latitude of the different films the sandpaper images were compared at a high exposure which was a constant multiple of that yielding the optimum density mentioned Thus the low contrast reference film gave a somewhat lower density than the other films Densities ranged between 2 06 and 2 21 The gamma value of the three images was about the same (2 7–2 8) The differences between the films had then disappeared and so the actual exposure latitude was considered to be the same in the three films When the clinical films were inspected films A and B generally appeared to have greater brilliance or clarity than the reference film The difference could be correlated to a greater number of visible fine details when the impression of higher brilliance was gained Film B generally appeared to be harder in contrast than the reference film The contrast difference between film A and the reference film was not generally detectable the difference in principle manifesting itself only in the form of a greater number of fine details

The latitude film (Fig 4) displayed a fairly sharp break in its characteristic curve

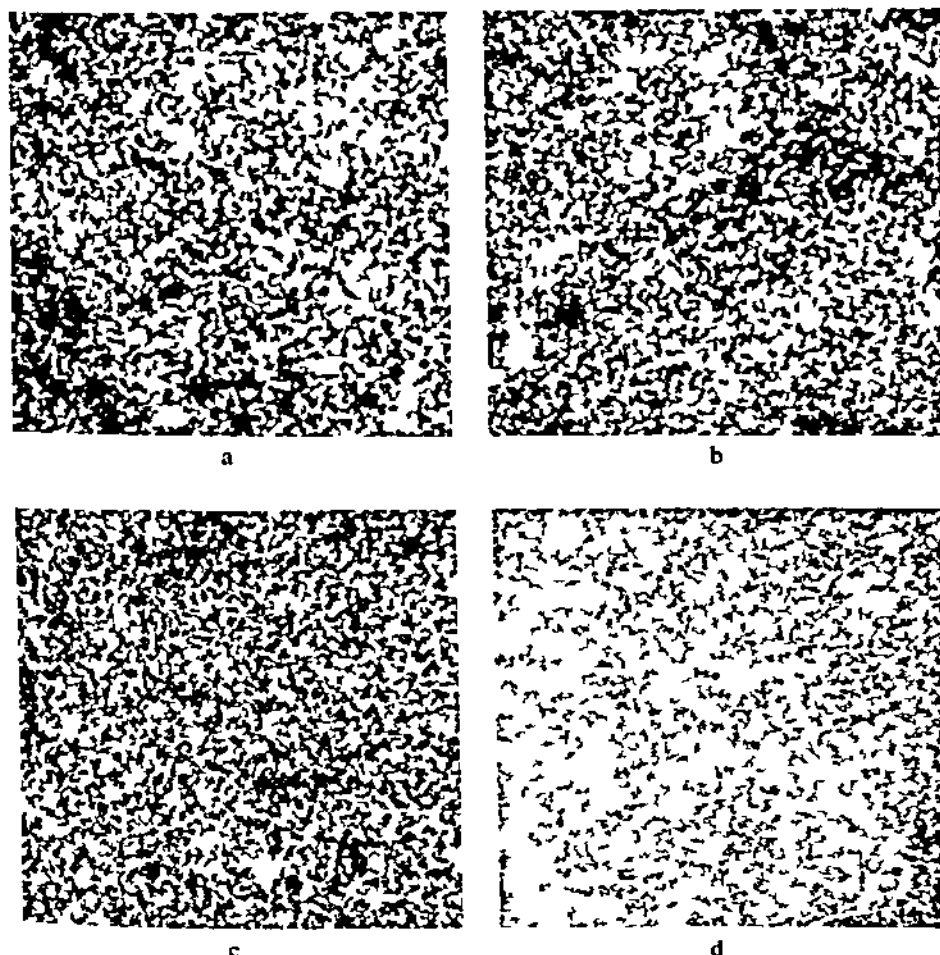


Fig 5 Recording capacity (magnified sandpaper image) of the latitude films compared with (d) black and white developed Medichrome Densities above fog are 1 16 1 72 2 12 and 0 44 the respective gamma values being 2 5 2.3 1 3 and 1 3 In passing the breaking point of the characteristic curve of the latitude film (cf Fig 4) the sandpaper image disappears completely (b c) Despite the same low gamma value the Medichrome film displays a clear sandpaper image (d) The failure of the latitude film at high density is apparently a matter of non recording rather than low contrast in itself

at a density value of about 1 8 This breaking point was found to affect image quality adversely In the region below that point (Fig 5) the sandpaper grains were well recorded When the breaking point was approached the recording was gradually impaired although the gamma value did not drop significantly At densities above the breaking point the gamma value lay between 1 4 and 1 1 and the sandpaper image disappeared completely In order to demonstrate that this effect was due to a non recording of the image rather than to a low gamma value in itself a similar recording was made on a Medichrome film (a blue monochrome colour film) which was given black and white development The resulting image was very soft (Fig 4)




Fig. 6 Magnified (3) copies of an intercostal space of a chest examination recorded in (a) the latitude film and (b) the reference film. The difference in contrast reflects the actual difference between the originals both of which were slightly overexposed in proportion to *their respective sensitivities The density of the latitude film is well above the breaking point* of the characteristic curve (cf Fig. 4) Since the reference film yields considerably more information it has in reality a larger exposure latitude than the latitude film.

At the gamma value of 1 3 the sandpaper grains were clearly detectable in the Medichrome image (Fig 5 d) Thus the failure of the latitude film to demonstrate the sandpaper was due to the fact that the image had not been recorded since the gamma value in itself was sufficient in a film of higher quality At low densities the reference film gave a slightly better recording than the latitude film However at high densities the difference became more marked to the advantage of the reference film so that the so-called latitude film in fact had an evidently smaller exposure latitude due to the fact that the densities near and above the breaking point were more or less useless

The clinical comparison including the latitude film mainly comprised pulmonary examinations Especially in areas of high density a clear difference was seen in favour of the reference film When the films were inspected at the ordinary light box the differences were small but with a strong light source the shortcomings of the latitude film were obvious (Fig 6)

Discussion

The sandpaper test method as described displays the recording properties of films in another way than is provided by the shape of the characteristic curve In fact only a weak correlation between these two tests was found in the present experiments The visual test method was more closely correlated to the clinical usefulness of the films than were the parameters derived from the characteristic curves If it is agreed that the characteristic curve does not give sufficient information the reason for the shortcomings of the sensitometric method of evaluating film quality must be investigated

In two previous reports (SELIN et coll 1975 SELIN & REICHMANN) evidence was given that the number of silver halide grains in a film emulsion may affect image quality quite apart from other quality factors of the film Thus films with many grains yield better image quality than films with fewer grains even if the gamma value is the same in the working range of densities It is difficult to incorporate this quality factor into the characteristic curve Previous experience indicates that this factor will be demonstrated together with other quality factors if the films are tested by recording very small spots of low contrast as in the sandpaper test procedure

The characteristic curve thus appears to give incomplete information about the film quality The sandpaper test method with the after treatment made possible a discrimination between films which was actually simple and convincing

One of the most interesting results was the finding that a latitude film may have a smaller rather than a larger exposure latitude than a standard film The extended latitude of the film tested was found to be merely a matter of the shape of the characteristic curve having no diagnostic relevance The question arose whether the result applied only to the film tested therefore another film with a similar characteristic curve but of another brand was also tested Only one sandpaper test was carried out against the reference film The same general pattern emerged with this type of latitude film as well Thus at least two latitude films on the market both manufactured by large companies have in fact a smaller exposure latitude for relevant diagnostic details than a standard film The low quality of these latitude films at high densities is not only due to a low gamma value in itself since the same gamma value in another emulsion gave a clear recording It appears more probable that the drop in image quality is due to the factors associated with the number of silver halide grains available for image recording

The sandpaper test method implies an evaluation of film quality which is apparently not used by film manufacturers The test method could be refined so that the original films are not evaluated by means of inspection but by microdensitometry It seems possible to devise standard test procedures in this way providing a system of evaluation indicating film quality This means that no film comparisons have to be performed in radiologic departments in the future Instead the data should be delivered by the manufacturers together with the characteristic curves of the films If this is done it should be expected that descriptive nonsense terms like brilliant images could be completely dispensed with

SUMMARY

Evaluation of film quality is often based upon the film s characteristic curve A practical test method implying radiography of sandpaper sheets has been devised yielding crucial information about the quality which cannot be derived from the characteristic curve Since this test appears to give more valid information about film quality than conventional sensitometry it is suggested that the test procedure should be standardised and used by the manufacturers

ZUSAMMENFASSUNG

Die Auswertung der Filmqualitat stutzt sich oft auf die charakteristische Kurve des Films Eine praktische Testmethode wurde entwickelt die auf Rontgenbildern von Sandpapier Blattern beruht welche wesentliche Information uber die Qualitat gibt die nicht aus der Kurvencharakteristik hervorgeht Da dieser Test eine bessere Information uber die Film qualitat als die konventionelle Empfindlichkeits Feststellung ergibt wird vorgeschlagen dass dieses Testverfahren standardisiert und von Herstellern verwendet werden sollte

RESUMÉ

L appreciation de la qualite d un film est souvent basée sur la courbe caractéristique du film Les auteurs ont mis au point une methode de test pratique comportant la radiographie de feuilles de papier d emeri fournissant des informations très importantes sur la qualité qui ne peuvent pas etre déduites de la courbe caractéristique Etant donne que ce te t parait donner des informations plus valables sur la qualité du film que la sensitometrie ordinaire les auteurs proposent que cette méthode de test soit standardisee et utilisée par les fabricants

REFERENCES

De Belder M and Bollen R Medichrome a new X ray film yielding more detail X ray bulletin 18 (1971) 3

Bergquist E Bergström K Bronge A Dahlin H Hemmingsson A Jorulf H Lindgren P G Nylén O Persson R Sahlstedt B Welander U and Wilbrand H A clinical comparison between monochrome colour film and black and white RP film as a universal x ray film Fortschr Rontgenstr 118 (1973) 705

Deichgraber E Reichmann S and Strid K G Intensifying screens in soft tissue radio graphy Acta radiol Diagnosis 16 (1975) 54

Lundh A Radiation damage to roentgen films Acta radiol Diagnosis 7 (1968) 272

Reichmann S and Helander C G High voltage radiography Theory and clinical applica tion Acta radiol Diagnosis 15 (1974) 561

Rose A Vision Plenum Press New York 1973

Selin K and Reichmann S High-density failure of radiographic films Acta radiol Diagno sis 18 (1977) 95

— Deichgraber E and Reichmann S Influence of secondary radiation on image quality Acta radiol Diagnosis 16 (1975) 520

FROM THE DIVISION OF ORTHOPAEDIC SURGERY AND TRAUMATOLOGY (DIRECTOR P SLATIS) UNIVERSITY CENTRAL HOSPITAL HELSINKI FINLAND

RADIOGRAPHIC ABNORMALITIES IN TUBULAR BONE AFTER RIGID PLATE FIXATION IN RABBITS

P PAAVOLAINEN E KARAHARJU and P SLATIS

Fracture repair after rigid plate fixation is characterized by end to end consolidation of the fracture with minimal concomitant formation of a radiologically visible callus around the fracture (MULLER et coll 1970 RAHN & PERREN 1971 RUEDI & ALLGÖWER 1974) Morphologically this so called primary fracture healing is accomplished by a widening of the Haversian canals the formation of resorption cavities in the cortical bone and activation of the osteogenic cells in the cortex New bone is laid down in the fracture gap as transverse osteons which through Haversian remodelling subsequently are transformed into dense lamellar bone (SCHENK & WILLENEGGER 1964 OLERUD & DANCKWARDT LILLIESTRÖM 1968 WILLENEGGER et coll 1971 GÖRDES et coll 1975) Compression applied to the plate increases the stability of the osteosynthesis but does not promote fracture repair (ANDERSON 1965)

Slight but definite reactions in the cortical bone may be observed in the fracture area at radiography In undisturbed healing the fracture gap fills up with new bone within 2 to 3 months and eventually becomes invisible Either persistent delineation of the fracture or increased widening of the fracture at radiography indicates delayed repair and may herald metal fatigue of the plate If stabilization of the fracture is inadequate periosteal callus forms around the fracture the conditions for primary bone healing alone are lost and the fracture heals through a combined primary and secondary healing process (WIESER & ALLGÖWER 1962 WIESER 1964 SCHMIT NEUERBURG & GREIF 1974 RUEDI & ALLGÖWER)

Recent reports have described adverse effects of rigid implants on the tubular bone even when fracture repair after plate fixation has been uneventful In experimental

Submitted for publication 27 April 1977

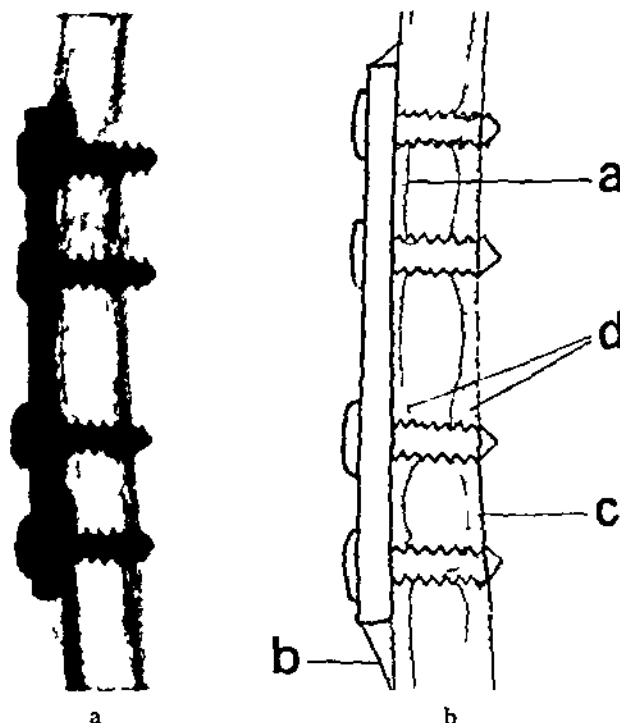


Fig 1 a) Intact tibio fibular bone 12 weeks after rigid plate fixation b) Sites at which the radiographic changes were semi quantitatively recorded a = cortical bone under the plate b new bone formation around the plate c cortical bone opposite the plate and d new bone formation around the screws

osteotomies progressive porotic transformation has been observed to accompany fracture repair of tubular bone (UHTHOFF & DUBUC 1971) and morphometric estimates of the mineral content of fixed tubular bone indicate substantial loss of mineral (GÖRDES et coll) Clinical reports on refractures after removal of the metallic implants suggest that the bone adjacent to the fracture has weakened (RICHON et coll 1967 DIETSCHI & ZENKER 1973) This assumption was corroborated by STRÖMBERG & DALÉN (1976) who showed that in canine femora subjected to rigid plate fixation torque capacity had decreased

Previous descriptions of the radiographic alterations in tubular bone after rigid plate fixation have dealt mainly with the features of fracture repair and with concomitant changes in the bone adjacent to the fracture The aim of the present report is to analyse the successive radiologic abnormalities observed in intact bone after rigid plate fixation with and without compression The results demonstrate that the radiologic appearance of the fixed bone reflects uniform and well defined time related changes

Material and Methods

Operation technique Forty adult rabbits were premedicated with pethidine and atropine and both lower extremities of each animal were prepared for operation in Nembutal anesthesia (pentobarbital Abbott) Through a straight incision the tibiofibular bone was exposed between the muscle compartments With the tibio fibular junction serving as a landmark a four hole DCP/ASIF plate of stainless steel was firmly

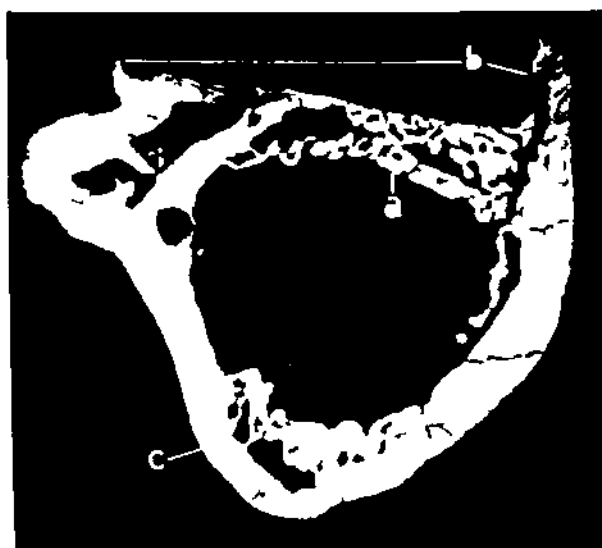


Fig 2. Cross section of the mid shaft of the tibio-fibular bone 24 weeks after rigid plate fixation a = diminished cortical thickness under the plate b new bone formation around the plate and c = porotic transformation of the cortical bone opposite the plate

attached onto the anterolateral aspect of the tibia with a specially devised plate holder On the right tibia the screws were driven home so as to achieve maximum axial compression whereas the left tibia was fixed without axial compression by using neutral fixation (PERREN et coll 1969) The plate was one half as long as the entire cortical length of the tibia

Postoperatively the animals were housed separately were allowed to move freely in their cages and wore no external splints or bandages The animals were killed 1 day and 1 3 6 12 24 and 36 weeks postoperatively The tibio fibular bones were removed the soft tissue was stripped off leaving the periosteum intact and the specimens were scrutinized macroscopically Eleven specimens were excluded because of infection or fracture of the fixed bone

Radiography of the bone was performed on Agfa Gevaert Structurix D 7 film and repeat exposures were taken after removal of the plate A Machlett 80-ZYM tube was used and operated at 70 kV 10 mA for 3 5 s FFD was 1 m

Transverse specimens from the mid shaft of the tibio fibular bone were embedded in methylmetacrylate and ground with carborundum paper to sections of 50 to 80 micrometres in thickness Films were exposed with a Machlett AEG 50 tube at 10 kV 10 mA for 1 s FFD 20 cm

Evaluation of the radiographic bone abnormalities which were graded as follows (Figs 1 2)

a) *Changes in cortical bone under the plate*

+ Slight decrease of cortical thickness

++ Decrease of cortical thickness to less than half of that in normal bone Patchy porotic appearance of the bone

+++ Marked thinning of cortical bone Profound porosis

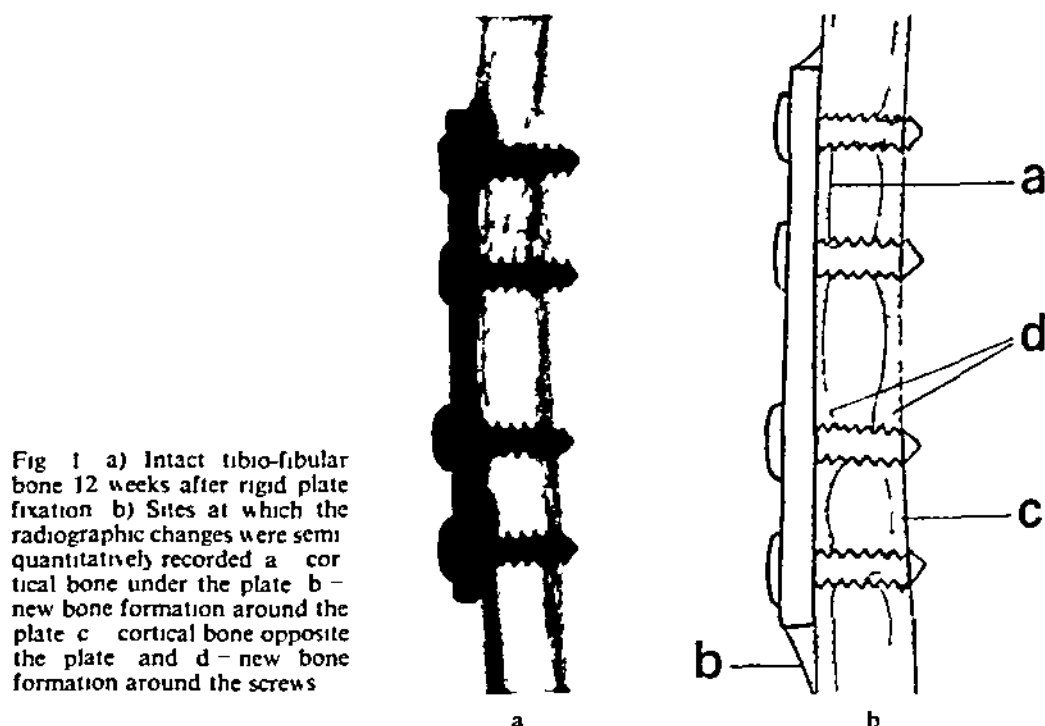


Fig 1 a) Intact tibio-fibular bone 12 weeks after rigid plate fixation b) Sites at which the radiographic changes were semi quantitatively recorded a cortical bone under the plate b – new bone formation around the plate c cortical bone opposite the plate and d – new bone formation around the screws

osteotomies progressive porotic transformation has been observed to accompany fracture repair of tubular bone (UHTHOFF & DUBUC 1971) and morphometric estimates of the mineral content of fixed tubular bone indicate substantial loss of mineral (GORDES et coll) Clinical reports on refractures after removal of the metallic implants suggest that the bone adjacent to the fracture has weakened (RICHON et coll 1967 DIETSCHI & ZENKER 1973) This assumption was corroborated by STRÖMBERG & DALEN (1976) who showed that in canine femora subjected to rigid plate fixation torque capacity had decreased

Previous descriptions of the radiographic alterations in tubular bone after rigid plate fixation have dealt mainly with the features of fracture repair and with concomitant changes in the bone adjacent to the fracture The aim of the present report is to analyse the successive radiologic abnormalities observed in intact bone after rigid plate fixation with and without compression The results demonstrate that the radiologic appearance of the fixed bone reflects uniform and well defined time related changes

Material and Methods

Operation technique Forty adult rabbits were premedicated with pethidine and atropine and both lower extremities of each animal were prepared for operation in Nembutal anesthesia (pentobarbital Abbott) Through a straight incision the tibio-fibular bone was exposed between the muscle compartments With the tibio fibular junction serving as a landmark a four hole DCP/ASIF plate of stainless steel was firmly

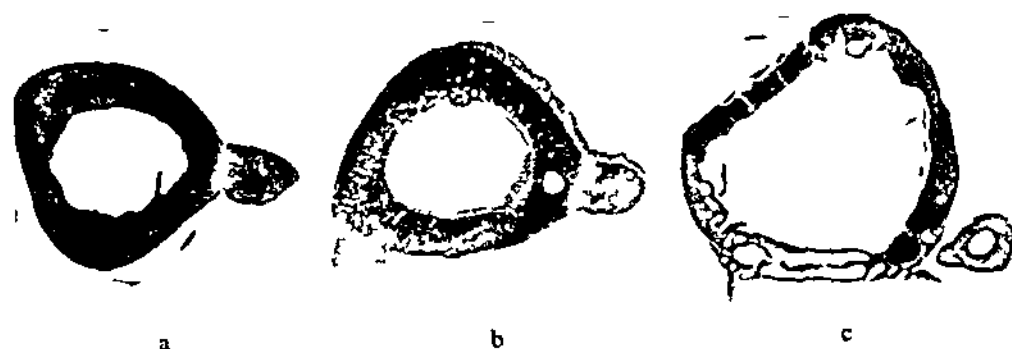


Fig 4 Cross-sections of the mid shaft of the tibio-fibular bone after rigid plate fixation a) After 3 days Normal appearance of the bone b) After 3 weeks Enlargement of the Haversian canals and newly formed subendosteal and subperiosteal bone c) After 36 weeks Porosis under the plate and marked thinning of cortex

Subendosteal resorption of the cortical bone was partly compensated by subperiosteal new bone formation that added to the over all diameter of the tubular bone (Fig 4) In the medullary cavity new bone had formed around the screws

The radiographic abnormalities in bones fixed with and without axial compression were similar The results are summarized in the Table

Changes of the cortical bone under the plate Six to twelve weeks after the operation the cortical bone under the plate had thinned in 2/6 tibias and 5/10 tibias respectively At 12 weeks marked thinning and porotic transformation had occurred in a further 5/10 tibias At 24 and 36 weeks postoperatively the cortical thickness had decreased markedly in all specimens this gave rise in some specimens to cortical defects under the plate In the films of the cross sections this thinning of the cortical bone was clearly delineated

New bone formation around the plate Six weeks after the operation slight new bone had formed around the implant in 4/6 tibias At 12 and 24 weeks postoperatively new bone formation had covered the entire surface of the implant in 7/10 and 8/12 tibias respectively Towards the end of the experiment the newly formed bone around the plate had been partly resorbed

Changes in the cortical bone opposite the plate Twelve weeks postoperatively slight to moderate porosis was found in the cortical bone in 5/10 tibias In another 5 specimens the cortical bone appeared double contoured when viewed in cross sections At 24 weeks marked porosis with subperiosteal new bone formation was present in all specimens At this stage subendosteal and intracortical resorption was accompanied by a slight increase in the outer diameter of the bone and in the diameter of the medullary cavity

New bone formation around the screws As early as 3 weeks after the operation new bone had formed in the medullary cavity in all specimens Bone formed subperiosteally

Table

Site and severity of radiographic abnormalities in bone structure after rigid plate fixation

Time after operation (wk)	No of specimens	Cortical bone under plate	Formation of new bone around plate	Cortical bone opposite to plate	Formation of new bone around screws
1	18	—	—	—	—
3	17	—	—	—	17 +
6	6	2 +	4 +	—	4 +
12	10	—	—	2 +	—
		5 +	3 +	3 + +	10 + +
		5 + +	7 + + +	5 + + +	
24	12	—	4 + +	—	12 + +
		12 + +	8 +	12 + + +	
36	6	—	4 +	5 +	—
			2 + +	1 + +	
		6			6 + +

at the opposite cortex in 2/6 tibias 6 weeks and in 10/10 tibias 12 weeks postoperatively At 24 and 36 weeks this subperiosteal bone had become transformed into a dense collar of juxtacortical bone in all specimens

Discussion

The results show that rigid plate fixation of an intact tubular bone calls forth changes in the radiographic appearance of the bone The cortical bone under the plate was always thinned while at the same time the entire tubular bone affected by the plate was deranged by cancellous transformation These results are similar to those reported by UHTHOFF & DUBUC in plated osteotomies of dog femora and by GÖRDES et coll in plated osteotomies of the rabbit tibio fibular bone The present observations suggest that the structural abnormalities observed are caused mainly by the application of a rigid plate to the bone and only slightly if at all by the presence of a fracture In the present series the bones with axial compression were altered similarly to those with neutral plate fixation

Essential for maintaining the normal shape and structure of a weight bearing tubular bone is axial cyclic loading Normal loading is disturbed if by operation a mechanical system is created in which two components have different moduli of elasticity as when a rigid metallic plate is attached to the bone In such a mechanical system there is stress protection of the bone and stress concentration around the screws

Clearly the bone even without fracture reacts to the harmful effects of plate fixation with remodelling processes such as bone resorption Haversian remodelling and new bone formation Bone resorption occurs early within 3 weeks after fixation

the Haversian canals have visibly increased in width (SCHENK & WILLENEGGER OLERUD & DANCKWARDT LILLIESTRÖM GÖRDES et coll) Considerable bone resorption obviously precedes the remodelling of bone whether or not a fracture is present A recent report by TONINO et coll (1976) shows that the rigidity of the plate used for the osteosynthesis affects decisively the amount of the bone resorbed after the procedure composite plates cause less porosis than do rigid metallic plates As expected loss of the mineral content of the bone reduces its torque capacity (STRÖMBERG & DALÉN) However even though the plate induced morphologic abnormalities are profound bio mechanical experiments in this laboratory have shown that compensatory mechanisms counterbalance the adverse structural effects of the rigid plate (PAAVOLAINEN et coll in progress) The apposition of subperiosteal bone caused a slight increase in the circumference of the tubular bone which may contribute to a constant though subnormal strengthening of the bone Furthermore the dense juxtacortical collar around the screws gradually provides a substantial increase in the mass of the bone which may in part counterbalance the porotic changes

Hence the changes in the radiographic bone structure may be considered not only as the progressive cancellous transformation of the cortical bone subjected to the rigid implant but also as a dynamic series of remodelling by which the bone strives to counterbalance the adverse effects of the plate

SUMMARY

Rigid stainless steel osteosynthesis plates (DCP/ASIF) were attached bilaterally onto the intact tibio-fibular bone in 40 rabbits Axial compression was used on the right side neutral plate fixation on the left The radiographic appearances of the bone were analysed 1 day and 1 3 12 24 and 36 weeks postoperatively The changes in the bone were progressive related to the time of fixation and similar in the right and left leg The main alterations were a progressive thinning of the cortical bone under the plate and a progressive cancellous transformation of the tubular bone

ZUSAMMENFASSUNG

Osteosynthetische Platten aus rigidem rostfreiem Stahl (DCP/ASIF) wurden bilateral an die intakten tibio fibularen Knochen von 40 Kaninchen angebracht Auf der rechten Seite wurde eine axiale Kompression verwendet und auf der linken Seite eine neutrale Plattenbefestigung Das rontgenologische Bild des Knochens wurde nach einem Tag und nach 1 3 12 24 und 36 Wochen postoperativ untersucht Die Veranderungen im Knochen waren progressiv zur Zeit der Fixation relatiert und gleicherweise im rechten und linken Bein Die wesentlichen Veranderungen waren eine fortschreitende Verdunnung des kortikalen Knochens unter der Platte und ein progressive Transformation des tubularen Knochens

RESUME

Des plaques d ostéosynthèse en acier inoxydable rigide (DCP/ASIF) ont ete fixees des deux côtes sur l os tibio-fibulaire chez 40 lapins Une compression axiale a éte effectuee

du coté droit et une fixation neutre de la plaque du côté gauche L aspect radiographique de l os a été étudie 1 jour 1 3 12 24 et 36 semaines après l opération Les modifications dans l os ont été progressives en rapport avec la durée de fixation et similaires sur les membres droit et gauche Les principales altérations ont été un amincissement progressif de la corticale sous la plaque et une transformation progressive de l os tubulaire en os spongieux

REFERENCES

ANDERSON L D Compression plate fixation and the effect of different types of internal fixation on fracture healing J Bone Jt Surg 47 A (1965) 191

DIETSCHI C und ZENKER H Refrakturen und neue Frakturen der Tibia nach AO Platten und Schrauben Osteosteosynthesen Arch orthop Unfall Chir 76 (1973) 54

GORDES W KOSSYK W und HOLLANDER H Histologische und histomorphometrische Ver anderungen bei Plattenosteosynthesen nach Osteotomien an der Tibia des Kaninchen Arch orthop Unfall Chir 82 (1975) 123

MULLER M E ALLGÖWER M and WILLENEGGER H Manual of internal fixation Springer Verlag Berlin Heidelberg New York 1970

OLERUD S and DANCKWARDT LILLIESTRÖM G Fracture healing in compression osteosyn thesis in the dog J Bone Jt Surg 50 B (1968) 844

PAAVOLAINEN P SLATIS P KARAHARJU K AHONEN J and HOLMSTROM T Decay in torsion al strength in cortical bone subjected to rigid plate fixation Unpublished data 1977

PERREN S M RUSSENBERGER M STEINEMANN S MÜLLER M E and ALLGÖWER M A dynamic compression plate Acta orthop scand 125 (1969) 29

RAHN B and PERREN S M Primary bone healing J Bone Jt Surg 53 A (1971) 783

RICHON A LIVIO J J et SAEGESSER F Les réfractures après osteosynthèse par plaque à compression Helv chir Acta 34 (1967) 49

RUEDI T und ALLGÖWER M Die Frakturheilung nach Osteosynthese im Rontgenbild Helv chir Acta 41 (1974) 213

SCHENK R und WILLENEGGER H Zur Histologie der primaren Knochenheilung Langen becks Arch Chir 308 (1964) 440

SCHMIT NEUERBURG K P und GREIF E Die Beurteilung der verzogerten Knochenheilung im Rontgenbild Arch orthop Unfall Chir 78 (1974) 40

STROMBERG L and DALÉN N Influence of a rigid plate for internal fixation on the maximum torque capacity of long bones Acta chir scand 142 (1976) 115

TONINO A J DAVIDSON C L KLOPPER P J and LINCLAU L A Protection from stress in bone and its effects J Bone Jt Surg 58 B (1976) 107

UHTHOFF H K and DUBUC F L Bone structures in the dog under rigid internal fixation Clin Orthop 81 (1971) 165

WIESER C Die primare Knochenheilung und ihre Storung im Rontgenbild Langenbecks Arch Chir 308 (1964) 434

— und ALLGÖWER M Die Beurteilung der Knochenheilung nach stabiler Osteosynthese im Rontgenbild Clin Radiol 31 (1962) 297

WILLENEGGER H PERREN S M und SCHENK R Primare und sekundare Knochenbruch heilung Chirurg 42 (1971) 241

Book review

DAS PANORAMA AUFNAHMEVERFAHREN By G Canigiani 88 pages with 100 figures Georg Thieme Verlag Stuttgart 1976 Price DM 85

The term panoramic radiography is used in maxillo-facial radiography to denote survey examination techniques of the teeth and the jaws The most widely known method of exposing panoramic images is the utilization of a rotating narrow beam so called orthopantomography In this book an alternative method is described In this method the focal spot is located within an extension of a specially designed roentgen tube which is placed intra orally at the exposure The film is bent around the jaws The focal spot is very small and it is slightly elevated in relation to the remaining parts of the anode in this way it is possible to have the beam cover an angle greater than 180 This intra-oral panoramic method was introduced for clinical application in 1944 and since then a great number of communications analysing different aspects of the technique have been published This book is the first one to present about 30 years of technical and clinical experience Therefore the book should be of great value to all radiologists and dentists who are interested in the method under view

The book is introduced by an historical review Then a technical part is presented followed by a survey of clinical applications which is richly illustrated

Intra oral panoramic radiography was originally designed for dental use with the primary purpose of examining the teeth and their surrounding structures In the survey of clinical applications however more consideration is payed to other applications than strictly dental such as examinations of the facial bones the mandible and the salivary glands Some of the illustrations demonstrate convincingly that intra-oral panoramic radiography may be a useful complement to conventional methods in the diagnosis of among all fractures cysts and tumours However the applicability of the method is limited regarding examinations of fractures involving the teeth or the jaws it may be delicate or even inappropriate to place the roentgen tube extension intra orally in cases with traumatic lesions in the region control examinations are in most cases impossible because inter maxillar fixation is dominating in the treatment of jaw fractures This is not clearly emphasized In other cases presented it is doubtful if the method really implies an improvement compared to conventional radiographic systems including tomography According to the reviewer this is particularly true considering the sialographic application the salivary glands tend to be cut off and are not in all instances completely reproduced in the panoramic image Moreover the distortion effects are great making it delicate to assess deviations of the salivary ducts in cases of cysts or tumours In connection to the salivary gland examinations one of the examples given of concrements in Wharton s duct is definitely erroneous

The part of the book that deals with dental examination techniques and dental diagnostic problems is summarily presented and it includes some mistakes in terminology and facts This is a disappointment to the reviewer it should have been to prefer if the dental applications had been given the main part of the book considering that the equipment is designed and mostly used for dental purposes

Quoting a work from 196_ the author lists among disadvantages of the intra oral panoramic technique an inferior resolution compared to conventional dental examination technique with intra-orally placed non screen films Modern equipment for panoramic radiography have focal spots of 0 1 to 0 2 mm It is obvious that uch small focal spots in combination with non screen films give rise to less geometrical unsharpness than the much larger focal spots of dental roentgen apparatuses Instead such small focal spots make it

possible to utilize the magnification technique which is the basis of intra oral panoramic radiography The author is doubtful to the statement that the resolution should be inferior to that of conventional dental radiography but leaves the question to be answered by the dentists It is unfortunate that a questionable statement on an inferior image quality is emphasized by a repeated quotation in the book

It has been a commonly accepted view that a serious disadvantage with intra-oral panoramic radiography is a high radiation dose given to the patient However recent under takings explained by the author have decreased the patient dose to a great extent In fact van Aken has shown that the mean energy imparted often referred to as the integral absorbed dose in intra oral panoramic radiography is favourable compared to most other dental examination techniques van Aken s report is listed among the references but being very important when estimating the method with respect to the radiation risks it ought to have been quoted also in the text The use of high resolution rare earth phosphor screens in intra oral panoramic radiography should furthermore reduce the radiation dose this possibility is not discussed in the book

Summing up the new text book fills a gap as no summary of a great number of reports on intra oral panoramic radiography published in various journals has been available previ ously It is therefore to be regretted that the book has some apparent shortcomings However it demonstrates without doubt that the intra-oral panoramic method is justified namely when it is used on limited indications as a complement to conventional techniques

FROM THE SECTION FOR MAXILLO-FACIAL ROENTGENOLOGY CENTRAL HOSPITAL, S 961 19 BODEN AND THE DEPARTMENT OF RADIATION PHYSICS UNIVERSITY OF UMEÅ S 901 85 UMEÅ SWEDEN

ELLIPTICAL NARROW BEAM ROTATION RADIOGRAPHY

K A SAMFORS U WELANDER and G WICKMAN

In a series of publications WELANDER et coll have analysed the principle of rotation narrow beam radiography It was demonstrated that these methods although generally referred to as modified tomographic methods (VAN AKEN 1973 ANDO 1971 BARTON 1970 BLACKMAN 1956 1960 1964 BRUEGGEMANN 1967 BUCHMANN 1974 DUHAMEL 1954 1957 EDGE & CHAMPION 1972 GRABER 1965 1966 HUDSON et coll 1957 ICRU 1963 JUNG 1965 KUMPULA 1964 MANSON HING 1971 1976 PAATERO 1949 1954 PASLER 1973 PHILLIPS 1967 SOILA 1961 TAMMISALO 1964 TAMMISALO & NIEMINEN 1964 VUORINEN 1959) are essentially based on a specific projection technique Rotation narrow beam methods are not tomographic according to the basic definitions of tomography (EDHOLM 1960) In narrow beam rotation radiography a layer is formed which has certain similarities to that associated with tomography but the basic cause of the layer formation is entirely different (WELANDER 1974 1975)

A mathematical model of narrow beam rotation radiography was presented in 1974 (WELANDER) and it has been proved experimentally that the mathematical model is valid (SJÖBLOM et coll 1975 WELANDER & WICKMAN 1977 1978) Different aspects of the panoramic image obtained with a rotating narrow beam have been analysed mathematically on the basis of this model The layer formation has been analysed (WELANDER 1975) and the blurring as well as the layer thickness has been given new

Submitted for publication 21 January 1977

9 – 785849

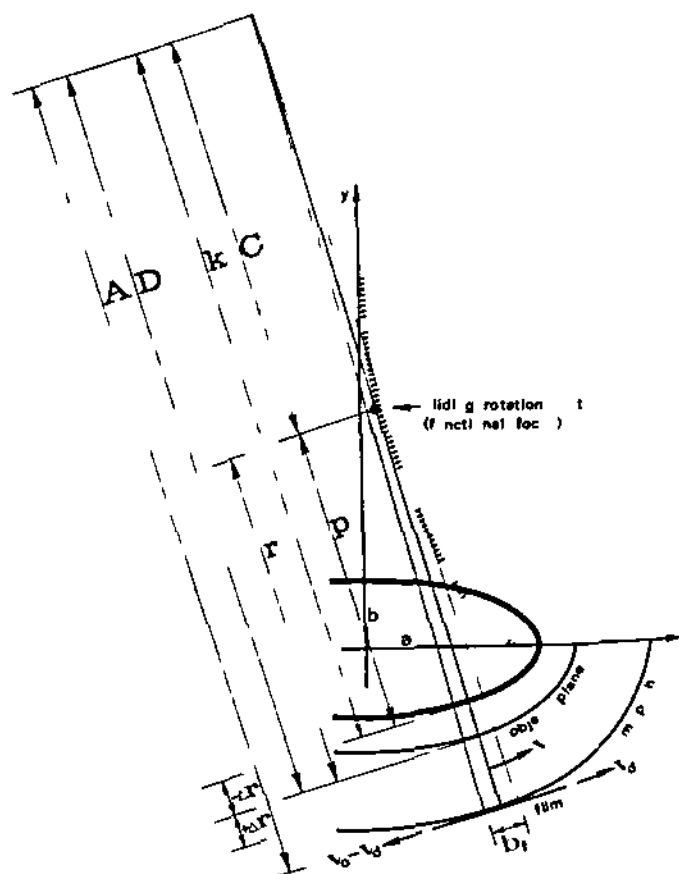


Fig 1 Essential parameters in elliptical narrow beam rotation radiography In elliptical systems the functioning focus of the projection is sliding along the evolute of the ellipse during the exposure The object plane does not necessarily coincide with the ellipse the position of the object plane is dependent on the relation between the velocities of the beam and the film.

definitions (WELANDER & WICKMAN 1977) The distortion phenomena have been defined and given geometrical and mathematical explanations angle distortion by SAMFORS & WELANDER (1974 a) area distortion by SAMFORS & WELANDER (1974 b) and form distortion by SJÖBLOM et coll (1975) In all these analyses a theoretical model of rotation narrow beam radiography based on a circular movement system was used In clinical work however various types of equipment are used some of them based on an elliptical movement and not on a circular one It was decided therefore to analyse the fundamental mathematics of elliptical rotation radiography

Definitions (See Fig 1)

A = distance tube target to film
D = distance tube target to object
d = horizontal distance in the object
d_f = horizontal distance in the image the distance d_o projected on the film
h_o = vertical distance in the object
h_f = vertical distance in the image the distance h projected on the film

r = distance from the rotation centre of the beam to the sharply depicted plane in the object object projection radius
Δr = positive or negative increment to the object projection radius
v_o = velocity of the beam in the object
v_d = velocity of the film
$v_o - v_d$ = velocity of the film in relation to the beam
b = width of the beam at the object projection radius
b_f = width of the beam at the film
C = distance tube target to the point where the central ray of the beam is tangential to the evolute of the ellipse
p = length of a perpendicular to the ellips to the point where it is tangential to the evolute this perpendicular coincides with the central ray of the beam
k = distance tube target to the ellipse
z = thickness of the sharply depicted image layer
M_a = magnification factor in the horizontal plane i e the rotation plane
M_b = magnification factor in the vertical plane
U_w = total length of a theoretically ideal line spread function total value of the characteristic blurring of narrow beam rotation radiography
U_{wr} = relative length of a theoretically ideal line spread function U_w/M_a relative value of the characteristic blurring of narrow beam rotation radiography

In the following it is presupposed that the tube target is a point source The curvature of the object within the beam is considered to be negligible (TAMMISALO & NIEMINEN 1964) The blurring is considered to be the length of a theoretically ideal line spread function (WELANDER & WICKMAN 1977) the energy distribution within this line spread function is neglected in the present work

The mathematical model of narrow beam rotation radiography as presented by WELANDER (1974) is valid for a circular movement system After simplifying substitutions it may be summarized

$$d_f + U_w = \frac{M_a}{d} + |M_a b - b_f| \quad (1)$$

where b = b (1 + $\Delta r/D$) because the width of the divergent beam varies within the object

The magnification factor in the horizontal plane this being also the rotation plane in the image is

$$M_a = \frac{rA}{D(r + \Delta r)}$$

From the mathematical model expressions for different image characteristics such as blurring layer thickness and geometrical properties may be derived

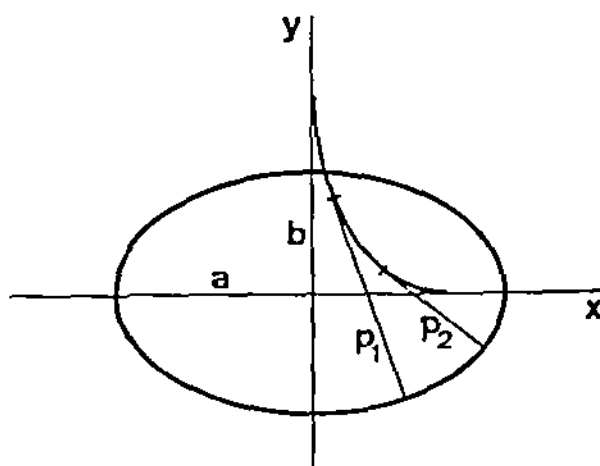


Fig 2 In elliptical narrow beam rotation radiography the effective projection radius for each part of the movement is the length between the sharply depicted object plane and the point where a perpendicular to the ellipse is tangent to the evolute The length of this perpendicular between the evolute and the ellipse p is marked in the illustration $x^2/a^2 + y^2/b^2 = 1$ $p = (x'^2 + y'^2)^{3/2}/(x'y'' - y'x'')$

Elliptical movement systems

A principle difference exists between a circular and an elliptical movement in association with narrow beam rotation radiography In a circular system the rotation centre of the beam is fixed during the exposure—although different rotation centres may alternate—but in an elliptical system the rotation centre of the beam slides along the evolute of the ellipse (Figs 1 2) The result of this condition is that in an elliptical movement system the object projection radius r varies continually during the exposure

Concerning most mathematical calculations of elliptical narrow beam methods knowledge of the variable object projection radius is necessary This radius may be found in the following way

It has been mathematically deduced (WELANDER 1974) and previously empirically postulated (TAMMISALO & NIEMINEN 1964) that the panoramic image is sharply depicted in the object plane where

$$\frac{v_o - v_d}{v_o} = \frac{A}{D} \qquad D = \frac{A v_o}{v_o - v_d} \tag{2}$$

Using this equation the position of the object plane may be calculated when the velocities of the beam and of the film are known

In the elliptical system it is true that (cf Fig 1)

$$r = D - C$$

Provided that the distance between the tube target and the ellipse k is constant during the exposure the value of C is expressed by

$$C = k - p$$

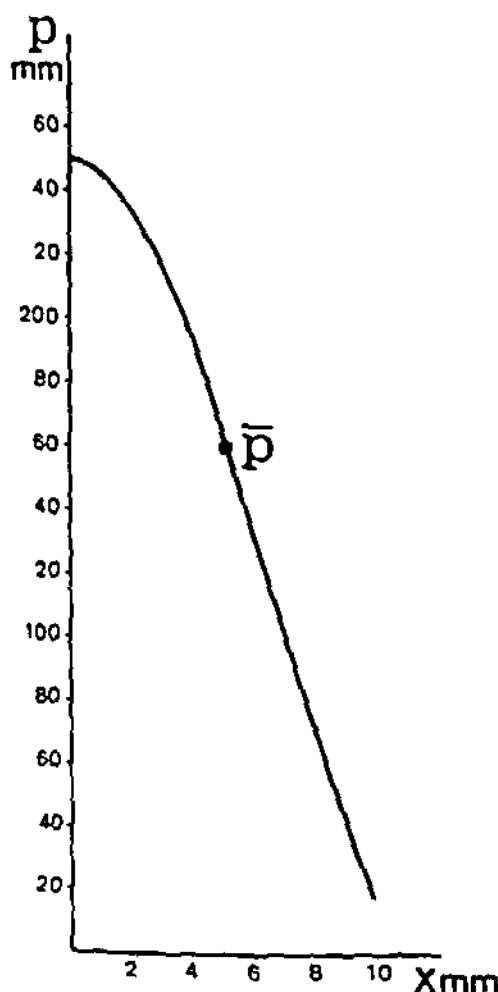


Fig 3 The length of the perpendicular to the ellipse to the point where it is tangent to the evolute as a function of the x-coordinate The function is valid for a theoretical elliptical system where a = 100 mm and b = 40 mm

Then

$$r = D - k + p \tag{3}$$

The value of p is found by applying the equation for the length of the perpendicular between the ellipse and its evolute (cf Fig 2)

$$p = \frac{a^2}{b}\left(1 - \frac{(a^2 - b^2)\,x^2}{a^4}\right)^3 \tag{4}$$

where $-a \leqslant x \leqslant a$

Substituting eq (3)

$$r = D - k + \frac{a^2}{b}\left(1 - \frac{(a^2 - b\ )\,x^2}{a^4}\right)^3 \tag{5}$$

is obtained

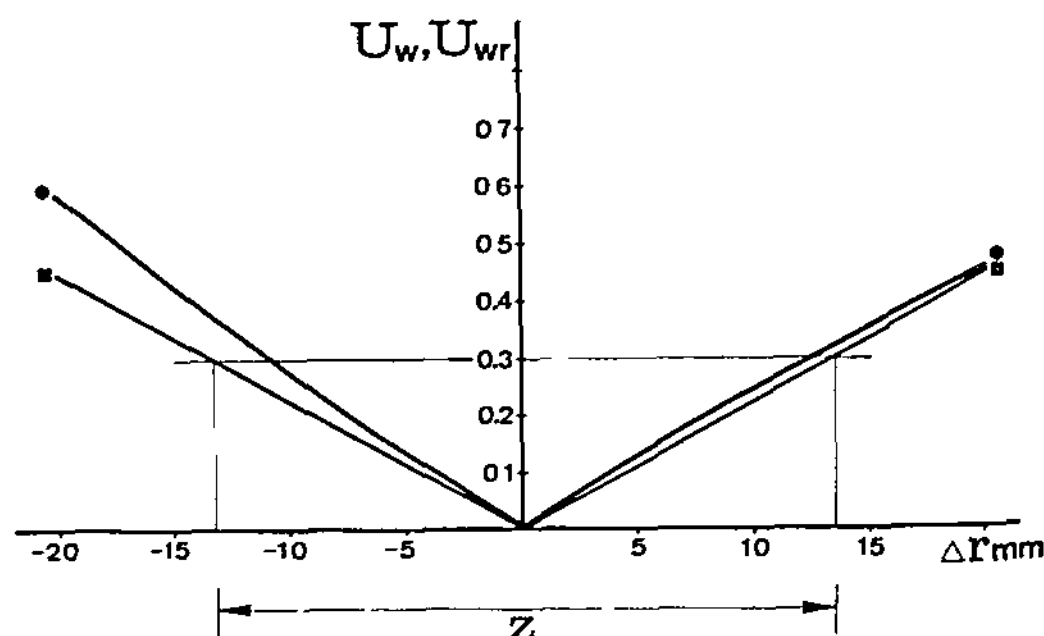


Fig. 4 Total (○) and relative (■) blurring in a theoretical elliptical system a = 100 mm b = 40 mm A = 460 mm D k 400 mm r = p 161 mm (p is equal to the approximate mean value of the function illustrated in Fig. 3) and b_r 7 mm. The layer thickness z is marked when the tolerable blurring is considered to be 0.3 mm

Eq (5) may be used to calculate the effective object projection radius for any part of the elliptical trajectory when the position of the object plane is known i e when D is known according to eq (2) p f(x) is exemplified in Fig 3 with values valid for a theoretical elliptical movement system

The mean value of the object projection radius for the total elliptical movement or indeed any part of it may be found from

$$r = D - k + \frac{a^2}{(x_2 - x_1) b} \int \left(1 - \frac{(a^2 - b^2) x^2}{a^4}\right)^3 dx \qquad (6)$$

where $x_1 < x$ and expresses the x-coordinates for the points on the ellipse between which the mean value of the object projection radius is sought

Application The mathematical model for circular rotation narrow beam radiography eq (1) and all equations derived from it may be applied to the elliptical system when r is substituted by the function presented in eq (5) To simplify the calculations a limited part of the ellipse may be considered to approximate a circle It is then possible to use a constant value for the object projection radius in calculations concerning a part of the elliptical movement To find a true mean value for the object projection radius within such a part of the ellipse eq (6) may be applied

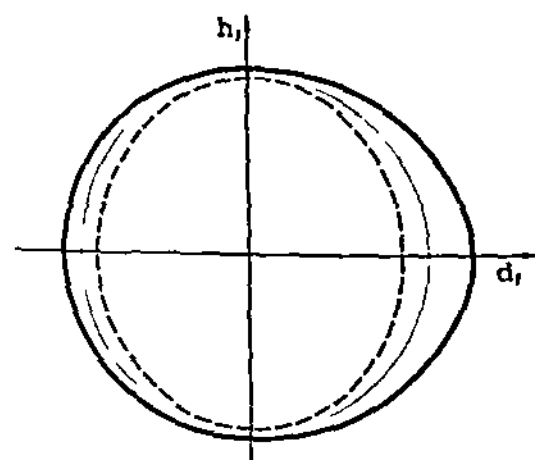


Fig 5 Distortion of a circular object exposed with the aid of a continually varying object projection radius When the circular object is reproduced in the image the beam is thought to move from the lateral part of the object to the anterior part i e from the left to the right in the drawing The projection radius is continually decreasing from the lateral to the anterior part of the imge When the circular object is positioned towards the rotation centre $\llcorner r < 0$ the magnification factor in the horizontal plane will increase successively during the exposure the circle is reproduced as an egg When the object is positioned towards the film $\llcorner r > 0$ the magnification factor will decrease successively during the exposure the circle is reproduced compressed more in the anterior part of the image than in the lateral part

The integral in eq (6) has a complex solution The most convenient way of solving the equation is to utilize numerical integration e g according to Simpson s rule Thus the mean value of p which is marked in Fig 3 was numerically computed It should be observed that $p = f(x)$ in a part approximates a linear function In this part of the function an arithmetic mean value of p should be a satisfactory approximation for most practical applications

Practical application may be demonstrated by some examples

Blurring and layer thickness According to WELANDER (1975) the total blurring in rotation narrow beam methods may be found from

$$U_w = |M_d b - b_f| \tag{7}$$

and the relative value of the blurring is (WELANDER & WICKMAN 1977)

$$U_{wr} - \left| b - \frac{b_f}{M_d} \right| \tag{8}$$

The layer thickness is expressed by (WELANDER & WICKMAN 1977)

$$z = 2 \left| \frac{U_{wr} rA}{b_f(r - D)} \right| \tag{9}$$

The solutions of eqs (7) (8) and (9) are all exemplified in Fig 4 In these cases a constant value of r has been used to illustrate the functions valid for a selected part along the elliptical movement a proper mean value of r was calculated from eq (6)

Geometrical properties The geometrical properties in elliptical narrow beam radiography may be exemplified by the calculation of the distortion of a circular

object (Fig 5) In this example the continuous variation of r along the elliptical trajectory has been incorporated

When a circular object is placed outside the centre of the object plane the distortion effects in the image are complex Due to the continuously varying object projection radius in elliptical systems the magnification factor varies continually in the rotation plane The result is that the circular object will be distorted to the form of an egg when placed towards the rotation centre placed towards the film the image will be compressed from both sides predominantly on the side where the object projection radius is shortest

The distortion effect (Fig 5) was computed from the expression (WELANDER & WICKMAN 1978)

$$h_f = \pm M_b \sqrt{1 - \left(\frac{d_f}{M_d}\right)^2}$$

where $M_b = A/(D + \Delta r)$ and $M_d = rA/D(r + \Delta r)$ r is expressed by eq (5)

Similarly other characteristics of the image geometry may be calculated

Discussion

Panoramic radiography utilizing a rotating narrow beam has become increasingly popular during the past years A fundamental objective in its evolution has been to improve the quality as regards both technical design of equipment and the clinical application

The concept of tomography has to date dominated the theoretical explanation of rotation narrow beam radiography Consequently the description of the basic principle of the method has been more or less focused on the layer formation However for a correct understanding of rotation narrow beam radiography it is necessary to analyse all the image forming elements and to consider their relative importance in the image formation In the present report the mathematical basis of the elliptical rotation narrow beam radiography is presented

A characteristic which should be observed is that the position of the layer i e the sharply depicted object plane does not coincide with the ellipse The layer may be positioned anywhere between the rotation centre of the beam and the film The critical factor deciding the position of the image layer is the relation between the velocities of the beam and of the film In elliptical movement systems the essential factor in the image formation is not the ellipse itself but the form of its evolute The rotation centre of the beam which is the functional focus of the projection in rotation narrow beam radiography slides along the evolute of the ellipse Thus it is the form of the evolute which is the factor that decides the direction of the beam in each part of the movement Thereby the evolute determines the projection of the object

Among the many different types of equipment based on a rotating narrow beam

some systems represent hybrids between circular systems for instance the Orthopantomo 70 and elliptical systems for instance the Panelips The Orthopantomographs 2 and 3 have sliding transitions between the anterior and the lateral rotation centres These sliding transitions do not coincide with the evolute of true ellipses but approximate an evolute Thus the Orthopantomographs 2 and 3 may be regarded as being based on a combination of circular movements and distorted elliptical movements

SUMMARY

The basic mathematics for elliptical narrow beam rotation radiography are deduced and exemplified An analysis of the functioning principle of elliptical systems shows that the essential factor in the image formation is the form of the evolute of the ellipse which determines the projection of the object The image layer does not necessarily coincide with the ellipse

ZUSAMMENFASSUNG

Die zugrunde liegende Mathematik der elliptischen Feinstrahlrotationsradiographie wird hergeleitet und am Beispiel erlautert Eine Analyse des funktionellen Prinzips des elliptischen Systems zeigt dass der entscheidende Faktor bei der Bildbildung die Form der Entwicklung der Ellipse ist welche die Projektion des Objekts bestimmt Die Bildschicht fallt nicht notwendig mit der Ellipse zusammen

RESUME

Les auteurs ont déduit les bases mathematiques de la radiographie rotatoire elliptique a faisceau étroit et en donnent des exemples L analyse du principe de fonctionnement des systemes elliptiques montre que le facteur essentiel dans la formation de l image est la forme de la développée de l ellipse qui determine la projection de l objet La couche d image ne coincide pas necessairement avec l ellipse

REFERENCES

VAN AKEN J Panoramic X ray equipment J Amer dent Ass 86 (1973) 1050
ANDO S Orthopantomography Its principle and technique Department of Radiology Nihon University School of Dentistry Tokyo 1971
BARTON E J The orthopantomography development and application Aust dent J 15 (1970) 151
BLACKMAN S Mass dental radiography Radiography 22 (1956) 21
— Rotational tomography of the face Brit J Radiol 33 (1960) 408
— Panoramic radiography Rotational tomography Brit J oral Surg 1 (1964) 209
BRUEGGEMANN I A Evaluation of the Panorex unit Oral Surg 24 (1967) 348
BUCHMANN F Die Prinzipien des Dental Tomograph Rontgenstrahlen 31 (1974) 24
DUHAMEL J Les procedés de radiographie en coupe rigoureux Sci Industr photogr 25 (1954) 129
— Sur la correspondance entre les espaces image et objet dans les procedés de radiographie en coupe par faisceau diaphragmé Sci Industr photogr 28 (1957) 225

EDGE M B B and CHAMPION CH Interpretation of the orthopantomogram Complications due to radiographic artifacts Brit dent J 133 (1972) 289
EDHOLM P The tomogram Its formation and content Acta radiol (1960) Suppl No 193
GRABER T M Panoramic radiography in dentistry J Canad dent Ass 31 (1965) 158
— Panoramic radiography Angle Orthodont 36 (1966) 293
HUDSON D C KUMPULA J W and DICKSON G A panoramic X ray dental machine U S armed Forces med J 8 (1957) 46
ICRU Methods of evaluating radiological equipm nt and materials Report 10 f 1962 National Bureau of Standards Handbook 89 Washington D C 1963
JUNG T Les procedes de radiographie panoramic en stomatologie Rev belge Méd dent 20 (1965) 165
KUMPULA J W Present status of panoramic ro ntgenography J Amer dent Ass 63 (1964) 194
MANSON HING L R Advances in dental pantomography the GE 3000 Oral Surg 31 (1971) 430
— Panoramic dental radiography Charles C Thomas Springfield Ill 1976
PAATERO Y V A new tomographical method for radiographing curved outer surfaces Acta radiol 32 (1949) 177
— Pantomography in theory and use Acta radiol 41 (1954) 321
PASLER F A Orthopantomographie in der zahnarztlichen Praxis Schweiz Mschr Zahnheilk 83 (1973) 1163
PHILLIPS J E Principles and function of the orthopantomograph Oral Surg 24 (1967) 41
SAMFORS K A and WELANDER U (a) Angle distortion in narrow beam rotation radiography Acta radiol Diagnosis 15 (1974) 570
— — (b) Area distortion in narrow beam rotation radiography Acta radiol Diagnosis 15 (1974) 650
SJOBLOM A SAMFORS K A and WELANDER U Form distortion in narrow beam rotation radiography Acta radiol Diagnosis 16 (1975) 565
SOILA P General theory of narrow beam rotation tomography Acta radiol 55 (1961) 458
TAMMISALO E H The dimensional reproduction of the image layer in orthopantomography Suom Hammaslaak Toim 60 (1964) 2
— Determination of the form of the image layer and calculation of its location within the object in conventional and simultaneous orthopantomography Suom Hammaslaak Toim 60 (1964) 14
— and NIEMINEN T The thickness of the image layer in orthopantomography Suom Hammaslaak Toim 60 (1964) 119
VUORINEN P The roentgenographic slit methods A survey and analysis of procedures based on the use of a narrow bundle of roentgen rays (scanography) Acta radiol (1959) Suppl No 177
WELANDER U A mathematical model of narrow beam rotation methods Acta radiol Diagnosis 15 (1974) 305
— Layer formation in narrow beam rotation radiography Acta radiol Diagnosis 16 (1975) 529
— and WICKMAN G Blurring and layer thickness in narrow beam rotation radiography Acta radiol Diagnosis 18 (1977) 705
— — Image distortion in narrow beam rotation radiography A mathematical analysis To be published in Acta radiol Diagnosis 19 (1978)

FROM THE DEPARTMENTS OF DIAGNOSTIC RADIOLOGY (DIRECTOR K HOORNSTRA) AND BIOSTATISTICS (DIRECTOR R VAN STRIK) ERASMUS UNIVERSITY ROTTERDAM THE NETHERLANDS

COLOUR PRESENTATION OF RADIOLOGIC IMAGES

G W DE WEY PETERS H J A SCHOUTEN and A W ZWAMBORN

A radiographic image contains about 100–150 distinguishable brightness levels (black and white gradations) this is in practice enough for evaluation of the images (GEBAUER et coll 1974) However the techniques used hitherto in the presentation of radiologic images make no use of an important property of the eye viz its ability to discriminate various colours It has been shown that the eye can distinguish about 150 spectral colours in addition the eye can also separate various levels of saturation of a given colour The saturation of a spectral colour is a measure of the amount of white light added to it if a lot of white light is added to a spectral colour its saturation is said to be low It has been found that the eye can distinguish about 10 degrees of saturation (WRIGHT & PITT 1935) It follows that the eye can perceive the difference between about 1 500 (10 150) different colours quite apart from possible differences in intensity between these colours (WARBURTON 1936)

It might be supposed on the basis of these facts that small contrast differences could be observed more easily in a colour image than in a black and white image Also WELANDER (1969) declared It seems that a colour image gives much better information than can be obtained from the black and white original images DAVIDSE (1971) developed a technique by means of which black and white radiographic images can be converted into colour images using colour TV equipment The colour converter will convert a black and white video-signal into three primary colour signals which are passed into a colour monitor Before the conversion takes place contrast can be expanded in the dark medium or light sections The result of the colour

Submitted for publication 20 April 1977

conversion is that to image sections of a certain light intensity a certain hue is assigned in such a manner that with increasing intensity all shades of the colour spectrum show up sequentially By means of a continuously adjustable colour selector a colour can be selected at random representing e g the dark sections thus fixing the starting point of the encoding This coding preserves the differences in light intensity in the radiologic image but the colour conversion probably facilitates rapid and less tiring observation The method can be applied to fluoroscopy (dynamic method) as well as to radiography (static method) In the dynamic method the video signal from the image intensifier/TV combination is coded directly while in the static method the image content of the film is first converted into a video signal with a black and white TV camera and then coded In this investigation the static method was used

The present investigation was initially started in order to test the utility of colour conversion for fluoroscopy However for statistic evaluation a reproducible fluoroscopic image is needed which is impossible to realize Colour and black and white slides were made from the colour monitor displaying the converted and non converted images respectively This method is not the best because the colour yield is not perfect Placing a good film in front of the black and white TV camera and displaying the TV image on a black and white or colour monitor would be better the adjustment of the viewer the TV camera the colour converter and the colour monitor being kept constant for each film But even in this way the reproducibility would not be satisfactory for a reliable statistic investigation The method with slides has the advantage of reproducibility Moreover since the method gives a positive result even though the colour yield is not perfect it is very likely that it will also be feasible for fluoroscopy

Material and Method

Twenty four p a chest films with lesions in the form of hematogenous metastases of various origin were used The metastases were hardly visible and could only be detected with certainty by comparing the chest films used with later ones These metastases were round a result of the growth mechanism of hematogenous metastases (BREUR 1965) In addition 24 chest films without metastases were used

The lung fields were divided into 6 roughly equal areas upper middle and lower on each side The image was converted into a video signal with a TV camera the video signal was passed to the colour converter (DAVIDSE & SANDERSON 1971) which was adjusted to give an optimum image subjectively This image was displayed on the screen of a high quality colour monitor (Philips EL 8500/51 625 lines with controlled interlace) one colour slide and one black and white slide were made of this image

The transfer from the colour monitor to colour slide material (Agfa CT 18) was optimized The white point of the monitor was adjusted by means of a photometer (Asahi Pentax Spot Meter 3) A colour correction filter (Kodak CCM 040) provided nearly ideal transfer of this white point to the slide material Moreover, the brightness and contrast content of the monitor was adjusted by means of the same photometer in

Table 1

The BW C and (BW + C) slides were mixed at random before being presented each series containing slides with and without metastases

Session		Presented material
Practice session		Separate slides
Round 1	session 1	BW1 C3 and (BW + C)2
	session 2	BW3 C1 and (BW + C)4
Round 2	session 3	BW2 C4 and (BW + C)1
	session 4	BW4 C2 and (BW + C)3

such a manner that optimum exposure within the contrast accepting properties of the colour slide material was obtained The adjustments were optimized experimentally in order to obtain reproducible colour slides representing the original monitor image as closely as possible with regard to contrast and colour

When a metastasis was photographed (Canon F_1 FD 1 2/55) in one of the 6 areas the corresponding area of a chest film without metastases was also photographed In this way 48 colour slides and 48 black and white slides were obtained

Experimental design A random permutation (MOSES & OAKFORD 1963) was used to number the black and white (BW) slides from 1a to 48a The colour (C) slides were numbered from 1b to 48b in such a way that BW slides and C slides with corresponding number had the same image content

The BW slides were divided into 4 series BW1 BW2 BW3 and BW4 consisting of the slides 1a–12a 13a–24a 25a–36a and 37a–48a respectively the C slides were correspondingly divided into series C1 to C4

The material was presented to 13 radiologists individually in 2 rounds of 2 sessions after an initial session for practice Table 1 shows the order of presentation of the material In the practice session separate slides were used in order to give the radio logists the possibility to practice observation of colour slides Each slide could be viewed either in colour or in black and white or simultaneously in colour and black and white The radiologists were also tested for colour blindness in this session

The material was presented in 2 rounds the same slides being inspected in the first round as in the second In order to minimize memory effects the 2 rounds were separated by a relatively long period of time (one month) Each round was split up into 2 sessions separated by a period of 2 weeks This reduced the duration of each session thus helping to avoid fatigue effects In addition arrangements were made to ensure that the radiologists were sitting comfortably and were relaxed while viewing the slides

Two projectors were used in each session one for the projection of the BW slides and one for the C slides When only a BW slide was presented the C projector was blocked with a uniform green slide when only a C slide was presented the BW

Table 2

Colour versus black and white (in per cent) Symbols < Metastases underscored = Correct number of metastases Metastases overscored The percentages in the margin were obtained by dividing the appropriate marginal total by the grand total Owing to rounding off of errors not all percentages total 100 Each table is based on 312 pairs of estimations 24 pairs from each of the 13 radiologists

With lesions		Colour			
			=	>	Total
Black		14	10	3	27
and	–	6	36	8	51
white		3	13	7	22
	Total	23	59	18	100

Without lesions		Colour		
		=	>	Total
Black	=	76	10	86
and	‸	11	4	14
white	Total	87	13	100

projector was blocked with a uniform grey slide (BW + C) means that both slides (with identical image content apart from the colour) were projected simultaneously The C BW and (BW + C) slides were mixed at random before being presented More over the slides in each series were changed around cyclically for each radiologist

At the start of each session the radiologist was given one minute for adaption to the darkness with the aid of the practice slides The slides from the series were then pre sented The maximum observation time per slide was one minute the observer being warned 10 seconds before the end of this period The radiologist reported the number of metastases detected in each image on a protocol Apart from noting down the answers the assistant also operated the projectors as directed by the observer

Comparison and Conclusions

The number of metastases reported by each radiologist on each slide was noted and compared with the actual number of metastases present on the slide Only when the radiologist told the right number of metastases was the answer scored as correct too many or too few metastases were scored as *incorrect* The number of correct answers from each of the 13 radiologists was used to compare the three methods separately for slides with and without metastases With the aid of the Wilcoxon matched pairs signed ranks test (SIEGEL 1956) applied as a two sided test an evaluation was made as to whether one method resulted in significantly more correct answers than did another method

Slides without metastases For the slides without lesions the difference between two methods never was statistically significant ($p > 0.30$) The three methods seem to be about equal (Table 2)

Slides with metastases The right number of metastases was more frequently re ported in the series of colour slides than in black and white (Table 2) the difference is significant ($p < 0.02$)

The combination of black and white with colour slides resulted in more correct answers than were obtained with black and white slides only and fewer correct answers than with colour slides only However these differences are not significant (p>0 10 in both cases) Thus one of them may be caused by chance but not both because colour slides give significantly better results than black and white slides

Acknowledgements

We should like to thank L P de Jong for his valuable technical advice and the 13 radiologists for their cooperation

SUMMARY

A technique is described for conversion of black and white fluoroscopic images into colour The advantages of this technique were investigated with the aid of slides Although the colour yield in slides is not perfect this method was chosen because it gives a reproducible image Lesions were recognized significantly better on colour slides than on black and white slides (p <0 02)

ZUSAMMENFASSUNG

Eine Technik wird beschrieben um schwarz weisse fluoroskopische Bilder in Farben umzuwandeln Die Vorteile dieser Technik wurden mit Hilfe von Diapositiven untersucht Obwohl die Farbwiedergabe der Bilder nicht perfekt ist wurde diese Methode gewahlt weil sie ein reproduzierbares Bild gibt Lasionen wurden signifikant besser an Farbbildern als an schwarz weissen Bildern festgestellt (p 0 02)

RESUME

Les auteurs décrivent une technique de conversion des images radioscopiques en blanc et noir en images colorees Ils examinent les avantages de cette technique à l aide de diapositives Bien que le rendu de la couleur sur les diapositives ne soit pas parfait cette méthode a ete choisie car elle donne une image reproducible Des lesions ont éte reconnues de façon significativement meilleure sur les diapositives colorees que sur les diapositives en blanc et noir (p <0 02)

REFERENCES

BREUR K Growth rate and radiosensitivity of human tumours Mouton & Co The Hague 1965

DAVIDSE J Improved interpretation of picture information by means of electronic signal processing Med mundi 16 (1971) 108

— und SANDERSON H J Helligkeits Kontrastverstarkung in der Rontgentechnik mit Hilfe des Farbfernsehens Nachrichtentech Z 24 (1971) 57

GEBAUER A LISSNER J und SCHOTT O Das Rontgenfernsehen 2nd edition p 37 Georg Thieme Verlag Stuttgart 1974

Kodak filters (for scientific and technical uses) Publication No B 3 cat 1528108 Eastman Kodak Company Rochester N Y 1973

MOSES L E and OAKFORD R V Tables of random permutations 1st edition Stanford University Press Stanford California 1963

SIEGEL S Nonparametric statistics for the behavioral sciences 1st edition p 75 McGraw Hill London 1956

WARBURTON F L The discrimination of the saturation of colours Proc physiol Soc (London) 48 (1936) 38

WELANDER U Multicolor combination images in subtraction angiography Acta radiol (1969) Suppl No 290

WRIGHT W D and PITT F H G The colour vision characteristics of two trichromats Proc physiol Soc (London) 47 (1935) 205

ACTA RADIOLOGICA

PUBLISHED BY THE SOCIETIES OF MEDICAL RADIOLOGY IN
DENMARK FINLAND NORWAY AND SWEDEN

Vol 19
Fasc 1 B

DIAGNOSIS

1978

ECTOPIC URETEROCELE IN THE MALE INFANT

O Eklöf G Löhr H Ringertz and B Thomasson

Ectopic ureterocele accounts for approximately one per cent of the entire urologic material at this department The female sex dominates the anomaly being 6 5 times more common in girls The relatively low frequency in boys explains why the condition has received only little attention in the male Except for 15 cases mainly considered from the clinical point of view by Williams & Royle (1969) there are few comments on sex differences on record (Williams et coll 1972 Williams 1974)

However a recent radiologic investigation of 66 consecutive cases indicated that the anomaly was more complex in boys (Eklof & Makinen 1974) An analysis of the differences in radiologic appearances between the sexes as well as of the therapeutic and prognostic implications of the anomaly in males has therefore been performed

Material and Method

The series consisted of 14 boys with a mean age at diagnosis of 25 months and a median age of 6 months (range 0 to 12 years) The girls included in the series of Eklöf & Makinen were used for comparison Nine of the 14 boys had been part of this larger mixed material

From the Departments of Pediatric Radiology (Director O Eklof) and Pediatric Surgery (Director B Thomasson) Karolinska Sjukhuset, S-104 01 Stockholm Sweden Submitted for publication 21 June 1977

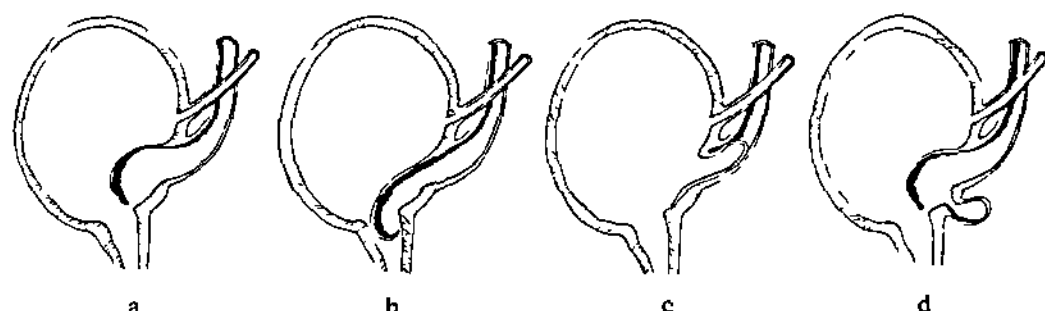


Fig 1 Potential behaviour of ectopic ureterocele during micturition a) Tense ureterocele b) Compressible ureterocele c) Eversion of ureterocele by intussusception into the associated ureter d) Eversion of the ureterocele in a case with deficient detrusor sheet

Table

Findings at radiography

Case number	1	2	3	4	5	6	7	8	9	10	11	12	13	14
Side of anomaly	R	R	R	L	L	L	R	R	R	R	R	R	L	L
Ipsilateral duplication		X			X	X	X	X	X	X	X	X		X
Contralateral duplication							X					X		X
Urography														
Ipsilateral pathology (lower moiety)		X						X	X	X	X	X		X
Contralateral pathology	X			X		X	X	X		X			X	X
Micturition cysto urethrography														
Reflux				X			X	X		X	X	X	X	
Eversion of ureterocele	X			X		X			X	X		X		
Pathologic urethra	X	X	X	X	X	X		X	X		X		X	X

All patients underwent at least one preoperative urography and all but one patient a preoperative micturition cysto urethrography The mean follow up period was 4 5 years and the median follow up 2 5 years (range 0 to 13 years) In 8 cases the follow up included urography and micturition cysto urethrography in 3 cases only urography In 3 patients recently operated upon no post operative radiography has been performed

Symptoms and signs These were rather uniform in 11 of the cases being urinary infection 2 of them had urosepsis One of the remaining patients had urinary retention at age 1 day and associated massive urinary infection Two other patients presented with gastro intestinal symptoms caused by an underlying urinary infection one of them had in addition imminent circulatory collapse In the last case the incidental finding of an abdominal mass resulted in urography and the diagnosis of a huge hydronephrosis secondary to an ipsilateral ectopic ureterocele



Fig 2 Micturition cysto-urethrography appearances in a case of ureterocele eversion by intussusception into the associated ureter b) After uncapping of the ureterocele Free reflux to the associated ureter located at the level of previous eversion

Radiology The essential findings are recorded in the Table The anomaly was right sided in 9 and left sided in 5 cases Impaired function of the upper moiety of the kidney on the side of the anomaly is a classical feature of ectopic ureterocele Occasionally the ipsilateral lower moiety also becomes afflicted This was evident in the present material ($p < 0.001$) a frequency significantly higher than in girls In 4 boys the ureterocele involved a ureter belonging to a single collecting system ($p < 0.01$) Kidney function was abolished in all these cases On the contralateral side the function did not differ from what is found in girls Some degree of dilatation existed in several cases ($p < 0.001$) Four boys had a moderate contralateral lower ureteric obstruction

The rate of ipsi and contralateral vesico ureteric reflux on micturition cysto-urethrography in the boys conformed with that in girls Eversion of the ureterocele occurred more often in boys ($p < 0.01$) Dilatation of the posterior urethra due to prolapse of the ureterocele was also frequently observed ($p < 0.01$) In 5 patients the concomitant elongation of the posterior urethra resulted in an appearance resembling that of posterior urethral valves (Fig 6 c) The deformity caused by the ureterocele persisted post operatively causing obstruction of the bladder outlet in 2 patients

Treatment In one patient an erroneous diagnosis of a posterior urethral valve was made and a transurethral resection was carried out later the correct diagnosis was established The non functioning ipsilateral kidney and the ureter which drained a single collecting system were removed The ureterocele was resected in a second session In another 2 patients with a single collecting system and a non functioning kidney on the side of the anomaly fulguration of an erroneously assumed urethral valve was performed in the same session as the resection of the ureterocele The non functioning kidney with its ureter was later removed in both patients Nephro-ureterectomy and resection of the ureterocele were performed in an additional 3 patients because of hydronephrosis and extremely poor function of the reduplicated



Fig 3 a b) Ureterocele and tortuous associated ureter displaced outside the bladder Different degrees of bladder filling and reflux c) During voiding the ureterocele and the coiled ureter are pressed down into the posterior urethra causing elongation dilatation and valvelike obstruction of prostatic urethra

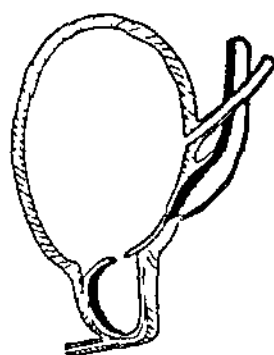
kidney Nephro-ureterectomy was thus more frequently needed in boys ($p < 0.001$) Heminephro ureterectomy and resection of the ureterocele was performed in 6 patients while treatment in the remaining 2 patients was confined to resection of the ureterocele (ERICSSON 1954)

Following surgery function of the remaining moieties of the kidney improved Some degree of upper urinary tract dilatation persisted on the side of the ureterocele in 4 and contralaterally in 3 patients The 2 patients treated with resection of the ureterocele alone had a persisting reflux of the ipsilateral ectopic ureter while 2 other patients had contralateral reflux at the follow up One of the patients who was operated upon for a suggested urethral valve was incontinent apparently because of a communication between the bladder and the posterior urethra mediated by the distal stump of the ectopic ureter The orifice of the ureter was located at the level of the external sphincter of the urethra

Discussion and Conclusions

The sex diversity of the radiologic appearance of ectopic ureterocele has not been generally appreciated Comparison of the present series with the girls included in the mixed material (EKLÖF & MAKINEN) appeared suitable as both groups belong to the same population No significant difference in mean age between the two groups was found However the median age of the boys was only half the median age of the girls indicating a different distribution within the groups

The symptoms and signs in the boys were significantly more marked and the mal formation more complex than in the girls The frequency of ipsilateral single col lecting systems was considerably higher in the males A poor or abolished renal func


Fig 4

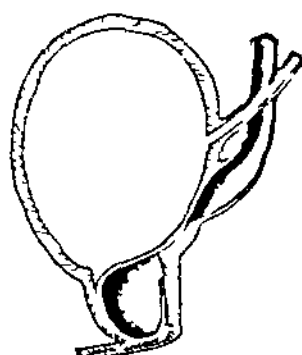

Fig 5

Fig 4 Caecoureterocele during micturition

Fig 5 Obstructed distal orifice of the ectopic ureter Behaviour during micturition

tion on the side of the anomaly resulted in a higher frequency of nephrectomy and heminephrectomy as compared with the girls The boys were operated upon at a lower age than the girls another indication of the severity of the condition as in the series of WILLIAMS & ROYLE The behaviour of the ureterocele during voiding is crucial for correct appreciation of the details of the anomaly and assessment of prognosis This makes micturition cysto-urethrography an obligatory examination

Occasionally obstruction at the ectopic orifice results in a rather high pressure in the ureter and in the associated collecting system During micturition the ureterocele remains at the base of the bladder and causes only slight or no obstruction to the urethra (WILLIAMS) (Fig 1 a) Only one of the boys had a ureterocele of this type

The remaining 13 cases displayed quite different appearances Located at the outlet of the bladder the ureterocele tended to contract or to become compressed during voiding (Fig 1 b) A change in shape size and location took place and interfered with the emptying of the bladder to a variable extent Both prolapse of the ureterocele into the posterior urethra and eversion of the anomaly were observed Similar observations have previously been recorded by KJELLBERG et coll (1957) STEPHENS (1963 1971) FRIEDLAND & CUNNINGHAM (1972) WILLIAMS et coll and WILLIAMS It seems that the potential defect of the muscular coat of the ureterocele (SUBBIAH & STEPHENS 1972) and any degree of insufficiency of the bladder wall behind the ureterocele are of crucial importance for the ultimate appearance of the ureterocele at voiding The width and site of the orifice of the ectopic ureter may be other factors of significance

Only little attention has been paid to the mechanisms leading to eversion of the ureterocele The everted ureterocele was particularly prominent in 2 patients it was 2 cm long and bulged posterolaterally at the trigone of the bladder (Fig 2 a) Comparison between the preoperative film and a film exposed after uncapping of the ureterocele (Fig 2 b) would imply that eversion at least in some cases may be due to intussusception of the ureterocele into its own ureter (Fig 1 c) The same conclusion has been drawn by CREMIN et coll (1977) on the basis of information obtained at serial 70 mm recording in 3 recently reported cases



Fig. 6 a) Caecoureterocele located at the bladder outlet Early filling phase b) Later stage of filling of the bladder Early prolapse of the ureterocele into the posterior urethra c) Elongation and dilatation of the prostatic urethra during voiding due to partial prolapse of the ureterocele Valvelike appearing deformity of the urethra has developed Part of the ureterocele has everted

Yet the most frequently entertained theory of eversion is based on the occasional observation of an insufficient detrusor sheet behind the ureterocele Increasing bladder pressure during voiding would then result in a local protrusion of the wall (Fig 1 d) The level of eversion in relation to the bladder neck and the site of the ureterocele on urography in the present series is less well in conformity with this theory (Fig. 6 c)

Another hypothesis suggests that the ureterocele may herniate through the ureteric hiatus of the bladder wall Intermittently the tortuous ectopic ureter and the ureterocele become projected outside the bladder Increasing pressure and ureteric peristalsis may particularly during voiding, force the ureterocele and sometimes part of the sinuous ureter down into the prostatic urethra The defective hiatus was observed at operation in 2 of the present cases and has previously been suggested by STEPHENS (1963 1971) FRIEDLAND & CUNNINGHAM (1972) and FENDEL (1977) Elongation and dilatation of the posterior urethra may ensue (Fig. 3 c) This phenomenon may even lead to a valvelike abnormality Apparently it has repeatedly been mistaken for posterior urethral valves in the past The orifice of the ectopic ureter may occasionally be wide and located in the bladder part of the ureterocele extending down into the



Fig 7 Obstructed ureterocele filled with urine and during micturition partly displaced into the posterior urethra Obstruction to bladder outlet somewhat less marked as compared with Fig 6 c

urethra (Fig 4) STEPHENS (1971) coined the term caecoureterocele for this type of anomaly Voiding is partially taking place into the ureterocele which becomes distended Because of the extensive filling of the ureterocele and adjacent structures with contrast medium the ureterocele will be hard to distinguish during voiding This sequence of events is illustrated in Fig 6 The marked obstruction of the bladder outflow is considered an important cause of impaired renal function as a rule mainly afflicting the kidney on the side of the anomaly

In a case with a narrow orifice at the lowermost aspect of the ureter increasing intravesical pressure and the urinary flow may displace the ureterocele down into the posterior urethra However with this displacement of the orifice the pressure exerted on the bladder neck counteracts escape of the contents of the ureterocele into the associated ureter (Fig 5) As the contrast medium cannot enter the ectopic system the ureterocele appears like a filling defect in the posterior urethra (Fig 7) Obstruction to the bladder outflow is as a rule less marked in this variety of ureterocele which does not increase in size during micturition

In the present series a broad spectrum of severity of bladder outlet obstruction was encountered The more severe the obstruction the more adversely afflicted was the kidney function Another unfavourable feature was the association of a single




Fig. 6 a) Caecoureterocele located at the bladder outlet Early filling phase b) Later stage of filling of the bladder Early prolapse of the ureterocele into the posterior urethra c) Elongation and dilatation of the prostatic urethra during voiding due to partial prolapse of the ureterocele Valvelike appearing deformity of the urethra has developed Part of the ureterocele has everted

Yet the most frequently entertained theory of eversion is based on the occasional observation of an insufficient detrusor sheet behind the ureterocele Increasing bladder pressure during voiding would then result in a local protrusion of the wall (Fig 1 d) The level of eversion in relation to the bladder neck and the site of the ureterocele on urography in the present series is less well in conformity with this theory (Fig 6 c)

Another hypothesis suggests that *the ureterocele may herniate through* the ureteric hiatus of the bladder wall Intermittently the tortuous ectopic ureter and the ureterocele become projected outside the bladder Increasing pressure and ureteric peristalsis may particularly during voiding force the ureterocele and sometimes part of the sinuous ureter down into the prostatic urethra The defective hiatus was observed at operation in 2 of the present cases and has previously been suggested by STEPHENS (1963 1971) FRIEDLAND & CUNNINGHAM (1972) and FENDEL (1977) Elongation and dilatation of the posterior urethra may ensue (Fig 3 c) This phenomenon may even lead to a valvelike abnormality Apparently it has repeatedly been mistaken for posterior urethral valves in the past The orifice of the ectopic ureter may occasionally be wide and located in the bladder part of the ureterocele extending down into the

KJELLBERG S R ERICSSON N O and RUDHE U The lower urinary tract in childhood Almqvist & Wiksell Uppsala 1957
STEPHENS D Congenital malformations of the rectum anus and genito urinary tracts E & S Livingstone Edinburgh London 1963
— Caecoureterocele and concepts of the embryology and etiology of ureteroceles Aust N Z J Surg 40 (1971) 239
SUBBIAH N and STEPHENS D Stenotic ureterocele Aust N Z J Surg 41 (1972) 257
WILLIAMS D I Ureteroceles *In* Urology in childhood Suppl XV of Encyclopaedia of Urology Springer Verlag Berlin Heidelberg New York 1974
— and ROYLE M Ectopic ureter in the male child Brit J Urol 41 (1969) 421
— FAY R and LILLIE J G The functional radiology of ectopic ureterocele Brit J Urol 44 (1972) 417

FROM THE DEPARTMENT OF DIAGNOSTIC RADIOLOGY UNIVERSITY HOSPITAL AND THE DEPARTMENT OF STATISTICS UPPSALA UNIVERSITY S 750 14 UPPSALA SWEDEN

KIDNEY SIZE IN INFANTS AND CHILDREN ASSESSED BY AREA MEASUREMENT

H JORULF J NORDMARK and Å JONSSON

Radiologic estimation of the kidney size in infants and children has considerable clinical application especially for preoperative evaluation and for demonstrating the effect of surgery

Different methods for estimating the kidney size have been reported including measurement of its length breadth depth or volume

The kidney length and cross section area of a growing child is well correlated to the total growth of the child (HODSON et coll 1962) These authors concluded that the length of the kidney was a good indication of its size in the absence of any morphologic abnormality COPPOLETTA & WOLBACH (1963) found a linear correlation between the weight of the kidney and the body weight in infants and children STOLPE et coll (1967) reported a good correlation between the length and the weight of the kidney A linear relationship has also been reported between the length of the kidney and the height of a segment of the vertebral column (SIMON 1964 CURRARINO 1965 EKLÖF & RINGERTZ 1976)

Planimetric measurements of the kidney area have been reported by several authors (HODSON 1960 HODSON et coll 1962 GUY & MUONIC 1971 JOUVE et coll 1971) The kidney area as a product of length and breadth was measured by MOËLL (1956) Planimetric measurement of the kidney size by means of a graphic tablet linked to a computer with an interface was reported by WARD et coll (1976) A linear relationship between the kidney area and the age of the child for the ages 5 to 15 years was found by KARN (1962) A good correlation between the area and the function of the

Submitted for publication 2 May 1977

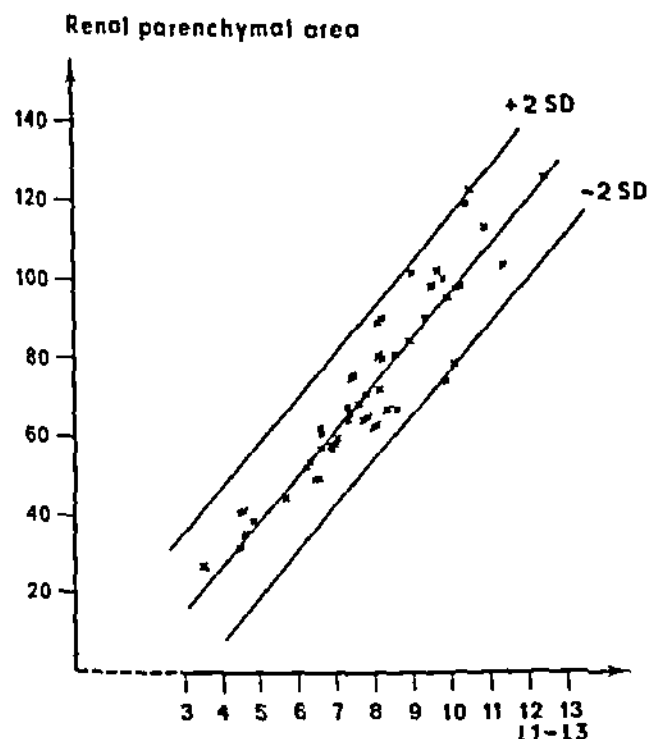


Fig 1 The sum of the parenchymal areas of the right and left kidney in cm² and distribution of the material according to length of L1–L3

Table 1

Correlation coefficients of some of the calculated parameters

Renal parenchymal area right + left / body height	0 922
Kidney length right + left / height of L1–L3	0 9 1
Renal parenchymal area right + left / body weight	0 919
Renal parenchymal area right + left / height of L1–L3	0 916
Renal parenchymal area right / height of L1–L3	0 897
Renal parenchymal area left / height of L1–L3	0 908
Renal parenchymal area left / right	0 945
Kidney length left / right	0 933

Table 2

The normal range (±2 SD) of the sum of the right and left renal parenchymal area in cm² given fo each mm of L1–L3 length

L1–L3 cm	0 0	0 1	0 2	0 3	0 4
4 0	8 2– 46 9	9 4– 48 0	10 6– 49 2	11 8– 50 3	12 9– 51 4
5 0	20 1– 58 3	21 3– 59 5	22 4– 60 6	23 6– 61 8	24 8– 62 9
6 0	31 9– 69 8	33 1– 71 0	34 3– 72 1	35 4– 73 3	36 6– 74 4
7 0	43 7– 81 4	44 8– 82 5	46 0– 83 7	47 2– 84 8	48 3– 86 0
8 0	55 3– 93 0	56 5– 94 2	57 7– 95 3	58 8– 96 5	60 0– 97 7
9 0	66 9–104 7	68 1–105 9	69 3–107 0	70 4–108 2	71 6–109 4
10 0	78 5–116 5	79 6–117 6	80 8–118 8	81 9–120 0	83 1–121 2
11 0	90 0–128 3	91 1–129 5	92 2–130 7	93 4–131 9	94 5–133 1
12 0	101 4–140 2	102 5–141 4	103 6–142 6	104 8–143 8	105 9–145 0

kidney was demonstrated by ANDERSEN & MOGENSEN (1973) WARD et coll and WIKSTAD et coll (1977)

EKLÖF & RINGERTZ presented an easily applicable method for assessing the kidney size in children based on measurements of the kidney length in relation to the height of the three upper lumbar vertebrae including the intervertebral discs, and drew a nomogram from which the size of the kidney is easily determined in terms of standard deviations from the normal

HODSON et coll (1975) found that the mass of the renal parenchyma decreases during the first two decades when related to the external renal dimension This process was rapid during the first few years of life This observation and the fact that reduction of the renal parenchyma following episodes of pyelonephritis may be irregular makes it reasonable to assume that the parenchymal area may be a better parameter for assessing the size of the kidney than its length or breadth However no practical method for radiologic assessment of the kidney size from the renal parenchymal area appears to have been described previously The present report presents such a method and its application in a series of healthy children

Material and Methods

The material comprised 80 healthy children with an even distribution between boys and girls ranging from 4 months to 15 years of age The height of the three lumbar vertebrae L1–L3 including the intervertebral discs ranged from 4 to 13 cm The distribution of the material appears in Fig 1 The measurements were made on urographic films Indications for urography were slight abdominal trauma micro scopic haematuria and enuresis Neither urography nor other examinations revealed any signs of infectious disease or other abnormalities of the urinary tract The shortest observation period was six months

Table 2 (*cont*)

0 5	0 6	0 7	0 8	0 9
14 1– 52 6	15 3– 53 7	16 5– 54 9	17 7– 56 0	18 9– 57.2
26 0– 64 0	27 2– 65 2	28 4– 66 3	29 5– 67 5	30 7– 68 6
37 8– 75 6	39 0– 76 7	40 1– 77 9	41 3– 79 0	4?.5– 80 2
49.5– 87 2	50 7– 88 3	51 8– 89.5	53 0– 90 7	54 2– 91 8
61 1– 98 8	62 3 100 0	63.5–101 2	64 6–102 3	65 8–103 5
72 7–110 6	73 9–111 7	75 0–112 9	76 2–114 1	77 3–115 3
84.2–12? 4	85 4–123 6	86 5–124 7	87 7–125 9	8? 8–127 1
96 7–134 3	96 8–135 4	98 0–136 6	99 1–137 8	100 2–139 0
107 0–146 2	198 2–147 4	109 3–148 6	110 4–149 8	111 6–151 0

All patients were examined in the supine position The amount of contrast medium used was 3 ml per kg body weight up to a weight of 7 kg and 2 ml per kg in heavier children The total amount of medium never exceeded 40 ml of a 60 per cent medium The film–focus distance was 100 cm and the table top–film distance 12 cm

Compression was applied on the ureters 5 min after injection of the contrast medium and 5 min later an a p film of the kidney area was exposed to serve as the basis for planimetry

Several parameters were measured the length of the kidney the length of L1–L3 including the intervertebral discs body height and body weight The total renal area projected on the film and the renal pelvic area (including the calyces) were measured planimetrically (MAHO Planimeter 9540–1) The renal parenchymal area was given after subtraction of the renal pelvic area (Fig 2) The correlation b tween the *various* parameters was determined by use of a computer The correlation coefficients of some of the relationships are given in Table 1

A linear correlation exists between the sum of the right and *left* renal parenchymal areas and the length of the three first lumbar vertebrae including the intervertebral spaces (Fig 1) The normal range ±2 standard deviations of the sum of the right and left renal parenchyma area in cm² i given in Table 2 for each mm of L1 L3 length

When the sizes of the right and left kidneys were compared the correlation based on kidney area was somewhat better than that for kidney *length*

In the whole material he area of the kidney was well correlated to its length as described by Eklöf & Ringertz

A nomogram for practical clinical use gives the standard deviations from the normal and is based on the parenchymal area and the height of the three vertebrae L1–L3 (Fig 3) For practical purposes the right and left renal parenchymal areas were assumed to be equal



Fig 2 Method to outline the calyces against the papilla and the renal pelvis along the medial margin of the kidney

A similar nomogram substitutes the height of the three lumbar vertebrae for body weight (Fig 4) This nomogram should be used in case the vertebral bodies are mal formed

Discussion and Conclusions

The nomograms are similar to that of EKLÖF & RINGERTZ but may in certain cases provide more information on the kidney size than estimation of the length of the kidney e g when there is a scarring of the lateral part of the kidney (reduction of the parenchyma) A hydronephrotic kidney also demands calculation of the projected area for assessing the kidney size which contradicts the report by MOELL (1956) who found no difference in renal area when measured planimetrically and from a standard formula Also it seems reasonable that the projected area determined planimetrically is a better parameter for assessing the renal size than length and width or the area from a standard formula in case of local reduction alternating with hypertrophy of the parenchyma of the affected kidney which at times is observed after recovery from pyelonephritis

However several inherent sources of error of the area method exist an important one being the slight increase in kidney size following the administration of the contrast medium (WOLPERT 1965) Also in some cases dilatation of the renal pelvis and calyces is observed on compression of the ureters The examination technique was therefore standardized the measurements were performed on the film exposed 10 min after injection of the contrast medium i e 5 min after application of ureteric compression

Several authors (HODSON et coll 1962 CURRARINO FRIEDENBERG et coll 1965 and STOLPE et coll) have reported that there is no difference in kidney size between boys and girls




Fig 3 Nomogram for the renal parenchymal area (in cm²) of any given kidney in standard deviations using the height of L1–L3 as reference

In the present investigation it was assumed that the projected areas of the right and left kidney are of equal size in spite of the wide variation in the rotation of the kidney about both axes which according to LUDIN (1967) and HEGEDUS (1972) makes it impossible to allow for foreshortening HEGEDUS found that the kidney is rotated around its transverse axis 0 to 24 with a mean of 12 on the right and 8 on the left side Similar results were reported by GRIFFITHS et coll (1974) Thus the foreshortening of the right kidney is greater than that of the left and according to MOELL (1961) the foreshortening reduces the length of the kidney by approximately 5 per cent Therefore measurement of the kidney length alone may in some instances be inaccurate The greater angle on the right may partly account for previous radiologic observations that this kidney is shorter than the left (HODSON MOELL 1961) The mean rotation around the longitudinal axis of the kidney to the horizontal was reported to be 43 (range 40 to 45) by GRIFFITHS et coll thus the rotation around this axis varies less than around the transverse one These authors concluded that the renal area was no better correlated to renal weight than the length in normal subjects




Fig. 4 Nomogram for the renal parenchymal area of any given kidney in standard deviations using body weight (in kg) as reference

The correlation was not improved when as KARN suggested the area occupied by the collecting system was subtracted However LUDIN in calculating the renal area from measurements of length and width found this to be better correlated with renal weight than length alone

For patients with abnormalities of the upper lumbar vertebrae it is proposed that the body weight be used as reference rather than the height of L1–L3 The appropriate nomogram (Fig 4) is based on unchanged focus object film distance

SUMMARY

A method for assessment of the kidney size in infants and children is described based on measurement of the renal parenchymal area determined planimetrically using for reference the height of the column of the upper three lumbar vertebrae or the body weight The kidney size is expressed in standard deviation in the appropriate nomograms

ZUSAMMENFASSUNG

Eine Methode zur Bestimmung der Nierengrosse von Sauglingen und Kindern wird beschrieben die sich auf die Messung der planimetrisch bestimmten Flache des Nierenparenchyms stutzt wobei als Referenz die Hohe der Wirbelsäule entsprechend den oberen drei Lumbalwirbeln oder das Korpergewicht verwendet wird Die Nierengrosse wird in Standardabweichung in entsprechenden Nomogrammen ausgedruckt

RESUME

Les auteurs décrivent une methode de mesure de la taille du rein chez les nourrissons et les enfants basée sur la mesure planimetrique de la surface du parenchyme renal en utilisant comme référence la hauteur de la colonne des trois premières vertebres lombaires ou le poids corporel La taille du rein est exprimee en deviation standard sur les nomogrammes appropries

REFERENCES

ANDERSEN M J F and MOGENSEN C E Relationship between renal size and function in normal subjects Acta radiol Diagnosis 14 (1973) 209

COPPOLETTA J M and WOLBACH S B Body length and organ weights of infants and children Amer J Path 9 (1963) 55

CURRARINO G Roentgenographic estimation of kidney size in normal individuals with emphasis on children Amer J Roentgenol 93 (1965) 464

EKLÖF O and RINGERTZ H Kidney size in children A method of assessment Acta radiol Diagnosis 17 (1976) 617

FRIEDENBERG M J BRUCE J WALZ A B MCALLISTER W H LOCKSMITH J P and GALLAGHER T L Roentgen size of normal kidneys Computer analysis of 1 286 cases Amer J Roentgenol 84 (1965) 1022

GRIFFITHS G J CARTWRIGHT G and MCLACHLAN M S F Estimation of renal size from radiographs is the effort worthwhile? Clin Radiol 26 (1974) 249

GUY E et MOUNIC M A propos des mesures des reins Ann Radiol 14 (1971) 13

HEGEDUS V Three dimensional estimation of renal shape and volume at angiography Acta radiol Diagnosis 12 (1972) 87

— and RAVNSKOV U Cortical volume in apparently normal kidneys Scand J Urol Nephrol 6 (1972) 159

HODSON C J Hypertension of renal origin *In* Modern trends in diagnostic radiology 3rd series Edited by McLaren Butterworth London 1960

— DAVIES Z and PRESCOD A Renal parenchymal radiographic measurement in infants and children Pediat Radiol 3 (1975) 16

— DREWE J A KARN M N and KING A Renal size in normal children A radiographic study during life Arch Dis Childh 35 (1962) 616

JOUVE P DENIZET D et FAGIANELLI J L A propos des applications de la planimetrie directe en radiologie Ann Radiol 14 (1971) 3

KARN M Radiographic measurements of kidney section area Ann hum Genet 25 (1962) 379

LEBOWITZ T HOPKINS T and COLODNY A H Measuring the kidneys Practical applications using a growth and hypertrophy chart Pediat Radiol 4 (1975) 37

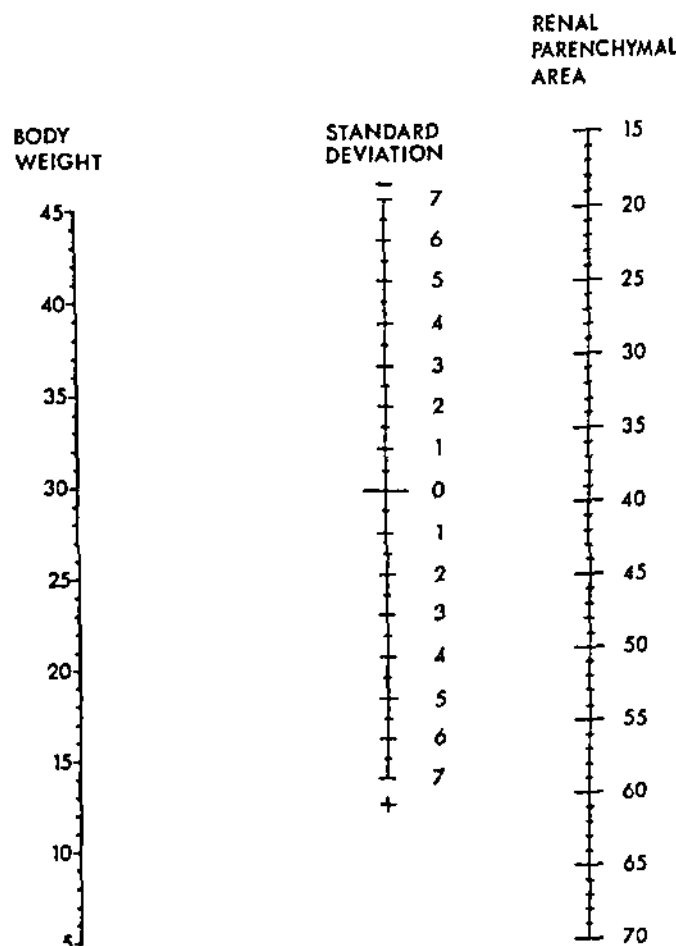


Fig 4 Nomogram for the renal parenchymal area of any given kidney in standard deviations using body weight (in kg) as reference

The correlation was not improved when as KARN suggested the area occupied by the collecting system was subtracted However LUDIN in calculating the renal area from measurements of length and width found this to be better correlated with renal weight than length alone

For patients with abnormalities of the upper lumbar vertebrae it is proposed that the body weight be used as reference rather than the height of L1–L3 The appropriate nomogram (Fig 4) is based on unchanged focus object film distance

SUMMARY

A method for assessment of the kidney size in infants and children is described based on measurement of the renal parenchymal area determined planimetrically using for reference the height of the column of the upper three lumbar vertebrae or the body weight The kidney size is expressed in standard deviation in the appropriate nomograms

FROM THE DEPARTMENT OF PEDIATRIC SURGERY (DIRECTOR L OKMIAN) AND THE SECTION OF PEDIATRIC RADIOLOGY (DIRECTOR W MORTENSSON) UNIVERSITY HOSPITAL S 221 85 LUND SWEDEN

RELATION OF LENGTH OF SUBMUCOUS SEGMENT OF THE URETER TO LESIONS OF THE RENAL PARENCHYMA IN CHILDREN

S Å KORNFALT W MORTENSSON and L STIGSSON

Urinary tract infection combined with vesico ureteral reflux is a common complaint in infants and children Although it may be self healing without apparent sequelae it sometimes produces marked injury to the renal parenchyma (HODSON & EDWARDS 1960 SMELLIE et coll 1964 SCOTT & STANSFELD 1968 HELIN et coll 1974) In the search for etiologic factors determining the future course of the condition much attention has been paid to the anatomy of the submucosal portion of the terminal ureter (GRUBER 1929 KJELLBERG et coll 1957 HUTCH 1961 STEPHENS & LENAGHAN 1962 DEBLED 1968 TANAGHO et coll 1965 TANAGHO & HUTCH 1965 TANAGHO et coll 1968 LYON et coll 1969 IRELAND & CASS 1972) A short or missing submucous ureteral segment often expressed indirectly in terms of the configuration and location of the ureteral orifice was found to be related to the occurrence and severity of vesico ureteral reflux (LYON et coll CASS & IRELAND 1972 POLITANO 1972 MORTENSSON & HELIN 1974)

This investigation aimed at determining whether a short submucous ureteral segment also means increased risk of injury to the renal parenchyma in children with urinary tract infection and vesico ureteral reflux

Material and Methods

The series comprised 59 infants and children with urinary tract infection who were operated upon by uni or bilateral uretero neostostomy because of reflux during a

Submitted for publication 29 June 1977

Table 1

Frequency and degree of vesico ureteral reflux related to length of submucous ureteral segment in 174 ureters in 89 patients

Length of submucous segment	Number of ureters			
	With reflux		Without reflux	Total
	Grade 2	Grade 3		
Normal	7	4	24	35
Short	23	11	17	51
Absent	31	57	—	88
Total	61	72	41	174

six year period terminating in 1976 without ureterocele neurogenic bladder disease or urethral obstruction Urography and micturition cysto urethrography were repeatedly performed in all patients Only patients whose latest urography was per formed at the most 12 months before surgery and whose latest micturition cysto urethrography was done at the most 3 months before operation were included In most cases the last preoperative examinations were carried out a few weeks before operation The age of the patients at operation ranged from 9 months to 13 years the median age being 5 years Prophylaxis with chemotherapy had been given con tinuously for 6 to 24 months before operation The reflux persisted despite success in eliminating the infection as indicated at repeat culture checks

The criteria for infection included presence of at least 10^5 microorganisms per ml urine at examination of a clean voided specimen which was cooled before delivery to the laboratory (BERGSTRÖM et coll 1972)

Destruction or deformation of papillae local scarring or *general reduction of* parenchyma present at urography were classified simply as parenchymal abnor malities The renal size index i e the *ratio of the longest axis of the kidney* to the distance from the upper border of the first to the lower border of the fourth lumbar vertebra measured on the a p film was used to express the degree of general paren chymal reduction and impaired growth of the kidney This index was not calculated for cases of single kidney hydronephrosis duplication of the renal pelvis or kidneys which could not be distinctly delineated at urography the last two reasons being the predominant ones

Micturition cysto-urethrography was performed with a standardized technique (MORTENSSON & HELIN) Reflux was defined as grade 1 when it involved the ureter only as grade 2 when the reflux reached the renal pelvis and as grade 3 when in addition the upper urinary tract became distended by the reflux

The length of the submucous segment was measured by probing following ex posure of the trigone at operation The segment was classified as normal short or

Table 2

Parenchymal abnormalities in 174 kidneys in relation to length of submucous segment of corresponding ureter

Length of submucous segment	Ves uret refl		No ves uret refl	
	Parench abnormalities		Parench abnormalities	
	Present	Absent	Present	Absent
Normal	5	6	0	24
Reflux grade 2	2	5		
Reflux grade 3	3	1		
Short	15	19	1	16
Reflux grade 2	6	17		
Reflux grade 3	9	2		
Absent	41	47		
Reflux grade 2	8	23		
Reflux grade 3	33	24		

Table 3

Parenchymal abnormalities in 174 kidneys correlated to presence and degree of vesico ureteral reflux

Degree of reflux	Parenchymal abnormalities	
	Present	Absent
No reflux	1	40
Reflux grade 2	16	45
Reflux grade 3	45	27

absent according to current concepts (HUTCH CUSSEN 1967) The minimum length of a normal segment was considered as being 3 mm in a one month old infant as 5 mm in a one year old and 8 mm in a 10 year old child The distribution of the material in regard to the length of the submucous ureteral segment and occurrence and degree of vesico ureteral reflux appears in Table 1

Quantitative differences were estimated by conventional t test for unpaired observations and qualitative differences by a chi square test including Yates correction All differences were considered significant when the probability was less than 0 05 that the distribution would occur in random fashion

Results

Vesico ureteral reflux became significantly more frequent and marked with decrease in length of the submucous ureteral segment (p<0 001 Table 1)

Table 4

Renal size index for 130 kidneys related to length of submucous ureteral segment and to presence and degree of vesico ureteral reflux Index was not calculated for kidneys with duplicated pelvis or with hydronephrosis single kidneys or kidneys which could not be distinctly delineated

Length of submucous segment	Renal size index					
	With reflux			Without reflux		
	Mean	1 SD	n*	Mean	1 SD	n*
Normal	94 3	17 8	7	96 5	6 8	22
Reflux grade 2	101 5	15 6	4			
Reflux grade 3	84 6	18 6	3			
Short	91 1	10 1	23	97 7	10 7	15
Reflux grade 2	92 5	9 4	15			
Reflux grade 3	88 5	8 4	8			
Absent	91 7	10 7	63			
Reflux grade 2	94 4	10 4	25			
Reflux grade 3	90 0	10 6	38			

Number of kidneys

Abnormalities of the renal parenchyma occurred with one exception only in kidneys with vesico ureteral reflux ($p < 0\ 001$) but were not related to the length of the sub mucous segment of the ureter (Table 2) However they were significantly more common in kidneys exposed to grade 3 than to grade 2 reflux ($p < 0\ 001$ Table 3)

Mean renal size index for kidneys with ureteral reflux was unrelated to the length of the submucous segment (Table 4) The index was lower for kidneys exposed to marked reflux than for those exposed to moderate reflux ($p < 0\ 05$ Table 5)

Discussion

Primary vesico-ureteral reflux is most often due to poor development of the muscular layers of the terminal ureter and the adjacent parts of the trigone (HUTCH STEPHENS & LENAGHAN TANAGHO et coll 1968) The ureter is insufficiently an chored to the weak trigone which results in lateral recession of the ureter with de formation of the ureteral orifice and shortening of the submucous segment DEBLED (1974) GREGORI & SCHULMAN (1974) and LIPSKY & EGGER (1974) considered that the shortening of the submucous segment was a consequence of or at least combined with defective muscular and collagen layers of the terminal ureter Surgery is neces sary to eliminate the reflux in many of these patients In others the submucous seg ment gains in length probably because the muscle layers mature and the child out grows the reflux (HUTCH STEPHENS & LENAGHAN CUSSEN MANLEY et coll 1976)

The length of the submucous segment is said to vary with the degree of filling of the bladder but the mechanism is apparently not clear IRELAND & CASS and MANLEY et coll stated that the length decreases at bladder distension POLITANO had the op-

Table 5

Renal size index for 93 kidneys exposed to vesico-ureteral reflux The kidneys are grouped according to degree of reflux

Grade of reflux	Renal size index		
	Mean	1 SD	n
Grade 2	94 7	10 7	44
Grade 3	89 4	10 6	49

* Number of kidneys

posite opinion In any case it is not certain that the length of the submucous segment as measured at operation accurately reflects its length on distension of the bladder Nevertheless HELIN et coll (1974) found good agreement between the length of the segment as measured at endoscopy with filled bladder and at operation provided the segment was short or absent on endoscopy If the segment was considered normal at endoscopy the length measured at surgery was found to vary from normal to zero Probably the latter measurements are the most valid ones

In a fourth of the cases the kidneys could not be distinctly delineated at urography and were therefore excluded from the calculation of the renal size index They were equally distributed among the groups in regard to the length of the submucous segment and the degree of reflux and presumably they should not have biased the results

The present investigation showed that both frequency and degree of renal parenchymal lesions were unrelated to the length of the submucous ureteral segment but related to the degree of the reflux However the shorter the submucous segment the more frequent were severe grades of vesico ureteral reflux

Previously overwhelming evidence of the deleterious effect of urinary tract infection and marked vesico ureteral reflux on the renal parenchyma has been reported (HODSON & EDWARDS SMELLIE et coll ROLLESTON et coll 1970 MORTENSSON & HELIN BABCOCK et coll 1976) In kidneys exposed to grade 3 reflux the glomerular filtration rate decreases substantially (APERIA et coll 1976) and the renal size closely reflects this parameter of renal function (WIKSTAD 1976)

The question whether sterile reflux may cause injury to the kidney is still a matter of controversy Observations exist which indicate that a sterile reflux of grade 3 may give rise to impaired renal function (HUTCH & SMITH 1969 APERIA et coll) some animal experiments also support this view (HODSON 1974 HELIN et coll 1975 MORGAN et coll 1976) However the validity of these findings could not be verified by STEPHENS & LENAGHAN or in animal experiments by KING & IDRISS (1967) and NEWMAN et coll (1974) The degree of reflux is usually not mentioned in these reports Experience obtained in the present series and previously (MORTENSSON & HELIN) indicate that the urographic findings are unchanged at least during a 2 year

period provided the patients received continuous chemotherapy Only a few isolated cases presented evidence of slight progress of the parenchymal lesions The present cases may be considered free from infection of the urinary tract during the period of treatment as estimated from monthly urine cultures and absence of symptoms This may have influenced the development of parenchymal lesions

The practical importance of the results is that the degree of vesico-ureteral reflux is more crucial than the length of the submucous ureteral segment in predicting the eventual outcome regarding renal function in children with recurrent urinary tract infection and vesico-ureteral reflux

SUMMARY

The possible relationship between the length of the submucous ureteral segment and frequency and degree of renal parenchymal injury was analysed in children with urinary tract infection and vesico ureteral reflux If the grade of reflux was disregarded no relation was found to exist between these parameters

ZUSAMMENFASSUNG

Die mögliche Relation zwischen der Lange des submukosen Ureteral Segments und die Haufigkeit und der Umfang des renalen parenchymatosen Schadens bei Kindern mit Infektion der Harnwege und vesico-ureteralem Reflux wird analysiert Falls der Grad des Refluxes nicht beachtet wird findet sich keine Korrelation zwischen diesen Parametern

RESUME

Les auteurs ont etudié sur des enfants ayant une infection des voies urinaires et un reflux vesico-ureteral la relation possible entre la longueur du segment ureteral sous muqueux et la frequence et le degre de l atteinte du parenchyme renal Si on ne tient pas compte du degré de reflux, on ne trouve pas de relation entre ces parametres

REFERENCES

Aperia A., Broberger O., Ericsson N-O and Wikstad I Effect of vesico-ureteral reflux on renal function in children with recurrent urinary tract infections Kidney Int 9 (1976) 418

Babcock J Keats G and King L Renal changes after an uncomplicated anti reflux operation J Urol 115 (1976) 720

Bergström T., Larsson H Lincoln K. and Winberg J Studies on urinary tract infections in infancy and childhood XII Eighty consecutive patients with neonatal infection J Pediat 80 (1972) 858

Cass A and Ireland G Significance of ureteral submucosal tunnels length orifice configuration and position in vesico-ureteral reflux J Urol 107 (1972) 963

Cussen L. Dimensions of the normal ureter in infancy and childhood Invest Urol 5 (1967) 164

DEBLED G La fonction normale et pathologique de la musculature urétérotrigonal Acta urolog belg 36 (1968) 366
— Die Ätiologie des primaren vesiko-ureteralen Refluxes *In* Der vesiko-uretero-renale Reflux p 10 Edited by P Strohmenger G Thieme Verlag Stuttgart 1974
GREGORI W und SCHULMAN C Die Pathologie des primaren vesiko-ureteralen Refluxes *In* Der vesiko-uretero-renale Reflux p 15 Edited by P Strohmenger G Thieme Verlag Stuttgart 1974
GRUBER CH A comparative study of the intra vesical ureters (uretero-vesical valves) in man and in experimental animals J Urol 21 (1929) 567
HELIN I OKMIAN L and OLIN T Renal blood flow and function in vesico-ureteric reflux An experimental study in the pig Scand J Urol Nephrol (1975) Suppl No 28 p 71
— — KORNFALT S Å and MORTENSSON W Vesico-ureteric reflux in children I A therapeutical approach and a prospective study Z Kinderchir 15 (1974) 299
HODSON C Vesico-uretoric reflux and renal scarring with and without infection Kidney Int 5 (1974) 308
— and EDWARDS D Chronic pyelonephritis and vesico-ureteric reflux Clin Radiol 11 (1960) 219
HUTCH J Theory of maturation of the intra vesical ureter J Urol 86 (1961) 534
— and SMITH D Sterile reflux Report of 24 cases Urol int 24 (1969) 460
IRELAND G and CASS A The clinical measurements of ureteral submucous tunnel J Urol 107 (1972) 564
KING L and IDRISS F The effect of vesico-ureteral reflux on renal function in dogs Invest Urol 4 (1967) 419
KJELLBERG S ERICSSON N and RUDHE U The lower urinary tract in childhood Some correlated clinical and roentgenologic observations p 187 Almqvist & Wiksell Stockholm 1957
LIPSKY H und EGGER G Über den histologischen Aufbau des distalen Harnleiterabschnittes bei Kindern ohne und mit vesicoureteralem Reflux Urologe 13 (1974) 151
LYON R MARSHALL S and TANAGHO E The ureteral orifice its configuration and competency J Urol 102 (1969) 504
MANLEY CH NEUMAN N and MCLISTER W Prognosis for resolution of moderate primary reflux in girls J Urol 115 (1976) 307
MORGAN M ASSCHER A and MOFFAT D The role of a vesico ureteric (V U) reflux in the pathogenesis of kidney scan in the rat Nephron 17 (1976) 8
MORTENSSON W and HELIN I Vesico-ureteric reflux in children II Roentgenologic examination Z Kinderchir 15 (1974) 444
NEWMAN L SCHULMAN C and BUCY J Vesicoureteral reflux in the dog A histologic and radiologic evaluation Invest Urol 11 (1974) 498
POLITANO V Ureterovesical junction J Urol 107 (1972) 239
ROLLESTON G SHANNON F and UTLEY W Relationship of infantile vesicoureteric reflux to renal damage Brit med J 1 (1970) 460
SCOTT J and STANSFELD J Ureteric reflux and kidney scarring in children Arch Dis Childh 43 (1968) 468
SMELLIE J HODSON C EDWARD D and NORMAND J Clinical and radiological features of urinary infection in childhood Brit med J 2 (1964) 1222
STEPHENS F and LENAGHAN D The anatomical basis and dynamics of vesicoureteral reflux J Urol 87 (1962) 669
TANAGHO E and HUTCH J Primary reflux J Urol 93 (1965) 158
— — MEYERS F and RAMBO O Primary vesicoureteral reflux Experimental studies of its etiology J Urol 93 (1965) 165

— MEYERS F and SMITH D The trigone anatomical and physiological considerations I In relation to the uretero vesical junction J Urol 100 (1968) 623
WIKSTAD I Correlation between the size of the renal parenchyma and the renal function Ann Radiol 19 (1976) 140

FROM THE DEPARTMENT OF PEDIATRIC RADIOLOGY KAROLINSKA SJUKHUSET S 104 01 STOCKHOLM SWEDEN THE DEPARTMENT OF PEDIATRIC RADIOLOGY ÖSTRA SJUKHUSET S 416 85 GOTHENBURG SWEDEN THE DEPARTMENT OF PEDIATRIC RADIOLOGY UNIVERSITY HOSPITAL SF-00290 HELSINKI FINLAND AND DEPARTMENT OF PEDIATRIC RADIOLOGY RIKSHOSPITALET OSLO NORWAY

TUMOURS OF THE LOWER URINARY TRACT IN CHILDREN

O EKLÖF B BRUN I CLAESSON P E HEIKEL and G STAKE

Neoplasms of the lower urinary tract in children are rare The majority of the tumours are malignant Surveys of the radiologic aspects are few and as a rule based on case reports or small consecutive series (MCDONALD 1970 TUCKER & PERSKY 1970) Most descriptions of the radiologic features are available in oncologic and urologic publications (TEFFT et coll 1973 CASTELLANOS et coll 1975) whereas the differential diagnosis has received only scant attention A re evaluation of symptoms and signs radiologic aspects and differential diagnosis on the basis of a large series was therefore performed and the results are new reported

Material

The material consisted of 37 cases compiled from Scandinavia and Finland during the past 20 years and 3 cases from Zurich Switzerland (28 boys 12 girls mean age at diagnosis 31 5 months median age 21 months) Microscopy revealed 33 cases with embryonic rhabdomyosarcoma 5 with polyp and one each of papilloma and haemangioma thus 33 malignant and 7 benign tumours

Symptoms and Signs The main symptoms and signs one or more prevalent in each case are listed in the Table

Submitted for publication 31 March 1977

Table

Symptoms and signs

Palpable tumour	11
Urinary retention	11
Urinary incontinence	3
Urinary infection	8
Haematuria	21
Dysuria	10
Abdominal pain	3
Constitutional symptoms	6
Incidental finding	1

Patients with embryonic sarcoma usually had a rather short duration of com plaints 17 patients had a history of less than 4 weeks 8 of them less than 1 week The most frequent clinical finding in this group was urinary retention (7 boys) Four patients presented with easily bleeding tumour masses extruding from the vagina 3 had haematuria urinary infection or both and 3 increasing abdominal distension and a palpable mass

Another 9 patients with the same diagnosis had a history of 1 to 3 months The symptoms were essentially the same as in the previous group An initial delay of diagnosis could be ascribed to the attitude of the parents diagnostic errors symptomatic treatment and idle clinical work up One girl presenting with tumour tissue extruding from the vagina initially had a period of conservative treatment In two other cases the initial biopsy specimens were inadequate for diagnosis In the remain ing 7 cases of embryonic sarcoma insidious onset of the disease and insufficient at tention to the clinical symptomatology explain why the final diagnosis was post poned more than 3 months

In 6 patients with benign tumours the initial symptoms were either minor and not evaluated correctly or a discrepancy between radiologic and cystoscopic findings resulted in postponement of treatment In a girl with a meningo myelocele a polyp of the posterior urethra was an incidental finding

Radiology Films from 34 urographies and 33 voiding cysto-urethrographies were reviewed In 10 cases simultaneous demonstration of the bladder and the rectum aided in assessment of the size of the tumour and its relationship to adjacent organs Pelvic angiography was carried out in one patient with a tumour extensively in filtrating the extravesical space and in the patient with haemangioma of the bladder The angiography was of little significance for the diagnosis

On conventional abdominal radiography a soft tissue mass was occasionally demonstrated in the lesser pelvis but only on urography was it possible to differentiate between a distended bladder and a tumour Tumour calcification or involvement of the bony pelvis were not observed



Fig 1



Fig 2

Fig 1 A 3 year old girl Embryonic rhabdomyosarcoma Large intravesical tumour Intact upper urinary tract Increasing dysuria finally stranguria

Fig 2 A 2 5 year-old boy Micturition urethrocystography Embryonic rhabdomyosarcoma growing infiltratively at base of bladder involving bladder neck and posterior urethra Obstruction of bladder outlet at voiding

In 3 patients with embryonic rhabdomyosarcoma an expanding lesion of the retroperitoneal paravertebral region was demonstrated similar to that observed in neuroblastoma (EKLÖF & GOODING 1967) Congenital tibial pseudarthrosis was present in two cases of rhabdomyosarcoma whether this was only coincidental or represents a syndrome is not known

The radiologic appearances of embryonic sarcomas are mainly determined by the mode of growth size and site of the tumour In 6 cases the capacity of the bladder





Fig 3 Fig 4

Fig 3 A 2 year old boy Slight elevation of bladder by disc like embryonic rhabdomyosarcoma at base of bladder Difficult bladder emptying resulting within one week in retention

Fig 4 A 9 month-old girl Large rounded embryonic rhabdomyosarcoma in posterior part of bladder Bleeding tumour mass protruding from the vagina

was markedly reduced by intruding grape like tumour masses (Fig 1) Most patients had an ordinary excretion at urography and only exceptionally was the kidney function abolished The function was normal even in cases with advanced tumour involvement of the trigone The most common upper urinary tract abnormality was a slight to moderate usually unilateral dilatation of the pelvis and the ureter

However the great majority of patients with rhabdomyosarcoma 13 cases presented with a localized tumour involving the base of the bladder around the urethra or close to it in one single case tumour growth was limited to the fundus of the bladder The neoplasm almost equally often extended into the anterior and posterior aspects of the bladder Some tumours strongly tended to obstruct the bladder outflow (Fig 2) In other patients the cauliflower like neoplasm changed position on voiding moving into the bladder neck or posterior urethra Occasionally the tumour was pedunculated

In 5 cases the tumour had a disc like shape growing partially extravesically at the base of the bladder (Fig 3) The bladder was slightly elevated and in some cases the urethra was stretched from displacement of the bladder

In 4 patients a well demarcated filling defect was present in the bladder (Fig 4) It remotely resembled an ectopic ureterocele However there was no deformity or displacement of the ipsilateral orthotopic collecting system which occurs in approximately 90 per cent of cases with ectopic ureterocele (EKLÖF & MAKINEN 1974)

In 5 cases the tumour grew mainly extravesically displacing and deforming the bladder (Fig 5) In 4 of these most of the tumour was confined to the lesser pelvis In the fifth patient the tumour originated from the region of the urachus of the bladder depressing the bladder and extending into the pelvis Whether the tumour was infiltrating the bladder wall could not be established

The appearance of the polyps was rather uniform All of them were round and




Fig 5 A 1 year-old boy Embryonic rhabdomyosarcoma Urography a) A p view with compression and displacement of bladder by left sided tumour in lesser pelvis b) Lateral view anterior displacement of ureters by paravertebral extension of tumour Rapidly increasing abdominal distension palpable abdominal mass and swelling of left leg

well demarcated On urography the polyp usually was located close to the outlet of the bladder and occasionally in the posterior urethra underneath the bladder neck which was partially open throughout the examination All 5 polyps were pedunculated the stalk being outlined in 4 During voiding the polyps were displaced into the urethra obstructing the bladder outflow (Figs 6 15 d)

A papilloma present in one single patient had a urographic appearance similar to that of an ectopic ureterocele (Fig 7)

The single case of haemangioma extended into the bladder and revealed itself by multiple phleboliths in the lesser pelvis The tumour indented the bladder wall in several places (Fig 8)

Discussion

Tumours of the lower urinary tract in children preferably afflict males and usually become manifest before the fifth year of life (TEFFT et coll WILLIAMS 1974) This is in conformity with the present series



Fig 3



Fig 4

Fig 3 A 2 year-old boy Slight elevation of bladder by disc like embryonic rhabdomyosarcoma at base of bladder Difficult bladder emptying resulting within one week in retention

Fig 4 A 9 month-old girl Large rounded embryonic rhabdomyosarcoma in posterior part of bladder Bleeding tumour mass protruding from the vagina

was markedly reduced by intruding grape like tumour masses (Fig 1) Most patients had an ordinary excretion at urography and only exceptionally was the kidney function abolished The function was normal even in cases with advanced tumour involvement of the trigone The most common upper urinary tract abnormality was a slight to moderate usually unilateral dilatation of the pelvis and the ureter

However the great majority of patients with rhabdomyosarcoma 13 cases presented with a localized tumour involving the base of the bladder around the urethra or close to it in one single case tumour growth was limited to the fundus of the bladder The neoplasm almost equally often extended into the anterior and posterior aspects of the bladder Some tumours strongly tended to obstruct the bladder outflow (Fig 2) In other patients the cauliflower like neoplasm changed position on voiding moving into the bladder neck or posterior urethra Occasionally the tumour was pedunculated

In 5 cases the tumour had a disc like shape growing partially extravesically at the base of the bladder (Fig 3) The bladder was slightly elevated and in some cases the urethra was stretched from displacement of the bladder

In 4 patients a well demarcated filling defect was present in the bladder (Fig 4) It remotely resembled an ectopic ureterocele However there was no deformity or displacement of the ipsilateral orthotopic collecting system which occurs in approximately 90 per cent of cases with ectopic ureterocele (EKLÖF & MAKINEN 1974)

In 5 cases the tumour grew mainly extravesically displacing and deforming the bladder (Fig 5) In 4 of these most of the tumour was confined to the lesser pelvis In the fifth patient the tumour originated from the region of the urachus of the bladder depressing the bladder and extending into the pelvis Whether the tumour was infiltrating the bladder wall could not be established

The appearance of the polyps was rather uniform All of them were round and



Fig 7 a) An 8 year-old girl Papilloma close to right ureteral orifice fairly smooth surface Normal upper urinary tract A 4 weeks history of terminal haematuria b) A 3 year-old girl Ectopic ureterocele reminiscent of papilloma Reduplicated right upper urinary tract Recurrent urinary infections

(Fig 9) Thus urography should invariably be supplemented with micturition cystourethrography in all patients with previously unexplained complaints from the urinary tract This is the only procedure that permits detailed evaluation of urethral anomalies which frequently occur in infancy

Examination of the colon may be rewarding for a more precise outlining of any extravesical extension of the tumour (Figs 10 b 14 b)

In the 2 cases examined by angiography the results were unrewarding A final position in regard to the potentials of this procedure should await more extensive experience Ultrasound technique and computer tomography have not been used in the present series

The analysis of the radiologic aspects revealed an unexpected heterogeneity of finding adding to the complexity of differential diagnosis

In cases presenting with a pelvic soft tissue mass containing lime deposits teratoma is the likely diagnosis As a rule the tumour is of ovarian origin but may occasionally be sacrococcygeal (EKLOF 1965) Recently a neuroblastoma containing discrete calcification was observed in the lesser pelvis of a girl infant It derived from the distal part of the sympathetic chain

None of the present tumours involved the bony pelvis Involvement of bone would rather indicate an inflammatory process a primary malignancy or tumour metastases

No comprehensive nalysis of the radiologic findings in tumours of the lower urinary tract in infants and children h been found Comments on rhabdomyosarcoma are scant or equivocal (MCDONALD TUCKER & PERSKY WILLIAMS) GHAZALI even claims that he diagnosis is a clinical matter which only needs to be con



Fig 8



Fig 9

Fig 8 A 15 year-old girl Haemangioma with infiltration of the wall of the bladder Haem angioma of the vulva and left leg as well Numerous phleboliths in the bladder region Intramural and extravesical growth with multiple areas of indentation in the bladder Gross haematuria

Fig 9 A 6-year-old boy Micturition urethrocystography Localized cystitis at the urachus region of the bladder resembling a disc like tumour not visible at conventional urography Recurrent urinary infections and episodes of obscure abdominal pain

firmed by endoscopic biopsy However certain forms of embryonic sarcoma may with a reasonable degree of confidence be diagnosed by radiologic means alone This is particularly true in cases of extensive multilobular intravesical tumour growth (Fig 1) Tumours infiltrating the bladder wall causing obstruction to the bladder outflow form another characteristic group (Fig 2) Large multilobular intrapelvic tumours elevating and protruding into the bladder by infiltration of the wall is a third form which has an almost pathognomonic appearance (Fig 10) The diagnostic difficulties are more evident with circumscribed lesions Local or general thickening of the bladder wall reduced bladder capacity irregular swollen mucosa and elevation of the base of the bladder are all features met with in embryonic




Fig 10 A 1 year-old girl Embryonic rhabdomyosarcoma a) Urography Intact upper urinary tract Lateral displacement of distal ureters b) Cystography Elevation and anterior displacement of bladder Multilobular tumour at bladder outlet Contrast medium injected intraperitoneally outlines upper border of the tumour Barium contrast in rectum which is compressed Tumour protruding from vagina

sarcoma (Fig 11 a) However surgery trauma inflammatory reaction (Fig 12 a) irradiation and chemotherapy (Fig 12 b) and even diseases primarily involving quite different systems of organs may display essentially identical radiologic appearances (Fig 11 b) Involvement of the fundus of the bladder as a rule indicates an inflammatory or otherwise benign lesion (Figs 9 13) Fortunately close analysis of the case history often will establish a reasonably safe diagnosis The differentiation between cystitis and a malignant tumour is difficult (HARRIS et coll 1974 DUCKETT & OGLETREE 1975 GRUNEBAUM & VARSANO 1976) Occasionally benign subepithelial bleeding must be thought of (THOMPSON & MCALISTER 1975) (Fig 13) Cystoscopy and biopsy are mandatory procedures in order to establish the definitive diagnosis

Tumours growing mainly extravesically may offer special diagnostic difficulties Deformation and displacement of the bladder and the distal parts of the ureters occur in embryonic sarcoma and in several neoplastic disorders primarily unrelated to the lower urinary tract Actually the same appearance was present in 2 recent cases of huge pelvic abscess of unknown origin (Figs 5 14) Other benign diagnostic alternatives are urachus cyst hydrometrocolpos and retroperitoneal expansive lesions of variable etiology (TUCKER & PERSKY)

A small amount of barium contrast aids in the demonstration of the spatial relationship of the tumour to the recto-sigmoid colon and assessment of the posterior border of a pelvic mass (Figs 10 14) Retrorectal tumour growth or growth around the



a



b

Fig 11 a) A 21 month old boy Embryonic rhabdomyosarcoma Soft tissue mass elevating and bulging into bladder Normal *upper urinary tract Episodes of painless* haematuria b) A 5 year old boy Epidermolysis bullosa Moderate dilatation of upper urinary tract Reduced bladder capacity irregular thickened bladder wall with swollen mucosa Haematuria and painful micturition

rectum was observed in several cases of lymphosarcoma and sacrococcygeal teratoma This is in contrast to lower urinary tumours and the majority of neoplasms of other origin which on encroaching upon the lesser pelvis tend to spread between the bladder and the rectum

Benign tumours of the lower urinary tract are extremely rare the solitary polyp being the most common In 4 of the present cases the tumour originated in the area of the verumontanum (Fig 15 d) in one case from the anterior aspect of the posterior urethra (Fig 6) The tumour which usually is pedunculated may change position On urography it will appear as a rounded well defined filling defect at the bladder outlet During voiding the polyp will be displaced with the stream down into the posterior urethra causing a more or less marked transient obstruction (WILLIAMS & ABRASSIAN 1966 DOWNS 1970)

Essentially similar radiologic appearances are not uncommon in ectopic ureterocele (Figs 7 b 15 a) A characteristic associated abnormality of the upper urinary tract

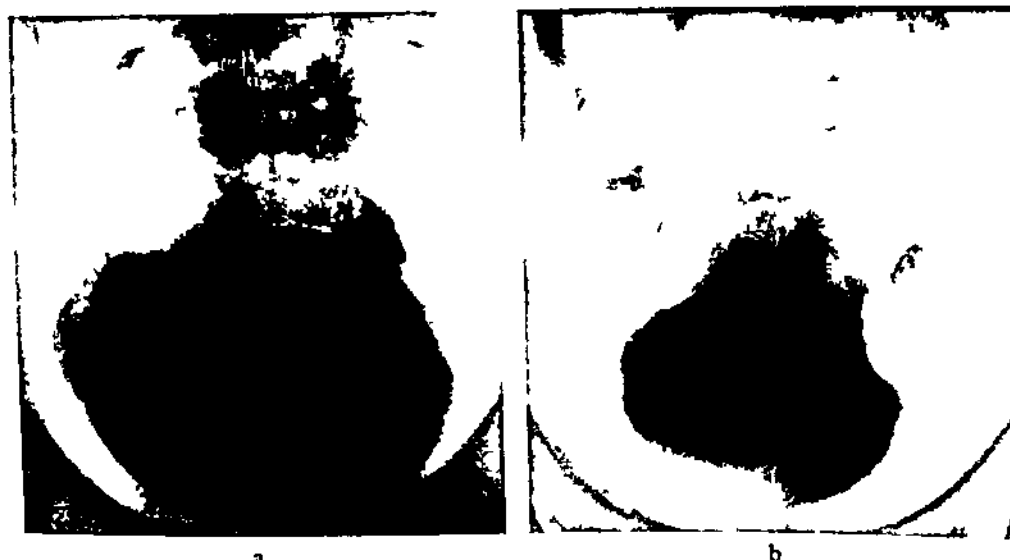


Fig 12 An 8 year-old boy Pelvic abscess secondary to appendicitis Mucosal indentations in the bladder fundus Dysuria and microscopic haematuria b) An 8 year-old girl Malignant teratoma of right ovary Slight dilatation of right ureter and collecting system Reduced bladder capacity with mucosal indentation of fundus due to reaction to cytostatic drug (Sendoxan)



Fig 13 A 10-year-old girl with Henoch-Schonlein purpura Submucosal haematoma Painless haematuria a) Irregular areas of narrowing in the upper part of both ureters b) Asymmetry of bladder In the bladder fundus markedly swollen irregular mucosa One week later normal appearance

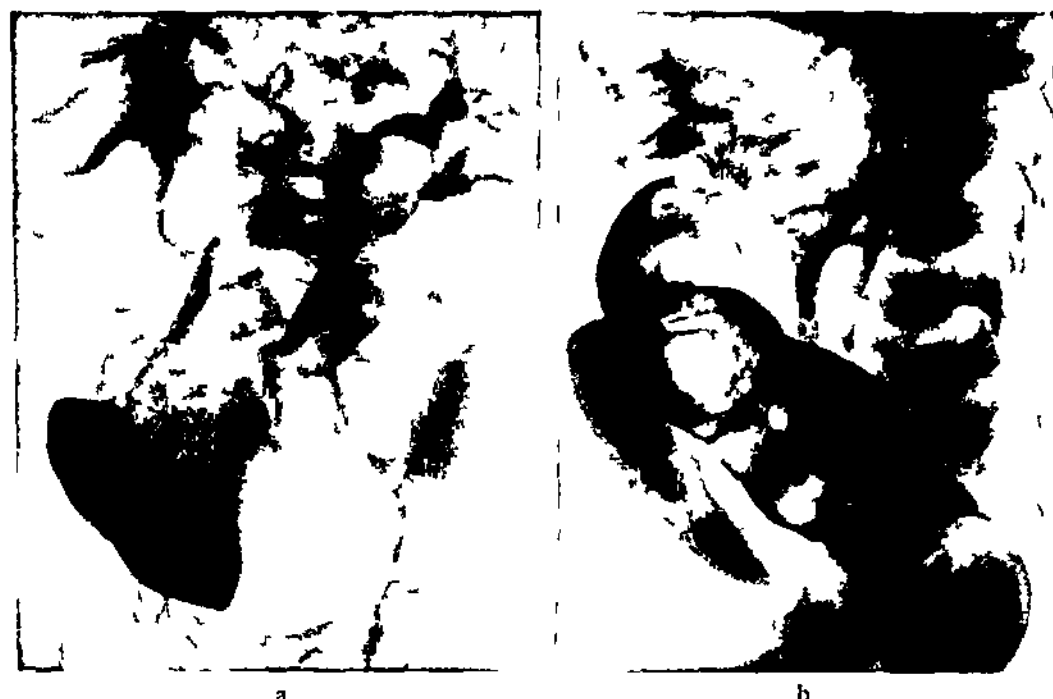


Fig 14 A 1 year-old girl Abscess in small pelvis a) Ureters displaced anteriorly and to the right Bladder compressed and displaced to the right and anteriorly Normal upper urinary tract b) Lateral view with barium contrast in rectum Anterior displacement and compression of elevated bladder Rapidly increasing distension of lower abdomen Palpable tumour and swelling of left leg No history of infection

usually will provide the diagnosis Cystoscopy and possibly biopsy may prove necessary in atypical cases A vesical foreign body changing position during examination a non-calcified concretion in the bladder and blood clots may all appear as contrast defects and furnish diagnostic alternatives (TUCKER & PERSKY GRÜNEBAUM & VARSANO) Malignant tumours tend to be multilobular (Fig 15 b) but may occasionally be erroneously considered to be polyps on microscopy as well as radiologically The only case of epidermolysis bullosa (Fig 15 c) developed permanent occlusion of the urethra an evolution so far not recorded in tumours of the lower urinary tract

Soft tissue masses protruding from the vagina should suggest embryonic sarcoma In 2 of 9 girls this was the only clinical finding leading to detection of the tumour Occasionally an ectopic ureterocele may temporarily or permanently, present as a mass appearing at the external urinary meatus In the male neither benign nor malignant tumours not even a ureterocele will ever protrude beyond the membranous urethra

Papillomas are frequently considered to be grade I carcinoma of the bladder (JAVADPOUR & MOSTOFI 1969 RAY et coll 1973 CASTELLANOS et coll REFSUM & REFSUM 1975) They appear as more or less irregular filling defects in the bladder



Fig 15 Tumours and tumour like masses obstructing bladder outflow a) Ectopic ureterocele in a boy with urinary infection b) Embryonic rhabdomyosarcoma in boy with painless haematuria and urinary infection c) Swollen mucosal pseudopolyp in epidermolysis bullosa d) Urethral polyp in patient with recurrent urinary tract infections

The only case in the present series had a fairly smooth surface resembling a ureterocele (Fig 7 a) However gross haematuria without pain made the latter diagnosis most unlikely

Haemangioma of the bladder is another benign tumour observed in children It has been reported in some 30 children and adults Gross haematuria is invariably present In approximately one third of all patients with haemangioma the lesions are multiple affecting several organs (HENDRY & VINNICOMBE 1971 RAY et coll) In patients with widespread lesions solitary or multiple indentations of the bladder wall are almost diagnostic for haemangioma However as an isolated lesion the diagnostic significance of this alteration is uncertain Phleboliths in a haemangioma of the bladder have not been reported previously They are characteristic of haemangioma of the trunk and extremities and are diagnostic also in patients with a tumour of the bladder and haematuria

In the literature a variety of other tumours involving the lower urinary tract are briefly discussed (MUTCHLER & GORDER 1972 WILLIAMS) neurofibromatosis being the most frequent (CARLSON & WILKINSON 1972 DANEMAN & GRATTAN SMITH 1976)

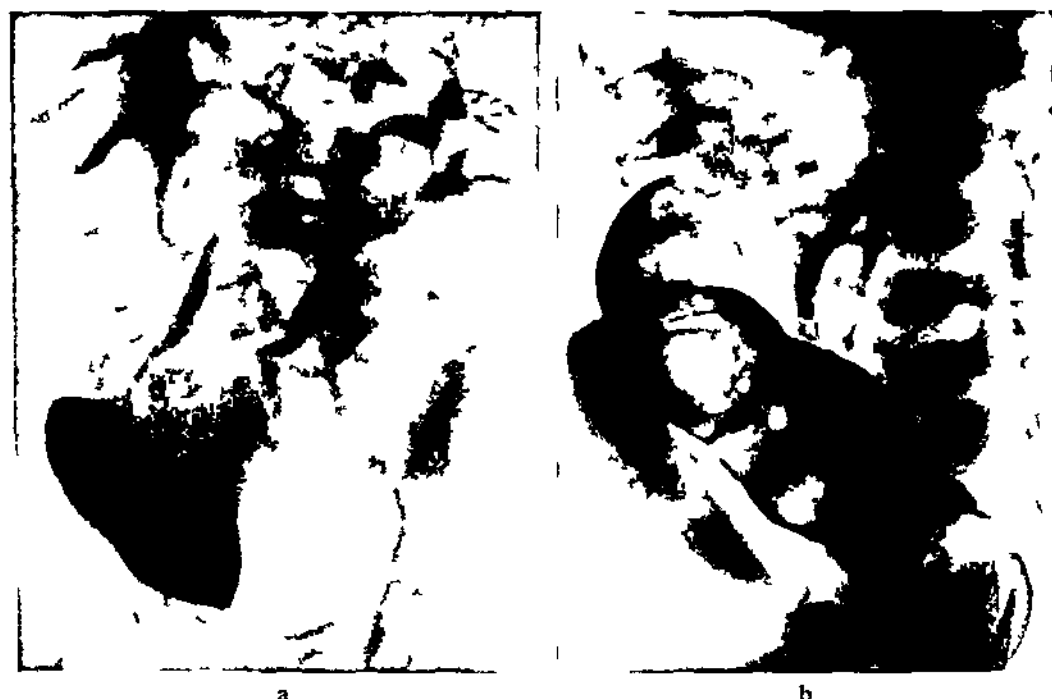


Fig 14 A 1 year-old girl Abscess in small pelvis a) Ureters displaced anteriorly and to the right Bladder compressed and displaced to the right and anteriorly Normal upper urinary tract b) Lateral view with barium contrast in rectum Anterior displacement and compression of elevated bladder Rapidly increasing distension of lower abdomen Palpable tumour and swelling of left leg No history of infection

usually will provide the diagnosis Cystoscopy and possibly biopsy may prove necessary in atypical cases A vesical foreign body changing position during examination a non calcified concretion in the bladder and blood clots may all appear as contrast defects and furnish diagnostic alternatives (TUCKER & PERSKY GRÜNEBAUM & VARSANO) Malignant tumours tend to be multilobular (Fig 15 b) but may occasionally be erroneously considered to be polyps on microscopy as well as radiologically The only case of epidermolysis bullosa (Fig 15 c) developed permanent occlusion of the urethra an evolution so far not recorded in tumours of the lower urinary tract

Soft tissue masses protruding from the vagina should suggest embryonic sarcoma In 2 of 9 girls this was the only clinical finding leading to detection of the tumour Occasionally an ectopic ureterocele may temporarily or permanently present as a mass appearing at the external urinary meatus In the male neither benign nor malignant tumours not even a ureterocele will ever protrude beyond the membranous urethra

Papillomas are frequently considered to be grade I carcinoma of the bladder (JAVADPOUR & MOSTOFI 1969 RAY et coll 1973 CASTELLANOS et coll REFSUM & REFSUM 1975) They appear as more or less irregular filling defects in the bladder

GHAZALI S Embryonic rhabdomyosarcoma of the urogenital tract Brit J Surg. 60 (1973), 124
GRUNEBAUM M and VARSANO I Multiple bladder filling defects in children with cystitis Pediat Radiol 4 (1976) 93
HARRIS V J., JAVADPOUR N and FIZZOTTI G Cystitis cystica masquerading as a bladder tumor Amer J Roentgenol 120 (1974) 410
HENDRY W F and VINNICOMBE J Haemangioma of bladder in children and young adults Brit J Urol 43 (1971) 309
JAVADPOUR N and MOSTOFI F K Primary epithelial tumors of the bladder in the first two decades of life J Urol 101 (1969) 706
MCDONALD P Genito-urinary tumours *In* Progress in Pediatric Radiology vol 3 p 298 Edited by H Kauffmann S Karger Basel Munchen, Paris, New York 1970
MUTCHLER JR R W and GORDER J L Leiomyoma of the bladder in a child Brit J Radiol 45 (1972) 538
RAY B GRABSTALD H., EXELBY P R and WHITMORE W F Bladder tumors in children Urology 2 (1973) 426
REFSUM JR S and REFSUM S B Bladder papilloma in a child Case report Scand. J Urol Nephrol 9 (1975) 285
TEFFT M JAFFE N and PAED D Sarcoma of the bladder and prostate in children. Rationale for the role of radiation therapy based on a review of the literature and a report of four teen additional patients Cancer 32 (1973) 1161
TUCKER A S and PERSKY L Cystography in childhood Tumors and pseudotumors. Amer J Roentgenol 109 (1970) 390
THOMPSON J S and MCALISTER W H Subepithelial hemorrhage in the renal pelvis and ureter simulating pyeloureteritis cystica Pediat Radiol 3 (1975) 156
WILLIAMS D I Urology of childhood *In* Encyclopaedia of urology vol XV p 309 Springer Verlag Berlin Heidelberg, New York 1974
— and ABRASSIAN A Solitary pedunculated polyp of the posterior urethra in children J Urol 96 (1966) 483
— and SCHISTAD G Lower urinary tract tumours in children Brit J Urol 36 (1964) 51

FROM THE DEPARTMENTS OF PEDIATRIC RADIOLOGY (DIRECTOR K EKENGREN) AND PEDIATRICS (DIRECTOR PROF R ZETTERSTROM) ST GÖRANS SJUKHUS S 112 81 STOCKHOLM SWEDEN

RELATIONSHIP BETWEEN AREA AND FUNCTION OF THE KIDNEY IN WELL DEFINED CHILDHOOD NEPHROPATHIES

A APERIA O BROBERGER K EKENGREN and I WIKSTAD

Urography not only depicts the gross morphology of the kidney but to some extent also gives information on its function The relationship between the morphologic appearances and the function as reflected by urography may vary in different diseases The validity of the information on the renal function in some diseases was therefore determined by comparing the functioning renal parenchyma with the glomerular filtration rate

Material

The material was divided into 4 groups

Group 1 consisted of 6 healthy adults kidney donors or volunteers 2 women and 4 men 18 to 34 years old

Group 2 consisted of 25 patients 24 females and 1 male with recurrent urinary tract infection and with or without vesico ureteral reflux uni or bilaterally The reflux was divided into 3 grades Grade I represented reflux into the ureter not reaching the pelvis grade II reflux into the pelvis without dilatation and grade III such reflux with dilatation The ages ranged from 3 to 16 years The urography was

Submitted for publication 25 May 1977



Fig 1 a) Reduction of the parenchyma Reflux grade III b) Shaded area is the planimetrically measured area

considered normal in 4 patients in 21 pyelonephritic scarring was demonstrated in one or both kidneys The degree of renal scarring generally correlated well with the degree of reflux

Group 3 consisted of 10 patients with obstructive or postobstructive hydronephrosis 4 girls and 6 boys from 3 to 17 years old Four had hydronephrosis with obstruction and 5 had hydronephrosis remaining after the obstruction had been removed One patient a girl was examined both preoperatively with obstruction and postoperatively when no obstruction remained

Group 4 consisted of 7 patients with glomerular disease 3 girls and 4 boys 5 to 13 years old all with macroscopic haematuria Renal biopsy was performed in all patients and confirmed the diagnosis of acute Henoch Schonlein or IgA IgG glomerulonephritis

Urography and determination of the renal function were performed in all patients in addition micturition cystography was carried out in group 2 The time interval between urography and renal function was generally only a few days

Methods

Urography

The tandard technique was used with a p and oblique projections In addition a lateral film of the kidney was exposed in those cases in which the volume was determined The contrast medium (Urografin 60°) in a dosage of 0 5 to 1 ml/kg body weight was injected intravenously The film focus distance was 100 cm

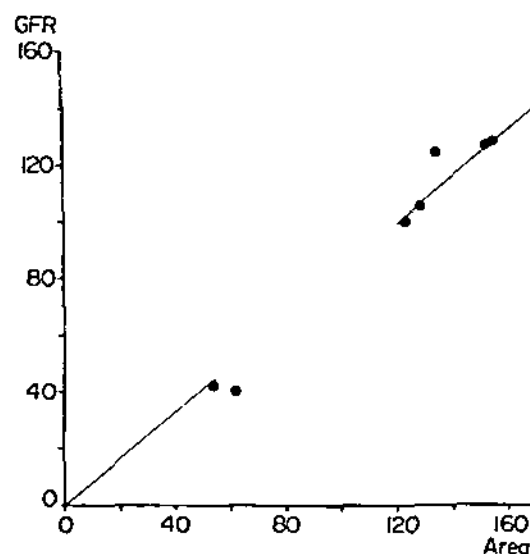


Fig 2

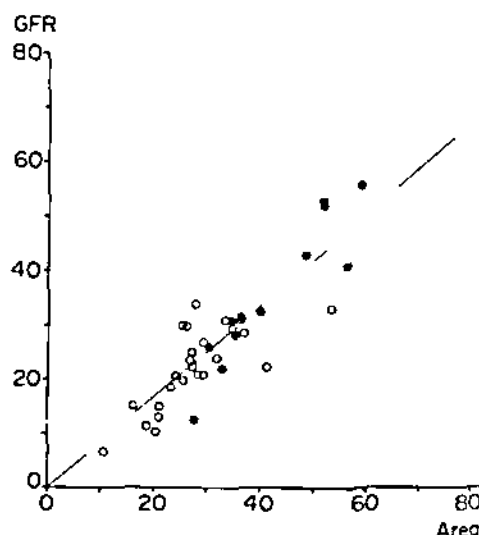


Fig 3

Fig 2 Relationship between area (cm) of renal parenchyma and filtration rate (ml/min) in 6 normal subjects The 2 lower dots are from the same patient with unilateral determination of function The 5 upper dots represent 5 patients with bilateral determination of function GFR* = 0 83 A

Fig 3 Relationship between area (cm²) of parenchyma and filtration rate (ml/min) in children with urinary tract infection with or without parenchymal scarring and with different degrees of reflux ● No reflux or reflux I ○ reflux grade II–III GFR* = 0 85 A corr ratio = 0 87

Morphometric analysis

Estimation of the renal parenchymal area This area was determined by tracing the outlines of the parenchyma on a transparent paper the renal pelvis being included (Fig 1) The film used for thi tracing was generally exposed approximately 5 min after the injection of the contrast medium at the time when no external ureteral com pression was applied The area of the renal parenchyma thus traced was measured twice with a planimeter The mean value of the two tracings was used

Estimation of the renal volume The length width and depth were measured on the films and the volume was calculated according to the formula of a regular ellipsoid body $\frac{4}{3}$ (ABC/2³) where A B and C represent the length width and depth respec tively (HEGEDÜS 1972)

The renal length was measured on the same film as the area

Clearance determinations

Unilateral The standard clearance technique was used including continuous in fusion of inulin (Laevassar Gesellschaft) and bladder catheterization In order to obtain a satisfactory diuresis an infusion of 20 per cent glucose was started half an hour before the examination which was started by collecting urine from both kid

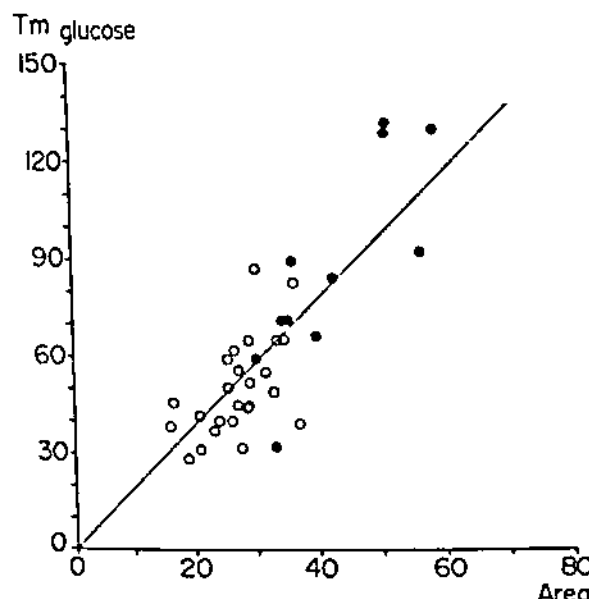


Fig 4 Relationship between tubular function (Tm glucose) and area (cm²) in children with urinary tract infection with or without scarring and with different degrees of reflux T_m - 1 96 A corr ratio - 0 83 Symbols as in Fig 3

neys during 3 periods of 10 minutes each In the middle of each p riod a blood sample was taken Urine was obtained from each kidney s^parately by ext^rnal compression of the contralateral ureter The compression and the complete bladder emptying was controlled by high amplifying fluoroscopy The details of this method have been given previously (BERG et coll 1970 BERG 1971) The compression of the ureter lasted for 10 to 15 min and urine was coll cted 2 or 3 times during this period The mean value from the clearance periods was us^d The first unilateral compression was followed by a 30 min rest period The result was considered satisfactory if the sum of the glomerular filtration rates from both kidneys obtained with and without ureteral compression agreed

Bilateral The renal function was evaluated with a clearance technique including bladder catheterization and continuous infusion of inulin and und r a standardized fluid intake of approximately 0 7 per cent body weight every hour The urine was collected during 20 min periods In the middle of each p^riod venous blood samples were withdrawn for analysis of inulin which was carried out with the antron method Before the analysis yeast was ad d d t the ample in order to eliminate glucose Serum and urine samples were n lys d for sodium with a flam^ photom^ter Glucose in serum and urine was determ ned ith the glucose oxidase method

Math n a l statistical comments

The model is based on the idea th he variable glomerular filtration rate (GFR) is proportional to the size of the k d ey especially the renal parenchymal area (A) i e GFR=c A where c is a proportioning coefficient determined from the obs^rva

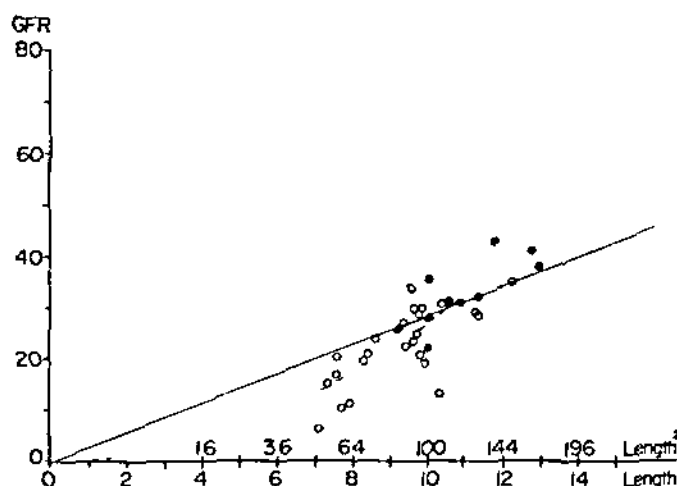


Fig 5 Relationship between length (cm) of kidney and filtration rate (ml min) in patients with urinary tract infection GFR* = 2 87 length (straight line) corr ratio – 0 67 GFR – 0 28 length² (dotted curve) corr ratio = 0 79 Symbols as in Fig 3

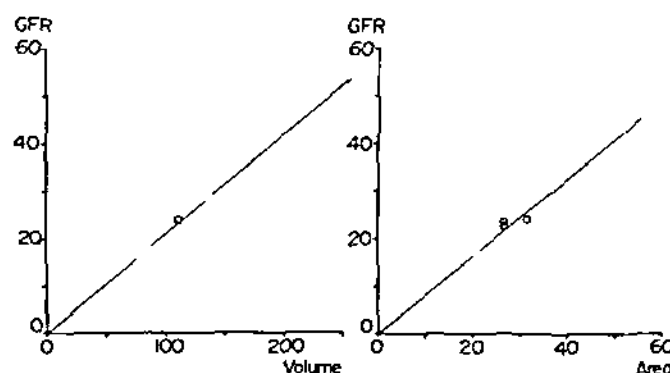


Fig 6 Relationship between filtration rate (ml/min) and renal parenchyma measured by determination of volume (cm) corr ratio = 0 76 (left) and area (cm²) corr ratio = 0 84 (right) Symbols as in Fig 3

tions of GFR and A This means that a regression line is fitted to the observations but forced to pass origo, i e the predicted value of GFR must be zero when the area A is zero A consequence of this is that the common measure of dependency between two variables—the correlation coefficient—does not apply but is replaced by the more general measure the correlation ratio (θ) If the regression line is not forced to pass origo the two measures coincide (CRAMER 1945)

When a variable is given an asterisk i e GFR* this means that the variable GFR is estimated and not observed

Results

Group I The total filtration rate in the healthy young adults averaged 106 18 ± 6 93 ml/1 73 m²/min (mean ± 1 SD) The proportioning coefficient was found to be 0 832 with the standard deviation 0 046 The estimated relationship between the filtration rate and the renal parenchymal area A was thus found to be GFR* ≈ 0 83 × A The correlation ratio between filtration rate and kidney area was 0 91 (Fig 2)

Table

Comparison between the different methods used for estimating si e of renal parenchyma

	Observed ind pendent variable	Regression equation	Correlation ratio
Hypothesis	**Glomerular filtration rate proportional to kidney area**		
48 kidneys	Area A cm^2	$GFR^* = 0\ 85\ A$	0 872
	Length L cm	$GFR\ -0\ 28\ L^2$	0 788
14 kidneys	Area A cm^2	$GFR\ -0\ 82\ A$	0 839
	Volume V cm^3	$GFR^*\ 1\ 09 \times V^{2\ 3}$	0 766
Hypothesis	**Glomerular filtration rate proportional to kidney length**		
48 kidneys	Area A cm^2	$GFR = 5\ 07\ A^{1/2}$	0 739
	Length L cm	$GFR^* = 2\ 87\ L$	0 665
14 kidneys	Area A cm^2	$GFR^* = 4\ 75\ A^{1\ 2}$	0 718
	Volume V cm^3	$GFR^* = 5\ 38\ V^{1\ 3}$	0 616
Hypothesis	**Glomerular filtration rate proportional to kidney volume**		
48 kidneys	Area A cm^2	$GFR^* = 0\ 13\ A^{3\ 2}$	0 821
	Length L cm	$GFR^* = 0\ 025 \times L^3$	0 741
14 kidneys	Area A cm	$GFR = 0\ 13\ A^{3\ 2}$	0 728
	Volume V cm^3	$GFR^* = 0\ 21 \times V$	0 762

Group 2 The renal function was determined in 48 kidneys from the 25 patients For technical reasons the filtration rate was determined only in one kidney in 2 patients The filtration rate ranged between 10 and 79 ml/1 73 m^2/min The low values were generally observed in patients with vesico ureteral reflux grade III The relation ship between the filtration rate and the renal parenchymal area was in this group estimated to $GFR^* = 0\ 85 \times A$ (Fig 3) The correlation ratio was 0 87 No patient had any remarkable deviation from this relationship The proportioning coefficient for this group $0\ 846 \pm 0\ 074$ was not significantly different from that in group 1 $0\ 832 \pm 0\ 046$ In this group of patients the relationship between a parameter of proximal tubular function (T_G) and renal parenchymal area was also estimated (Fig 4) The connection was calculated $T_G^* = 1\ 96 \times A$ and the correlation ratio was 0 83 The observed values are well clustered around the regression line

The filtration rate was related to the length of the kidney in 48 kidneys from patients with urinary tract infection (Fig 5) and to the volume in 14 kidneys from such patients (Fig 6) A comparison between the different methods used for estimating the size of the renal parenchyma is made in the Table The correlation ratio was higher between the GFR and the area ($\theta = 0\ 87$) than between the GFR and the length ($\theta = 0\ 67$) of the kidney The correlation ratio was also higher between GFR and parenchymal area ($\theta = 0\ 84$) than between GFR and volume ($\theta = 0\ 76$) When the observed variables were transformed into the same dimension as the area the

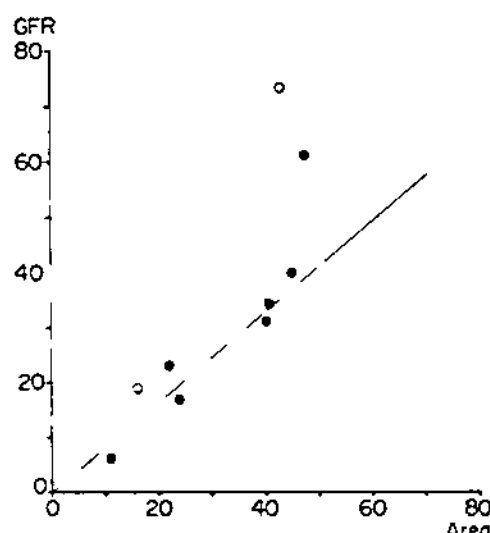


Fig 7

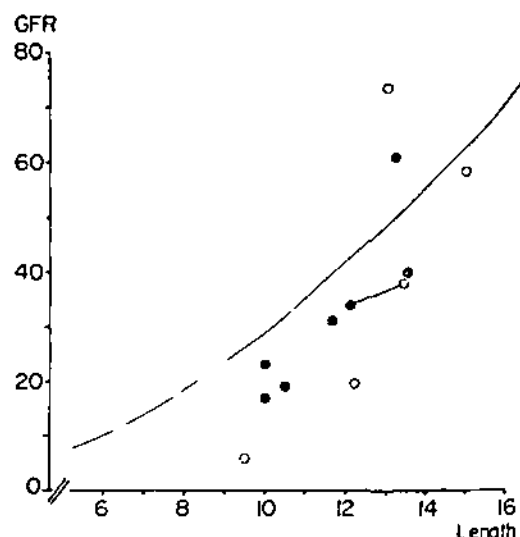


Fig 8

Fig 7 Relationship between area (cm^2) and filtration rate (ml/min) in patients with obstructive and remaining hydronephrosis the solid line represents the normal group The two connected dots represent the same patient ○ Obstruction ● remaining hydronephrosis

Fig 8 Relationship between length (cm) of kidney and filtration rate (ml/min) in patients with obstructive and remaining hydronephrosis The curve is based on the squared length in patients with urinary tract infection The two connected dots represent the same patient Symbols as in Fig 7

length by squaring the volume by squaring its cube root the correlation ratios improved but never exceeded the one between the GFR and the area

Group 3 In 5 kidneys from 5 patients with obstructive and in 7 kidneys from 6 patients with remaining hydronephrosis after the obstruction had been removed the filtration rate ranged between 12 and 98 ml/1 73 m /min The relationship between the filtration rate and the parenchymal area appears in Fig 7 It is evident that most of the observations are scattered around the line determined from group 1 but there are hydronephrotic kidneys that deviate markedly Therefore the relationship established in group 1 is not always applicable in this disorder The relationship between the filtration rate and the square of the length of the kidney deviates from that found both in group 1 and group 2 (Fig 8) The filtration rate is lower than could be expected from the size of the kidney estimated as the square of the kidney length (L^2)

Group 4 In 7 patients with acute Henoch Schonlein or IgA IgG nephritis the filtration rate ranged between 61 and 93 ml/1 73 m^2/min i e was 42 to 12 per cent reduced compared with the rate in group 1 The relationship between the filtration rate and the renal area was compared with that in group 1 (Fig 9) In all cases the filtration rate was lower than what could be expected from the measured renal area

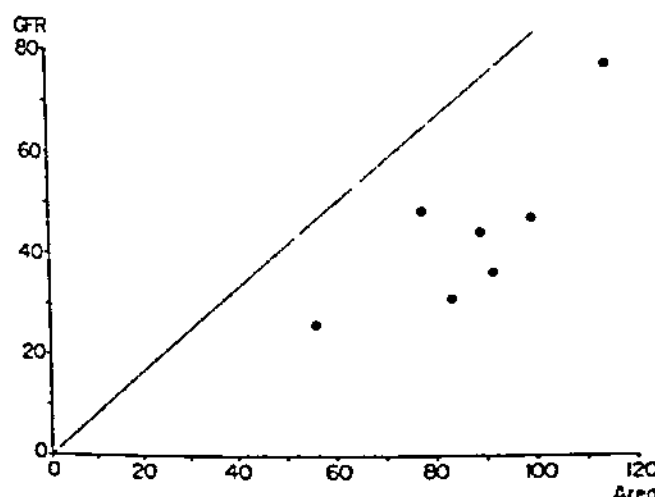


Fig 9 Relationship between area (cm²) of both kidneys and bilateral filtration rate (ml/min) in patients with glomerular disease The solid line represents the normal group

Discussion

The results have shown that the size of the kidney is a good index of its function in patients with urinary tract infection with or without reflux and in many patients with obstructive and remaining hydronephrosis This information is of great clinical importance since those patients are generally considered for surgical intervention A deterioration of the renal function is a primary indication for an anti reflux operation The urography then provides sufficient information about the function of the kidney and more elaborate analysis of separate kidney function is not needed in uncomplicated cases Before any conclusions are drawn about the kidney function from the urographic appearance some general knowledge of the functional capacity of the kidney in various renal diseases is necessary In acute glomerulonephritis the filtration rate was consistently lower than what would be expected from the size of the kidney In acute Henoch Schönlein and IgA IgG glomerulonephritis an often reversible depression of the filtration rate is found (LINNE et coll 1976) Available evidence suggests that this depression is functional rather than structural in origin On the other hand pyelonephritis seems to result in irreversible scarring of entire nephrons as indicated experimentally (BANK & AYNEDJIAN 1966) The remaining nephrons will continue to function at a fairly intact level This so-called intact nephron hypothesis is supported by the present results that the area of the renal parenchyma correlated as well to the glomerular as to tubular function

In previous reports on the relationship between the renal function and the size of the renal parenchyma no attempt has been made to distinguish between different nephropathies In reports on the relationship between function and size as estimated by total kidney area in healthy adults or patients with renal diseases of various origin (LADEFOGED & PEDERSEN 1968 ANDERSEN & MOGENSEN 1973) the correlation coefficient was 0 68 i e lower than that found for patients with urinary tract in

fection with or without reflux The reason for the relatively low correlation coefficient is most likely a combination of several factors such as The analysis was performed in a heterogeneous group of nephropathies or the estimation of the renal area was made without excluding the pelvis

Previously the size of the kidney in different conditions was estimated by using the length (GONDOS 1962 CURRARINO 1965 STOLPE et coll 1967 HODSON et coll 1962 1975 EKLÖF & RINGERTZ 1976) the volume (HEGEDÜS) or the area measured as product of length and width (MOELL 1961 KARN 1962 FRIEDENBERG et coll 1965) of the kidney The planimetric determination of the area of the renal parenchyma is however the superior method of estimating the size of the functioning renal parenchyma The glomerular filtration rate correlated better to the planimetrically determined area than to the length and the volume of the kidney This may be explained as follows

At the planimetric determination the renal pelvis was subtracted from the area of the kidney The error introduced by including the renal pelvis in the determination of the functional renal parenchyma increases in conditions with dilatation of the pelvis Thus it is not surprising that the discrepancy in the correlation between renal function and renal area and between renal function and renal length was greatest in patients with obstructive and post obstructive hydronephrosis Further the filtration occurs across the glomerular capillary wall i e an area Thus ideally the filtration rate should be related to an area The increases in correlation ratio between function and size when the length was squared and the volume was squared by its cube root support this assumption

The planimetrically determined area of the kidney is a better index of the functional renal parenchyma than the length of the kidney and should therefore be used in scientific work Yet the length of the kidney correlated so well with the function of the kidney that it could generally be used clinically when the function of the kidney in patients with urinary tract infection should be estimated The length is easier to determine When this method is used the length is best related to the height of the lumbar vertebral bodies (CURRARINO EKLÖF & RINGERTZ)

Acknowledgements

The authors are indebted to Nils Wikstad for statistical advice The investigation was supported by grants from the Swedish Medical Research Council (B76-19X 2049 10B) and the fund of Karolinska Institutet

SUMMARY

Length parenchymal area planimetrically determined and volume of the kidney were estimated at urography and related to glomerular filtration rate in patients with different nephropathies The results demonstrate that the size of the kidney is an excellent index of

renal function in patients with pyelonephritic scarring secondary to urinary tract infection and vesicoureteral reflux It is also a good index in patients with obstructive hydronephrosis but a poor index in patients with glomerulonephritis

ZUSAMMENFASSUNG

Die Lange die planimetrisch bestimmte Flache des Parenchyms und das Volumen der Niere wurden bei der Urographie festgestellt und zur Filtrations Rate des Glomerulus bei Patienten mit verschiedenen Nephropathien relatiert Die Resultate zeigen dass die Grosse der Niere ein ausgezeichneter Index der Nierenfunktion bei Patienten mit pyelonephritischer Narbenbildung *sekundar zu einer Infektion der Harnwege und einem vesico-ureteralen* Reflux ist Sie ist ebenfalls ein guter Index bei Patienten mit obstruktive Hydronephrose jedoch ein schlechter Index bei Patienten mit Glomerulonephritis

RÉSUME

La longueur la surface du parenchyme déterminee par planimetrie et le volume du rein ont ete estimés au cours de l urographie et correlés avec le taux de filtration glomerulaire chez des malades atteints de differentes néphropathies Les resultats montrent que la taille du rein est un excellent index de la fonction renale chez les malades qui ont des séquelles de pyelonephrite secondaire à une affection des voies urinaires et à un reflux vesico urétéral C'est aussi un bon index chez les malades qui ont une hydronéphrose obstructive mais un mauvais index chez les malades qui ont une glomerulo-nephrite

REFERENCES

ANDERSEN M J F and MOGENSEN C E Relationship between renal size and function in normal subjects Acta radiol Diagnosis 14 (1973) 209

BANK N and AYNEDJIAN H S Individual nephron function in experimental bilateral sodium potassium and water reabsorption J Lab clin Med 68 (1966) 713

BERG U Renal function in children with recurrent urinary tract infections Thesis Stockholm 1971

— APERIA A BROBERGER O EKENGREN K and ERICSSON N O Relationship between glomerular filtration rate and radiological appearance of the parenchyma in children Acta paediat cand 59 (1970) 1

CRAMER H Mathematical methods of statistics Almqvist & Wiksell Uppsala 1945

CURRARINO G Roentgenographic estimation of kidney size in normal individuals with emphasis on children Amer J Roentgenol 93 (1965) 464

EKLOF O and RINGERTZ H Kidney size in children A method of assessment Acta radiol Diagnosis 17 (1976) 617

FRIEDENBERG M J WALTZ B J MCALISTER W H LOCKSMITH J P and GALLACHER T L Roentgen size of normal kidneys Radiology 84 (1965) 1022

GONDOS B Roentgenography evaluation of the size and shape of the kidney Med Ann D C 31 (1962) 158

HEGEDUS V Three-dimensional estimation of renal shape and volume at angiography Acta radiol Diagnosis 12 (1972) 87

HODSON C J DAVIES Z and PRESCOD A Renal parenchymal radiographic measurement in infants and children Pediat Radiol 3 (1975) 16

— DREWE J A KARN U N and KING A Renal size in normal children A radiographic study during life Arch Dis Childh 37 (1962) 616

KARN M N Radiographic measurements of kidney section area Ann Hum Genet 25 (1962) 379

LADEFOGED J and PEDERSEN F Relationship between roentgenological size of the kidney and the kidney function J Urol 99 (1968) 239

LINNÉ T APERIA A and BROBERGER O Kidney function in acute juvenile glomerulo nephritis Paper read at the Annual Meeting of Swedish Medical Association Stock holm December 1–4 1976

MOELL H Kidney size and its deviation from normal in acute renal failure A roentgen diagnostic study Acta radiol (1961) Suppl No 206

STOLPE Y KING L R and WHITE H The normal range of renal size in children Invest Urol 4 (1967) 600

FROM THE DEPARTMENTS OF PEDIATRIC RADIOLOGY AND PEDIATRIC SURGERY ST GÖRANS SJUKHUS S 112 81 STOCKHOLM SWEDEN

BIRTH INJURIES TO THE EPIPHYSEAL CARTILAGE

K. EKENGREN S BERGDAHL and G EKSTRÖM

In infants and children the skeleton in general and the epiphyseal cartilage in particular is less resistent to trauma than the ligaments and the joint capsules Consequently a birth injury to a joint results not in dislocation but in a fracture through the weakest part of the epiphyseal cartilage i e the layer of hypertrophic cells (SALTER & HARRIS 1963 WEIGL & CONFORTY 1974) The proliferating cells remain attached to the epiphysis (Fig 1) Thus the direction of the future growth of the diaphysis is determined by the position of the epiphysis after healing of the fracture However the skeleton of the growing child has great remodelling capacity and the initial deformity often decreases during growth The purpose of this communication is to report short and long term sequelae of injuries to the epiphyseal cartilage at birth

Material

The series comprised 20 patients Eight infants born between 1961 and 1969 were treated at Kronprinsessan Lovisas Barnsjukhus and 12 infants born between 1970 and 1976 at the Pediatric Clinic of St Gorans Sjukhus The location and number of the fractures were as follows Proximal humerus—9 distal humerus—5 proximal femur—1 distal femur—5 (4 patients) and distal tibia and fibula—1

Breech deliveries were reported in 14 cases in 2 cases the deliveries were complicated in other ways Normal deliveries were reported in 4 infants with injuries to elbow knee and hip joint respectively

Submitted for publication 22 June 1977

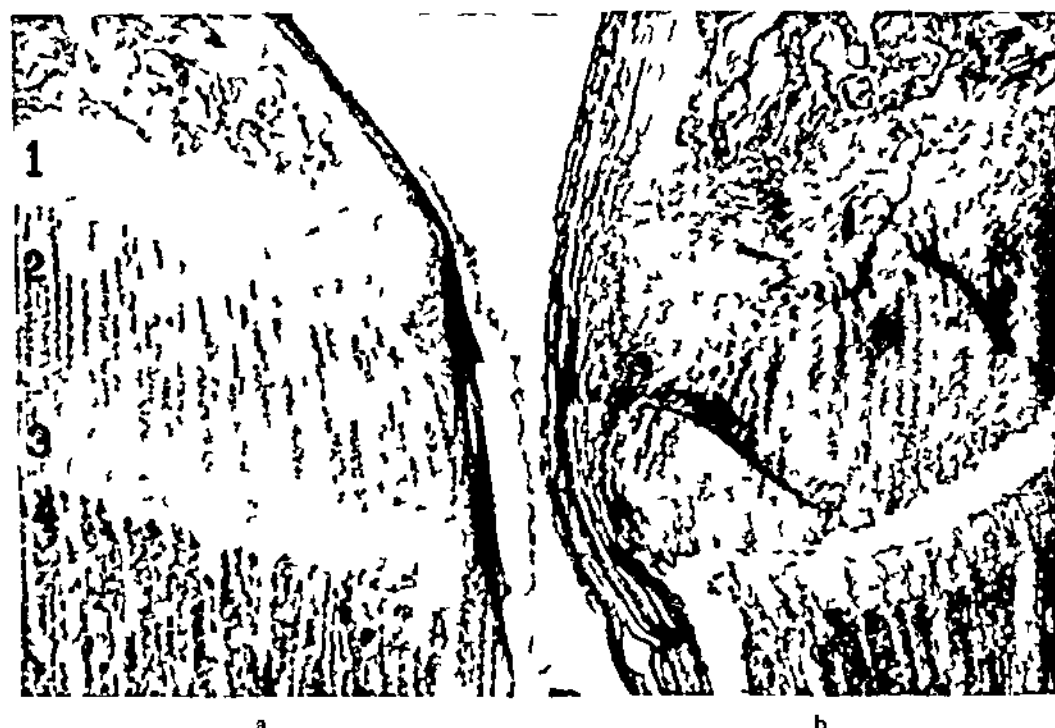


Fig 1 Distal ulna of rabbit a) Normal epiphysis Cartilaginous zones (1) resting cells (2) proliferating cells (3) hypertrophic cells (4) provisional calcification b) Experimentally produced fracture Cl avage within the hypertrophic zone (Courtesy of L F Rogers and Radiology)

Radiographic diagnosis and clinical course A fracture entirely restricted to the epiphyseal cartilage cannot be demonstrated at radiography However in many cases the fracture extends through a part of the metaphysis separating a tiny bony fragment This fragment is attached to the epiphysis and if no displacement of the epiphysis has occurred the fragment is the only radiographic evidence of fracture In considering a potential displacement a comparison with the uninjured extremity is necessary particularly when no ossification center has appeared in the epiphysis Callus becomes visible when the infant is 10 to 14 days old

Following birth injury to the proximal epiphyseal cartilage of the *humerus* a small metaphyseal fragment is usually visible indicating the position of the epiphysis if no ossification center has yet appeared The degree of displacement is estimated by comparison with the healthy side (Fig 2) In 5 of the 9 patients with this injury the humeral shaft was displaced medially or dorsally 5 mm or more The displacement was reduced in 2 cases All these infants later had normal mobility in the shoulder joint

In the *elbow joint* no ossification center is present at birth and an epiphyseal fracture in the lower humerus must be investigated by comparison with the other side All 5 patients with this injury had the forearm including the humeral epiphysis and



Fig 2 a b) Newborn boy Epiphyseal fracture in left humerus Slight medial displacement of humeral shaft Small metaphyseal fragment (→) c) Four weeks later The fracture is healed

the joint displaced dorsally as described by TRUESDELL (1917) In addition some of them had a small metaphyseal fragment (Fig 3 a b) Reduction was performed in 4 cases with varying results Even if the reduction was not complete the bone was rebuilt during the subsequent years (Fig 3 c d e) One patient in whom no reduction was performed had a minor extension defect at 3 years of age The others had normal mobility

Birth injury to the upper epiphyseal cartilage of the *femur* is rare Only about 40 cases have been reported (LINDSETH & ROSENE 1971 WEIGL & CONFORTY) At radiography the lesion may be mistaken for congenital dislocation of the hip the femoral shaft is displaced upwards and no ossification center is present in the epiphysis to demonstrate the position of the femoral head However with epiphyseal birth injury no acetabular dysplasia exists which should exclude congenital dislocation of the hip (Fig 4 a) furthermore the patient has clinical signs of fracture No conclusive evidence exists that traumatic dislocation of the hip ever occurs at birth (MORTENS & CHRISTENSEN 1964)

A female neonate presented with the typical displacement of the femoral shaft (Fig 4) Several attempts at reduction were made but some dorsal angulation remained The site of angulation was gradually transferred distally as a result of growth at the proximal epiphyseal cartilage (Fig 4 c) No visible deformity remained at 6 years and the mobility was normal

In the *distal femoral* epiphysis an ossification center is normally present at birth In 3 of the 4 patients with injuries to the knee the femoral epiphysis was displaced considerably either dorsally or dorsolaterally The only sequelae of any clinical significance in the entire series occurred among these patients In one male infant with lateral and dorsal displacement and anterior angulation reduction was not entirely successful (Figs 5 6) Two weeks later abundant new bone formation was



Fig 3 a b) Right and left elbow of 3-day-old girl Epiphyseal fracture in left distal humerus proved by small metaphyseal fragment (→) and displacement of radius and ulna c) Two weeks later Ulnar displacement not reduced dorsal displacement changed to anterior displacement d e) At 15 months almost complete remodelling only slight anterior curvation of humerus

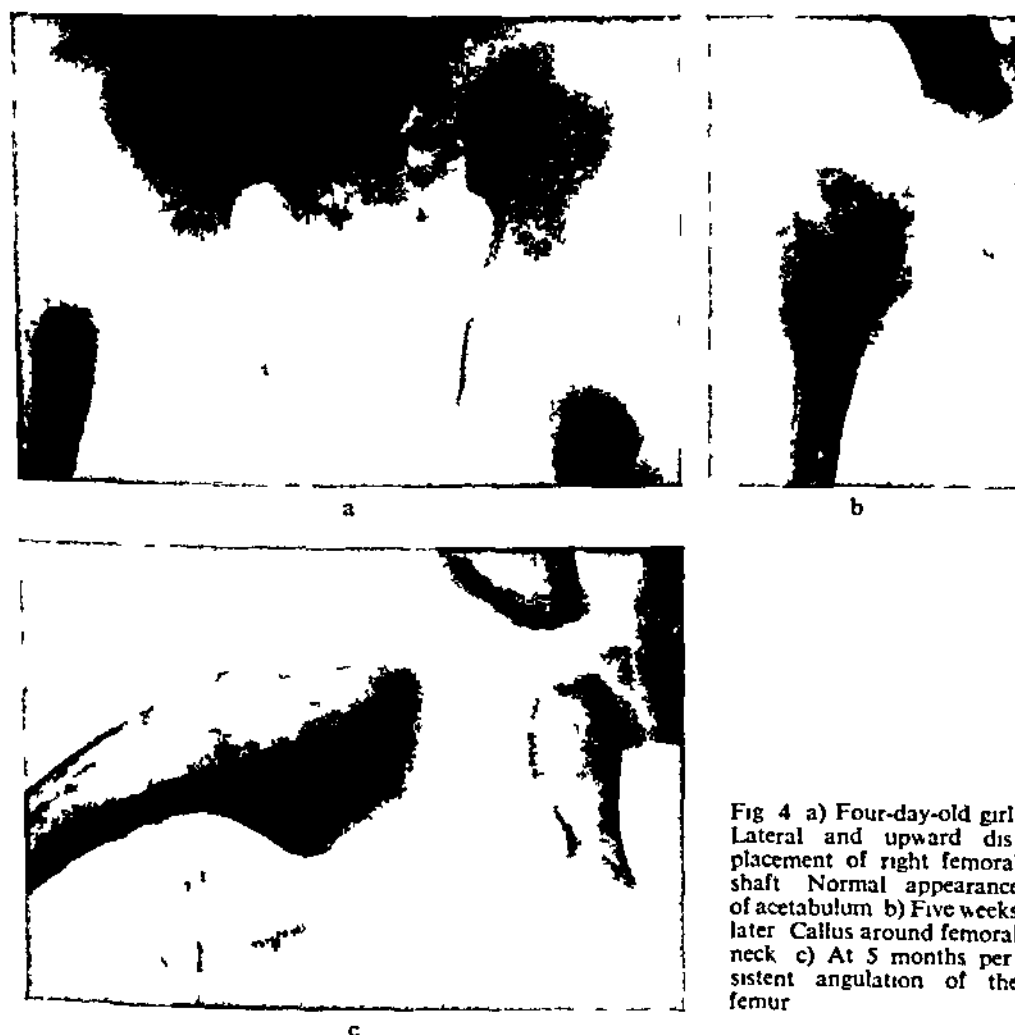


Fig 4 a) Four-day-old girl Lateral and upward dis placement of right femoral shaft Normal appearance of acetabulum b) Five weeks later Callus around femoral neck c) At 5 months per sistent angulation of the femur

found The lateral displacement and a medial angulation was completely com pensated 4 months after birth The remodelling of the anterior angulation occurred much more slowly but when the boy was 2 years old only a slight recurvation of the femoral shaft remained

In the other 2 cases the injury was diagnosed late and reduction was impossible In one of these infants a swelling of the left knee was found 2 days after birth treat ment of a supposed osteo arthritis began then haemophilia was diagnosed and treated When the boy was 2 months old an extension defect of the left knee was found and films showed a healed epiphyseal fracture of the femur with an anterior angulation of 60 degrees (Fig 7 a b) During the following years some remodelling occurred (Fig 7 c) at the age of 8 years the anterior angulation still amounted to about 45 degrees (Fig 7 d) The other infant with late diagnosis was 2 weeks old




Fig 5 a b) Right knee of 3 day old boy Fracture through femoral epiphyseal plate Lateral and dorsal displacement of epiphysis with ossification center (→) and small metaphyseal fragment c d) Two weeks later Abundant callus formation Lateral displacement of ossification center remains Slight anterior and medial angulation

when hard tumours were palpated around both knees Bilateral fractures of the distal femoral epiphysis with callus formation and anterior angulation of 30 degrees were demonstrated When the boy was 8 years old his legs were still curved but at the age of 16 his legs are reported to be straight

Only one patient had epiphyseal fractures distally in tibia and fibula which were treated with reduction and plaster with good result This type of injury is extremely rare

a b c d

Fig 6 Same case as in Fig 5 a b) At 4 months and c d) at 11 months Continued remodelling persistent slight recurvation of femur Remnants of primary cortical layer visible in femoral shaft

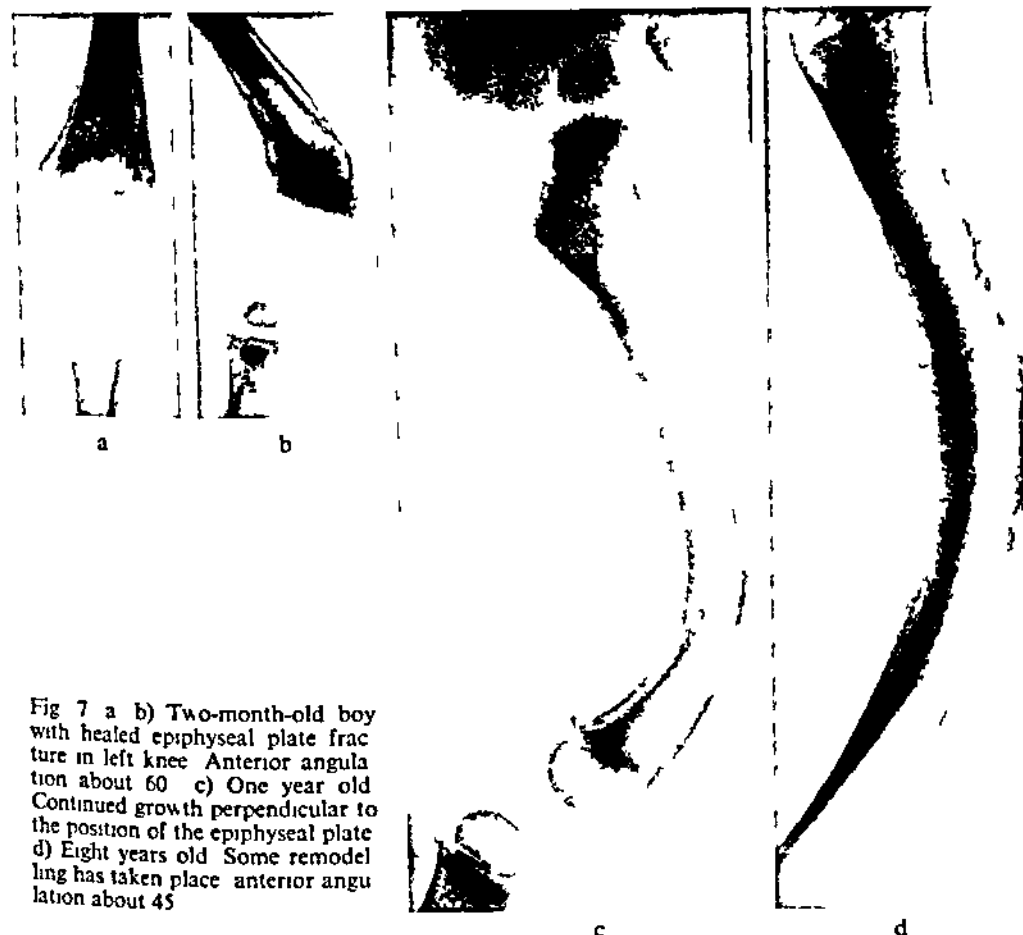


Fig 7 a b) Two-month-old boy with healed epiphyseal plate fracture in left knee Anterior angulation about 60 c) One year old Continued growth perpendicular to the position of the epiphyseal plate d) Eight years old Some remodelling has taken place anterior angulation about 45

The present series includes no patient with separation of the upper tibial epiphysis but one such patient was recently encountered He had severe displacement which was reduced

Ten of the 20 patients were more than one week old at the time of correct diagnosis In 7 of them the treatment was complicated and prolonged by delay in diagnosis The injury to the epiphyseal cartilage was erroneously considered to be paralysis congenital dislocation or osteo arthritis Such a delay may lead to serious consequences Although there is a strong tendency to remodelling during growth active reduction is often necessary In the present material 2 patients sustained severe sequelae which could probably have been avoided had a correct diagnosis been established early

Conclusions

Every newborn infant with pain swelling or impaired movement of a limb or joint should be examined radiographically without delay

Isolated traumatic dislocation of a joint probably never occurs at birth i e every instance of traumatic dislocation of the diaphysis should be regarded as an epiphyseal fracture

Since displacements in the newborn may be difficult to detect comparison with films of the contralateral joint is a sine qua non

SUMMARY

A birth injury in the vicinity of a joint might lead to a fracture through the epiphyseal cartilage The criteria for diagnosing such a fracture at radiography are considered and the continued remodelling of the bone demonstrated The history of 2 cases with late diagnosis and serious long term sequelae are described in order to emphasize the necessity of early radiography

ZUSAMMENFASSUNG

Ein Geburtstrauma in der Nahe eines Gelenkes kann zu einer Fraktur des epiphysealen Knorpels fuhren Die Kriterien zur Diagnose einer solchen Fraktur auf dem Rontgenbild werden festgestellt und die fortlaufende Umwandlung des Knochens nachgewiesen Zwei Fälle mit einer spaten Diagnose und einem schweren langanhaltenden Verlauf werden beschrieben um die Notwendigkeit der fruhzeitigen Rontgenuntersuchung zu betonen

RESUME

Un traumatisme obstetrical au voisinage d une articulation peut entrainer une fracture a travers le cartilage epiphysaire Les auteurs examinent les criteres du diagnostic radiographique de cette fracture et mettent en evidence la continuation du remodelage de l os Ils presentent l observation de 2 cas ou le diagnostic a eté fait tardivement et ou il existait des séquelles tardives graves afin de souligner la nécessité d une radiographie precoce

REFERENCES

LINDSETH R E and ROSENE H A Traumatic separation of the upper femoral epiphysis in a newborn infant J Bone Jt Surg 53 A (1971) 1641

MORTENS J and CHRISTENSEN P Traumatic separation of the upper femoral epiphysis as an obstetrical lesion Acta orthop scand 34 (1964) 239

ROGERS L F The radiography of epiphyseal injuries Radiology 96 (1970) 317

SALTER R G and HARRIS W R Injuries involving the epiphyseal plate J Bone Jt Surg 45 A (1963) 587

TRUESDELL E D Birth fractures and epiphyseal dislocations Paul B Hoeber New York 1917

WEIGL K und CONFORTY B Die traumatische Epiphysenablosung am oberen Femurende beim Neugeborenen Z Orthop 112 (1974) 1286

FROM THE SECTION OF PEDIATRIC RADIOLOGY DEPARTMENT OF DIAGNOSTIC RADIOLOGY
MALMÖ ALLMANNA SJUKHUS S 214 01 MALMÖ SWEDEN

CALCIFICATION IN CHONDRODYSPLASIA PUNCTATA

Relation to ossification and skeletal growth

G THEANDER and H PETTERSSON

Multifocal congenital calcification of cartilage has been considered the distinguishing feature of a condition first described by CONRADI (1914) and later referred to as Conradi s disease Several other terms have been used e g chondrodystrophia calcificans congenita chondrodysplasia hypoplastica calcinosa and stippled epiphyses but chondrodysplasia punctata is the name recommended by the European Society of Pediatric Radiology in its Nomenclature for the constitutional (intrinsic) diseases of bone (1971)

Most authors have reported only single cases but in 1968 an extensive review of the literature was published by MOSEKILDE A more recent survey chiefly concerned with the relation of radiologic to clinical findings has been given by SPRANGER et coll (1970 1971) The total number of cases on record now approaches 150

Some cases have been prematurely born babies who were stillborn or died shortly after birth In these and in a few who survived longer the calcification was accompanied by severe bone dysplasia involving the limbs spine and pelvis by abnormalities of the skin and eyes and occasionally also by cardiovascular renal abdominal or cerebral malformations This complex of abnormalities has been claimed to represent a special lethal or rhizomelic type of chondrodysplasia punctata In another type nowadays often referred to as the Conradi Hunermann type coexisting abnormalities have been fewer and less severe

Submitted for publication 4 March 1977



Fig. 1 Case 2 Two days. Calcific deposits bilaterally in pelvic and trochanteric cartilages and on the right side in the femoral head distal femoral epiphysis and proximal tibial and fibular epiphyses.

Cumulative evidence suggests that both types can be discriminated also radiologically and that they may constitute two different syndromes rather than reflect only variations in the manifestations of a single disease (SPRANGER et coll 1970 1971) Some clinical findings such as saddle nose cataract skin lesions shortness of limbs or digits, and joint contractures however seem to be frequent in both types

The abnormal calcification in both types is particularly common in the epiphyses of tubular bones and in small bones but it may affect any cartilage in the skeleton or elsewhere e g. in the trachea As pointed out by SPRANGER et coll (1970) and HEWITT & VAN BOCHOVE (1971) calcification at the same sites may be found also in certain other uncommon conditions but concomitant findings and the course of calcification should prevent confusion between these and chondrodysplasia punctata

In several cases of chondrodysplasia punctata observed immediately after birth ossification has been found to be retarded at sites with calcific deposits Repeat examination of some of the children with the Conradi Hünermann type and of a few with the rhizomelic type suggests that the deposits will as a rule disappear within the first few years of life but ossification still seems to be retarded and persistence of retardation has been observed also later Any shortness of bones appears to be permanent although some improvement has occasionally been reported

Table 1

Case 1 Number of calcific deposits in hip cartilages according to age N numerous (uncertain number more than 15) = fewer than on previous occasion

		5 d.	3 m.	15 m.	16 y
Great trochanter	R	N		,	0
	L	N			' 0

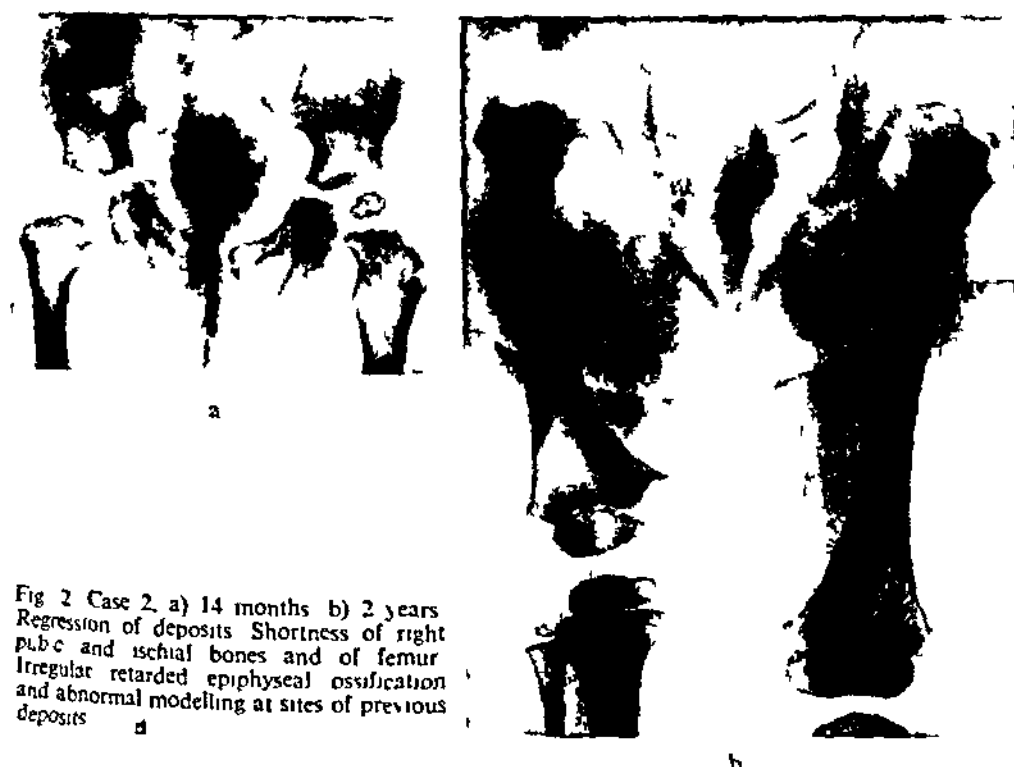


Fig 2 Case 2, a) 14 months b) 2 years Regression of deposits Shortness of right pubic and ischial bones and of femur Irregular retarded epiphyseal ossification and abnormal modelling at sites of previous deposits

Data on record are hardly sufficient for closer analysis of the relations between the calcification of cartilage and the osseous abnormalities The present report contributes 5 previously unpublished cases of chondrodysplasia punctata in which these relations were analysed

Material and Methods

The material consisted of 5 children with chondrodysplasia punctata type Conradi Hunermann All except one were born in Malmo and 4 of them were radiologically examined already in the first week of life One child was first seen at 12 months of age Radiologic examination was carried out at least twice in all cases the follow up ranging from 11 months to 16 years

All films were reviewed and the record sheets were consulted for clinical information The site number and size of the abnormal calcifi deposits were recorded and the state of ossification and the bone size in the affected regions were compared with those on the opposite side The measurements obtained were compared with standards for normal development given in current text books (SCHMID 1973 POZNANSKI 1974)

Any observed side difference in length of a pair of tubular bones with calcification in only one was calculated as the quotient between the length on the side with deposits

Table 2

Case 2 Number of calcific deposits at various sites according to age N = numerous (uncertain number more than 15) ↓ = fewer than → = same as on previous occasion

		2 d	4 m	14 m	2 y	3 y	4 y	9 y
Shoulder								
Humeral head	R	4	↓0	0	0	0		0
Great tubercle	R	N	→	→	↓	↓		↓0
Elbow								
Humeral epiph	R	N	↓	→	↓	↓		↓0
Wrist								
Ulnar epiph	R	6	↓	↓	↓	↓0		
Scaphoid	R	N	↓	↓0				
Trapezium	R	N	↓	↓0				
Hamatum	R	10	↓	↓0				
Lumbar spine	R	N	↓	↓0				
	L	N	↓	↓0				
Pelvis								
Sacrum	R	N	→	↓0				0
	L	N	↓	↓0				0
Iliac crest	R	N	→	↓				↓0
	L	0	0	0				0
Y-cartilage	R	N	→	↓	→	↓0	0	0
	L	N	↓	↓	↓	↓0	0	0
Pubic ramus	R	N	↓	↓	↓0	↓0	0	0
	L	0	0	0	0	0	0	0
Ischial ramus	R	N	ı	↓	→	↓	↓0	0
	L	0	0	0	0	0	0	0
Hip								
Femoral head	R	N	↓	↓0	0	0	0	0
	L	5	↓0	0	0	0	0	0
Trochanter	R	N	↓	↓	↓	→	↓	↓0
	L	15	↓0	0	0	0	0	0
Knee								
Femoral epiph	R	N	↓	↓	↓	↓	↓0	0
	L	2	↓	↓0	0	0	0	0
Tibial epiph	R	N	ı	↓	↓	↓0	0	0
	L	0	0	0	0	0	0	0
Fibular epiph	R	N	→	↓	→	→	↓	↓0
	L	0	0	0	0	0	0	0
Ankle								
Tibial epiph	R	N	→	↓	↓	↓	→	↓0
	L	0	0	0	0	0	0	0
Fibular epiph	R	N	↓	↓	↓0	0	0	0
	L	0	0	0	0	0	0	0

Table 2 (*cont*)

		2 d	4 m	14 m	2 y	3 y	4 y	9 y
Tarsus								
Talus	R	N	↓	↓		↓0	0	0
	L		N				↓0	0
Calcaneus	R	N	↓	↓		↓0	0	0
	L		N				0	0
Other tarsals	R	N					↓0	0
	L						0	0

and that on the other Since also epiphyseal ossification centers were sometimes unilateral this quotient was based on measurement of the diaphyses At all sites where the entire diaphysis on either side had been included in the examination on more than one occasion the quotient was evaluated for variation with age

Results

The clinical course and the initial radiologic appearances are described in the following case reports

Case 1 A boy born at term of a normal pregnancy was admitted to hospital at 5 days of age because the hip joints had not felt quite normal on routine palpation He had a saddle nose but no other external stigma Radiography included the pelvis lumbar spine hips and knees No osseous abnormality was found but punctate calcification of the cartilage was seen in the trochanter on either side These minute calcific deposits could not be counted with certainty but their number was estimated to 25 on the right side and 35 on the left (Table 1) The hips were radiologically reexamined at 3 months of age at 15 months and at 16 years Growth and general development throughout this time appeared normal

Case 2 A girl born at term of a normal pregnancy had a congenital deformity of the right foot and the right leg was somewhat shorter than the left Radiography at 2 days of age included the spine and pelvis both right limbs and the left thigh It showed a metatarsal deformity of the right foot and confirmed that the right femur was shorter than the left The proximal femoral metaphysis was somewhat broader on the right side where the pubic and ischial bones were also shorter No ossification center was present in the carpal bones or in any of the epiphyses and tarsal bones examined No further osseous abnormality was found but numerous small calcific deposits in the cartilage were present bilaterally in the pelvis and lumbar spine and in the proximal ends of the femurs On the right side there were similar deposits in both ends of the humerus tibia and fibula in the distal end of the ulna and in the carpus and tarsus A selection of the findings appears in Figs 1 and 2 and the number of deposits at the various sites is given in Table 2

Repeat radiography was performed at 4 months at 14 months and at 2 3 4 and 9 years The right leg had appeared somewhat weak in the first few months of life but motility had afterwards been normal Shortness of the right leg persisted despite growth In all other respects the child seemed to have developed normally

Case 3 A girl born at term of a normal pregnancy was admitted to hospital because the left third finger and the left second and right third toes were abnormally short A complete

Table 3

Case 3 Number of calcific deposits at various sites according to age N = numerous (uncertain number more than 15) ↓ = fewer than → = same as on previous occasion

			1 d	8 m	19 m	2½ y	5 y
Shoulder							
Coracoid		L	N		↓ 0	0	
Humeral head		L	3		↓ 0	0	
Great tubercle		L	1		→	→1	
Elbow							
Radial head		L	2		→	↓ 0	
Wrist							
Capitatum		L	8	↓	↓	→	↓ 0
Hamatum		L	5	↓	→	↓	→1
Hand							
2nd metacarp	prox. part	L	7	↓	↓	→	↓ 0
	dist part	L	1	↓ 0	0	0	0
3rd metacarp	prox. part	L	3	→	↓	→	↓ 0
	centr part	L	1	↓ 0	0	0	0
4th metacarp	prox. part	L	1	→	→	→	→1
	dist part	L	1	→	→	→	→1
3rd base phal	prox part	L	1	→	→	→	→1
	centr part	L	1	↓ 0	0	0	0
4th base phal	prox. part	L	1	→	→	→	→1
Pelvis							
Y-cartilage		R	10		↓	→3	
		L	3		↓ 0	0	
Pubic ramus		R	3		↓ 0	0	
		L	N		↓	↓ 10	
Ischial ramus		R	5		↓ 0	0	
		L	N		↓	↓ 5	
Hip							
Femoral head		R	3		↓ 0	0	
		L	N		↓ 0	0	
Knee							
Femoral epiph.		R	1		↓ 0	0	
		L	N		↓	↓ 0	
Tibial epiph		R	0		0	0	
		L	N		↓	↓ 15	
Ankle							
Tibial epiph.		R	N		↓	↓ 0	0
		L	N		↓	↓	↓ 0
Tarsus							
Calcaneus		R	N		↓	↓	↓ 0
		L	3		↓ 0	0	0
Other tarsals		R	N		↓	↓	↓ 0
		L	N		↓	↓	↓ 0

Table 3 (*cont*)

		1 d	8 m	19 m	2½ y	5 y
Foot						
2nd metatars prox. part	R	0		0	0	0
	L	5		↓	→	' 0
3rd metatars prox part	R	1		→	' 0	0
	L	0		0	0	0
4th metatars prox part	R	2		↓	↓ 0	0
	L	0		0	0	0

radiologic survey of the skeleton revealed that the left second and right third metatarsals were hypoplastic (Fig 3 a b) and that the proximal interphalangeal joint of the third finger in the left hand was at the same level as the metacarpophalangeal joints of the digits 2 4 and 5 (Fig 4 b) The left third metacarpal and base and middle phalanges were abnormally short and plump The fourth base phalanx and metacarpal of the left hand were somewhat smaller than of the right and the proximal end of this phalanx and of the left second meta carpal was slightly malshaped (Fig 4 a b)

Numerous small calcific deposits were found in the left carpus and both tarsi as well as in the distal epiphyseal cartilage of both tibiae The tibial cluster was largest on the left side Most of the calcifications in the right foot were found in the calcaneus which had no ossi fication center At the corresponding site in the left foot deposits were relatively few and the calcaneal ossification center appeared normal as did that of the talus in both feet Of the tarsal deposits one cluster in the left foot but not in the right could be assigned to the navi cular cartilage A minute deposit was present close to the metaphysis of each of the two hypoplastic metatarsals (Fig 3 a b)

In the left hand punctate deposits were present at either end of the fourth metacarpal as well as at the proximal end of the second and third metacarpals and of the third and fourth base phalanges A minute deposit was also seen within two of the malshaped diaphyses in the left third ray Of these intradiaphyseal deposits at least the one in the metacarpal was surrounded by a small cyst like ossification defect (Fig 4 b)

Further deposits were found bilaterally in the femoral head and the pelvis and on the left side in the coracoid process the proximal epiphyses of the humerus and tibia and the distal epiphysis of the femur None of these epiphyses had an ossification center whereas in the right knee a normal ossification center was present both in the femoral and in the tibial epiphysis The sites and number of calcifications are further specified in Table 3

Repeat radiography was made at 8 and 19 months and at 2 1/2 and 5 years Relative shortness of the three grossly affected digits persisted but otherwise growth and development of the child appeared normal

Case 4 A boy born in the 33rd week of an otherwise normal pregnancy had a saddle nose epicanthus folds and a prominent chin Immediately after birth he had an attack of paleness and muscular hypotonicity from which he recovered spontaneously in a few minutes A radiologic survey of the skeleton on the fourth day of life was done because of suggested Down s syndrome which was however later excluded No osseous abnormality was found except the absence of a calcaneal ossification center This bone in each foot contained in stead a cluster of calcific deposits A few similar deposits were present bilaterally in the trochanter cartilage (Fig 6 a b Table 4)

Radiologic re-examination of the pelvis and fee was performed at 6 weeks 6 months







Fig. 3 Case 3 a b) 1 day Calcific deposits bilaterally in tarsal and distal tibial epiphyseal cartilages Larger tibial cluster on left than on right side Clusters in left navicular and instead of ossification center in right calcaneus Minute deposits at metaphyses in hypoplastic right third and left second metatarsals c d) 2½ years Regression of deposits No ossification of left navicular Retarded osseous development in bipartite right calcaneus and in left tibial epiphysis Residual deposits in left navicular and posterior part of right calcaneus

15 months and 5 years The unusual facial appearance persisted mental and motor development was somewhat retarded and in the first year of life recurrent urinary and upper respiratory infections had occurred No further clinical abnormality was observed

Case 5 A girl born at term of a normal pregnancy was admitted to hospital at 12 months



Fig 4 Case 3 a b) 1 day Left hand Calcific deposits in carpal cartilages centrally in short and broad diaphyses of third metacarpal and base phalanx and at deformed proximal ends of second metacarpal and fourth base phalanx Ossification defect surrounding deposit in third metacarpal Right hand Normal c) Left hand at 8 months

of age because of a slight equinus deformity of the left foot Radiologic examination of the feet showed no osseous abnormality but revealed punctate calcification of the cartilage bilaterally in the talus the navicular and the first and second cuneiform bones as well as at the proximal ends of the second third and fourth metatarsals The feet were re-examined 11 months later when films of the hands were also obtained Similar deposits were found in the right scaphoid cartilage and at the proximal ends of the right second and third and the left third and fourth metacarpals (Table 5) A convergent eye squint had been detected and treated in the meantime The foot deformity persisted No further clinical abnormality was observed

Fate of calcifications

The number of calcific deposits demonstrated at various sites at follow up is given according to age separately for each case in Tables 1 to 5 and representative examples

Table 4

Case 4 Number of calcific deposits at various sites according to age N = numerous (uncertain number more than 15) ↓ = fewer than → = same as ↑ = more than on previous occasion

		4 d	6 w	6 m	15 m	5 y
Hip						
Great trochanter	R	3	↑ 4	↑ 7	→	↓ 0
	L	7	↑ 12	↑ 15	→	↓ 0
Tarsus						
Calcaneus	R	N	→	↓	→	↓ 0
	L	N	→	↓	→	↓ 0

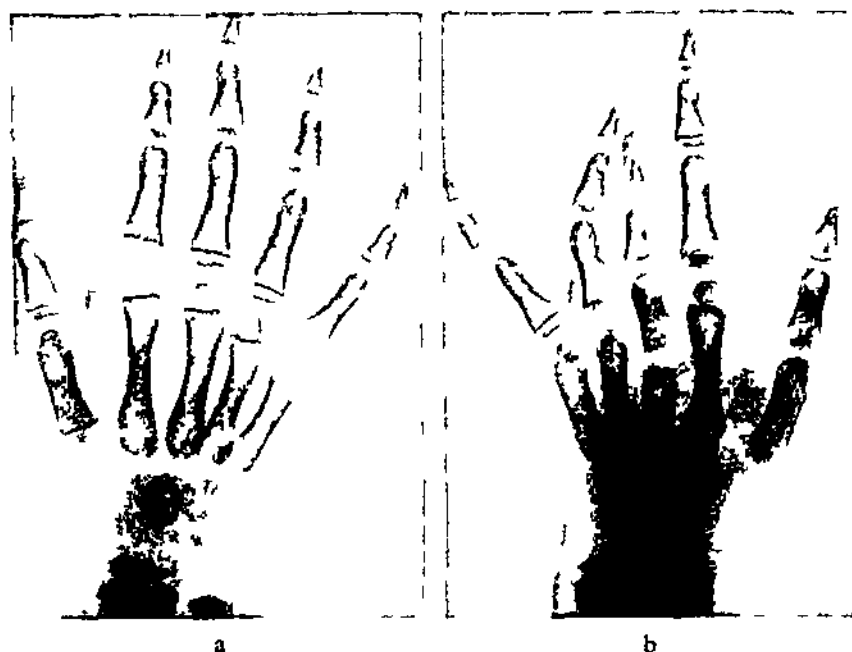


Fig 5 Case 3 a b) 2½ years c d) 5 years Regression of deposits Retarded irregular ossification and abnormal metaphyseal modelling at sites of previous deposits Persistent diaphyseal ossification defect and shortness of tubular bones



Fig 6 Case 4 a b) 4 days Calcific deposits in trochanteric and calcaneal cartilages No calcaneal ossification center c) 6 weeks

are illustrated in Figs 1 to 7 Since at many sites the small deposits were arranged in clusters they could frequently not be counted with certainty but at all sites except two the deposits decreased steadily in number and size The exceptions were the trochanter regions in Case 4 in which the visible deposits increased slightly in number from 4 days to 6 months of age after which they disappeared (Figs 6 7) this sequence of events was similar on both sides In all cases followed up for more than 5 years practically all the deposits proved to have disappeared within that time

In no case was calcification found to occur at a new site but some of the clusters were seen to spread slightly with advancing age before they disappeared (Figs 6 7) This increase in spacing between individual deposits was usually accompanied by a clear decrease in their size Measurement revealed that even the transient increase in number of trochanteric deposits in Case 4 ran parallel to a slight reduction rather than an increase of the total volume of these deposits

Ossification

In most carpals tarsals and epiphyses with multiple deposits in the cartilage and in some with only one deposit ossification was found to commence abnormally late Ossification centers at these sites did not occur until after disappearance or marked regression of the deposits and their development usually remained retarded throughout the follow up (Figs 1 to 7) At sites without deposits the ossification centers were invariably normal

Some of the centers at affected sites deviated from normal also in shape and number In Case 4 for example ossification of the calcaneus in which calcific deposits could neonatally be assigned to an anterior part of the cartilage subsequently developed first from a posterior and later also from an anterior center At 5 years both centers

Table 5

Case 5 Number of calcific deposits at various sites according to age N = numerous (uncertain number more than 15) ↓ fewer than →− same as on previous occasion

		12 m	2 y
Wrist			
Scaphoid	R		0
	L		8
Trapezium	R		10
	L		0
Other carpals	R		3
	L		0
Hand			
2nd–4th metacarpals prox. part	R		N
	L		6
Tarsus			
Talus	R	10	→10
	L	3	↓2
Navicular	R	N	↓5
	L	3	→3
Cuneiforms	R	10	↓0
	L	3	↓0
2nd–4th metatarsals prox. part	R	N	↓N
	I	N	↓N

were still separate and the anterior one had remained undersized (Figs 6 7) The findings in this case were similar in both feet on all occasions

In Case 3 the unilateral calcification of the calcaneus was more widespread neonatally but also in this case the retarded ossification developed from two centers At 2 1/2 years the calcaneus was still bipartite and deposits in its cartilage persisted only in the posterior portion but both parts had remained undersized (Fig 3) Three years later when all the calcaneal deposits had disappeared both parts of the calcaneus were continuously ossified Then the bone did not differ in size or shape from that in the normal left foot

The deposits in the left coracoid process in Case 3 had disappeared already at 16 months whereas ossification at this site was not seen until 4 years later and was then multicentric In the same case the cyst like ossification defect initially surrounding a central calcific deposit in the diaphysis of the left third metacarpal persisted throughout the follow up despite early disappearance of this deposit (Figs 4 5)

Longitudinal growth of tubular bones

At the initial examination the diaphysis was abnormally short in some of the tubular bones with calcific deposits close to the metaphysis (Figs 1 to 5) and in both

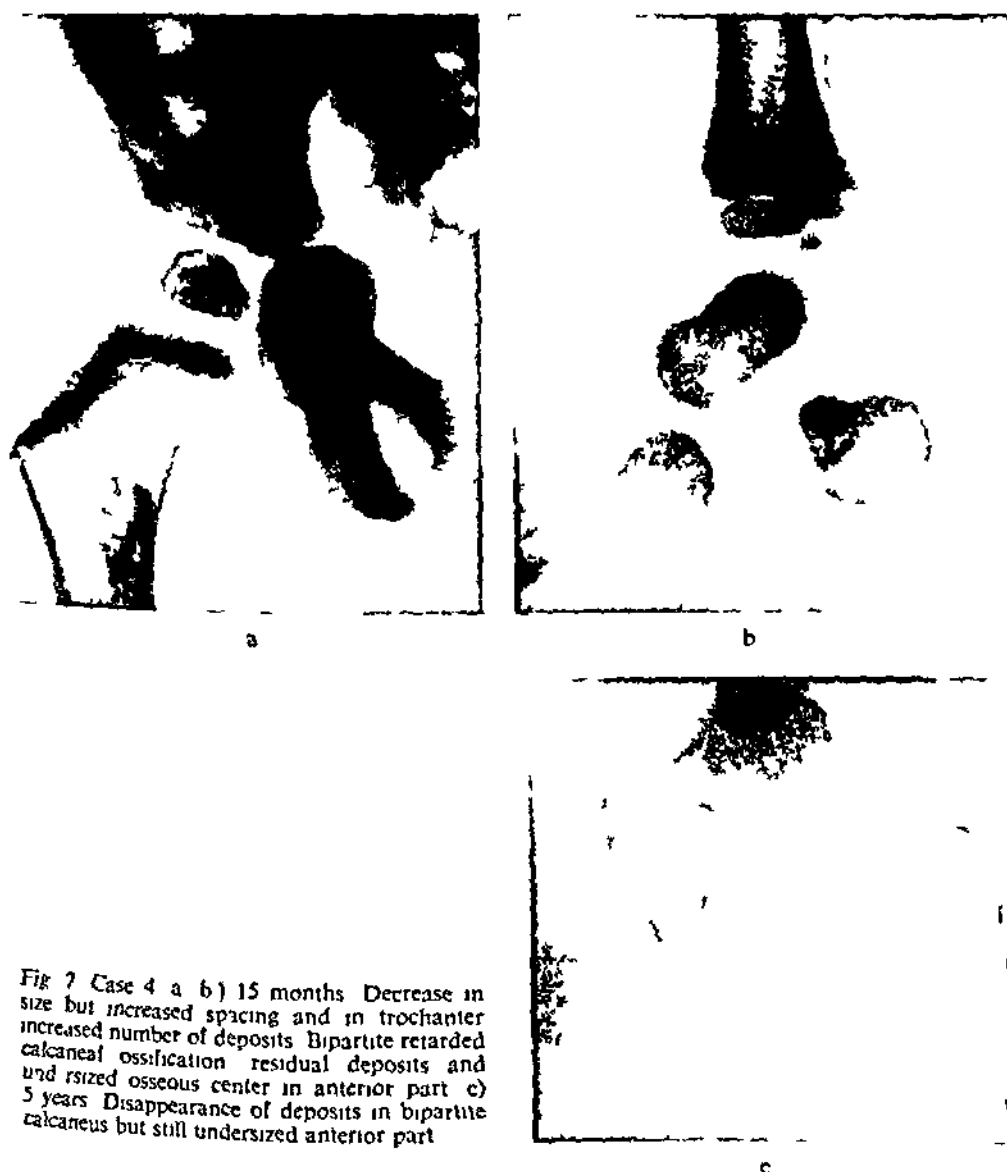


Fig 7 Case 4 a b) 15 months Decrease in size but increased spacing and in trochanter increased number of deposits Bipartite retarded calcaneal ossification residual deposits and und rsized osseous center in anterior part c) 5 years Disappearance of deposits in bipartite calcaneus but still undersized anterior part

of those with a central deposit in the diaphysis (Figs 4 5) In all other tubular bones the length did not differ significantly from normal standards but comparison of one side with the other revealed that at all sites with unilateral calcifications the bone with deposits was shorter than that without In Case 3 a slight difference in length with side was found also in two pairs of finger phalanges without deposits In each of these pairs the longer phalanx was in the normal hand In no case did re examination reveal any deviation in bone length from normal standards or from that on the other side at a new site

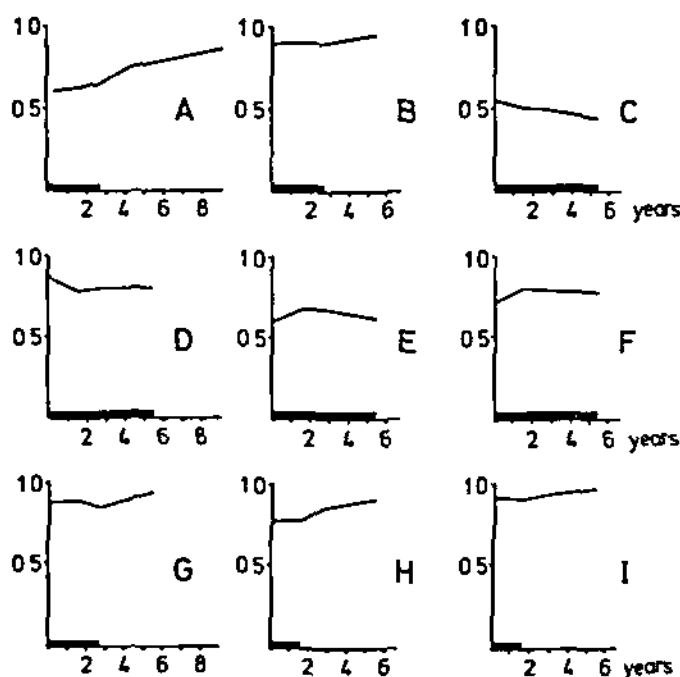


Fig 8 Diaphyseal length quotient according to age (curve) and observed duration of deposits (bar) at sites with unilateral calcification in Case 2 (A) and Case 3 (B-I) A femur B Second metacarpal C Third metacarpal D Fourth metacarpal E Base phalanx of third finger F Base phalanx of fourth finger G Second metatarsal H Third metatarsal I Fourth metatarsal

At some sites with an initial difference in length with side later examinations did not include the entire diaphyses on both sides but most of the differences observed at sites with unilateral deposits could be followed up These differences expressed as quotients are given according to age in the diagrams illustrated in Fig 8 which shows that the relative shortness on the affected side persisted at all sites throughout follow up but often varied in degree from one examination to the next The calcific deposits at the respective sites are also indicated in the diagrams It appears that the degree of shortness might either increase or decrease before but invariably decreased after disappearance of the deposits Changes in length difference preceding disappearance of the deposits occurred almost exclusively before 2 years of a,e

Modelling of bone

The abnormal ossification at sites with calcific deposits was sometimes accompanied by abnormal modelling not only of retarded ossification centers e g in the calcaneus but also of other parts of bones The illustrations give examples observed in the pubic and ischial bones the femoral neck and the distal femoral metaphysis on the right side in Case 2 (Figs 1 2) and in some of the metaphyses in the left hand in Case 3 (Figs 4 5) Such abnormal modelling was on the whole most marked at those sites where the calcific deposits in the cartilage were or had been closest to the ossified portion of the bone

Discussion

The incidence of chondrodysplasia punctata has been estimated by MORCH (1944) and many later authors to be 1 50 000 births In the present series 4 of the children were born in Malmo in 1960 to 1976 representing a 1 14 000 incidence among all births in this city in the period mentioned The true incidence is probably still higher at least for the Conradi Hunermann type since it must be assumed that in some mild cases of this type a radiologic examination will not be performed before the calcifica tions have disappeared

Both types of chondrodysplasia punctata are considered hereditary by most authors but embryopathy caused by some external factor during pregnancy has also been suggested and the etiology and pathogenesis are still obscure Microscopy of cartilage obtained from affected sites mainly in the rhizomelic type has shown the calcific deposits to be situated in the ground substance Various microscopic ab- normalities observed in this and other components of the cartilage or in adjacent osseous tissue seem to reflect both degenerative and reactive processes but it has not been clarified whether these changes are secondary to calcification or vice versa The disappearance of calcifications may be attributed to vascular granulation tissue with giant cells which has been found at sites of absorption in the cartilage (MOSEKILDE)

DE TONI (1948) described a case of chondrodysplasia punctata in which calcifica tion of cartilages progressed markedly between 5 days and 11 months of age In another case reported by SELAKOVICH & WHITE (1955) calcific deposits in the talus seemed to increase slightly in number but this statement appears less convincing No further case seems to be on record in which deposits have been claimed to in crease in number or size or to occur at new sites On the other hand disappearance or regression of the deposits has been established in many cases

In the present series the calcific deposits at all sites seem to have undergone steady regression after birth The transient increase in number of the deposits in the tro chanters in one of the cases cannot be considered a true progression since these deposits did not increase in total volume The increase in number in this case was probably caused by fragmentation but since minute deposits are difficult to dis criminate radiologically if they are closely packed a virtual increase in their number might also result from merely spatial separation Such increase in spacing evidently occurred at some sites in the present cases and indicates growth of the cartilage

Several authors have claimed that at sites with calcific deposits the ossification centers may be supernumerary or untimely absent It has also been observed that tubular bones with epiphyseal deposits may be both shorter than normal and ab- normally shaped The present findings agree with these observations and suggest that even within an individual cartilage a spatial relationship exists between calcifica tion and disturbed ossification and growth In the proximal end of the femur for example such disturbances may affect either the trochanter or the femoral head if not both and in the calcaneus ossification may develop at differing rates from sepa

rate centers apparently depending on the distribution of deposits in the cartilage In the tubular bones proximity of epiphyseal deposits to the metaphyseal surface seems to prevent proper modelling of the affected end

Also the temporal relationship between the calcification and the osseous abnormalities has been discussed by some authors though systematic observations at follow up have been only scanty The present series illustrates that both ossification and growth may be locally retarded before disappearance of the deposits The measurements of the tubular bones suggest however that retardation of longitudinal growth will usually not continue after 2 years of age not even if the epiphyseal deposits persist longer They also suggest that any relative shortness of an affected tubular bone may be expected to improve slightly after disappearance of the local deposits because by that time longitudinal growth of this bone tends to accelerate as compared with the rate of growth on the opposite side It should be mentioned that KAUFMANN et coll (1976) who reported on calcifications in tracheal and laryngeal cartilages in 3 cases of chondrodysplasia punctata found growth to be retarded at the affected sites as long as the deposits persisted In one of their patients in whom the deposits disappeared the cartilage afterwards seemed to grow normally

It is evident from the marked shortness of limbs at birth in many cases of chondrodysplasia punctata that the underlying disease may commence in a relatively early stage of intrauterine life The calcific deposits seem to have been clearly demonstrated in utero in only 2 cases (BERGSTRÖM et coll 1972 HYNDMAN et coll 1976) but HAYNES & WANGNER (1951) reported that during a previous pregnancy which ended by abortion of a cyclopic monster the mother of a baby with the lethal type of chondrodysplasia punctata had been submitted to radiologic examination already in the sixth month of gestation The findings on that occasion suggested both punctate epiphyseal calcification and shortness of fetal limbs Since in survivors the deposits seem usually to regress steadily before they disappear and to progress only exceptionally it might be assumed that in most cases regression also has commenced already in utero This would explain why in some cases with unilateral changes shortness of tubular bones is found on the affected side also at sites where no deposits existed at birth

It is also possible that the unknown disorder responsible for the calcification may affect the fetal cartilages at different times The findings in the left hand in one of the present cases is interesting in this respect because two diaphyses initially had central calcific deposits Such intradiaphyseal deposits which have apparently never been reported before might reflect an unusually early onset of calcification at these sites The early disappearance of the intradiaphyseal deposits as well as the fact that the affected diaphyses were particularly short and plump would also seem consistent with this assumption

SUMMARY

In 5 children with chondrodysplasia punctata the calcification in the cartilage was investigated by radiologic follow-up ranging from 11 months to 16 years Intimate spatial rela

tions were found between calcific deposits and disturbances in ossification and skeletal growth The temporal relationship was also analysed

ZUSAMMENFASSUNG

Bei 5 Kindern mit Chondrodysplasia punctata wurden Knorpelverkalkungen radiologisch nachgewiesen und mit nochmahligen Untersuchungen wahrend 11 Monate bis 16 Jahre gefolgt Genaue Lagebeziehungen zwischen den Verkalkungen und Storungen der Verknocherung sowie des Zuwachses des Skeletts wurden beobachtet Auch die Zeitrelationen wurden analysiert

RÉSUME

Chez 5 enfants atteints de chondrodysplasie ponctuée la calcification dans le cartilage a ete etudiee par une surveillance radiologique allant de 11 mois a 16 ans Les auteurs ont trouvé des relations spatiales étroites entre les dépots calciques et les troubles de l ossification et la croissance squelettique Ils ont aussi étudié les relations temporelles

REFERENCES

Bergstrom K Gustavsson K H and Jorulf H Chondrodystrophia calcificans congenita (Conradi s disease) in a mother and her child Clin Genet 3 (1972) 158

Conradi E Vorzeitiges Auftreten von Knochen und eigenartigen Verkalkungskernen bei Chondrodystrophia fetalis hypoplastica Histologische und Rontgenuntersuchungen Jahrb Kinderheilk 80 (1914) 86

Haynes E R and Wangner W F Chondroangiopathia calcarea seu punctata Radiology 57 (1951) 547

Hewitt H L and van Bochove W M Chondrodystrophia calcificans congenita Radiol Clin Biol 40 (1971) 175

Hyndman W B Alexander D S and Mackie K W Chondrodystrophia calcificans congenita (The Conradi Hunermann syndrome) Clin Ped 15 (1976) 317

Kaufmann H J Mahboubi S Spackman T J Capitanio M A and Kirkpatrick J Tracheal stenosis as a complication of chondrodysplasia punctata Ann Radiol 19 (1976) 203

Mosekilde E Chondroangiopathia calcarea seu punctata *In* Encyclopedia of medical radiology Vol 5 Part 3 Edited by L Diethelm O Olsson F Strnad H Vieten and A Zuppinger Springer Verlag Berlin Heidelberg New York 1968

Morch E T Discussion of the paper of Gørtz (In Danish) Nord Med 21 (1944) 375

Poznanski A K The hand in radiologic diagnosis W B Saunders Company Philadelphia London Toronto 1974

Schmid F Padiatrische Radiologie Band 1 Springer Verlag Berlin Heidelberg New York 1973

Selakovich W G and White J Chondrodystrophia calcificans congenita Report of a case J Bone Jt Surg 37 A (1955) 1271

SPRANGER J W BIDDER U und VOELZ C Chondrodysplasia punctata (Chondrodystrophia calcificans) I Typ Conradi Hunermann Fortschr Rontgenstr 113 (1970) 717

— — — Chondrodysplasia punctata (Chondrodystrophia calcificans) II Der rhizomele Typ Fortschr Rontgenstr 114 (1971) 327

DE TONI G e PAPIO F Condrodistrofia congenita calcificante primo contributo casistico italiano (In Italian) Policlin infant 16 (1948) 3

FROM THE DEPARTMENTS OF ORTHOPEDIC SURGERY (DIRECTOR PROF T HIERTON) AND DIAGNOSTIC RADIOLOGY (DIRECTOR PROF H LODIN) AKADEMISKA SJUKHUSET S 750 14 UPPSALA SWEDEN

SIMULTANEOUS ARTHROGRAPHY OF THE TALOCRURAL AND TALONAVICULAR JOINTS IN CHILDREN

IV Measurements on congenital club feet

Å HJELMSTEDT and B SAHLSTEDT

By simultaneous arthrography of the talocrural and talonavicular joints a demonstration of the anatomy the topographic relation between the bones and the shape of the talus may be obtained (Part II HJELMSTEDT & SAHLSTEDT 1976) In small children this is not obtainable by conventional radiography The choice of treatment of certain foot deformities is facilitated by this information

Arthrographies were performed on 41 children with congenital club foot in order to elucidate the degree and frequency of talar deformity in this condition and to determine

1) The relation between the length of the talus and the width of the talar trochlea and the possibility of using these measurements for assessing other age dependent dimensions

2) The radius chord and central angle of the trochlear curvature and the plantar and medial deviations of the talonavicular joint

3) The size of the talocrural recesses whether any communication between the punctured joints and adjacent joints and tendon sheaths existed

Submitted for publication 14 May 1976

Table 1

Treatment before the arthrography

	Number of feet		
	Group I	Group II	Total
Cons rvative treatment correction – plaster	19	10	29
Conservativ treatment lengthening of tendo Achilles	2	13	15
Conservativ treatment lengthening of Achilles and posterior tibial muscle tendons	2	2	4
Conservative treatment lengthening of Achilles and posterior tibial muscle tendons – transfer of anterior tibial muscle	0	2	2
Further soft tissue intervention Medial release	0	2	2
Calcaneal osteotomy according to Dwyer	0	7	7
	23	36	59

4) Whether and in what way the talar variables change over a long period of time

5) Whether there is any relation between the degree of deformity in the talocrural and talonavicular joints

Material

Arthrographies were performed on 63 congenital club feet in 41 patients (30 boys and 11 girls) during the period August 1970 to December 1974 The patients were divided into two groups

Group I (consecutive series) originally comprised 20 consecutively treated patients with 29 congenital club feet whose primary treatment was begun during the period in qu stion Arthrography was not p rformed in 3 patients with bilateral club feet that were easily corrected hitherto the result of the conservative treatment in these children is satisfactory In group I thus remained 17 patients with 23 congenital club feet

Group II (s lected group) comprised 24 patients with 40 congenital club feet whose treatment was started before August 1970 or who had been primarily treat d in an other hospital This group consisted mostly of refractory cases In 4 pati nts with bilateral club feet only one foot was examined arthrographically Thus in group II arthrography was p rformed on 24 patients with 36 cong nital club feet

The total material thus consisted of films from 59 congenital club feet 17 club feet *were examined more than onc and for these patients the results from the latest* arthrography are reported

Before the arthrography the club feet had been treated as described in Table 1 In the consecutive s ries (23 feet) 19 had been treated only by correction and plast r of Paris and in 4 feet the tendo Achilles had been lengthened in 2 of the latter the tendon of the posterior tibial muscle had also been lengthened In group II (36 feet) 10 feet had been treated conservatively while 26 feet had also had soft tissue op ra

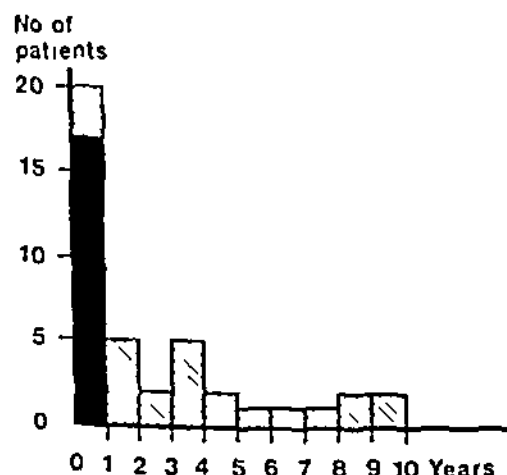


Fig. 1 Age at first arthrography ■ consecutive series (group I) □ selected series (group II)

tions of varying extent in 7 of the latter calcaneal osteotomy by the Dwyer method had also been performed

The ages of the patients at the first arthrography varied between 3 weeks and 9 years In the consecutive series the first arthrography was performed during the first year of life (Fig 1)

Arthrographic technique This has been described in detail previously (Part I SAHLSTEDT 1976) The examinations were carried out under general anaesthesia and in almost all patients bilaterally Following puncture of the talonavicular and talocrural joints in that order contrast medium was injected into the joints at a pressure of about 100 cm H_2O Four standardized projections were used a p a p with the ankle inwardly rotated lateral and dorso-plantar Measurements were made on the films as described in part I Examples are presented in Fig 2

Table 2

Normal limits for the talar variables The values are expressed as 95 tolerance limits which with 90 p obability include 95 of a normal population and were obtained in an arthrographic material of 54 normal feet in children (Hjelmstedt & Sahlstedt 1976) R = radius and C = chord of the trochlear curvature L = length of the talus W = width of the trochlea

Variable	Mean	Standard deviation	95 tolerance limits
R/L	0 35	0 03	0 29-0 42
R/W	0 68	0 07	0 5--0 84
C/L	0 66	0 05	0 55-0 78
C/W	1 30	0 13	1 00-1 60
Central angle (α) of trochlear curvature	154	8.3	135 -173
Plantar deviation (β) of talonavicular joint	24	4 6	14 -35
Medial deviation (γ) of talonavicular joint	15	3 1	8 -22



Fig. 2 a) Severe club foot deformity in a 1½-year-old boy Lateral view of the ankle Flattening of the trochlear curvature and circular appearance of the talonavicular joint due to its marked medial deviation Spontaneous filling of a medial tendon sheath. b) Dorso-plantar view of the foot. Considerable medial deviation of the talonavicular joint.

Results

The normal values used for reference (Table 2) are based on the previous results (Parts II III HJELMSTEDT & SAHLSTEDT 1976 1977) In evaluating the club feet values outside the 95 per cent tolerance limits of the normal material were regarded as pathologic

1) *Relation between length of talus (L) and width of talar trochlea (W)* In normal cases as a reference when assessing age-dependent variables either the length of the talus or the width of the trochlea may be used as these are linearly correlated (HJELMSTEDT & SAHLSTEDT) A relatively constant linear correlation was also found between these variables in the club foot material r = 0 94 (Fig 3)

2 a) *The radius of the trochlear curvature (R)* increases obviously with talar growth In normal feet this radius is linearly related to the length of the talus (L) Thus the index R/L is relatively constant The mean value and 95 per cent tolerance limits of the index are given in Table 2.

A high index indicates that the radius is abnormally large in relation to the length of the talus i e that the trochlea is flattened

Of the 23 club feet in the consecutive series 13 (57 %) had a normal R/L index and 10 (43 %) an increased value (Table 3) In the selected series of 36 club feet this index was normal in 16 (44 %) and increased (i e the trochlea was flattened) in 20 (56 %) The mean R/L index was clearly lower in group I than in group II (Table 4)

The width of the trochlea (W) also has a constant linear relationship to the radius of the trochlear curvature The mean normal index R/W and the 95 per cent tolerance limits are given in Table 2. Also in this case a high index is an indication of flattening of the talar trochlea.

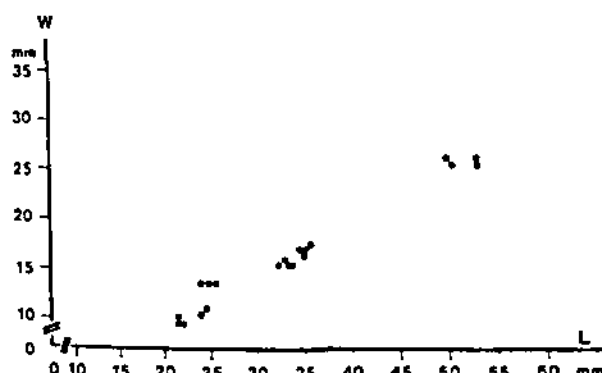


Fig 3 Linear relationship (r = 0 94) between the length of the talus (L) and the width of the trochlea (W)

In the consecutive series of 23 club feet 14 (61 %) had a normal R/W index and 9 (39) an increased index In the selected series of 36 club feet this index was normal in 13 (36) and increased in 23 (64 %)

2 b) *The chord of the talar trochlea* (C) In the lateral view the chord connects the anterior and posterior margins of the trochlea and is tangential to the lowest point of the ankle recesses It has previously been demonstrated (Part III) that in normal feet the chord has a relatively constant linear relationship to the length of the talus (L) The normal mean value and 95 per cent tolerance limits of the index C/L are given in Table 2

In the consecutive series of 23 club feet 17 (74 %) had a normal C/L index Six of the 23 feet (26 %) had a raised index In the selected group this index was normal in 34 (94) of the 36 club feet and increased in 2 (6) (Table 5) The mean values of the two groups did not differ appreciably (Table 4)

The width of the trochlea also has a fairly constant linear relationship to the chord in normal feet The mean value and 95 per cent tolerance limits of the index C/W are given in Table 2

Of the 23 club feet in the consecutive series 16 (69) had a normal C/W index and

Table 3

Distribution of R/L indic s in th lub foot mat rial 0 4? and 0 44 are th upp r 9 a 1 99 tolerance limits respectively in n al aterial Group I = consecutive s ries G p II – l ted series

R/L	Number of feet		
	Group I	Group II	Total
≤0 42	13	16	29
0 43–0 44	4	1	5
0 45–0 47	3	8	11
≥0 48	3	11	14
	23	36	59

Table 4

A comparison between the consecutive and selected series of club feet The talus of the feet in the latter series was generally more deformed

Variable	Mean and range		
	Group I	Group II	Total
R/L	0 42	0 47	0 45
	0 38–0 49	0 35–0 85	0 35–0 85
C/L	0 75	0 73	0 74
	0 69–0 88	0 64–0 80	0 64–0 88
Central angle (α) of trochlear curvature	127	108	116
	108–150	53–142	53 150
Plantar deviation (β) of talonavicular joint	34	39	37
	15–53	21–65	15–65
Medial deviation (γ) of talonavicular joint	33	47	42
	12–53	24–66	12–66

7 (31 %) an abnormally high index In the selected group this index was normal in 26 (72 %) of the 36 club feet and increased in 10 (28 %)

2 c) *Central angle of the trochlear curvature* The normal value and 95 per cent tolerance limits appear in Table 2

Of the 23 club feet in the consecutive series 7 (30 %) had a normal angle and 16 (70 %) a reduced angle In the selected series only 2 (6 %) of the 36 club feet had a normal angle while in 34 (94 %) the angle was clearly reduced (Table 6) The mean central angle was distinctly higher in the consecutive than in the selected series (Table 4)

2 d) *Plantar deviation of the talonavicular joint* (navicular facet) Normal value and 95 per cent tolerance limits are given in Table 2

In 12 (52 %) of the 23 club feet in the consecutive series the talonavicular joint deviated in a normal way in the plantar direction In the other 11 (48 %) the plantar

Table 5

Distribution of C/L indices in the club foot material 0 78 and 0 81 are the upper 95 and 99 tolerance limits respectively in a normal material Group I = consecutive series Group II = selected series

C/L	Number of feet		
	Group I	Group II	Total
≤0 78	17	34	51
0 79–0 81	4	1	5
0 82–0 86	1	1	2
≥0 87	1	0	1
	23	36	59

Table 6

Distribution of central angles (α) of the trochlear curvature in the club foot mat rial 135 and 129° are the lower 95 and 99 tolerance limits respectively In a normal material Group I – consecutive series Group II – selected series

Central angle (α) of trochlear curvature	Number of feet		
	Group I	Group II	Total
> 135	7	2	9
134 –129	2	1	3
128 –110	12	17	29
109 –90	2	12	14
< 89	0	4	4
	23	36	59

deviation was pathologically accentuated In the selected group only 12 feet (33 %) exhibited normal plantar deviation (Table 7) The mean plantar deviation was some what lower in group I than in group II (Table 4)

2 e) *Medial deviation of talonavicular joint* (navicular facet) in relation to longitudinal axis of trochlea The normal value and 95 per cent tolerance limits of this variable are given in Table 2

In the consecutive series this deviation was normal in 4 (17 %) of the 23 club feet and increased in 19 (83 %) In the selected series only one (3 %) of the 36 club feet was normal (Table 8) The mean deviation of the talonavicular joint was considerably smaller in the consecutive than in the selected series (Table 4)

Sixteen of the 59 club feet were unilateral and thus in these cases the talus could be directly compared with that of the normal foot It was found in these comparisons that the width of the trochlea was affected more than the length of the talus by the

Table 7

Distribution of plantar deviations (β) of the talonavicular joint in the club foot material 35 and 38 are the upper 95 and 99 tolerance limits respectively in a normal material Group I – consecutive series Group II – sel cted series

Plantar deviation (β) of the talonavicular joint	Number of feet		
	Group I	Group II	Total
< 35	12	12	24
36 –38	5	6	11
39 –47	2	12	14
48 –56	4	5	9
> 57	0	1	1
	23	36	59

Table 8

Distribution of medial deviations (γ) of the talonavicular joint in the club foot material 22 and 24 are the upper 95 and 99 tolerance limits respectively in a normal material Group I = consecutive series Group II = selected series

Medial deviation (γ) of the talonavicular joint	Number of feet		
	Group I	Group II	Total
22	4	1	5
23 -24	1	1	2
25 -39	9	8	17
40 -54	9	16	25
55	0	10	10
	23	36	59

deformation The mean trochlear width was 12 per cent smaller in the club feet than in the normal feet (range of difference +3 to −24 %) The deformed talus was on the average 7 per cent shorter than the normal talus (range +3 to −18 %) The length of the talus is therefore recommended as a reference in evaluations of the growth dependent variables R and C One advantage of using this reference is that R C and L are all to be found in the same (lateral) view Thus the calculated indices R/L and C/L will not be affected by any errors of magnification

3 a) *The talocrural recesses* were graded according to a scale a–c where (a) implied no or only very slight reduction of the size of the recesses (b) moderate reduction and (c) subtotal or total obliteration of the anterior and posterior recesses

Of the 23 club feet in the consecutive series 7 (30 5 %) were assigned to grade (a) 9 (39 %) to grade (b) and 7 (30 5 %) to grade (c) Of the 36 club feet in the selected series only 5 (14 %) were graded (a) whereas 20 (56 %) were graded (b) and 11 (30 %) (c)

When the central angle of the trochlear curvature was related to the size of the recesses in the total club foot material the mean angle in grade (a) was found to be 129 (range 109–142) in grade (b) 116 (range 91–143) and in grade (c) 105° (range 53–150)

3 b) *Filling of adjacent joints and tendon sheaths* From the talocrural joint the posterior subtalar joint was spontaneously filled with contrast medium in 10 (17 %) of the total 59 club feet Posterior medial tendon sheaths were filled from the talocrural joint in 20 (34 %) No filling of lateral tendon sheaths was observed From the talonavicular joint the anterior subtalar joint was spontaneously filled with contrast medium in 38 (64 %) the calcaneo-cuboidal joint in 9 (15 %) and the joints between the navicular and cuneiform bones in 4 (7 %)

4) *Repeated examinations of the same foot* Repeat arthrography was performed in 17 club feet on two occasions The mean age of the patients at the first examination was 11 months and the mean interval between the examinations was also 11 months

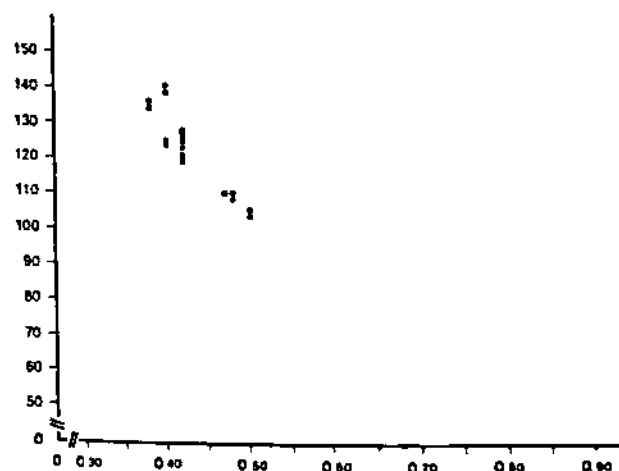


Fig 4 The central angle (x) of the trochlear curvature plotted against the index R/L. Relatively strong correlation (r = 0 79) between reduction of the central angle and flattening of the trochlea (high values of the index R/L)

Between the examinations the tendo Achilles was lengthened in 3 of the feet In 3 other feet the tendon of the posterior tibial muscle was also lengthened with transference of the anterior tibial muscle tendon The other 11 feet were not operated upon

During the interval between the arthrographies the radius of the trochlear curvature (R) increased on the average by 3 4 mm the length of the talus (L) by 7 8 mm and the chord (C) by 5 2 mm The other mean differences were small thus the central angle of the trochlear curvature increased by 1 2 the plantar deviation of the talonavicular joint by 1 8 and the medial deviation of the talonavicular joint by 2 6 The relation between the radius of the trochlear curvature and the length of the talus and that between the chord of the trochlea and the length of the talus remained essentially unchanged Thus the index R/L increased by only 0 005 and C/L by 0 006 In 6 of 17 feet the ankle recesses decreased in size during the interval between examinations

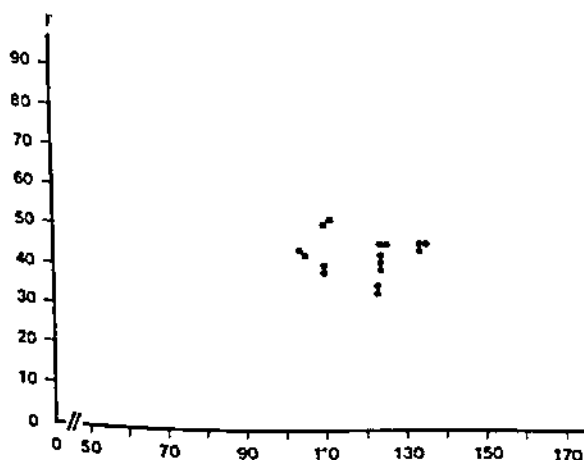


Fig. 5 The medial deviation (y) of the talonavicular joint plotted against the central angle (x) of the trochlear curvature Moderate tendency (r = 0.50) towards increasing medial deviation of the talonavicular joint with a reduction of the central angle of the trochlear curvature

5) *Correlation between degree of deformation in the talocrural and talonavicular joints* In the club foot material a relatively clear correlation existed between the central angle of the trochlear curvature and the flattening of the trochlea Thus a relatively strong correlation was found between central angle reduction and increasing R/L index r = 0 79 (Fig 4)

Further there was a moderate covariation between the central angle of the trochlear curvature and the medial deviation of the talonavicular joint with a tendency to greater medial deviations with small central angles r = 0 50 (Fig 5)

Only a weak correlation was found between the central angle of the trochlear curvature and the plantar deviation of the talonavicular joint r = 0 15

No evident covariation was observed between the plantar deviation of the talonavicular joint and changes of the index R/L r = 0 20 Neither was there any covariation between the plantar and medial deviations of the talonavicular joint r = 0 20

The medial deviation of the talonavicular joint showed no appreciable correlation to the index R/L r = 0 16

Discussion

Normal values for the talar variables in question for children up to 8 years of age or more exactly with a talar length (L) of up to 57 mm or a trochlear width (W) of up to 31 5 mm have been presented by HJELMSTEDT & SAHLSTEDT In the present investigation a good correlation was found between L and W

Further it was demonstrated that the problems of such age dependent factors as the radius (R) and chord (C) of the trochlear curvature could be solved by correlating them to L or W Thus each of the indices R/L R/W C/L and C/W is relatively constantly independent of age (up to 8 years)

Even in the club foot material L and W were well correlated (Fig 3) However in patients with unilateral club foot the deformed talus was 7 per cent shorter than the normal talus and the trochlea of the deformed talus 12 per cent narrower than that on the normal side As a reference measure for comparison with normal material L is therefore preferable to W A further advantage of using L is that R C and L are all measured on the same film and that the indices R/L and C/L are thus not influenced by errors of magnification

When the trochlea is flattened the radius of its curvature (R) increases On the other hand R also increases with growth and therefore can never be used directly as a measure of the degree of flattening The analysis of normal feet has shown that the index R/L is relatively constant i e R and L increase proportionately through the years If on the other hand the trochlea is flattened R increases proportionately more than L i e the index R/L becomes greater This index seems to allow a good estimate of the curvature of flattening of the trochlea and in the present material it did not alter in the 11 month interval between two arthrographies

Flattening of the trochlea was observed in about 40 per cent of the consecutive series of club feet and in about 60 per cent of the club feet in the selected series Some

flattening is thus usual in club foot As no arthrographies were performed before the start of treatment it cannot be stated whether or not the treatment contributed to the flattening Autopsy material has revealed however that some flattening of the trochlea may already be present at birth (ADAMS 1854 KOCHER 1879 BISSEL 1888 SETTLE 1963)

In the consecutive series the patients were treated according to standardized principles by one and the same orthopaedic surgeon (with the exception of short periods of time) and therapeutic differences cannot therefore explain the fact that the trochlea was flattened in about 40 per cent of the cases and not in the others It seems reasonable to assume that in those cases where flattening was observed this had been present since birth though some deterioration might have occurred later

The chord of the trochlea cannot be assessed as a single entity but must be related to the length of the talus This chord and the length of the talus are linearly correlated and for normal cases the index C/L is constant

The length of the talus (L) is approximately the sum of the chord of the trochlea (C) and the length of the talar head and neck A high C/L index may thus be due to an abnormally long chord an abnormally short talar head and neck or a combination of the two This index was increased in a minority of the club feet In the majority it was normal implying that a decrease in length of the talar head and neck is accompanied by an approximately corresponding reduction of the length (=chord) of the trochlea Thus in most cases of club foot the chord is normal and in a small number it is relatively slightly increased

The central angle of the trochlear curvature is reduced when the trochlea is flattened i e when the R/L index is raised (Fig 4) A clear correlation was also found between the reduction of the central angle and the degree of obliteration of the ankle recesses A reduction of this angle must imply some restriction of the ankle mobility which is probably irreversible In 70 per cent of the club feet in the consecutive series and 94 per cent of those in the selected series this central angle was distinctly reduced This may be regarded as indicating that the majority of club feet lack the prerequisites for full restoration of ankle mobility

Normal joint recesses are necessary for full joint movement Partial or total obliteration of the recesses may be either a result or a cause of reduced joint mobility Only a minority of the club feet had normal talocrural recesses The recesses of the talonavicular joint were sometimes difficult to assess and therefore no attempt at classification was made

Medial or plantar subluxation or luxation of the navicular bone is an essential feature of the club foot deformity The head of the talus then presents a newly formed articular facet against the navicular and frequently the talonavicular recesses are partly or almost completely obliterated The plantar deviation of this new articular facet was markedly accentuated in half of the club feet in the consecutive series and in two thirds of those in the selected series The medial deviation was accentuated in about 80 per cent of the former club feet and in practically all of the latter The

results for the consecutive series show that full correction was achieved in only a minority of the cases Possibly the same holds for the talonavicular as for the talocrural joint i e that the joint is already altered to such an extent at birth that full restoration is not possible Some correlation exists between the degree of medial and of plantar deviation but too weak to be of real interest

It was hoped that the anatomic findings would have allowed a classification of club foot deformities Had there been a good correlation between the changes in the talocrural and talonavicular joints this would have been possible However, there was only very slight correlation between the central angle of the trochlear curvature and the medial deviation of the talonavicular joint As no such classification can be made each case must be evaluated individually and the treatment chosen on the basis of the clinical and arthrographic findings

Spontaneous filling of the posterior subtalar joint and of the medial tendon sheaths occurs in a higher frequency in series of club feet than in normal feet in adults (BROSTRÖM et coll 15 6 and 22 %, LUNING et coll 10 % and 14 %, MEYER 12 % and 10 % respectively) and children (SAHLSTEDT 5 % and 4 5 %) The reason for this is not clear

Conclusions

1) As was demonstrated previously on a normal material (Part III) a good correlation exists between the length of the talus and the width of the talar trochlea in this series of club feet

2) Both of these variables may be used as reference measures for the size of the talus but of the two the length of the talus is preferable

3) In this series of club feet there was a clear correlation between changes of the central angle of the trochlear curvature and flattening of the trochlea expressed as the index R/L where R is the radius of the trochlear curvature and L the length of the talus

4) The correlation between the central angle of the trochlear curvature and the medial deviation of the talonavicular joint was weak

5) Some relationship between the central angle of the trochlear curvature and the size of the ankle recesses was found

6) No other correlation existed between the different variables examined which means that a classification of the club feet according to anatomic criteria does not seem possible

7) In the consecutive series of club feet it was found that (a) the trochlea was flattened in about 40 per cent of the cases (b) the central angle of the trochlear curvature was reduced in about 70 per cent of the cases (c) the ankle recesses were smaller than the normal in two-thirds of the cases (d) in half of the cases the plantar deviation of the talonavicular joint was accentuated (e) in four fifths of the cases the medial deviation of the talonavicular joint was accentuated

8) In the selected series which comprised relatively refractory cases the frequency

of deviations from normal values was greater than in the consecutive series and the measured values were often extreme

9) Repeat arthrographies performed after a mean interval of 11 months revealed no changes of measurable skeletal deformities but in one third of the cases the ankle recesses seemed to have decreased in size

10) Spontaneous filling of the posterior subtalar joint and of medial tendon sheaths occurred in a higher frequency in this material of club feet than has been observed previously in normal feet in children

11) The arthrographic method employed gives reliable anatomic information which is of value both in the choice of therapeutic method in refractory or recurrent club foot and for assessing the prognosis

SUMMARY

Simultaneous arthrography of the talocrural and talonavicular joints was performed on 59 club feet in 41 children The material was divided into a consecutive and a selected series the latter consisting mainly of more severe cases The consecutive series allowed an estimation of the frequency and degree of skeletal deformity in an ordinary club foot material In about 40 per cent of the cases the trochlea of the talus was flattened and in 70 per cent the central angle of the trochlear curvature was reduced and the ankle recesses smaller than normally The majority of club feet exhibited increased medial or plantar deviation of the talonavicular joint A correlation between the central angle of the trochlear curvature and the flattening of the trochlea and between this central angle and the size of the ankle recesses was found Otherwise there were no or only weak correlations between the investigated variables which meant that classification of the deformities on the basis of anatomic findings was not possible The arthrographic survey of the anatomy provides good guidance with respect to the choice of treatment in refractory and recurrent club feet It also gives prognostic information

ZUSAMMENFASSUNG

Eine gleichzeitige Arthrographie der talo-cruralen und talo-navicularen Gelenke bei 59 Klumpfussen von 41 Kindern wurde vorgenommen Das Material war in eine konsekutive und eine selektive Gruppe aufgeteilt die letztere umfasste vorwiegend die schweren Falle Die konsekutive Gruppe ermoglichte es die Haufigkeit und das Ausmass von Skelett Deformierung in einem gewohnlichen Klumpfuss Material abzuschatzen In etwa 40% der Falle waren Trochlea und Talus abgeflacht und in 70 der zentrale Winkel der Kurvatur der Trochlea reduziert und der Knochel Rezessus kleiner als normal Die meisten Klumpfusse zeigten eine gesteigerte mediale oder plantare Abweichung des talo navicularen Gelenks Eine Korrelation zwischen dem zentralen Winkel der Kurvatur der Trochlea und der Abflachung der Trochlea existierte und auch zwischen dem zentralen Winkel und der Grosse des Knochel Rezessus Im ubrigen fanden sich keine oder nur schwache Korrelationen zwischen den untersuchten Variablen Das bedeutet dass eine Klassifikation der Deformationen auf der Basis der anatomischen Befunde nicht moglich war Die arthrographische Übersicht der Anatomie gibt eine gute Leitung hinsichtlich der Wahl der Behandlung bei dem refraktaren und wiederauftretenden Klumpfuss Sie gibt ebenfalls eine prognostische Information

RESUME

Les auteurs ont fait des arthrographies simultanées des articulations tibio tarsiennes et astragalo scaphoidiennes sur 59 pieds bots chez 41 enfants Ce matériel a éte divisé en une série consecutive et une série selectionnee cette dernière comprenant principalement les cas les plus severes La serie consecutive a permis une estimation de la fréquence et du degré de la deformation squelettique dans une serie de pieds bots ordinaires Dans environ 40% des cas la trochlee de l astragale est aplatie et dans 70% l angle central de la courbure trochléenne est reduit et les recessus de la cheville sont plus petits que normalement Dans la majorité des pieds bots la deviation interne ou plantaire de l articulation astragalo scaphoidienne est augmentee Les auteurs ont trouvé une corrélation entre l angle central de la courbure trochléenne et l aplatissement de la trochlée et entre cet angle central et les dimensions des recessus de la cheville Par ailleurs il n y avait pas ou seulement peu de correlation entre les variables examinees ce qui signifie qu il n est pas possible de classer ces deformations sur la base des constatations anatomiques L etude arthrographique de l anatomie fournit de bonnes indications en ce qui concerne le choix du traitement dans les pieds bots réfractaires et réci divants elle donne aussi des informations pronostiques

REFERENCES

ADAMS W A series of four specimens illustrating the morbid anatomy of congenital club-foot (talipes varus) Trans path Soc Lond 3 (1854–55) 348

BISSEL J B The morbid anatomy of congenital talipes equinovarus Arch Pediat 5 (1888) 406

BROSTROM L LILJEDAHL S O and LINDVALL N Sprained ankles II Arthrographic diagnosis of recent ligament ruptures Acta chir scand 129 (1965) 485

HJELMSTEDT Å and SAHLSTEDT B Simultaneous arthrography of the talocrural and talona vicular joints in children II Comparison between anatomic and arthrographic measure ments Acta radiol Diagnosis 17 (1976) 557

— — Simultaneous arthrography of the talocrural and talonavicular joints in children III Measurements on normal feet Acta radiol Diagnosis 18 (1977) 513

KOCHER T Zur Aetiologie und Therapie des Pes varus congenitus Dtsch Z Chir 9 (1879) 329

LUNING M BURGER K und BIEDERMANN F Das normale Arthrogramm des oberen Sprung gelenkes und seine Varianten Radiol diagn (Berl) 9 (1968) 57

MEYER J M L arthrographie de l articulation sous astragalienne posterieure et de l articula tion de Chopard Thèse 3318 Genève 1973

SAHLSTEDT B Simultaneous arthrography of the talocrural and talonavicular joints in children I Technique Acta radiol Diagnosis 17 (1976) 545

SETTLE G W The anatomy of congenital talipes equinovarus Sixteen dissected specimens J Bone Jt Surg 45 A (1963) 1341

FROM THE SECTION OF PEDIATRIC RADIOLOGY DEPARTMENT OF DIAGNOSTIC RADIOLOGY
MALMÖ ALLMANNA SJUKHUS S 214 01 MALMÖ SWEDEN

PARTIAL DISAPPEARANCE OF THE HYOID BONE IN PYKNODYSOSTOSIS

Report of a case

G THEANDER

The hyoid bone develops from the second and third branchial arches It is pre formed by hyaline cartilage which is mineralized first in its body and later in the horns Ossification of the body usually occurs already before birth

Occasionally the cartilage is the site of the congenital calcific deposits charac terizing chondrodysplasia punctata (MOSEKILDE 1968) The bone may be displaced by a cervical mass such as local malformation neoplasm or inflammatory disease but with these few exceptions involvement of the hyoid bone in congenital dysplasia or acquired disease seems to be unknown This prompted the present report of a case in which the hyoid bone partly disappeared during childhood

Case report

The patient a male born in 1950 was examined radiologically already at 19 months of age Available films from that time included the chest skull hands and feet and revealed marked osteosclerosis of these parts In addition the end phalanges of the fingers and toes were short and pointed multiple relatively large ossicles existed along the lambdoid suture and the mandibular angle was obtuse (Fig 1) The hyoid bone appeared normal (Fig 2 a)

During childhood repeated radiologic examination of the legs because of only slight trauma showed bilateral sclerosis in the tibia and fibula and deficient modelling of their metaphyses Pathologic transverse diaphyseal fractures were found on one occasion in the

Submitted for publication 11 June 1977



Fig 1 19 months Multiple ossicles along wide lambdoid suture Obtuse mandibular angle

right tibia and on another in the left tibia and fibula Subsequent periosteal callus formation was scanty and healing was slow

The further clinical course was dominated by shortness of stature and prognathism with malocclusion Skull radiography at 14 years showed undersized maxillary bones and increased slope of the mandible Although most of the calvarial ossicles had fused with either the parietal bones or the occipital bone giving the lambdoid suture a strikingly curved margin this suture had become several times as wide as before (Fig 3) The sagittal suture also had increased in width The horns of the hyoid bone had disappeared and its body had clearly decreased in size (Fig 2 b)

The patient was re admitted at 21 years of age because of contemplated surgical correction of his bite He had then had no further fracture Inquiry revealed no history of familial disease The liver and spleen were normal in size and no anemia was found Radiography



a b c

Fig. 2. a) 19 months, b) 14 years, c) 21 years Disappearance of horns and major part of body of hyoid bone followed by slight growth of apparently eroded body



Fig 3 14 years Markedly increased width of lambdoid suture despite fusion of ossicles with occipital and parietal bones Abnormal shape of lambdoid suture Undersized maxillary bones and steeply sloping mandible

this time included the entire skeleton and general osteosclerosis was found In addition to the previously known deformities abnormal modelling of the vertebral bodies and bilateral acetabular protrusion were demonstrated The acro-osteolysis of the fingers and toes had advanced considerably Almost no pneumatisation of the mastoid bones had developed and no visible paranasal sinuses except for a few ethmoid cells Ossification had proceeded along the lambdoid suture and had thereby created an abnormal foramen in the posterior part of the right parietal bone but both this suture and the sagittal suture were still widely open (Fig 4) The body of the hyoid bone had grown slightly but appeared eroded (Fig 2 c)

Discussion

The combination of osteosclerosis and abnormal modelling of bones osseous fragility delayed healing of fractures and progressive digital acroosteolysis is characteristic of an unusual congenital dysplasia first described in 1962 by ANDRÉN et coll who referred to the condition as osteopetrosis acroosteolytica and by MAROTEAUX & LAMY who introduced the term pyknodysostosis Other significant features of this dysplasia include undersized maxillary bones and an abnormally steep slope of the mandible causing malocclusion anomalous ossification of the calvarial bones with long persistence of multiple ossicles and non union or even progressive widening of the sutures and deficient pneumatisation of the facial and mastoid bones The osteosclerosis has none of the structural peculiarities specific

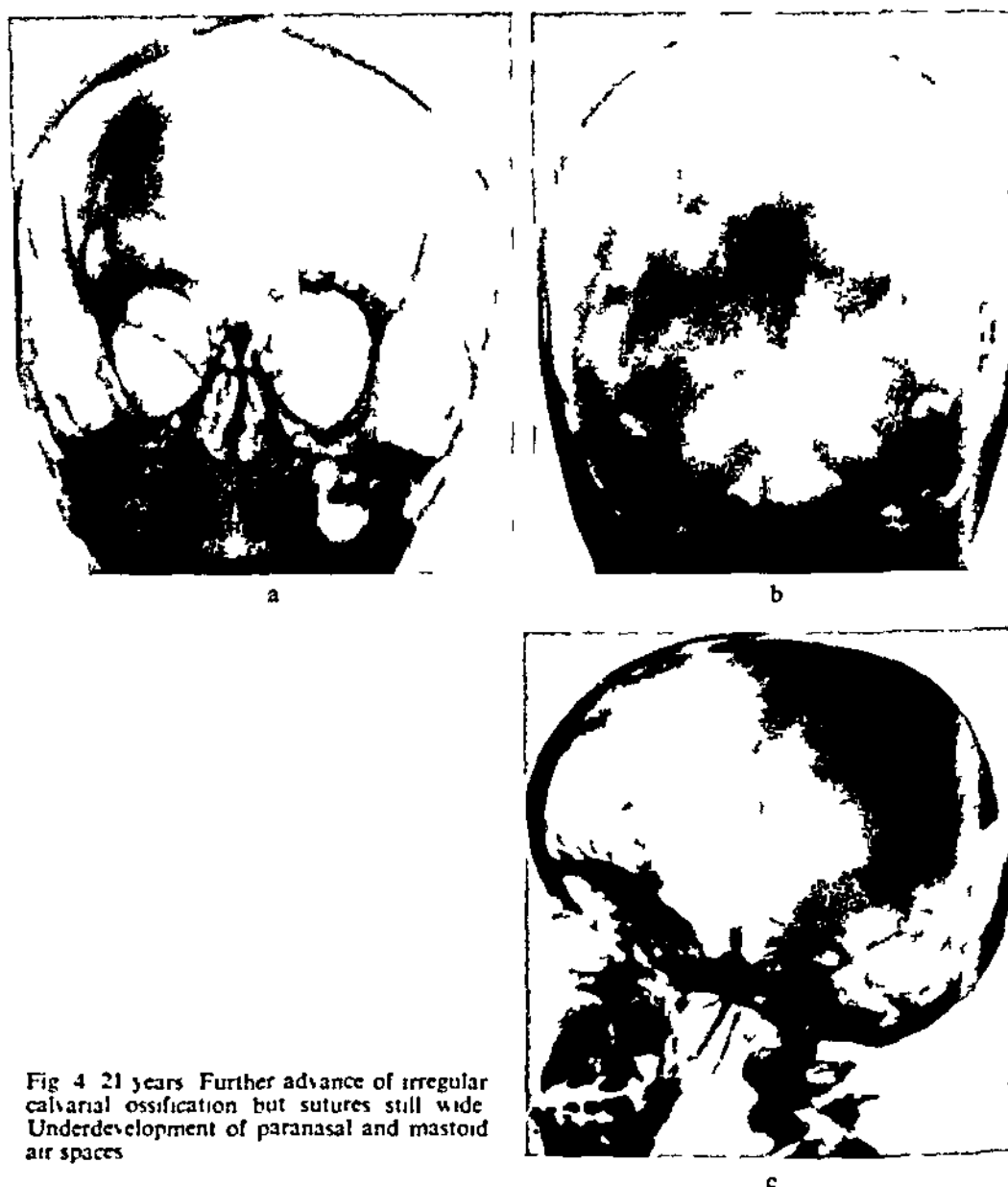


Fig 4 21 years Further advance of irregular calvarial ossification but sutures still wide Underdevelopment of paranasal and mastoid air spaces

of true osteopetrosis e g endobone and striations (ENGFELDT et coll 1960) and it is not accompanied by anemia or hepatosplenomegaly The etiology is unknown

The abnormalities found in the present case and their course firmly establish the diagnosis of pyknodysostosis The abnormalities of the skull and face are particularly instructive and the increasing width of the lambdoid suture despite simultaneous progression of delayed ossification along its margin is probably pathognomonic of this dysplasia The most remarkable findings were however those in the hyoid bone

The report on pyknodysostosis by ANDRÉN et coll included two original cases observed in this hospital The present author reviewed the films taken at 20 years of age in each case In both of them the hyoid bone appeared normal Earlier films of these patients are not available No further similar case has been seen at this hospital and no report of the syndrome has been found in which the hyoid bone is mentioned Most reports include a lateral skull film but it is rarely possible to see whether the hyoid bone is present or not In the few illustrations in which this bone is visible it appears to be normal in size and shape

It is not known whether abnormalities of the hyoid bone similar to those observed during childhood in the present case have occurred in any previous case of pyknodysostosis Since no microscopy was carried out it is also uncertain whether the radiologic disappearance of bone reflects destruction or only decalcification It is feasible that either of these changes may result from local infection or tumour but in the present case no such explanation would deserve consideration

Since pyknodysostosis is far from common and since disappearance of the hyoid bone is probably even rarer it is also highly improbable that the combination of both should be merely coincidental It might rather be assumed that the observed abnormalities of the hyoid bone are an unusual manifestation of pyknodysostosis analogous with the acro-osteolysis occurring in the digits as an inherent feature of this syndrome

SUMMARY

A case of pyknodysostosis is reported in which radiography between the ages of 1 and 21 years revealed partial disappearance of the hyoid bone during childhood

ZUSAMMENFASSUNG

Ein Fall von Pyknodysostose wird beschrieben in dem es aus Rontgenuntersuchungen in den Altern von 1 bis 21 Jahren hervorging dass das Zungenbein in der Kindheit teilweise verschwand

RESUME

Presentation d un cas de pyknodysostose ou la radiographie entre les ages de 1 et 21 ans a revele une disparition partielle de l os hyoide pendant l enfance

REFERENCES

ANDRÉN L DYMLING J F HOGEMAN K E and WENDEBERG B Osteopetrosis acro osteolytica Acta chir scand 124 (1962) 496

ENGFELDT B FAJERS C M LODIN H and PEHRSON M Studies on osteopetrosis III Roentgenological and pathologic anatomical investigations on some of the bone changes Acta paediat 49 (1960) 391

MAROTEAUX P et LAMY M Deux observations d une affection osseuse condensante la pycnodysostose Arch franç Pediat 19 (1962) 267

MOSEKILDE E Chondroangiopathia calcarea seu punctata *In* Encyclopedia of medical radiology Vol 5 Part 3 p 49 Ed by L Diethelm O Olsson F Strnad H Vieten and A Zuppinger Springer Verlag Berlin Heidelberg New York 1968

FROM THE AURORA HOSPITAL SF-00 50 HELSINKI FINLAND

TRAUMATIC BOWING OF FOREARM AND LOWER LEG IN CHILDREN

R STENSTRÖM L GRIPENBERG and A R BERGIUS

Traumatic bowing of forearm and lower leg is not mentioned in most standard works on fractures in children However RANG (1974) referred to bowing of extremity bones as a self evident occurrence but he did not cite any references He divided pediatric fractures into four groups bend of bone buckle or torus fractures green stick fracture and complete fracture The present report considers the first group i e bowing of bones

Material and Methods The series consisted of 31 cases most of them diagnosed during the last 4 years In the majority i e in 25 cases bowing occurred in combination with fracture of the other bone in the forearm or leg At radiography two perpendicular projections were regularly used both for the injured and the unaffected limb

Results

The age distribution of the series appears in Table 1 The age averaged 6 3 years (range 2 to 14 years) No significant difference in age distribution was found between the forearm and lower leg mean ages 6 2 and 6 5 years respectively The proportion of boys to girls was 7 3 The most common mechanism of trauma to the forearm was falling from a height in 10 patients 7 had tumbled down in 3 patients other mechanisms had been present Collision between a bicycle and a motorcar wrestling and unknown trauma were recorded in the remainder of the patients Of the 11 lower leg

Submitted for publication 9 June 1977

MAROTEAUX P et LAMY M Deux observations d une affection osseuse condensante la pycnodysostose Arch franç Pédiat 19 (1962) 267

MOSEKILDE E Chondroangiopathia calcarea seu punctata *In* Encyclopedia of medical radiology Vol 5 Part 3 p 49 Ed by L Diethelm O Olsson F Strnad H Vieten and A Zuppinger Springer Verlag Berlin Heidelberg New York 1968



Fig. 1 Boy aged 4 years Fracture of left radius and 12 radial and 5 posterior bowing of ulna After repositioning only 2 posterior angulation remained

Four of the 11 lower leg injuries were repositioned all 4 were associated with fracture of the tibia Two cases with a solitary fibular deformity were not repositioned General anaesthesia was applied at repositioning in all but one case in which nerve block anaesthesia was administered No patient in this series had any radiologic evidence of generalized bone disease No callus formation was observed on the bowed bones but a remodelling of the bone with thickening of the cortex on the concave aspect gradually appeared

Some cases illustrating the mechanism of traumatic bowing of the forearm and lower leg appear in Figs 1 to 4

Discussion

Traumatic bowing of bones is not mentioned in standard books of reference and has been dealt with only recently in the literature Thus BORDEN IV (1974 1975)



Fig. 2. Boy aged 7 years. a) 3° radial and 5° posterior bowing of radius and 11° radial and 15° posterior bowing of ulna. No repositioning. b) One year later radius was straight; in ulna 13° radial and 2° posterior bowing persisted and cortex was thickened.

reported 17 cases of bowing, all of the forearm. He raised the question why bowing occurs only in the forearm. His hypothesis was that the lack of intrinsic curvature of the tibia may account for the apparent absence of plastic deformities in the lower leg. RANG stated that the most common locations are the ulna and fibula, and gave the same relative frequency as that found in the present series: 40 per cent involved the ulna and 28 per cent the fibula.

According to BORDEN IV the trauma to the forearm was a longitudinal blow against an arm in hyperextension. Some of the present cases may have been exposed to the same mechanism of trauma, because falling was usually the cause of forearm bowing, although direct trauma also occurred. In the lower leg a direct trauma to the patient was most common, through collision with a car or during sleighing.

It has been found that the bone of a child differs from that of adults as regards



Fig. 3 Boy aged 3 years a b) 8 tibial bowing of fibula possibly slight bowing of tibia in same direction. No repositioning c) 18 months later the concavity had filled in bowing of only 2 remained and cortex and fibula were thickened (→)

elasticity and strength (HIRSCH & EVANS 1965) According to RANG the curve for bone during loading has a more or less flattened top in puppies whereas in mature dogs it is peaked TSCHANTZ & RUTISCHAUER (1967) and CHAMAY & TSCHANTZ (1972) observed microfractures at loading of bone Electron microscopy revealed that these microfractures constitute parallel zones of fragmentation within the bone architecture

Typical for the bowing deformity is that sequential roentgen examinations within two to four weeks of the injury reveal no callus formation The deformities are wide




Fig 4 Girl aged 14 years Transverse fracture of tibia and bowing of fibula 5 laterally and 4 posteriorly

curvatures which involve the shaft and blend imperceptibly into the normal bone at either end (BORDEN IV) In young children thickening of the cortex is found on the concave surface of the bone (Fig 3 c) For the diagnosis of a traumatic bowing de formity and for its differentiation from a congenital bowing a comparison with the unaffected limb is most important

Most of the traumatic bowing deformities in the forearm were located in the middle third Within this area of the diaphysis the angular deformity is corrected by growth only slowly or not at all depending on the age of the child In conformity herewith a bowing deformity tends to persist for a long time or will be permanent unless it is initially repositioned

A bowing of the forearm or the lower leg whether isolated or as part of more extensive injuries to the skeleton should be considered a fracture Consequently it should be treated according to the principles which apply in the management of children s fractures

Addendum in proof

After submission of this report a communication by J E CROWE and L E SWISCHUK has appeared in Amer J Roentgenol 128 (1977) 981 (Acute bowing fractures of the fore arm in children—A frequently missed injury) These authors also emphasize the importance of dislocation of the head of the radius in traumatic bowing On the whole the results are in agreement with the present ones

SUMMARY

Traumatic bowing of the forearm or lower leg is reported in 31 children It is a relatively rare condition Bowing occurs most frequently in combination with fracture of the other bone in the same extremity In a minority of cases a bowing deformity is a single lesion Age distribution degree of deformity mechanism of origin and therapy are presented and discussed

ZUSAMMENFASSUNG

Eine traumatische Beugung des Unterarms oder der unteren Extremitat wird bei 31 Kindern beschrieben Das ist ein relativ seltenes Vorkommen Eine Beugung entsteht am meisten in Kombination mit einer Fraktur eines anderen Knochens derselben Extremitat In einer minderzahl der Falle ist die Beugungsdeformation eine einzelne Lasion Die Alters verteilung das Ausmass der Deformitat Entstehungsmechanismus und die Therapie werden diskutiert

RESUMÉ

Les auteurs rapportent 31 cas de courbure traumatique de l avant bras ou de la jambe chez des enfants C est une affection relativement rare La courbure se produit le plus souvent en association avec une fracture de l autre os du meme membre Dans une minorite de cas une deformation en courbure est une lésion isolee Les auteurs étudient la distribution en fonction de l âge le degré de la deformation le mecanisme d origine et le traitement de cette lesion

REFERENCES

BORDEN IV S Traumatic bowing of the forearm in children J Bone Jt Surg 56-A (1974) 611

— Roentgen recognition of acute plastic bowing of the forearm in children Amer J Roentgenol 125 (1975) 524

CHAMAY A and TSCHANTZ P Mechanical influences in bone remodeling Experimental research on Wolff s law J Biomech 5 (1972) 173

HIRSCH C and EVANS F G Studies on some physical properties of infant compact bone Acta orthop scand 35 (1965) 300

RANG M Children s fractures p 1 J B Lippincott Co Philadelphia–Toronto 1974

TSCHANTZ P et RUTISCHAUER E La surcharge mecanique de l os vivant Les deformations plastiques initiales et l hypertrophie d adaption Ann Anat path 12 (1967) 223

FROM THE DEPARTMENT OF PEDIATRIC RADIOLOGY (DIRECTOR O EKLÖF) KAROLINSKA SJUKHUSET S 104 01 STOCKHOLM SWEDEN

RECURRENT INTUSSUSCEPTION

Analysis of a series treated with hydrostatic reduction

O EKLÖF and S REITER

Among the arguments against barium enema as treatment in childhood intussusception the risk of incomplete reduction and the danger of recurrence are frequently stressed Although criteria for successful hydrostatic reduction hitherto to some extent unheeded have recently been presented it would be unreasonable to suppose that erroneous evaluation of radiologic findings has been eradicated (EKLÖF & HUGOSSON 1976)

One aim of the present investigation was to assess the rate of recurrences and their clinical implication on the basis of a large material Another object was to analyse the radiologic findings as revealed on conventional films and at barium enema in patients with recurrent intussusception Relevant characteristics were compared with findings in cases running an uncomplicated course in order to ascertain whether the two groups differed in any respect from each other

Material and Methods

During the period 1961 through 1975 428 intussusceptions were diagnosed in 380 patients Throughout the period hydrostatic reduction was almost invariably employed as the primary therapeutic measure Operation was with few exceptions performed only if the intussusception proved hydrostatically irreducible

In 24 boys and 11 girls with a mean age of 22 months and a median age of 19 months on the first admission a total of 48 recurrences were subsequently diagnosed

Submitted for publication 11 June 1977

Table 1

Symptoms and signs in 35 patients (83 examinations group I) with 48 recurrences and in 35 patients (35 examinations group II) without recurrences

	Group I		Group II	
	No of exam	Per cent	No of exam	Per cent
Interval pain	83	100	35	100
Vomiting	37	44 5	19	54 2
Bloody rectal discharge	12	14 4	10	28 5
Palpable tumour	3	3 6	4	11 4

Table 2

Abnormalities on conventional abdominal films in 35 patients (83 examinations group I) with 48 recurrences and in 35 patients (35 examinations group II) without recurrences

	Group I	Group II
Soft tissue tumour	68 (81 9)	32 (91 4)
Abnormal gas distribution	15 (18 0)	4 (11 4)
Reduced bowel gas	42 (50 6)	18 (51 4)
Dilated small bowel loops	26 (31 3)	15 (42 8)
Intestinal obstruction	23 (27 7)	13 (37 1)

The recurrences appeared 19 times in 15 patients within 48 hours of the primary reduction of the intussusception Late recurrences occurred up to 2 years and 9 months after the first admission One relapse occurred in 27 patients 2 in 4 patients 3 in 3 and 4 in 1 patient The group of patients presenting with recurrent intussusceptions (group I) was compared with the same number of consecutively diagnosed intussusceptions running an uncomplicated course following reduction with barium enema The latter patients formed the control group (group II) It consisted of 27 boys and 8 girls with a mean age of 19 5 and a median age of 14 5 months at presentation The two groups did not differ with respect to sex or age distribution

Results

All cases of both groups proved to have ileocaecal intussusception The clinical symptoms and signs were somewhat more marked in group II (Table 1) However the difference was considered statistically insignificant The review of the conventional abdominal films aimed particularly at a re-evaluation of the features listed in Table 2 These are generally accepted as criteria of intussusception (BOHLIN

FROM THE DEPARTMENT OF PEDIATRIC RADIOLOGY (DIRECTOR O EKLOF) KAROLINSKA SJUKHUSET S 104 01 STOCKHOLM SWEDEN

RECURRENT INTUSSUSCEPTION

Analysis of a series treated with hydrostatic reduction

O EKLOF and S REITER

Among the arguments against barium enema as treatment in childhood intussusception the risk of incomplete reduction and the danger of recurrence are frequently stressed Although criteria for successful hydrostatic reduction hitherto to some extent unheeded have recently been presented it would be unreasonable to suppose that erroneous evaluation of radiologic findings has been eradicated (EKLÖF & HUGOSSON 1976)

One aim of the present investigation was to assess the rate of recurrences and their clinical implication on the basis of a large material Another object was to analyse the radiologic findings as revealed on conventional films and at barium enema in patients with recurrent intussusception Relevant characteristics were compared with findings in cases running an uncomplicated course in order to ascertain whether the two groups differed in any respect from each other

Material and Methods

During the period 1961 through 1975 428 intussusceptions were diagnosed in 380 patients Throughout the period hydrostatic reduction was almost invariably *employed as the primary therapeutic measure Operation was with few exceptions* performed only if the intussusception proved hydrostatically irreducible

In 24 boys and 11 girls with a mean age of 22 months and a median age of 19 months on the first admission a total of 48 recurrences were subsequently diagnosed

Submitted for publication 11 June 1977

Table 1

Symptoms and signs in 35 patients (83 examinations group I) with 48 recurrences and in 35 patients (35 examinations group II) without recurrences

	Group I		Group II	
	No of exam	Per cent	No of exam	Per cent
Interval pain	83	100	35	100
Vomiting	37	44.5	19	54.[illegible]
Bloody rectal discharge	12	14.4	10	28.5
Palpable tumour	3	3.6	4	11.4

Table 2

Abnormalities on conventional abdominal films in 35 patients (83 examinations group I) with 48 recurrences and in 35 patients (35 examinations group II) without recurrences

	Group I	Group II
Soft tissue tumour	68 (81.9)	3[illegible] (91.4)
Abnormal gas distribution	15 (18.0)	4 (11.4)
Reduced bowel gas	42 (50.6)	18 (51.4)
Dilated small bowel loops	26 (31.3)	15 (42.8)
Intestinal obstruction	23 (27.7)	13 (37.1)

The recurrences appeared 19 times in 15 patients within 48 hours of the primary reduction of the intussusception Late recurrences occurred up to 2 years and 9 months after the first admission One relapse occurred in 27 patients 2 in 4 patients 3 in 3 and 4 in 1 patient The group of patients presenting with recurrent intussusceptions (group I) was compared with the same number of consecutively diagnosed intussusceptions running an uncomplicated course following reduction with barium enema The latter patients formed the control group (group II) It consisted of 27 boys and 8 girls with a mean age of 19 5 and a median age of 14 5 months at presentation The two groups did not differ with respect to sex or age distribution

Results

All cases of both groups proved to have ileocaecal intussusception The clinical symptoms and signs were somewhat more marked in group II (Table 1) However the difference was considered statistically insignificant The review of the conventional abdominal films aimed particularly at a re-evaluation of the features listed in Table 2 These are generally accepted as criteria of intussusception



Fig 1 Five year old girl with clinical suggestion of intussusception Successful reduction 18 hours later almost complete evacuation minor contrast medium residuals in the collapsed descending colon sparse amount of gas in the intestines Recurrence

1964 GIERUP et coll 1972 FRIMANN DAHL 1974) It was found that the various radiologic abnormalities occurred at the same rate in both series On the basis of available reports and films a rough estimation of the degree of difficulty of reduction was carried out In approximately one third of the cases in both groups the reduction was laborious In these cases several attempts at reduction were made In group I reduction was successful in 96 per cent and in group II in 88 per cent of the cases Thus the rate of recurrence was not related to the recorded difficulty of reduction

Particular interest was paid to the post-evacuation films As pointed out by EKLÖF & HUGOSSON incomplete evacuation of the barium enema including propagation in the oral direction and retention of the contrast medium in the small bowel should indicate successful reduction This type of evacuation was found in 70 per cent of the cases in group I and in 80 per cent in group II A complete evacuation of the enema even that after an apparently successful reduction should be regarded as indicating that the reduction could in reality be incomplete (Fig 1) Every third recurrence that appeared within 48 hours revealed complete evacuation When



Fig. 2



Fig 3

Fig 2 Detail of ileocaecal region after hydrostatic reduction Thick ileocaecal valve and irregular oedematous wall of terminal ileum No recurrence

Fig 3 Filling defect repres nting intussusception occupying proximal colon to level of hepatic flexure No passage of contrast medium to small bowel Failure at attempted hydrostatic reduction

combined with mild small bowel meteorism the possibility of incomplete reduction is enharced

Following hydrostatic reduction swelling of the ileocaecal valve and irregularity of the terminal ileal wall was observed in three fourths of all patients (Fig 2) being equally common in both groups Even if swelling of the valve and the terminal ileum tended to increase in extent with multiple intussusceptions of the bowel appearing within a short period of time these alterations were not suggestive of imminent recurrence

Among the patients readmitted within a few hours reported success of primarily applied hydrostatic reduction was questionable in at least 2 of them On the basis of the available film material an erroneous evaluation of the findings appeared likely Thus contrast filling of the caecum and appendix (Fig 3) in the absence of retrograde transport of the medium into the small bowel is not a criterion of effective reduction as a matter of fact it is strongly indicative of an unsuccessful reduction

Twelve of 35 patients with recurrent intussusception (group I) were operated upon in 9 the operation was undertaken to establish the etiology if possible In the



Fig 4 Abnormal distribution of intestinal gas with collapsed large bowel empty of gas Slightly dilated, gas-containing small bowel loops in the right hypochondrium Corresponding to the hepatic flexure a soft tissue tumour (=intussusceptum) surrounded by bowel gas

remaining 3 cases the intussusception was radiologically irreducible At operation manual reduction was successful in 2 while in the third case spontaneous reduction had occurred during anaesthesia

A broad based caecal polyp was found in one case it may have acted as an inducting element (leading point EIN 1975) Oedema of the ileocaecal valve and the terminal ileum hyperplasia of glands in the wall of the small bowel and in the mesentery were observed in the other 8 cases

Five patients belonging to group II underwent operation In 4 of them attempts at hydrostatic reduction had not been successful while a possible tumour called for surgery in the remaining case At operation the intussusception was reduced in 3 cases In one case spontaneous reduction had occurred during anaesthesia No tumour was found in the remaining case nor was any inducting element found on the intussusceptum

Discussion and Conclusions

Depending on general attitudes and traditions available means of therapy and service facilities hydrostatic reduction or operation will be chosen for treatment Surgery is probably commoner in areas with a low frequency of intussusceptions and



Fig 5 Boy aged 18 months admitted with clinical suggestion of intussusception a) Sparse intestinal gas Possible soft tissue mass in right lumbar region b) Barium enema revealed intussusception reduced hydrostatically c) Detail of ileocaecal region after reduction persistent swelling of the valve and terminal ileum

in hospitals lacking a full 24-hour radiologic service In certain centers a long case history and poor condition of the patients on admission left the attending surgeon no choice at the selection of treatment As a consequence operation rates varying from 50 to virtually 100 per cent of cases have been reported (CHING et coll 1970 DENNISON & SHAKER 1970 MAYELL 1972 WAYNE et coll 1973 EIN 1975) In Sweden with a rather high frequency of intussusceptions and easy access to hospital care hydrostatic reduction has for decades been employed as the primary means of treatment (HELLMER 1948 BOHLIN GIERUP et coll) The use of barium enemas not only for diagnostic but also for therapeutic purposes has resulted in successful reduction of the intussusception in 80 to 90 per cent of all cases This approach seems to be

becoming more generally accepted (EIN & STEPHENS 1971 WAYNE et coll HÖRMANN et coll 1976)

The experiences from the present series demonstrate the value of conservative treatment The majority of the patients could be dismissed immediately after the reduction Attempts at hydrostatic reduction failed and made operation necessary in only about 10 per cent of all cases treated during the period 1961 to 1975 Post operative recovery was uneventful throughout the period including 2 cases of in testinal perforation secondary to attempted barium enema The perforation was the only severe complication encountered in the series Conventional films of the ab domen suggested marked obstruction of the bowel and peritonitis and the patients should not have been subjected to hydrostatic reduction NORDENTOFT & HANSEN (1955) using the same approach reported an almost identical incidence of bowel perforation in a series of 1 838 patients On the basis of present experience the overall incidence of serious complications with hydrostatic reduction should be regarded as low

The rate of recurrences was 9 2 per cent in the present series almost the same figure as that given by EIN (1975) However patients presenting with one episode of recurrence run a significantly higher risk of additional relapse Thus 22 per cent of the patients in group I (recurrences) presented with 48 per cent of all instances of relapse a fact of considerable clinical consequence

The benefit of operation of all recurrences has been discussed in the literature The low rate of observed leading points in EIN s (1975) and the present series does not support the previous assumption that surgery should be mandatory This is also true for early recurrence According to BUSSMAN et coll (1974) the indications for surgery in older patients and late recurrences should be considered separately This is because the rate of manifest inducting element is supposed to be higher in older age groups than in infants However this assumption was not proved valid in the 15 year series of which the present material is a part nor in EIN s series

The findings at conventional radiography of the abdomen have been described repeatedly Much attention has been paid to the appearance of the intestinal gas and particularly to the presence of gas containing slightly dilated small bowel loops in the right hypochondrium (Fig 4) occasionally combined with a soft tissue mass representing the intussusceptum (BOHLIN GIERUP et coll JORULF 1973) In later stages and depending on the degree of obstruction the films may indicate me chanical ileus (FRIMANN DAHL HILLE et coll 1976) The significance of an ab- normally scant amount of intestinal gas as a potential indication of intussusception has not been recognized until recently (HÖRMANN et coll) However this is not specific for intussusception and may even be present in cases with no proven ab- normality (EKLÖF & LETTE 1978)

The appearance of the abdomen at conventional radiography was essentially the same in the two groups analysed and consequently did not aid in predicting relapse The single feature of some significance was complete evacuation of the bowel fol

lowing enema and observed in approximately one third of the cases with early recurrence When associated with a mild small bowel meteorism this finding is an important suggestion of impending relapse even following an successful hydrostatic reduction

It is also clear that the results of hydrostatic reduction may be erroneously evaluated if strict criteria of successful reduction are not applied (EKLÖF & HUGOSSON) The number of such errors was small and probably limited to two cases in the present material On readmission a few hours later because of increasing abdominal symptoms and signs complete reduction by barium enema was achieved No complications occurred

From the practical point of view the possibility of predicting recurrences of childhood intussusception is rather limited at radiography However patients with complete evacuation after reduction and those with early relapse have an increased tendency to recurrence Thorough observation of these patients for at least 48 hours is recommended

SUMMARY

The appearances at conventional radiography and barium enema were compared in a series of 35 patients with recurrent intussusception and in the same number of cases with an uncomplicated course Only minor disparities between the group could be established The significance of a sparse amount of intestinal gas pointing to intussusception and the implication of a complete evacuation of the bowel following barium enema are stressed The latter phenomenon occasionally combined with persistent mild small bowel meteorism occurred in approximately one third of all early relapses Patients with one manifest relapse run a significantly increased risk of further recurrences although in the majority of cases no significant etiologic factors are encountered

ZUSAMMENFASSUNG

Die Befunde bei einer konventionellen Röntgenuntersuchung und bei einem Barium Einlauf in 35 Patienten mit einer wiederholten Invagination wurden mit denen einer gleichen Anzahl von Fällen mit einem unkomplizierten Verlauf verglichen Nur geringe Abweichung zwischen diesen Gruppen wurde festgestellt Die Bedeutung einer kleinen Menge von Intestinalgas die auf eine Invagination hindeutet und die Bedeutung einer vollständigen Entleerung nach einem Barium Einlauf werden hervorgehoben Das letztere Phänomen gelegentlich zusammen mit einem bestehenden geringfügigen Meteorismus des Dünndarms kommt in etwa einem Drittel aller frühzeitigen Rückfälle vor Patienten mit einem manifesten Rückfall haben ein signifikant höheres Risiko eines zukünftigen Wiederauftretens obwohl in der Mehrzahl der Fälle keine signifikanten ursächlichen Faktoren festgestellt werden konnten

RESUMÉ

Les aspects sur la radiographie sans préparation et sur le lavement baryté ont été comparés sur une série de 35 malades ayant une invagination intestinale récidivante et sur le même nombre de cas ayant une évolution sans complication Les auteurs n'ont trouvé que des

differences minimes entre ces deux groupes Ils insistent sur l importance d une petite quantité de gaz intestinaux indiquant l invagination et sur la signification d une evacuation complete de l intestin apres le lavement baryte Ce dernier phenomene parfois associe avec un discret metéorisme persistant de l intestin grele etait présent chez environ 1/3 des recidives precoces Les maldes qui ont une recidive manifeste courent un risque significativement augmente de récidives ulterieures bien que dans la majorite des cas on ne trouve pas de facteurs etiologiques significatifs

REFERENCES

BOHLIN H Conventional roentgenography in diagnosis of intussusception in children Acta radiol Diagnosis 2 (1964) 32

BUSSMAN J F LOEWE K R und WEMMER U Invagination durch pathologische Darm veranderungen Bruns Beitr klin Chir 221 (1974) 605

CHING E CHING L T and LYNN H B Intussusception in children Mayo Clin Proc 45 (1970) 724

DENNISON W M and SHAKER M Intussusception in infancy and childhood Brit J Surg 57 (1970) 679

EIN S H Recurrent intussusception in children J Pediat Surg 10 (1975) 751

— and STEPHENS C A Intussusception 354 cases in 10 years J Pediat Surg 6 (1971) 16

EKLOF O and HUGOSSON C Post-evacuation findings in barium enema treated intussusceptions Ann Radiol 19 (1976) 133

— and LETTE E Scanty intestinal gas in infants and children Clinical significance and radiologic diagnosis Acta radiol Diagnosis 19 (1978) 259

FRIMANN DAHL J Roentgen examinations in acute abdominal diseases Third edition p 253 Charles C Thomas Springfield Illinois 1974

GIERUP J JORULF H and LIVADITIS A Management of intussusception in infants and children A survey based on 288 consecutive cases Pediatrics 50 (1972) 535

HELLMER H Intussusception in children Diagnosis and therapy with barium enema Acta radiol (1948) Suppl No 65

HILLE M DRÖGMOLLER U ERFURTH F und MÜLBLER T Invaginationsileus im Kindes alter Teil 1 15 Jahresstudie Zbl Chir 101 (1976) 157

HÖRMANN D KNUPPER P und MEISSNER F Die hydrostatische Desinvagination Zbl Chir 101 (1976) 146

JORULF H Tip of the liver in intussusception of the bowel in infancy and childhood Acta radiol Diagnosis 14 (1973) 26

MAYELL M J Intussusception in infancy and childhood in Southern Africa A review of 223 cases Arch Dis Child 47 (1972) 20

NORDENTOFT J M and HANSEN H Treatment of intussusception in children A brief survey based on 1 838 Danish children Surgery 38 (1955) 311

WAYNE E R CAMPBELL J B BURRINGTON J D and DAVIS W S Management of 344 children with intussusception Radiology 107 (1973) 597

FROM THE DEPARTMENT OF PEDIATRIC RADIOLOGY (DIRECTOR O EKLÖF) KAROLINSKA SJUKHUSET S 104 01 STOCKHOLM SWEDEN

SCANTY INTESTINAL GAS IN INFANTS AND CHILDREN

Clinical significance and radiologic diagnosis

O EKLÖF and E LETTI

The classical appearance of the bowel in mechanical obstruction of the gut with gas and fluid accumulated in dilated intestinal loops above the hindrance and a more or less collapsed bowel below it is well known Aspects of differential diagnosis are considered at great length in modern text books of radiology (GLAUNER 1965 SAMUEL 1969 GIRDANY 1973 FRIMAN DAHL 1974 FRANKEN 1975) Less attention has been paid to disorders presenting with scanty or completely absent intestinal gas which has often been considered to be caused by high obstruction of the intestines or strangulation of loops of the bowel Some well-defined congenital abnormalities of the gastro-intestinal tract clinically becoming apparent in the neonatal period may demonstrate similar features but will not be discussed in this context

However in the pediatric age group there are several other diagnostic alternatives The aim of this report is to call attention to this group of conditions of heterogeneous etiology and to the value of contrast examinations

Material and Methods

The material consisted of 23 boys and 18 girls dispersed over the whole age interval from the neonatal period to 15 years of age It was partly compiled from the files representing patients with unexplained abdominal complaints and partly assembled during a recent 6 month period and representing routine examinations carried out on

Submitted for publication 24 February 1977



Fig 1 Girl aged 14 months developed severe urinary infection 6 weeks after operation for Wilms tumour Increasing respiratory distress and abdominal distension Air-distended stomach but absent intestinal gas Metal clips in the previous tumour area On follow through examination no evidence of intestinal obstruction Patient died of sepsis

Table

Conditions encountered presenting as abdominal emergencies displaying reduced intestinal gas

Dehydration caused by vomiting or diarrhoea with alkalosis or acidosis
Septicaemia
Blood disorders such as leucaemia or aplastic anaemia
Increased intracranial pressure secondary to hydrocephalus brain oedema or haemorrhage
Disturbed deglutition in tumours meningitis or palsy
Appendicitis and mesenteric lymphadenitis
Non-obstructive postoperative conditions (intestinal paralysis)
Intestinal obstructions at all levels including intussusception
Intra and extraperitoneal tumours (teratoma Wilms tumour)
Urinary tract abnormalities (ureteric concretion posterior urethral valve with ascites)
Peritonitis intra and extraperitoneal bleedings or ascites
Abdominal pain of unknown origin



Fig 2 Girl aged 6 years Right sided renal trauma 4 weeks earlier Mainly left-sided abdominal pain of 5 hours duration tending to increase Slight microscopic haematuria Sparse amount of intestinal gas At urography intense nephrographic effect on the left side secondary to a non visible concrement at the junction between the pelvis and the ureter Concrement passed spontaneously

patients referred to this department as abdominal emergencies The history was shorter than 24 hours in 24 cases and longer in 17 cases Laparotomy had previously been performed in 9

All patients had at least one conventional roentgen examination of the abdomen revealing only sparse intestinal gas In some of the cases the gas was distributed abnormally The examination was invariably carried out according to the technique described by EKLOF (1969) a slight modification of that recommended by LAURELL (1939) and FRIMANN DAHL (1951) Films were exposed with the patient supine and in the left recumbent lateral position and with vertical as well as horizontal beam directions The number of exposures and projections employed depended on the history and the information obtained during the examination In some cases a repeat examination was performed after a period of observation in other patients supplementary contrast examinations were carried out most frequently either a contrast enema or a follow through examination Barium sulphate regarded as the least harmful contrast medium was preferred to Gastrografin throughout the series In some cases urography or micturition cysto-urethrography was carried out



Fig 3 Boy aged 18 months who one week after a skull trauma causing intracerebellar bleeding developed increasing abdominal distension No gastro-intestinal gas at all Attempted follow through examination revealed no evidence of obstruction (5 min film) Deficient deglutition Patient died of brain damage

Results

Symptoms and signs Abdominal distension with or without concomitant pain and vomiting was common The pain was either slight and intermittent or continuously severe Failure to pass flatus or stools in some cases diarrhoea were other reflections of disease Active muscular defense on palpation occasionally indicated peritonitis In other cases the palpatory finding was either equivocal or normal In neonates with marked dehydration secondary to vomiting or diarrhoea in cases of respiratory distress and in sepsis electrolyte disturbances and abnormal pH values were recorded

Defective deglutition and abnormal peristalsis of the intestines were other findings encountered at the clinical examination

Radiology In some cases no intestinal gas at all could be found but a certain amount was present in the stomach in most cases Occasionally gas was demon




Fig 4 Boy aged 4 years with a 3-day history of vague abdominal pain and vomiting Equivocal clinical findings Sparse intestinal gas Follow through examination revealed normal conditions Uneventful recovery

strated in short non distended small bowel loops or in the large bowel which was frequently collapsed

Intussusception was the disorder most commonly associated with canty intestinal gas In 5 of 7 cases in the present series small bowel loops containing minor amounts of gas were found to be displaced to the right hypochondrium In 3 cases the intus susceptum app ared as a soft tissue tumour obliterating the liver tip (JORULF 1973)

In a further 5 patients intestinal obstruction of other etiology was diagnosed and confirmed surgically No evidence of obstruction of the bowel was found in the remaining 29 cases Ten of these patients underwent surgery for non-obstructive intestinal disorders or conditions afflicting other organs Conservative treatment was employed in the remaining 19 patients

Discussion and Conclusions

Clinical and radiologic observations surgery and autopsy revealed a great number of conditions associated with sparse intestinal gas on conventional abdominal films (Table)

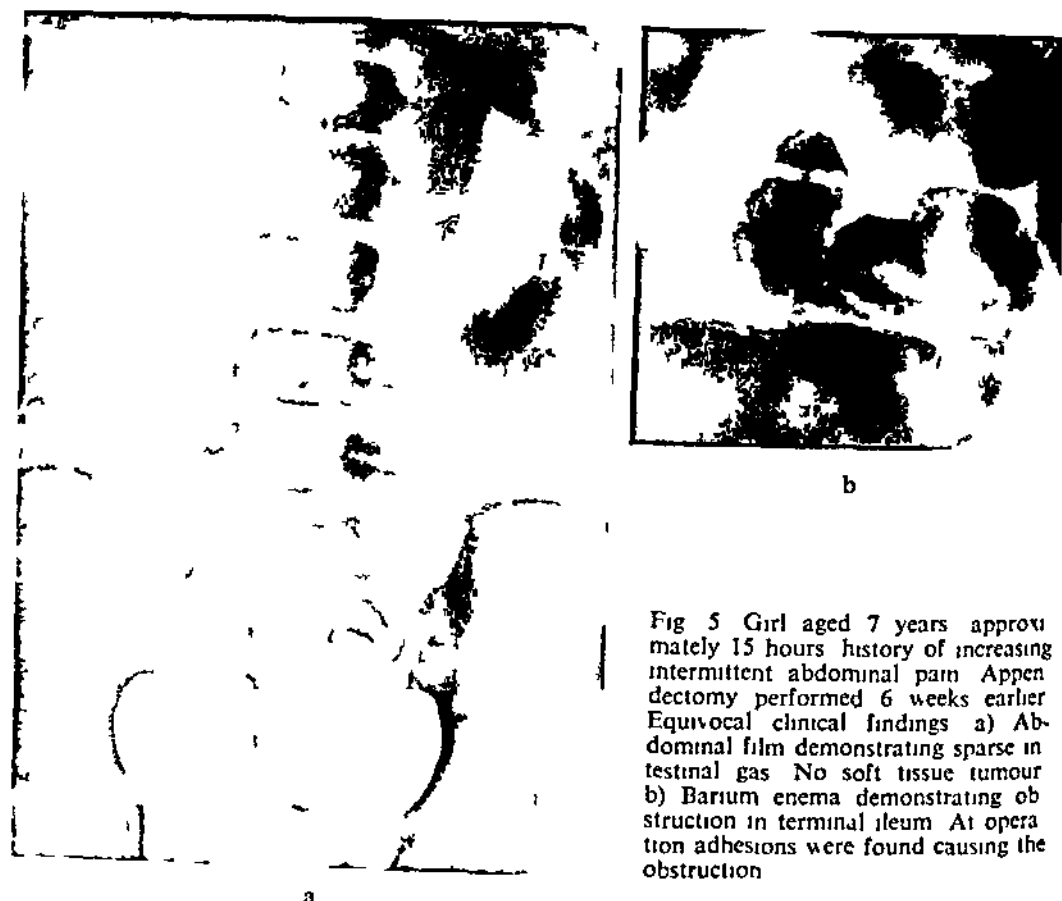


Fig 5 Girl aged 7 years approximately 15 hours history of increasing intermittent abdominal pain Appendectomy performed 6 weeks earlier Equivocal clinical findings a) Abdominal film demonstrating sparse intestinal gas No soft tissue tumour b) Barium enema demonstrating obstruction in terminal ileum At operation adhesions were found causing the obstruction

Gas in the intestines mainly consists of swallowed air To a lesser extent it may be released on neutralization of acid stomach contents as these enter the small bowel or by putrefaction in the bowel itself In certain circumstances diffusion of gas takes place from the blood into the bowel (SWART & MEYER 1974 FRIMANN DAHL 1974) Several factors impairing absorption of gas operate in cases of mechanical obstruction of the gut thus increasing distension of the bowel

Scanty intestinal gas is generally considered characteristic of disorders running a course with reduced responsiveness It has also been met with in sedated patients and in cases with marked retroperistalsis (SWART & MEYER) This is the case during the terminal stages of malignancies Nausea caused by the disease and by cytostatic drugs or other medication may result in abdominal distension and pain Except for air in the stomach the gastro-intestinal tract contains very little or no gas (Fig 1) In none of the present cases could bowel obstruction be proved

Severe pain for instance caused by blunt trauma by a twisted ovarian cyst or a ureteric concretion (Fig 2) may reduce involuntary swallowing of air and produce intestinal paralysis or retroperistalsis all factors liable to result in sparse amounts

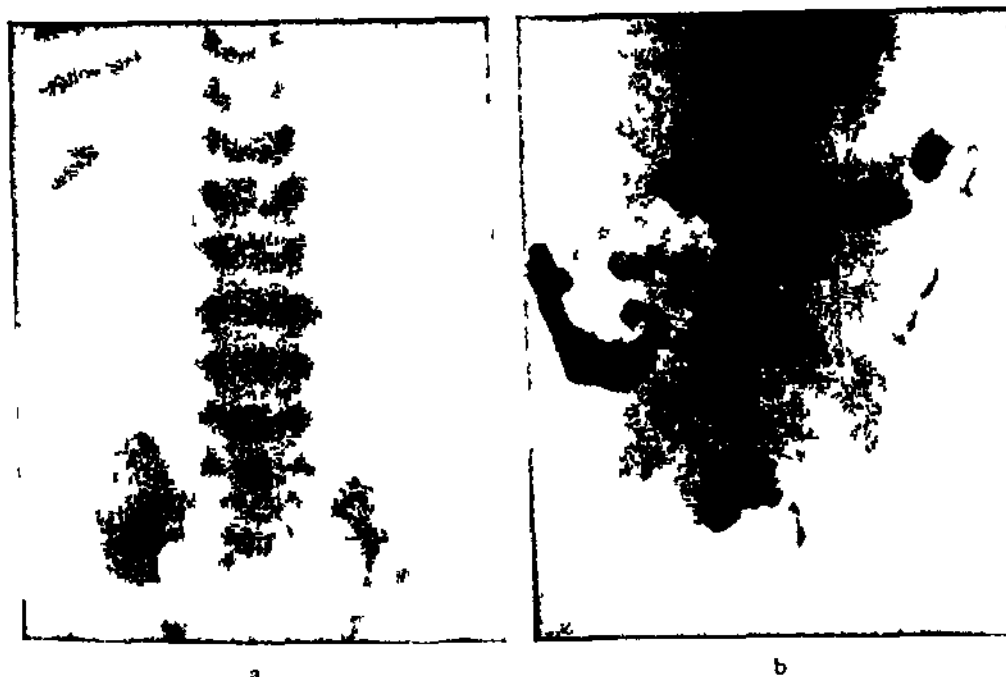


Fig 6 Boy aged 9 days respiratory distress syndrome and sepsis caused by staphylococcus aureus a) Reduced amount of intestinal gas Gastric tube Catheter in the bladder b) Film exposed -4 hours after contrast medium had been administered orally Severe acidosis Still only small amount of gas Collapsed large bowel containing some barium Patient recovered on conservative treatment

of gas in the intestines This effect has also been obs rved in pati nts with increased intracranial pressure and neurogenic disorders affecting deglutition (Fig 3)

Peritonitis secondary to app*ndicitis p ritoneal effusion of various etiology and abdominal complaints without definitive abnormality are oth*r conditions en countered in the series (Fig 4)

A scanty amount of intestinal gas is often h rved with high mechanical obstruc tion of the bowel However it may oc asic nally be encountered in low obstructions as well (Fig 5) Intussusception is by far the most common abdominal emergency associated with sparse intestinal gas The reason for the reduction is still unexplained

Acidosis or alkalosis in dehydrated neonates often in s*psis or in respiratory distress may present with almost no intestinal gas (Fig 6) (WEENS & GOLDEN 1955 FEINBERG et coll 1956 MARGULIS et coll 1956 BENSON & JACOBSON 1959 LOPRESTI et coll 1972) Severe gastro enteritis may cause a similar situation in older children

Abdominal emergency disorders pres*nting almost without gas in the gut are by no means uncommon in the pediatric age group It is evid*nt that the numb*r of conditions will increase considerably if due attention is paid to this feature

The value of extensive conventional roentgenography of the abdomen in different age groups has been analysed in detail by JORULF (1975) Yet often only one projec

tion is used routinely i e an upright a p view exposed with a horizontal beam This approach reduces the amount of obtainable information to a fraction of its potential However even with a multiprojectional technique the wide variety of conditions presenting with vague abdominal complaints and ambiguous findings on conventional films frequently makes supplementary contrast examinations necessary for a correct diagnosis At times repeat roentgenography of the abdomen may establish th diagnosis

SUMMARY

A material of 23 boys and 18 girls attending as abdominal emergencies and covering the age interval of neonates to 15 years of age had only scanty amounts of intestinal gas on films of the abdomen A wide variety of underlying abnormalities were revealed some of them calling for immediate operation Supplementary contrast examinations were frequently needed in order to establish the diagnosis

ZUSAMMENFASSUNG

Dreiundzwanzig Jungen und 18 Madchen neugeborene bis zu 15 Jahre alt die als abdominale akute Falle aufgenommen waren hatten nur geringe Mengen Intestinalgas auf der Bauchubersicht Mehrere unterschiedliche zu Grunde liegende Abnormitaten wurden festgestellt von denen einige eine unmittelbare Operation notwendig machten Eine zusatzliche Kontrastuntersuchung war haufig notwendig um die Diagnose zu sichern

RESUME

Une serie de 23 garçons et de 18 filles admis a l'hopital comme des urgences abdominales et dont les ages allaient du nouveau ne a 15 ans n avait que de petites quantites de gaz intestinaux sur les radiographies de l abdomen Une grande variété d anomalies sous jacentes ont ete decouvertes, dont certaines ont necessité une opération immediate Des examens supplementaires avec moyen de contraste ont ete souvent nécessaires pour etablir le diagnostic

REFERENCES

BENSON H H and JACOBSON G Deficiency of small intestinal gas in infants simulating obstruction Amer J Roentgenol 82 (1959) 450

BOHLIN H Conventional roentgenography in diagnosis of intussusception in children Acta radiol Diagnosis 2 (1964) 32

EKLÖF O Abdominal plain film diagnosis in infants and children Progr pediat Radiol 2 (1969) 3

FEINBERG S B MARGULIS A R and NICE C M The problem of absent or deficient gas pattern in the intestines in early infancy Pediatrics 18 (1956) 790

FRANKEN JR E A Gastrointestinal radiology in pediatrics First edition p 129 Harper & Row Publishers, Hagerstown Maryland 1975

FRIMANN DAHL J Roentgen examinations in acute abdominal diseases First edition p 35 and 81 1951 Third edition p 37 and 88 1974 Charles C Thomas Springfield Illinois
GIRDANY B R Diseases of the small intestine *In* Pediatric X ray diagnosis Sixth edition p 657 Edited by J Caffey Year Book Medical Publishers London 1973
GLAUNER R Die Leeraufnahme des Abdomens *In* Lehrbuch der Rontgendiagnostik Sixth edition Edited by H R Schinz et coll Georg Thieme Verlag Stuttgart 1965
JORULF H Tip of the liver in intussusception of the bowel in infancy and childhood Acta radiol Diagnosis 14 (1973) 26
— Roentgen diagnosis of intraperitoneal fluid Acta radiol (1975) Suppl No 343
LAURELL H Om rontgen vid akuta bukfall (In Swedish) Almqvist & Wiksell Uppsala 1939
LOPRESTI J M MAJD M and RANDOLPH J G The airless abdomen in the newborn infant Sth med J 65 (1972) 309
MARGULIS A R CONKLIN F P NICE C M and RIGLER L G Deficiency of intestinal gas in infants with diarrhoea Radiology 66 (1956) 93
SAMUEL E The acute abdomen *In* A textbook of radiology p 712 Edited by D Sutton assisted by R D Grainger E & S Livingstone Edinburgh London 1969
SWART B und MEYER G Die Diagnostik des akuten Abdomens beim Erwachsenen Ein neues klinisch rontgenologisches Konzept Radiologe 14 (1974) 1
WEENS S and GOLDEN A Adrenal cortical insufficiency in infants simulating high intestinal obstruction Amer J Roentgenol 74 (1955) 213

tion is used routinely i e an upright a p view exposed with a horizontal beam This approach reduces the amount of obtainable information to a fraction of its potential However even with a multiprojectional technique the wide variety of conditions presenting with vague abdominal complaints and ambiguous findings on conventional films frequently makes supplementary contrast examinations necessary for a correct diagnosis At times repeat roentgenography of the abdomen may establish the diagnosis

SUMMARY

A material of 23 boys and 18 girls attending as abdominal emergencies and covering the age interval of neonates to 15 years of age had only scanty amounts of intestinal gas on films of the abdomen A wide variety of underlying abnormalities were revealed some of them calling for immediate operation Supplementary contrast examinations were frequently needed in order to establish the diagnosis

ZUSAMMENFASSUNG

Dreiundzwanzig Jungen und 18 Madchen neugeborene bis zu 15 Jahre alt die als abdominale akute Falle aufgenommen waren hatten nur geringe Mengen Intestinalgas auf der Bauchubersicht Mehrere unterschiedliche zu Grunde liegende Abnormitaten wurden festgestellt von denen einige eine unmittelbare Operation notwendig machten Eine zusatzliche Kontrastuntersuchung war haufig notwendig um die Diagnose zu sichern

RESUME

Une série de 23 garçons et de 18 filles admis a l hopital comme des urgences abdominales et dont les ages allaient du nouveau né a 15 ans n avait que de petites quantites de gaz intestinaux sur les radiographies de l abdomen Une grande variété d anomalies sous jacentes ont ete découvertes dont certaines ont nécessité une operation immédiate Des examens supplementaires avec moyen de contraste ont eté souvent nécessaires pour établir le diagnostic

REFERENCES

BENSON H H and JACOBSON G Deficiency of small intestinal gas in infants simulating obstruction Amer J Roentgenol 82 (1959) 450

BOHLIN H Conventional roentgenography in diagnosis of intussusception in children Acta radiol Diagnosis 2 (1964) 32

EKLÖF O Abdominal plain film diagnosis in infants and children Progr pediat Radiol 2 (1969) 3

FEINBERG S B., MARGULIS A R and NICE C M The problem of absent or deficient gas pattern in the intestines in early infancy Pediatrics 18 (1956) 790

FRANKEN JR E A Gastrointestinal radiology in pediatrics First edition p 129 Harper & Row Publishers Hagerstown Maryland 1975

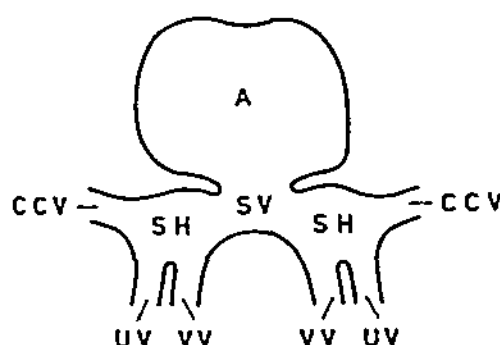


Fig. 1 Umbilical veins and connexions 4 weeks of intrauterine life A = atrium, CCV = common cardinal vein SH = sinus horn, SV = venous sinus UV = umbilical vein, VV = vitelline vein

horns i e the lateral parts of the venous sinus which in turn issues into the atrium of the primitive heart (Fig 1)

The original bilateral symmetry is gradually lost by changes occurring both in the sinus horns and in all their recipient veins The first vessel to be affected by this reorganisation process is the right umbilical vein which begins to obliterate already in the 4th week and eventually disappears The left umbilical vein undergoes similar changes though only the part closest to the sinus horn The remaining part connects with the hepatic sinusoids which have then arisen by transformation of a segment of the vitelline veins These sinusoids participate in the development of the portal venous branches and the ductus venosus The single umbilical vein normally persisting at birth is thus a residue of the primitive left umbilical vein.

On the left side the part of the vitelline vein closest to the sinus horn, and the entire common cardinal vein, also disappear The venous sinus and its left horn become incorporated in the wall of the atrium After completion of the interatrial septum this horn may persist in the left atrium as the oblique vein of Marshall whereas the actual venous sinus is converted into the coronary sinus

On the right side parts of the vitelline vein are transformed to hepatic veins and to the hepatic segment of the inferior vena cava and the right common cardinal vein becomes part of the superior vena cava The right sinus horn persists merely as the sinus venarum i e a part of the wall of the right atrium between the two caval openings

In the umbilical cord both umbilical veins are converted into one by fusion. The cord may therefore contain only one umbilical vein already before disappearance of the right umbilical vein in the embryo After birth the remaining umbilical vein and the ductus venosus regress and are obliterated but for a few days they can usually be catheterised from the cord stump

Abnormal development Several malformation complexes such as situs inversus and the asplenia and polysplenia syndromes include anomalies of vascular com ponents developmentally related to the umbilical veins but it is not known how these veins may be affected in such maldevelopment Only one case seems to be on record



Fig 2 Abnormal situs of heart and liver but not of aorta and stomach Feeding tube (arrows) demonstrates normal site of esophageal hiatus No visible minor pleural fissure

in which a truly anomalous umbilical vein existed (KAUFMANN & WEISSER 1964) This was in a newborn with situs inversus who was found at catheterisation to have two umbilical veins but although contrast medium was injected into at least one of these vessels the angiographic findings seem to have been insufficient for closer analysis of the supernumerary vein

A newborn male with an abnormal situs in whom the right umbilical vein was found to persist was recently observed at this department

Case report

The boy had an attack of cyanosis a few hours after birth but was otherwise in a good general condition Treatment included the insertion of a feeding tube and umbilical catheterisation after which he was referred for a chest film and checking of the position of the catheter Three vessels had been observed to exist in the umbilical cord

The heart was found to have a right sided apex whereas the site of the aortic arch and descending aorta was normal The stomach and a major part of the liver were left sided The position of the feeding tube revealed that the esophageal hiatus was at its ordinary site in the diaphragm (Fig 2) A search was made for the interlobar pleura in several views but neither in the right nor in the left lung could any minor fissure be identified

Umbilical vessels The catheter had been inserted through the right umbilical artery but was arrested in the iliac artery and therefore withdrawn Arterial catheterisation was again attempted 4 days later but by that time the cord stump had already been shed and only one of the vascular openings in the umbilical pit allowed insertion of a catheter This vessel was found at angiography to be only 2 mm wide and to run an oblique course to the



Fig 3 Umbilical phlebography 4 days of age a) A p b) lateral view Right umbilical vein Arrow at tip of catheter

right hemidiaphragm without branching and without communicating with the portal system (Fig 3)

Having pierced the diaphragm almost 4 cm from the midline the anomalous vessel reached the right border of the heart It emptied into the right atrium but apparently via a system of narrow channels in the atrial wall (Fig 4) The contrast medium was rapidly diluted by blood in the atrium but could be subsequently seen to reach the ascending aorta slightly later than the pulmonary artery

Concomitant findings In addition to the abnormal situs of the heart and liver evident already in the chest films malrotation of the bowel suggesting a common mesentery was demonstrated by a barium meal which also confirmed that the esophagus and stomach were normal Urography revealed no abnormality

At 3 weeks of age heart catheterisation via a femoral vein and cardioangiography were carried out in another hospital The course taken by the catheter indicated that the inferior vena cava was normal The injection was made into the right ventricle which proved to be abnormally high in position and to form most of the right heart border A minor right to-left shunt through an interatrial septum defect was demonstrated The right atrium and the abdominal aorta were not included in the examination

Since the initial attack of cyanosis the child has been largely free from symptoms

Discussion

From its course and the absence of communication with the portal system the vein catheterised via the umbilicus in the present case was identified as the right umbilical vein The early normal disappearance of this vein has been considered partly re sponsible for the subsequent developmental changes in the venous sinus and its horns It therefore seems likely that persistence of the right umbilical vein will



Fig 4 a) A p b) lateral view Contrast medium reaching right atrium via channels in its wall

modify the derivatives of the venous sinus or at least its right horn This might explain the peculiar channels found in the atrial wall

One of the three vessels found in the umbilical cord was identified as the right umbilical artery One of the others may have been the l ft umbilical artery or possibly the left umbilical vein It seems likely that an ordinary l ft umbilical vein securing fetal circulation of placental blood through the portal system was present but it should be recollected that even if both umbilical veins persisted they might have fused into one in the umbilical cord

It is remarkable that despite the intense use of angiography and the dis overy of congenital anomalies in nearly all parts of the vascular system a persistent right umbilical vein has apparently not previously been observed However this may not reflect the true incidence of the anomaly because no umbilical vessel is likely to remain patent very long after birth Even in the newborn an anomalous umbilical vein may easily escape recognition at umbilical catheterisation and angiography and also at autopsy In the case reported by KAUFMANN & WEISSER for example one of the two catheterised vessels may have been a persistent right umbilical vein

The combination of a persistent right umbilical vein with an abnormal situs of the heart and liver is probably not merely coincidental These malformations date back to roughly the same early stage of development and may have a common cause or be interdependent They may also be developmentally related to the other abnormalities found in the heart and digestive system in the present case as well as to several further anomalies Such combined malformations are frequently specific entities as shown by IVEMARK (1955) in his analysis of the asplenia and polysplenia syndromes

At the first radiologic examination polysplenia was thought to be present because of the type of abnormal situs and because no minor pl ural fissure could be demon

strated The attempts at umbilical angiography were made in an endeavour to confirm or refute this diagnosis Though umbilical angiography could not be performed in the way intended the findings made at this and the subsequent examinations appear consistent with a polysplenia syndrome An exact radiologic diagnosis would however require abdominal angiography (VAUGHAN et coll 1971)

Addendum in proof

Recently we found an annotation by I W MONIE (Teratology 4 (1971) 461) calling attention to an autopsy report of a stillborn boy which was published in 1826 by D MENDE who had observed that the umbilical vein passed outside the liver to the right atrium The only further anomaly seen in this baby was absence of the right umbilical artery

MONIE s article also gives references to several vascular malformations induced in the offspring of rats by various teratogenic measures during pregnancy These malformations include absence of the ductus venosus and persistence of the right umbilical vein running extrahepatically to the inferior vena cava

SUMMARY

The ontogeny of the umbilical venous system is described and a case is reported in which a persistent right umbilical vein was angiographically demonstrated in a 4-day old infant

ZUSAMMENFASSUNG

Die Ontogenie des Nabelvenensystems wird beschrieben und ein Fall berichtet in dem eine persistierende rechte Nabelvene bei einem 4 Tage alten Saugling angiographisch nachgewiesen wurde

RÉSUMÉ

Description de l ontogénèse du système veineux ombilical et presentation d un cas ou une veine ombilicale droite persistante a été mise en evidence par angiographie chez un nourrisson age de 4 jours

REFERENCES

AREY L B Developmental anatomy 7th ed W B Saunders Co Philadelphia and London 1965

BAKER D H BERDON W E and JAMES L S Proper localization of umbilical arterial and venous catheters by lateral roentgenograms Pediatrics 43 (1969) 34

CAMPBELL R E Liver size evaluation in the early newborn A new role for the umbilical vein catheter Radiology 103 (1972) 165

IVEMARK B J Implications of agenesis of the spleen on the pathogenesis of conotruncus anomalies in childhood Acta paediat (1955) Suppl No 104

KAUFMANN H J and WEISSER K Neonatal transumbilical angiography A preliminary report Ann Radiol 7 (1964) 437

— — Technik und Anwendungsgebiete der neonatalen transumbilikalen Angiographie Rontgenpraxis 21 (1968) 223

PECK D R and LOWMAN R M Roentgen aspects of umbilical vascular catheterization in the newborn Radiology 89 (1967) 874

ROSEN M S and REICH S B Umbilical venous catheterization in the newborn Identification of correct positioning Radiology 95 (1970) 335

SAGEL S S and ABLOW R C The use of umbilical venography for the diagnosis of congenital right sided diaphragmatic hernia Radiology 91 (1968) 797

VAUGHAN T J HAWKINS I F and ELLIOTT L P Diagnosis of polysplenia syndrome Radiology 101 (1971) 511

FROM THE DEPARTMENT OF RADIOLOGY AND THE CARDIOVASCULAR RESEARCH INSTITUTE
UNIVERSITY OF CALIFORNIA SCHOOL OF MEDICINE SAN FRANCISCO CALIFORNIA 94143
USA

TOTAL ANOMALOUS PULMONARY VENOUS RETURN IN ASSOCIATION WITH TETRALOGY OF FALLOT

Report of a case

J C FIELD R C GROSS R G HOLT and E CARLSSON

In patients with tetralogy of Fallot pulmonary venous drainage is usually normal (VAN PRAAGH & VAN PRAAGH 1965) although occasional association with partial anomalous pulmonary venous return has been reported (BLALOCK 1948 KJELLBERG et coll 1959 MUSTER et coll 1959) Other associated cardiovascular malformations are not uncommon (GASUL et coll 1966) However the simultaneous occurrence of tetralogy of Fallot and total anomalous pulmonary venous return is quite rare only 3 cases (without heterotaxy) having been reported previously (DELISLE et coll 1976 MUSTER et coll 1973) An additional case of this rare combination of findings is now presented with emphasis on the clinical presentation radiographic findings and pathology demonstrated at autopsy

Case reports

An 11 month old girl cyanotic since her birth She had no other cardiorespiratory symptoms A cousin has possible polysplenia and an atrial septal defect

On physical examination the child was moderately cyanotic well nourished well de

Supported in part by National Heart and Lung Institute Training Grant in Cardiovascular Radiology HL 05824 Submitted for pulication 14 June 1976



Fig 1 P a projection of an injection in the left vertical vein Right and left pulmonary veins unite behind the left atrium to form the left vertical vein which communicates superiorly with the dilated left innominate vein as in total anomalous pulmonary venous return type I

veloped and in no distress Arterial and venous pulses were normal A mild right ventricular heave was present S_1 was normal S_2 was single and prominent A Grade III/VI long systolic ejection murmur was heard best along the left sternal border Right ventricular hypertrophy was demonstrated at ECG

The following data were obtained at cardiac catheterization

Pressures (mmHg) Right ventricle 77/4 pulmonary artery 18/11 left ventricle 76/7 aorta 75/44

Representative oxygen saturations (per cent) High superior vena cava 82 low superior vena cava 85 right atrium 81 left ventricle 79 inferior vena cava at junction of right atrium 74 inferior vena cava subphrenic 64 aorta 74

Flows (Fick l/min/m²) Pulmonary 4 9 systemic 6 2

Shunts Left to right 2 5 1 right to left 3 8 1

Cinecardioangiography demonstrated that a single right and a single left pulmonary vein received all of the pulmonary venous drainage from each lung These 2 veins united behind the left atrium to form a left vertical vein which communicated superiorly with the dilated left innominate vein (Fig 1) as in total anomalous pulmonary venous return type I

No pulmonary venous obstruction was present The superior vena cava was dilated A high ventricular septal defect of moderate size pulmonic valvar stenosis with post stenotic dilatation of the main pulmonary artery stenosis of the proximal right ventricular infundibulum and right ventricular hypertrophy constituted the characteristic findings of tetralogy of Fallot (Fig 2) The peripheral pulmonary arteries were slightly dilated (Fig 2 c) An atrial septal defect was present An aberrant left subclavian artery arose from the right aortic arch (Fig 3)

Following cardiac catheterization the patient remained asymptomatic except for cyanosis until 16 months of age when she began to have repeated episodes of marked cyanosis and

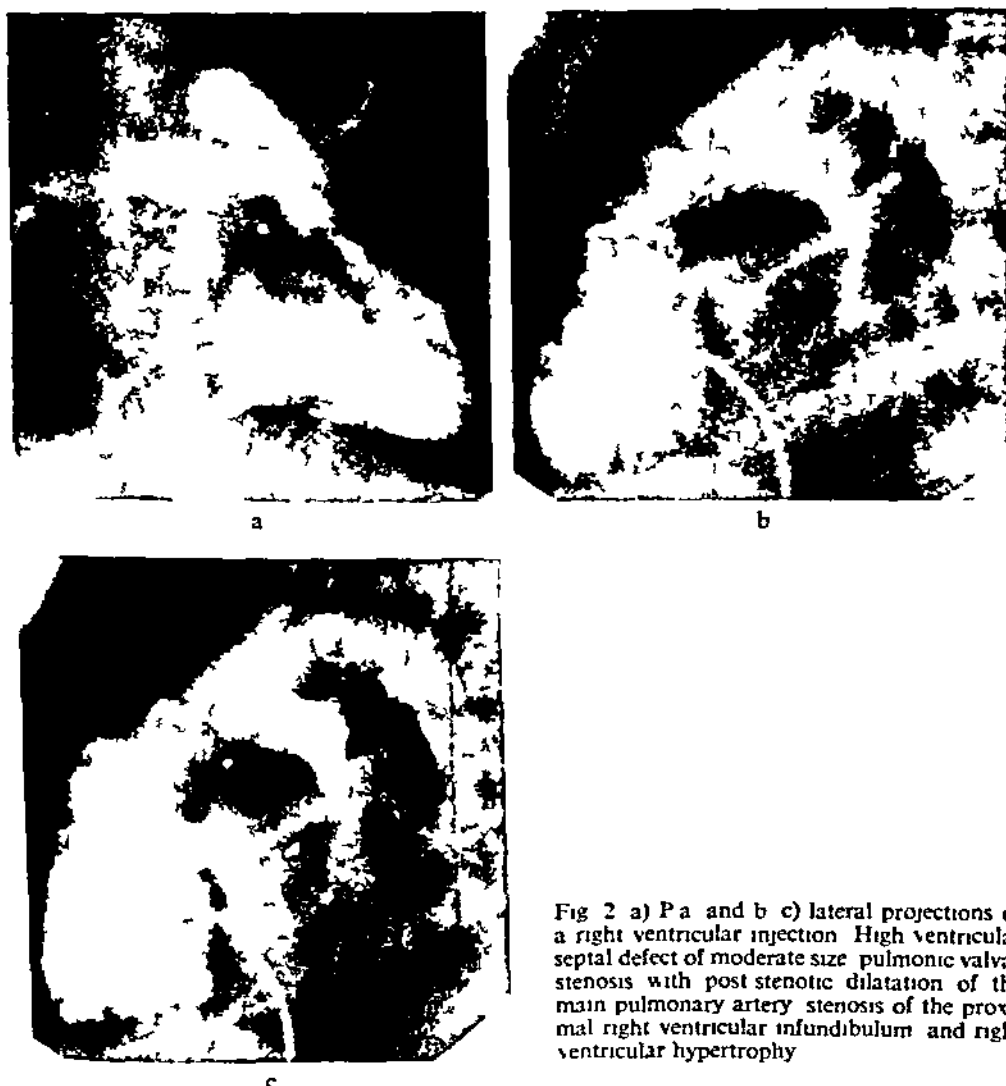


Fig 2 a) P a and b c) lateral projections of a right ventricular injection High ventricular septal defect of moderate size pulmonic valvar stenosis with post stenotic dilatation of the main pulmonary artery stenosis of the proximal right ventricular infundibulum and right ventricular hypertrophy

respiratory distress which were usually precipitated by crying Dyspnea and fatigue on exertion were observed to occur more readily than before and she frequently assumed a squatting position At 19 months of age the patient was readmitted for corrective surgery Physical findings were unchanged ECG demonstrated right atrial and ventricular hypertrophy and primary atrioventricular heart block A chest film (Fig 4) demonstrated normal pulmonary vessels evidence of right heart enlargement widening of the right superior mediastinum secondary to the right aortic arch and the dilated superior vena cava and widening of the left superior mediastinum caused by the presence of the vertical vein

At surgery an anastomosis was created between the left atrium and the transverse segment of the right pulmonary vein the left atrium was enlarged with a pericardial path the vertical vein was ligated the atrial and ventricular septal defects were closed with teflon patches a commissurotomy of the pulmonic valve was performed and a pericardial patch was applied



Fig 3 P a projection Left ventricular injection Right aortic arch and aberrant course of the left subclavian artery



Fig. 4 Chest films Normal pulmonary vessels evidence of right heart enlargement widening of the right superior mediastinum secondary to the right aortic arch and dilated superior vena cava and widening of the left superior mediastinum caused by the left vertical vein

to the right ventricular outflow tract following resection of the infundibular stenosis Thus a total anatomic correction was achieved

Postoperatively the patient developed intractable pulmonary edema renal failure and disseminated intravascular coagulation She expired on the fourth postoperative day

At autopsy although the anastomosis between the left atrium and the transverse segment of the right pulmonary vein was widely patent and the surgical enlargement of the left atrium seemed adequate for the accommodation of systemic blood flow the junctions of the single left and right pulmonary veins with the more peripheral pulmonary veins appeared to be partially obstructed by incomplete webs or membranes In addition large bronchial arteries



Fig 5 Anterior view of the heart and lungs following their removal from the thorax Left vertical vein connected to the left innominate vein. The large central vessel is the ascending aorta

to both lungs were present These findings might account for the relentless postoperative pulmonary edema The vertical vein and its connection with the left innominate vein are illustrated in Fig 5 which is a photograph of the autopsy specimen

Discussion

At cardiac catheterization high oxygen saturations in the superior vena cava and right side of the heart with respect to the inferior vena cava reflected total anomalous pulmonary venous return to the left innominate vein whereas systemic arterial desaturation was produced by the mixing of pulmonary and systemic venous return in the right atrium

The surprising absence of cardiorespiratory symptoms before the age of 16 months except for the obligatory cyanosis may be attributed to the pulmonic stenosis which was of the exact degree required to prevent flooding of the pulmonary vessels with both systemic and pulmonary venous return and yet to allow simultaneously a high normal pulmonary blood flow instead of the markedly reduced flow which is so often found in classic tetralogy of Fallot It should be noted that the predominant shunt was from right to left and that the pulmonary blood flow was 80 per cent of the elevated systemic blood flow

Early congestive heart failure which is a common feature of total anomalous pulmonary venous return (Gasul et coll 1966 Rowe & Mehrizi 1968) was notably absent in the present case and in the 2 cases presented by Muster et coll (1973) probably because of the prevention of pulmonary overcirculation by pulmonic

stenosis All 3 patients presented clinically as tetralogy of Fallot In contrast to the moderate obstruction of right ventricular outflow in the present case the patients of MUSTER et coll had severe pulmonic stenosis (pulmonary atresia in one case) which led to clinical difficulties from hypoxia in the neonatal period

Each of the 3 cases presented a different anatomic type of total anomalous pulmonary venous return (DARLING et coll 1957) The first case of MUSTER et coll was type IV (mixed type) with anomalous drainage of all pulmonary veins into the coronary sinus except for drainage of the left upper lobe pulmonary vein into a left vertical vein which entered the left innominate vein Their second case had a type III (infracardiac) anomalous connection with the portal vein The present case had a type I (supracardiac) anomalous connection of the left vertical vein with the left innominate vein The vertical vein received all of the pulmonary venous return

SUMMARY

A case of total anomalous pulmonary venous return in association with tetralogy of Fallot is described

ZUSAMMENFASSUNG

Ein Fall eines vollstandig anomalen pulmonellen venosen Ruckflusses im Zusammenhang mit einer Fallot schen Tetralogie wird beschrieben

RESUME

Description d un cas de retour veineux pulmonaire anormal total associe à une tetralogie de Fallot

REFERENCES

BLALOCK A Surgical procedures employed and anatomical variations encountered in the treatment of congenital pulmonic stenosis Surg Gynec Obstet 87 (1948) 385

DARLING R E ROTHNEY W B and CRAIG J M Total pulmonary venous drainage into the right side of the heart Lab Invest 6 (1957) 44

DELISLE G ANDO M CALDER A L ZUBERBUHLER J R ROCHENMACHER S ALDAY L E MANGINI O VAN PRAAGH S V and VAN PRAAGH R Total anomalous pulmonary venous connection Report of 93 autopsied cases with emphasis on diagnostic and surgical considerations Fund clin Cardiol 91 (1976) 99

GASUL B M ARCILLA R A and LEV M Heart disease in children p 608 Lippincott Philadelphia 1966

KJELLBERG S R MANNHEIMER E RUDHE U and JONSSON B Diagnosis of congenital heart disease p 249 Yearbook Medical Publishers Chicago 1959

MUSTER A J PAUL M H and NIKAIDOH H Tetralogy of Fallot associated with total anomalous pulmonary venous drainage Chest 64 (1973) 323

ROWE R D and MEHRIZI A The neonate with congenital heart disease p 219 Saunders Philadelphia 1968

VAN PRAAGH R and VAN PRAAGH S The anatomy of common aorticopulmonary trunk (truncus arteriosus communis) and its embryologic implications A study of 57 necropsy cases Amer J Cardiol 16 (1965) 406

FROM THE DEPARTMENT OF RADIOLOGY AND THE CARDIOVASCULAR RESEARCH INSTITUTE
UNIVERSITY OF CALIFORNIA SCHOOL OF MEDICINE SAN FRANCISCO CALIFORNIA 94143
USA

DISPLACEMENT OF LEFT VENTRICLE IN ATRIAL SEPTAL DEFECT

H RINGERTZ J YOUKER and E CARLSSON

It has long been observed that marked right ventricular enlargement causes posterior displacement of the left ventricle and rotation of the heart into the left hemithorax thereby reducing the space occupied in the right hemithorax by the right atrium and superior vena cava The increasing posterior displacement of the left ventricle with increasing left to right shunt at the atrial level is demonstrated in Fig 1 However no quantitative analysis of this phenomenon is available Physiologic investigations of the effect of right ventricular enlargement upon the left ventricle including right and left ventricular volume measurements have been reported (GRAHAM et coll 1972 POPIO et coll 1975)

The purpose of this report is to show that the position of the left ventricle in the chest is closely correlated to the relative volume of the right venctricular cavity in a series of patients with atrial septal defect The series consisted of 28 patients 15 females and 13 males The age range was 2 weeks to 71 years the average age being 10 years and the median age 4 years Cardiac catheterization and cineangiography were performed in all patients In 3 cases a low grade pulmonary stenosis was present and in 3 cases the mitral valve was deformed but not insufficient No other shunt than the one through the atrial septal defect was present in any case

Supported in part by Statens Medicinska Forskningsråd Dnr 385/74 and NHLI Training Grant in Clinical Radiology (HL05875) Submitted for publication 15 April 1977



Fig. 1 Lateral films from left ventricular angiography in three patients with atrial septal defect. Left to-right shunts as measured by increasing oxygen saturation in the right ventricle during cardiac catheterization was from left to right 1 3 2 0 and 2 9 Progressively increasing posterior displacement of the left ventricle

Methods

The radiologic examinations were performed with a biplane 16 mm GE cine system at 60 frames per second in each plane exposed alternately The volumes of the ventricles at end-diastole and end systole were calculated according to the method described by GOERKE & CARLSSON (1967) The stroke volume and the end-diastolic volume of the right ventricle were corrected for effective diastolic filling time according to CARLSSON et coll (1971) The average correction was 1 17 with a range of 0 79 to 1 63 The end-diastolic right ventricular volume was taken to be the sum of the uncorrected end systolic volume and the corrected stroke volume

The relative size of the right ventricle was calculated as the ratio between right and left ventricular end-diastolic volumes as well as the ratio of the right to left ventricular stroke volumes

The axis of the left ventricle was defined as the line between the center of the aortic valvar plane and the calculated center of gravity of the left ventricle This line was constructed at end-systole and end-diastole in the antero-posterior and lateral views The angle between the average position of these two lines and a transverse plane through the body was calculated in each projection A ventricle with the center of gravity below and slightly anterior and to the left of the center of the aortic valve would give a slightly less than 90 angle in both projections A series of contour drawings of the left ventricle in the antero-posterior and lateral view with the axis of the left ventricle drawn appear in Fig 2

The sizes of the angles in the antero-posterior and lateral views were plotted against each other (Fig 5) A close correlation between stroke volume ratio on one

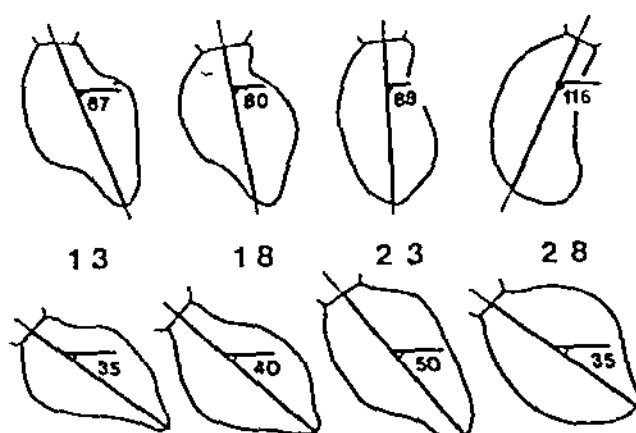


Fig 2. Upper row Average position of the left ventricular axis in the lateral projection anterior wall to the right lower row left ventricular axis in the a p projection The numbers between the rows indicate from right to left the right-left ventricular stroke volume ratios

hand and the angle measured in the lateral view on the other is evident The following analysis was performed to explore whether an even closer correlation could be obtained in an oblique projection

A third composite angle P was calculated from the angles above—A_{lt} and A_{ap}—according to the formula

$$P = A_{lt} \times \cos V + A_{ap} \times \sin V$$

The variable angle V represents the deviation from the true lateral view The value of P was correlated to stroke volume ratios as well as relative right ventricular end diastolic volumes for every two degrees of the angle V Standard statistical methods were applied

Results

The findings are summarized in Table 1 in order of increasing right to left ventricular stroke volume ratios The right and left ventricular stroke volumes per square meter body surface area according to DU BOIS & DU BOIS (1916) are given in columns 3 and 4 The averages and standard deviations (SD) were 54 ± 24 ml and 30 ± 10 ml respectively The ratio between the stroke volumes is given in column 5 and ranges between 0 94 and 2 92 The average and SD was $1\ 85 \pm 0\ 55$ Columns 6 to 8 give the right and left end diastolic ventricular volumes and the ratio of these two respectively The average and SD of these three parameters were found to be 93 ± 41 ml 45 ± 15 ml and $2\ 08 \pm 0\ 75$ respectively The measured angles of the left ventricle in the lateral and postero anterior projections are given in columns 9 and 10 Their averages and SD were 86 ± 17 and 38 ± 10 The last column (11) shows the composite value P for an optimum angle V=32 Statistical analysis showed a maximum correlation r=0 89 between the relative right ventricular end diastolic volume and the compositive angle P The plot in Fig 5 rotated 32 represents a left

Table 1

Findings in order of increasing right to left ventricular stroke volume ratios 1—Case No 2—Age (years) and sex 3—RSV/m² (ml) 4—LSV/m² (ml) 5—RSV/LSV 6—RVEDV/m² (ml) 7—LVEDV/m² (ml) 8—RVEDV/LVEDV 9—Lateral (degrees) 10—P.a (degrees) 11—P/V

1	2		3	4	5	6	7	8	9	10	11
1	0.6 (6 m 3 w)	F	26	27	0.94	41	36	1.15	58	35	68
2	0.02 (2 w)	M	24	21	1.14	34	31	1.10	69	32	75
3	0.02 (2 w)	F	29	23	1.25	42	39	1.06	62	28	67
4	7	F	62	49	1.26	93	60	1.56	66	43	79
5	2	F	43	33	1.28	66	45	1.47	76	39	85
6	2	F	38	30	1.29	68	48	1.42	78	27	79
7	5	M	46	34	1.36	99	48	2.06	71	39	81
8	0.4 (4 m 2 w)	M	23	17	1.36	32	24	1.33	75	32	80
9	6	M	48	31	1.56	102	59	1.74	79	46	91
10	11	M	55	35	1.56	126	62	2.04	78	48	91
11	0.1 (5 w)	M	46	29	1.58	61	38	1.59	86	30	88
12	5	F	44	28	1.58	79	57	1.38	75	35	82
13	0.8 (9 m)	M	68	42	1.61	122	76	1.61	91	29	91
14	3	F	71	42	1.67	105	56	1.88	85	33	89
15	4	M	64	37	1.72	111	54	2.05	79	37	86
16	51	F	55	32	1.73	96	47	2.03	100	24	96
17	3	F	32	18	1.77	46	24	1.94	71	58	91
18	3	F	90	43	2.11	144	65	2.22	85	47	97
19	6	F	53	25	2.16	100	39	2.53	78	60	98
20	11	F	72	32	2.28	96	43	2.25	87	60	106
21	4	F	53	23	2.29	103	38	2.68	97	35	100
22	6	M	64	27	2.36	132	42	3.17	95	47	105
23	6	M	102	42	2.42	173	61	2.83	94	39	99
24	4	F	61	25	2.45	87	38	2.29	95	39	100
25	67	M	24	9	2.55	43	16	2.66	116	29	112
26	1	M	92	34	2.69	168	51	3.31	114	32	112
27	2	M	105	38	2.77	168	62	2.69	115	42	118
28	71	F	23	8	2.98	55	13	4.32	125	29	119

lateral projection with the patient rotated 32° left side forward (Fig 3) For ventricular stroke volume ratios the corresponding optimum angle was 34° with $r = 0.95$ (Fig 4) Dividing the material into four groups according to the size of the stroke volume ratio gave the typical angular findings presented in Table 2 and Fig 5

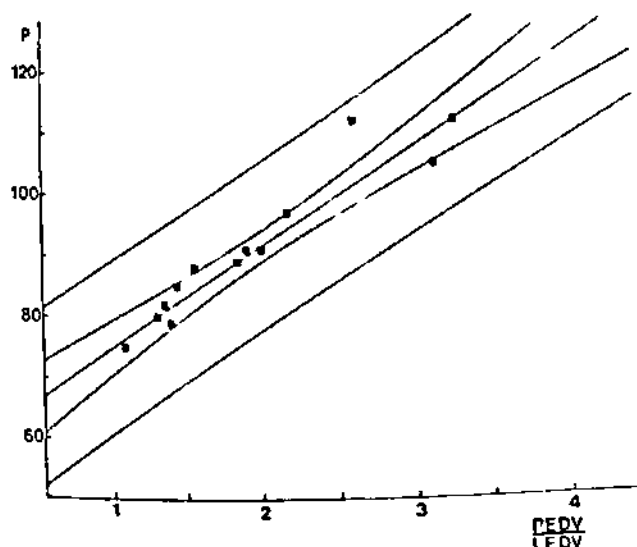


Fig 3 Plot of the composite angular measurement P against the right-left ventricular end diastolic volume ratio r = 0 886

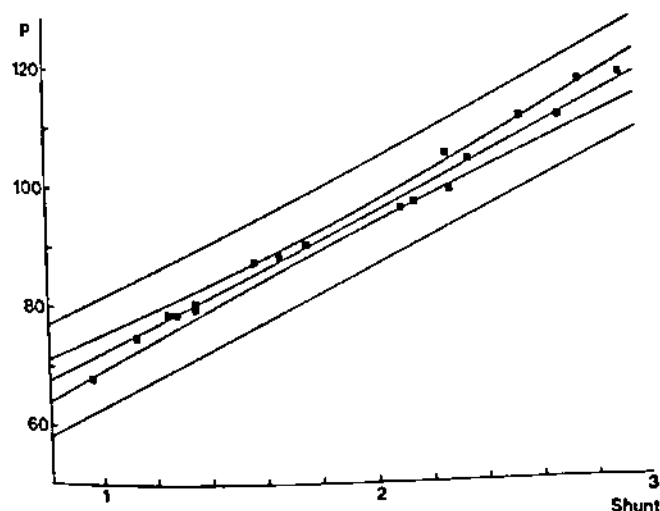


Fig 4 Plot of the composite angular measurement P and the right-left ventricular stroke volume ratios r = 0 953

Discussion

The effect of right ventricular enlargement upon the overall cardiac performance is largely unexplored On the basis of animal experiments involving destruction by cauterization of the anterior right ventricular wall and exclusion of the right ventricle it has been claimed that the right ventricle does not play a significant role in the function of the heart (KAGAN 1952 SADE & CASTANEDA 1975) However it is possible that a complete absence of right ventricular myocardial function is less deleterious to the function of the heart than a markedly enlarged right ventricle Recent reports indicate that the left ventricle suffers from impaired diastolic filling as a

Table 1

Findings in order of increasing right to left ventricular stroke volume ratios 1—Case No 2—Age (years) and sex 3—RSV/m² (ml) 4—LSV/m² (ml) 5—RSV/LSV 6—RVEDV/m² (ml) 7—LVEDV/m² (ml) 8—RVEDV/LVEDV 9—Lateral (degrees) 10—P a (degrees) 11—P/V

1	2		3	4	5	6	7	8	9	10	11
1	0 6 (6 m 3 w)	F	26	27	0 94	41	36	1 15	58	35	68
2	0 02 (2 w)	M	24	21	1 14	34	31	1 10	69	32	75
3	0 02 (2 w)	F	29	23	1 25	42	39	1 06	62	28	67
4	7	F	62	49	1 26	93	60	1 56	66	43	79
5	2	F	43	33	1 28	66	45	1 47	76	39	85
6	2	F	38	30	1 29	68	48	1 42	78	27	79
7	5	M	46	34	1 36	99	48	2 06	71	39	81
8	0 4 (4 m 2 w)	M	23	17	1 36	32	24	1 33	75	32	80
9	6	M	48	31	1 56	102	59	1 74	79	46	91
10	11	M	55	35	1 56	126	62	2 04	78	48	91
11	0 1 (5 w)	M	46	29	1 58	61	38	1 59	86	30	88
12	5	F	44	28	1 58	79	57	1 38	75	35	[illegible]
13	0 8 (9 m)	M	68	42	1 61	122	76	1 61	91	29	91
14	3	F	71	42	1 67	105	56	1 88	85	33	89
15	4	M	64	37	1 72	111	54	2 05	79	37	86
16	51	F	55	32	1 73	96	47	2 03	100	24	96
17	3	F	32	18	1 77	46	24	1 94	71	58	91
18	3	F	90	43	2.11	144	65	2.22	85	47	97
19	6	F	53	25	2.16	100	39	2 53	78	60	98
20	11	F	72	32	2.28	96	43	2 25	87	60	106
21	4	F	53	23	2 29	103	38	2.68	97	35	100
22	6	M	64	27	2.36	132	42	3 17	95	47	105
23	6	M	102	42	2 42	173	61	2 83	94	39	99
24	4	F	61	25	2.45	87	38	2 29	95	39	100
25	67	M	24	9	2.55	43	16	2.66	116	29	112
26	1	M	92	34	2 69	168	51	3 31	114	32	[illegible]
27	2	M	105	38	2.77	168	62	2.69	115	42	118
28	71	F	23	8	2.98	55	13	4 32	125	29	119

lateral projection with the patient rotated 32 left side forward (Fig 3) For ventricular stroke volume ratios the corresponding optimum angle was 34 with r=0 95 (Fig 4) Dividing the material into four groups according to the size of the stroke volume ratio gave the typical angular findings presented in Table 2 and Fig 5

view GRAHAM et coll reported similar although less marked findings in children with atrial septal defect.

In patients with right ventricular enlargement on the basis of a left to-right shunt at the atrial level or right heart valvar insufficiency a varying degree of myocardial insufficiency may be superimposed Pressure and flow determinations do not adequately define this complex functional state of the heart without data on the absolute and relative right and left ventricular volumes

Limited clinical experience with patients with marked pulmonary valve insufficiency indicates that right ventricular enlargement may constitute a more serious problem than is generally believed However no quantitative data are available As left ventricular diastolic filling appears to be impaired by marked right ventricular enlargement an assessment of the volume ratio between the right and left ventricle may be clinically useful in such conditions as combined coarctation of the aorta and atrial septal defect, when the decision must be made as to which lesion should be operated upon first. If the coarctation is operated first the small hypertrophic left ventricle may conceivably suffer from significantly reduced diastolic filling in the postoperative period jeopardizing the outcome of the operation

Information on the positional changes of the left ventricle and its causes is of significance for diagnosis of cardiac pathology at conventional radiography It appears from Fig 2 that the lateral displacement of the left ventricular apex as a result of right ventricular enlargement as opposed to the posterior displacement of the apex reaches a minimum at a certain degree of right ventricular stroke volume and end diastolic volume The angular lateral moment is a discontinuous function of the right ventricular size while the angular posterior displacement is continuous Because of the strong correlation between posterior apical displacement of the left ventricle and relative right ventricular stroke volume the lateral angle will have only little effect on the overall correlation between the combined angular value and the right ventricular enlargement

For the same atrial filling pressure the effective diastolic filling pressure of the left ventricle will be less than that for the right ventricle because of the greater restriction to filling exerted by the thickness of the left ventricular myocardium The angulation of the left ventricle and the mitral plane which occurs possibly influences the diastolic filling of the left ventricle as well However no conclusive evidence on this point exists The angulation of the left ventricle cranio-posteriorly will produce lower filling pressure for the same atrial pressure in the erect position because of reduced hydrostatic pressure

The significance of the described findings from the practical angiographic point of view is essentially that the yield of the left ventriculography increases The left ventriculography may be used for an assessment of right ventricular enlargement, as well and not only for functional and anatomic evaluation of the left ventricle

The close correlation between the angular position of the left ventricle and the volume of the right ventricle may also prove useful in assessment of right to left

ventricular volume ratios by echocardiography isotope examinations and computed tomography Investigations to explore the possibilities for such non invasive determination of right to left ventricular volume ratios are initiated

SUMMARY

Catheterization and biplane cineangiography were performed in 28 patients with atrial septal defect The left and right ventricular volume in end systole and end-diastole were estimated with a computed method The relation between the left and right stroke volume ratio and the posterior displacement of the left ventricle was analysed A statistically highly significant positive correlation between the angle of the long axis of the left ventricle and the shunt was established

ZUSAMMENFASSUNG

Katheterisierung und Angiographie in zwei Ebenen wurden bei 28 Patienten mit arteriellem Septum Defekt vorgenommen Das Volumen des linken und rechten Ventrikels in der End Systole und End Diastole wurde mit einer Computer Methode festgestellt Die Relation zwischen dem linken und rechten Schlagvolumen Verhaltnis und der Verschiebung des linken Ventrikels nach hinten wurde analysiert Eine statistisch hoch signifikante positive Korrelation zwischen dem Winkel der Langsachse des linken Ventrikels und dem Shunt wurde festgestellt

RESUME

Les auteurs ont fait un cathétérisme et une cineangiographie bidirectionnelle chez 28 malades ayant une communication inter auriculaire septale Ils ont estime par une méthode utilisant un ordinateur les volumes télé systoliques et téle diastoliques des ventricules gauche et droit Ils ont etudié la relation entre le rapport du volume d ejection gauche et droit et le déplacement postérieur du ventricule gauche Ils ont trouvé une corrélation positive statistiquement tres significative entre l angle du grand axe du ventricule gauche et le shunt

REFERENCES

CARLSSON E KEENE R J LEE P and GOERKE R J Angiocardiographic stroke volume correlation of the two cardiac ventricles in man Invest Radiol 6 (1971) 44

DU BOIS D and DU BOIS E F A formula to estimate the approximate surface area if height and weight be known Arch intern Med 17 (1916) 863

GOERKE R J and CARLSSON E Calculation of right and left cardiac ventricular volumes Method using standard computer equipment and biplane angiocardiograms Invest Radiol 2 (1967) 360

GRAHAM JR T P JARMAKANI J M and CANENT JR R V Left heart volume characteristics with a right ventricular volume overload total anomalous pulmonary venous connection and atrial septal defect Circulation 45 (1972) 144

KAGAN A Dynamic responses of the right ventricle following extensive damage by cauterization Circulation 5 (1952) 816

POPIO K A GORLIN R TEICHHOLZ L E COHN P F BECHTEL S and HERMAN M V Abnormalities of the left ventricular function and geometry in adult with an atrial septal defect Amer J Cardiol 36 (1975) 302

SADE R M and CASTANEDA A R The dispensable right ventricle Surgery 77 (1975) 624

ACTA RADIOLOGICA

PUBLISHED BY THE SOCIETIES OF MEDICAL RADIOLOGY IN DENMARK FINLAND NORWAY AND SWEDEN

Vol 19 Fasc 2 — DIAGNOSIS — 1978

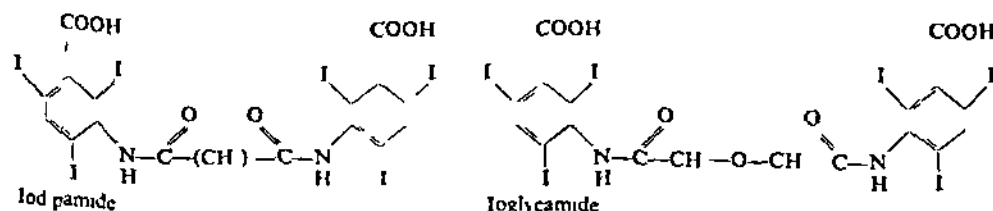
EFFECTS OF STEROID HORMONES ON THE BINDING OF IOGLYCAMIDE (BILIVISTAN) TO HUMAN BLOOD SERUM

STAFFAN WIRELL

The most toxic intravenously administered contrast media in use today (iodipamide sodium acetrizoate) have proved to be albumin binders (LASSER et coll 1962) On the other hand it has been found that also steroid hormones are bound to the albumin during its transport in the blood (ALFSEN 1963 SANDBERG et coll 1966 WESTPHAL 1971)

Clinical and experimental investigations carried out by LINDGREN et coll (1974) have demonstrated that the side effects from contrast media increase when the content of steroid hormone in the blood is high This provided an incentive to investigate whether there might be an interaction between a protein binding contrast medium (ioglycamide) and steroid hormones in particular progesterone with respect to protein binding

Some of the intravenously administered contrast media are transported to the liver in the bound form Ioglycamide (Bilivistan) used in the present experiments has a structure resembling iodipamide (Biligrafin)



From the Department of Diagnostic Radiology University of Umeå S-901 85 Umeå Sweden
Submitted for publication 18 January 1977

Of iodipamide 98 per cent is bound to albumin (LASSER et coll 1962) Other binding proteins may also be relevant but have not been proved to have the same effect (LASSER et coll 1962)

KNOEFEL & HUANG (1956) maintained that the degree of the protein binding determines the toxicity of substances of the type now discussed This theory was confirmed by LASSER et coll (1962) who reviewed information gained on the toxicity of contrast media as expressed in the LD_{50} for several species of animals and compared these values with the degree of the protein binding capacity in these species The correlation was significant for protein binding in relation to LD_{50}

The binding between albumin and unesterified fatty acids follows a complicated association dissociation equilibrium in accordance with the law of mass action Among the factors determining the binding are hydrophobic effects together with an electrostatic factor between the carboxylate anion and some positively charged group or pole on the surface of the albumin (FREDRICKSON & GORDON 1958) A similar relationship probably exists in the case of iodinated contrast media and protein (e g albumin) LASSER et coll (1962) stated that it is the absence of an acetylamino group or other prosthetic structure in the 5 position of the benzene ring which is of significance in this association promoting function of iodipamide

It has long been known that a competition takes place between different molecules or their ions with respect to the binding sites of proteins Information on this subject was reviewed by KLOTZ (1953) As regards organic substances of the type under discussion ODELL (1959 b) demonstrated that organic ions such as salicylates and certain sulfonamides can dissociate bilirubin from albumin by comp ting successfully for the binding sites on the albumin

Iodipamide displays a greater propensity for binding to albumin than do salicylates Thus bilirubin both in vitro and in vivo can be dissociated from its binding sites on serum protein by iodipamide (LASSER et coll 1962)

Similar effects have been considered likely by LASSER et coll (1963) with resp-ct to the interaction between sodium pentobarbital (Nembutal) and the contrast medium sodium acetrizoate (Urokon) They postulated that thes- substances comp te with respect to protein binding although other forms of cooperation had not been considered

Experiments in albumin binding necessitate that the solutions are free from impurity from competing substances with an affinity for albumin and that the pH (buffer) is scrupulously controlled The importance of the pH has been stressed by ODELL (1959 a) who d-monstrated that albumin binds per mol 3 3 mol s of bilirubin at pH 7 9 and 1 9 mol-s at pH 7 4 A similar result was obtained by BISCHOFF & PILHORN (1948) for the albumin binding of testosterone

Direct methods such as m-asurement of ultraviolet light absorption and of changes in viscosity do not tend to give reliable results when the affinity (reflected in the binding constant) is high since saturation is rapidly attained owing to complex formation at th- site on the albumin where the affinity is highest (RAY et coll 1966 REYNOLDS et coll 1968 POLET & STEINHARDT 1968) In th cas- of low affinity

however these methods allow determination of the binding constant Determination of viscosity change can be applied at a high protein concentration if the conforma tion alteration of the protein is of a high degree

Methods

A method capable of determining with sufficient accuracy the binding constant for ioglycamide in the absence and in the presence of steroids is necessary to obtain information whether competition exists between steroid hormones and ioglycamide with respect to their binding to protein ALBERTSSON (1971) has worked out a liquid two phase system in which equilibrium is established between protein and a substance bound to it a ligand on the one side and an unbound ligand on the other side The method is easy to use and requires only small amounts of test solution thus in volving low costs compared with the traditional dialysis methods It works rapidly and permits better control of oxidation problems which could be expected to arise in this connection However it has no advantages in the measuring process in which direct measurement of gamma radiation (^{125}I labelled ioglycamide) or liquid scin tillation counts (^{14}C labelled ioglycamide) are to be made The affinity for the io- glycamide binding could not be predicted but direct measurement of the ultraviolet light absorption was possible at least in the preliminary stage when the magnitude of the binding constant was to be determined

Binding and interaction effects using labelled ioglycamide in a two-phase system Methods for the use of such a two-phase system for binding experiments as the one introduced by ALBERTSSON have been worked out by SHANBHAG et coll (1971) The principles for determining the binding relationships may be briefly described as fol lows

The contents of the polymers in this case dextran and polyethylene glycol their molecular weights and the salts included in the system are selected with reference to the type of molecules that are to be separated The reason for this is to ensure that the protein will be found in the bottom phase

When a substance a ligand which has the affinity of becoming bound to protein is introduced into this two phase system it is distributed together with the protein in such a way that in the bottom phase bound ligand and more than 99 per cent of the protein under discussion will according to the law of mass action adjust to equilibrium with unbound ligand In the top phase only unbound (free) ligand will be present Bound ligand is present in only a negligible amount in relation to the accuracy allowed by the method The distribution coefficient for small molecules in systems such as those in question here does not deviate much from 1 0 The concen tration of the ligand ioglycamide in the top phase could be obtained by direct mea surement of the gamma radiation from ^{125}I labelled ioglycamide and by liquid scintillation counts using ^{14}C labelled ioglycamide

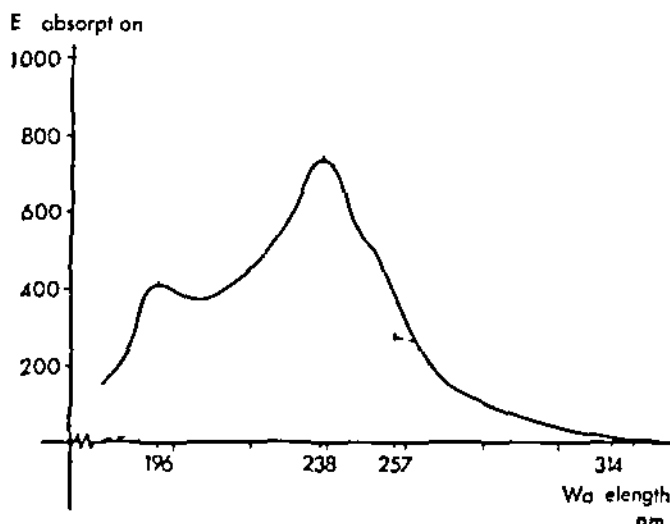


Fig 1 UV light absorption for Bilivistan in water (——) and for Bilivistan in serum (- - -)

With use of a two phase system the COOH group might dissociate into a weak acid As the two phases in this system are of similar milieu in regard to this a pK_a correction is not needed

The association constant and the binding capacity may be determined by Scatchard plotting or a simplified procedure suggested by SHANBHAG et coll

Determinations were carried out in the absence of steroid hormones as well as in the presence of various physiologically occurring concentrations of these hormones The steroid hormones used were testosterone progesterone oestradiol and cortisol

The serum used was tapped on one single occasion according to the methods employed at the Blood Centre of this hospital from a healthy female donor on the 7th to 8th day of the menstrual cycle The endogenously introduced steroids were removed with activated carbon according to the method applied by HEYNS et coll (1967)

The concentration of ioglycamide in the serum was selected on the basis of determinations of the plasma level of Biligrafin and Bilivistan carried out by FLECK et coll (1974)

Binding and interaction effects using ultraviolet light absorption measurements (1) in a two-phase system and (2) by direct measurement of light absorption (1) The ultra violet light absorption of ioglycamide at different concentrations was determined by diluting the substance in water The calibration curve thus obtained was determined by linear regression analysis of the measuring results The Bilivistan content could then be determined using the values for the ultraviolet light absorption obtained in the top phase of the two-phase system mentioned earlier The determination was carried out at the wave length for the absorption maximum 238 nm obtained after manual scanning within the frequency range of 180 to 330 nm (Fig 1)

Table I

The binding constant for ioglycamide in a two phase system using ^{125} labelled Bilivistan added to serum after and before the addition of progesterone The difference denotes that a conformation alteration has taken place in the protein

	Progesterone pg/ml	No of measurements	Binding constant K_A	
			Range	Mean value
Bilivistan after addition of progesterone	0	4	0 124–0 133	0 128
	10	4	0 135–0 148	0 141
	200	4	0 135–0 140	0 137
	2 000	4	0 133–0 141	0 137
Bilivistan before addition of progesterone	0	4	0 121–0 128	0 124
	10	4	0 115–0 122	0 120
	200	4	0 111–0 121	0 117
	2 000	4	0 118 0 129	0 122

(2) These experiments were primarily performed at room temperature and with free access of air A deformation of the curve was observed during the continuous apparatus controlled scanning and it was presumed that the explanation must lie in oxidation of the ioglycamide under the influence of ultraviolet light This effect could be overcome by arranging for freedom from oxygen (nitrogen atmosphere) and a low temperature (+2 C) The method was used for direct examination of samples from two independent solutions of ioglycamide in water and in serum from which endogenous hormone had been removed by HEYNS method In both cases steroid hormones were added to both the water and the serum before the contrast medium was introduced Two continuous scans were then carried out in two independent experimental series

Results

At direct measurement of the ^{1} I labelled contrast medium added to serum before and after the addition of progesterone it was noted that the binding constant changed significantly at the 5 per cent level (= low degree of significance nearly significant) (Table I) The difference in the binding constant in the different cases is an expression of a structural alteration at the binding site in the protein structure under the influence of the ligands progesterone and ioglycamide introduced Thus if progesterone was added to the serum before the ioglycamide the binding constant increased in other words the binding affinity increased If the progesterone was added after the ioglycamide the binding constant was not affected

At continuous scanning over the wave length range 180 to 330 nm identically reproducible curves were obtained in two independent experimental series and with two scans for each experiment (Fig 1) The numerical values for the absorbances and the absorption maxima depicted graphically in Fig 2 will be found in Table 2

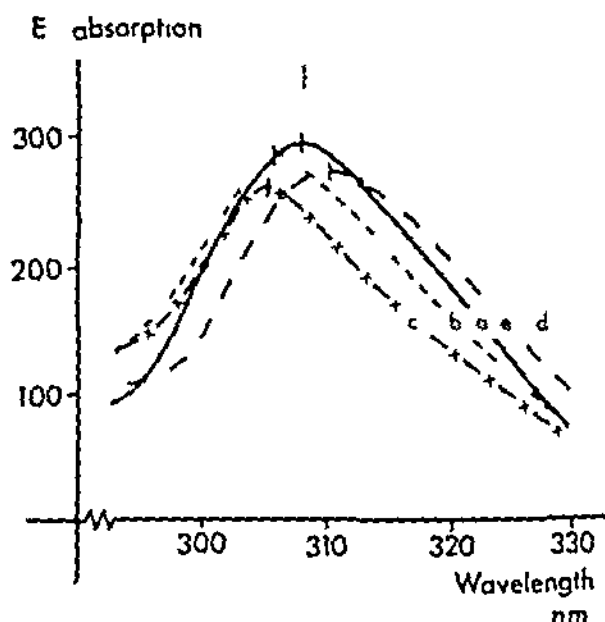


Fig 2 Progesterone 200 pg/ml a (——) Progesterone 2 000 pg/ml b (---) Progesterone 20 000 pg/ml c (—) Testosterone 200 pg/ml d ( ) Oestradiol 40 pg/ml e (O—O) Ultraviolet light absorption of ioglycamide in serum in the presence of steroid hormones in relation to serum alone and the respective steroid hormone The greatest deviation from the conditions when a steroid hormone is not present (314 nm) occurs at higher contents of progesterone (cf Fig 1)

Ioglycamide in serum in the presence of steroid hormones was compared with serum plus steroid hormones as a reference medium In the presence of progesterone a decrease in the light absorption and a shift of the absorption maximum in the direction of a shorter wave length was noted In the presence of progesterone in concentrations of 2 000 pg/ml and 20 000 pg/ml a deformation of the curves in the range around 240 nm was obtained this was probably referable to absorption maxima for free ioglycamide Thus a liberation of ioglycamide probably takes place in the presence of high concentrations of progesterone

Table 2

Light absorption of ioglycamid in undiluted human serum (light path 0 25 cm) in the presence of different concentrations of some steroid hormones

Steroid hormone pg/ml		Absorbance A	Absorption maximum nm
Progesterone	200	285	308
Progesterone	2 000	280	306
Progesterone	20 000	250	305
Oestradiol	40	273	310
Oestradiol	200	307	309
Testosterone	00	345	308
Testosterone	8 000	287	308
Cortisol	50 ng/ml	316	314
No steroid		395	314

Reference medium Serum + the respective steroid hormone
Medium tested Serum + the respective steroid hormone + ioglycamide (See also Fig 2)

Discussion

Previous observations regarding a clinical and experimental increase in the side effects from contrast media when high concentrations of steroid hormones are used (LINDGREN et coll 1974) suggested the possibility that there might be some reciprocity of action on the binding between the protein binding of ioglycamides and of steroid hormones

The present experiments on the interaction between a contrast medium and a steroid hormone revealed that a structural alteration takes place in the protein in human serum when progesterone and ioglycamide are present simultaneously

When the ultraviolet light absorption in solutions of ioglycamide was determined an experiment which should be carried out at a low temperature and in the absence of oxygen an alteration in absorbance in the direction of lower values and a wave length shift in the direction of lower frequencies was observed this being due probably to a change in the surface of the protein at the binding locus

It was clearly demonstrated that an interaction between ioglycamide and steroid hormones in particular progesterone exists relative to the binding to human serum protein

Acknowledgements

Thanks are due to Svenska Schering AB who made ^{131}I and ^{14}C labelled Biliviistan available without cost The author is also greatly indebted to Prof H Carstensen Ass Prof V Shanbhag, and R Sodergård for valuable cooperation in the theoretic and practical problems connected with the planning of the investigation

SUMMARY

The binding relationships between ioglycamide and steroid hormones were determined in a liquid two-phase system with labelled ioglycamide and by direct measurement of ultra violet light absorption It was found that an interaction between ioglycamide and steroid hormones particularly progesterone existed relative to the binding to human serum protein

ZUSAMMENFASSUNG

Die Bindungsverhaltnisse zwischen Ioglycamid und Steroidhormonen in einem [illegible] keits zwei Fasen System mit gezeichnetem Ioglycamid und durch direkte Me[illegible] der Ultraviolett Licht Absorption wurden bestimmt Es wurde gefunden dass [illegible] Wechselwirkung zwischen Ioglycamid und Steroidhormonen besonders Progesteron [illegible] zur Bindung an humanes Serumprotein besteht

RESUME

Les rapports de liaison entre l ioglycamide et les hormones stéro[illegible] un système liquide a deux phases avec de l ioglycamide marqué et [illegible] de l absorption de la lumière ultra violette L auteur a trouvé une [illegible] entre l'ioglyca-

mide et les hormones steroïdes en particulier la progestérone cette interaction concerne la liaison aux protéines du sérum humain

REFERENCES

ALBERTSSON P Å Partition of cell particles and macromolecules Second edition Almqvist & Wiksell Stockholm and Wiley New York 1971

ALFSEN A Studies of the bond between testosterone and serum albumin and the action of heptane on the serum albumin molecule C R Lab Carlsberg 33 (1963) 415

BISCHOFF F and PILHORN H R Distribution of steroid hormones in biologic systems III Solubilities of testosterone progesterone and α-estradiol in aqueous salt and protein solution in serum J biol Chem 174 (1948) 663

FLECK A CAINE S LUCAS J and DUNCAN J G Determination of plasma levels of biliary contrast media Clin Radiol 25 (1974) 511

FREDRICKSON D S and GORDON JR R S Transport of fatty acids Physiol Rev 38 (1958) 585

GOODMAN D S Interaction of human serum albumin with long-chain fatty acid anions J Amer chem Soc 80 (1958) 3892

HEYNS W VAN BAELEN H and DE MOOR P Study of steroid protein binding by means of competitive adsorption Clin chim Acta 18 (1967) 361

KLOTZ I M Protein interactions *In* The proteins Chap 8 Edited by H Neurath and K Bailey Academic Press New York 1953

KNOEFEL P K and HUANG K C Biochemorphology of renal tubular transport Iodinated benzoic acids J Pharmacol exp Ther 117 (1956) 307

LASSER E C ELIZONDO-MARTEL G and GRANKE R C Potentiation of pentobarbital anesthesia by competitive protein binding Anesthesiology 24 (1963) 665

— FARR R S FUJIMAGARI T and TRIPP W N The significance of protein binding of contrast media in roentgen diagnosis Amer J Roentgenol 87 (1962) 338

LINDGREN P SALTZMAN G F and ZEUCHNER E Intravenous cholegraphy and peroral contraceptives A preliminary report Acta radiol Diagnosis 15 (1974) 217

ODELL F B (a) Protein binding of bilirubin and its possible relationship to kernicterus Amer J Dis Child 98 (1959) 624

— (b) Dissociation of bilirubin from albumin and its clinical implications J Pediat 55 (1959) 268

POLET H and STEINHARDT J Binding induced alterations in ultraviolet absorption of native serum albumin Biochemistry 7 (1968) 348

RAY A REYNOLDS J A POLET H and STEINHARDT J Binding of large organic anions and neutral molecules by native bovine serum albumin Biochemistry 5 (1966) 2606

REYNOLDS J HERBERT S and STEINHARDT J The binding of some long chain fatty acid anions and alcohols by bovine serum albumin Biochemistry 7 (1968) 1357

— — POLET H and STEINHARDT J The binding of diverse detergent anions to bovine serum albumin Biochemistry 6 (1967) 937

SANDBERG A A ROSENTHAL H SCHNEIDER S L and SLAUNWHITE W R JR Protein-steroid interactions and their role in the transport and metabolism of steroids *In* Steroid dynamics p 1 Edited by G Pincus T Nakao and J F Tait Academic Press New York 1966

SHANBHAG V P SÖDERGÅRD R CARSTENSEN H and ALBERTSSON P Å A new method for the determination of the binding capacity of testosterone-estradiol binding globulin in human plasma J Steroid Biochem 4 (1973) 537

WESTPHAL U Steroid protein interactions Springer Verlag, Berlin Heidelberg and New York 1971

FROM THE DEPARTMENT OF RADIOLOGY THE DIVISION OF TRANSPLANTATION SURGERY AND THE DEPARTMENT OF PATHOLOGY HUDDINGE SJUKHUS S 141 86 HUDDINGE SWEDEN

ANGIOGRAPHY AND SCINTIGRAPHY OF HUMAN PANCREATIC ALLOGRAFTS

T SVAHN R LEWANDER C HÅRDSTEDT G LUNDGREN P SUNDELIN and C G GROTH

Following pancreatic transplantation in 4 diabetic patients it was found that angiography and scintigraphy provided important information concerning graft morphology and function This report describes the radiologic findings with special reference to the abnormalities associated with pancreatic allograft rejection

Material

The recipients 3 men and 1 woman were aged between 32 and 43 years In 3 the indication for transplantation was hyperlabile diabetes with an extremely variable need of insulin and in one progressive loss of vision due to retinopathy and optic nerve atrophy

The grafts which were obtained from cadaveric donors consisted of the body and tail of the pancreas The splenic artery or the branch ligated coeliac axis was anastomosed end to-end to the recipient left internal iliac artery and the splenic or portal vein was anastomosed end to side to the recipient external iliac vein (Fig 1) The graft was placed extraperitoneally in the pelvis In the first case the pancreatic duct was ligated In the following 3 the transected end of the graft was implanted into a jejunal Roux en Y loop (Fig 1) Postoperative immunosuppression was given with

Submitted for publication 31 March 1977

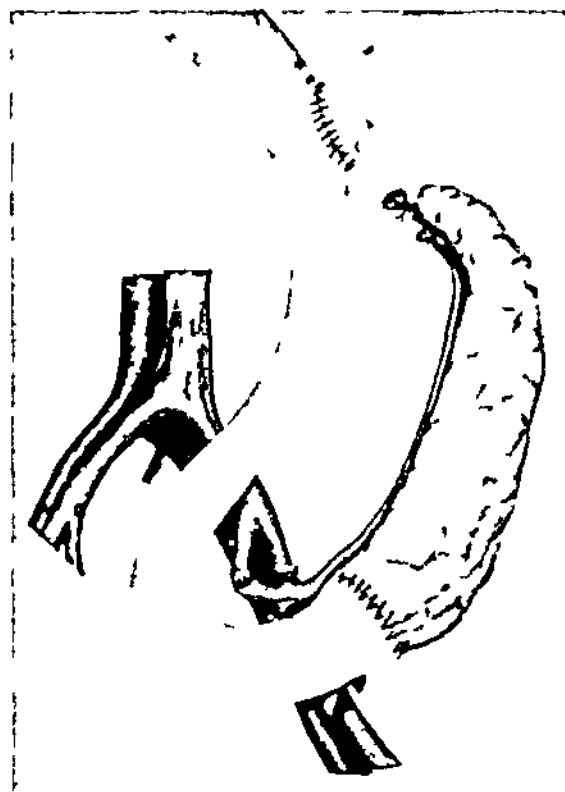


Fig. 1 The technique used for pancreatic transplantation.

azathioprine prednisone and antilymphocyte globulin Further details concerning the patients their management and their clinical course have been published recently (LUNDGREN et coll 1975 GROTH et coll 1976)

Methods

Angiography After percutaneous puncture of the right femoral artery a Mikaelsson or Cobra catheter was inserted until it reached just above the aortic bifurcation The tip was directed into the left common iliac artery and 20 to 25 ml of Isopaque Coronar or Cerebral (Nyegaard & Co) was injected The rate of injection varied between 6 and 12 ml s During each of the first 10 seconds 1 to 2 exposures were made whereupon the rate was reduced to 1 exposure per 2 to 3 s The arterial circulation time was defined as the time elapsing between contrast medium appearing in the graft artery and in the peripheral arterial branches The time before the contrast medium appeared in the parenchyma and in the vein of the graft was also noted

Scintigraphy After the intravenous injection of 250 μCi Se methionine (BLAU & BENDER 1962) pancreatic scintigraphy was performed with a General Electric gamma camera connected on line to a Nukab computer with an image matrix of 64 × 64 cells The recordings were made with a high sensitivity low-energy collimator and a 30

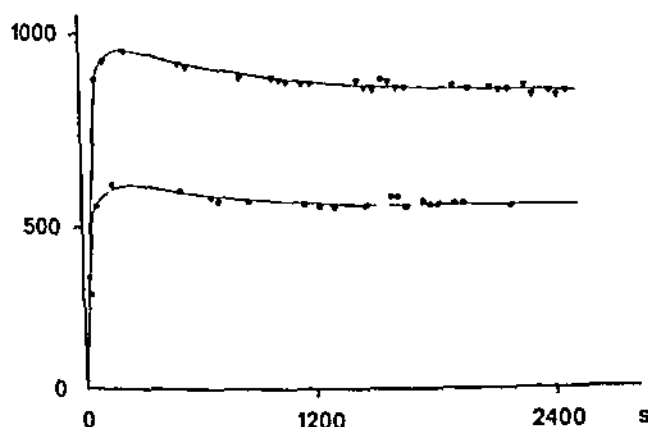


Fig 2 Time activity curves of the well functioning pancreatic graft (▼) in Fig 3 a and of the blood background (●) The maximum uptake at 1 min 40 s corresponds to 1 per cent of the administered activity

per cent window over the 136 keV peak The examination began with serial scintigraphy with a recording every 40 s in order to obtain a time activity curve Regions of interest in the graft and an area representative of the blood background near the graft were outlined with a light pen system and related to one another (Fig 2) One to three hours later one or two static scintigraphies were taken

Case reports

Case 1 Following pancreatic transplantation the patient s blood glucose level was normal or near normal without the administration of insulin for 41 days A persistent pancreatic fistula complicated the course from day 4 onwards Scintigraphy on the 6th day after transplantation demonstrated excellent uptake of isotope by the graft (Fig 3 a) after 1 min 40 s a maximum uptake corresponding to 1 per cent of administered activity was recorded The activity fell slowly during the following hour (Fig 2) The findings indicated an adequate circulation to and good functioning of the graft

Angiography on the 13th postoperative day showed a stationary wave phenomenon in the main artery of the graft The arterial branches appeared normal (Fig 4) About 2 s after the filling of the main artery contrast medium passed into the peripheral vessels Good filling of the parenchyma was obtained after 3 s The outline of the graft was well defined in a p projection it measured approximately 8 cm 14 5 cm The vein was filled after 6 s and appeared normal

The uptake of the isotope was even better on the 35th postoperative day than on the previous scintigraphy

However on the 42nd day after transplantation the fasting blood glucose suddenly increased and no uptake of isotope by the graft was obtained at scintigraphy (Fig 3 b) Insulin had to be reinstituted on the following day On exploration an abscess was found around the graft which was hard and discolored Both the artery and the vein were occluded by recent thrombi The graft was removed

Microscopy of the graft indicated acute and chronic rejection with fibrinoid necrosis of the arterial walls proliferative endarteritis with multiple recent and organized thrombi The exocrine glandular tissue was partly necrotic and extensively fibrosed The islets were small and some of them were slightly fibrotic



Fig 3 Scintigraphy a) Well functioning pancreatic allograft b) The same graft during the final stages of rejection No uptake of isotope during rejection

Case 2 Following control of the patients blood glucose for the first 24 hours after transplantation the levels again rose and insulin had to be administered At angiography only the proximal part of the main artery was filled with contrast medium (Fig 5) suggesting graft thrombosis On exploration the main artery was found to pulsate but the graft was oedematous dark blue and necrotic The vein was hard and filled with thrombi extending from the anastomosis into the graft

Microscopy of the removed graft revealed that the vein thrombus was in an early state of organization The pancreatic tissue was haemorrhagic and infarcted

Case 3 Blood glucose remained normal or near normal without administration of insulin for 35 days after transplantation Angiography on the 5th day after transplantation showed the arterial anastomosis to be slightly irregular and the main artery moderately dilated (Fig 6 a) Circulation time of the contrast medium to the peripheral branches was 3 5 s The proximal part of the splenic vein was filled after 9 5 s and the whole vein after 15 5 s when there was still contrast medium in the artery The filling of the parenchyma clearly outlined the graft It measured 6 cm 10 cm Excellent isotope uptake in the graft was obtained at scintigraphy on the 22nd day after transplantation

On the 36th day after transplantation a sudden increase in blood glucose necessitated the administration of insulin and scintigraphy demonstrated a marked reduction of the isotope uptake in the graft At angiography the main artery was narrowed with its distal segment being extremely irregular Several branches of the artery were stenosed or obliterated (Fig 6 b) Circulation time was 4 5 s The vein was filled after 12 5 s and 28 s after injection it still retained contrast medium The pancreatographic effect was faint The graft had indistinct borders and had become smaller it measured approximately 4 5 cm × 6 cm

Since the deterioration in graft function and morphology was as umed to be due to rejection steroids were given in high dose The blood glucose levels improved for a few days but then again deteriorated At repeat scintigraphy on the 48th day no isotope uptake was



Fig 4 Angiography Well functioning pancreatic graft Stationary wave phenomenon in the *main artery* although without peripheral vascular abnormalities



Fig 5 Angiography Pancreatic graft with venous thrombosis No passage of contrast medium beyond the proximal part of the main artery




Fig 7 Angiography of pancreatic graft undergoing r jection Vascular irregularities in tail of the graft

cludes inflammatory oedema and proliferation and degeneration of the vascular endothelium with obliteration of vessels

At scintigraphy of well functioning grafts rapid uptake of the isotope was obtained and a clear image of the gland During rejection the isotope uptake was reduced or absent if the graft could not be demonstrated subsequent microscopy demonstrated the end stage rejection with thrombosis Scintigraphic delineation was made easy by the superfici location of the graft in the lower part of the abdomen Not only could the collima or of the gamma camera be placed only a few cm above the graft but neither was th e any interferin from isotope in the liver and intestines

It has been sugge ed that endocrine tissues such as the islets of Langerhans should be less readily r ected than other tissues However the present experiences indicate that loss of endocrine function and pathologic changes in exocrine tissue as demonstrated by angiography and scintigraphy take place simultaneously

SUMMARY

Serial graft angiographies and scintigraphies were obtained in 4 human pancreatic allograft recipients Important information was obtained both of graft morphology and func tion Graft rejection was accompanied by characteristic abnormalities including arterial irregularities and prolonged contrast medium passage time On scintigraphy rejection was associated with reduced isotope uptake

ZUSAMMENFASSUNG

Bei 4 menschlichen Pankreas Allotransplantat Empfangern wurden Angiographie und Szintigraphie der Transplantate ausgefuhrt Wesentliche Informationen uber die Morphologie und Funktion der Transplantate wurden erhalten Abstossung des Transplantats war von charakteristischen Abnormalitaten begleitet einschliesslich arterieller Unregelmassigkeiten und einer verlangerten Kontrastmittelpassage Bei der Szintigraphie war die Abstossung von einer verminderten Isotopenaufnahme begleitet

RESUME

Les auteurs ont fait des angiographies en serie de la greffe et des scintigraphies chez 4 receveurs humains d allogreffe pancreatique Ils ont obtenu des donnees importantes concernant la morphologie et le fonctionnement de la graffe Le rejet de la greffe est accompagne d anomalies caractéristiques comprenant des irrégularites arterielles et une prolongation du temps de passage du moyen de contraste A la scintigraphie le rejet est associé avec une reduction de la fixation isotopique

REFERENCES

ALFIDI R J MEANEY TH F BUONOCORE E and NAKAMOTO S Evaluation of renal homotransplantation by selective angiography Radiology 87 (1966) 1099

BLAY M and BENDER M Se ⁷⁵ selenmethionine for vizualisation of the pancreas by isotope scanning Radiology 78 (1962) 794

GROTH C G LUNDGREN G ARNER P COLLSTE H HÅRDSTEDT C LEWANDER R and ÖSTMAN J Rejection of isolated pancreatic allografts in patients with diabetes Surg Gynec Obstet 143 (1976) 933

KAUDE J SLUSHER D H PFAFF W W and HACKETT R L Angiographic diagnosis of rejection and tubular necrosis in human kidney allografts Acta radiol Diagnosis 10 (1970) 476

LUNDGREN G ARNER P GROTH C G HÅRDSTEDT C LEWANDER R RINGDÉN O and ÖSTMAN J Pancreatic transplantation for diabetes mellitus Discussion of indications and surgical technique with reference to 3 cases Scand J Urol Nephrol Suppl 29 (1975) 63

FROM THE DEPARTMENT OF DIAGNOSTIC RADIOLOGY UNIVERSITY HOSPITAL S 2 1 85
LUND SWEDEN

SELECTIVE PHLEBOGRAPHY IN CARCINOMA OF THE PANCREAS

W REICHARDT A LUNDERQUIST and U TYLÉN

Most exocrine pancreatic tumors can be demonstrated by angiography with selective arterial injection eventually supplemented by pharmacoangiography (GOLDSTEIN et coll 1974 HAWKINS et coll 1975 UDEN 1976) In case this examination is not conclusive the diagnosis may often be obtained by supplementary examinations such as percutaneous transhepatic cholangiography and fine needle biopsy guided by the findings at angiography (TYLÉN et coll 1976) However in some cases it is still not possible to achieve a correct diagnosis or to evaluate the size of the tumor Therefore selective pancreatic phlebography was performed in a few cases to determine if this examination could offer further information

Anatomy of the pancreatic veins The following description of the normal venous anatomy of the pancreas is based on 120 selective pancreatic phlebographies (Fig 1) In most of the cases the veins of the pancreatic head were examined

The dorsal part of the head is drained mainly by the posterior superior pancreatico duodenal vein which often is double 3 may occur The vein ends in the portal vein some centimeters from the confluence of the superior mesenteric vein and the splenic vein The veins from the ventral part of the pancreatic head drain to the anterior superior pancreatico-duodenal vein which together with the right colic vein and the right gastroepiploic vein forms the gastrocolic trunk The gastrocolic trunk opens out into the superior mesenteric vein 1 to 2 cm below the confluence with the splenic

Submitted for publication 1 June 1977

20 – 785833

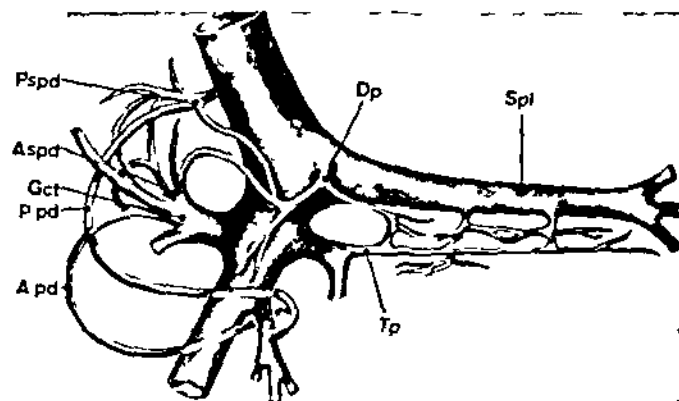


Fig 1 Schematic venous anatomy of th pancrea Pspd posterior superior pancreatico duodenal vein Aspd anterior superior pancreatico-duodenal vein Gct – gastrocolic trunk Pipd posterior inferior pancreatico-duodenal vein Aipd anterior inferior pancreatico duodenal vein Tp transverse pancreatic vein Dp dorsal pancreatic vein

vein The dorsal and the ventral pancreatico duodenal veins anastomose freely and form arcades which together end in the first jejunal vein

The size of the inferior arcades varies from case to case and seems to be of minor importance for the venous drainage of the head in most of the cases

When contrast medium is injected into the post sup pancreatico duodenal vein the intrapancreatic veins of the head are normally filled and contrast medium flows to the ant sup one and the superior mesenteric vein

Vice versa by injection into the anterior vein contrast medium flows via intra pancreatic veins and the posterior vein into the portal vein In some cases the inferior arcades ending in the first jejunal vein are filled (Fig 2)

A dorsal pancreatic vein ending dorsally in the confluence of the splenic vein and the superior mesenteric vein may also be present By injection into this vein a great number of small veins of the body and the head are filled in most cases communicating with the posterior pancreatico duodenal vein The main part of the veins in the body and the tail are small and end in the splenic vein A transverse pancreatic vein ending into the inferior mesenteric vein or into the superior mesenteric vein probably exists in most cases

The technique of the transhepatic catheterization of the portal vein has been described elsewhere *and is therefore only briefly mentioned here* (GOTHLIN *et coll* 1974) After local anesthesia the liver is punctured with a 25 cm long needle sheathed with an polyethylene catheter The puncture is made horizontally in the mid axillary line at the level of the supposed position of the hilum of the liver (patient in supine position) The point of the needle is to be positioned 2 to 3 cm laterally to the vertebral spine After removal of the needle the catheter is slowly pulled back until blood is aspirated without resistance A test injection makes sure that the catheter is placed in a branch of the portal vein A curved guide wire is manipulated into the main stem of the portal vein and the catheter is pushed over it into the portal vein After injection into the portal vein splenic vein and the upper part of the superior mesenteric vein for evaluation of the tumor extension the pancreatic veins may be catheterized with

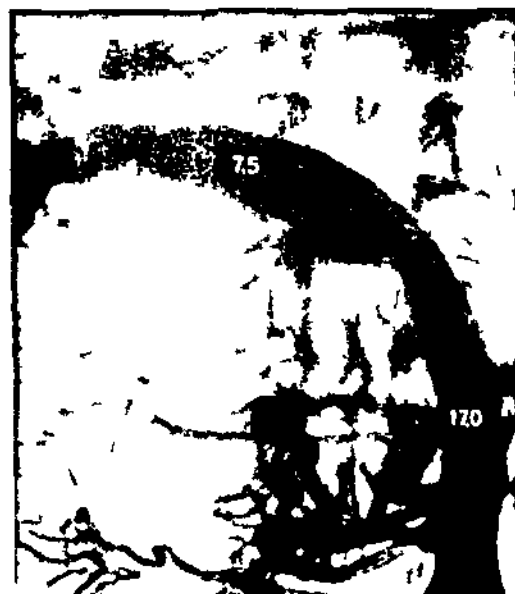


Fig 2 Normal pancreatic phlebography Injection into posterior superior pancreatico-duodenal vein Veins of the head of the pancreas filled

the aid of the curved guide wire This is performed by letting the bent tip of the guide wire enter the vein and then pushing the catheter into position It is important never to let the tip of the catheter pass beyond the tip of the guide wire introduced into a pancreatic vein Injury to the wall of the vein otherwise easily occurs with subsequent extravasation of contrast medium In all the patients the head of the pancreas was examined by injection into the posterior superior pancreatico duodenal vein the anterior superior pancreatico duodenal vein or both In some cases contrast medium was also injected into the dorsal pancreatic vein Depending on the size of the veins 2 to 8 ml of Isopaque Cerebral (280 mg I/ml) was injected by hand and eight films exposed at the rate of 2 films/s

Material and Methods

In 18 patients with carcinoma of the pancreas or the extrahepatic biliary duct percutaneous transhepatic cholangiography was performed because of obstructive jaundice In connection with this examination transhepatic portography and selective catheterization of the pancreatic vein were carried out It was not possible to evaluate the pancreatic veins in 2 patients due to extravasation The material therefore consisted of 16 patients The final diagnosis confirmed at operation and microscopy was carcinoma of the pancreas in 13 patients and cholangiocarcinoma in 3



a



b



c

Fig 3 a) Male aged 58 years with a 4 cm 5 cm tumor of the head of the pancreas compressing superior mesenteric and portal veins causing a pressure gradient of 9 5 cm H O and collateral circulation via gastrocolic trunk and pancreatic veins b c) Injection into posterior superior pancreatico-duodenal vein A p and right posterior oblique projections Dilated branches Occlusion of intrapancreatic branches Slight filling of anterior superior pancreatico-duodenal vein (→)

The phlebographic examinations were evaluated retrosceptively Obstruction of veins with collateral flow and irregular stenosis of veins was considered as evidence of carcinoma The phlebographic findings were compared to the findings at arterial injection operation and examination of the operative specimen in those patients in whom the tumor was resectable

Results

Phlebographic evidence of carcinoma was demonstrated in 9 of the 13 patients with tumor of the pancreas (Figs 3 4) No abnormality was found in 3 patients while in one case slight abnormalities suggestive of carcinoma but not definitely diagnostic were present




Fig 4 Male aged 59 years with a 3 cm 5 cm tumor of the head of the pancreas invading superior mesenteric vein (→) b) Injection into posterior superior pancreatico-duodenal vein Obstruction of intrapancreatic branches

In 8 of the 9 patients with abnormal phlebography large tumors with extrapancreatic growth were disclosed at operation The tumor was considered unresectable in 6 and resection was unsuccessfully tried in the other 2 patients In the ninth patient a tumor with a diameter of 3 cm was found Tumors sized 1 to 2 cm were revealed in the patients with no phlebographic abnormality In one of these only pancreatitis was considered to exist at operation The tumor with a diameter of 2 cm was disclosed at autopsy 4 months later (Fig 5) In the patient with suggested neoplasm a tumor with a diameter of 3 cm was found

Arterial injection was carried out in 11 of the patients with pancreatic carcinoma In 9 of these a tumor diagnosis was made only atheromatosis was demonstrated in the remaining 2 patients (Fig 7) In one of the latter cases the examination was difficult due to stenosis of the coeliac artery which made superselective catheterization impossible

The extension of the tumor was correctly determined with arterial injection in 7 patients while it was overestimated in the remaining 2 due to surrounding pancreatitis (Fig 6) The pancreatic neoplasm was demonstrated both at phlebography and at arterial injection in 6 patients Angiography disclosed only atheromatosis of the pancreatic vessels in 2 of the remaining 3 patients with abnormal phlebography indicating malignancy (Fig 7) in the third patient no arterial injection was performed A tumor diagnosis was also made in 2 of the patients without abnormal phlebographic findings and in the patient with uncertain result of the phlebography



a



b



c

Fig 5 Male 60 years of age with previous resection of the stomach a) Hepatic angiography Slight stenosis of gastroduodenal artery Occlusion of right hepatic artery which is filled through tortuous collaterals in liver hilum (→) Tortuous arteries in the region of resection b c) Pancreatic phlebography Injection into b) posterior superior and c) anterior superior pancreatico-duodenal veins Branches around the head of the pancreas stretched Intrapancreatic branches tortuous and slightly irregular No obstruction At autopsy 4 months later a 2 cm large tumor of the head of the pancreas surrounded by purulent pancreatitis was found

Arterial injection was not performed in the third patient with normal phlebographic findings (Fig 8)

Differential diagnosis Pancreatic phlebography was normal in 2 of the 3 patients with cholangiocarcinoma in the third patient the post sup pancreatico duodenal vein was dilated and wide tortuous veins were present in the hepato duodenal ligament (Fig 9) Similar tortuous veins in the hepato duodenal ligament were also demonstrated in another of the patients with cholangiocarcinoma and were considered as caused by obstruction

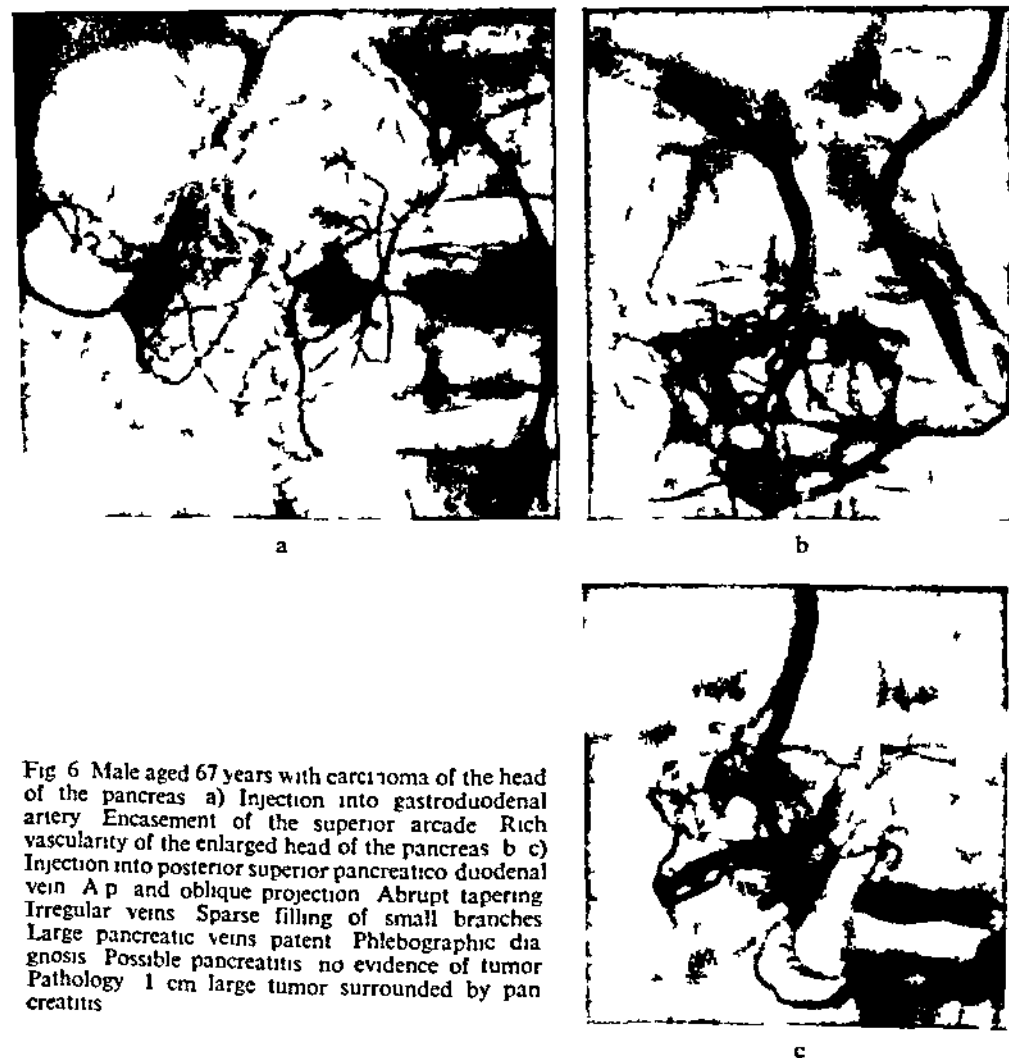


Fig 6 Male aged 67 years with carcinoma of the head of the pancreas a) Injection into gastroduodenal artery Encasement of the superior arcade Rich vascularity of the enlarged head of the pancreas b c) Injection into posterior superior pancreatico duodenal vein A p and oblique projection Abrupt tapering Irregular veins Sparse filling of small branches Large pancreatic veins patent Phlebographic diagnosis Possible pancreatitis no evidence of tumor Pathology 1 cm large tumor surrounded by pancreatitis

The veins of the head of the pancreas were stretched slender and kinked without direct evidence of carcinoma i e obstruction or irregular stenosis in 2 of the patients with pancreatic tumor In one of the latter (Fig 5) only pancreatitis with abscess formation was found at operation The 2 cm large carcinoma was not disclosed until at autopsy several months later In the second patient (Fig 6) a large tumor was palpated at operation After resection the carcinoma was only 1 cm in diameter but was surrounded by a thick rim of pancreatitis

Complications With the exception of extravasation in 3 patients no complications occurred The extravasations caused no discomfort to the patients but made the examination impossible to evaluate in 2 cases

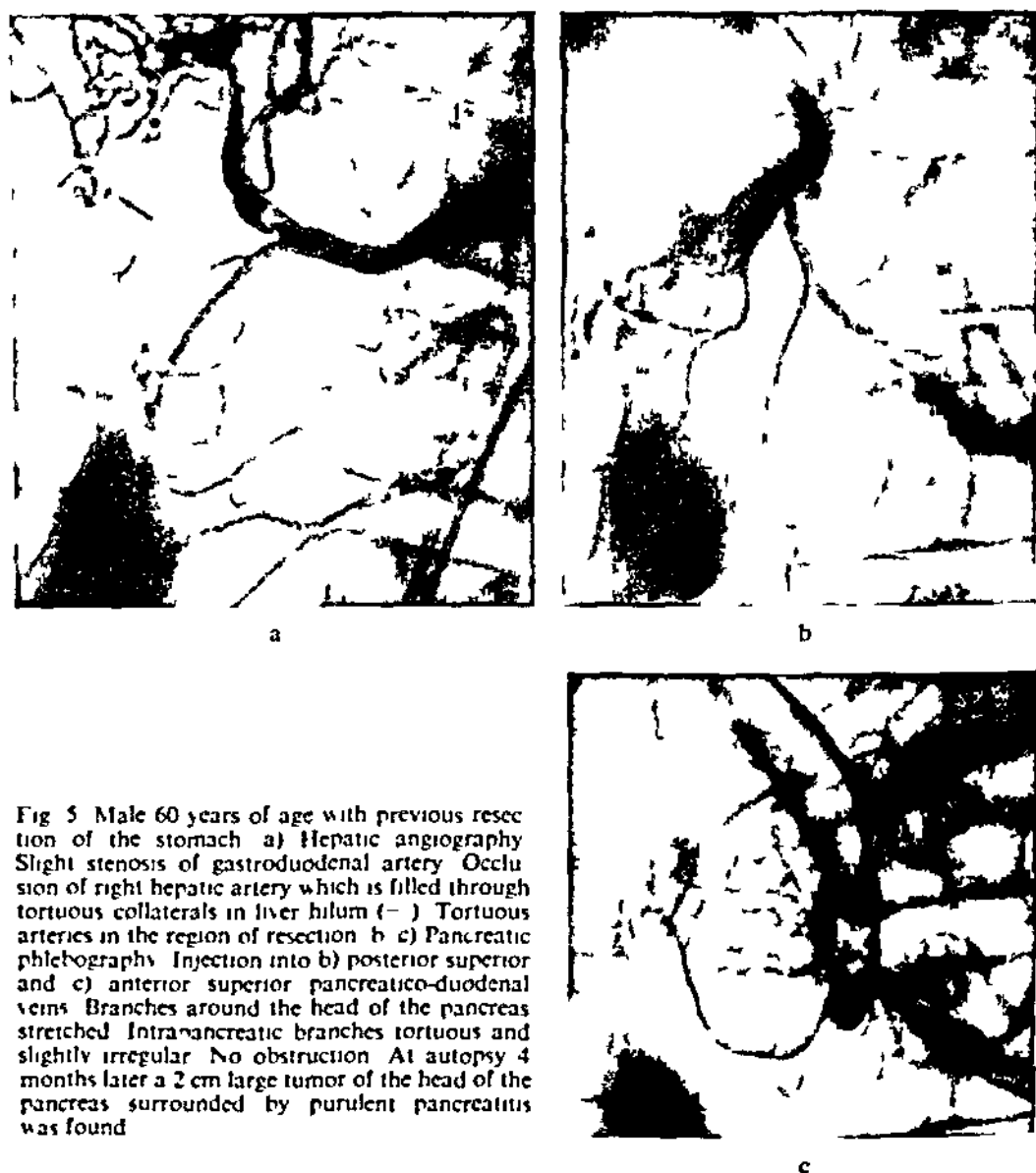


Fig 5 Male 60 years of age with previous resection of the stomach a) Hepatic angiography Slight stenosis of gastroduodenal artery Occlusion of right hepatic artery which is filled through tortuous collaterals in liver hilum (→) Tortuous arteries in the region of resection b c) Pancreatic phlebographs Injection into b) posterior superior and c) anterior superior pancreatico-duodenal veins Branches around the head of the pancreas stretched Intrapancreatic branches tortuous and slightly irregular No obstruction At autopsy 4 months later a 2 cm large tumor of the head of the pancreas surrounded by purulent pancreatitis was found

Arterial injection was not performed in the third patient with normal phlebographic findings (Fig 8)

Differential diagnosis Pancreatic phlebography was normal in 2 of the 3 patients with cholangiocarcinoma in the third patient the post sup pancreatico-duodenal vein was dilated and wide tortuous veins were present in the hepato-duodenal ligament (Fig 9) Similar tortuous veins in the hepato-duodenal ligament were also demonstrated in another of the patients with cholangiocarcinoma and were considered as caused by obstruction



Fig 8



Fig 9

Fig 8 Male aged 52 years with carcinoma of the head of the pancreas sized 1 cm at operation Pancreatic veins normal

Fig 9 Male aged 55 years with cholangiocarcinoma Injection into posterior superior pancreaticoduodenal vein Wide tortuous veins in the hepatoduodenal ligament indicating obstruction No occlusion of pancreatic veins

angiography with arterial injection since the abnormalities caused by the tumor may be easier to differentiate from those caused by surrounding pancreatitis (Figs 5 6) Whether slender and kinked veins without obstruction or irregular stenosis per se indicate pancreatitis remains to be investigated The present experience is restricted to only 2 cases with pancreatitis surrounding carcinoma

Phlebography of the pancreatic veins may moreover be of importance when an obstruction of the extrahepatic bile ducts is demonstrated at transhepatic chol angiography Such an obstruction may be caused by cholangiocarcinoma as well as by pancreatic carcinoma and the differentiation may be difficult The demonstration of normal pancreatic veins then rules out a large carcinoma of the pancreas as the cause of the obstruction This information is important in the planning of the opera tion since the two diseases differ as to the operative technique and the prognosis

In evaluating the films attention must be given to the fact that as in most phlebo graphic examinations the contrast medium is injected against the blood flow This may give a false impression of obstruction The injection into the post sup pan creatico duodenal vein under normal conditions fills also the anterior veins and vice versa The filling of venous branches emptying into the dorsal pancreatic vein at

these injections is much more inconsistent If the presence of an obstruction for example of branches to the post sup pancreatico duodenal vein is suggested but not proven additional injection into the ant sup vein may solve the problem

In most instances the results of angiography with arterial injection and phlebography agreed In 2 patients in whom arterial injection revealed atheromatosis only the tumor was demonstrated at phlebography (Fig 7) On the other hand phlebography missed 3 small tumors Pancreatic phlebography therefore seems less accurate than angiography with arterial injection for demonstration of small tumors Probably it does not permit an early tumor diagnosis and is thus not an appropriate primary procedure in patients with abdominal pain Phlebography should be used as a complementary examination in the preoperative evaluation of the patient

The transhepatic approach to the portal vein involves a 2 per cent risk of intraperitoneal bleeding (HOEVELS et coll) which makes it more suitable for use in conjunction with transhepatic cholangiography In the present series the only complication noted was extravasation of contrast medium This type of complication was without inconvenience to the patients but made the examination impossible to evaluate This complication may be avoided if care is taken not to wedge the catheter in the small vein branches and if a side hole is made close to the tip of the catheter

SUMMARY

Eighteen patients with obstructive jaundice were examined by pancreatic phlebography In 15 cases the final diagnosis was carcinoma of the pancreas in 3 cholangiocarcinoma The normal phlebographic anatomy and the morphologic abnormalities in patients with carcinoma of the pancreas are described The accuracy of pancreatic phlebography in the diagnosis of carcinoma of the pancreas and cholangiocarcinoma is evaluated

ZUSAMMENFASSUNG

Achtzehn Patienten mit obstruktivem Ikterus wurden mit Pankreasphlebographie untersucht Ein Pankreaskarzinom war die definitive Diagnose in 15 Patienten und in 3 ein Cholangiokarzinom Die normale phlebographische Anatomie und die Veränderungen in Patienten mit einem Pankreaskarzinom werden beschrieben Die Zuverlässigkeit der Pankreasphlebographie fur die Diagnose von Pankreaskarzinom und Cholangiokarzinom wird ausgewertet

RÉSUMÉ

Dix huit malades atteints d ictère obstructif ont été examinés par phlébographie pancréatique Dans 15 cas le diagnostic final a été celui de carcinome du pancreas dans 3 cas celui de carcinome des voies biliaires Les auteurs décrivent l anatomie phlébographique normale et les anomalies morphologiques chez les malades atteints de carcinome pancréatique Ils étudient la precision de la phlébographie pancréatique pour le diagnostic de carcinome du pancréas et pour le carcinome des voies biliaires

REFERENCES

BURANASIRI S and BAUM S The significance of the venous phase of celiac and superior mesenteric arteriography in evaluating pancreatic carcinoma Radiology 102 (1972) 11

DESCOMPS P et LALAUBIE G Les veines mesenteriques J Anat (Paris) 48 (1912) 337

DOUGLASS B E BAGGENSTOSS A H and HOLLINSTEAD W H The anatomy of the portal vein and its tributaries Surg Gynec Obstet 91 (1950) 562

FALKONER C W and GRIFFITHS E The anatomy of the blood vessels in the region of the pancreas Brit J Surg 37 (1950) 334

GOLDSTEIN H M NEIMAN H L and BOOKSTEIN J J Angiographic evaluation of pancreatic disease Radiology 112 (1974) 275

GOTHLIN J LUNDERQUIST A and TYLÉN U Selective phlebography of the pancreas Acta radiol Diagnosis 15 (1974) 474

HAWKINS I F KAUDE J V and MAC GREGOR A Priscoline and Epinephrine in selective pancreatic angiography Radiology 116 (1975) 311

HOEVELS J LUNDERQUIST A and TYLÉN U Percutaneous transhepatic portography To be published in Acta radiol Diagnosis

LUNDERQUIST A and TYLÉN U Phlebography of the pancreatic veins Radiologe 15 (1975) 198

PETRÉN T Die Arterien und Venen des Duodenums und Pankreaskopfes beim Menschen Z Anat Entwickl Gesch 90 (1929) 234

TYLEN U and ARNESJO B Resectability and prognosis of carcinoma of the pancreas evaluated by angiography Scand J Gastro nterol 8 (1973) 691

— HOEVELS J and VANG J Percutaneous transhepatic cholangiography (PTC) with external drainage of obstructive biliary lesions Surg Gynec Obstet 144 (1977) 13

— ARNESJÖ B LINDBERG L G LUNDERQUIST A and ÅKERMAN M Percutaneous fine needle aspiration biopsy of pancreatic tumors directed by the findings at angiography Surg Gynec Obstet 142 (1976) 737

UDEN R Secretin and epinephrine combined in celiac angiography Acta radiol Diagnosis 17 (1976) 17

FROM THE DEPARTMENT OF DIAGNOSTIC RADIOLOGY MEDICAL COLLEGE OF VIRGINIA HOSPITALS RICHMOND VIRGINIA 23298 U S A

URINARY BLADDER NECROSIS FOLLOWING SELECTIVE EMBOLIZATION OF THE INTERNAL ILIAC ARTERY

SVEN OLA HIETALA

Several recent reports have emphasized the value of transcatheter intravascular occlusion for the control of pelvic bleeding (GERLOCK 1975 MARGOLIES et coll 1972 RING et coll 1973) The materials used in pelvic artery bleeding have been autologous blood clot gelatin (Gelfoam) and recently balloon catheters (PASTER et coll 1974 WHOLEY et coll 1970) No complications associated with the embolization have been reported It has been suggested that because of an extensive collateral vascular supply to the pelvic organs (GERLOCK, SEAVERS et coll 1964) traumatic pelvic bleeding lends itself to an embolic approach without risk of infarction However a case is now reported which demonstrates that such a risk really exists Embolization with autologous blood clot effectively controlled a bleeding, but also resulted in bladder necrosis

Case report

The patient is a 26-year-old skydiver whose main parachute failed to open The safety chute opened close to the ground and the patient landed on his left foot Emergency roentgen examinations demonstrated multiple rib fractures a fracture of the 8th thoracic vertebra massive crush injury to the pelvis with fracture of the sacrum and left pelvic ring An angiographic evaluation of the abdominal and pelvic

Submitted for publication 7 March 1977




Fig 1 Angiography of the left common iliac artery a) Early and b) late arterial phase before embolization Pelvic hematoma displacing and stretching the pelvic branches of the left internal iliac artery Extravasation of contrast medium (→) from several arterial branches

organs was performed The aortic injection demonstrated a retroperitoneal hematoma on the left side Selective angiography of the celiac artery revealed splenic rupture and pelvic angiography extravasation of contrast medium from multiple branches of the internal iliac artery on the left side Selective angiography of the left internal iliac artery localized the bleedings to the superior gluteal artery vesical arteries internal pudendal and obturator arteries (Fig 1) The excretory phase following the angiography revealed an unobstructed and normal upper urinary tract bilaterally The urinary bladder was evaluated fluoroscopically and also by radiography and there was no extravasation of contrast medium Treatment of the massive hemorrhage without delay was imperative and it was considered that transcatheter embolization of the left internal iliac artery would be the method of choice The opposite femoral artery was used for the insertion of the needle and the catheter The polyethylene catheter (ID/OD = 1 4 mm/2 2 mm) was advanced into the left internal iliac artery as near the bleeding site as possible The embolic material autogenous blood clot was drawn into syringes with contrast medium and was injected under fluoroscopic control The total amount of embolic material injected was about 5 ml The angiography was repeated after the embolization and confirmed that effective hemostasis had been produced (Fig 2) Exploratory laparotomy was performed and a moderate sized hematoma could be palpated The splenic rupture was confirmed and a splenectomy performed During the postoperative period massive pulmonary embolism occurred A percutaneous transvenous catheter extraction of pulmonary emboli was successful

The patient developed febrile episodes Urography 5 weeks after admission revealed again bilateral unobstructed upper urinary tracts without extravasation of



Fig 2 Angiography of the left common iliac artery a) Arterial and b) capillary phase after emboli zation Only the main stem of the left internal iliac artery is filled No further extravasation of contrast medium The branches of the internal iliac artery filled with a mixture of contrast medium and blood clots (→)

contrast medium or development of abscesses Because of the persistent rise in the patient s temperature repeat urography was carried out one week later This time it revealed dilatation of the upper urinary tract bilaterally and gross leakage of contrast medium from the bladder On exploration of the bladder the entire wall on the side of the embolization was found necrotic and a transmural biopsy was done The microscopy of the specimen revealed infarction and necrosis of the bladder wall

Discussion

Patients with multiple pelvic fractures are often difficult to evaluate surgically because of massive hematoma and difficulty in localizing a small source of bleeding Pelvic hemorrhage may be easily located by angiography Subselective catheterization followed by embolization may result in the complete cessation of hemorrhage as in the present case Uncontrollable hemorrhage has also been stopped by ligation of the internal iliac artery uni or bilaterally (SEAVERS) However a basic difference exists between a surgical ligation of an artery and a transcatheter embolization The surgical ligation is a proximal procedure allowing for development of collateral vascular supply to the involved area while embolization is a peripheral procedure The level of arterial occlusion with a transcatheter embolization depends on the actual size of the emboli Very small emboli such as powder of gelatin (Gelfoam) and minute fragments of blood clots as in this case may embolize at the capillary level and the collateral connections appearing at a pre-capillary level cannot establish adequate blood supply The result will therefore be irreversible tissue infarction It may be argued that the bladder necrosis in this case may have been the late result

of the original trauma causing extravasation from the vesical arteries Although there were no other radiologic indications of injury to the bladder at the time of the accident the extensive pelvic trauma probably made the bladder wall more vulnerable to the permanent tissue injury following the embolization

It is apparent that the ideal size of the emboli must be tailored to each given circumstance The aim should be to occlude anywhere between the level of surgical ligation and the point at which capillary obstruction will not be produced It is important that complete occlusion is accomplished proximally in order to produce a substantial reduction of the blood pressure at the bleeding site This occlusion is ideally performed with the aid of balloon catheters (PASTER WHOLEY) or with different mechanical devices (GIANTURCO et coll 1975) With these techniques it may be expected that occlusion of the main internal iliac artery will decrease the venous bleeding after massive pelvic trauma and the reduced flow and perfusion pressure will allow effective hemostasis and clot formation The collateral network within the pelvis will reconstitute enough flow in the distal vessels and ensure viability of the tissues In the case reported there are reasons to believe that the occlusion of the arteries occurred at the precapillary and capillary levels

SUMMARY

A case of massive hemorrhage from pelvic fractures was controlled by embolization of the internal iliac artery with autologous blood clots Later an infarct of the bladder wall developed probably because of embolic material in the capillary system preventing adequate collateral supply It is concluded that collateral flow should be considered before embolization and that the technique of embolization must be adapted to the individual case

ZUSAMMENFASSUNG

Eine massive Blutung, durch eine Beckenfraktur verursacht wurde durch Embolisierung der Arteria iliaca interna mit autologen Blutkoageln kontrolliert Spater entwickelte sich *ein Infarkt* der Blasenwand wahrscheinlich weil embolisches Material im Kapillarsystem eine adaquate kollaterale Versorgung verhinderte Daraus wird geschlossen dass die kollaterale Blutversorgung vor der Embolisierung festgestellt werden sollte und die Technik individualisiert sein muss

RESUME

Une hémorragie massive causee par des fractures du bassin a ete arretee par embolisation dans l artère iliaque interne au moyen de caillots sanguins autologues Plus tard est apparu un infarcissement de la paroi vesicale causé probablement par des embolies dans le système capillaire empechant une vascularisation collaterale convenable L auteur conclut que la circulation collaterale doit être prise en compte avant l embolisation et que la technique d embolisation doit etre adaptee a chaque cas individuel

REFERENCES

GERLOCK A J JR Hemorrhage following pelvic fracture controlled by embolization A case report J Trauma 15 (1975) 740

GIANTURCO C ANDERSON J H and WALLACE S Mechanical devices for arterial occlusion Amer J Roentgenol 124 (1975) 428

MARGOLIES M N RING E J WALTMAN A C KERR W S and BAUM S Arteriography in the management of hemorrhage from pelvic fracture New Engl J Med 287 (1972) 317

PASTER S B VAN HOUTEN F X and ADAMS D F Percutaneous balloon catheterization a technique for the control of arterial hemorrhage caused by pelvic trauma J Amer med Ass 230 (1974) 573

RING E J ATHANASOULIS C WALTMAN A C MARGOLIES M N and BAUM S Arteriographic management of hemorrhage following pelvic fracture Radiology 109 (1973) 65

SEAVERS R LYNCH J BALLARD R JERNIGAN S and JOHNSON J Hypogastric artery ligation for uncontrollable hemorrhage in acute pelvic trauma Surgery 55 (1964) 516

WHOLEY M H STOCKDALE R and TIM K H A percutaneous balloon catheter for the immediate control of hemorrhage Radiology 95 (1970) 516

FROM THE DEPARTMENT OF DIAGNOSTIC RADIOLOGY (DIRECTOR PROF OLLE OLSSON)
UNIVERSITY HOSPITAL S 221 85 LUND SWEDEN

EVALUATION OF SOLITARY RENAL CYSTIC LESIONS

L EKELUND and W KARP

When the diagnosis of a renal cyst is unequivocal surgery is rarely indicated With modern diagnostic approach including urography nephrotomography ultrasound examination cyst puncture with cytologic examination of aspirate and injection of contrast medium and ultimately angiography (eventually enhanced by use of vaso active drugs) the nature of the lesion is usually revealed However differential diagnostic difficulties may arise in cases of cystic or necrotic renal carcinoma The hemorrhagic cyst sometimes offers a diagnostic dilemma as reported by HARRIS et coll (1975) After reviewing a material of 106 patients with cystic lesions of the kidney it was found worthwhile to report the experience at this department in the management of these entities

Material and Methods

The material comprised 106 patients 68 males and 38 females aged from 2 days to 83 years (mean 62 years) A renal mass was demonstrated at urography in all cases High dose nephrotomography was not routinely applied

Ultrasound examination was used in 29 patients in the present material Per cutaneous cyst puncture was performed in all cases and cytologic examination of aspirated fluid in 98 Water soluble contrast medium was injected into the cyst in 67 patients Angiography was performed in 74 patients using the transfemoral technique with selective examination of both kidneys in 2 projections usually preceded by aortography Pharmacoangiography with angiotensin (Hypertensin N Ciba Switzer

Submitted for publication 28 January 1977

21 – 785833







Fig 1 Male aged 74 a) Avascular mass in middle part of right kidney Cyst puncture Clear fluid Cytology No malignant cells b) Two years later the mass has increased in size c) Nephroangiography with 0 5 μg angiotensin reveals tumor vessels in the thick lateral wall of the cyst Microscopy Carcinoma with extensive necroses and hemorrhage

land EKELUND et coll 1972) was employed in most cases The injection of Lipiodol Ultra Fluide (Laboratoires Andre Guerbet France) into the cyst was not routinely applied

Results

Ultrasound examination demonstrated cystic lesions in 28 cases and a solid lesion in one Puncture yielded clear fluid in 79 patients hemorrhagic fluid with old blood in 8 cases and fresh red blood (caused by the puncture) in 11 In 97 cases no malignant cells were found at cytologic examination Two of these patients later turned out to have necrotic renal carcinoma (Fig 1) In one patient with clear cyst aspirate malignant cells were found (Fig 2) In 8 patients no fluid was obtained at puncture Fine needle biopsy was performed in these cases and in 3 patients a cytologic diagnosis of malignancy was obtained (Fig 3) No diagnostic material was obtained in the remaining 5 patients Follow up of these patients has given no evidence of malignancy



Fig 2 Male aged 44 a b) Avascular mass in the lower pole of right kidney supplied by 2 arteries c) Aspiration of clear fluid and injection of contrast medium A regular cyst cavity Cytology of aspirate Malignant cells Surgery Macroscopically benign cyst Microscopy Cystic carcinoma with degenerative changes and fibrous capsule

Nephroangiography was performed in 74 patients 2 had vascular and 2 hypovascular lesions and in 70 the mass was found to be avascular Four of these latter cases had necrotic carcinoma One patient had an avascular mass at angiography clear fluid at cyst puncture smooth walls of the cyst as demonstrated by injection of contrast medium but malignant cells in the aspirated fluid Another two patients with hypovascular tumors at angiography but with smooth walls of the cystic lesion and negative cytology turned out to have renal carcinoma In one of these cases the size of the cyst did not correspond to that of the mass at urography which indicated that



Fig 3 Female aged 57 a) Nephroangiography No tumor vessels but the mass in middle of left kidney has no sharp demarcation Biopsy suggested malignancy b) Magnification radiography of specimen after intra arterial injection of barium A fine network of tumor vess ls

the lesion was not a solitary cyst In the other case the diagnosis of carcinoma was made at rep at angiography 2 years after the cyst puncture

Four patients with hemorrhagic cysts had thick and irregul r walls of the cyst as demonstrated by injection of contrast medium All were avascular at angiography Two were caused by necrotic renal carcinoma and the other 2 by fibrous cysts The mass was calcified in one case (Fig 4)

Discussion

It has been stated that the diagnosis of a solitary renal cyst can b settled at puncture if (1) clear fluid is obtained (2) no malignant cells are found in the aspirate (3) the cyst wall is smooth without more or less irregular masses protruding into the cyst as demonstrated after injection of contrast medium and (4) the siz of the cyst corresponds to the lesion found at urography (DE WEERD 1962 LANG 1966) The present material further substantiates these criteria However clear fluid may be with drawn from cystic tumors as happened in 3 of the cases No malignant cells were found in 2 of these cases but in one of these the size of the cyst filled with contrast medium did not equal the size of the mass at urography The importance of comparing the size of the cyst at puncture with that of the expanding lesion found at urography

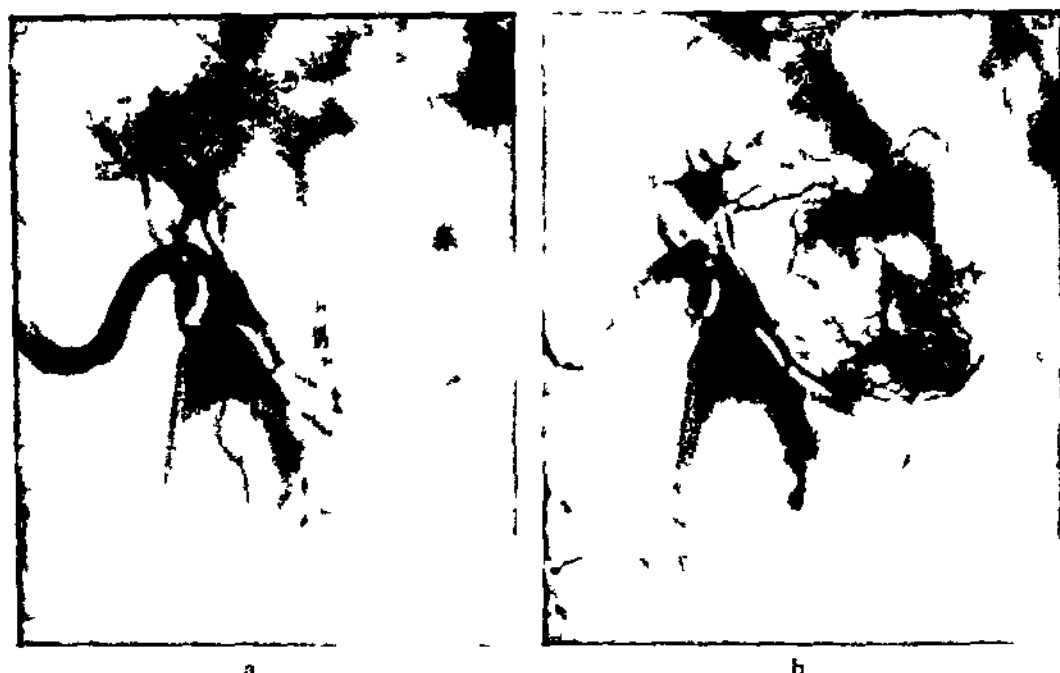


Fig 4 Male aged 72 a) Nephroangiography Avascular mass surrounded by a shell like calcification b) After aspiration of hemorrhagic fluid injection of contrast medium Thick and irregular cyst cavity Cytology No malignant cells Microscopy of operation specimen Fibrous cyst wall with inflammatory cells no evidence of malignancy

must therefore strongly be emphasized In the third case clear fluid was obtained from a smooth walled cyst which was avascular at angiography In this case malignant cells were found in the aspirate This is a rare condition suggesting extensive regressive changes within the tumor a fact that was also confirmed by microscopy which demonstrated an almost healed carcinoma It is possible that surgery in such patients may be limited to resection of the tumor as was done in the present case

Cysts and tumors may be present within the same kidney (1) as independent lesions (2) tumor with cystic degeneration (3) origin of the tumor within a cyst and (4) cyst arising distal to a tumor (Gibson 1954) Coexistence of renal cyst and carcinoma is reported with an incidence rate of about 2 1 to 3 5 per cent (Rehm et coll 1961 Brennan et coll 1962 Emett et coll 1963 Silverman & Kilhenny 1969 Gross & Beach 1971 Lang 1971) Four of the present 106 patients (3 8%) had associated cyst and tumor all of them probably belonging to the second group in Gibson s classification

The degree of reduced vascularity of a renal carcinoma at angiography is mainly dependent upon the extent of tumor necrosis Four of the patients had avascular tumors at angiography In 3 the diagnosis of malignancy was obtained at cytologic examination of fluid or biopsy material Further 2 patients had hypovascular carcinoma and in these cases diagnostic information was enhanced by pharmaco-



a b

Fig 5 Male aged 38 a) Nephroangiography Hypovascular mass b) Nephroangiography with 0 5 g of angiotensin Tumor vessels in the mass

angiography with angiotensin (Figs 1 5) (EKELUND et coll 1972) In all these 6 tumors extensive necrosis and hemorrhage were present at microscopy

Nineteen patients in the series had hemorrhagic cyst fluid at puncture In 11 cases this was explained by bleeding caused by the puncture (fresh red blood) Eight patients had a dark brownish aspirate indicating old hemorrhage A higher incidence of malignancy is reported with such hemorrhagic cysts (20–35 %) and exploration has been recommended (HARRIS et coll 1975) Others have advocated that a presumptive diagnosis is possible by a combination of examinations (JACKMAN & STEVENS 1974) In their report 6 cases of benign hemorrhagic renal cysts are presented 3 of them with irregular cyst cavity but none with malignant cells in the fluid Two of the cases were explored multiple biopsies performed without evidence of malignancy and the kidneys were saved LANG (1966) reported 4 cases of cystic tumors with grossly bloody fluid at puncture all with cytologic evidence of malignancy These cases had been diagnosed as cysts on the basis of previous angiography nephrotomography and clinical presentation Two of the present 8 patients with hemorrhagic cysts had a carcinoma in one malignant cells were present in the aspirate and in the other the cytology was inconclusive Another patient with a thick walled hemorrhagic cyst with a thin calcification in the periphery (Fig 4) but with no malignant cells was explored Malignancy could be ruled out at surgery with multiple open biopsies and the kidney was saved The remaining 5 cases were diagnosed as post traumatic renal cysts and close follow up has given no evidence of malignancy It is thus evident that the

hemorrhagic cyst may be a differential diagnostic problem and therefore all efforts including puncture and (pharmaco)angiography are needed to establish the correct diagnosis Magnification angiography may add information in these cases Yet some cases have to be explored in order to determine the nature of these lesions with certainty

Before ultrasound examination was introduced angiography had to be performed in a majority of renal expanding lesions During the last year ultrasound was always used following urography thus the number of angiographies was reduced If ultra sound examination indicates a cyst puncture is performed If clear fluid is then ob tained no malignant cells found at cytology and examination with contrast medium reveals a cyst with smooth walls and a size corresponding to the mass found at urography no further investigations seem to be necessary If on the other hand the ultrasound examination indicates a solid lesion or is not conclusive angiography is performed in the majority of cases Sometimes in the elderly patient where surgery is not contemplated fine needle biopsy is performed in connection with the ultrasound examination Diagnostic puncture of renal tumors with cytologic examination of biopsy material was introduced already in 1952 by LINDBLOM This approach usually leads to a definite diagnosis Although being a debated procedure as spread of tumor cells may occur there has been no convincing evidence in the literature that this risk is significantly greater than that caused by manipulation of the tumor at surgery However biopsy is only performed on specific indications As a conclusion the diagnostic approach in the evaluation of renal masses may be given as follows

I Urography ————→ renal mass

II Ultrasound

A) cyst ————→ puncture ↗ cytology ↘ radiography with contrast medium in the cyst

B) solid ↗ biopsy ↘ angiography

III Angiography — solid mass; ultrasound not conclusive; hematuria; hemorrhagic cyst

SUMMARY

The diagnostic approach in cases of expanding renal lesions is reviewed on the basis of 106 patients with cystic lesions Differential diagnostic aspects of cysts tumor masses and cystic tumors are given Ultrasound examination is considered to reduce the need of nephroangio graphy otherwise required The value of nephroangiography with angiotensin in equivocal cases is emphasized

ZUSAMMENFASSUNG

Die Diagnostik von expansiven Nierenprozessen wird an Hand von 106 Patienten beschrieben Die Differentialdiagnose zwischen Zysten soliden und zystischen Tumoren wird diskutiert Ultraschalluntersuchung scheint die Anzahl der Nephroangiographien zu reduzieren Der Wert der Nephroangiographie mit Angiotensin in unsicheren Fallen wird hervorgehoben

RESUME

Les auteurs ont revu la marche du diagnostic dans des cas de lesion renale expansive en se basant sur une serie de 106 malades ayant des lesions kystiques Les auteurs donnent les éléments du diagnostic différentiel des kystes des masses tumorales et des tumeurs kystiques L examen par les ultra sons semble diminuer la nécessité de la néphroangiographie qui sans cela aurait été necessaire et les auteurs insistent sur l intéret de la néphro angiographie avec angiotensine dans les cas douteux

REFERENCES

BRENNAN W MILLER W and CRISLER M Coexistence of renal neoplasm and renal cyst Sth med J 55 (1962) 749

DE WEERD J H Percutaneous aspiration of selected expanding renal lesions J Urol 87 (1962) 303

EKELUND L GÖTHLIN J and LUNDERQUIST A Diagnostic improvement with angiotensin in renal angiography Radiology 105 (1972) 33

EMETT J L LEVINE S R and WOOLNER L B Coexistence of renal cyst and tumor in 1 007 cases Brit J Urol 35 (1963) 403

GIBSON T E Interrelationship of renal cyst and tumors J Urol 71 (1954) 241

GROSS M and BEACH P D The simultaneous occurrence of renal carcinoma and cyst Sth med J 64 (1971) 1059

HARRIS R O GOERGEN T G and TALNER L B The bloody renal cyst aspirate A diagnostic dilemma J Urol 114 (1975) 832

JACKMAN R and STEVENS G M Benign hemorrhagic renal cyst Radiology 110 (1974) 7

LANG E K The differential diagnosis of renal cyst and tumors Radiology 87 (1966) 883

— Coexistence of cyst and tumor in the same kidney Radiology 101 (1971) 7

LINDBLOM K Diagnostic kidney puncture in cyst and tumors Amer J Roentgenol 68 (1952) 209

REHM R A TAYLOR W N and TAYLOR J N Renal cyst associated with carcinoma J Urol 86 (1961) 307

SILVERMAN J F and KILHENNY C Tumor in wall of simple renal cyst Radiology 93 (1969) 95

FROM THE DEPARTMENTS OF DIAGNOSTIC RADIOLOGY (DIRECTOR H ARVIDSSON) AND CLINICAL PHYSIOLOGY (DIRECTOR S BEVEGÅRD) SÖDERSJUKHUSET S 100 64 STOCKHOLM SWEDEN

ANGIOTENSIN EFFECT IN THE HUMAN KIDNEY

K JEKELL S SANDQVIST and J CASTENFORS

Since the introduction of pharmacoangiography with epinephrine (ABRAMS et coll 1962) drugs have been widely used in angiography of tumours In nephroangiography angiotensin provokes a constrictive effect on normal renal vessels but usually not on tumour vessels Faint accumulation of contrast medium within a tumour may thus be enhanced and render the tumour more evident (EKELUND et coll 1972) The main principles for assessing the pharmacologic effects on the renal circulation as demonstrated with angiography were presented by ABRAMS & OBREZ (1971) but no data on the duration of these effects were provided The pharmacologic action of angiotensin II on the renal circulation is known mainly from animal experiments (PAGE & BUMPUS 1961 AURELL 1969) In man the duration of the angiotensin effect has been analysed in visceral vessels by intermittent injections of contrast medium under fluoroscopy (KAPLAN & BOOKSTEIN 1972) These experiments indicated that most of the angiotensin effect was dissipated within one to two minutes No systematic assessments of the time sequence of angiotensin activity on the renal vascularity in man have appeared An analysis of this time relation was therefore performed to provide an indication of the optimum time schedule for nephroangiography with angiotensin

Material and Methods

The material consisted of 29 patients 19 males and 10 females age range 45 to 70 years The indications for angiography were suggested malignancy in 22 patients

Submitted for publication 20 April 1977

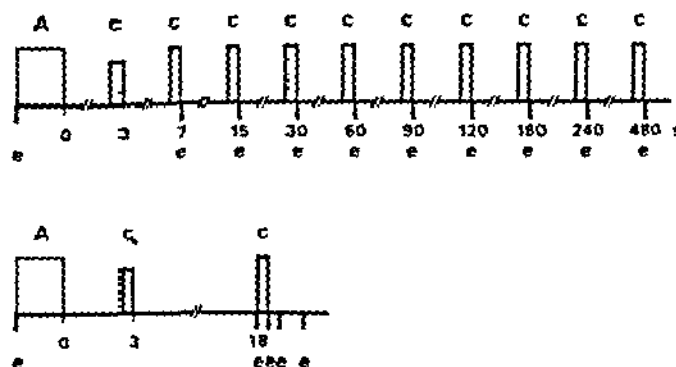


Fig 1 Top Programme for fractionated selective angiography of the renal artery Bottom Programme for the control series A injection of angiotensin dissolved in saline A_0 injection of saline only c_0 contrast injection to fill the catheter c injection of 2 5 ml contrast medium e exposure

and haematuria in 7 Premedication with 10 mg diazepam and 0 25 to 0 50 mg atropine was given Experiments were made after a lumbar aortography with injection of 50 ml diatrizoate (Urografin 60 Schering AG) Angiotensin II (Hypertensin N CIBA) 0 01 μg kg body weight dissolved in saline was injected through a catheter into the renal artery with a specially designed injector (JEKELL et coll 1975) using an injection speed of 5 ml s The injections of contrast medium were performed with a high pressure injector (Cisal II Siemens Elema) through the same catheter A film changer programmed by IBM punch cards (Puck Siemens Elema) was used The injections of angiotensin and contrast medium as well as the exposures were timed by the punch cards thereby ensuring identical conditions in the experiments

The effect of angiotensin injected into the renal artery was recorded with three different procedures

Determination of the variation in kidney length The effect of angiotensin on kidney length was recorded in 21 patients 3 patients acting as controls received only saline instead of angiotensin The length was measured only in non diseased kidneys supplied by a single renal artery In order to demonstrate the outline of the kidney on the films 100 ml diatrizoate (Urovison Schering AG) was given intravenously during 6 min starting 2 min before the angiotensin injection The angiotensin administration and the exposures followed a standardized programme comprising 12 exposures during 8 min including a pre injection film (Fig 3) The length of the kidney was measured on the films as the largest diameter of the organ The pre injection length was used as control and values obtained after the injection of angiotensin were expressed as a percentage of the initial length To determine the shift in the position of the kidney due to respiration the distance between the lowermost border of the kidney and the iliac crest was measured

Fractionated selective angiography of the renal artery The duration of the effect of angiotensin on the renal vessels was recorded in 6 patients Repeat injections of

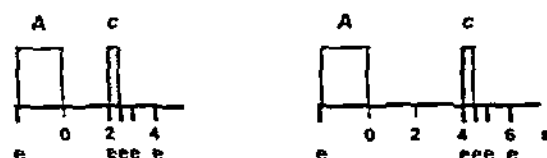


Fig 2 Programme for selective angiography of the renal artery with short time interval between the injection of angiotensin and of contrast medium in one patient A = injection of angiotensin c = injection of 3 ml contrast medium e = exposure

2 5 ml of Urografin 60 % were given with an injection time of 0 5 s each Immediately after each injection a film was exposed The programme was standardized and consisted of one injection of angiotensin and 9 consecutive injections of contrast medium with single exposures during 8 min (Fig 1 top) The films were exposed with the same time intervals as in the programme for the length measurements except at one and three seconds when no injections could be carried out for technical reasons A preceding control series was made angiotensin was substituted by an equal volume of saline and a single injection of 2 5 ml of contrast medium was given (Fig 1 bottom) The total volume of contrast medium in the fractionated selective angiography and in the control series was 25 ml

Selective angiography with short time interval between injection of angiotensin and of contrast medium The time delay between the angiotensin injection and the vasoconstrictor effect on renal vessels was recorded in 2 patients In one 3 ml of contrast medium was injected 2 s after the angiotensin administration After a washout time of 10 min a new injection of angiotensin was made and 4 s later 3 ml of contrast medium was injected (Fig 2) In the other patient the time intervals between injection of angiotensin and of contrast medium were 4 and 8 s respectively The films were compared with those in the preceding control series

Due to the limited number of experiments the effect could not be graded The films were simply interpreted as demonstrating effect or no effect of the angiotensin injection Effect indicates that the contrast medium remained in the renal artery and its main branches no contrast medium reached the cortical vessels and no washout of contrast medium was seen in the renal artery No effect implies that the visible distribution of contrast medium in the renal arteries did not differ from that in corresponding films in the preceding control series

Results

Variations in kidney length Angiotensin injection elicited a significant decrease in kidney length (Fig 3) This decrease was already significant after 7 s ($p < 0\ 01$) and the maximum reduction (about 5 %) was observed 90 s after the angiotensin injection This was followed by a gradual return to the pre injection size which was reached after 4 to 8 min In the 3 control cases when only saline was given no significant change in length was observed Respiratory kidney movements were 0 to 14 mm

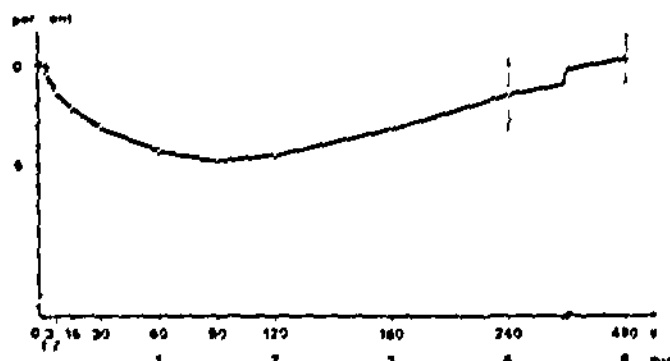


Fig. 3 Variation in kidney length after injection of angiotensin into the renal artery Injection at zero Circles represent average percentile reduction of kidney length at times indicated on abscissa Means SD are presented

cranially and 0 to 22 mm caudally as compared with the position of the kidney in the pre injection films

Fractionated selective angiography of the renal artery In all 6 patients the effect of angiotensin was already apparent 7 s after the injection (Table) After 90 s the effect was still visible in 3 patients and had disappeared in the other 3 After 3 min the angiotensin effect had disappeared in all 6 patients (Fig 4) The diameter of the main renal artery did not vary during the experiments

Selective angiography with short time interval between injection of angiotensin and of contrast medium When contrast medium was given 2 s after the angiotensin injection no angiotensin effect was demonstrable When the interval between the injection of angiotensin and of contrast medium was 4 or 8 s a marked angiotensin effect occurred

Discussion

The effect of angiotensin on the renal circulation was recorded with three different procedures The angiography provides only a semiquantitative evaluation of the vasoconstrictive effect of angiotensin but allows a determination of the appearance and disappearance times for this effect With fractionated selective angiography a

Table

Effect of angiotensin demonstrated with fractionated selective angiography of the renal artery

	Time (s) after injection of angiotensin								
	7	15	30	60	90	120	180	240	480
Effect	6	6	6	5	3	1	0	0	0
No effect	0	0	0	1	3	5	6	6	5*

* No injection at 480 s in one case



Fig 4 Fractionated selective angiography of the renal artery Each film exposed immediately after injection of 2 5 ml Urografin 60 a) Distribution of the medium without preceding angiotensin injection (control series) Contrast medium in cortical vessels b) Exposure at 15 s after angiotensin Contrast medium remains in the renal artery and its main branches Accumulation of medium within the cortex due to preceding injection of medium at 7 s c) Exposure at 60 s after angiotensin Effect less marked than at 15 s Slight washout of contrast medium in the renal artery d) Exposure at 120 s after angiotensin Contrast medium in cortical vessels Angiotensin effect has almost ceased

significant angiotensin effect was demonstrated by the injection of contrast medium 7 s after the angiotensin injection Using a short interval between the injection of angiotensin and of contrast medium the results suggest that the time for appearance of the vasoconstrictive action of angiotensin lies between 2 and 4 s after the injection The angiotensin effect disappeared rather rapidly after 90 s it had subsided in 3 of 6 patients The time sequence of the angiotensin effect evaluated in this way is similar to that observed with renal blood flow determinations in dogs after injection of angiotensin in the renal artery (CALDICOTT et coll 1970)

The time for appearance of the angiotensin effect coincided with the onset of diminished kidney length but the maximum reduction was seen as late as 90 s after the injection of angiotensin by which time the angiotensin effect had disappeared in 3 of the 6 patients Three minutes after the injection of angiotensin when the vasoconstrictive effect of angiotensin had disappeared in all cases there was still a rather marked decrease in kidney length It was not until 8 min after injection that the kidney length had returned to control values

The length of the kidney is influenced not only by the renal vasoconstriction per se but also by changes in glomerular filtration rate and tubular reabsorption Infusion of angiotensin in a dose of 1 3 ng kg body weight per min induced a significant decrease in renal blood flow and glomerular filtration rate suggesting an effect on both the pre and the post glomerular renal vessels (AURELL 1969) This probably contributes to the prolonged and delayed effect of angiotensin on the kidney length compared with the vascular effects demonstrated on angiography Consequently measurement of the kidney length is not suitable for analysing the time sequence of the vascular effect of angiotensin

The respiratory movements of the kidneys introduce a systematic error in determination of the kidney length (JOHANSSON et coll 1969) The systematic error arising from the movement of the kidney compared with its position in the pre injection film may introduce a false reduction in kidney length The measurements obtained in the experiments were corrected for this error before the statistical analysis was performed

Injection of diatrizoate has been demonstrated to give a transient increase in kidney volume (JOHANSSON et coll) Thus an increase in kidney length due to the contrast infusion could be expected However in the control series of 3 patients when only saline was given instead of angiotensin no significant change of the length of the kidney was found during the 8 min of examination Injection of angiotensin invariably led to a significant decrease in kidney length indicating that this effect of angiotensin by far exceeds the antagonistic effect of the contrast medium

Modern contrast media have a low nephrotoxicity Nevertheless renal lesions may be produced by injections into the renal artery (KALDE & NORDENFELT 1973) The risk of lesions is reduced if the injection is fractionated (ALMÉN personal communication)

Postangiographic control of the renal function was not performed in the 6 patients examined with fractionated selective angiography This technique is tolerated in man

only if small volumes of medium are given in each injection and the total volume is restricted

In conclusion the present experiments demonstrate the onset and duration of the angiotensin effect in the human kidney A time delay of 10 to 20 s between the injection of angiotensin and contrast medium is recommended for optimum results

SUMMARY

The renal effect of angiotensin has been recorded in patients by determination of variations in the length of the kidney and by selective injection of contrast medium into the renal artery with special angiographic techniques The experiments demonstrate the rapid onset of the angiotensin effect on the renal vessels The effect on kidney length was considerably prolonged compared with the vascular effect

ZUSAMMENFASSUNG

Der Effekt von Angiotensin auf die menschliche Niere wurde durch Bestimmung der Veranderung in der Lange der Niere und durch selektive Injektion von Kontrastmittel in die Nierenarterie mit spezieller angiographischer Technik registriert Die Untersuchungen deuten auf ein rasches Einsetzen des Angiotensineffektes auf die Nierengefasse Der Effekt auf die Lange der Niere war wesentlich verlangert im Vergleich mit dem vaskularen Effekt

RÉSUMÉ

L effet de l angiotensine sur le rein a ete etudie chez des malades en déterminant les variations de la longueur du rein et par injection sélective de moyen de contraste dans l artere renale avec une technique angiographique speciale Ces experiences montrent l installation rapide de l effet de l angiotensine sur les vaisseaux renaux L effet sur la longueur du rein est considerablement prolonge par rapport a l effet vasculaire

REFERENCES

ABRAMS H L and OBREZ I Epinephrine in the study of renal tumors *In* Angiography vol II p 831 Little Brown and Company Boston 1971

— BOIJSEN E and BORGSTRÖM K E Effect of epinephrine on the renal circulation Radiology 79 (1962) 911

ALMÉN T Personal communication

AURELL M Renal response in man to plasma volume expansion and angiotensin Scand J clin Lab Invest 24 (1969) Suppl No 112

CALDICOTT W J H HOLLENBERG N K and ABRAMS H L Characteristics of the response of renal vascular bed to contrast media Evidence for vasoconstriction by renin angiotensin system Invest Radiol 5 (1970) 539

EKELUND L GOTHLIN J and LUNDERQUIST A Diagnostic improvement with angiotensin in renal angiography Radiology 105 (1972) 33

JEKELL K JOHNSSON S and SANDQVIST S Injection device for pharmacoangiography Acta radiol Diagnosis 16 (1975) 541

JOHANSSON S, SCHAUMAN P, THEANDER G and WEHLIN L: Variation in size of the kidney during nephro-angiography in anesthetised dogs. Clin. Radiol. 20 (1969), 309.
KAPLAN J. H. and BOOKSTEIN J. J.: Abdominal visceral pharmacoangiography with angiotensin. Radiology 103 (1972), 79.
KAUDE J. and NORDENFELT I.: Influence of nephroangiography on [131]I hippuran nephrography. Acta radiol. Diagnosis 14 (1973), 69.
PAGE I. H. and BUMPUS F.: Angiotensin. Physiol. Rev. 41 (1961), 331.

FROM THE DEPARTMENTS OF DIAGNOSTIC RADIOLOGY (DIRECTOR PROF M C. BEACHLEY) RADIATION THERAPY (DIRECTOR PROF T A HAZRA) AND UROLOGY (DIRECTOR PROF W W KOONTZ JR) MEDICAL COLLEGE OF VIRGINIA HOSPITAL RICHMOND VIRGINIA 23298 USA

MALIGNANT THYMOMA WITH RENAL METASTASES

Report of a case

S O HIETALA T A HAZRA and J H TEXTER JR

Cases of histologically confirmed malignant thymoma metastasizing outside the thorax are rare The first case of malignant thymoma metastasizing to the kid neys lymph nodes liver spleen cranial nerves and eyes was reported by MEIGS & DE SCHWEINITZ (1894) Since then 31 additional cases with extrathoracic spread of malignant thymoma have been reported (LEIMANN & SMITH 1926 DANISCH & NEDELMANN 1928 BEDFORD 1930 O GARA et coll 1958 ERICSON & HÖÖK 1960 BERNATZ et coll 1961 HASNER & WESTENGAARD 1963 MOTTET 1964 RACHMANINOFF & FENTRESS 1964 ROSEN et coll 1966 FRIEDMAN 1967 GRAVANIS 1968) There seems to be no previous reports of angiographic findings in metastasizing thymoma The purpo e of this communication is to report a case in order to further emphasize the unpredictable clinical behavior of thymomas and also to describe the radiographic and especially the angiographic findings in a case of thymoma metastasizing to the kidney

Case report

The patient was a 25 year old white male with a history of a mediastinal mass diagnosed at routine chest radiography about 16 months before the present admission The preliminary diagnosis was lymphoma but further evaluation with an exploratory thoracotomy revealed

Submitted for publication 29 March 1977



Fig. 1 Retrograde pyelography on the right side Multiple filling defects in the renal pelvis calyces and proximal ureter

malignant thymoma The thymus could not be completely excised because it was partly adherent to the great vessels The patient received postoperatively radiation therapy to the mediastinum and to the left infraclavicular region

About 9 months after surgery the patient was admitted again to the Urological Service because of painless gross hematuria Pertinent physical findings revealed no cervical or supracalvicular adenopathy The abdomen was soft and the liver and spleen were not palpable Laboratory data showed hemoglobin 14 5 g% WBC 8 900 BUN 15 and creatinin 1 0 g Ultrasonography was performed and demonstrated a predominantly solid mass in the lower and anterior part of the right kidney

Radiographic findings Urography demonstrated a delayed excretion of contrast medium on the right side and a lower pole renal mass A retroperitoneal mass displaced the kidney anteriorly Cystoscopy and right retrograde pyelography (Fig 1) were performed and revealed multiple intrinsic filling defects with the appearance of blood clots in the right uretero pelvic system and a superior displacement of the lower pole calyces Multiple nodular infiltrations consistent with metastases were present on chest films as well as an elevation of the left hemidiaphragm suggesting some degree of phrenic nerve paralysis

Abdominal aortography demonstrated no changes in the abdominal aorta or the major vessels The right kidney was supplied by 2 arteries and the left by a single artery (Fig 2 a) The mass in the lower pole of the right kidney was avascular (Fig 2 b) The intrarenal arterial branches were displaced and stretched The selective angiography did not reveal any additional findings compared to the non-selective angiography

The patient was treated with chemotherapy (Cytoxan Prednisone Oncovin) During this treatment the patient had several episodes of hematuria Repeated intravenous urography



Fig 2 a) Selective nephroangiography of the main renal artery No hypervascularity A dilated capsular artery b) Late parenchymal phase The lower pole of the right kidney is distorted and enlarged by an avascular mass

demonstrated that the condition was essentially unchanged since previous examinations The patient was therefore operated upon

Operative findings The kidney contained a huge hard mass invading the retroperitoneum but did not appear to be attached to the psoas muscle The lower pole was entirely replaced by a hard greyish beige mass Similar lesions of small size were found in the upper pole and throughout the substance of the kidney Several large nodes were identified at the level of the renal hilum The liver appeared to be unremarkable Para aortic nodes were palpated on the left side On palpation of the left kidney some nodularity consistent with tumor extension in the left kidney was discovered

Histology Macroscopic examination demonstrated multiple white and fishy flesh like round nodules throughout the entire kidney extending into the pelvis of the kidney The largest of the masses measured about 6 cm × 5 8 cm × 6 cm the smallest was approximately 1 cm in diameter

On microscopic examination (Fig 3) the tumor nodules demonstrated predominantly epithelial components with scattered round cells The cells in the majority of the tumor were arranged in a spindle pattern There were occasional mitosis and nucleoli The tumor nodules had replaced much of the renal parenchyma sparing the glomeruli The tumor was involving the renal pelvis and had involved the perirenal fat but the major renal vessels were not invaded Microscopically the appearance of the tumor was consistent with a spindle epithelioma type of metastatic thymoma



Fig. 3 Microscopy Predominantly epithelial thymoma with spindle cells and scattered lymphocytes 222

Follow up A year and a half after the thoracotomy and resection of the thymoma the patient developed nausea and vomiting and also headache Physical examination demonstrated bilateral papilledema but was otherwise unremarkable Pertinent laboratory data revealed normal EMI scan isotope brain scan and EEG Lumbar puncture was performed and cytology from the spinal fluid proved to be positive The patient was treated with radiation therapy for cerebral metastasis from previously diagnosed malignant thymoma

Discussion

The reason for the thoracic limitation in cases of malignant thymoma is not apparent since discontinuous metastases in the pleura have been observed fairly frequently and the predominant intrathoracic spread of thymomas has been emphasized previously (CASTLEMAN 1962) Occasional cases have been reported where there have been true distant metastases to the liver (BERNATZ et coll LEIMANN & SMITH HASNER & WESTENGAARD O GARA et coll MORGAN & DUDLEY 1955 LATTES 1962) kidney (ERICSON & HÖÖK MEIGS & DE SCHWEINITZ) and brain and meninges (HASNER & WESTENGAARD RACHMANINOFF & FENTRESS) It has been discussed as to whether the liver metastases are the result of hematogenic dissemination or if they represent tumor spread through implantation Cases have been described (KATZ 1953) where the tumor grew through the diaphragm to the peritoneal cavity However several reported cases as well as the present case fulfill the criteria for metastasizing thymoma

The ages at the time of microscopic diagnosis have ranged in previous publications (LEGG & BRADY 1955 CHATTEN & KATZ 1976 SALYER & EGGLESTON 1976) from 10 years to 76 years with a mean age of about 50 years Thymomas are rather unusual below 25 years of age although 2 cases of thymoma in children have been described The occurrence among sexes is about equal

The presenting symptoms in most cases of thymoma have been myasthenia gravis thoracic pain and various signs of respiratory distress The incidence of myasthenia gravis is 25 per cent or more Many tumors are asymptomatic as in the present case and are discovered on routine chest films Further diagnostic work up has involved more extensive radiologic methods only to a limited extent There are no previous

reports of angiography in cases of malignant thymoma with metastases to the kidney It appears that the radiographic findings are nonspecific demonstrating a mass lesion in the kidney The angiographic findings in this case were those of an avascular tumor infiltrating the kidney parenchyma Similar findings on conventional films and at angiography are observed in cases of malignant lymphoma involving the kidneys The radiologic methods, including angiography indicate the presence of tumor in the kidney but do not allow a specific diagnosis

The thymomas are usually composed of two cell types lymphocytes and so-called epithelial cells One of these cell types may dominate or there may be a mixed type of thymoma consisting of approximately equal numbers of the two cell types diffusely intermixed In some epithelial tumors as in the present case the spindle cells constitute the vast majority of the tumor It has been shown previously that invasive growth of the thymomas cannot be predicted by the microscopic appearance Invasion or implants may thus occur with all types of thymomas It has also been shown that there is no apparent relation of the histologic type either to the associated syndromes or to the prognosis The single most important factor determining the prognosis of a patient with thymoma is the gross behavior and the extent of the tumor A 5 year survival in a previous series (BERNATZ et coll) was 80 per cent for the patients with non invasive tumors and only 23 per cent for those with invasive lesions The benefit of complete surgical excision whenever possible even in the presence of obviously invasive tumors has been emphasized Radiation therapy following biopsy alone has been reported as being successful in occasional cases It has a definite role in the management of patients with tumors which cannot be completely resected

SUMMARY

A patient with metastasizing thymoma is presented This case as well as 31 previously reported cases in the literature demonstrate that thymoma may give distant metastases and that the behavior of the tumors cannot be predicted on histologic grounds The case reported here is the first case where angiography was performed

ZUSAMMENFASSUNG

Ein Fall mit einem metastasierenden Thymom wird beschrieben Dieser Fall sowie 31 in der Literatur berichtete Falle zeigen dass Thymome Fernmetastasen verursachen konnen und das das Verhalten des Tumors nicht auf histologischer Basis vorhergesagt werden kann Der beschriebene Fall ist der erste bei dem Angiographie vorgenommen wurde

RESUME

Presentation d un cas de thymome donnant des metastases Ce cas ainsi que les 31 cas déjà publies dans la littérature montrent que le thymome peut donner des métastases a distance et que le comportement des tumeurs ne peut pas etre prevu sur des arguments histologiques Le cas presenté ici est le premier cas ou une angiographie a éte effectuee



Fig 3 Microscopy Predominantly epithelial thymoma with spindle cells and scattered lymphocytes 222

Follow up A year and a half after the thoracotomy and resection of the thymoma the patient developed nausea and vomiting and also headache Physical examination demonstrated bilateral papilledema but was otherwise unremarkable Pertinent laboratory data revealed normal EMI scan isotope brain scan and EEG Lumbar puncture was performed and cytology from the spinal fluid proved to be positive The patient was treated with radiation therapy for cerebral metastasis from previously diagnosed malignant thymoma

Discussion

The reason for the thoracic limitation in cases of malignant thymoma is not apparent since discontinuous metastases in the pleura have been observed fairly frequently and the predominant intrathoracic spread of thymomas has been emphasized previously (Castleman 1962) Occasional cases have been reported where there have been true distant metastases to the liver (Bernatz et coll Lehmann & Smith Hasner & Westengaard O Gara et coll Morgan & Dudley 1955 Lattes 1962) kidney (Ericson & Hook Meigs & de Schweinitz) and brain and meninges (Hasner & Westengaard Rachmaninoff & Fentress) It has been discussed as to whether the liver metastases are the result of hematogenic dissemination or if they represent tumor spread through implantation Cases have been described (Katz 1953) where the tumor grew through the diaphragm to the peritoneal cavity However several reported cases as well as the present case fulfill the criteria for metastasizing thymoma

The ages at the time of microscopic diagnosis have ranged in previous publications (Legg & Brady 1955 Chatten & Katz 1976 Salyer & Eggleston 1976) from 10 years to 76 years with a mean age of about 50 years Thymomas are rather unusual below 25 years of age although 2 cases of thymoma in children have been described The occurrence among sexes is about equal

The presenting symptoms in most cases of thymoma have been myasthenia gravis thoracic pain and various signs of respiratory distress The incidence of myasthenia gravis is 25 per cent or more Many tumors are asymptomatic as in the present case and are discovered on routine chest films Further diagnostic work up has involved more extensive radiologic methods only to a limited extent There are no previous

reports of angiography in cases of malignant thymoma with metastases to the kidney It appears that the radiographic findings are nonspecific demonstrating a mass lesion in the kidney The angiographic findings in this case were those of an avascular tumor infiltrating the kidney parenchyma Similar findings on conventional films and at angiography are observed in cases of malignant lymphoma involving the kidneys The radiologic methods including angiography indicate the presence of tumor in the kidney but do not allow a specific diagnosis

The thymomas are usually composed of two cell types lymphocytes and so-called epithelial cells One of these cell types may dominate or there may be a mixed type of thymoma consisting of approximately equal numbers of the two cell types diffusely intermixed In some epithelial tumors as in the present case the spindle cells constitute the vast majority of the tumor It has been shown previously that invasive growth of the thymomas cannot be predicted by the microscopic appearance Invasion or implants may thus occur with all types of thymomas It has also been shown that there is no apparent relation of the histologic type either to the associated syndromes or to the prognosis The single most important factor determining the prognosis of a patient with thymoma is the gross behavior and the extent of the tumor A 5 year survival in a previous series (BERNATZ et coll) was 80 per cent for the patients with non invasive tumors and only 23 per cent for those with invasive lesions The benefit of complete surgical excision whenever possible even in the presence of obviously invasive tumors has been emphasized Radiation therapy following biopsy alone has been reported as being successful in occasional cases It has a definite role in the management of patients with tumors which cannot be completely resected

SUMMARY

A patient with metastasizing thymoma is presented This case as well as 31 previously reported cases in the literature demonstrate that thymoma may give distant metastases and that the behavior of the tumors cannot be predicted on histologic grounds The case reported here is the first case where angiography was performed

ZUSAMMENFASSUNG

Ein Fall mit einem metastasierenden Thymom wird beschrieben Dieser Fall sowie 31 in der Literatur berichtete Falle zeigen dass Thymome Fernmetastasen verursachen konnen und dass das Verhalten des Tumors nicht auf histologischer Basis vorhergesagt werden kann Der beschriebene Fall ist der erste bei dem Angiographie vorgenommen wurde

RESUME

Presentation d un cas de thymome donnant des metastases Ce cas ainsi que les 31 cas déjà publiés dans la littérature montrent que le thymome peut donner des metastases a distance et que le comportement des tumeurs ne peut pas etre prevu sur des arguments histologiques Le cas presente ici est le premier cas ou une angiographie a ete effectuee

REFERENCES

Bedford G V A case of carcinoma of the thymus with extensive metastases in a newborn child Canad med Ass J 23 (1930) 197
Bernatz P E Harrison E G and Clagett O T Thymoma A clinicopathologic study J thorac cardiovasc Surg 42 (1961) 424
Castleman B Case records of the Mass Gen Hospital (Case 14 1962) New Engl J Med 266 (1962) 456
Chatten J and Katz S M Thymoma in a 12 year old boy Cancer 37 (1976) 229
Danisch F und Nedelmann E Bösartiges Thymoma bei einem 3 1/2 jahrigen Kind mit eigenartiger Metastasierung ins Zentralnervensystem Arch Path Anat 268 (1928) 492
Ericson J and Höök O Malignant thymoma with metastases A report of three cases two with myasthenia gravis J Neuropath exp Neurol 19 (1960) 538
Friedman N B Tumors of the thymus J thorac cardiovasc Surg 53 (1967) 163
Gravanis M B Metastasizing thymoma Report of a case and review of the literature Amer J clin Path 49 (1968) 690
Hasner E and Westengaard E Thymomas Acta chir scand 126 (1963) 58
Katz H H Malignant thymoma in myasthenia gravis Report of an unusual case with a brief discussion of the role of the thymus in the disease New Engl J Med 248 (1953) 1059
Lattes R Thymoma and other tumors of the thymus An analysis of 107 cases Cancer 15 (1962) 1244
Legg M A and Brady W J Pathology and clinical behavior of thymomas A survery of 51 cases Cancer 18 (1965) 1131
Leimann I I and Smith J Primary carcinoma of the thymus Arch intern Med 38 (1926) 807
Meigs A V and de Schweinitz G E Roundcelled sarcoma of the anterior mediastinum extensive metastasis including the brain both choroid coats oculo motor and optic nerves and external ocular muscles Amer J med Sci 108 (1894) 193
Morgan W L and Dudley H R Malignant thymoma and myasthenia gravis New Engl J Med 253 (1955) 625
Mottet N K Malignant thymoma Amer J clin Path 41 (1964) 61
O Gara R W Horn R C Jr and Enterline H T Tumors of the anterior mediastinum Cancer 11 (1958) 562
Rachmaninoff N and Fentress V Thymoma with metastasis to the brain Amer J clin Path 41 (1964) 618
Rosen V J Christiansen T W and Hughes R K Metastatic thymoma presenting as a solitary pulmonary nodule Cancer 19 (1966) 527
Salyer W R and Eggleston J C Thymoma A clinical and pathological study of 65 cases Cancer 37 (1976) 229
Shields T W Fox R T and Lees W M Thymic tumors classification and treatment Arch Surg 92 (1966) 617
Wilson F N and Pritchard J E Malignant thymoma Canad med Ass J 53 (1945) 444

FROM THE DEPARTMENT OF RADIOLOGY UNIVERSITY OF LUND MALMÖ ALLMANNA SJUKHUS S 214 01 MALMÖ SWEDEN

ILEOCECAL ABNORMALITIES IN APPENDICEAL ABSCESS

OLLE EKBERG

Perforating appendicitis is the most common cause of an intraabdominal abscess (ALTEMEIER et coll 1973 BERK & LASSER 1975) The position of the abscess is dependent on the position of the appendix As this may vary considerably the radiologic appearance also varies but the abnormality is usually easy to recognize

Material and Methods Sixteen patients with surgically proven appendiceal abscess were examined 13 with barium enemas and 2 by small bowel examination including the ileocecal region Both methods were used in one patient The patients were between 29 and 87 years of age and had had abdominal pain for between 2 weeks and 9 months at the time of the radiologic examination except 10 patients who were examined within 4 weeks after the onset of the disease In the present report only the barium examinations are reviewed as survey films of the abdomen were infrequently taken and were of minor interest for the diagnosis in this series

Results

The abnormalities found consisted of (1) deformation and (2) displacement of the cecum (3) appendiceal defects and (4) filling of fistulas and cavities (BERK & LASSER)

Deformation of the cecum was slight to moderate in 7 patients with no other abnormalities observed (Fig 1) in 6 the deformation was marked

Submitted for publication 18 April 1977



Fig 1



Fig 2

Fig 1 Moderate deformation of the medial aspect of the cecum by an appendiceal abscess (→)

Fig 2 Medial displacement of the cecum and ascending colon by an appendiceal abscess partially filled with barium Air fluid level (→)

Displacement of the cecum was observed in 5 patients In 3 of these the abscess was located close to the cecum which was displaced but with no deformation of the small bowel (Figs 2 3) In one patient the small bowel was also displaced In one of the patients with barium filling of a cavity the cecum and the small bowel were displaced forward (Fig 4)

Appendiceal defects were common findings In none of the patients was the appendix normally filled In 12 patients the appendix was not observed In 4 cases the appendix was partially filled The lumen was either irregular or filling defects were present (Fig 5) Fecaliths were not observed

Filling of fistulas and cavities occurred in 2 patients (Fig 4) both of them had marked deformity and displacement of the cecum as well

Discussion

Intraabdominal abscesses often cause diagnostic difficulties Because of their close relation to the bowel periappendiceal abscesses usually cause impressions on the colon and terminal ileum Rarely a fistulation is found (BERK & LASSER) JOFFE (1974) reported on 4 cases with radiologically demonstrated fistulas to appendiceal abscesses A fistula and adjacent cavity was filled with barium in 2 patients in the present series



Fig 3 Medial displacement of the cecum and ascending colon by an appendiceal abscess Deformation of the lateral aspect of the ascending colon

The significance of an indentation of the medial aspect of the cecum in patients with appendicitis has been pointed out by FIEGEL & FIEGEL (1962) among others It was ascribed to the swelling and induration of the tissues surrounding the appendiceal stoma The appearance of such indentations in the present series was similar to that which may be observed after appendectomy (EKBERG 1977) but was accompanied by large abscesses The local deformation of the cecum was common being second in frequency to appendiceal abnormalities

In the radiologic diagnosis of appendicitis with or without periappendiceal abscess much attention has been paid to the filling of the appendix with barium In a series of 10 patients with acute appendicitis reported by CHROM & GUDBJERG (1954) no appendix could be filled in 10 patients with chronic appendicitis either no filling was obtained or filling defects occurred MEYERS & OLIPHANT (1974) reported that in a series of 17 patients with appendiceal abscesses none had a normal barium filling of the appendix SCHEY (1973) reported on 25 children with acute appendicitis and a control group of 46 children without acute abdominal complaints who had been examined with barium enemas He concluded that non filling of the appendix is highly suspicious but not diagnostic of appendicitis The present results agree well with those of these authors inasmuch as if an appendix was filled it was always abnormal



Fig 4



Fig 5

Fig 4 Marked displacement of the cecum. Fistula (→) and abscess cavity (★)

Fig 5 Irregular filling of the appendix in connection with an appendiceal abscess Slight deformation of the distal ileum but not of the cecum

BERK & LASSER point to the fact that if the inflammation extends retroperitoneally into the root of the small bowel mesentery typical displacement of the small bowel occurs This was observed once in the present series

A differentiation between an appendiceal abscess and Crohn s disease is essential This latter disease may present with fistulation and abscesses in the right lower quadrant but the typical appearance of the small bowel should lead to the correct diagnosis (MARSHAK 1976) In rare instance Yersinia enterocolitica may cause an extreme thickening of the wall of the distal ileum simulating a juxta cecal abscess in these cases also a small bowel examination should disclose the true nature of the disease (EKBERG et coll 1977) Sometimes an appendiceal mucocele may displace the small and large bowel thus simulating an appendiceal abscess (FELSON & WIOT 1969)

In the majority of patients with appendiceal abscesses the clinical findings are unequivocal and radiology cannot contribute to the diagnosis However patients sometimes exhibit more atypical symptoms and the physical examination is not conclusive In these rare instances the radiologic examination may disclose the true nature of the disease If deformation or displacement of the cecum and small bowel is observed together with filling defects in the appendix an appendiceal abscess may be suggested If in addition a fistula and cavity are filled the diagnosis is certain

Although deformation was usually seen before displacement two patients had a marked medial displacement without any deformation of the cecum

SUMMARY

The radiologic findings were reviewed in 16 patients with surgically proven appendiceal abscesses The indirect indication of abscess comprised displacement of the cecum or small bowel deformation of the cecum and *filling defects or non filling of the appendix One or* more of these abnormalities were observed in all the patients In addition a fistula and a cavity were filled in 2 patients

ZUSAMMENFASSUNG

Die rontgnologischen Befunde bei 16 Patienten mit chirurgisch nachgewiesenen Appendix Abszessen werden zusammenfassend dargestellt Ein direkter Hinweis auf einen Abszess bilden die Verlagerung des Caecums oder des Dunndarms eine Deformation des Caecums und Fullungsdefekte oder fehlende Fullung der Appendix Eine oder mehrere dieser Abnormalitaten wurden bei allen Patienten gefunden Zusatzlich wurde eine Fistel und eine Kavitat bei 2 Patienten gefullt

RÉSUME

Les signes radiologiques ont eté revus chez 16 malades ayant des abces appendiculaires prouves chirurgicalement Les signes indirects d abces comprennent le deplacement du coecum ou de l intestin grèle la deformation du coecum et les defauts de remplissage de l appendice Une ou plusieurs de ces anomalies ont ete observées chez tous les malades En outre une fistule et une cavite se sont remplies de moyen de contraste chez 2 malades

REFERENCES

ALTEMEIER W A CULBERTSON W R FULLEN W D and SCHOOK C D Intra abdominal abscesses Amer J Surg 125 (1973) 70

BERK R N and LASSER E C Radiology of the ileocecal area p 134 W B Saunders Philadelphia 1975

CHROM S A and GUDBJERG C E Roentgen examination in acute or chronic appendicitis Acta radiol 41 (1954) 132

EKBERG O Cecal changes following appendectomy Gastrointest Radiol 2 (1977) 57

— SJOSTROM B and BRAHME F Radiological findings in Yersinia ileitis Radiology 123 (1977) 15

FELSON B and WIOT J F Some interesting right lower quadrant entities Radiol Clin N Amer 7 (1969) 83

FIEGEL L S and FIEGEL S J Barium examination of the cecum in appendicitis Acta radiol 57 (1962) 469

JOFFE N Some uncommon roentgenologic findings associated with acute perforative appendicitis Radiology 110 (1974) 301

MEYERS M A and OLIPHANT M Ascending retrocecal appendicitis Radiology 110 (1974) 295

SCHEY W L Use of barium in the diagnosis of appendicitis in children Amer J Roentgenol 118 (1973) 95

MARSHAK R H and LINDNER A E Radiology of the small intestine W B Saunders Company Philadelphia 1976

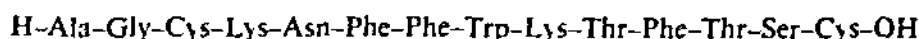
FROM THE DEPARTMENTS OF ENDOCRINOLOGY AND RADIOLOGY KAROLINSKA SJUKHUSET
S 104 01 STOCKHOLM AND THE KABI RESEARCH GROUP S 104 25 STOCKHOLM SWEDEN

EFFECT OF SOMATOSTATIN ON INTESTINAL MOTILITY

SUAD EFENDIĆ and OVE MATTSSON

In 1973 a growth hormone release inhibiting factor somatostatin was isolated from ovine hypophyses and synthetized It could be characterized as a tetradecapeptid

H-Ala-Gly-Cys-Lys-Asn-Phe-Phe-Trp-Lys-Thr-Phe-Thr-Ser-Cys-OH



It was soon demonstrated that somatostatin also lowered growth hormone levels in acromegalic patients As an accidental finding it was demonstrated that somatostatin also inhibited the release of a number of other hormones such as insulin glucagon gastrin secretin cholecystokinin motilin etc (for review see EFENDIĆ et coll 1976 1978)

In connection with investigations of the effects of somatostatin on hormone release it was demonstrated that somatostatin is produced also outside the hypothalamus in specific endocrine like cells in pancreas thyroid glands stomach and gut (HÖKFELT et coll 1975) Thus somatostatin has to be considered as a peptid with a broad distribution in the body and with possible physiologic significance in the regulation of the hormone release In addition somatostatin has been demonstrated to retard gastric emptying (BLOOM et coll 1975)

The effect of stomatostatin on intestinal activity was investigated by using a roentgenologic technique involving video tape recording The results are now reported This procedure means a low-dose modification of the technique used for intestinal motility examinations reported previously (LILJEDAHL et coll 1958 a b)

Submitted for publication 15 March 1977



a



b



c



d

Fig 1 Films exposed a) before b c) during and d) after somatostatin infusion Ten min interval between b and c Evident inhibition of activity (subject 1)




Fig. 2. Example of double contrast examination (subject 2)

Material and Methods

Two volunteers were in detail informed about the nature and purpose of the examination They were fasting overnight and reported to hospital at 9 a m In one subject a thin duodenal tube had been introduced into the duodenum one hour before radiography Ten minutes after an ingestion of a barium contrast meal (Barytgen 150 ml) the basic motility was recorded After that a 20 min intravenous infusion of stomatostatin was started the total dose being 300 μg The motility was recorded at 5 min intervals Frequent fluoroscopic observations were made at shorter intervals After completion of the infusion the recording of the intestinal activity was continued for another 30 min again at 5 min intervals

The series of films in Fig 1 is taken on subject 1 Fig 1 b and c represent the somatostatin infusion period The inhibition of the intestinal activity is evident The other films (a d) are exposed before and after the infusion Fig 2 is an example of double contrast examination of a selected part of the small intestine of subject 2

Results

In both subjects the intestinal motility was normal during the pre infusion period The peristalsis was lively and the jejunum was partly filled within 10 min (Fig 1 a) The infusion of somatostatin caused an almost instantaneous suppression of the intestinal activity (Fig 1 b c) After about 2 min no peristalsis at all was observed The normal morphologic appearance of the intestine was preserved in both subjects No dilatation of the gut was observed In addition contracted and more relaxed parts of the gut were alternating as observed under normal conditions After comple

tion of the infusion the motility gradually started and was after about 20 min completely restored (Fig 1 d)

In the second subject air was introduced through the tube which was placed with its tip in the lower duodenum (Fig 2) The insufflation was made about 2 min before the somatostatin infusion started and was repeated until satisfactory double contrast effect was obtained It was apparent that the suppressive effect of somatostatin on the motility produced possibilities to perform an excellent double contrast examination of the small intestine The air filling could be controlled adequately since the intestinal motility was completely suppressed It seems to be possible to select any part of the small intestine to be examined in this way

Discussion

Somatostatin appears to be a potent inhibitor of the intestinal motility This effect might be attributed to the direct inhibition of the intestinal activity since it has been demonstrated that somatostatin inhibited the release of acetylcholine electrically induced in the myenteric plexus of the longitudinal muscles of the guinea pig ileum (GUILLEMIN 1976) In addition the inhibitory effect of somatostatin on the release of a number of gastrointestinal hormones might be the primary site of action of somatostatin secondarily leading to suppression of motility The present experiments demonstrate that somatostatin might be used as a tool in connection with double contrast examinations The advantage of somatostatin to other agents used at present e g for hypotone duodenography is the good tolerability and on the basis of the present preliminary data it is to be expected that somatostatin is also advantageous from technical viewpoints as it facilitates the examination

SUMMARY

The effect of somatostatin on intestinal motility has been investigated The demonstrated inhibition of the motility has proved to be suitable for performing double contrast examinations of the small intestine particularly as the tolerability to somatostatin is better than to other comparative substances

ZUSAMMENFASSUNG

Die Einwirkung von Somatostatin auf die Darmbewegung ist untersucht worden Die demonstrierte intestinale Bewegungshemmung hat sich bei Doppelkontrastuntersuchungen des Dünndarmes als sehr günstig erwiesen besonders weil Somatostatin im Vergleich zu ähnlichen Substanzen leichter zu vertragen ist

RESUME

Les auteurs ont étudié l effet de la somatostatine sur la motilité intestinale L inhibition de cette motilité s est révélée utile pour faire des examens en double contraste de l intestin grêle en particulier parce que la somatostatine est mieux tolerée que d autres substances comparables

REFERENCES

BLOOM S R RALPHS D N BESSER G M HALL R COY D H KASTIN A J and SCHALLY A V Effect of somatostatin on motilin levels and gastric emptying Gut 18 (1975) 834

EFENDIC S HOKFELT T and LUFT R Somatostatin *In* Advances in metabolic diseases Edited by R Levine and R Luft Academic Press London 1978

— HALL K HÖKFELT T och LUFT R Somatostatin Somatomediner — nya hormoner med anknytning till diabetesforskning och framtida diabetesterapi (In Swedish) Lakartidningen 73 (1976) 1198

GUILLEMIN R Somatostatin inhibits the release of acetylcholine induced electrically in the myenteric plexus Endocrinology 99 (1976) 1653

HÖKFELT T EFENDIC S HELLERSTRÖM C JOHANSSON C LUFT R and ARIMURA A Cellular localization of somatostatin like immunoreactivity in endocrine like cells and neurons of the rat with special reference to the β-cells of the pancreatic islets and hypothalamus Acta endocrin (Kbh) 80 (1975) Suppl No 200

LILJEDAHL S O MATTSSON O och PERNOW B (a) Cineroentgenography of the intestine with special reference to the effect of stimulating agents upon motility Acta radiol 49 (1958) 348

— — — (b) The effect of substance P on intestinal motility in man Scand J clin Lab Invest 10 (1958) 16

FROM THE RESEARCH LABORATORIES AND THE DEPARTMENT OF DIAGNOSTIC RADIOLOGY,
MALMÖ ALLMÄNNA SJUKHUS S 214 01 MALMÖ SWEDEN

EXPERIMENTAL COLONIC TUMOURS IN THE RAT

I Preparation and technique of examination

J E ROSENGREN

Little is known about the development of adenocarcinoma of the large intestine Opinions differ about the role played by benign polyps and their tendency to grow malignant (EKELUND et coll 1974) Some authors are of the opinion that adenomatous polyps have a strong tendency to become *malignant* (DOCKERTY 1958) an assertion denied by others (SPRATT et coll 1958) Clinical experiences have not proved that a benign polyp really is a premalignant lesion Therefore the induction of colon carcinoma by administration of carcinogenic agents to experimental animals might be more informative (DRUCKREY et coll 1967 KING & VARASDI 1959 MARTIN et coll 1973 SPJUT & SPRATT 1965) However at present no radiologic method is available for the demonstration of the subsequent formation and development of experimental polyps and carcinomas in the colon of experimental animals Moreover such a method suitable for the detection and follow up of polyps and early carcinoma in animals can profitably be used in experimental immunologic research on colon malignancies (STEELE et coll 1975)

A safe and easy radiologic method for detection of the primary lesion is also a prerequisite for the evaluation of the effect of cytostatic and immunologic treatment of colon malignancies With the aid of repeated radiologic examinations the growth of colonic carcinomas and their presumptive regression after treatment may be evaluated without killing the animals

Supported by grants from the University of Lund Faculty of Medicine (No 59442900-3) and the Swedish Cancer Society (No 795 B74-01X) Submitted for publication 21 January 1977

In this communication a simple technique for the double contrast radiography of the colon of the rat is described

Material and Methods

The material consisted of 418 animals 390 adult Wistar/Furth rats maintained by continuous single line, brother to sister mating and 28 rats of race BD (4) of both sexes weighing 150 to 350 g For the elaboration of the method 45 of the animals were used The remaining 373 rats were treated with 2 different forms of carcinogenic agents 1-2 dimethylhydrazine administered subcutaneously and N methyl N nitro N nitrosoguanidine given as rectal instillations The administration technique and the doses given are described elsewhere (ROSENGREN & LINDSTRÖM 1978) The rats were examined 1 to 17 times The animals were fed a standard diet of pellets (Astra) and had free access to water Composition of the pellets raw protein 23 5 % raw fat 4 5 % vegetable fiber 3 4 % water max 11 0 ash max 7 5 calcium 1 4 phosphorus 1 0 NaCl 0 4 % plus vitamins and tracers of other substances The rats were divided into 3 different groups each group was given a different anesthesia

On 2 occasions 147 rats were examined with different forms of anesthesia and are consequently included in 2 of these groups

The examination of the bowel was preceded by a cleansing procedure including 2 water enemas with bisacodyl 2 % (Toilax Erco) given via a Foley catheter No 8 inserted into the rectum The catheter was withdrawn after about one minute The animals were allowed to rest for 35 min before and after the second enema to provide a satisfactory evacuation of the bowel

The double contrast examination was performed as follows A Foley catheter No 8 was again inserted into the rectum of the animal and the balloon was inflated Two ml of a colloidal $BaSO_4$ suspension were given via the catheter followed by 20 to 25 ml of air This colloidal barium enema had ion exchange properties and was specially prepared for the purpose of the present investigation (A roentgen diagnostic method and preparation therefore Sw pat pend 740202 6 Pharmacia AB Uppsala Sweden) Detailed properties of the enema will appear in a forthcoming report (ROSENGREN & ROTHMAN 1978) The contrast medium and the air were given under fluoroscopy To ensure a uniform distribution of the contrast medium to all parts of the colon the animals were rotated during the insufflation of the air When the coating of the colonic mucosa was satisfactory the animals were held head down for a few seconds in order to displace excess barium suspension to the proximal colon Films were exposed with vertical beam and the animal in supine prone left and right lateral and oblique positions respectively (Fig 1 a) The animals were then fixed with adhesive tape on a specially designed Plexiglas object holder (Fig 1 b c) and another 4 ml of air were insufflated Four projections with horizontal beam direction were used left and right lateral erect and head down a p projections The Foley catheter was removed immediately after the examination




Fig 1 Magnification radiography with a) vertical beam b) horizontal beam in a p projection c) horizontal beam in lateral decubitus projection

A microfocus rhenium anode tube (Philips Super Rotalix 3/100 kW 0 15/1 5 mm) and standard films for radiography in cassettes with Siemens Saphir intensifying screens were used Film object distance 40 cm Film focus distance 105 cm All the films were thus taken with a magnification of 1 6 1 Exposure data 60 kV 30 mAs 0 10 s

After a final radiologic examination 90 rats were killed and a thorough necropsy and microscopic examination of the colon were performed The technique for the pathologic examination is described elsewhere (LINDSTROM et coll 1978)

Group I One hundred and ninety five animals were lightly anesthetized with diethylether for the 2 cleansing enemas and with an intraperitoneal injection of pentobarbital sodium (Nembutal Veterinary Abbott) in a dose of 2 5 mg/kg body weight for the radiography (Table)

Group II To 60 animals the enemas were given without any form of anesthesia The double contrast examination was performed under the same general anesthesia as in group I

Group III The cleansing enemas were also given without anesthetic to 310 animals The double contrast examination was performed under general anesthesia



a b c

Fig 2



Fig 3

Fig. 2 Radiography of rat bowel with a) vertical beam (lateral projection) b) horizontal beam (a p projection) c) horizontal beam (lateral decubitus projection)

Fig. 3 Double contrast examination of uncleansed rat bowel

with an intraperitoneal injection of 1 ml/100 g body weight of a solution containing 1 mg atropine sulfate (Atropine ACO) and 36 mg chloral hydrate (Mecoral Dumex)

The rats were carefully observed after the examination until they were fully awake or succumbed due to the procedure The death rate was calculated as per cent of the radiographic examinations performed (Table)

Table

Number of double contrast examinations and death rates in the different anesthetic groups

Anesthesia	Number of Rats	Double contrast examinations	Deaths	Death rate (per cent)
I Diethylether – Nembutal	195	420	60	14 3
II Nembutal	60	210	10	4 8
III Chloral hydrate + atropine sulfate	310	940	15	1 6

Results

A total of 1 570 double contrast examinations was performed (Table) They were well tolerated by 480 animals whereas 85 animals succumbed shortly after the examination None of these rats succumbed during the preparation for the examina tion The animals tolerated the repeated ether anesthesia well but 60 rats succumbed after the 2 diethylether anesthesias followed by intraperitoneal injection of Nembutal (Table) The mortality rate was markedly reduced in groups II and III

Autopsy was performed of 20 of the dead rats In 12 animals a contributory cause of death proved to be bronchopneumonia In the remaining animals that succumbed the cause of death was circulatory respiratory failure due to the barbiturate anesthesia

In all 3 groups the films obtained were of high diagnostic quality with only minor amounts of fecal material in the bowel (Fig 2) A uniform contrast coating of the colonic mucosa was obtained No flocculation (cracking) of the contrast occurred In the carcinogenic treated animals several tumours were present in different parts of the bowel and were well outlined The radiologic diagnosis as well as the distribu tion and appearance of the tumours will be presented separately (ROSENGREN & LINDSTROM LINDSTROM et coll)

Differentiation of air bubbles fecal material and tumours caused no difficulties

Discussion

The total procedure 2 cleansing enemas and a double contrast examination required anesthesia During the elaboration of the method it was necessary to anesthetize the animals when the enemas were given as well as at the radiologic examination However it was possible to perform the cleansing enemas without anesthesia when the examiner had gained more experience in handling the animals It was evident that the 3 anesthetias in group I given within the short period of 1½ hours were followed by a fairly high mortality rate (14 3 %) This high mortality of the rats in group I may be explained by complications secondary to the anesthesia



Fig 2



Fig 3

Fig 2 Radiography of rat bowel with a) vertical beam (lateral projection) b) horizontal beam (a p projection) c) horizontal beam (lateral decubitus projection)

Fig. 3 Double contrast examination of uncleansed rat bowel

with an intraperitoneal injection of 1 ml/100 g body weight of a solution containing 1 mg atropine sulfate (Atropine ACO) and 36 mg chloral hydrate (Mecoral Dumex)

The rats were carefully observed after the examination until they were fully awake or succumbed due to the procedure The death rate was calculated as per cent of the radiographic examinations performed (Table)



Fig 5 Multiple tumours in distal colon and rectum after intra rectal administration of nitroguanidine

A second cleansing enema was found to be the best method for cleansing the colon Two Toilax enemas under general anesthesia were found sufficient for cleansing the bowel For technical reasons it was difficult to use ether anesthesia for the radiologic examination A magnification technique was used to obtain a good definition of minor structures in the colonic mucosa The best results were obtained with a microfocus tube and an enlargement factor of 1 6 1

The 10 different positions used were necessary in order to obtain all parts of the colon demonstrated in more than one projection and to enable differentiation between tumours of the mucosa and fecal material

With the standardization of the technique it was also possible to estimate the growth rate of tumours from consecutive examinations The multiple projections used also facilitated evaluation of the degree of malignancy of a polyploid tumour An early and probably the most relevant symptom of a malignant lesion was an irregular indentation at the base of the polyp (ROSENGREN & LINDSTRÖM) (Figs 4 5) Such indentation was demonstrable only in a true tangential projection With the projections used it was almost always possible to demonstrate the base of a polyp

The diagnostic accuracy of the examination of the colon was high Pathologic examinations in 90 tumour bearing rats have shown a high correlation to the result of the radiography (ROSENGREN & LINDSTROM) The examination can be repeated at short intervals Several rats were examined up to 17 times during 12 months This makes the technique useful for demonstrating the effect of carcinogenic agents of the colon for simultaneous immunologic investigations where the survival of the animals is a circumstantial demand (STEELE et coll 1975)

SUMMARY

A method is described for demonstrating the mucosal appearance of the colon of the rat with double contrast and magnification radiography The rats were examined at regular intervals Double contrast examinations were performed 1 570 times in 418 rats The animals



Fig 4 Rat treated with dimethyl hydrazine a) In the distal colon a radiologically 0 5 mm 1 mm benign polyp b) After 3 months an infiltrating carcinoma (2 mm 5 mm) with an irregular indentation at the base and contrast filled spots Another tumour has developed more distally in the colon

None of the animals succumbed during the diethylether anesthesia proper but it is possible that this anesthesia made the animals more sensitive to the following barbiturate administration The animals must be in a good general condition in order to survive the ether anesthesia

The mortality rate was much reduced in groups II and III where the cleansing enemas were given without any form of anesthesia which requires special training of the examiner In the 210 double contrast examinations included in group II the mortality rate was reduced to 4 8 per cent

The best results were obtained in group III where intraperitoneal injection of chloral hydrate was used as anesthesia This anesthesia combined with the administration of atropine sulfate resulted in the very low mortality rate of 1 6 per cent Atropine was used (1) to support the anesthesia by its effects on the circulatory and respiratory systems and (2) to decrease the peristalsis of the bowel The bowel was more distensible in the animals in group III probably due to the atropine administration and this made it easier to diagnose different forms of mucosal lesions (ANDRÉN et coll 1955)

In rats as in human beings a prerequisite for more effective diagnosis of lesions of the colon is that the large bowel has been cleansed (ANDREN et coll) (Fig 3) During the elaboration of the technique cleansing procedures were tried The animals were deprived of food for several days before the examination but not of water This deprivation had no effect on the amount of fecal material in the large bowel on the day of examination A light diet of chicken meat without vegetables proved as ineffective as starvation Incorporation of laxatives in the food was not sufficient to cleanse the large intestine either

IROM THE LABORATORY OF ELECTRONMICROSCOPY (DIRECTOR ASS PROF TIMO NEVA LAINEN) AND THE DEPARTMENT OF ROENTGENOLOGY (DIRECTOR PROF PEKKA VIRTAMA) UNIVERSITY OF TURKU SF 05 0 TURKU FINLAND

SCANNING ELECTRON MICROSCOPY OF THE SPREADING OF BARIUM SULFATE SUSPENSIONS ON THE GASTRIC MUCOSA OF THE RAT

Effect of wetting agents bile salt and lecithine

ILMARI LINDGREN TIMO NEVALAINEN and JOUKO MAKI

Since the Kontrastmalzeit for gastrointestinal radiography was introduced by RIEDER (1904) dozens of commercial barium sulfate preparations have become available Their compositions vary according to their adjuvants which should alter the physicochemical properties of the suspensions most suitable for spreading and adhering on the mucosal surface The large number of proprietary products for sale indicates that the perfect suspension has not yet been made

The demonstration of the mucosal surface in detail is essential for the double contrast examination of the stomach which has been reintroduced especially by Japanese authors (SHIRAKABE 1972) When the contrast medium reaches a high miscibility with the liquid phase of the mucosa the prerequisite for the double con trast method is achieved The thickness of the $BaSO_4$ film formed on the mucosal surface is dependent on the particle size and other physicochemical properties of the suspensions (HEJGAARD et coll 1956 MILLER 1965 EMBRING & MATTSSON 1968 SCHWARTZ et coll 1974) The viscosity the suspension stability and the degree of

Submitted for publication 10 February 1977

were prepared by cleansing the colon with enemas The mortality rate for different forms of anesthesia was recorded An anesthesia with intraperitoneal administration of chloral hydrate and atropine sulfate was the most appropriate

ZUSAMMENFASSUNG

Eine Methode zur Darstellung der Mucosa des Dickdarms von Ratten mit einem Doppel kontrast und Vergrosserungsverfahren wird beschrieben Die Ratten wurden in regel massigen Zeitintervallen untersucht Doppelkontrastuntersuchung wurde 1 570 mal bei 518 Ratten durchgefuhrt Die Tiere wurden durch Reinigung des Dickdarms mit Einlauf vor behandelt Die Mortalitatsrate fur verschiedene Formen der Narkose wurde festgestellt Intraperitoneales Chloral Hydrat und Atropin Sulfat waren fur die Anasthesie best ge eignet

RESUME

Description d une methode pour mettre en evidence l aspect de la muqueuse du colon du rat en double contraste et en agrandissement radiographique Les rats ont ete examines a intervalles reguliers Des examens en double contraste ont ete pratiques 1 570 fois sur 418 rats Les animaux étaient prepares par lavements évacuateurs Le taux de mortalite pour differents types d anesthesies a été enregistré Une anesthesie par administration intrapéri toneale d hydrate de chloral et de sulfate d atropine est la plus appropriee

REFERENCES

ANDEN L FRIEBERG S and WELIN S Roentgen diagnosis of small polyps in the colon and rectum Acta radiol Diagnosis 43 (1955) 201

DOCKERTY M B Pathologic aspects in control of spread of colonic carcinoma Mayo Clin Proc 33 (1958) 157

DRUCKREY H PREUSMANN R MATZKIES F und IVANKOVIC S Selektive Erzeugung von Darm Krebs bei Ratten durch 1 2 Dimethylhydrazine Naturwissenschaften 54 (1967) 285

EKELUND G LINDSTROM C and ROSENGREN J E Appearance and growth of early carcinomas of the colon rectum Acta radiol Diagnosis 15 (1974) 670

KING E S J and VARASDI G Experimentally induced tumours of the intestine Aust N Z J Surg 29 (1959) 38

LINDSTROM C ROSENGREN J E and EKBERG O Experimental colonic tumours in the rat III Induction time distribution and appearance of induced tumours To be published in Acta radiol Diagnosis 19 (1978)

MARTIN M S MARTIN F MICHIELS R BASTIEN H JUSTRABO E BORDES M and VIRY B An experimental model for cancer of the colon and rectum Digestion 8 (1973) 22

ROSENGREN J E and LINDSTRÖM C Experimental colonic tumours in the rat II Double contrast examination and microscopy To be published in Acta radiol Diagnosis 19 (1978)

— and ROTHMAN U A new barium contrast To be published

SPJUT H J and SPRATT J S Jr Endemic and morphologic similarities between spontaneous colonic neoplasms in man and 3 2-dimethyl-4-aminobiphenyl induced colonic neoplasms in rats Ann Surg 161 (1965) 309

SPRATT J S ACKERMAN L V and MOYER C A. Relationship of polyps of the colon to colonic cancer Ann Surg 148 (1958) 682

STEELE G Jr SJÖGREN H O ROSENGREN J E LINDSTROM C LARSSON A and LEANDOER L Sequential studies of serum blocking activity in rats bearing chemically induced primary bowel tumours Int J Cancer 54 (1975) 959

England) and Mixobar (Astra, Sweden) According to the manufacturers their compositions were as follows

Barosulf

Barium sulfate	55 7 %
Flavouring and preserving agents combined with mucilaginous vehicle	5 4 %
Purified water	38 9 %

Micropaque

Barium sulfate	92 %
Lactose	4 9 %
Flavouring combined with mucilaginous vehicle	3 0
Soluble sulfates and chlorines	0 02 %
Moisture (loss at 100 C)	0 08 %

Mixobar

Barium sulfate	100 g
Flavouring and preserving agents with purified distilled water to make	100 ml

The contrast media were mixed with physiologic saline in a concentration of 80 % weight volume The suspensions were heated to ~37° C before application. Two synthetic wetting agents, Fairy (detergent fluid) and Triton X 100 (Rohm & Haas Philadelphia Pa.) were added in concentrations of 0 2 and 1 0 % volume volume into barium sulfate suspensions Sodium taurocholate with or without an equivalent amount of lecithine (Merck, Germany) was added in concentrations of 0.2 and 1 0 weight volume into different contrast suspensions

Results

When the surface of the gastric mucosa is examined at low magnification (100 to 300 times) in the scanning electron microscope the surface epithelium appears as a ridged formation and the openings of the foveolae gastricae are seen (Fig. 1)

At a magnification of about 3 [illegible] (Fig. 5) the polygonal luminal surfaces of the individual [illegible] Their surfaces are covered with numerous knob-like microvilli [illegible] been filled with contrast medium, the particles were seen [illegible] artially intermingled with precipitated

foaming have been recorded in numerical values and the particle size and the degree of aggregation of particles (flocculation) by microscopy The capacity for adhesion and the film thickness have been tested by dipping glass slides or strips of intestinal mucosa into different barium suspensions After a certain period of time the glass slides or the mucosal strips were photographed or radiography performed and com parisons were made

Theoretically the easiest way to increase the miscibility of the contrast medium with the liquid phase of the gastric mucosa should be the diminution of the surface tension by using wetting agents excellent results were reported by KRAMER (1956) EMBRING & MATTSSON tried chemically produced wetting agents but they abandoned the method because of the foam appearing in the stomach The water soluble con trast medium Gastrografin contains the synthetic wetting agent Tween 80 which is blamed for the cytotoxicity of the preparation (LUTZGER & FACTOR 1976)

The effect on the barium contrast media of physiologic wetting agents bile salts has not yet been examined If they are present as for example in hypotonic duodeno graphy a good double contrast effect is generally obtained

Scanning electron microscopy has proved to be a valuable tool in the investigation of gastrointestinal tract topology in a three dimensional view (PFEIFFER 1970 SIEW 1972) The present experiments were performed in order to determine the electron microscopic appearance of rat gastric mucosa irrigated with either pure $BaSO_4$ or some commonly used barium preparations Further an attempt is made to evaluate the effect of two synthetic wetting agents and bile salt solutions

Material and Methods

Adult Wistar rats of both sexes served as the test material The rats were kept fasting for two days before 10 ml of the contrast medium was introduced into the stomach by a gastric cannula The infusion cannula was removed and the animals were killed after five minutes then specimens measuring 5 mm × 5 mm were taken from the antral part of the stomach The specimens were first gently rinsed in physiologic saline to remove the extra contrast medium which was not adhering to the mucosal surface and were then fixed in a 3 0 per cent glutaraldehyde 0 1 M cacodylate buffer solution for 4 to 5 days Smaller pieces (1 mm × 1 mm) were cut and washed in sucrose solution at pH 7 3 for 15 minutes Secondly the specimens were fixed in 1 per cent osmium tetroxide solution in 0 1 M cacodylate buffer for two hours Samples were dehydrated in rising alcohol series to 100 per cent ethanol Dehydrated specimens were dried in air and coated with an approximately 20 to 30 nm thick layer of gold in a vacuum evaporator The samples were examined in a JSM U3 scanning electron microscope operated at 15 kVp

Pure $BaSO_4$ (Pharmacopoea Nordica) and three commercial brands of barium preparations were used Barisulf (Leiras Finland) Micropaque (Nicholas Ltd



Fig 3 Surface of gastric antrum in the rat covered partially with contrast medium in the form of both flocculations (centre) and solitary contrast medium particles Barisulf suspension Openings of gastric pits and concave surfaces of epithelial cells visible SEM 1 050



Fig 4 Surface of gastric antrum in the rat covered mainly with considerable contrast medium flocculation In the right upper corner solitary particles of contrast medium. Two strands of precipitated mucus Pure BaSO SEM × 1 050

Comment

The surface ultrastructural characteristics of the human ferret and cat stomach as demonstrated by scanning electron microscopy were previously described in detail (PFEIFFER FRENNIG & ÖBRINK 1971) The rat stomach seems to be quite similar However the microvilli are somewhat lower in the rat

The opinion that pure $BaSO_4$ displays the highest degree of flocculation is shared by most authors According to MILLER this is due to mucin in the gastrointestinal



Fig 5 Rat antrum Microvilli on the surface of epithelial cells and strands of precipitated mucus SEM 3 375




Fig 6 Detail of Fig 2 Cell surfaces covered with separate contrast medium particles SEM ×3 375

tract Hence additives in commercial preparations are used The exact composition of these preparations is kept secret for commercial reasons The following answer may be obtained from the manufacturer after further inquiry The mucilage is best described as a gel obtainable from any of a number of mucilaginous seeds such as psyllium plantage or Ispaghul deprived of its gelling properties It is of no importance which is used and the reason for its inclusion is to reduce osmotic irritation of mucous membranes and make the suspension more readily miscible with body fluids (MILLER) As may be concluded from the information given by the manufacturers these addi

tives are vegetal drugs or animal products as honey starch pectin agar acacia mucin buttermilk gelatin egg yolk etc EMBRING & MATTSSON warned against the use of such products because of batch variations instability and the danger of infection

The bile salts were used in concentrations of 0 2 and 1 per cent From the available physiologic data the lower range of bile salt concentration in the distal duodenum is estimated to be about 0 2 per cent (DASHER 1952) The commonly used concentration of technical wetting agents is about 1 per cent Lecithine was added because it increases the emulsifying power of bile salts to a great extent This effect may be demonstrated in a model system of fatty acids bile salts and water When the amphipathic phosphatide lecithine is added micelle formation is markedly stimulated (HOFMANN 1964) Since the quantification of the emulsifying phenomena is achieved by microscopy the effect of lecithine addition could not be clearly demonstrated in the present experiments

The idea of using natural emulsifiers as additives for increasing the miscibility of the contrast medium seems to be a new one The present ultramicroscopic observations speak perhaps in favour of their use A combination with ionic stabilisators (EMBRING & MATTSSON) would possibly produce an ideal contrast medium Such trials are presently in progress The only obstacle hitherto observed the unpleasant smell and taste of the bile acid preparations will without doubt be overcome

SUMMARY

Scanning electron microscopy was performed on the rat stomach mucosa after application of $BaSO_4$ and three barium-containing commercial contrast media The degree of flocculation was assessed flocculation could be prevented by using synthetic wetting agents and by physiologic natural emulsifiers sodium taurocholate and lecithine

ZUSAMMENFASSUNG

Eine rasterelektronmikroskopische Untersuchung der Mucosa des Magens der Ratte nach Applikation von BaSO und drei Barium-enthaltende kommerzielle Kontrastmittel wurde vorgenommen Der Grad der Flockung wurde festgestellt die Flockung konnte durch Verwendung von synthetischen Suspensionsmitteln und durch physiologische natürliche Emulsionsmittel Natriumtaurocholat und Lezithin verhindert werden

RESUME

Une microscopie électronique à balayage a été faite sur la muqueuse gastrique du rat après application de $BaSO_4$ et de trois moyens de contraste du commerce contenant du baryum Les auteurs ont determiné le degré de floculation la floculation peut etre empechee en utilisant des agents mouillants synthetiques et par des émulsifiants physiologiques naturels taurocholate de sodium et lecithine

REFERENCES

DASHER G F Surface activity of naturally occurring emulsifiers Science 116 (1952) 660

EMBRING G and MATTSSON O Barium contrast agents Acta radiol Diagnosis 7 (1968) 245

FRENNIG B and ÖBRINK K J The effects of acetic and acetylsalicylic acids on the appearance of the gastric mucosal surface epithelium Scand J Gastroent 6 (1971) 605

HEJGAARD J J RATJEN E und SCHULZE K Eine objektive Methode zur Bestimmung der Suspensionsstabilitat von Bariumsuspensionen Fortschr Rontgenstr 84 (1956) 349

HOFMANN A F The function of bile salts in fat absorption Thesis Lund 1964

KRAMER W Verwendung von Netzmitteln in der Magendiagnostik Fortschr Rontgenstr 84 (1956) 740

LUTZGER L G and FACTOR S M Effects of some water soluble contrast media on the colonic mucosa Radiology 118 (1976) 545

MILLER R E Barium sulfate suspensions Radiology 84 (1965) 241

PFEIFFER C J Gastric surface morphology in man monkey and ferret Evidence for in situ surface degeneration Exp Mol Path 13 (1970) 319

PHARMACOPOEA NORDICA EDITIO FENNICA Laakintohallitus Helsinki 1964

RIEDER H Radiologische Untersuchungen des Magens und Darmes beim lebenden Menschen Munch med Wschr 51 (1904) 1548

SCHWARTZ S E FISCHER H W and HOUSE A J S Studies in adherence of contrast media to mucosal surfaces Radiology 112 (1974) 727

SHIRAKABE H Double contrast studies of the stomach Georg Thieme Verlag Stuttgart 1972

SIEW S A study of the gastrointestinal tract by microvision (SEM) Scientific exhibition at the American Medical Association clinical convention Cincinnati Ohio 1972

FROM THE DEPARTMENT OF DIAGNOSTIC RADIOLOGY KAROLINSKA SJUKHUSET S 104 01 STOCKHOLM SWEDEN

EFFECTS OF THE PREGNANT UTERUS ON THE ABDOMINAL AORTA AND ITS BRANCHES

LARS OHLSON

Certain aspects of the pressure and traction exerted by the pregnant uterus on the posterior abdominal wall were reported previously (OHLSON 1972 1973 a b) The displacement and compression of the aorta were then briefly mentioned A more detailed account of these and certain other related effects on the vessel and its branches is now presented

Material

Radiography The material consisted of 20 normal abdominal aortographies in non pregnant women and 273 uterine angiographies in pregnant women performed between 1953 and 1971 i e while angiography was still used to determine the site of the placenta The patients were examined in the supine position the FFD was 100 cm and the exposure time 0 32 s After onset of labour the exposures were performed between uterine contractions The examinations were related to the duration of pregnancy in weeks and for statistical analyses divided into the following periods 16 to 20 weeks 21 to 25 weeks 26 to 29 weeks 30 to 32 weeks 33 to 34 weeks 35 to 36 weeks and 37 to 41 weeks The length of each period was determined by the distribution of cases throughout pregnancy

Autopsy The material consisted of 200 cases without disease or recent surgical intervention in the abdomen The cadavers were examined at about 20 C and with the organs in situ

Submitted for publication 7 October 1976

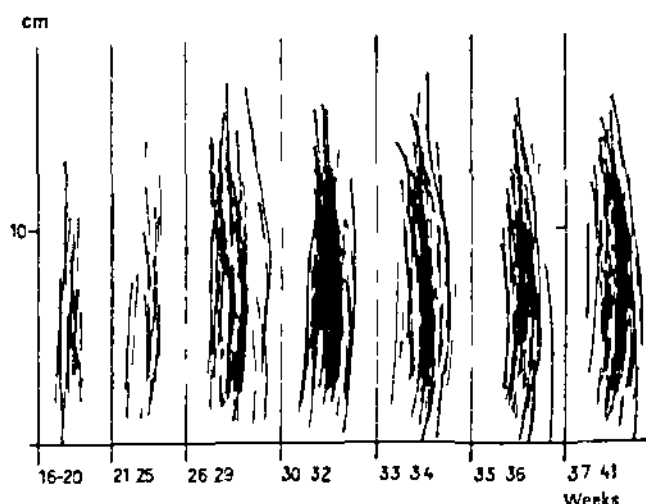


Fig 1 Displacement of the aorta in pregnancy Analysis of the left wall of the vessel by superposition of course records Scale 1 4

Methods

Radiography The course of the aorta from the main renal arteries to the bifurcation was recorded in a topographic coordinate system and by superposed analysis of the records (OHLSON 1972) The position of the left outline of the vessel at different levels of the y axis (abscissa for each centimetre) was recorded The right outline of the aorta is more difficult to determine in pregnancy than the left due to the origin of the lumbar arteries and therefore it is less suited for the recording of the position of the aorta In addition the following factors were evaluated directly on the films (1) Compression of the aorta (2) movements of the right and left aspects of the aorta during the time of exposure resulting from the pulsations within the vessel (3) compression of the common and external iliac arteries and (4) compression and stretching of the lumbar arteries The statistical analyses comprised discrimination of mean values and standard deviations for the positions at each level in each period and linear regression analysis

Autopsy The loops of the small intestines and their mesentery were deflected cranially When the area of the mesentery attached to the posterior abdominal wall covered the cranial part of the aorta it was freed by deflection i e without using dissection The consistency and mobility of the aorta and its lumbar branches were examined by digital palpation without opening the peritoneum Thereafter the peritoneum was removed and the vessels examined in situ by blunt and sharp dissection

Results

Radiography

Displacement of the aorta Displacement to the right occurred in 7 cases one in weeks 32 and 33 each two in weeks 35 and 36 each and one in week 38 Displacement to the left is shown in superposed analysis in Fig 1 The total number of cases was




Fig 2



Fig 3

Fig 2 Late pregnancy (34 weeks) Appearance of the aorta and its branches

Fig 3 Late pregnancy (28 weeks) Displacement and compression of the aorta and pulsations of its left segment only Compression of the right common iliac artery Compression and stretching of right lumbar arteries

266 The aorta became displaced from non pregnancy to 16 weeks ($p<0\ 001$) The displacement increased in proportion to the duration of pregnancy ($p<0\ 001$) It also extended in a cranial direction during pregnancy ($p\ \ 0\ 005$)

Compression of the aorta is illustrated in Figs 2 to 4 The right segment of the vessel was compressed in 79 cases and the left in 7 On the left side of the vessel no increase in the frequency of compression occurred after 29 weeks On the right side the frequency increased up to 32 weeks but not later On this side the site of com pression moved cranially with advancing pregnancy ($p<0\ 01$) and the length of the compression increased ($p<0\ 01$)

Pulsations of the aorta were demonstrated in 31 cases invariably on the left aspect of the vessel With advancing pregnancy the length of the pulsating part increased cranially but the frequency was unchanged In 9 cases the wall was seen in systole as well as in diastole (Fig 3) while in the remaining cases the wall was intermediate in position

Compression of the iliac arteries On the right side the frequency was as follows 16–20 weeks 4/22 cases (15 %) 21–25 weeks 7/13 (52 %) 26-29 weeks 21/36 (60 %)



Fig 4 Late pregnancy (35 weeks) Lateral projection Compression of the aorta most marked at the most prominent parts of the lumbar spine

30–32 weeks 22/33 (66 %) 33–34 weeks 26/45 (56 %) 35–36 weeks 24/38 (69 %) and 37–41 weeks 26/42 cases (64 %) The frequency thus increased up to 25 weeks but not later The compression was always most marked over the most prominent parts of the lumbar region i e the median caudal aspect of the fourth lumbar vertebra and the fourth intervertebral disc (Figs 3 4) In some cases a continuous compression was present from the right aspect of the aorta to the right common and external iliac arteries On the left side compression was found from 21 weeks in a total of 12 cases with almost equal distribution into the different periods Also on this side the compression was most marked on the most prominent parts of the spine Accordingly compression of the left aspect of the aorta was only present when the vessel was displaced to the right or not displaced in the frontal plane

Compression and stretching of the lumbar arteries (Figs 2 3) The left lumbar arteries were compressed only when the aorta was displaced to the right The right lumbar arteries were compressed on displacement of the aorta to either side as well as in the absence of displacement of the greater vessel in the frontal plane but both the frequency and the extent of the compression increased with displacement to the left ($p < 0\ 01$) In some cases the compression involved the second lumbar artery but in no case the first one The displacement and the compression both increased in a cranial direction after 29 weeks ($p < 0\ 01$)

Autopsy

The most prominent part of the lumbar lordosis was the median caudal aspect of the fourth vertebra and the median aspect of the fourth intervertebral disc The abdominal aorta and the common and external iliac arteries were readily displaced 2 to 4 cm laterally by digital compression The renal mesenteric and gonadal arteries did not impede this displacement their origins and proximal parts followed the displacement The vena cava and its left homologs permitted the aorta to slide easily over them The most fixed branches of the aorta were the lumbar arteries The muscular and spinal branches of these could not be evidently displaced nor stretched by

the traction from the aorta On displacement of the aorta to the left the distal part of any right lumbar artery—passing between the ligaments and the periosteum along the lateral aspect of the middle part of the vertebra before giving off the branches—was stretched by the traction but not displaced The proximal part passing in front of the vertebral column was put under a greater tension and thus elongated by 2 to 3 cm The proximal part of any left lumbar artery—considerably shorter than its right homolog—was similarly stretched by displacement of the aorta to the right although considerably less so than the right homolog

Discussion

The three dimensional configuration of the abdominal aorta is complex more so than that of most other arteries The complexity is evident already from a considera tion of its embryologic development the vessel being formed by fusion of the two embryonic dorsal aortas It also fuses with the vitelline arteries i e the coeliac and mesenteric arteries The different categories of branches given off by the aorta are quite distinct from one another the ventral ones mentioned the lateral branches comprising the renal suprarenal and gonadal arteries and the dorsal branches forming the lumbar arteries The continuation of the aorta results in the sacral artery and the common iliac arteries with their dissimilar topography on the right and left sides Thus the aorta and its branches form a composite system of communicating vessel The form of the transverse area of the aorta differs widely from one level to another It diminishes with each branch given off and includes the origin and proxi mal part of each branch It appears not to be circular at any level and at most levels its geometry deviates far from a circle the transverse area forming complex figures Pressure and traction from surrounding structures are added as is the dynamics of the vessel and its branches the pulsations in different parts of the arterial system interfering with one another at many locations

The attachment of the abdominal aorta is loose There are no ligaments or other fibrous or muscular connections to the posterior abdominal wall The branches of the aorta do not prevent its displacement with the exception of the lumbar arteries these are in this respect analogous to ligaments This was found at angiography and at autopsy and is also a common finding at surgery and in ordinary angiography of the abdomino-lumbar region

The growing pregnant uterus exerts pressure and traction on the surrounding organs and structures (OHLSON 1973 a b) The pressure gradually exerts its effects in all directions When the uterus reaches the lumbar region i e the posterior abdominal wall the small intestines are gradually pushed upwards This process creates tension in the mesentery the traction being transmitted to the area of fusion of the mesentery and the parietal peritoneum (root of the mesentery) In the supine position the uterus transmits pressure but no primary traction to the paravertebral structures This pres sure effect was found to extend cranially with advancing pregnancy and to be greatest

on the most prominent parts of the posterior abdominal wall viz the median caudal part of the lumbar spine This prominence thus acts as a fulcrum for compression and displacement

The displacement of the aorta to the left is preconditioned by the normal non pregnant slight sinistro position of the vessel However in 7 cases in the present material the aorta was displaced to the right This would indicate some dextro-position of the aorta in the non pregnant state in these cases permitting the vessel to slide to the right of the fulcrum The gradual increase of the displacement to the left with advancing pregnancy as well as the gradual cranial extension of the displacement are effects of the enlarging uterus

The compression of the aorta which was most marked on the right aspect of the vessel and which extended cranially during pregnancy is also predetermined by its normal non pregnant sinistro position Pulsations could be detected only on the left aspect of the aorta but small pulsations of the right aspect may have been present in some examinations where the interval between exposures was equal to or exceeded the period of a pulsation

The compression of the aorta and the direction of pulsations to the left are two factors of the transformation of the vessel The uterus thus compresses the right aspect of the aorta displacing the whole vessel to the left along the convexity formed by the vertebral column and the paravertebral structures notably the psoas muscle the vessel thus moves in a curve in a leftward and dorsal direction The right part of the aorta is compressed between the uterus and the fulcrum in such a way that the right and anterior parts of its wall are displaced to the left in relation to the vessel itself The right outline of the inner aortic wall in the a p projection is therefore the original anatomic right posterior aspect of the circumference and the left outline is the original anatomic left anterior aspect This appears in Figs 2 and 3 (cf also Fig 4) where the right wall is projected at the origins of the lumbar arteries and the left wall at the origins of the inferior mesenteric and left ovarian arteries The compression of the right part of the vessel inhibits pulsations to the right whereas the anterior left part is free to pulsate in the space formed by the uterus and the soft left mesocolon on the one hand and the slope of the underlying psoas muscle on the other a space where the pressure is much lower than over the fulcrum The transformation of the composite arterial system in pregnancy is recorded in a schematic transverse section in Fig 5

The mechanism for the compression of the iliac arteries is evident from the discussion The course of the right iliac artery prevents its displacement thus the vessel is trapped between the uterus and the fulcrum and compressed The same mechanism applies to the right lumbar arteries The compression of these vessels is effected by the pressure from the uterus and their stretching by traction from the displaced aorta

These conditions apply to the horizontal supine position and similar mechanisms operate in the prone position where the uterus is compressed by a surface such as a

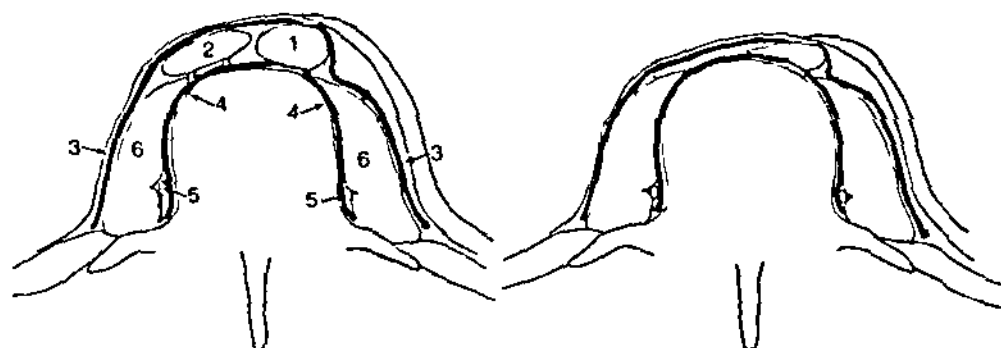


Fig 5 Transverse section of the aorta and its branches at the level of the ovarian arteries Supine position Left Non pregnancy Right Late pregnancy 1—aorta 2—inf rior vena cava 3—ovarian artery 4—lumbar artery 5—ascending lumbar vein 6—psoas muscle

table against the weight of the posterior abdominal wall If a patient rises from a prone position to her elbows and knees thus assuming a position similar to that of a standing quadruped the pressure from a normal relaxed uterus ceases the uterus hanging free from the lumbar region and supported only by its peritoneal duplicatures and the ventral abdominal coverings Likewise women with hypotensive symptoms in the supine position are often relieved when turning to the side many patients with such symptoms are aware of the mechanism spontaneously avoiding supine and prone positions The relief from the pressure exerted by the uterus on one of the paravertebral structures the inferior vena cava was demonstrated by KERR et coll (1964)

In many patients in the present material the aorta the right common iliac artery and sometimes also the lower right lumbar arteries were completely occluded for a period of 3 to 6 seconds in the absence of sensible contractions as well as of symptoms of hypotension BIENIARZ et coll (1969) believed that compression of the aorta during uterine contractions could cause a dangerous retardation of the placentofetal blood flow and emphasized the potential importance of the ovarian arteries as collaterals for the blood supply to the fetus This compression is relieved by the patient herself by simply assuming other than supine and prone positions Therefore patients with a tendency to hypotension should be instructed to avoid supine and prone positions when symptoms appear Normal contractions of the myometrium cause a delay in the placental blood flow by compressing the myometrial arteries (BORELL et coll 1964 1965) this compression comprises the flows from the ovarian arteries as well as those from the uterine and round ligament arteries thus suspending the function of the ovarian arteries as collaterals to the placenta In normal contractions the delay was found to have a short duration that did not involve any danger to the fetus Contractions with increased frequency duration and intensity are potentially dangerous to the fetus irrespective of the position of the patient and should apparently receive conventional therapy

SUMMARY

The pregnant uterus was found to exert pressure upon the lumbar region with a maximum over the midline of the lordosis and diminishing laterally Those parts of the arterial system formed by the aorta and its dorsal branches and displaceable at autopsy were accordingly dislodged by the uterus whereas the fixed parts were compressed The pressure effects extended cranially during pregnancy Symptoms of compression can be relieved by avoiding supine and prone positions

ZUSAMMENFASSUNG

Es wurde gefunden dass der Uterus wahrend der Gravidität einen Druck auf die Lumbal region mit einem Maximum uber der Mittellinie der Lordose der sich seitlich vermindert ausubt Die Teile des arteriellen Systems die durch die Aorta und deren dorsale Zweige gebildet werden und die bei der Autopsie verschiebbar sind werden entsprechend mit dem Uterus verschoben wahrend die fixierten Teile komprimiert werden Der Druckeffekt dehnt sich wahrend der Gravidıtat kranialwarts aus Die Zeichen der Kompression konnen durch Vermeidung von Rucken und Bauchlagen vermindert werden

RESUMÉ

L auteur a constate que l utérus gravide exerce une pression sur la région lombaire avec un maximum sur la ligne mediane de la lordose et diminuant latéralement Les parties du système artériel forme par l aorte et ses branches dorsales qui peuvent être déplacées a l autopsie sont de meme deplacées par l uterus alors que les parties fixes sont comprimees Les effets de la pression s étendent vers le haut au cours de la grossesse Les symptomes de compression peuvent etre soulagés en evitant les positions en décubitus et en procubitus

REFERENCES

Bieniarz J Yoshida T Romero-Salinas G Curuchet E Caldeyro Barcia R and Crottogin J J Aortocaval compression by the uterus in late human pregnancy Amer J Obstet Gynec 103 (1969) 19

Borell U Fernstrom I Ohlson L and Wiqvist N Effect of uterine contractions on the human uteroplacental blood circulation Amer J Obstet Gynec 89 (1964) 881

— — — — Influence of uterine contractions on the uteroplacental blood flow at term Amer J Obstet Gynec 93 (1965) 44

Fernström I Arteriography of the uterine artery Acta radiol (1955) Suppl No 122

Kerr M G Scott D B and Samuel E Studies on the inferior vena cava in late pregnancy Brit med J I (1964) 532

Ohlson L Coordinate topographic recordings in the abdomen Acta radiol Diagnosis 12 (1972) 705

— (a) Non pregnant anatomy of the posterior abdominal wall as reflected in the course of the ovarian artery and the ureter Acta radiol Diagnosis 14 (1973) 145

— (b) Ovarian vessels and ureter as indicators of the expansion of the uterus in pregnancy Acta radiol Diagnosis 14 (1973) 467

FROM THE DEPARTMENT OF DIAGNOSTIC RADIOLOGY (DIRECTOR PROF H LODIN)
AKADEMISKA SJUKHUSET S 750 14 UPPSALA SWEDEN

GASTROCNEMIO-SEMIMEMBRANOSUS BURSA AND ITS RELATION TO THE KNEE JOINT

III Pressure measurements in joint and bursa

PER GUNNAR LINDGREN

The gastrocnemio semimembranosus bursa is located in the medial part of the popliteal region posterior to the joint capsule Its anterior portion lies anterior to the gastrocnemius and semimembranosus muscles its middle portion between these muscles and its posterior portion posterior to them

The bursa often communicates with the knee joint via a slit shaped opening in the joint capsule posterior to the medial femoral condyle where the tendon of the medial head of the gastrocnemius muscle leaves the capsule (Fig 1 a) A valvular mechanism in the communication between this bursa and joint was questioned as early as in 1840 by ADAMS but he did not investigate this matter in any detail Other authors have since discussed the possibility of a valve like mechanism between the joint and the bursa (WILSON 1938 HAGGART 1938 BEATTY 1959 MAUDSLEY & ARDEN 1961) Pressure measurements in the knee joint have been performed previously by CAUGHEY & BYWATERS (1963) DIXON & GRANT (1964) and JAYSON & DIXON (1970) The pressure in popliteal cysts communicating with the knee joint in patients with rheumatoid arthritis was also measured by JAYSON & DIXON who found that the pressure in the cyst was higher than that in the knee joint when the knee was extended In one of their 12 cases a valvular mechanism was observed fluid only passed in the direction from the knee joint to the cyst

The aims of the present investigation were to demonstrate the presence of a closure

Submitted for publication 6 December 1976

Table 1

Pressures (kPa) in the knee joint and communicating gastro cnemio-semimembranosus bursa in the patients

Patient	Injected fluid ml	Flexion 90–100		Max extension	
		Joint	Bursa	Joint	Bursa
1	20	—	—	2	15
2	20	11	11	2	27
3	20	5	5	2	27
4	20	13	13	<2	20
5	15	2	2	2	21
6	20	13	15	2	11
7	20	1	5	<2	40
8	30	2	9	<2	33
9	20	—	—	2	7
10	20	17	17	<2	27
11	15	—	—	<2	10
12	20	5	5	<2	7

mechanism in the communication between the knee joint and the gastrocnemio semimembranosus bursa and to elucidate the factors leading to the occurrence of such a mechanism and the way in which it functions

Material

Pressure measurements in the knee joint and gastrocnemio semimembranosus bursa were performed in 12 patients referred for arthrography of the knee and with a gastrocnemio-semimembranosus bursa communicating with the knee joint The material included patients both with and without constant and intermittent symptoms from a gastrocnemio semimembranosus bursa By symptoms from this bursa is meant discomfort or aching in the medial part of the popliteal region which is accentuated on extension or vigorous flexion of the knee A palpable cyst lying posteriorly between the gastrocnemius and semimembranosus muscles was also present A gastrocnemio semimembranosus bursa giving these symptoms and signs is often called a Baker s cyst

In 10 cases the clinical question was whether or not a Baker s cyst was present These patients had varying degrees of symptoms in the popliteal region One of them was examined one year after surgical resection of a Baker s cyst on sugges tion of recurrence Two patients had symptoms only in the medial part of the knee joint and had a torn medial meniscus clinically and radiographically

Pressure measurements were also performed in 9 autopsy cases with a communica tion between the gastrocnemio semimembranosus bursa and the knee joint at arthro

Table 2

Pressures (kPa) in the knee joint and communicating gastrocnemio semimembranosus bursa in the autopsy cases a = exposed bursa b = percutaneous puncture of bursa

Autopsy case	Injected fluid ml	Flexion 90-100		Max. extension	
		Joint	Bursa	Joint	Bursa
13	20	<2	<2	<[illegible]	[illegible]
14	30	2	2	<2	[illegible]
15	20	—	—	<[illegible]	[illegible]
16	20	—	—	<[illegible]	[illegible]
	50	7	7	<[illegible]	[illegible]
17	20	7	7	2	[illegible]
18	20	8	8	—	—
19	30	—	—	3	
20	20	<2	<[illegible]	[illegible]	
21	20	7	7	<[illegible]	[illegible]

graphy and in 5 autopsy cases without communication [illegible] not include any patients with diseased knee joint, an[illegible] palpable bursa

Methods

Clinical material A Radicath cerebral catheter was [illegible] knee joint following puncture medial to the patella The [illegible] was 1 57 mm and the inner diameter 1 14 mm The [illegible] under the patella or in the inferior part of the suprapa[illegible] After 10 to 20 ml Urografin 45% had been injected [illegible] was flexed until the gastrocnemio-semimembrano[illegible] medium The bursa was then punctured percuta[illegible] catheter of the same calibre was introduced into [illegible] was placed in the posterior part of the bursa poster[illegible] membranosus muscles with the knee extended [illegible] pressure transducers (EMT 34 Siemens Elema) [illegible] the bursa were recorded simultaneously on a [illegible]

The patient lay on the side of the examined kne[illegible] have the least possible effect on the mea urem[illegible]

Pressure recordings were made from the k[illegible] in full extension and at different degrees of [illegible] pressure against the bursa and also durin[illegible] quadriceps muscle [illegible]

Table 3

Pressures (kPa) in the anterior and postero medial part of the knee joint in the autopsy cases

Autopsy case	Injected fluid ml	Flexion 90–100		Max flexion	
		Ant	Post	Ant	Post
22	40	4	4	15	15
23	20	8	7	—	—
24	20	10	10	23	23
	40	20	20	>40	>40
25	10	<2	<2	10	10
	20	8	8	16	16
	40	12	13	33	33
26	20	10	9	24	24
	60	13	13	40	40

Autopsy material In the autopsy cases pressure measurements were performed after injection of 15 to 30 ml of Urografin 45 coloured with methylene blue into the knee joint After flexion of the knee with filling of the gastrocnemio-semimembranosus bursa the bursa was exposed in 7 cases A catheter was then inserted into the bursa and fixed in place with Histoacryl which at the same time served to seal the puncture site In 2 cases the catheter was inserted percutaneously In all cases the tip of the catheter was placed in the posterior part of the bursa For pressure measurements in the knee joint a metal cannula was inserted in 7 cases and a plastic catheter in 2 cases The tip of the cannula or catheter was placed under the patella Pressures were measured in the knee joint and the bursa simultaneously during maximum extension and varying degrees of flexion of the knee (Table 2) Two recordings were made on one case (16) Pressure measurements were also performed in the knee joint during injection into the bursa of physiologic saline coloured with methylene blue and in the bursa during corresponding injection into the knee joint

Pressures were measured in the knee joint alone in 5 cases with no communication between the joint and the bursa In these cases two metal cannulae were inserted percutaneously The tip of one of them was placed under the patella and the tip of the other in the posterior medial knee joint recess Pressures were recorded after injection of increasing amounts of fluid into the knee joint and at varying degrees of knee flexion (Table 3)

Results

Clinical material When the knee joint was flexed 45 the pressure both in the gastrocnemio-semimembranosus bursa and in the knee joint was low 0 to 4 kPa On flexion of 90 to 100 the pressure increased considerably in both the bursa and joint (Table 1) In 2 cases (7 8) the pressure in the bursa increased significantly more

than in the joint When the knee was passively extended maximally the pressure increased considerably in the bursa to a maximum of 40 kPa while the pressure in the knee joint was less than 2 kPa When the quadriceps muscle was moderately contracted with the leg in this position the pressure in the knee joint increased by 2 to 4 kPa and when the muscle was relaxed it returned to a low level When slight manual compression was applied from behind against the bursa with the knee still fully extended the pressure in the bursa increased further by 3 to 5 kPa while that in the knee joint remained low When the compression was released the pressure in the bursa fell to the pre-compression level When manual compression was applied intermittently against the bursa with the knee flexed 45 the pressure variations were transmitted to the knee joint

When the knee was alternately flexed and extended repeatedly no progressive pressure increase occurred either in the joint or in the bursa

Autopsy material With the knee flexed 45 the pressure in both the bursa and the joint was low—less than 2 kPa When the knee was flexed 90 to 100 the pressure in both the bursa and joint increased to a similar extent in both cavities (Table 2) On maximum extension of the knee the intrabursal pressure increased considerably but it was still low in the knee joint On manual compression of the bursa with the leg in this position the pressure in the bursa increased by a further 3 to 5 kPa while that in the knee joint was still low

During injection of fluid into the bursa with the knee flexed 45 and 90 the intra articular pressure continuously increased During injection into the joint at corresponding degrees of flexion the pressure in the bursa increased but not on full extension For these injections physiologic saline coloured with methylene blue was used That a flow of fluid between the two cavities did in fact occur with the knee flexed was established on direct inspection of the bursa and on aspiration of fluid from the joint No flow of fluid between the joint and the bursa was observed on full extension of the knee

In the 5 autopsy cases (9 recordings) with no communication between the joint and bursa pressure measurements were performed in the anterior part of the joint and at the same time in the postero medial part of the joint (Table 3) As seen in the table even when relatively small amounts of fluid were injected into the joint the pressure increased markedly on flexion of more than 90 The pressures were equal in the anterior and posterior parts of the joint

Discussion

Material and methods As the results for the clinical and autopsy materials were essentially similar regardless of whether or not the patients had symptoms from the gastrocnemio semimembranosus bursa it was considered not justified to examine a control group of individuals with healthy knees



Fig 1 Posterior medial capsule seen from the joint a) The slit shaped communication between the joint and the bursa open as on flexion of the knee b) The communication is closed as on extension of the knee The slit is compressed between the medial femoral condyle and the tendon of the gastrocnemius muscle T – tendon of the gastrocnemius muscle

In the clinical material some problems were encountered in the pressure measure ments On flexion of the knee kinking or compression of the catheter in the knee joint sometimes occurred This meant that in 3 patients (Table 1 1 9 11) reliable values were not obtained with the knee flexed These problems could have been avoided if a metal cannula or a more rigid coarse catheter had been used instead of the relatively narrow and soft catheter but this was considered to involve a certain risk of injury

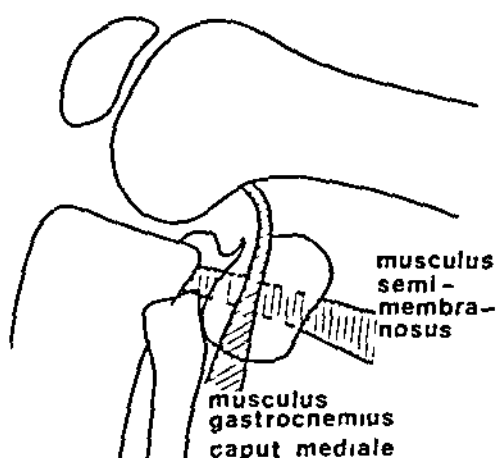
Leakage of fluid at the site of puncture in the bursa occurred on two occasions (9 and 12 in Table 1) This was established at fluoroscopy

It was not the intention to correlate the measured pressures to the volumes of the two cavities and the volume injected into the joint was therefore 20 ml in most cases thus independent of the amount of fluid in the joint at the beginning of the examina tion

In the autopsy cases on the other hand a large bore metal cannula was inserted into the joint while a catheter was used for the bursa as a cannula might have torn the thin wall In 2 cases a plastic catheter was also used in the joint and in one of them (15) kinking of the catheter made it difficult to obtain reliable recordings at 90 to 100 flexion Leakage of fluid at the site of puncture in the bursa occurred in one case (18 in Table 2) and was observed on direct inspection On flexion three of the values could not be obtained in 3 cases due to technical problems (16 and 19 in Table 2 23 in Table 3)

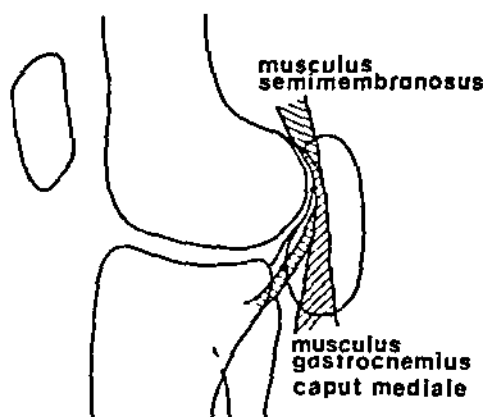
Anatomy and results The anatomic appearance (LINDGREN & WILLÉN 1977 LINDGREN 1977) and the present observations have established the existence of morphologic prerequisites for a closure mechanism in the communication between the knee joint and the gastrocnemio semimembranosus bursa and also between the anterior and posterior parts of this bursa The opening in the posterior joint capsule





a





b

Fig 2 a) Flexion of the knee The slit between joint and gastrocnemio-semimembranosus bursa is open b) Extension The slit is clo ed compressed between the medial femoral condyle and the tendon of the medial head of the gastrocnemius muscle

was slit shaped On flexion of the knee the slit gaped and the communication with the anterior part of the bursa was then open (Figs 1 a 2 a) At cineradiography in connection with the arthrography it has been demonstrated that contrast medium then passes from the knee joint to the bursa and vice versa (DOPPMAN 1965 LINDGREN



Fig 3 The popliteal region seen from behind The posterior part of the bursa has been re sected a) The anterior and middle parts of the bursa are seen between and anterior to the gastroc nemius and semimembranosus muscles on flexion of the knee The arrows indicate the margins of the incised bursa b) The middle part of the bursa is compressed on extension of the knee G gastroc nemius muscle S = semimembranosus muscle B = gastrocnemio-semimembranosus bursa

1977) On extension on the other hand the slit was compressed between the medial femoral condyle and the tendon of the medial head of the gastrocnemius muscle (Figs 1 b 2 b)

The part of the gastrocnemio semimembranosus bursa lying between the tendon of the medial head of the gastrocnemius muscle and the semimembranosus muscle is compressed on extension of the knee at the same time as the anterior part of the bursa is compressed between the medial femoral condyle and the gastrocnemius Any fluid in the bursa is then forced in a posterior direction On maximum extension the gastrocnemius and semimembranosus muscles are forcibly pressed against one another causing total compression of the middle part of the bursa (Fig 3 a b) (LINDGREN 1977) The fluid present in the posterior part of the bursa with the knee extended could not be forced by manual compression into the anterior part of the bursa and further into the knee joint On flexion of the knee no such compression of the bursa occurred

Both in the patients and in the autopsy cases the pressure in the joint and the bursa was low when the knee was semiflexed and the quadriceps was not being actively contracted Under those conditions neither the suprapatellar recess nor the gastrocnemio semimembranosus bursa was compressed On further flexion of the knee to 90 or more combined with active contraction of the quadriceps the suprapatellar recess became compressed and the pressure in the joint and in the bursa rose The pressure increase was similar in the two cavities The joint and the bursa communicated at these degrees of flexion also as was observed in the autopsy cases when coloured fluid was used and direct inspection of the flow of fluid was possible

The results of the measurements in the patient and autopsy materials did not differ essentially In the autopsy cases in whom the bursa had been exposed the

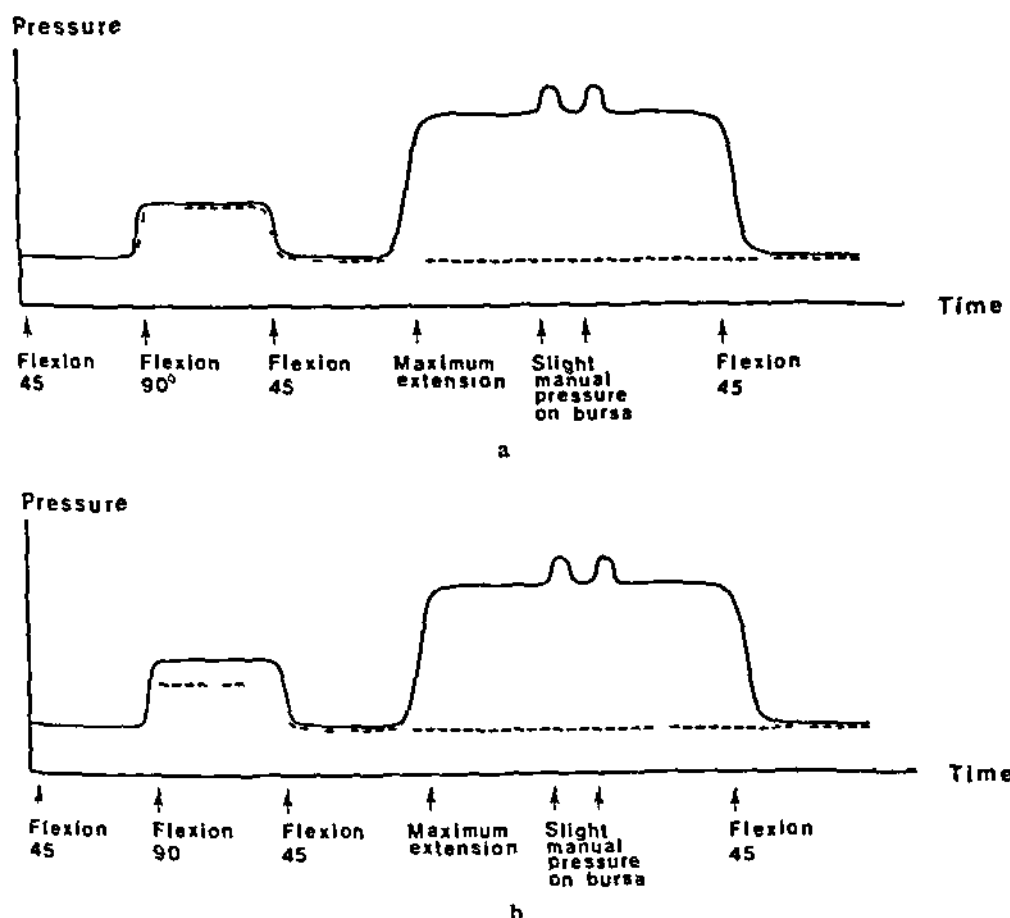


Fig 4 a) Schematic drawing of pressure variations in the autopsy cases and the patients with a closure mechanism b) Pressure variations in the 2 patients with a partial valve mechanism. No spontaneous passage of fluid from bursa to joint but no hindrance in the other direction. = pressure in the knee joint ——— = pressure in the gastrocnemio-semimembranosus bursa

pressures in the bursa were generally lower than in the clinical material on maximum knee extension When the volume of fluid in the bursa increased the bursa could then distend more easily which explains why the pressures then became lower In 2 cases in whom the catheter was inserted by percutaneous puncture the pressures were of the same order of magnitude as in the patients No valvular mechanism was found in the autopsy material

Two of the patients (7 8) had a palpable bursa but no definite joint *effusion* was present The fluid in the bursa was much more viscous than normally At the pressure measurements with the knee flexed the pressure in the bursa was higher than in the knee joint in these patients The higher pressure in the bursa was probably due to external pressure from soft tissues of the thigh The fact that no pressure

equilibrating flow of fluid occurred during the measurements could probably be explained by the high viscosity of the fluid in the bursa probably in combination with a membranous septum partially bridging the slit such septa occur in a high percentage of cases (LINDGREN & WILLEN 1977) However during fluoroscopy it was seen that on manual pressure on the bursa a small part of the fluid mixed with contrast medium could be forced back into the joint Thus with the knee flexed no absolute mechanical hindrance to the passage of fluid from bursa to joint existed although the flow was retarded In these 2 cases a partial valvular mechanism was present as the fluid did not pass spontaneously from the bursa to the joint despite the existence of a pressure gradient between the two cavities on flexion of the knee These findings correspond with observations made in a clinical material examined cineradiographically where a similar valve mechanism was observed (LINDGREN 1977)

On maximum extension the pressure in the bursa increased considerably and *remained high as long as the knee was fully extended The pressure in the bursa* increased further on manual compression and on release of this compression it returned to the same high pre compression level Thus on full extension of the knee no pressure equilibrating flow of fluid existed which showed that in this knee position the joint and the bursa did not communicate Schematic diagrams of the pressure variations in the joint and the bursa are given in Fig 4

The closure mechanism was due to two different factors First the slit shaped opening was compressed between the medial femoral condyle and the medial head of the gastrocnemius thus preventing the passage of fluid from the anterior part of the bursa into the joint Secondly the gastrocnemius and semimembranosus muscles pressed forcibly against one another on extension of the knee preventing passage of fluid in an anterior direction from the posterior part of the bursa

A membrane partially bridging the slit may hinder the flow of fluid between the joint and the bursa and may probably also lead to a valvular mechanism resembling the type found in the foramen ovale in the heart

At operation in patient 9 the posterior part of the bursa was removed The opening between the joint and the bursa was left untouched which explains why a bursa like cavity was observed postoperatively at arthrography and why the pressure variations in the joint and the bursa were essentially similar to those in the other patients

JAYSON & DIXON (1970) performed pressure measurements in the knee joint and gastrocnemio-semimembranosus bursa in patients with rheumatoid arthritis These patients had a dilated bursa but no or only a slight amount of fluid in the joint The authors considered that a valvular mechanism was present between the joint and bursa allowing fluid to pass from the joint to the bursa but not in the opposite direction They suggested two possible mechanisms for this valvular function One was that there might be a ball valve with a narrow channel through which fluid could be pumped from the joint into the cyst When higher pressure developed in the reverse direction the large quantities of fibrin within the cyst plugged the opening

The second possibility was that the valve was of the Bunsen type consisting of a narrow curved passage the walls of which collapsed under direct cyst pressure

The second suggestion seems less likely An alternative possibility is that the content of the bursa might have been highly viscous and prevented a pressure equilibrating flow in the direction towards the joint It is also conceivable that the valvular mechanism was caused by membranous septa partially bridging the opening between the joint and the bursa A combination of these conditions is also possible

No progressive pressure increase in the joint or the bursa was noted on repeated flexion-extension of the knee It is conceivable that in the presence of articular hydrops there may be a transient pump mechanism when the knee is repeatedly flexed and extended if the patient after having the leg in a resting position contracts the quadriceps as in extension of the lower leg This causes a pressure increase in the knee joint and a flow of fluid in the direction towards the gastrocnemio-semimembranosus bursa When on maximum extension the communication is closed this flow is interrupted to be made possible again on subsequent flexion and further active extension After a few of these flexions and extensions a steady state is reached A few patients also reported that the symptoms from the bursa were accentuated during the first few steps of walking after having had the knee in the resting position

The pressures were of equal magnitude in the anterior and posterior parts of the knee joint with all degrees of flexion (Table 3) Fairly small amounts of fluid may give a considerable increase in pressure when the knee is flexed more than 90 a maximum pressure of 40 kPa was noted in the material which was the upper limit recordable by the apparatus used A marked pressure increase in the knee joint may probably contribute to the occurrence of a communication between the joint and the gastrocnemio-semimembranosus bursa (LINDGREN & WILLÉN 1977)

Conclusion The results have demonstrated the occurrence of a closure mechanism with complete hindrance of flow between the joint and bursa on full extension of the knee independently of whether the patient has symptoms from the bursa or not In 2 patients with symptoms from the bursa a partial valvular mechanism was also present so that fluid was only able to pass spontaneously from the joint to the bursa but not in the other direction

SUMMARY

Pressure measurements in the knee joint and gastrocnemio-semimembranosus bursa were performed on patients and autopsy cases A normally occurring closure mechanism between the joint and the bursa was demonstrated and analysed Two patients were also found to have a partial valvular mechanism in the form of a hindrance to spontaneous passage of fluid from the bursa to the joint but no hindrance in the other direction

ZUSAMMENFASSUNG

Druckmessungen in Kniegelenk und der Bursa musculi gastrocnemii et semimembranosi wurden bei Patienten und in einem Sektionsmaterial vorgenommen Ein normal vorkommender ventilahnlicher Mechanismus zwischen dem Gelenk und der Bursa wurde nachgewiesen und analysiert Bei 2 Patienten wurde auch ein partieller Klappenmechanismus in Form eines Hindernisses fur eine spontane Passage der Flussigkeit von der Bursa zum Gelenk aber ohne Hindernis in der anderen Richtung gefunden

RÉSUMÉ

Des mesures de pression dans l articulation du genou et dans la bourse commune au jumeau et au semimembraneux ont été effectuées sur des malades et sur des sujets d autopsie L auteur a mis en évidence et a étudié un mécanisme de soupape qui se produit normalement entre l articulation et la bourse Il a trouvé aussi chez 2 malades un mécanisme partiel de soupape sous la forme d un obstacle au passage spontané du liquide de la bourse vers l articulation mais sans obstacle dans l autre sens

REFERENCES

LINDGREN P G and WILLÉN R Gastrocnemio semimembranosus bursa and its relation to the knee joint I Anatomy and histology Acta radiol Diagnosis 18 (1977) 497 (For further references see part I)

FROM THE DEPARTMENT OF RADIOLOGY (DIRECTOR PROF P VIRTAMA) AND MEDICINE (DIRECTOR PROF L KALLIOMAKI) TURKU UNIVERSITY HOSPITAL SF 20520 TURKU FINLAND

SOFT TISSUE RADIOGRAPHY FOR EVALUATING CLINICAL ACTIVITY OF RHEUMATOID ARTHRITIS

P MAKELA and M HAATAJA

The activity of rheumatoid arthritis is a term which refers to the reversible and predominantly inflammatory features of the disease The great variation in the clinical course and symptoms together with the fact that the etiology and pathogenesis of the disease still remain unknown necessitates the use of various signs and items when evaluating the host response to the disease process Numerous criteria have been found to be quantifiable and to correlate sufficiently well with the disease activity Assembling those various items to define the intensity of the whole process requires the use of some numerical system One such activity index has been suggested by LANSBURY (1966) and is often used

Joint pathology has always been considered of primary importance when assessing the activity of the disease The traditional characteristics of inflammation are pain swelling heat and redness and loss of function Although clinical observation of these features is simple their quantification is more difficult Palpometers have been developed for quantification of joint tendernes and goniometers for estimation of joint motility The temperature of the joints may be estimated by *thermography* (BOAS 1954) Several methods have been suggested for the measurement of joint swelling but none has been generally accepted HART & CLARK (1951) recommended the use of a ring series ECCLES (1956) and SMYTH et coll (1963) measured the swelling of the hands and feet on the basis of the amount of fluid they supplanted

Submitted for publication 18 March 1977




Fig. 1 Female aged 46 with a 3 year history of rheumatoid arthritis Grade 2 swelling in 2nd and 3rd proximal interphalangeal and metacarpophalangeal joints Grade 1 swelling in 4th and 5th proximal interphalangeal and 5th metacorpophalangeal joints Grade 2 superficial erosions in 5th proximal interphalangeal and 2nd and 3rd metacarpophalangeal joints

The earliest roentgenographic lesions in rheumatoid arthritis appear in the soft tissues of the joints and are at least partly reversible Radiologically identifiable are fusiform thickening and swelling of the joint capsule and periarticular oedema which appears as a blurring of the outline of the joint capsule and as a somewhat mottled structure in the joint surroundings Several authors have emphasized the importance of the soft tissue appearance in the early diagnosis of rheumatoid arthritis It has also been found that massive joint swelling and periarticular oedema are indicative of the active stage of the disease (LOCKIE 1953 SOILA 1958 BERENS et coll 1964 STEINBACH & JENSEN 1975)

Advances in the field of soft tissue radiography have improved the demonstration of these lesions particularly in the hands and feet (FISCHER 1973 REICHMANN et coll 1974)

Increased blood flow in the inflammatory joint tissue may be measured using isotopes In recent years the isotope most frequently employed has been $^{99}Tc^m$ either as pertechnetate or as $^{99}Tc^m$ tagged albumin (OKA et coll 1970 MAXFIELD et coll 1972 GOMEZ et coll 1974) Significant correlations have been found between the



Fig 2 Male aged 35 a) Grade 3 swelling and periarticular oedema in 2nd and 3rd proximal inter phalangeal joints b) Six months later Grade 2 swelling and no periarticular oedema Clinical activity (Lansbury index) decreased at the same time from 85 to 55

accumulation of the isotope in the joint tissue and the estimated degree of activity of the disease (OKA et coll 1973 HAATAJA 1975) A Tc index based on the isotope accumulation in the joints had a highly significant correlation to the Lansbury index of the patients (OKA et coll 1973)

The radiologic appearances of the soft tissues of the hands were correlated with the clinical activity of the disease as evaluated with the Lansbury index Correlations between local isotope accumulation in the hands and soft tissue lesion scores were also investigated The results are now reported

Material and Methods

The material comprised 67 patients under treatment at this department of medicine The diagnosis of rheumatoid arthritis was confirmed through the clinical laboratory and radiographic fulfilment of the criteria for classical or definite disease as defined by the American Rheumatism Association (ROPES et coll 1959)

The patients 50 females and 17 males ranging from 26 to 47 years of age (mean 50 5 years) were classified into 3 groups according to the duration of the disease



Fig 3 Female aged 65 with rheumatoid arthritis for more than 10 years Grade 3 swelling and periarticular oedema in 2nd proximal interphalangeal joint

less than one year in 17 patients more than one year but less than 3 years in 9 patients and more than 3 years in 40 patients The clinical activity of the disease was estimated according to the Lansbury activity index based on the following six criteria (1) Duration of morning stiffness (2) the time interval between getting out of bed and the onset of fatigue (3) the daily need for analgesics calculated to an equivalent amount of acetylsalicylic acid (4) grip strength measured by sphygmomanometer (5) joint index based on joint tenderness to pressure or passive movement and the size of the joints involved and (6) erythrocyte sedimentation rate

Soft tissue radiography of the hands was performed using a combination of molybdenum target equipment for mammary radiography and immersion of the hands in a 2 5 cm layer of 1 1 ethanol–water solution (MAKELA & HAATAJA 1976) The radiologic abnormalities were scored as follows

1) All proximal interphalangeal and metacarpophalangeal joints and the radial and ulnar parts of the wrist were examined for the presence of erosions and scored as follows 0 = no erosion 1 = subperiosteal osteolytic region representing a pre-erosive lesion 2 = one pocketed erosion or surface erosion 3 = two or more erosions The total maximum score for erosions was 66



Fig 4 Same case as in Fig 3 One year later Grade 1 swelling in 2nd proximal interphalangeal joint grade 3 swelling and periarticular oedema in 4th and 5th proximal interphalangeal joints Deteriorating erosive lesions especially in 2nd proximal interphalangeal joint

2) The same regions were also examined for evidence of joint capsule thickening and swelling and scored as follows 0 = no swelling 1 = slight thickening 2 = definite swelling 3 = massive swelling The highest possible joint swelling score was thus 66

3) The same joints were also investigated for evidence of periarticular oedema as suggested by blurring of the outline of the joint capsule or the presence of a slightly mottled structure around the joint Dilated vessels proximal to a joint were also considered evidence of periarticular oedema The number of joints thus affected was counted and the maximum score for joint oedema was 22

In 33 patients measurement of radioactive $^{99}Tc^{m}$ accumulation in the hand and wrist was performed using a modification of the method described by OKA et coll (1973) Thirty minutes after intravenous injection of one mCi of $^{99}Tc^{m}$ pertechnetate activity distribution was recorded by a Single Channel Analyser AS 11 (Wallace Oy Finland) Activity was measured for a total of 30 seconds over both hand and wrist using a 30 cm detector skin distance The centre of the field was focused midway between the metacarpophalangeal joints and the wrist on the dorsum of the hand with the fist clenched For background activity pulses over the heart and bladder

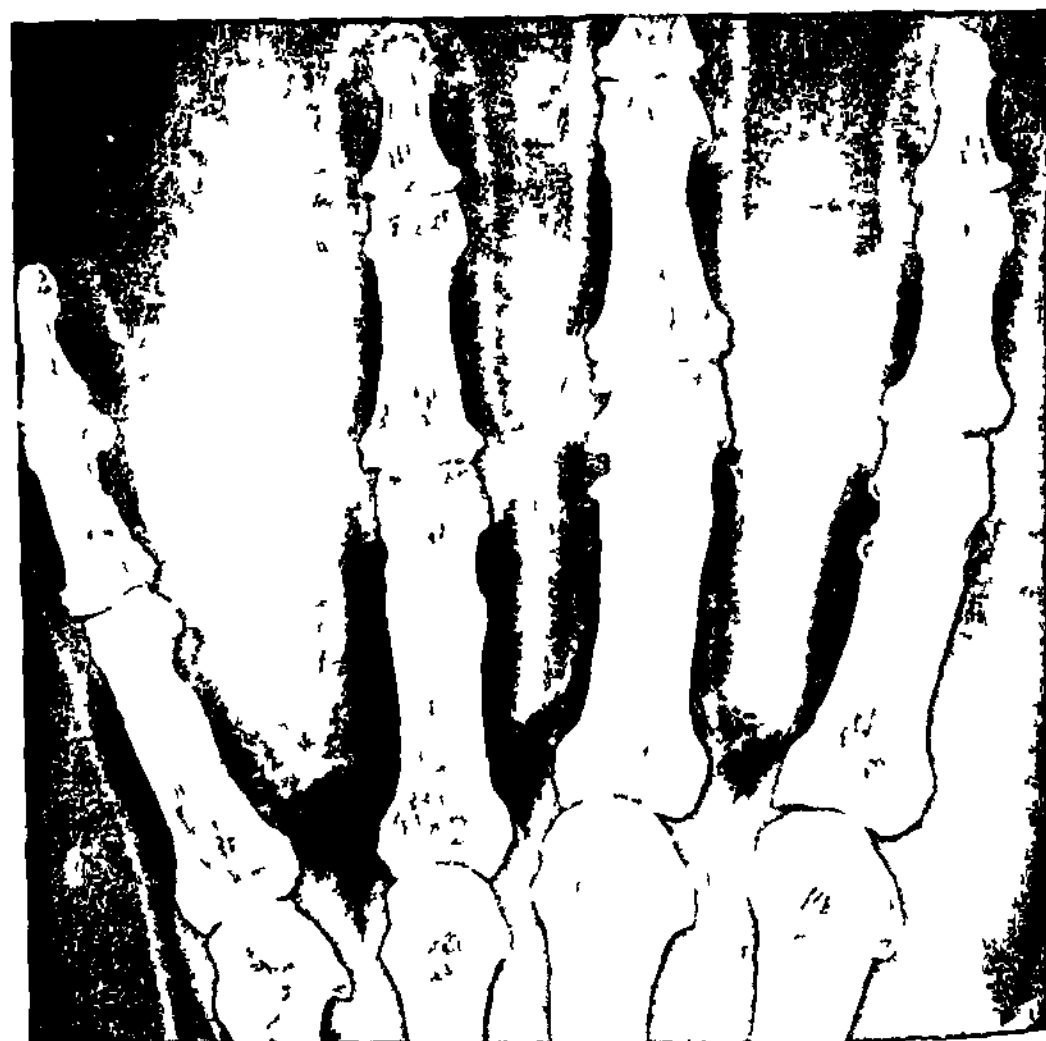


Fig 5 Female aged 55 with rheumatoid arthritis for over 6 years Mainly degenerative joint changes without erosion or periarticular oedema and with some joint capsule thickening in proximal interphalangeal joints and 5th metacarpophalangeal joint The rheumatoid arthritis was not clinically active

were also recorded for 30 s The Tc index for the hand was calculated by dividing the value of the pulses obtained over the hand by the mean value of the pulses over the heart and bladder In these 33 patients scores for erosions joint swelling and periarticular oedema were estimated for the right and the left hand separately Coefficients for linear correlation between variables were estimated according to the Pearson method Corresponding p values were obtained from the statistical tables of Documenta Geigy (1960) Examples of soft tissue radiography results and corresponding scores are given in Figs 1 to 5

Table

Mean range and standard deviation of Lansbury indices and radiologic scores (n = 67)

	Mean	Range	SD
Lansbury activity index	68 99	8–125	31 36
Erosion score	17 18	0–48	9 44
Joint swelling score	14 10	0–37	13 47
Periarticular oedema score	3 90	0–14	3.25

Results

The mean range and standard deviation for Lansbury indices scores for erosions joint capsule swelling and oedema are expressed in the Table Figs 6 to 8 represent scatter diagrams for the association between different radiologic scores and the corresponding Lansbury index values They also show the coefficients for regression (+SD) and coefficients for correlation These are all highly significant ($p < 0\ 001$) The highest correlation coefficient is obtained between the score for oedema and Lansbury index ($r = 0\ 654$) and the lowest between the score for erosions and the Lansbury index ($r = 0\ 486$)

No significant correlation was found between Lansbury index and the age of the patients or the duration of the disease Correlations between the scores for different lesions were all highly significant the closest correlation being that between scores for swelling and oedema ($r = 0\ 732$) Correlation coefficients between scores for erosions and scores for joint swelling and between scores for erosions and scores for oedema were $r = 0\ 689$ and $r = 0\ 463$ respectively The number of erosions was also observed to correlate to the duration of the disease but this was not so for swelling and oedema This observation supports the concept of the partly reversible nature of joint swelling and oedema

The $^{99}Tc^m$ indices obtained from 66 hands of 33 patients ranged from 0 33 to 0 06 (mean 0 17 SD 0 06) A highly significant correlation existed between the Lansbury index and the $^{99}Tc^m$ index of the hands ($r - 0\ 403$) Figs 9 and 10 give the correlation between scores for joint swelling and Tc index and between scores for periarticular oedema and Tc index in corresponding hands These correlation coefficients are both significant ($p < 0\ 01$)

Discussion

An accurate determination of the activity of the rheumatoid arthritis is mandatory in the assessment of the effectiveness of various treatments Signs and symptoms as well as laboratory findings have often been used in measuring the improvement in the patient s condition while structural changes (as demonstrated for example by radiology) have been given less attention

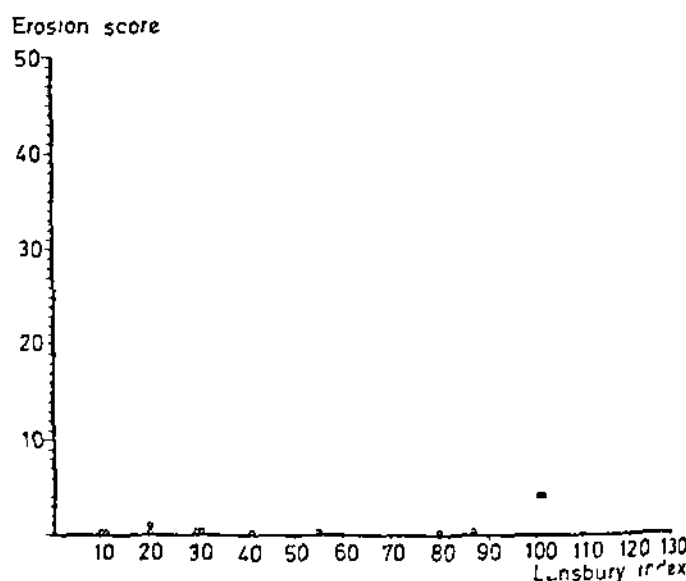


Fig 6 Scatter diagram of erosion score and Lansbury activity indices b = 0 20819 ± 0 0464 r = 0 486* * n = 67

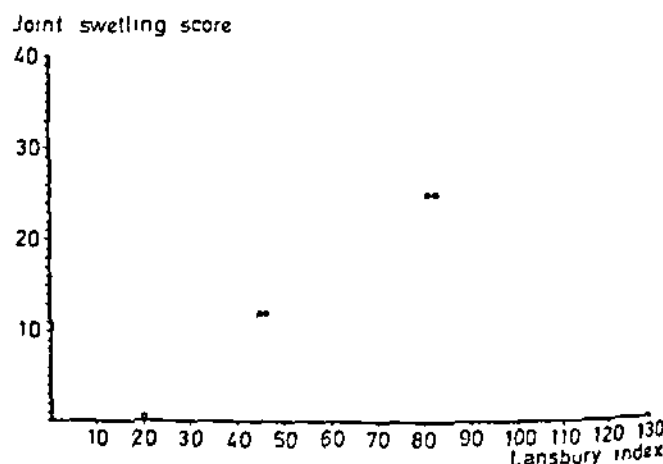


Fig. 7 Scatter diagram of joint swelling score and Lansbury activity indices b = 0 1729 ± 0 0305 * r = 0 574*** n = 67

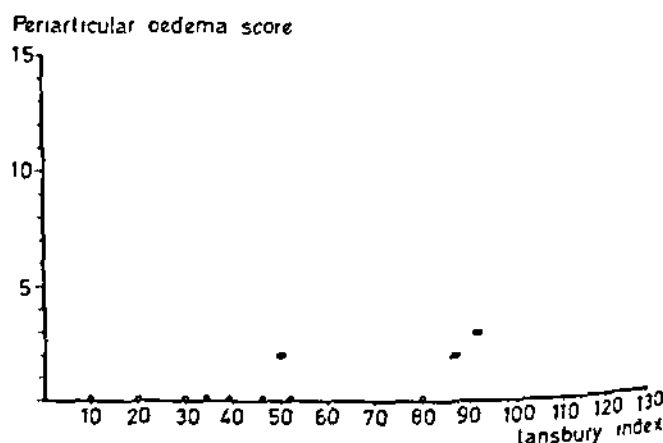


Fig 8 Scatter diagram of periarticular oedema score and Lansbury activity indices b = 0 067741 ± 0 0097 r = 0 654** n = 67

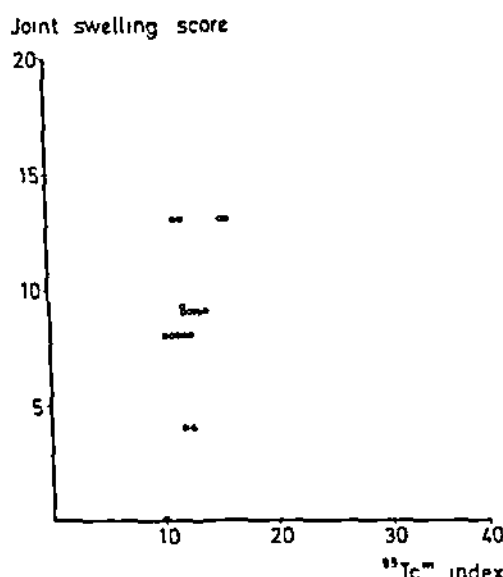


Fig 9

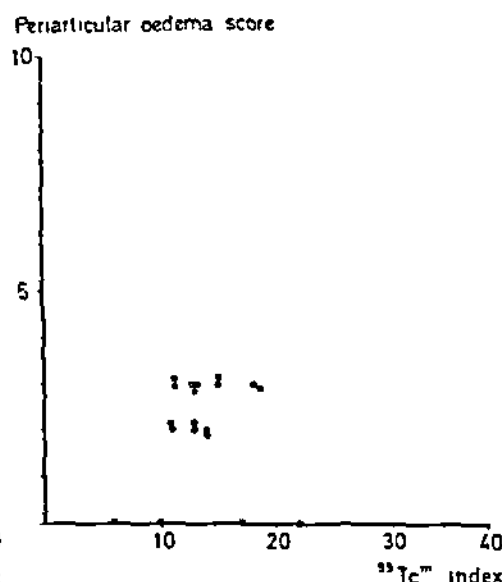


Fig 10

Fig 9 Scatter diagram of joint swelling score and $^{99}Tc^m$ indices b = 27 1335 ± 8 69 * r = 0 363 n = 66

Fig 10 Scatter diagram of periarticular oedema score and $^{99}Tc^m$ indices b = 12.325 ± 3 9861 r = 0 361 n = 66

Analgesics and anti inflammatory drugs are thought to have a temporary effect on several signs without having any effect on the course and prognosis of the disease It has been suggested that serial determinations of ESR and C reactive protein together with an increase of erosions demonstrated at radiography is more useful (AMOS et coll 1977)

Significant positive correlations have been found between the extent of radiographic abnormalities or the rate of progression of radiographic lesions and several clinical and laboratory manifestations (SHARP et coll 1971) In the latter report narrowing of the joint space and the number of erosions were scored However these lesions are irreversible and the actual activity of the disease process cannot be measured By using a high resolution radiographic technique increase of erosions can be demonstrated even within a three month follow up period (MAKELA & HAATAJA) However increase of erosions and joint space narrowing is sometimes demonstrated in patients without clinical evidence of active disease (KARTEN et coll 1972)

Little information is available about morphologic changes in the earliest phase of the disease Biopsies have not been performed until several days after the apparent onset of an acute attack KULKA (1959) suggested that venulitis is the cardinal primary pathologic event in the disease process COOPER (1968) regarded the aggregation of

inflammatory cells around dilated venules as a prelude to migration of these blood borne cells The synovial membrane is generally agreed to be the site of origin of the process Exudation and oedema are the most striking features in the early stage (GARDNER 1972) Joint effusion results as a secondary phenomenon from the spread of these inflammatory components from the synovial membrane In the acute phase swelling and thickening of the joint capsule are partly due to extension of the synovial oedema

In the later stage of the disease this thickening mainly results from scar formation and thus resembles the irreversible bone and joint abnormalities (COOPER) This is in accordance with the results of the present investigation and periarticular oedema appears to be the lesion which has the closest correlation to the clinical activity indices reflecting the acute inflammatory reaction The value of observing the oedema in long term evaluation needs closer investigation In the present series only a few patients were followed for a long period

A close correlation with the results of joint scintigraphy proves that increased blood flow in joint regions joint swelling and oedema all indicate active synovitis Vascular dilatation is often seen in soft tissue hand films proximal to a synovitic joint (FISCHER & BRAUN 1973) Thermography has also been used for demonstration of active synovitis but appears to be inferior to joint scintigraphy (MAXFIELD et coll)

One major disadvantage of this soft tissue radiographic method is the considerable local skin radiation dose which would appear to limit its use in standard examinations *particularly in the case of children The use of low dose mammary radiography* techniques possibly provides one solution to this problem

SUMMARY

The value of soft tissue radiography in assessing the activity of rheumatoid arthritis was investigated in 67 patients and correlated to the clinical activity of the disease Soft tissue radiography using a technique for mammary radiography was combined with immersion Radiologically demonstrated periarticular oedema was most closely correlated to clinical activity A close correlation also existed between soft tissue radiographic lesions and $^{99}Tc^m$ accumulation in hands

ZUSAMMENFASSUNG

Der Wert der rontgenologischen Weichteildiagnostik zur Feststellung der Aktivitat einer rheumatischen Arthritis wurde bei 67 Patienten untersucht und zur klinischen Aktivitat der Erkrankung korreliert Die Weichstrahlaufnahmen wie sie fur Brustuntersuchung verwendet werden wurden mit einer Immersion kombiniert Das rontgenologisch nachweisbare periartikulare Ödem war am engsten zur klinischen Aktivitat korreliert Eine enge Korrelation bestand auch zwischen den rontgenologisch nachweisbaren Weichteil Veranderungen und der $^{99}Tc^m$ Aufnahme in den Handen

RESUME

Les auteurs ont etudie l interet de la radiographie des tissus mous pour juger l activite de la polyarthrite rhumatoïde sur 67 malades et l ont correlée a l activite clinique de la maladie La radiographie des parties molles utilisant une technique de radiographie mammaire a été

associée avec l immersion L oedème periarticulaire montré par la radiographie est en relation très étroite avec l activité clinique Il y a aussi une correlation etroite entre les lésions radiographiques des tissues mous et la fixation du Tc^{m} dans les mains

REFERENCES

AMOS R S CONSTABLE T J CROCKSON R A CROCKSON A P and MCCONKEY B Rheumatoid arthritis Relation of serum C reactive protein and erythrocyte sedimentation rates to radiographic changes Brit med J 1 (1977) 195

BERENS D L LOCKIE L M LIN R and NORCROSS B M Roentgen changes in early rheumatoid arthritis Radiology 82 (1964) 645

BOAS N F Thermography in rheumatoid arthritis Ann N Y Acad Sci 121 (1964) 223

COOPER N S Pathology of rheumatoid arthritis Med Clin N Amer 52 (1968) 607

Documenta Geigy Wissenschaftliche Tabellen 6 Auflage J R Geigy A G Basel 1960

ECCLES M Hand volumetrics Brit J phys Med 19 (1956) 5

FISCHER E Die rontgenologische Weichteildiagnostik der rheumatischen Arthritis (Weichstrahlaufnahmen der Hand) *In* Klinisch Radiologisches Seminar Band 3 p 17 Georg Thieme Verlag Stuttgart 1973

— und BRAUN J Neue diagnostische Moglichkeiten an den Extremitaten durch Weichstrahlaufnahmen mit Mammographiegeraten Electromedica 3 (1973) 90

GARDNER D Articular tissues Gross and microscopic pathology *In* The pathology of rheumatoid arthritis p 7 Edward Arnold Publishers London 1972

GOMEZ E GREEN F A and HAYS M T New techniques for identification of synovitis and evalutation of joint disease Bull rheum Dis 25 (1974) 786

HAATAJA M Evaluation of the activity of rheumatoid arthritis Scand J Rheum 4 (1975) Suppl No 7

HART F and CLARK C Measurement of digital swelling in rheumatoid arthritis Lancet 1 (1951) 775

KARTEN I O BRIEN W M BECKER M H and MCEWEN C Articular erosions in rheumatoid arthritis J chron Dis 25 (1972) 449

KULKA J P The pathogenesis of rheumatoid arthritis J chron Dis 10 (1959) 388

LANSBURY J Methods for evaluating rheumatoid arthritis *In* Arthritis and allied conditions p 269 Edited by J Hollander Lea & Febiger Philadelphia 1966

LOCKIE L M Treatment of the common forms of arthritis Ariz Med 10 (1953) 221

MAKELA P and HAATAJA M Soft tissue radiography of the hands in the rheumatoid arthritis Scand J Rheum 5 (1976) 113

MAXFIELD W S WEISS T E and SHULER S E Synovial membrane scanning in arthritic disease Sem nucl Med 2 (1972) 50

OKA M RENKONEN A and RUOTSI A Technetium 99m in the study of rheumatic joints Acta rheum scand 16 (1970) 271

— — — and KUIKKA J Measurement of systemic inflammatory activity in rheumatoid arthritis by the Tc 99m method Scand J Rheum 2 (1973) 101

REICHMANN S DEICHGRABER E STRID F HEYMAN F and STRAND T Soft tissue radiography of finger joints Acta radiol Diagnosis 15 (1974) 439

ROPES M BENNET G COBB S JACOX R and JESSAR R 1958 revision of diagnostic criteria for rheumatoid arthritis Arthr and Rheum 2 (1959) 16

SHARP J T LIDSKY M D COLLINS L C and MORELAND J Methods for scoring the progression of radiologic changes in rheumatoid arthritis Correlation of radiologic clinical and laboratory abnormalities Arthr and Rheum 14 (1971) 706

SMYTH C VELAYOS E and HLAD C A method for measuring swelling of hands and feet Acta rheum scand 9 (1963) 293

STEINBACH H L and JENSEN P S Roentgenographic changes in the arthritides Part I Sem Arthr Rheum 5 (1975) 167

SOILA P Roentgen manifestations of adult rheumatoid arthritis With special regard to the early changes Acta rheum scand (1958) Suppl No 1

ACTA RADIOLOGICA

PUBLISHED BY THE SOCIETIES OF MEDICAL RADIOLOGY IN
DENMARK, FINLAND NORWAY AND SWEDEN

Vol 19
Fasc 3

DIAGNOSIS

1978

PROTEINURIA FOLLOWING NEPHROANGIOGRAPHY

III Role of osmolality and concentration of contrast medium in renal arteries in dogs

S HOLTÅS T ALMEN and L TEJLER

The observation of massive proteinuria in a patient developing renal failure following nephroangiography (TEJLER et coll 1977 b) revealed that a profound but transitory increase in glomerular permeability resulting in massive albuminuria is frequent after nephroangiography in man when metrizoate is used as the contrast medium (TEJLER et coll 1977 a) Following nephroangiography in dogs albuminuria occurred within minutes after the injection of metrizoate or diatrizoate but no difference in the albuminuric effect of the two contrast media could be demonstrated (HOLTÅS et coll 1978) Furthermore neither the catheterization procedure nor the intrarenal arterial injection of an electrolyte solution iso-osmolal with plasma (Perfadex Pharmacia AB Sweden) caused such albuminuria

The present investigation which is part of a project aiming at exploring the mechanism(s) underlying this postangiographic albuminuria concerns the role of osmolality of the contrast medium solution and of concentration of the medium in the renal vessels

Material and Methods

The experiments were performed on mongrel dogs weighing on the average 16 kg (range 13 to 26 kg) anesthetized with intravenous Mebumal (pentobarbitone) and

From the Research Laboratories Department of Diagnostic Radiology and the Department of Clinical Chemistry Malmö Allmänna Sjukhus University of Lund S-214 01 Malmo Sweden
Submitted for publication 7 July 1977

Table 1

Number of dogs site of injection and dose and osmolality of the injected solutions in the experimental groups

Group	No of dogs	Injected solution	Dose ml/20 kg	Osmolality Osm	Site of injection
I	11	Urografin 76	10	2 1	Renal artery
II	7	Sodium chloride	10	2 1	Renal artery
III	6	Urografin 76	20	2 1	Peripheral vein

Urografin 76 Sodium/meglumine diatrizoate Iodine content 2 9 mol/l 370 mgI/ml

breathing spontaneously through an endotracheal tube Arterial and urinary bladder catheterizations were performed as previously described (HOLTÅS et coll) The dogs were divided into three groups Changes in concentration of urinary albumin were analysed following injection into one renal artery of equal volumes of Urografin 76% (group I) or a sodium chloride solution (group II) with the same osmolality as that of Urografin 76% and in group III following intravenous injection of Urografin 76% in twice the dose used in group I

The number of dogs in the groups the dose and osmolality of the test solutions are given in Table 1 Urine samples were obtained via the transurethral catheter before and 15 30 and 60 min after the injection In two additional dogs the urinary bladder was opened and polyethylene catheters (PE 60 Clay-Adams) were introduced 5 to 10 cm into the ureters These dogs received Urografin 76% 10 ml/20 kg into one of the renal arteries and urine samples were taken from both ureters separately before and at 15 min intervals after the injection during an observation time of 60 min

In all dogs one arterial blood sample was taken before the injection of the test solution Concentrations of albumin and creatinine in urine and plasma were determined as previously described and the concentration of urinary albumin was expressed per gram creatinine for reasons previously discussed (HOLTÅS et coll)

The ratio between the maximum postinjection concentration of urinary albumin and the preinjection value was calculated for each animal For this ratio the term relative increase of urinary albumin is used Differences were considered significant when p-values $<$ 0 05 were obtained by the Mann Whitney rank sum test

Results

After injection of Urografin 76% into one of the renal arteries in a dose of 10 ml/20 kg (group I) all 11 dogs reacted with marked albuminuria and in 9 of them the relative increase of urinary albumin was more than 1 000 After injection into one of the renal arteries of a corresponding volume (10 ml/20 kg) of a sodium chloride solu

Table 2

Number of dogs in groups I–III reacting with relative increase of urinary albumin of more than 10

Group	No of dogs	Relative increase		
		>10	>100	>1 000
I	11	11	11	9
II	7	7	0	0
III	6	2	0	0

Table 3

Median and range of albumin concentrations in preinjection urine samples and in the postinjection urine samples with maximum albumin concentration Median and range of the relative increase are also given Concentrations of albumin in urine are expressed in arbitrary units/g creatinine

Group	Concentration of albumin in urine		Relative increase of urinary albumin
	Preinjection	Postinjection	
I	0 32 (0 15–0 74)	1 200 (49–3 500)	3 300 (160–22 000)
II	0 32 (0 12–0 98)	8 2 (5 7–16)	26 (13–92)
III	0 33 (0 14–2 0)	2 3 (1 2–5 9)	5 9 (3 0–15)

Statistical evaluation of differences between the groups (Mann–Whitney) I–II I–III and II–III $p < 0\,005$

tion with the same osmolality as Urografin 76 (group II) or after injection into a peripheral vein of twice that volume of Urografin 76 % (group III) the relative in crease of urinary albumin never exceeded 100 (Table 2) After the angiography the concentration of albumin in urine reached or exceeded that in plasma in 7 of the 11 dogs in group I The relative increase of urinary albumin in group I (median 3 300) differed significantly from that in group II (median 26) which in turn was significantly higher than that in group III (median 5 9 Table 3)

The changes in concentration of urinary albumin following injection of Urografin 76 % in a dose of 10 ml/20 kg into one of the renal arteries in the two dogs which had bilateral ureteral catheters are presented in Table 4 In both dogs concentrations of urinary albumin rose to very high values in samples from the injected kidney while no definite changes were observed in samples from the other kidney

Table 4

Concentrations of albumin in urine from the right and left ureters respectively before and after injection of Urografin 76 in a dose of 10 ml/20 kg body weight into the right renal artery Concentrations of albumin in urine are expressed in arbitrary units/g creatinine

Time (min)	Dog 1		Dog 2	
	Right	Left	Right	Left
Before	9 9	6 7	16	6 4
15	4 000	3 4	1 600	8 5
30	1 800	1 8	3 600	4 7
45	1 300	2 1	2 800	7 1
60	1 000	1 7	1 900	7 9

Discussion

The high single dose of contrast medium used for nephroangiography was chosen because in a previous investigation this dose regularly resulted in such massive albuminuria that the possible influence on the results of any microscopic hematuria caused by the bladder catheterization or admixture of ureteral urine with residual urine in the bladder thereby would be minimized (HOLTÅS et coll)

In dogs the glomerular clearance of albumin has been estimated to be about 1 per cent of that of inulin (HARDWICKE et coll 1970) Blockage of tubular reabsorption of albumin without alterations of glomerular permeability would consequently lead to increased concentration of albumin in urine However from the estimation above it could be calculated that such concentrations of urinary albumin as occurred in group I following angiography could not be reached unless glomerular permeability for albumin is increased In the majority (7/11) of dogs in group I the postangiographic urinary albumin concentration exceeded the plasma concentration which most probably is a result of tubular reabsorption of water from the glomerular filtrate

From the data obtained in the two dogs with separate ureteral catheters it is evident that glomerular permeability to albumin increases only in the kidney subjected to a selective contrast medium injection This fact excludes the possibility that general reflex mechanisms cause the postangiographic albuminuria

The hypertonicity towards plasma of Urografin 76 % does not seem to be a dominating factor for the postangiographic albuminuria since injection of a sodium chloride solution of equal osmolality and volume resulted in a significantly lower degree of albuminuria Hypertonicity might still be of some importance as minor relative increases of urinary albumin also occurred after injection of the sodium chloride solution Postangiographic albuminuria is probably caused by several fac

tors of which hypertonicity is a minor one and the chemical structure of the contrast medium possibly a major one Other investigations concerning changes in permeability of the blood brain barrier in rabbits and dogs (BROMAN & OLSSON 1949 HOPPE 1959 HARRINGTON et coll 1966) and aortic endothelium in rats (NYMAN & ALMEN personal communication) after administration of contrast media and other hypertonic solutions have shown that the chemical structure of the contrast medium probably is more important as a cause of increased permeability than the hypertonicity which is in accordance with the present observations

The degree of glomerular dysfunction following intravascular injections of contrast medium does not seem to be related to the total amount of medium that the kidney excretes as this amount was highest in the intravenous series where only minor relative increases of urinary albumin occurred However the concentration of contrast medium in the renal arteries seems to be critical if albuminuria is to develop because nephroangiography with *high concentrations of contrast medium in the* renal arteries during a short time always resulted in massive albuminuria

Several methods for evaluating the effect of contrast media on vascular endothelia have been used through the years (BROMAN & OLSSON 1948 STEINWALL 1958 ZINNER & GOTTLOB 1959 MCCONNELL & MERSEREAU 1964 JEPPSSON & OLIN 1970 RITCHIE et coll 1973) For ethical reasons these methods may be used only in experimental animals but it would be of value to have a method which could be used both in man and in animals One effect of damage to vascular endothelia is altered permeability to various substances This can conveniently be evaluated in the kidney since urine is easily available If endogenous proteins are used to detect disturbances in permeability no substance which might be harmful or influence the results is given The present model has these advantages namely that it can be used both in man and animals it is easy to perform and no damage is caused except such as could be due to the contrast medium itself

Acknowledgements

This investigation was supported by grants from the Medical Faculty University of Lund the Swedish Medical Research Council (Project No 3483) Svenska AB Philips and CEA verken The expert technical assistance of Anita Burnett Birgitta Sparre and Gail Åkerman is gratefully acknowledged

SUMMARY

Nephroangiography in dogs with renal artery injections of Urografin 76° resulted in massive albuminuria Unilateral nephroangiography caused massive albuminuria only from the injected kidney Significantly less albuminuria was caused by renal artery injections of a corresponding volume of a sodium chloride solution of equal *osmolality or intravenous* injections of twice that volume of Urografin 76 ° Thus the hypertonicity of the contrast medium is not the main cause of the albuminuria The degree of albuminuria is related to the concentration of medium in the renal arteries and not to the amount excreted

ZUSAMMENFASSUNG

Die Nephroangiographie bei Hunden mit renalen arteriellen Injektionen von Urografin 76% führte zu einer massiven Albuminurie Die unilaterale Nephroangiographie verursachte nur bei der injizierten Niere eine massive Albuminurie Eine signifikant geringere Albuminurie wurde durch die renale arterielle Injektion eines entsprechenden Volumens einer NaCl Lösung gleicher Osmolalität oder der intravenösen Injektion eines doppelten Volumens von Urografin 76% verursacht Somit ist die Hypertonisität des Kontrastmittels nicht die hauptsächliche Ursache der Albuminurie Der Grad der Albuminurie ist zur Konzentration des Mittels in den renalen Arterien und nicht zur ausgeschiedenen Menge relatiert

RESUME

Une néphroangiographie chez des chiens comportant des injections d Urografin 76% dans l artère renale a donné une albuminurie massive La nephroangiographie unilaterale donne une albuminurie massive uniquement du rein injecté Les injections dans l artere rénale d un volume correspondant d une solution de chlorure de sodium de meme osmolarite ou l injection intraveineuse de deux fois ce volume d Urografin 76 causent une albuminurie nettement moins importante Ainsi l hypertonicite du moyen de contraste n est pas la cause principale de l albuminurie Le degré d albuminurie est relie a la concentration du moyen de contraste dans les arteres rénales et non à la quantité excrétée

REFERENCES

BROMAN T and OLSSON O The tolerance of cerebral vessels to a contrast medium of the diodrast group Acta radiol 30 (1948) 326

— — Experimental study of contrast media for cerebral angiography with reference to possible injurious effects on the cerebral blood vessels Acta radiol 31 (1949) 321

HARDWICKE J CAMERON J HARRISON J HULME B and SOOTHILL J Proteinuria studied by clearances of individual macromolecules *In* Proteins in normal and pathological urine p 111 Edited by Y Manuel J Revillard and H Bethel Karger Basel New York 1970

HARRINGTON G MICHIE C LYNCH P RUSSEL M and OPPENHEIMER M Blood brain barrier changes associated with unilateral cerebral angiography Invest Radiol 1 (1966) 431

HOLTÅS S ALMEN T and TEJLER L Proteinuria following nephroangiography II Influence of contrast medium and catheterization in dogs Acta radiol Diagnosis 19 (1978) 33

HOPPE J Some pharmacological aspects of radiopaque compounds Ann N Y Acad Sci 78 (1959) 727

JEPPSSON P and OLIN T Neurotoxicity of roentgen contrast media Study of blood brain barrier in the rabbit following selective injection of contrast media into the internal carotid artery Acta radiol Diagnosis 10 (1970) 17

MCCONNELL F and MERSEREAU W The effect of angiographic contrast media on arterial endothelium An experimental study J Canad Ass Radiol 15 (1964) 3

NYMAN U and ALMEN T Personal communication

RITCHIE W STEWART C and LYNCH P The effects of simulated phlebography on the venous endothelium A scanning electron microscopy study Invest Radiol 8 (1973) 279

STEINWALL O An improved technique for testing the effect of contrast media and other substances on the blood brain barrier Acta radiol 49 (1958) 281

TEJLER L ALMÉN T and HOLTÅS S (a) Proteinuria following nephroangiography I Clinical experiences Acta radiol Diagnosis 18 (1977) 634

— EKBERG M ALMÉN T and HOLTÅS S (b) Proteinuria following renal arteriography Report of two cases Acta med scand 202 (1977) 131

ZINNER G and GOTTLOB R Morphologic changes in vessel endothelia caused by contrast media Angiology 10 (1959) 207

FROM THE DEPARTMENTS OF CLINICAL PHYSIOLOGY AND DIAGNOSTIC RADIOLOGY
ODENSE UNIVERSITY HOSPITAL, DK 5000 ODENSE DENMARK

PULMONARY ABNORMALITIES IN MITRAL VALVE DISEASE

Comparison between pulmonary wedge pressure, regional pulmonary blood flow and chest films

L HESLET ANDERSEN and POUL ERIK ANDERSEN JR

Pulmonary congestion and edema occur in patients with left sided heart disease These complications are usually evaluated from the history the clinical findings and radiography of the chest Many of these patients are referred for right sided heart catheterization in order to evaluate the pressure in the pulmonary circulation

The regional perfusion varies with a gradual transition from congestion via interstitial to alveolar edema In patients with mitral valve disease the pulmonary wedge pressure (PWP) varies widely The PWP values have been shown to correlate with the distribution of regional pulmonary perfusion i e with a normal positive apico-basal perfusion gradient in low PWP values and reversal of the perfusion gradient with higher PWP values (BALL et coll 1962 SIMON 1963 STEINER 1964 ANDERSEN et coll 1976)

Several reports have elucidated the correlation between radiologic evaluation and hemodynamic parameters (MILNE 1963 FRIEDENBERG et coll 1966 TURNER et coll 1972) As the major determinant of the radiologic evaluation in these patients has proven to be the flow shift to the upper lobes (LOGUE et coll 1963 MILNE, SIMON) it was found suitable to correlate the radiologic perfusion distribution with

Submitted for publication 17 December 1976

the distribution measured by the ^{133}Xe technique in order to ascertain the value of chest films in evaluation of early left sided heart failure at a stage where no auscultatory findings exist (STAGE et coll 1976)

Material and Methods

The material includes 28 patients with mitral valve disease—stenosis or insufficiency or both The diagnosis was established by right and left sided heart catheterization using an exercise test together with left sided cardioangiography The heart catheterization regional perfusion distribution in the lungs determined by ^{133}Xe as well as the radiologic examination of the chest were carried out within a period of 2 days This examination sequence was used 31 times inasmuch as 3 patients were re examined following surgery of the mitral valve The investigation included 7 men and 21 women between the ages of 30 and 65 years average 51 years

Catheterization Right sided heart catheterization was carried out under local anesthesia with the patient in the supine position and the pulmonary wedge pressure was measured Catheterization of the left side was performed using the retrograde technique over the aortic valve following introduction of a pigtail catheter into the femoral artery

Radiology of the chest was carried out with the patient erect with p a projection and left lateral projection The films were exposed with 190 kV 10 to 16 mAs The patient was required to hold his breath after a deep inspiration The film focus distance was 3 m

In areas of the chest film in apical and basal zones corresponding to the position of scintillation detectors 1 and 4 (Fig 1) the pulmonary vascularity was evaluated The evaluation paid regard particularly to the vessels of the right lung whether they were normally distributed or increased or reduced in number basally and apically per unit area whether the vessels were dilated or constricted whether alveolar edema and pleural fluid were present and finally whether interstitial edema blurred the vessels

The following parameters were measured on the chest film The heart volume (normally 250–450 ml/m² body surface JONSELL 1939) and width of the main pulmonary artery (normally ≤ 1/4 of largest internal thorax diameter) The width of the right hilum was measured from the midline to the lateral border of the main pulmonary artery or its main descending branch (normally ≤ 5 5 cm)

The left atrium is considered enlarged when (1) the posterior outline of the heart bulges below the tracheal bifurcation leaving an empty epidiaphragmatic retrocardiac space (left lateral view) (2) a bulge exists below the left pulmonary artery in the p a view and (3) a double outline or a bulge is seen at the upper part of the right heart outline in the p a view

When the number and size of vessels apically and basally are equal the condition is classified as slightly pathologic caliber enlargement and increase in number of

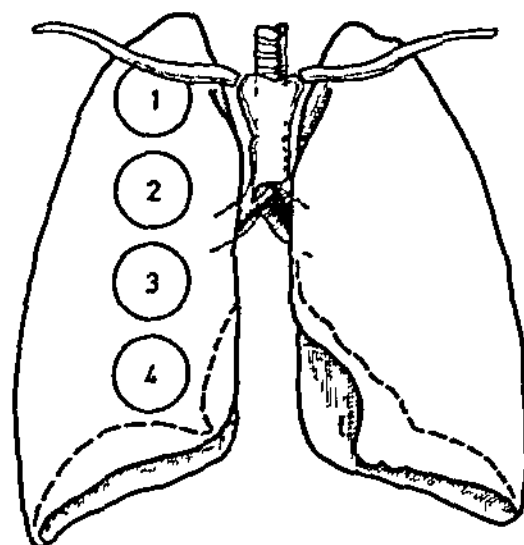


Fig 1 Positioning of external scintillation detectors vertically over posterior surface of right chest

vessels apically and diminution of vascularity of the lower zone is classified as moderately pathologic

In order to avoid any bias the evaluation of the chest films was carried out by one and the same radiologist (P E A) who had no knowledge of the hemodynamic parameters

^{133}*Xe technique* The regional perfusion distribution of the lungs was measured over the right posterior surface in the sitting position with 4 scintillation detectors positioned in a vertical row (Fig 1) The upper edge of the upper detector was on a level with a line joining the upper edge of the right scapula to the right clavicle during maximum inspiration The diameter of the detectors was 5 cm and the distance between the centre of the upper and lower detectors was 18 cm during all the tests While the patients held their breath at maximum inspiration 0 7 mCi of ^{133}Xe was injected into a left cubital vein The activity corresponding to each of the four detectors was measured and registered on a four channel recorder using a ratemeter having a time constant of 2 seconds (ANDERSEN et coll) The perfusion index (PI) was calculated from the regional activity measurements This is an expression of the relative magnitude of the regional flow in such a manner that a high PI indicates a large flow (ANDERSEN et coll)

The patients were divided into groups on the basis of the perfusion distribution and pulmonary wedge pressure in the following manner Basal perfusion (detector 4) Normal perfusion index. $PI > 1\,03$ slightly reduced $0\,92 \leq PI \leq 1\,03$ and moderately reduced $PI < 0\,92$ Apical perfusion (detector 1) Normal $PI < 0\,73$ slightly increased $0\,73 \leq PI < 0\,95$ moderately increased $PI > 0\,95$ PWP Normal < 15 mmHg, slightly increased $15 \leq PWP < 22$ mmHg moderately increased $PWP \geq 22$ mmHg.

Table 1

Measured pulmonary capillary venous pressures (PWP) related to 3 radiologically estimated grades

Radiologic estimation	Measured PWP values			
	Normal	Slightly increased	Moderately increased	Total
Normal	6	2	0	8
Slightly pathologic	4	3	1	8
Moderately pathologic	2	5	8	15
Total	12	10	9	31

$\chi^2 = 11\ 8$ $p = 0\ 002$

The statistical evaluation was performed by the χ^2 test A level of significance of $p < 0\ 05$ was employed

Results

The radiologic grouping and the measured PWP values ($p = 0\ 002$) agree well (Table 1)

Agreement between the radiologic evaluation and the measured perfusion distribution was found both between the estimated and measured values for the apical (Table 2 $p = 0\ 008$) and the basal perfusion (Table 3 $p = 0\ 05$) In 3 patients in whom the estimation indicated moderately increased apical perfusion and moderately increased PWP both the apical perfusion and the measured PWP were normal Two of these 3 patients had evident abnormalities in the chest films suggesting pulmonary fibrosis

The central hemodynamic parameters (Table 4) were related to the measured radio logic parameters Interlobular septae did not occur with a normal PWP but otherwise no significant relationship was observed

Table 2

Apical perfusion measured by ^{133}Xe related to radiologically estimated perfusion

Radiologic estimation	Measured by ^{133}Xe			
	Normal	Slightly increased	Moderately increased	Total
Normal	5	1	2	8
Slightly increased	0	4	0	4
Moderately increased	3	7	9	19
Total	8	12	11	31

$\chi^2 = 13\ 4$ $p = 0\ 008$

Table 3

Basal perfusion measured by ^{133}Xe related to radiologically estimated perfusion

Radiologic estimation	Measured by ^{133}Xe			
	Normal	Slightly reduced	Moderately reduced	Total
Normal	13	3	8	24
Slightly reduced	0	2	1	3
Moderately reduced	0	1	3	4
Total	13	6	12	31

$\chi^2 = 9.4$ $p = 0.05$

In order to test the discriminative ability of the measured radiologic parameters the patients were divided into groups on the basis of the pulmonary wedge pressure (PWP < 15 mmHg normal and PWP ≥ 15 mmHg pathologic). The ability of the following parameters to discriminate between normal and pathologic was tested. Volume of the heart ($p = 0.10$), enlargement of the left atrium ($p = 0.10$), dilatation of the main pulmonary artery ($p = 0.20$), size of the right hilar area ($p = 0.80$) and finally the presence of interlobular septae ($p = 0.03$).

Discussion

In the upright position and normal human lungs a linear flow gradient is found with hyperperfusion of the basal and hypoperfusion of the apical lung regions (BALL et coll., WEST 1963, ANDERSEN et coll.).

The perfusion resulting from gravity is reflected in the fact that the size and number of the dependent vessels are greater than in the upper zones in the chest film (SIMON, STEINER, CHEN et coll. 1968, ELLIOTT & SHIEBLER 1968, MOSS & ADAMS 1968).

Table 4

Relationship of hemodynamic and radiologic parameters

Radiologic parameters	Central hemodynamic parameters measured					
	PWP		Apical perfusion		Basal perfusion	
	Normal	Increased	Normal	Increased	Normal	Increased
Width of hilum increased	7	12	3	16	7	12
Width of main pulmonary artery increased	4	13	2	15	6	11
Heart volume increased	10	15	6	20	11	15
Enlargement of left atrium	6	16	3	19	7	15
Presence of interlobular septae	0	8	1	7	3	5
Total number of patients	12	19	8	23	13	18



a



b

Fig 2 Moderately altered distribution of pulmonary vessels PWP = 25 mmHg, basal PI < 0 92 and apical PI > 0 95 a) The apical vessels are dilated and increased in number in contrast to the basal vessels b) Wide interlobular septae are present in the basal part of the right lung

When the pressure in the left atrium and pulmonary veins rises the resistance of the basal vessels will increase this results in a greater apical flow at the expense of the basal flow (FRIEDMAN & BRAUNWALD 1966 ANDERSEN et coll) which is reflected in the chest films vessels reopen and increase in width in the upper lobe (LOGUE et coll MILNE SIMON STEINER)

An additional increase in pressure will result in interstitial edema (interlobular septae) an indistinct outline of the vessels of the lower lobes later in pleural fluid and finally in alveolar edema (LANG 1971 TURNER et coll MESZAROS 1973) (Fig 2)

Correlation of chest films and central hemodynamic measurements has been carried out from pre and postcapillary parameters (TURNER et coll) The PWP level is mainly evaluated from the flow distribution In the lower pressure range (PWP less than 25 mmHg) any rise in PWP will bring about a corresponding rise in mean pulmonary artery pressure (PA) (passive pulmonary hypertension) The increase in PA will exceed the increase in PWP (excessive pulmonary hypertension WALSTON et coll 1973) only when the PWP is greater than 25 mmHg

As all of the patients had a PWP$\leq$25 mmHg a distinction between pre and postcapillary radiologic parameters is of little value This is in agreement with the finding that it is not possible to distinguish between normal and pathologic central hemodynamics from the width of the trunk of the pulmonary artery

With higher pressure in the pulmonary circulation symptomatology and physiology agree whereas no symptoms occur with pressure in the lower part of the range (CHAIT et coll 1972) Further chest auscultation may be negative (STAGE et coll) As such an evaluation of the asymptomatic lung congestion is mainly based on the perfusion distribution in the lungs the perfusion distribution determined with ^{133}Xe was compared with that estimated radiologically A good agreement was found

Erroneous radiologic estimation of the central hemodynamic parameters may occur in mitral valve disease with perivascular fibrosis in the basal parts of the lungs without increase in PWP (OLSEN 1966) The resultant redistribution of the pulmonary blood flow takes place without any significant increase in pressure As the radiologic evaluation of the central pressure is based on perfusion distribution even moderate change of the blood vessels brings about over-estimation of the PWP pressure as was the case in 2 of the 3 patients

Conclusion When considered separately the measured radiologic parameters were found to be of minor significance whereas the presence of interlobular septae and changed perfusion distribution were found to be reliable for the estimation of the level of the PWP Thus chest films are suitable for the evaluation of early left sided heart failure at a stage where only the flow distribution is changed and thus no auscultatory findings are available from the lungs Erroneous evaluation of the PWP and perfusion occurred with abnormalities in the chest film suggesting fibrosis Estimation of the perfusion of the parenchyma in chest films should thus be carried out in patients with left sided heart disease

SUMMARY

Chest films right sided heart catheterization and measurement of the regional lung perfusion using ^{133}Xe were carried out 31 times on patients with mitral valve disease A relationship was found between the radiologic evaluation in 3 grades and the values of pulmonary wedge pressure and the apical and basal perfusion Changes in flow distribution as reflected in altered appearance of the vessels and the presence of interstitial edema were found to be the most sensitive factors in the evaluation of pulmonary wedge pressure Chest radiography was thus found suitable for the evaluation of pulmonary wedge pressure in mitral valve disease

ZUSAMMENFASSUNG

Lungfilme Katheterisierung des rechten Herzens und Messungen der regionalen Lung durchblutung unter Verwendung von ^{133}Xe wurde 31 mal bei Patienten mit Mitralis klappenfehler vorgenommen Eine Beziehung zwischen der radiologischen Beurteilung nach drei Graden und den Werten des PW Druckes und der apikalen und basalen Perfusion wurde festgestellt Die Veranderung in der Durchblutungsverteilung wie sie sich im veränderten Bild der Gefässe und dem Vorkommen von interstitiellem Ödem aussern wurden als die empfindlichsten Faktoren bei der Bewertung des PW Druckes festgestellt Die Rontgenuntersuchung der Lunge wurde deshalb als geeignet befunden den PW Druck bei der Mitralisklappenerkrankung festzustellen

RESUMÉ

Des radiographies thoraciques un cathétérisme du cœur droit une mesure de la perfusion pulmonaire régionale au moyen du ^{133}Xe ont éte faits 31 fois sur des malades atteints de maladie de la valve mitrale Les auteurs ont trouvé une relation entre l évaluation radiologique en 3 degrés et les valeurs de la pression pulmonaire bloquee et la perfusion apicale et basale Les modifications de la distribution de la circulation traduites par une alteration de l aspect des vaisseaux et par la présence d œdeme interstitiel se sont révélees etre les facteurs les plus sensibles dans l évaluation de la pression pulmonaire bloquée La radiographie thoracique a donc eté trouvee utile pour l evaluation de la pression pulmonaire bloquee dans la maladie de la valve mitrale

REFERENCES

ANDERSEN L H JOHANSEN J K and HYLDEBRANDT N Regional pulmonary blood flow in mitral disease studied by Xenon radiospirometry Brit Heart J 38 (1976) 573

BALL JR W C STEWART P B NEWHAM L G S and BATES D V Regional pulmonary function studied with ^{133}Xenon J clin Invest 41 (1962) 519

CHAIT A COHEN H E MELTZER L E and VAN DURM J P The bedside chest radiograph in the evaluation of incipient heart failure Radiology 105 (1972) 563

CHEN J T T BEHAR V S MORRIS J J MCINTOSH H D and LESTER R. G *Correlation* of roentgen findings with hemodynamic data in pure mitral stenosis Amer J Roentgenol 102 (1968) 280

ELLIOTT L. P and SHIEBLER G L X Ray diagnosis of congenital cardiac disease p 3 Charles C Thomas Publisher Springfield Illinois 1968

FRIEDENBERG M J TEMPLETON A W and PARKER B M Correlation of pulmonary artery diameter and pressure in mitral valve disease Acta radiol Diagnosis 4 (1966) 33
FRIEDMAN W F and BRAUNWALD E Alterations in regional pulmonary blood flow in mitral valve disease studied by radioisotope scanning A simple nontraumatic technique for estimation of left atrial pressure Circulation 34 (1966) 363
JONSELL S A method for determination of the heart size by teleroentgenography (a heart volume index) Acta radiol 20 (1939) 325
LANG E K Roentgenographic changes reflecting the hemodynamics of the pulmonary vascular bed J La med Soc 123 (1971) 68
LOGUE R B ROGERS J V and GAY B B Subtle roentgenographic signs of left heart failure Amer Heart J 65 (1963) 464
MESZAROS W T Lung changes in left heart failure Circulation 47 (1973) 859
MILNE E N C Physiological interpretation of the plain radiograph in mitral stenosis including a review of criteria for the radiological estimation of pulmonary arterial and venous pressure Brit J Radiol 36 (1963) 902
MOSS A J and ADAMS F H Heart disease in infants children and adolescents p 103 Williams & Wilkins Company Baltimore 1968
OLSEN E G J Perivascular fibrosis in lungs in mitral valve disease Brit J Dis Chest 60 (1966) 129
SIMON M The pulmonary vessels Their hemodynamic evaluation using routine radiographs Radiol Clin N Amer 1 (1963) 363
STAGE P MOVILD B HESSE B and STEINMETZ E Pulmonary congestion in chronic heart disease Radiologic clinical and hemodynamic relationships Acta radiol Diagnosis 17 (1976) 417
STEINER R E Radiology of pulmonary circulation—Chamberlain Lecture 1963 Amer J Roentgenol 91 (1964) 249
TURNER F LAU F Y K and JACOBSON G A method for the estimation of pulmonary venous and arterial pressures from the routine chest roentgenogram Amer J Roentgenol 116 (1972) 97
WALSTON A PETER R H MORRIS J J KONG Y and BEHAR V S Clinical implications of pulmonary hypertension in mitral stenosis Amer J Cardiol 32 (1973) 650
WEST J B Distribution of gas and blood in the normal lungs Brit med Bull 19 (1963) 53

FROM THE DEPARTMENTS OF SURGERY AND RADIOLOGY SINT LUCAS ZIEKENHUIS AMSTERDAM THE NETHERLANDS

COMPUTER TOMOGRAPHY IN ACUTE PANCREATITIS

R M J M BUTZELAAR G L MULDER W J KUHLER
P D M F BUYINK and G DAVIES

Since general purpose scanners were introduced for clinical use several reports on CT scanning for detection of pancreatitic disease have appeared (HAAGA et coll 1976 STANLEY et coll 1976 SHEEDY et coll 1976)

Although selective pancreatic angiography isotopic and ultrasonic imaging and endoscopic retrograde pancreatography have been introduced during the last 25 years the diagnosis of pancreatic disease remains difficult

CT scanning depicts the entire pancreas and its anatomic surrounding without technically difficult procedures and without any risk to the patient Early enthusiasm about the possibility of detecting pancreatic malignancy with CT scanning has been followed by descriptions of failures of this technique (STEPHENS 1976) Unlike ultrasound which reveals changes in pancreatic structures due to alterations in their echoes CT scanning is based on changes in attenuation and shape As yet no contrast medium will satisfactorily enhance pancreatic tumours selectively and thus only comparatively large tumours can be accurately diagnosed

The value of the CT scan for the diagnosis of acute pancreatitis and its complications has scarcely been discussed

Material and Methods

The scans were performed with an EMI CT 5005 Whole Body scanner using a 320 × 320 matrix with a scan speed of 20 seconds and a scan width of 13 mm Scans

Submitted for publication 26 August 1977

Table 1

Results of CT scanning in 15 patients with acute pancreatitis

Case No	Enlargement	Irregular outline	Cysts
1	+ +	+	−
2	+	−	+
3	+	+	+
4	+ +	+	+
5	+ +	−	+ +
6	+ +	−	+ +
7	+	−	+
8	+ +	+	−
9	+	+	−
10	+ +	+	+ +
11	+	−	+
12	+ +	+	+ +
13	+	−	−
14	+ +	−	+
15	+	+	+
Total	15	11	11

were made in the supine and lateral decubitus positions with or without the administration of contrast medium (diluted oral gastrografin)

All patients admitted to the surgical unit of this hospital with a possible acute pancreatitis were examined by CT scanning This preliminary report covers the first 15 patients A review of the results of the scanning is given in the Table Three illustrative cases are reported

Case reports

Case 4 A 37 year-old man was admitted because of severe upper abdominal pain and vomiting. He had no history of ulcer or signs of cholelithiasis The patient was known to be a heavy drinker Epigastric palpation was painful but no signs of peritonitis were found Laboratory investigations were normal except serum amyla e 128 E (normal <64 E) and urine amylase 4 098 (normal <128 E)

A diagnosis of alcohol induced acute pancreatitis warranted conservative treatment Two days after admission a CT-scan demonstrated an enlarged irregular pancreas (Fig. 1 a) 18 days later the pancreas was still enlarged though some regression of the abnormalityies was evident (Fig 1 b)

Case 5 A 25 year-old woman underwent laparotomy because of a right upper abdominal mass and jaundice At operation a large choledochal cyst was found and a Roux-en Y choledochojejunostomy was performed The patient remained well for 5 years but was then admitted with signs of acute pancreatitis After the acute episode had subsided ERCP revealed considerable abnormalities of the bile duct system One year later the patient

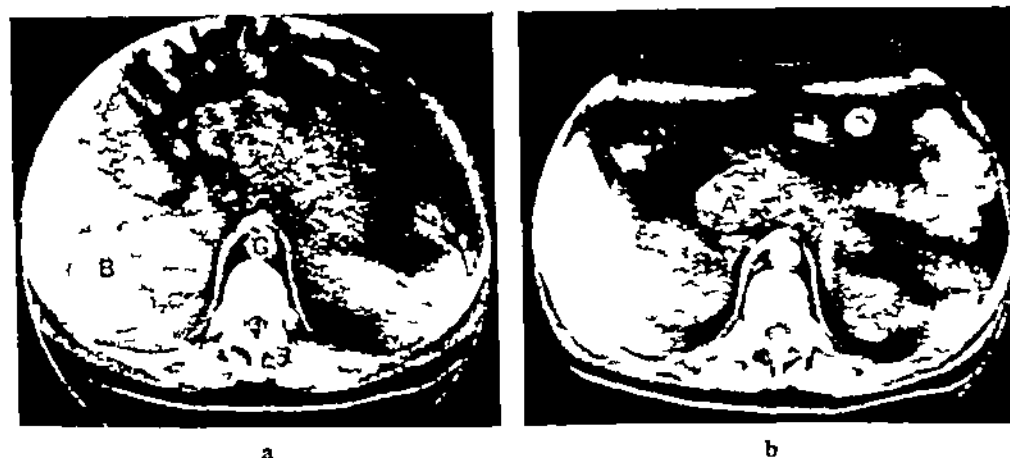


Fig 1 Case 4 a) Enlarged pancreas with irregular contours (A) Liver (B) Aorta (C) Window level 32 Window width 200 b) 18 days after admission Still slightly enlarged pancreas Level 34 Width 100

presented with similar upper abdominal pain Amylase in blood and urine were normal Liver function tests were slightly abnormal

Because of the risks of endoscopic cannulation a CT scan was performed A large irregular pancreas and multiple cysts especially in the tail were demonstrated Air was observed in the intrahepatic bile ducts (Fig 2 a) After a short period of clinical observation the patient was discharged The CT scan 7 weeks later demonstrated an almost normal pancreas The cysts had completely disappeared (Fig 2 b)

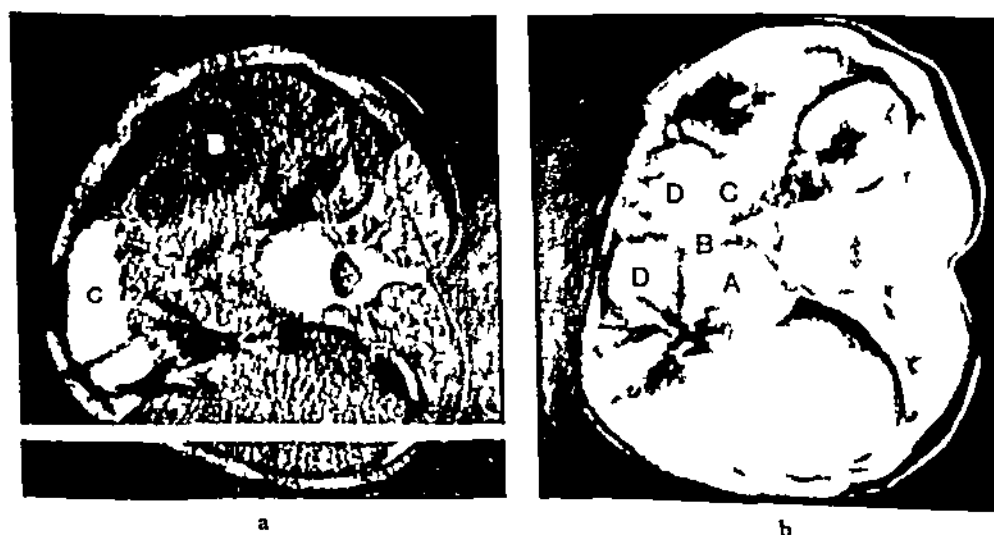


Fig 2 Case 5 a) Pancreas (A) Tail of pancreas with cysts (B) Contrast medium (C) Fat layer (F) Level 36 Width 100 b) Head of pancreas (A) Body of pancreas (B) Tail of pancreas (C) Contrast medium in duodenum (D) Level 34 Width 200 The cysts have disappeared

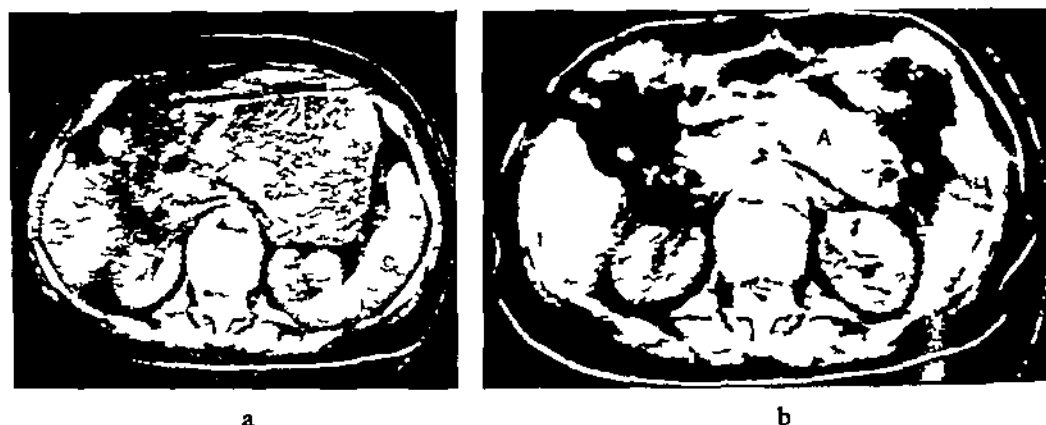


Fig 3 Case 6 a) Pancreatic cyst (A) Kidney (B) Spleen (C) Air fluid level is indicated by the arrow Level 26 Width 100 b) Only remnants of the cyst remain Level 34 Width 200

Case 6 A previously healthy 62 year old woman was admitted with a 6 week history of upper abdominal pain Physical examination revealed a large tender tumour under the right costal margin without signs of peritonitis Laboratory investigations ESR 80 mm after one hour leukocytes 16 4 10 /l alkalic phosphatase 15 8 BE (normal 1 2–3 0 BE) SGPT 34 E (normal 3–20 U/l) serum amylase 64 E (normal < 64 E) urine amylase 4 096 E (normal < 128 E)

A diagnosis of acute cholecystitis with pancreatitis was made Conservative treatment was begun After one week the amylase in blood and urine were normal At CT scan one week after admission a large pseudocyst of the pancreas was found Four weeks after admission the condition of the patient deteriorated A second CT scan demonstrated a pancreatic abscess with an air fluid level (Fig 3 a) which was drained At a second operation a cystogastrostomy was made Postoperatively the condition of the patient improved and on the postoperative CT scan only slight remnants of the pancreatic pseudocyst were observed (Fig 3 b) The follow up was uneventful

Discussion

Acute pancreatitis is a clinical diagnosis It is typically accompanied by elevated levels of amylase in serum and urine Differentiation from acute cholecystitis peptic ulcer perforation mesenteric artery occlusion or ruptured aortic aneurysm is difficult Moreover these conditions may also have elevated serum amylase (IMRIE 1974) On the other hand TRAPNELL (1972) stated that the serum amylase may be normal in acute pancreatitis (5% of 590 cases) and that another 5 per cent of the cases had no abdominal pain For these reasons it is believed that CT scanning should play an important part in the diagnosis and management of acute pancreatitis Even a serious condition of the patient is no contraindication for scanning

In the present series the pancreas has been moderately to greatly enlarged either generally or focally (Table) In most cases the outline of the organ was irregular and

difficult to distinguish from surrounding structures as the fat around the organ is edematous decreasing the attenuation differences the attenuation of the pancreas becomes irregular Small cystic areas may appear These abnormalities may be completely reversible

One of the local complications following acute pancreatitis is a pseudocyst (10 7 % IMRIE 3 % TRAPNELL) with or without abscess formation (2 1 % IMRIE 5 % TRAPNELL) The onset of both abscess and pseudocyst formation may be insidious making the diagnosis extremely difficult With CT scanning these two conditions may be clearly distinguished (Case 6)

CT scanning seems to offer the following advantages in acute pancreatitis (1) An accurate specific diagnosis excluding other conditions (2) complications may be easily detected (3) with time CT findings can be correlated with prognosis the value of different medical treatments assessed and the time for surgical intervention decided

SUMMARY

Acute pancreatitis is a disease with high mortality and morbidity CT scanning, preferably combined with ultrasound allows accurate diagnosis and early detection of complications

ZUSAMMENFASSUNG

Die akute Pancreatitis ist eine Erkrankung mit hoher Mortalitat und Morbiditat CT scanning vorzugsweise kombiniert mit Ultraschall ermoglicht die genaue Diagnose und die fruhzeitige Aufdeckung von Komplikationen

RÉSUME

La pancreatite aigue est une affection qui comporte une haute morbidité et une haute mortalité La tomométrie de préference associée a l echotomographie permet un diagnostic precis et une détection précoce des complications

REFERENCES

HAAGA J R ALFIDI J J ZELCH M G MEANY T F BOLLER M GONZALEZ L and JELDEN G L Computed tomography of the pancreas Radiology 120 (1976) 589

IMRIE C W Observations on acute pancreatitis Brit J Surg 61 (1974) 539

SHEEDY P F STEPHENS D H HATTERY R R MUHM J R and HARTMAN G W Computed tomography of the body Initial clinical trial with an EMI prototype Amer J Roentgenol 127 (1976) 23

STANLEY R J STUART S S and LEVITT R G Computed tomography of the body Early trends in application and accuracy of the method Amer J Roentgenol 127 (1976) 53

STEPHENS D H SHEEDY P F HATTERY R R and HARTMAN G W Initial clinical experience with computerized tomography of the body Radiol Clin N Amer 14 (1976) 149

TRAPNELL J E The natural history and management of acute pancreatitis Clin Gastroenterol 1 (1972) 147

— and DUNCAN E H L Patterns of incidence in acute pancreatitis Brit med J 2 (1975) 179

FROM THE DEPARTMENTS OF PAEDIATRIC SURGERY SURGERY AND DIAGNOSTIC RADIOLOGY UNIVERSITY HOSPITAL S 221 85 LUND AND THE DEPARTMENT OF ANATOMY UNIVERSITY OF LUND S 223 62 LUND SWEDEN

ROENTGEN STEREOPHOTOGRAMMETRY FOR EVALUATION OF LIVER VOLUME AND SHAPE

G CLAESSON P FREDLUND A MUHLOW and G SELVIK

Changes in liver volume and shape may occur in several conditions both as a result of physiologic variations and following diseases affecting the liver In particular liver tumours often present with hepatomegaly In recent years several methods have been introduced in the treatment of primary and secondary liver tumours A surgical approach is often made in order to remove the tumour if possible When radical resection cannot be performed alternative treatment may include dearterialization regional cytostatic infusions or systemic treatment with oncolytic drugs Simple and exact methods to estimate the effect of the treatment is today lacking Palpation liver scintigraphy and ultrasound may give a fairly crude measure of the liver volume The feasibility of whole body computer tomography newly introduced for determining liver volume has not yet been investigated Angiography is a complicated investigation with certain risks and cannot be frequently repeated

Roentgen stereophotogrammetry was used by HAGBERG (1961) in experiments on variations in liver volumes in dogs A modified method including computer technique for the complex calculations has been developed to facilitate clinical use As a prerequisite for clinical evaluation of tumour growth some technical and biologic implications of the method have been investigated Both model experiments and tests on 2 patients were performed

Submitted for publication 14 September 1977

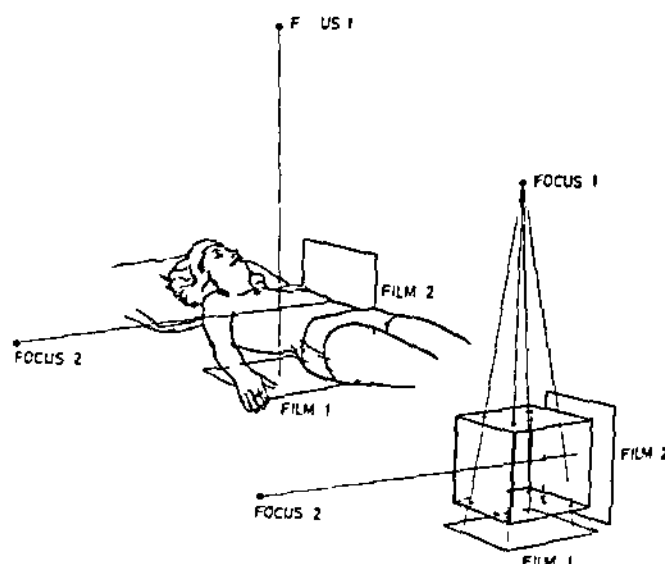


Fig 1 Top view Patient examination Bottom view Recording of calibration cage The calibration markers are only indicated on the plates for focus 1 The central areas of the cage sheltered by lead sheets Tubes and films have the same position in the 2 steps

Methods

Roentgen stereophotogrammetry as developed by SELVIK (1974) has been utilized The method presupposes that measurement points are attached to the object As such tantalum balls 0 8 mm in diameter, have been used In the model experiments they were fixed with tape in the 2 patients the balls were introduced at laparotomy under the liver capsule by means of a needle About 15 balls were attached to each object but sometimes due to technical factors all indicators were not visible on the films Only variations in shape and size of geometric objects defined by these markers can be evaluated with the present method

The objective with the roentgen stereophotogrammetric method is to determine the marker positions in a three dimensional laboratory coordinate system The markers are simultaneously exposed from 2 roentgen tubes on one or two films On the same film(s) are indicators in a calibration cage exposed before or after the recording of the object The calibration indicators are exposed on two narrow strips of the film leaving ample space free for the object After the two dimensional positions of the object and calibration marker images have been measured in a coordinatograph the known calibration marker coordinates enable a calculation of the position of the film(s) and tube foci Thus the beams from the two foci are reconstructed and object coordinates are determined by crossing of corresponding rays By using a television camera coupled to the coordinatograph and focussing the measurement points in a monitor even films with very poor definition and contrast can be successfully evaluated

For a detailed account of the method see SELVIK (1974) Only 2 aspects will be further emphasized The object can be double-exposed on one film or two The first procedure which was utilized for the model experiments and the earliest patient

recordings has a drawback when examining the liver As the 2 images have to be projected free from each other the beams must pass obliquely through the trunk which requires a large size film and leads to a heavy secondary radiation Therefore when later a set up became available using 2 film changers 35 cm × 35 cm positioned at right angles the recording was greatly facilitated (Fig 1) The problem now was one of identification To identify the indicators on the a p film has proved easy as the indicators have remained in stable positions but to find the corresponding indicator on the lateral films necessary for a correct coupling in the stereo model may be difficult It has been solved by computing the distances for a given ray in the a p exposure to all the rays in the lateral beam and normally selecting the ray with the shortest distance as the correct one

The reconstruction of the object coordinates is very accurate The mean three dimensional error is of the magnitude of 0 05 mm It is also highly automatized and requires little time and costs when the computer programs are available

Volume calculation The further analysis of the stereo model can proceed differently HAGBERG marking the dog liver with 7 indicators refrained from computing the volume of the decahedron defined by the indicators Instead he calculated the center of gravity of the decahedron and the root mean square distance R from this point to the object markers This mean distance R was raised to the third power to provide a measure of the volume which in the case of isotropic dilatation would vary exactly as the real liver volume This volume has also been computed in the present experiments and has been denoted by V_1 Thus

$$V_1 = \frac{4\pi}{3} R^3$$

with the scale factor $4\pi/3$ (not used by HAGBERG) to give the volume of a sphere

For several bodies this measure of volume might be misleading e g for bodies with extension mainly in one or two dimensions An exact calculation of the volume of a polyhedron defined by the indicators is to prefer even when only recording variations of volume In the case of points which define a convex polyhedron the polyhedron is uniquely determined and its volume can be calculated by dividing it into tetrahedrons from a reference point P inside the body In more complex cases a body with the given points on the surface can be constructed in the following way Project the points onto a sphere centered at the center of gravity of the indicators Construct the lines connecting the edges of the now uniquely defined convex polyhedron Project back these lines to the original points and calculate the polyhedron volume from tetrahedrons formed by the center of gravity P and the triangles formed by the lines just defined This volume is denoted by V_2 in the model experiments and is the one presented in the patient examinations

The projection of the indicators and the connecting lines calculated on the frontal

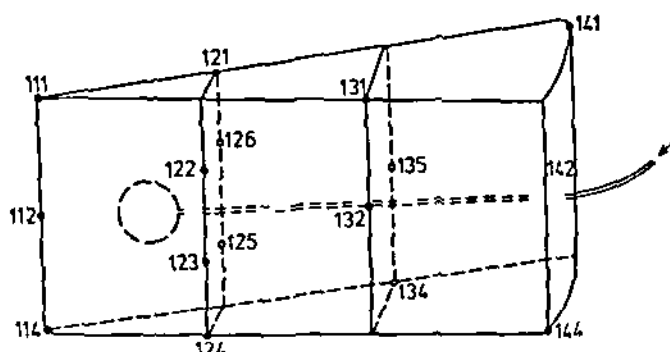


Fig 2 Phantom liver with a Foley catheter Sixteen indicators on the surface are denoted with the same numbers as in Fig 4

and sagittal planes are drawn by computer to demonstrate the stereo model By excluding some points from the calculations partial volumes might be obtained which can be of value for localizing an expansivity

Another measure of size changes are variations in distances between indicators Both the variation of the mean distance between all indicators and the variation between each pair of indicators were computed the latter with the view to disclose a localized expansivity

Model experiments

Two model experiments were performed The first one intended to test the volume calculations for a roughly spherical object a situation in which the 2 kinds of volume measures V_1 and V should be comparable A thin balloon of rubber was indicated with 12 markers approximately covering the surface The balloon was then connected with a syringe and filled with water in 8 steps from 400 to 1 500 cm³ at each of which a stereo film was exposed with the balloon lying on a table

In the second experiment the intention was to analyse the applicability of the method to disclose a small increment of a large volume A piece of foamed plastic was formed into the shape of a liver It was filled with gelatine to make it incompressible and simulating the consistency of a liver Inside the liver model near one of its edges the balloon of a Foley catheter was placed Sixteen indicators marked the surface of the model (Fig 2) Stereo films were exposed with empty Foley balloon and with 5 fillings from 20 to 100 cm³ The total volume of the model with empty balloon was 2 190 cm³ as determined by immersing it in water Besides the total volumes for the stereo models partial volumes and distances between pairs of indicators were computed

Clinical tests

Two patients were supplied with 15 tantalum balls under the liver capsule and surrounding the liver parenchyma except for the distal part of the left lobe in Case 1 This was a 55 year old female with a carcinoid syndrome Multiple liver metastases were found at right sided hemicolectomy At a second operation a temporary de

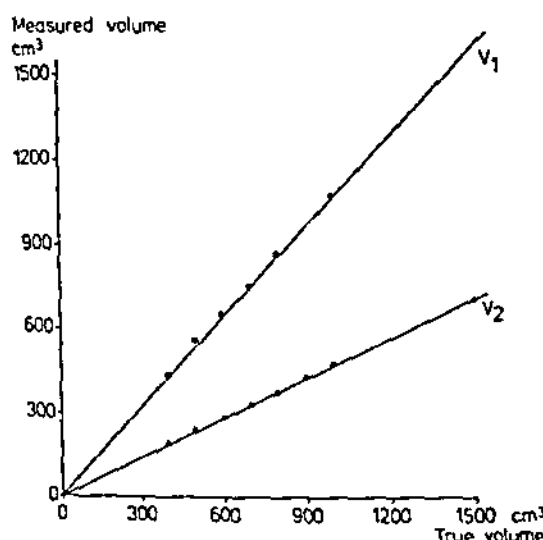


Fig 3 The sphere volume V_1 (●) and polyhedron volume V_2 (▲) in relation to the volume filled in a balloon

arterialization was performed and the tantalum indicators introduced A substantial reduction in tumour size was demonstrated at post operative angiography Three years later the patient is still free of symptoms although a slight progress of tumour size has been noted at recent angiography Stereophotogrammetric investigation started 9 months after the marking

The patient gave her consent to a test of the variation of the volume with stage of breathing and body position She was examined first supine in maximum expiration and then in maximum inspiration and then prone in expiration and inspiration The whole procedure was once repeated resulting in totally 8 stereo films

The other patient a 60 year old female had a colon carcinoma with liver metastases A hemicolectomy was performed She was followed for 84 days with the investigation starting almost a year after a resection of the right liver lobe During the investigation she had a recurrence confirmed by liver angiography and biopsy She died 5 months after the last examination

Except when stated in the respiration test the intention has been to make all exposures at the end of expiration The reason for this consistent with common practice except at lung examinations is that expiration is considered to be the more reproducible phase HAGBERG s test on dogs were also made at expiration

Re evaluations of 7 stereo pairs of Case I were performed to test the precision of the method

Results

First model experiment The variation of the measured volumes V_1 and V_2 with the true volume filled in the balloon is presented in Fig 3 A good linear correlation was obtained

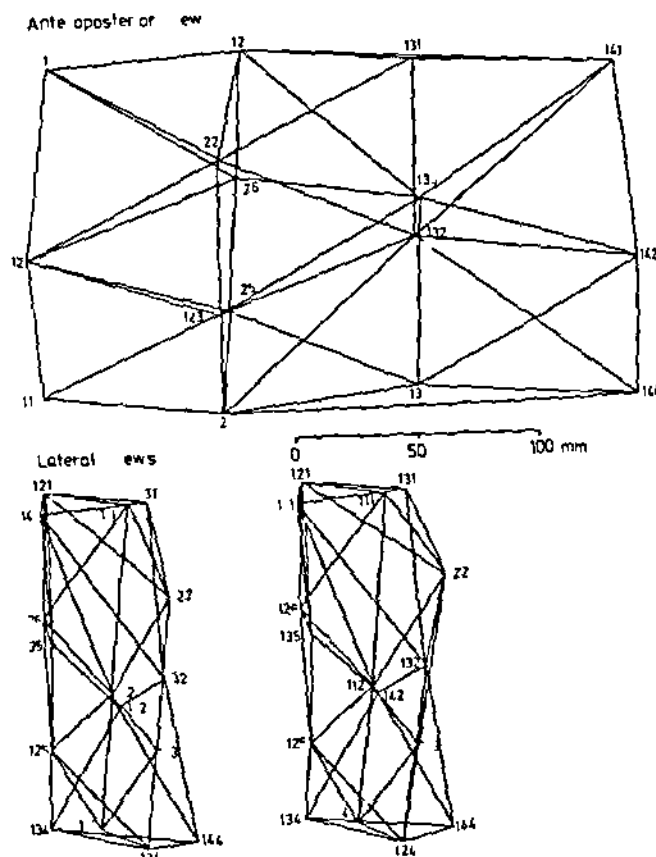


Fig 4 Computer drawings representing the liver model with a small balloon (cf Fig 2) The polyhedron defined by the markers 111–144 is drawn and its volume and area are given The two bottom views show the model with the balloon unfilled in the right lateral view the balloon is filled with 100 cm³ Increase of the distance 122–126 corresponding to the site of the balloon

Second model experiment The volumes V_1 and V_2 with empty balloon were 3 864 and 951 cm³ respectively Filling the balloon the calculated volumes (in cm³) increased as follows

Volume added	20	40	60	80	100
Volume V_1 increase	8	33	50	69	75
Volume V_2 increase	17	29	43	55	62

Photogrammetric imprecision did not invalidate the calculated volumes as shown in precision tests accounted for under the clinical tests

Calculating partial volumes it was found that in the part of the phantom liver where the Foley balloon was located part 111 to 126 (Fig 2) the increase of volume was significantly higher ($p<0\,001$) than in the rest In the part opposed to the Foley balloon part 131 to 144 the volume increase was significantly lower ($p<0\,001$) than in the rest

Analysing distance variations between pairs of indicators it was found that the greatest increase for the 100 cm³ filling was 9 mm, obtained for the distance 122 to 126 This is demonstrated in the lateral views of the stereo model (Fig 4) which show the empty and 100 cm³ filled stages

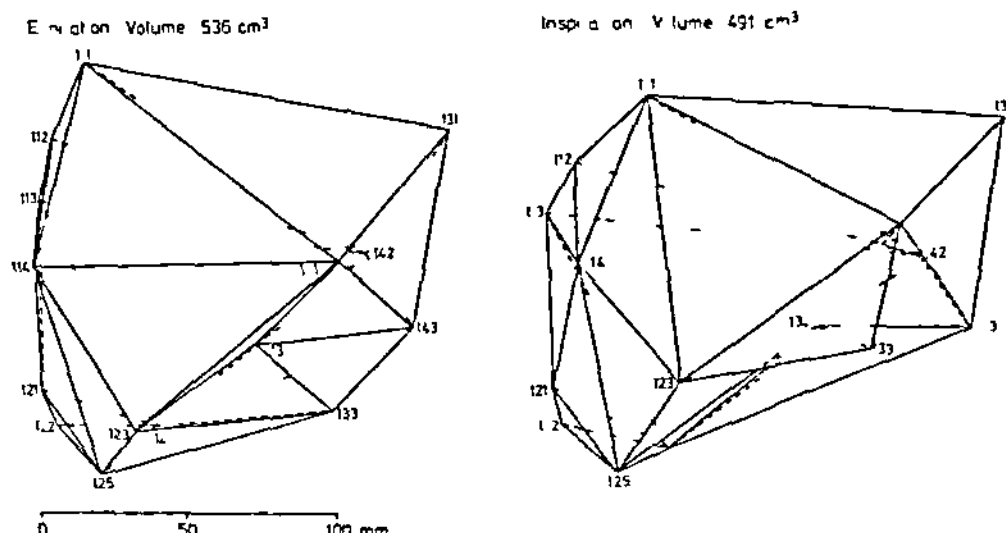


Fig 5 The orthogonal projections of the liver markers in Case 1 on the frontal plane The connecting lines between the edges of the polyhedron that are not seen in the a p view are indicated by broken lines Supine examinations at expiration and inspiration on the same day are presented The right liver contour is seen bent at inspiration

Clinical tests In the first 2 films of Case 1 only 11 indicators could be observed due to the rather unsuitable technique then used Comparing the volume with 11 and 15 indicators respectively for 2 stereo models obtained at the third occasion a factor of 1 33 was found which was used to adjust the first 2 volumes to those for 15 indicators

The following series was then obtained with all but the first 2 volumes calculated from 15 indicators

Day	0	84	252	587	712	746	803
Volume V_2 (cm³)	477	449	483	480	518	536	489

At the respiration tests performed on day 746 the reduction of volume from expiration stage to inspiration was 7 9 and 8 4 per cent for the supine position and 7 7 and 9 2 per cent for the prone position respectively in each test The mean reduction from supine to prone (mean of four volume determinations in each position) was 8 6 per cent The highest volume 536 cm³ common with the longitudinal series certainly represents a deep expiration It is presented together with an inspiration recording in Fig 5

Besides the polyhedron volumes V_2 the sphere volumes V_1 were calculated The latter did not generally vary in accordance with the polyhedron volumes nor did they show any clear variation in the respiration tests In the longitudinal series no net increase in volume V_1 was recorded

The calculation of differences of distances between indicator pairs revealed that the distance of 140 mm laterally between the upper diaphragmal and the visceral surface (indicators 111–125 Fig 5) decreased 12 mm from expiration to inspiration The distance between two indicators (125–143) on the visceral surface increased 7 mm in the same test From day 252 when the first complete examination was obtained to day 803 the mean length between all indicator pairs increased 1 1 mm with variations between separate pairs from −4 to 7 mm

Case 2 was only examined twice 84 days apart For the same reason as in Case 1 only 11 indicators could be observed The polyhedron volume V_2 increased from 390 to 450 cm³ and the sphere volume V_1 by 102 cm³ (6 9%)

The standard deviation of polyhedron volume computed from seven double evaluations of films from Case 1 was 0 4 cm³ i e 0 08 per cent of the volume The sphere volume and the polyhedron area showed standard deviations of 0 06 and 0 04 per cent respectively

Repeated examinations of Case 1 on several occasions allowed for a determination of the variation of volume at a certain occasion with 7 degrees of freedom Only supine investigations with the same intended stage of breathing were included The percentage standard deviation of volume thus found was 2 0 per cent

Discussion

First model experiment Only 2 indicators if on the opposite ends of a diameter would be needed to give the correct volume of a marked sphere when the volume is calculated according to HAGBERG In the present case the 12 balloon indicators are rather arbitrarily placed and the balloon is flattened due to gravity However the mean radius inserted into the formula for a sphere s volume i e volume measure V_1 gave a good estimate of the real volume while the exact polyhedron volume V only measured half of the balloon volume Increasing the number of indicators the polyhedron volume is expected to increase but the sphere volume calculated from a mean radius might be constant or change in any direction

Second model experiment In the case of the oblong liver phantom the sphere volume V_1 exaggerates the true volume with about the double An exaggeration is to be expected for flat or elongated bodies as the squares of the radii are used for calculating their mean The polyhedron volume V_2 was with 16 indicators used again about half of the true volume

The filling of the Foley balloon representing a localized expansivity was clearly demonstrated though the incremental fillings were only one per cent of the total volume Both volume measures V_1 and V_2 seem equally good in disclosing the increase of volume That no exact linear correlation was found should be of less concern as it would not be necessary for drawing clinical conclusions

In order to localize the expansivity calculations of partial volumes and distances between indicator pairs were of value

Clinical tests The highest volume in the longitudinal series of Case 1 was found at the respiration test Comparing the shape in Fig 5 with those obtained at the other occasions it can be concluded that intended expirations more resemble the inspiration recording The importance of standardizing the stage of breathing in the examinations is evident from the tests A hypothesis of liver volume increase in the longitudinal series cannot be confirmed as the examinations have not been sufficiently standardized

The variations of volume with stage of breathing may be explained as the composite effect in expiration of facilitated blood filling when diaphragmal pressure is diminished and restrained blood outflow due to the higher intrathoracic pressure The variation from supine to prone might be explained by squeezing of blood out of the liver due to pressure on it

Between the different stages of breathing a more complex deformation of the liver than isotropic volume variation has occurred as evident from the presented distance changes This probably is the reason why the HAGBERG measure of volume did not give consistent results in the respiration examinations

The variations of distances between indicator pairs were smaller in the longitudinal series than between different stages of breathing on one occasion Thus no progressive movements of the markers were found which would indicate that no expansion has occurred and also that the implantation can be done at stable sites

The increase of polyhedron volume during the 84 days in Case 2 does not permit a conclusion of tumour growth but combined with the increase in sphere volume this is made plausible

No other photogrammetric errors of importance are met with when comparing different examinations than those accounted for in precision tests (SELVIK) Thus the results of the precision test justify omitting such errors from discussions of volume variations

Clinical implications The tantalum indicators are easy to place under the liver capsule at laparotomy but can also be inserted with a long needle at laparoscopy or even percutaneously e g in connection with angiography

Changes in liver volume are known to occur after liver resection the remaining part of the liver regenerating in some months This process has mainly been followed in experimental animals but can now be closely followed in man with the new technique The method can be used not only for marking of livers with known tumours but also after surgery in the abdominal region when the risk for liver metastases is supposed to be high as in gastric and colonic malignant tumours To take full advantage of the high technical reliability of the method biologic variations as those depending on the stage of breathing must be carefully controlled

SUMMARY

Model experiments and tests on 2 patients were performed to probe the feasibility of roentgen stereophotogrammetry for evaluating variations in shape and volume of the liver The surface of the object was marked with indicators and the three-dimensional marker coordinates were determined The model experiments demonstrate a good correlation between true volume and the volumes defined by the indicators and also demonstrate the possibility of localizing an expansivity The variability of the volume of a polyhedron defined by 15 liver indicators with stage of breathing is discussed

ZUSAMMENFASSUNG

Modellexperimente und Versuche an 2 Patienten wurden vorgenommen um die Anwendbarkeit von Rontgenstereophotogrammetrie zur Feststellung von Veranderungen in der Form und dem Volumen der Leber festzustellen Die Oberflache des Objektes war mit Indikatoren versehen worden und es wurden drei dimensionale Coordinaten Markierungen verwendet Die Modellexperimente wiesen eine gute Korrelation zwischen dem echten Volumen und dem Volumen angegeben durch die Indikatoren auf und wiesen ebenfalls die Moglichkeit der Lokalisation einer Expansivitat nach Es wird die Variabilitat des Volumens eines vielseitigen Korpers definiert durch 15 Leber Indikatoren mit dem Stadium der Atmung diskutiert

RESUME

Des etudes sur modèles et des essais sur 2 malades ont éte effectues pour prouver la possibilite de la stereophotogrammetrie radiologique pour évaluer les variations de forme et de volume du foie La surface de l objet a ete marquee par des indicateurs et les coordonnees tridimensionnelles des marqueurs ont éte determinees Les experiences sur modele sont en bonne correlation avec le vrai volume et le volume defini par les indicateurs et montrent aussi la possibilite de localiser une lesion expansive La variabilite du volume d un polyedre defini par 15 indicateurs hepatiques aux differents stades de la respiration est étudiée

REFERENCES

HAGBERG S Roentgen stereophotogrammetry in studies of liver volume variations in the dog under the effect of haemorrhagic shock and hypothermia. Acta chir scand (1961) Suppl No 279

SELVIK G A roentgen stereophotogrammetric method for the study of the kinematics of the skeletal system Thesis Lund 1974

FROM THE DEPARTMENT OF RADIOLOGY VANDERBILT UNIVERSITY HOSPITAL NASHVILLE
TENNESSEE 37232 U S A

ROENTGENOLOGIC APPEARANCE OF FIBROMUSCULAR DYSPLASIA

L EKELUND J GERLOCK J MOLIN and C SMITH

Fibromuscular dysplasia of the renal arteries is a well recognized cause of reno vascular hypertension Many reports have appeared dealing with this entity but only a few with large series (PALUBINSKAS et coll 1966—70 cases KINCAID et coll 1968—125 cases GILL & MEANEY 1969—203 cases FOSTER et coll 1969—56 cases) Certain characteristic angiographic appearances indicating fibromuscular disease of the renal arteries were early stressed (PALUBINSKAS & WYLIE 1961) and it is commonly agreed that the angiographic abnormalities in a typical case are pathognomonic In spite of the many reported cases only a few authors have taken interest in the natural history of the disease (KINCAID et coll MEANEY et coll 1968) Also only a few re ports have dealt with the urographic findings in this particular entity Vanderbilt University Hospital is a specialized center for the investigation and treatment (medical as well as surgical) of renovascular hypertension with a large patient material From this material 100 hypertensive patients with typical angiographic features of fibro muscular disease were selected and clinical and roentgenologic findings in this material are now presented

Material and Methods

The material comprised 100 hypertensive patients 83 females and 17 males aged 8 to 69 years (mean 46) with angiographic findings consistent with fibromuscular disease of the renal arteries Each patient was examined with rapid sequence uro-

Submitted for publication 19 January 1977

8 – 785835

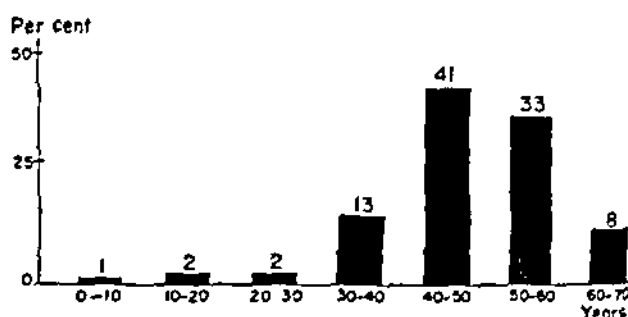


Fig 1 Age distribution Mean age females 47 years Mean age males 43 years

graphy (MAXWELL et coll 1964) and abdominal aortography Selective nephroangiography was performed in most of the cases usually in several projections in order to obtain optimum information regarding intrarenal arterial involvement In some cases catheterization of other arteries was also performed (e g common carotid celiac and superior mesenteric arteries) Blood samples from the renal vein were obtained simultaneously from both kidneys for renin determination Arterial and venous catheterization were performed on different days Twenty three patients were operated upon receiving venous grafts Microscopic documentation was available only in a few cases Repeat angiography was performed in 28 patients within a time range of 1 to 9 years

In reviewing the urographic findings the following criteria were evaluated kidney size appearance time of contrast medium in the renal pelvis and possible differences in contrast concentration on both sides Regarding the angiograms special attention was paid to the distribution of the fibromuscular abnormalities and to the appearance of collaterals Attempts were also made to evaluate the degree of stenosis created by the disease

Results

There was a striking female sex preponderance 83 per cent of the patients being women (Table) The mean age for the females was 47 years as compared with an average of 43 for the males (Fig 1) The youngest patient in the material was an 8 year-old boy with a membraneous stenosis of the main stem of the right renal artery and with collaterals (Fig 2 a) The peak incidence (41 %) occurred in the fourth decade (Fig 1) Rapid sequence urography was pathologic in 22 cases (Fig 3) the most common abnormality being size disparity (length of right kidney exceeding that of the left by more than 1 5 cm or length of left kidney exceeding that of the right one by more than 2 cm) Delayed appearance of contrast medium in the calyces occurred in 18 patients The typical string of beads appearance as demonstrated by angiography was found in 73 patients A short membraneous stenosis was the only abnormality in 5 patients Bilateral involvement of the renal arteries was demonstrated in 67 cases Out of the 33 cases with unilateral disease 31 were found on the right side The middle and distal third of the main stem of the renal artery was involved



Fig 2 a) Abdominal aortography in 8 year-old boy with hypertension Short membraneous stenosis in right main renal artery with post stenotic dilation Collaterals in renal hilum (→) b) Postoperative aortography following venous graft Patient normotensive

in 93 cases Segmental arterial involvement to a varying degree was found in 60 patients

Multiple renal arteries were found supplying 32 kidneys and fibromuscular involvement was demonstrated in 5 of these supplementary arteries Often it was difficult to evaluate the degree of stenosis and its hemodynamic significance However a marked stenosis was found in 29 cases Collaterals were demonstrated in 17 cases Adrenal and lumbar arteries were the most common source of these collaterals Lateralizing renins (ratio > 1 5) were found in 27 patients (Fig 3)

Films from repeat angiography were available in 28 patients (time range 1 to 9 years) In 5 (32 year old woman 41 year old woman 44-year old woman 50-year old man and 35 year old woman reexamined after 2 2 2 5 5 and 9 years respectively) progression of the disease was demonstrated In two of these arterial occlusion and ensuing infarction of the kidney were found (Fig 5) In the remaining 23 patients no evidence of progression of disease was displayed

Renal ptosis was evident in 12 cases with ipsilateral involvement of the main stem of the renal artery Aneurysm formation within the main stem of the renal artery or its intrarenal branches occurred in 9 cases (Figs 6 7) Dissecting fibromuscular lesions existed in 3 renal arteries in one case leading to partial infarction of the kidney (Fig 8)

Extrarenal manifestation of the disease was noticed in 12 patients all of whom also

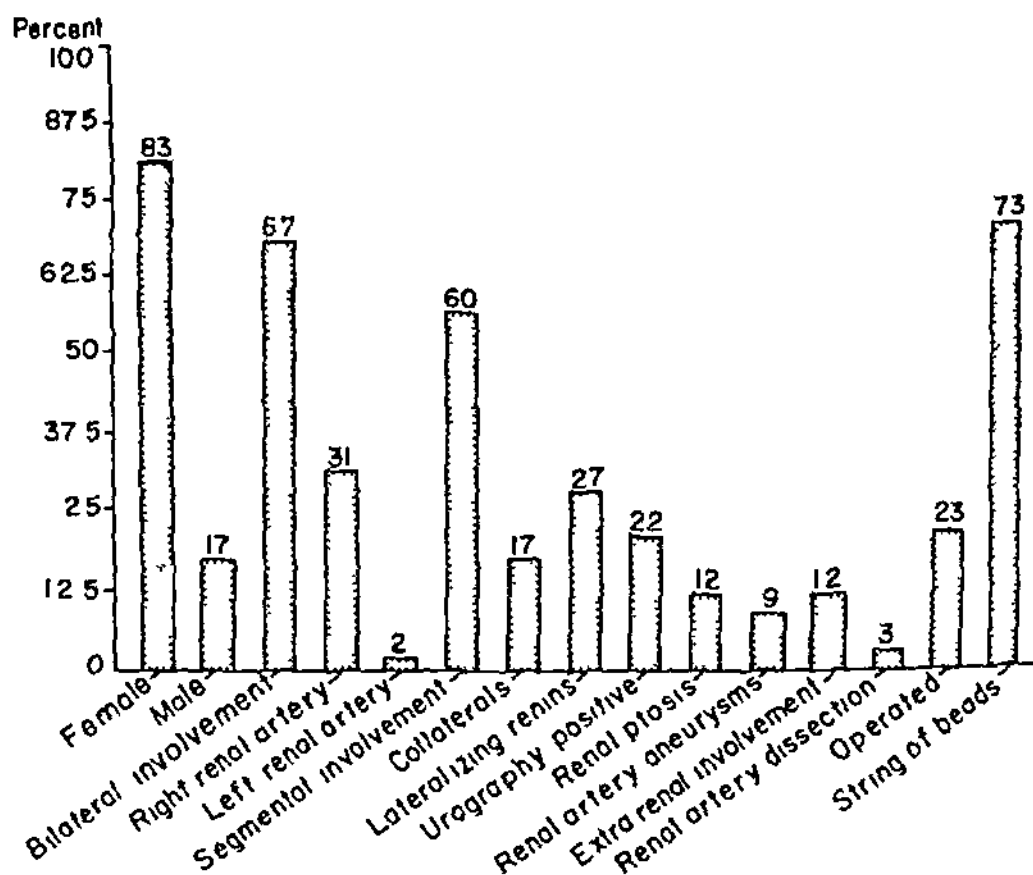


Fig 3 Findings in 100 patients

had involvement of the renal artery Of these one patient had fibromuscular lesions in the right internal carotid artery 3 patients had engagement of the external iliac arteries 4 patients displayed evidence of superior mesenteric artery involvement (one with dissection proved at surgery) 2 patients had stenosis and occlusion of the celiac artery respectively and finally 2 patients had splenic artery lesions (Figs 9–12)

Discussion

Fibromuscular dysplasia of the renal artery as a cause of renovascular hypertension was initially reported by LEADBETTER & BURKLAND (1938) Reports of similar cases were subsequently described by DE CAMP & BIRCHALL (1958) MCCORMACK et coll (1958) WYLIE & WELLINGTON (1960) PALUBINSKAS & WYLIE (1961) and THOMPSON et coll (1964) Clinical materials of this disease continued to grow and KINCAID et coll (1968) reported on a series of 125 cases This was followed by GILL & MEANEY (1969) reporting a series of 203 cases Since the early descriptions of the disease many facets remain unknown Until more is learned about the disease reviews of large series of cases will continue to be of value



Fig 4 Marked stenosis in distal third of right main renal artery Collaterals from inferior adrenal artery



a



b

Fig 5 a) Selective nephroangiography in hypertensive male Fibromuscular dysplasia in upper branch of renal artery b) Five years later Occlusion of branch to lower pole of the kidney with tiny intrarenal collaterals Loss of parenchyma in lower pole evident on later film The fibromuscular changes in the upper branch of the renal artery are not evidently changed

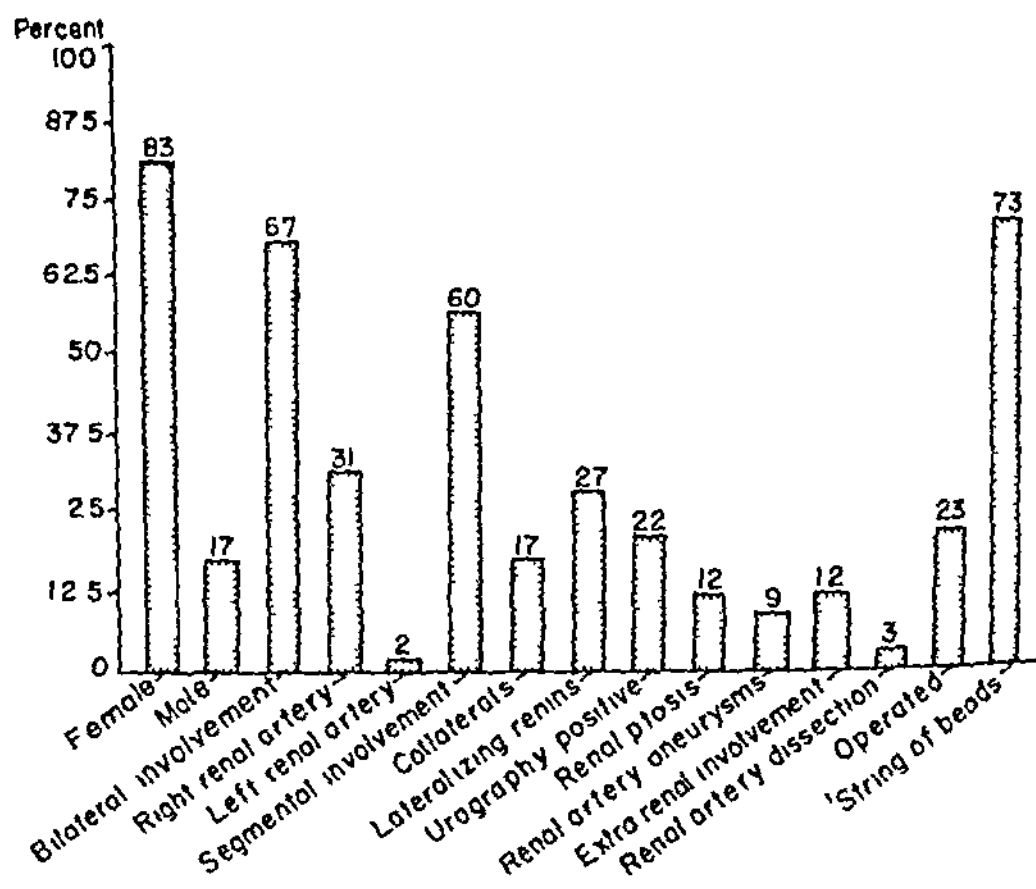


Fig. 3. Findings in 100 patients.

had involvement of the renal artery. Of these one patient had fibromuscular lesions in the right internal carotid artery, 3 patients had engagement of the external iliac arteries, 4 patients displayed evidence of superior mesenteric artery involvement (one with dissection proved at surgery), 2 patients had stenosis and occlusion of the celiac artery, respectively, and finally 2 patients had splenic artery lesions (Figs. 9–12).

Discussion

Fibromuscular dysplasia of the renal artery as a cause of renovascular hypertension was initially reported by LEADBETTER & BURKLAND (1938). Reports of similar cases were subsequently described by DE CAMP & BIRCHALL (1958), MCCORMACK et coll. (1958), WYLIE & WELLINGTON (1960), PALUBINSKAS & WYLIE (1961), and THOMPSON et coll. (1964). Clinical materials of this disease continued to grow and KINCAID et coll. (1968) reported on a series of 125 cases. This was followed by GILL & MEANEY (1969) reporting a series of 203 cases. Since the early descriptions of the disease many facets remain unknown. Until more is learned about the disease, reviews of large series of cases will continue to be of value.



Fig 7



Fig. 8

Fig 7 Hypertensive 42 year-old female Fibromuscular dysplasia in middle and distal part of main renal artery with aneurysm formation and marked stenosis distal to the aneurysm Collaterals from inferior adrenal artery

Fig 8 Dissecting fibromuscular lesion of distal main renal artery and major branches

reviewed and correlated with the findings (Table) The parameters evaluated in the present material appear in Figs 1 and 3

The urographic findings are seldom discussed in reports of fibromuscular dysplasia Abnormalities have been reported with varying frequency Significant changes suggesting unilateral renal disease were observed in less than one third of 26 cases reported by SUTTON & BRUNTON (1963) A higher incidence (70%) was reported by McCORMACK et coll (1967) and 75 per cent by HUNT & STRONG (1973) This wide range is probably related to the criteria used for making the diagnosis of an abnormal urography The criteria used in the present material were (a) difference of renal length of 1 5 cm to 2 cm (b) unilateral delay in excretion and (c) hyperconcentration of the contrast medium on late films With these criteria abnormal urography was found in 22 *per cent This figure should be related to the fact that unilateral* disease was found in only 33 per cent of the patients (Table)

It is sometimes difficult to evaluate the hemodynamic significance of fibromuscular renal artery lesion at angiography The demonstration of collaterals provides one indicator for such significance In the present material collaterals were demonstrated in 17 per cent usually emanating from adrenal and lumbar arteries This figure is higher than in previously reported series (KINCAID et coll 1968) GILL & MEANEY 1969) A disparity of the renin concentrations in the renal vein of 1 5 fold or more between the two sides favors hemodynamic significance and is also thought to be of prognostic value in deciding possible operation (MICHELAKIS et coll 1967) Lateralizing renins were encountered in 27 patients in the present series 23 of whom



Fig 9



Fig 10

Fig 9 Angiography of right common carotid artery in 52 year old hypertensive female with documented fibromuscular dysplasia of the renal arteries Abnormalities consistent with fibromuscular disease in the internal carotid artery (→)

Fig 10 Abdominal aortography in 56-year old hypertensive female with extensive fibromuscular dysplasia in both renal arteries Fibromuscular dysplasia is also evident in both external iliac arteries

went to surgical reconstruction REICH et coll (1975) suggested that not only the degree of stenosis may be of hemodynamic significance but also changes in pulse wave characteristics caused by irregular vessel lumens and based this theory on experiments with various models of normal and pathologic renal arteries tested in a pulse duplicator

Progression of fibromuscular dysplasia has been described In the present series repeat angiography ranging from one to nine years was performed in 28 patients Progression occurred in 5 3 of which were over 40 years of age at the time of the angiography Of these 5 2 progressed to total occlusion of the renal artery and infarction of the kidney In a review of 51 patients by MEANEY et coll progressive disease occurred in only 4 patients and new disease in 4 others The follow up of these patients ranged from 1 to 7 years In none of the patients more than 40 years old



Fig 11 Same case as in Fig 10 Pelvic arteriography

Fig 12 Abdominal aortography 61 year-old hypertensive female Fibromuscular dysplasia is evident in distal half of right main renal artery Dissecting aneurysm in the proximal part of the superior mesenteric artery Resection was performed and fibromuscular dysplasia proven by histology

Table

Distribution in per cent of 428 cases of fibromuscular dysplasia

	Kincaid et coll 125 cases	Gill & Meaney 203 cases	Present material 100 cases
Women	80 (mean age–35 years)	81 (mean age–45 years)	83 (mean age–46 years)
Bilateral disease	39	59	67
Unilateral disease	61	40	33
Segmental artery disease	46	33	60
Collaterals	13	5	17

at the time of the primary examination did new disease develop or was progression evident KINCAID et coll performed one or more follow up arteriographies on 16 patients The time between the first and last angiography ranged from 8 months to 5½ years the average time elapse being 31 months Definite progression of the disease including the development of new lesions was noted in 6 of the 16 patients Although the abnormalities of the renal artery were definite in no patient was progression marked

Aneurysms have also been found in association with fibromuscular dysplasia ROTHFIELD & HARE (1968) found 3 of 24 cases to have renal artery aneurysms all involving the left renal artery True aneurysms were found in only 2 of the 203 patients reported by GILL & MEANEY (1969) 13 aneurysms were reported by KINCAID et coll In the present series aneurysms were found in the renal artery in 9 patients

Fibromuscular dysplasia may involve extrarenal arteries In a survey of 5 000 carotid angiographies HOUSER et coll (1971) found 16 cases involving the extracerebral portion of the internal carotid artery (an incidence of 0 32 %) and HARRINGTON et coll (1970) in a review of 2 000 carotid angiographies reported 5 cases (0 25 %) Other cases of extracerebral internal carotid artery involvement have also been reported including CONNETT & LANSCHE (1965) one case PALUBINSKAS et coll (1966) 3 cases MORRIS et coll (1968) 12 cases PERRY (1972) one case and NOWN (1974) one case These total 39 cases of extracerebral internal carotid artery involvement and make this artery the most common extrarenal site for fibromuscular dysplasia Carotid angiography was performed in only a few of the present patients and in one case there was evidence of internal carotid artery involvement Intracranial aneurysms have also been found in patients with this disease WYLIE et coll (1966) found intracranial aneurysms in 10 patients of 70 with fibromuscular dysplasia of the renal arteries

The visceral arteries are the next most common site involved Symptomatic lesions of the superior mesenteric artery have been described by RIPLEY & LEVIN (1966) WYLIE et coll (1966) reported 7 patients with the disease in the celiac artery 3 of these had visceral ischemic symptoms PATCHEFSKY & PAPLANUS (1967) described the disease in the hepatic artery which eventually formed a dissecting aneurysm In

the present material there was an incidence of 8 per cent of visceral arterial involvement Four cases had involvement of the superior mesenteric artery in one patient resulting in dissection two cases of possible celiac artery involvement were present one with stenosis and one with occlusion of the celiac artery Two cases of splenic artery lesion were found Involvement of the peripheral arteries is infrequent Cases of iliac artery involvement have been described by NAJAFI (1966) and TWIGG & PALMISANO (1965) GARRETT et coll (1967) described involvement of the axillary artery The present material displayed a 3 per cent incidence of external iliac artery involvement

Initial reports describing this disease suggested that the stretching of the renal artery in ptotic kidneys may be an etiologic factor (KAUFMAN et coll 1964) Ptotic kidneys with ipsilateral fibromuscular involvement of the renal artery were found in 12 of the present patients Subsequent reports of involvement of other more stable arteries do not support this thesis (WYLEY & WELLINGTON 1960) In dog experiments ROTHFIELD (1969) found that stretching of the renal arteries resulted in intimal and medial smooth muscle thickening and fibrosis but rarely was sufficient to produce abnormal arteriographic appearance and concluded that other factors were responsible for the development of fibromuscular dysplasia A familiar relationship has been suggested by HALPERN et coll (1965) and HANSEN et coll (1965) The greater incidence in young women and its frequent initial detection during or after pregnancy caused WYLIE & WELLINGTON to suggest hormonal influences as an etiologic factor in this disease

The age distribution varies (Fig 1) The frequency in children remains small LEADBETTER & BURKLAND (1938) were the first to report a case in a child in a 5 year old hypertensive boy WELLINGTON (1963) had one patient under 10 years of age while HARRISON et coll (1967) had 2 children of 6 and 9 years of age among 66 histologically confirmed cases Two cases with multiple lesions in young children have been reported by ANDERSEN (1970) The first case was a 3 year old girl with hepatic and renal artery involvement while the second case was an 8 year old boy with lesions of carotid and vertebral arteries both renal arteries the mesenteric and the lumbar arteries A one per cent incidence of the disease was found in the present material including the pediatric age group (Fig 1) Fibromuscular dysplasia has been called a disease of young women (20 to 40 years) (MCCORMACK et coll 1967) It is of interest that the mean age among the present female patients was 47 years with a peak incidence between 40 and 60 years Also the mean age in the largest material presented (203 cases) was 45 years (GILL & MEANEY) These statistics indicate that fibromuscular dysplasia at least at the time of diagnosis is rather to be regarded as a disease of middle aged women

SUMMARY

Clinical and roentgenologic findings in 100 hypertensive patients with *fibromuscular* disease of the renal arteries are presented and compared with the experiences obtained from previously reported large series Frequency of bilateral disease and abnormal findings at

urography involvement of segmental arteries and occurrence of extrarenal manifestations are reported A striking female preponderance is noted and there is evidence that the disease inflicts middle aged rather than young women

ZUSAMMENFASSUNG

Die klinischen und rontgenologischen Befunde von 100 Patienten mit Hochdruck und mit einer fibromuskularen Erkrankung der Nierenarterien werden beschrieben und mit den Erfahrungen von fruher publizierten grosseren Serien verglichen Die Frequenz von bilateraler Erkrankung und pathologischen Befunden bei der Urographie der Beteiligung der segmentalen Arterien und dem Auftreten von extrarenalen Manifestationen werden beschrieben Eine klare weibliche Bevorzugung wurde festgestellt und es ist offenbar dass diese Erkrankung Frauen im mittleren Alter eher als jungere Frauen trifft

RÉSUME

Les auteurs presentent les signes cliniques et radiologiques chez 100 malades hypertendus atteints de maladie fibromusculaire des arteres rénales et les comparent avec les resultats de grandes series publiés auparavant Ils rapportent la frequence de l atteinte bilateral et des signes anormaux à l urographie l atteinte des artères segmentaires et l existence de manifestations extrarenales Ils notent une prédominance frappante dans le sexe féminin et une plus grande frequence chez les femmes d age moyen que chez les jeunes femmes

REFERENCES

ANDERSEN P E Fibromuscular hyperplasia in children Acta radiol Diagnosis 10 (1970) 203

BJÖRK L and FAGERBERG S Fibromuscular hyperplasia of the renal arteries without hypertension Acta radiol Diagnosis 4 (1966) 508

CONNETT M C and LANSCHE J M Fibromuscular hyperplasia of the internal carotid artery Report of a case Ann Surg 162 (1965) 59

DE CAMP P T and BIRCHALL R Recognition and treatment of renal artery stenosis associated with hypertension Surgery 43 (1958) 134

FOSTER J H DEAN R H PINKERTON J A and RHAMY R K Ten years experience with the surgical management of renovascular hypertension Ann Surg 177 (1973) 755

— OATES J RHAMY R KLATTE E BURKO H and MICHELAKIS A Hypertension and fibromuscular dysplasia of the renal arteries Surgery 65 (1969) 147

GARRETT E H HOSOSII S and DEBAKEY M E Fibromuscular hyperplasia of the left axillary artery Arch Surg 94 (1967) 737

GILL W M and MEANEY T F Medial fibroplasia of the renal artery Radiology 92 (1969) 861

HALPERN M M SANFORD H S and VIAMONTE M Renal artery abnormalities in three hypertensive sisters probable familial fibromuscular hyperplasia J Amer med Ass 194 (1965) 512

HANSEN J HOLTEN C and THORBERG J V Hypertension in two sisters caused by so-called fibromuscular hyperplasia of renal arteries Acta med scand 178 (1965) 461

HARRISON E G JR HUNT J C and BERNATZ P E Morphology of fibromuscular dysplasia of renal artery in renovascular hypertension Amer J Med 43 (1967) 97

HARRINGTON O B CROSBY V G and NICHOLAS L Fibromuscular hyperplasia of the internal carotid artery Ann thorac Surg. 9 (1970) 516
HOUSER O W BAKER H L SANDOK B A and HOLLEY K E Cephalic arterial fibromuscular disease Radiology 101 (1971) 605
HUNT J C and STRONG C G Renovascular hypertension Mechanisms natural history and treatment Amer J Cardiol 32 (1973) 562
— HARRISON E G KINCAID O W BERNATZ P E and DAVIS G D Idiopathic fibrous and fibromuscular stenosis of renal arteries associated with hypertension Proc Mayo Clin 37 (1962) 181
— — SHEPS S G BERNATZ P E and DAVIS G D Hypertension caused by fibromuscular dysplasia of renal arteries Postgrad Med J 38 (1965) 53
KAUFMAN J J HANAFEE W and MAXWELL M H Upright renal arteriography in the study of renal hypertension J Amer med Ass 187 (1964) 977
KINCAID O W DAVIS G D HALLERMAN F J and HUNT J C Fibromuscular dysplasia of the renal arteries Amer J Roentgenol 104 (1968) 271
LEADBETTER W F and BURKLAND C E Hypertension in unilateral renal disease J Urol 39 (1938) 611
MAXWELL M H GONICK H C WIITA R and KAUFMAN J J Use of the rapid sequence intravenous pyelogram in the diagnosis of renovascular hypertension New Engl J Med 270 (1964) 213
McCORMACK L J HAZARD J B and POUTASSE E F Obstructive lesions of the renal artery associated with remediable hypertension Amer J Pathol 34 (1958) 582
— NOTO T J MEANEY T F POUTASSE E F and DUSTAN H P Subadventitial fibroplasia of the renal artery a disease of young women Amer Heart J 73 (1967) 602
MEANEY T F DUSTAN H P and McCORMACK L J Natural history of renal arterial disease Radiology 91 (1968) 881
MICHELAKIS A M FOSTER J H LIDDLE G W RHAMY R K KUCHEL O and GORDON R D Measurement of renin in both renal veins Its use in diagnosis of renovascular hypertension Arch intern Med 120 (1967) 444
MORRIS G C LECHTER A and DE BAKEY M E Surgical treatment of fibromuscular disease of the carotid arteries Arch Surg 96 (1968) 636
NAJAFI H Fibromuscular hyperplasia of external iliac arteries Arch Surg 92 (1966) 394
NUNN D B Fibromuscular hyperplasia of the internal carotid artery Am r Surg 83 (1974) 112
PALUBINSKAS A J and WYLIE E J Roentgen diagnosis of fibromuscular hyperplasia of the renal arteries Radiology 76 (1961) 634
— PERLOFF D and NEWTON T H Fibromuscular hyperplasia Amer J Roentgenol 98 (1966) 907
PATCHEFSKY A J and PAPLANUS S H Fibromuscular hyperplasia and dissecting aneurysm of the hepatic artery Arch Path 83 (1967) 141
PERRY M O Fibromuscular disease of the carotid artery Surg Gynec Obstet 134 (1972) 57
REICH S B RILEY J C III CHRISTOPHER R A WALKER L A and EVERITT J H Changes in the pulse wave form with flow through vessels with repetitive saccular dilatations and stenosis Invest Radiol 10 (1975) 622
RIPLEY H R and LEVIN S M Abdominal angina associated with fibromuscular hyperplasia of the celiac and superior mesenteric arteries Angiology 17 (1966) 297
ROTHFIELD N J H Experimental fibromuscular arterial dysplasia Radiology 93 (1969) 1291
— and HARE W S C Upright aortography and fibromuscular hyperplasia Radiology 91 (1968) 335

SUTTON D and BRUNTON F J Fibromuscular fibrous and non atheromatous renal artery stenosis and hypertension Clin Radiol 14 (1963) 381
THOMPSON J E AUSTIN D J and WHEELER C G Renal artery reconstruction for hyper tension Surgery 55 (1964) 42
TWIGG H L and PALMISANO P J Fibromuscular hyperplasia of the iliac artery Radiology 95 (1965) 418
WELLINGTON J S Fibromuscular hyperplasia of renal arteries in hypertension Amer J Pathol 43 (1963) 955
WYLIE E J and WELLINGTON J S Hypertension caused by fibromuscular hyperplasia of the renal arteries Amer J Surg 100 (1960) 183
— BINKLEY F M and PALUBINSKAS A J Extrarenal fibromuscular hyperplasia Amer J Surg 112 (1966) 149

FROM THE DEPARTMENT OF DIAGNOSTIC RADIOLOGY (DIRECTOR PROFESSOR M C BEACHLEY) MEDICAL COLLEGE OF VIRGINIA HOSPITALS RICHMOND VIRGINIA 23298 U S A

ANGIOGRAPHY IN VESICAL AND PERIVESICAL NEOPLASTIC AND NON-NEOPLASTIC LESIONS

SVEN OLA HIETALA and TAPAN HAZRA

The clinical suggestion of tumor of the urinary bladder arises in patients with hematuria or obstructive uropathy If the routine radiographic evaluation (urography cystography chest films and bone survey) demonstrates a mass lesion in the bladder with an irregular surface typical tumor calcifications widespread local mural infiltration or distant metastases there is no doubt that the lesion represents a neoplasm However other space occupying neoplastic and non neoplastic lesions arising in the vesical and perivesical tissues may closely mimic the clinical and radiologic features of a urinary bladder carcinoma by causing deformity of the bladder ureteral obstruction and radiologic indications of intramural infiltration During the past 10 years (NILSSON 1967) pelvic or bladder angiography has been advocated for further differential diagnostic investigation in such cases Bladder angiography (HASSLER & HIETALA 1973) allows the demonstration of a tumor and its extension in and outside the bladder wall In typical cases the tumors are hypervascularized with tortuous vessels of varying caliber, accumulation of contrast medium and widened and tortuous veins These vascular appearances allow the angiographic diagnosis of carcinoma in about 85 per cent of bladder tumors (HASSLER & HIETALA) Thus 15 per cent of the bladder tumors do not have these angiographic features

Submitted for publication 29 March 1977

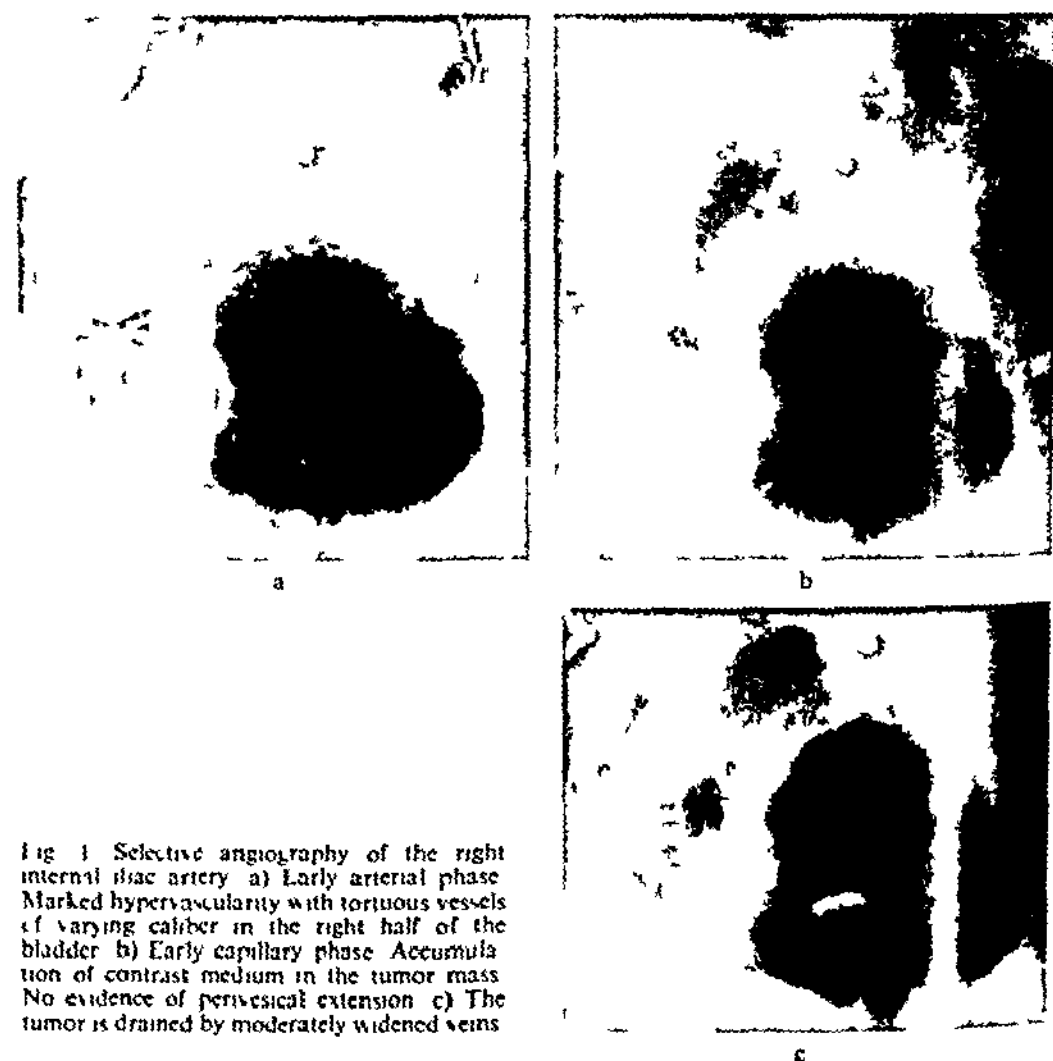


Fig 1 Selective angiography of the right internal iliac artery a) Early arterial phase Marked hypervascularity with tortuous vessels of varying caliber in the right half of the bladder b) Early capillary phase Accumulation of contrast medium in the tumor mass No evidence of perivesical extension c) The tumor is drained by moderately widened veins

The angiography is not reliable after radiation therapy because the vessels in irradiated and inflammatory conditions may produce the same type of angiographic abnormalities as epithelial tumors (HOFER et coll 1974 HIETALA & DUCHEK 1975) This is also true for tumors of nonepithelial origin (HIETALA et coll 1977)

It appears therefore that the diagnostic value of angiography as to the specific diagnosis may be questioned The applications and limitations of the angiography must be known Thus it seems appropriate to discuss the value of bladder angiography in the differential diagnosis of vesical and perivesical lesions on the basis of 7 presented cases

Case reports

Case 1 A 71 yea old white male Cystoscopy with palpation demonstrated a 4 cm 4 cm tumor in the right posterior portion of the bladder with no perivesical growth on



Fig 2 Nonselective bladder angiography a) Early arterial phase Considerable hypervascularity in the bladder wall b) Late arterial and early capillary phase Tortuous vessels of varying caliber in the thickened wall No intravesical tumor

palpation Microscopy indicated a transitional cell carcinoma moderately differentiated (Grade II) infiltrating the superficial muscular coat (Stage T 2) Both nonselective and selective bladder angiography was performed The selective angiography of the internal iliac artery on the right side demonstrated a marked hypervascularity with tortuous vessels of varying caliber in the right half of the bladder (Fig 1 a) and accumulation of contrast medium in the mass that extended almost to the midline (Fig 1 b) The draining veins were widened (Fig 1 c) No angiographic indications of perivesical extension The patient received external irradiation by using a 34 MeV betatron and four field technique The tumor dose delivered was 60 Gy in 6 weeks Seven months after completion of the irradiation, cystoscopy and bimanual examination revealed an irregularity in the bladder wall at the site of the primary tumor The post treatment angiography demonstrated a markedly increased number of tortuous vessels in the bladder wall (Fig 2 a) but no intra vesical tumor (Fig 2 b) The patient died 9 months after completion of therapy The autopsy showed ulcerative cystitis but no microscopic evidence of tumor Diagnosis Radiation cystitis

Case 2 A 70-year old male with a 5 year history of prostatism urinary tract infections and occasional hematuria Cystoscopy demonstrated a papillomatous tumor in the bladder involving the left ureteral orifice Biopsy and microscopy showed acute and chronic non specific cystitis but no evidence of tumor Bladder angiography demonstrated a hyper vascular lesion on the left side of the bladder (Fig 3 a b) with intravesical soft tissue protrusion Abnormal vascularity was also identified in the perivesical tissues Cytologic examinations did not reveal any malignancy Transvesical prostatectomy was done The bladder was thoroughly examined and palpated during surgery but no evidence of tumor or infiltration of the bladder wall was found Repeat angiography about one year after the prostatic operation revealed a slightly increased number of arteries (Fig 3 c) in the bladder wall and no vesical mass (Fig 3 d) Diagnosis Chronic nonspecific cystitis

Case 3 A 23 year-old white male with pulmonary tuberculosis during his pre school age Later on he suffered from recurrent cystitis unresponsive to conventional therapy Cystoscopy revealed extensive inflammatory changes with ulcerations in the bladder mucosa An exophytic lesion was visible at the site of the right ureteric opening Cytologic examination of the lesion revealed inflammatory cells and microscopy indicated tuberculosis of the

9 785835




Fig 3 Selective angiography of the left internal iliac artery a) Arterial phase l ft anterior oblique position Markedly increas d number of widened and tortuous arteries in the left half of the bladder b) Early capillary phase Some very tortuous vessels of varying caliber in the thickened bladder wall Intravesical soft tissue protrusion (→) c) Selective angiography one year later after antibiotic treatment Only slight hypervascularity in the left bladder wall d) Capillary phase Wall only slightly thickened no visible tumor mass (→)

bladder Lowenstein Jensen culture and the guinea pig test were positive for tuberculosis Selective angiography demonstrated bilateral hypervascularity (Fig 4 a b) and on the right side (Fig 4 c) a soft tissue protrusion containing tortuous vessels of varying caliber Diagnosis Tuberculosis of the bladder

Case 4 A 53 year-old white female with a history of previous pleuritis and pulmonary tuberculosis and pollakisuria Cystoscopy demonstrated a slight bulge in the left posterior part of the vesical mucosa and the left ureteric opening was rigid and patent Later cystoscopies revealed shiny yellow protuberant epithelial abnormalities in the left side of the bladder which felt hard on palpation Repeat cystoscopic examinations revealed moderate progression The major part of the left half of the bladder was involved and the lesion extended to the right ureteric opening Biopsy and microscopy showed amyloid disease of the pericollagen type Angiography demonstrated hypervascular soft tissue lesions




Fig 4 Selective angiography of the right internal iliac artery a) Early arterial phase Increased number of tortuous vessels of varying caliber (→) in the right half of the bladder b) Capillary phase Tumor protruding into the bladder (→) c) Selective angiography of the left internal iliac artery arterial phase Moderate hypervascularity with widened and tortuous vessels of varying caliber in the left half of the bladder

with tortuous ves els of varying caliber (Fig 5 a b) on both sides of the bladder Diagnosis Primary amyloidosis of the bladder

Case 5 A 20-year old black female The patient had hypertension on a routine obstetric office visit 4 months into her first pregnancy The blood pressure was treated and she delivered a healthy baby at full term In the postpartum period a central vision loss in the right eye and blurred vision in the left eye occurred She complained of headaches palpitation and a salty taste in her mouth during micturition The symptomatology was considered typical for urinary bladder pheochromocytoma and cystoscopy was not performed At angiography a hypervascular lesion (Fig 6 a) was demonstrated in the left side of the bladder The tumor had parasitic supply from the opposite side and was drained by extremely widened and tortuous veins (Fig 6 b) At surgery a large tumor was found on the left anterior side of the bladder microscopically a pheochromocytoma (paraganglioma)

Case 6 A 47 year old black male The patient complained of crampy lower abdominal pain usually occurring during micturition and defecation The symptoms had started 2 years earlier but the recent increase in severity had resulted in dysuria and constipation On a conventional film of the abdomen the pelvic soft tissues had an attenuation of the radiation similar to that of fat A deformed bladder with anterior and lateral displacement




Fig 5 Nonselective bladder angiography a) Early arterial phase Increased number of tortuous arteries on *both* sides in the bladder wall on the left side (→) irregular variations in caliber b) Late arterial and capillary phase Tortuous and irregular vessels especially in the soft tissue protrusion in the left half of the bladder The bladder wall slightly thickened

was found on urography Barium enema demonstrated a tubular narrowing of the rectum Pelvic angiography (Fig 7 a) showed hypervascularity of the perivesical soft tissues which contained tortuous vessels of varying caliber The bladder wall had a normal thickness (Fig 7 b) and there was no early venous filling Because of the possibility of an inflammatory or neoplastic process involving the pelvic soft tissues an exploratory laparotomy was performed An excessive amount of fatty tissue occupied most of the pelvis resulting in compression of the urinary bladder Microscopy revealed normal appearing fatty tissue with mixed fibrotic changes consistent with pelvic lipomatosis

Case 7 A 78 year old white male was admitted because of constant back pain dysuria and difficulty in bowel movements Rectal examination revealed a mass above and to the



Fig 6 Nonselective angiography of the bladder a) Early arterial phase Marked hypervascularity with tortuous vessels of varying caliber draining the tumor on the left side Main feeder arteries (→) at the periphery of the tumor Extensive parasitic blood supply from the opposite side b) Venous phase Accumulation of contrast medium within the tumor which is drained bilaterally by widened and tortuous veins

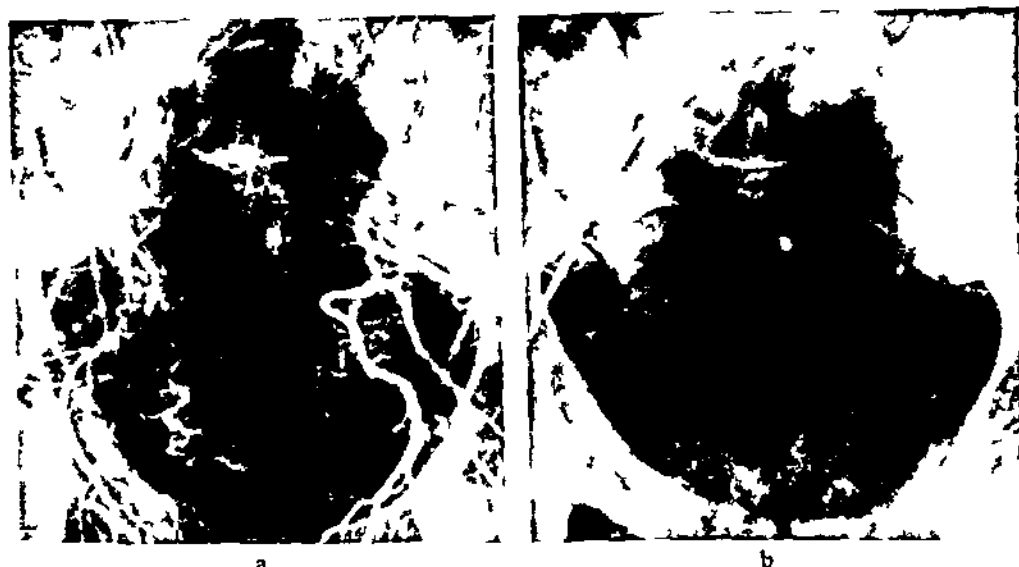


Fig 7 Nonselective angiography of the bladder a) Arterial phase Diffusely increased vascularity in the bladder wall and perivesical tissues The arteries are tortuous with irregular variations of the caliber b) Capillary phase The urinary bladder is deformed The bladder wall has a normal thickness No increased accumulation of contrast medium

left of the prostate in the immediate vicinity of the urinary bladder and not connected to the bowel The findings on urography indicated a retroperitoneal tumor Exploratory laparotomy was performed Microscopy demonstrated a well defined and encapsulated cellular tumor with many vascular channels typical of hemangiopericytoma Nine years postoperatively a hard mass was felt in the right iliac fossa and a tumor was excised from the retrocecal area The microscopy again reported hemangiopericytoma and the tumor was completely excised Two years later the patient experienced dysuria and radiating pain in his left leg Pelvic angiography demonstrated a left sided hypervascular perivesical mass with wide feeder arteries in the periphery of the tumor corkscrew arteries penetrating the tumor mass and tortuous vessels of varying caliber in the perivesical tissues to the left (Fig 8 a b) The tumor had an intense accumulation of contrast medium and was drained by widened and tortuous veins (Fig 8 c)

Discussion

Pelvic angiography in the examination of tumors of the urinary bladder has been described in several publications (NILSSON LANG 1968 HASSLER & HIETALA) Although there are considerable differences regarding the angiographic findings in different series it is apparent that the earlier expectations regarding angiography have not been completely fulfilled

The vascular abnormalities demonstrated angiographically in a case of urinary bladder carcinoma (Fig 1) reflect only to a limited extent the biologic characteristics of the tumor Small tumors may have no angiographic abnormalities (NILSSON HASSLER & HIETALA) and furthermore it has been shown that the grade




Fig 8 Selective angiography of the left iliac artery a) Arterial phase Extremely hypervascular mass with wide (→) feeder arteries at the periphery of the tumor Corkscrew arteries penetrating the mass b) Late arterial phase Tortuous vessels of varying caliber (→) in the perivesical tissue Early intense accumulation of contrast medium in the tumor c) Venous phase Accumulation of contrast medium within the tumor which is drained by widened and tortuous veins (→)

of malignancy of tumors and the degree of intramural infiltration cannot be determined by angiography Opinions have been divided as to the reliability of angiography when it comes to demonstrating the extension of the tumors with respect to the perivesical tissue (NILSSON GEORGI et coll 1968 LANG LENTZEN et coll 1968 KELAMI & TAENZER 1969) Later HASSLER & HIETALA have shown that compared with clinical and microscopic examinations angiography gives a false negative result in about 20 per cent and a false positive result in about 10 per cent of the cases with regard to the perivesical extension of the tumor However angiography constitutes a valuable complement to clinical and microscopic examinations for localizing the lesion in identifying its blood supply and predicting the nature and extension of the mass The procedure may be of value in patients undergoing cystectomy following irradiation by identifying the blood supply of the tumor

The vascular abnormalities caused by radiation are often modest and uncharacteristic and not usually observed angiographically (HASSLER & HIETALA) However in cases with advanced reactions angiography may demonstrate hypervascularity (Fig 2) with vessels resembling tumor vessels The differential diagnosis of tumor recurrences has proven to be difficult A certain diagnosis of recurrent tumor by angiography is only possible in cases where the tumor is well defined or where it is partially protruding into the lumen of the bladder Radiation reactions and tumors cannot be distinguished at angiography from the appearance of the vessels alone

It is evident that the angiographic appearances of a bacterial cystitis are non specific (Fig 3) and may be similar to those found in cases of radiation reaction (HASSLER & HIETALA) Hypervascularity with tortuous vessels of varying caliber

similar to those appearing in tumors may occur Furthermore the bladder wall may be irregular and soft tissue proliferations of similar appearance as in cases of bladder carcinoma may be found This is especially true in cases of chronic infections such as tuberculosis (Fig 4) The tuberculous lesions may be either hypo or hypervascular (HIETALA & DUCHEK) depending on the stage of activity of the tuberculous process The vessels may have the same appearance as those in tumors of the urinary bladder thus it is not possible to differentiate angiographically between a tuberculous infection and a tumor of the bladder

Similar angiographic abnormalities may also be found in other tumorous conditions of the bladder as for instance in primary localized amyloidosis (HOFER et coll) (Fig 5) The amyloid lesion may appear hypervascular and vessels similar to so called tumor vessels may be observed However the angiography is useful in appraising the extent of the amyloid lesion

The angiographic appearances of pheochromocytoma (Fig 6) of the urinary bladder have been described as fairly characteristic although not as uniform (CHRISTENSON et coll 1976 HIETALA et coll 1977) Feeding arteries are usually found at the periphery of the neoplasm The vessels within the tumor vary in caliber and are similar to those occurring in other tumors They may be extremely hypervascular and have remarkable parasitic arterial supply A high accumulation of contrast medium within the tumor is rather characteristic for pheochromocytoma Another distinguishing feature for pheochromocytoma of the urinary bladder has been the early filling of extremely dilated draining veins due to the rapid circulation Although pheochromocytomas may demonstrate some distinguishing features it is apparent that the angiographic appearance of pheochromocytoma is not pathognomonic nor does angiography allow differentiation between a malignant and benign tumor However angiography is indicated for ruling out adrenal or extra adrenal tumors and for exact localization of the bladder tumor

Perivesical hypervascularity similar to that occurring in inflammatory or neoplastic processes may be observed in pelvic lipomatosis (Fig 7) In this condition the bladder wall is not infiltrated but the bladder is deformed by pressure from the lipomatous tissue The angiographic findings may be either normal or be comparable to those of inflammatory or neoplastic processes (HIETALA et coll 1977) Angiography appears therefore to be of limited value for differential diagnostic purposes

Hemangiopericytomas may occur wherever capillaries exist and thus also in the perivesical tissue At angiography (Fig 8) a certain vascular appearance may be found (LOWMAN et coll 1972 MARC et coll 1972) Thus small corkscrew vessels from dilated feeder arteries penetrate into the tumor The accumulation of contrast medium is high but the degree of arterial displacement is usually somewhat less than expected from the size of the mass thus suggested in the mid arterial phase The circulation time is usually normal or prolonged Dilated draining veins remain filled for a long period of time It appears that the angiographic appearance of

hemangiopericytoma is highly characteristic but not pathognomonic The increased vascularity is not an absolute indication of malignancy and absence of vascularity in the mass need not be an indication that the mass is benign by nature From a differential point of view malignant tumors of mesodermal origin have to be considered These tumors are characterized by gross angiographic abnormalities with bizarre irregular vascular deformities

SUMMARY

Seven cases of neoplastic and non neoplastic lesions involving the urinary bladder and perivesical tissues are presented Each of the described lesions may have nonspecific angiographic appearances and hence angiography does not permit a specific diagnosis to be made The primary object of performing angiography is to localize the lesion and identify the vascular supply

ZUSAMMENFASSUNG

Sieben Falle mit neoplastischen und nicht neoplastischen Veranderungen der Blase oder des perivesikalem Gewebes werden beschrieben Jeder dieser Veranderungen kann ein nicht spezifisches angiographisches Bild haben und deshalb ist keine spezifische Diagnose mit Angiographie moglich Die primare Absicht bei der Angiographie ist die Veranderungen zu lokalisieren und die Blutversorgung darzustellen

RESUMÉ

Les auteurs presentent sept cas de lesions néoplsiques et de lesions non néoplasiques de la vessie et des tissus peri vesicaux Chacune des lesions décrites peut avoir des aspects angiographiques non spécifiques et l angiographie ne permet donc pas de faire un diagnostic specifique Le but principal de l angiographie est de localiser la lésion et d identifier sa vascularisation

REFERENCES

Christensson R Smith C W and Burko H Arteriographic manifestations of pheochromocytoma Amer J Roentgenol 126 (1976) 567

Georgi M Karcher K H Keiser D und Scheurlen H Arteriographie bei Tumoren im Beckenbereich Radiologe 8 (1968) 185

Hassler O and Hietala S O Angiographic abnormalities in the urinary bladder wall after irradiation Part 1 Animal experiments Part 2 Clinical investigation Acta radiol (1973) Suppl No 328

Hietala S O and Duchek M Angiography in urinary bladder tuberculosis Acta radiol Diagnosis 16 (1975) 297

— Texter J H and Crane D B Angiography in pheochromocytoma of the urinary bladder Acta radiol Diagnosis 18 (1977) 313

— Ghahremani G G Faunce H F and Yaghmai I Radiologic manifestations of pelvic lipomatosis Radiologe 17 (1977) 120

HOFER P Å WINBLAD B, ANDERSSON L, SCHÖNEBECK J LINGÅRDH G and HIETALA S O Primary localized amyloidosis of the bladder Scand J Urol Nephrol 8 (1974) 193

KELAMI A und TAENZER B Fehlinterpretationen bei der Harnblasen Angiographie Urol int 24 (1969) 349

LANG E K Roentgenographic diagnosis of bladder tumors Charles C Thomas Springfield Ill 1968

LENTZEN W DIHLMAN W und SCHIFFER A Grenzen der Harnblasenangiographie Fortschr Rontgenstr 109 (1968) 479

LOWMAN R M GRNJA V PECK D R OSBORN D and LOVE L The angiographic patterns of the primary retroperitoneal tumors Radiology 104 (1972) 259

MARC J A TAKEI Y SCHECHTER M M and HOFFMAN J C Intracranial hemangiopericytomas Angiography pathology and differential diagnosis Amer J Roentgenol 125 (1972) 823

NILSSON J Angiography in tumors of the urinary bladder Acta radiol (1967) Suppl No 263

FROM THE DEPARTMENTS OF RADIOLOGY AND SURGERY CENTRALSYGEHUSET DK 7500 HOLSTEBRO DENMARK

DISPLACED RENAL LOBE SIMULATING TUMOUR

NIELS HENRIK JENSEN and NIELS PETER MORTENSEN

A localized circumscribed mass of normal renal parenchyma radiologically simulating a tumour has been called pseudotumour Several reports on the subject have appeared in the literature over the past few years drawing attention to this benign type of lesion and making it possible to establish a correct diagnosis thus preventing traumatizing renal surgery ultimately nephrectomy if the mass is erroneously diagnosed as a neoplasm At this hospital 3 cases have been observed recently and are now briefly reported

Case reports

Case 1 A 50-year old female had microscopic haematuria but no evidence of urinary infection At urography a mass was found centrally in the left kidney displacing the upper and middle calyceal groups (Fig 1) Abdominal aortography and selective nephroangiography revealed one artery to each kidney and displacement of the interlobar arteries around the process but no tumour vessels (Fig 2 a) In the nephrographic phase an intense well demarcated accumulation of contrast medium measuring 2 5 cm in diameter occurred the contrasting effect being more marked than that of the outer cortex (Fig 2 b) except in a small region towards the renal sinus Within this region the nephrographic effect was similar to that of the adjacent renal medulla No early venous filling occurred The possibility of a centrally placed renal lobe consisting of both cortex and medulla was considered but an operative exploration was performed A slightly increased consistency of the mass was felt However the cut surface showed no sign of tumour Apparently the mass consisted of normal renal cortex and medulla which was confirmed microscopically on deep biopsy (Fig 2 c)

Subbmitted for publication 23 March 1977



Fig 1 Case 1 Tomography Initial urography Splaying of the upper and middle calyceal groups by a space occupying mass (→) The lateral border of the kidney is protruding

Case 2 Female 56 years old with occasional macroscopic haematuria and slight fever Urography revealed a slightly dilated upper urinary tract on the right side In the left kidney an impression upon the upper pole infundibulum together with a slight stretching of the middle calyceal group suggested a central mass (Fig 3 a) Aortography and selective left nephroangiography demonstrated a slight deviation of the interlobar arteries around the process in the capillary phase followed by a circumscribed contrasting effect of the lesion which measured 2 5 cm in diameter (Fig 3 b c) The accumulation of the contrast medium within the mass was higher than that of the outer cortex to which the mass was connected through a prominent renal column Medially within the process a small area of lesser accu mulation was demonstrated No tumour vessels were seen and the venous phase was normal On nephroscintigraphy with $^{99}Tc^{m}$ pyrophosphate the uptake was normal which ruled out a malignant tumour or cyst A plausible explanation of the patient s symptoms was found at cystoscopy which revealed a haemorrhagic cystitis

Case 3 A 46-year old male was admitted because of low back pain radiating to the lower abdomen and right flank ESR 65 mm/h At urography a round mass measuring approxi mately 3 cm in diameter was demonstrated in the right kidney The mass encroached upon the renal pelvis and the upper and middle calyceal groups A chest film revealed a nodular lesion measuring 3 cm in diameter basally in the lower lobe of the left lung suggestive of a metastasis The probability of a primary renal carcinoma with secondary spread was con sidered A selective right nephroangiography showed the characteristics of displaced renal tissue with slight deviation of interlobar arteries a well demarcated mass in the nephrographic phase containing a central part with less accumulation of contrast medium indicating medullary tissue Four months after the onset of symptoms the patient died at autopsy an adenocarcinoma was found in the lower lobe of the left lung with widespread metastases to lymph nodes liver and bone (including the thoraco-lumbar spine) In the right kidney a displaced renal lobe was found but no evidence of malignancy (Fig 4)

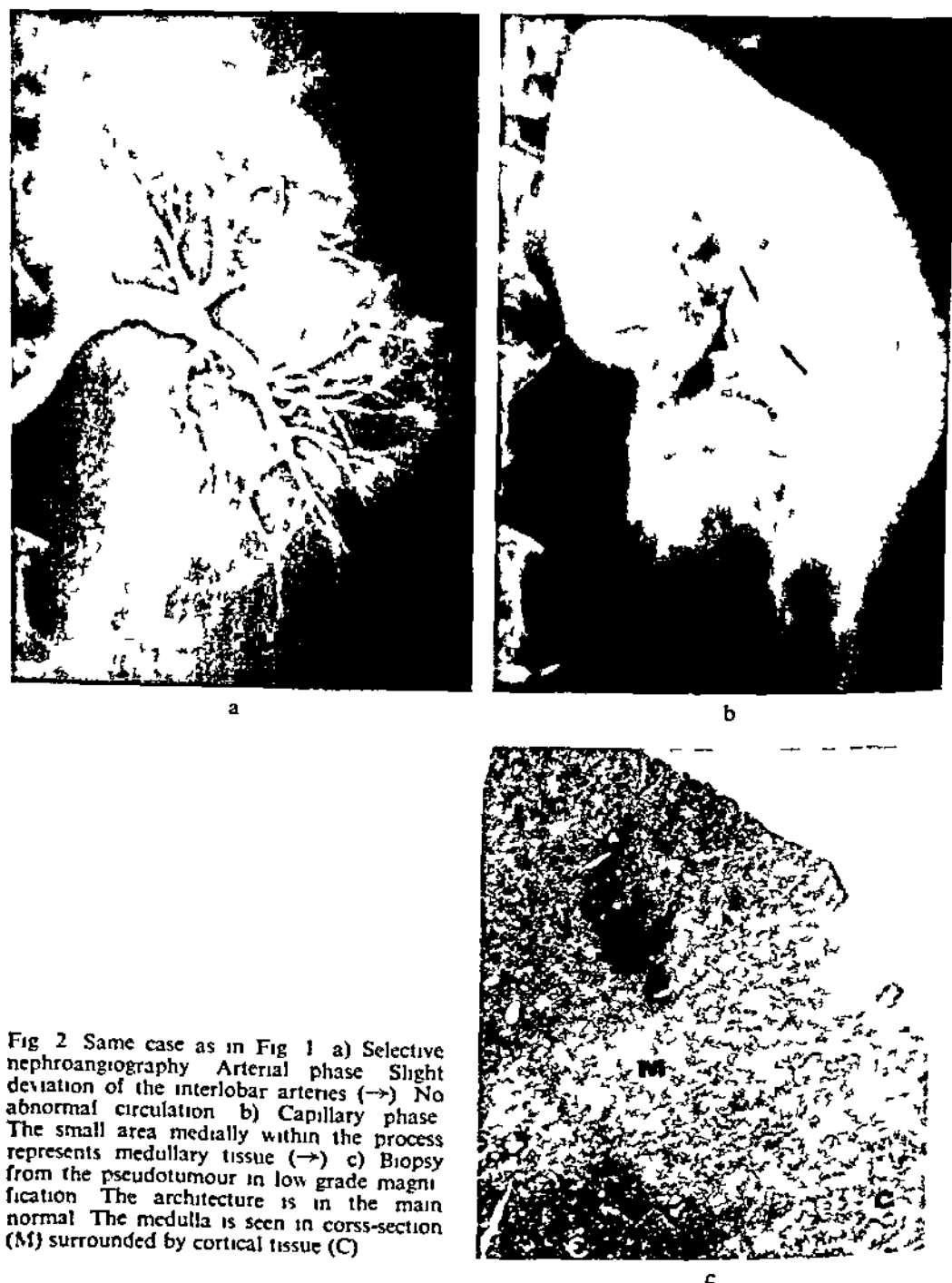


Fig 2 Same case as in Fig 1 a) Selective nephroangiography Arterial phase Slight deviation of the interlobar arteries (→) No abnormal circulation b) Capillary phase The small area medially within the process represents medullary tissue (→) c) Biopsy from the pseudotumour in low grade magnification The architecture is in the main normal The medulla is seen in corss-section (M) surrounded by cortical tissue (C)

a



b



c

Fig 3 Case 2 Urography Nodular space occupying mass in the left kidney impinging upon adjacent calyces (→) b) A slight displacement of interlobar arteries outlining the process The arterial sypply is normal c) Nephrographic phase Well demarcated lesion with higher radiographic contrast than outer cortex with which the process is continuous through a prominent renal column



Fig. 4 Case 3 Kidney removed at autopsy The centrally placed pseudotumour represents a misplaced renal lobe built up by normal cortex, medulla and a calyx (→)

Discussion

Two types of renal pseudotumour are generally distinguished (KING et coll 1968) A secondary acquired type may be found in diseased kidneys e g chronic pyelonephritis trauma (surgery) or infarction the mass representing nodular areas of unaffected renal tissue or regions of compensatory hypertrophy More difficult to diagnose is the primary congenital type often encountered in otherwise non diseased kidneys such as an invaginated cortical mass or a centrally placed renal lobe Terms such as prominent or infolded renal column of Bertin infolding of a cortical mass (KING et coll) and lobar dysmorphism (malposition of a renal lobe CHARGHI et coll 1971) have been used to describe the mass simulating a tumour As these last conditions often occur in association with complete or abortive duplication of the kidney or the renal pelvis a developmental origin has been suggested (KING et coll)

The roentgenologic appearances are characteristic and uniform from one case to another At urography a mass is found usually in the upper or middle third of the kidney causing displacement or stretching of adjacent calyces In a high percentage

of cases partial or complete duplication is present The second of the present cases had an abortive duplication consisting of a partially duplicated pelvis together with a long upper pole infundibulum (Fig 3 a) Urography does not usually provide any additional information as to the nature of the process unless a large amount of contrast medium and tomography (nephrotomography) is used A selective nephroangiography will with reasonable certainty lead to a final and correct diagnosis The interlobar arteries are displaced around the mass which measures up to 3 cm in diameter the blood supply is normal with no tumour vascularity The nephrographic effect is simultaneous with and of the same intensity as that of the outer cortex In the nephrographic phase the mass is well demarcated and homogeneous if consisting of cortical tissue throughout but may demonstrate a small area of medullary tissue with less uptake of contrast medium close to the renal sinus Gross and microscopic examination of the mass suggests that the lesion is produced by a misplaced but otherwise normal renal lobe No pooling of contrast medium or early venous filling occurs

The two main differential diagnoses to be considered are renal cyst and carcinoma At angiography a cyst will produce a defect in the nephrogram and is therefore ruled out Absence of tumour vessels a well demarcated mass during the capillary phase and a normal venous phase speak against a carcinoma In doubtful cases nephroscintigraphy should be performed Cysts and carcinomas have a diminished isotopic uptake producing filling defects in the scintigram whereas a displaced renal lobe will accumulate the isotope to the same degree as normally functioning parenchyma (WAGNER 1968 FELSON & MOSKOWITZ 1969 CARTY et coll 1975)

SUMMARY

Three cases of renal pseudotumour are presented with the radiographic appearances At urography a mass is demonstrated Angiography reveals slight displacement of the interlobar arteries a normal venous phase but no tumour vessels The nephrographic effect is similar in the mass and in the renal parenchyma The nephroscintigraphy is likely to be normal The main differential diagnoses are mentioned

ZUSAMMENFASSUNG

Drei Falle von renalen Pseudotumoren und deren rontgenologisches Erscheinungsbild werden beschrieben Bei der Urographie wurde eine Tumorahnliche Veranderung fest gestellt Die Angiographie zeigte eine leichte Verlagerung der interlobularen Arterien eine normale venose Phase aber keine Tumorgefasse Der nephrographische Effekt ist in der Expansivitat und in dem renalen Parenchym ahnlich Die Nierenszintigraphie ist ebenfalls normal Die hauptsachlichen Differentialdiagnosen werden in Erinnerung gebracht

RÉSUMÉ

Les auteurs présentent trois cas de pseudo tumeur renale avec leurs aspects radiologiques L urographie met en evidence une masse l angiographie revele un leger deplacement des

artères interlobaires une phase veineuse normale mais pas de vaisseaux tumoraux L effet nephrographique est semblable dans la masse et dans le parenchyme renal La néphro scintigraphie est vraisemblablement normale Les auteurs mentionnent les principaux diagnostics differentiels

REFERENCES

BRAUNSTEIN P HERNBERG J G BOSNIAK M A and BARASCH E Scintiscan evaluation of prominent renal columns Radiology 104 (1972) 103

CARTY A T SHORT M D and O CONNELL M E A The diagnosis of renal pseudotumours Brit J Urol 47 (1975) 495

CHARGHI A DESSUREAULT P DRONIN G GAUTHIER G E PERVAS P ROY P and CHARBONNEAU J Malposition of a renal lobe (lobar dysmorphism) A condition simulating renal tumour J Urol 105 (1971) 326

FELSON B and MOSKOWITZ M Renal pseudotumours The regenerated nodule and other lumps bumps and dromedary humps Amer J Roentgenol 107 (1969) 720

GREEN W M PRESSMAN B D MCCLENNAN B L and CASARELLA W J Column of Bertin diagnosis by nephrotomography Amer J Roentgenol 116 (1972) 714

KING M C FRIEDENBERG R M and TENA L B Normal renal parenchyma simulating tumour Radiology 91 (1968) 217

KYAW M M Renal pseudotumour due to infolding column of Bertin J Amer med Ass 219 (1972) 1634

WAGNER H N Principles of nuclear medicine p 643 Saunders Philadelphia 1968

FROM THE RESEARCH LABORATORIES DEPARTMENTS OF DIAGNOSTIC RADIOLOGY AND PATHOLOGY MALMÖ ALLMÄNNA SJUKHUS S 214 01 MALMÖ SWEDEN

EXPERIMENTAL COLONIC TUMOURS IN THE RAT

II Double contrast examination and microscopy

J E ROSENCREN and C G LINDSTROM

The development of polyps and carcinomas in the human colon and rectum has been the subject of many speculations and investigations A consecutive investigation of the development of polypoid colon tumours in man and their presumptive tendency to become malignant is practically impossible (EKELUND et coll 1974) Surgical intervention has made it impossible to assess the growth of a human colon carcinoma from the early signs of malignancy to the final stages However such sequential estimates are quite feasible in experimental animals in which colonic tumours have been induced The morphology of developing polyps and carcinomas can be simultaneously compared with the appearance of tumour immunology (STEFLE et coll 1975)

The rat is a suitable animal for such experiments Colonic tumours appear seldom spontaneously in rats (ROBERTS 1960) but may easily be induced by different carcinogens In many respects these tumours resemble human colon carcinomas (DRUCKREY et coll 1967 SPJUT & SPRATT 1965 MARTIN et coll 1973)

Attempts have been made to demonstrate small carcinomas and polyps in the rat with barium enemas but small abnormalities can hardly if ever be detected with this method Double contrast examination of the colon offers much better means of detecting early and small lesions in the colonic mucosa (ANDREN et coll 1955)

Supported by grants from the University of Lund Faculty of Medicine (No 5944-900-3) the John and Augusta Persson Foundation, and the Swedish Cancer Society (No 795-B74-01X) Submitted for publication 21 January 1977

The purpose of this investigation was to evaluate the diagnostic accuracy of the double contrast examination of the colon in the rat and to describe the valid criteria of benign and malignant lesions

Material and Methods

The total material consisted of 124 rats and included 10 adult Wistar rats 85 adult inbred Wistar/Furth (WF) rats obtained by continuous single line brother to sister mating and 29 adult rats of race BD of both sexes (DRUCKREY et coll) All animals were fed on a standard pellet diet and water ad libitum

Ten WF rats were used as untreated controls The remaining 114 animals were treated with one of the two carcinogenic agents 1 2 dimethylhydrazine 2 HCl (DMH) or N methyl N nitro N nitrosoguanidine (MNNG)

DMH was administered as subcutaneous injections of 2 per cent oily suspension and MNNG as rectal instillations of 0 25 per cent water solution Twenty nine BD rats of both sexes were given a total individual dose of 180 mg DMH/kg body weight subdivided into 15 doses during 4 to 12 weeks Sixty four female Wistar rats were given a dose of 300 mg DMH/kg body weight subdivided into 15 doses during 15 weeks Twenty one Wistar male rats received a dose of 60 mg MNNG/kg body weight as 0 5 ml enemas twice a week for 4 weeks followed by 0 5 ml once a week for 8 weeks

During and after the treatment with carcinogens repeated double contrast examinations were performed according to the technique described in Part I (ROSENGREN 1978)

The animals were observed during an individually varied period of time and were killed when the information obtained from the colon examinations was expected to be most profitable as evaluated by necroscopy and microscopy The individual response of the animals to the carcinogens the incidence of colonic lesions obtained and the individual tumour growth are beyond the scope of the present report and will be given in a forthcoming communication

In total 434 colon examinations (10 examinations of the control animals included) were performed Usually the rats died because of the colonic malignancy and only some rats were killed At autopsy all parts of the large bowel were carefully inspected and possible lesions of the colonic mucosa were photographed and microscopically examined in addition to sections of macroscopically normal parts

The preparation and technique of the microscopic examinations will be described in Part III (LINDSTRÖM et coll 1978 a)

Results

Macro and microscopic findings

Hyperplastic mucosal lesions Two macroscopically different forms of hyperplastic mucosal lesions were observed The first one consisted of plateau shaped slightly



Fig 1 Carcinoma of the endophytic type in the distal part of the main flexure a) Slightly elevated area to the lumen of the large bowel b) Microphotograph Mucus producing, poorly differentiated adenocarcinoma developing in a lymphoid plaque Almost all of the lymphatic tissues is replaced, only small remnants of lymph follicles Haematoxylin-eosin 25

elevated areas of the mucosa with a regular but somewhat higher epithelium and with slightly longer glands than normally In the second form the lesions were polypoid with glands of the same appearance

Inflammatory polypoid lesions One inflammatory polyp was observed in the material It had a stroma infiltrated with mainly eosinophilic leukocytes in which glandular structure with cystic dilation surrounded by regular epithelium were embedded (Fig 2)

Adenomas These lesions were benign tumours of the mucosal gland epithelium with varying degree of epithelial atypia from slight moderate and marked up to the borderline to carcinoma in situ (Figs 3 4) The adenomas varied in size from microscopic collections of glands up to several millimeter large sessile or pedunculated tumours A special form of adenoma was also observed the adenomatous diverticulum (Fig 6) These diverticula were often very small some of them were visible directly on necropsy others could be detected only by microscopy

Adenocarcinoma in situ To this entity were assigned all adenomatous tumours with a marked epithelial and glandular atypia of such a degree that the diagnosis carcinoma was justified but with no evidences of infiltration

Infiltrating adenocarcinoma Two macroscopically different forms of infiltrating carcinoma were found The first one was a polypoid exophytic carcinoma with cauliflower like growth or a carcinoma interspersed in an adenomatous polyp

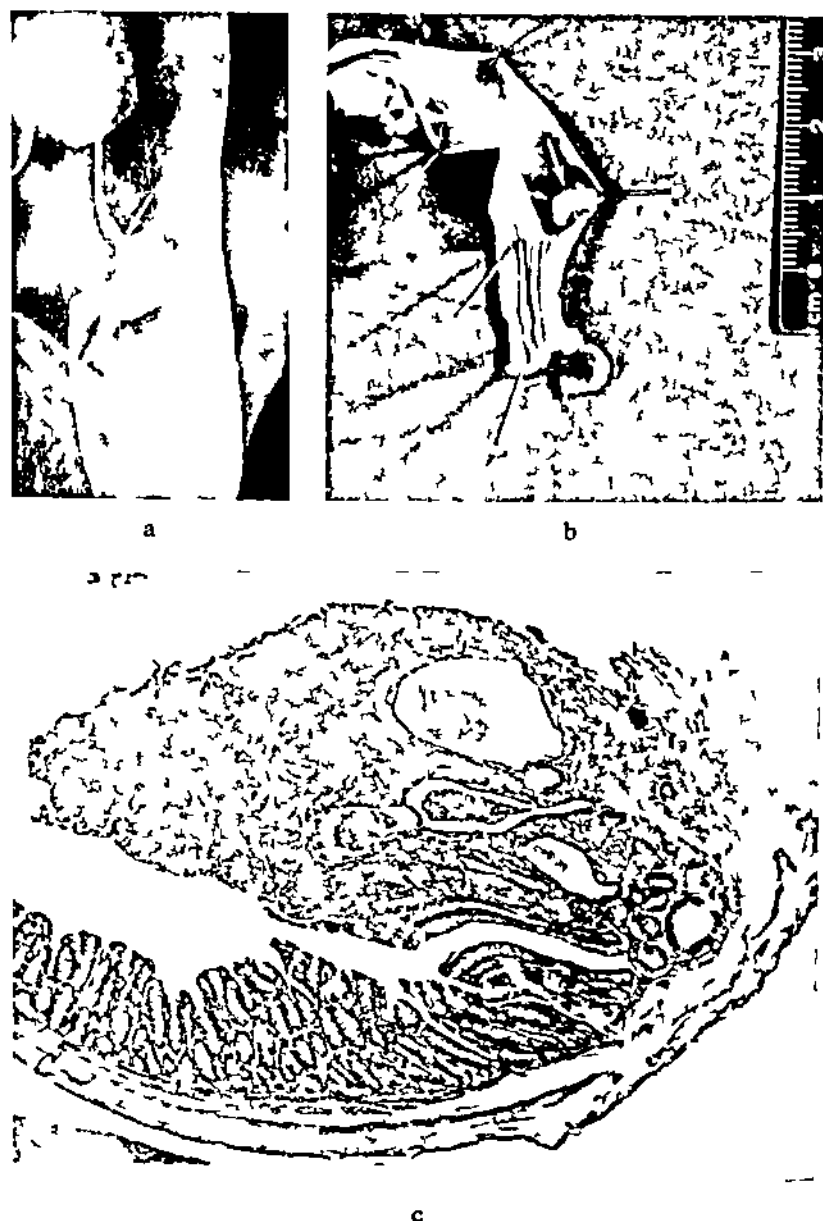


Fig 2 Inflammatory polyp of a type resembling a human retention (juvenile) polyp in the distal part of the colon in a DMH treated rat a) At radiography the polyp was considered as an infiltrating carcinoma b) Photograph of the specimen c) Microphotograph Severe inflammation in the stroma Htx E × 35

(Fig 4 b) The other form was a plaque like or ulcerating type of tumour visible as a slightly elevated irregular and circumscribed area of the mucosa (Fig 2 b) The latter form will further on be referred to as endophytic carcinoma (LINDSTRÖM et coll 1978 b) The adenocarcinomas were characterized as tumours with marked epithelial and glandular atypia and with infiltrative growth In a few cases this infiltra



Fig 3 Carcinoma and benign polyp revealed at 2 con ecutive double contrast examinations a) Carcinoma (→) in the distal part of the main flexure at the first examination b c) One month later a small benign polyp (↔) in the proximal part of the main flexure The carcinoma has increased *in size d)* Photograph of the colon The proximal part of the colon to the right The polyp (↔) measures 1 mm 2 mm and the carcinoma (→) 5 mm 8 mm

tion was confined to the lamina propria but in the majority of cases the infiltration affected the muscularis mucosae or deeper parts of the bowel wall

No abnormalities were observed in 45 animals The abnormal findings at autopsy and microscopy were as follows 10 benign polyps (9 animals) 10 carcinomas in situ (8 animals) 114 infiltrating carcinomas (52 animals) 3 cases of lymphoid plaques and 3 with ulceration inflammation and adenomatous diverticulum respectively (6 animals)

Radiology

No abnormalities were observed in the controls confirmed at necroscopy

The findings made in 424 double contrast colon examinations performed in the



Fig 4 Same case as in Fig 3 Microphotograph a) The polyp (tubular adenoma) Htx E ×88 b) Part of the polypous carcinoma with infiltration in the submucosa of the pedicle Htx E ×35

carcinogen treated animals are summarized and compared with the final diagnoses in the Table It appears that of 41 animals considered as normal at double contrast examination 3 were found to have a carcinoma at the following necropsy and microscopy Two of these carcinomas were not possible to detect radiographically They were located in the rectum and thereby superimposed by the balloon of the Foley catheter necessary for the examination In another animal a small plateau carcinoma of the descending colon escaped detection This carcinoma appeared at autopsy as a

Table

Correlation of radiologic and microscopic examinations in 114 rats treated with DMH and MNNG At microscopy 134 tumours were diagnosed of 141 tumours observed at double contrast examination

Radiology	Microscopy					
	Normal	Non tumorous lesion	Benign polyp	Carcinoma in situ	Carcinoma	Total
Normal	41				(3)**	41
Non tumorous lesion						
Benign polyp		2*	9	2		13
Malignant polyp		3		3	3	9
Carcinoma	4*	1	1*	5*	108	119
Total	45	6	10	10	114	

Overdiagnosis
** Underdiagnosis
Underlined figures indicate correspondence between radiology and microscopic diagnosis



Fig 5



Fig 6a



Fig. 6b

Fig 5 In the main flexure a benign polyp 6 mm × 6 mm with a short stalk

Fig 6 Adenomatous diverticulum in the distal part of the main flexure in a DMH treated rat a) Roentenogram, b) Microphotograph Htx E 27

flat elevation of the mucosa without any sharp margins to the surroundings In retrospect a slight indentation of the barium-coated mucosa was present (Fig 1)

In the remaining 73 carcinogen treated animals 141 abnormalities were registered at the double contrast examination These examinations included both under and overdiagnosis of lesions when compared with the final diagnoses at microscopy (Table)

In 4 cases the radiologic diagnosis of a carcinoma could not be confirmed at autopsy The bowel of these animals contained fecal material which erroneously was considered as tumour lesions also in retrospect a tumour could not be excluded

In another 12 cases radiologic overdiagnosis was made Thus of 3 cases of lymphoid plaques 2 were considered to be adenomas and one a carcinoma Three benign lesions (one adenomatous diverticulum one local hyperplasia and one inflammatory ulceration) were considered as carcinomas in situ In one animal a lesion suggested to be a carcinoma was shown to be an inflammatory polyp (Fig 2) In 5 cases a polypoid lesion was observed and considered to be malignant but microscopy revealed a carcinoma in situ without any signs of infiltrative growth

Five lesions were underdiagnosed (Table) Of these 2 classified as benign at the



Fig 7



Fig 8a



Fig 8b

Fig 7 Carcinoma in situ in the proximal part of the colon

Fig 8 MNNG treated rat In the distal part of the colon a carcinoma with radiologic appearance indicating infiltration a) A p and b) lateral projection

double contrast examination were shown to be carcinomas in situ while 3 lesions considered to be malignant polyps were classified as carcinomas at microscopy

In summary of 57 cases considered normal or benign at radiography 5 were malignant of 128 cases considered malignant 9 were benign Thus a correct diagnosis of abnormality or benign lesion was made in 52 cases and a correct diagnosis of malignant lesion in 119 cases The radiographic differentiation between normal/benign and malignant findings was correct in 171 cases (92 %) and not correct in 14 cases (8 %)

Radiographic criteria of colonic lesions Based on the present results and those given in the previous report (ROSENGREN) radiologic criteria of colonic lesions are made up

Adenomas The appearance of the benign small adenomatous polyp less than 2 mm in diameter was characteristic En face it appeared annular often with a more elliptic than rounded shape and with a distinct and smooth internal margin (Figs 3 4) The external border was also sharp and the contrast ring so formed was uniform in width In other projections it appeared as an asymmetric ellipse The tangential image of the base of the polyp was also informative In this projection the true polypoid tumour of the colonic mucosa had a base which more or less was in continuity with the mucosa Such a mucosal attachment of a polyp indicated a true benign adenoma



Fig 9 DMH treated rat Infiltrating carcinoma in the distal part of the colon a) Double contrast examination b) Photograph of the specimen

In polyps larger than 2 mm in diameter the outer margin of the image was distinct while the inner one appeared more irregular with increasing size (Fig 5) In a tangential projection of the tumour base generally contrast coating of the tumour base appeared as an indentation This contrast coating was smooth regular and unbroken Such an appearance was also observed in adenomas with a short stalk The appearance of the inflammatory polyp was the same as that of the adenomatous polyp

The adenomatous diverticulum was usually small or microscopic in size and it was demonstrated only once (Fig 6)

Adenocarcinoma in situ The prerequisite for radiologic diagnosis of carcinoma in situ was that the atypic glandular formation was localized at the surface of the tumour either at the base or at the top In the films it often had the appearance of a benign adenoma with a slightly irregular part of the tumour surface (Fig 7) The base of the tumour could resemble that of a benign polyp but sometimes that of a malignant one In other cases it could not be differentiated from a small infiltrating carcinoma (Table)

Infiltrating adenocarcinoma of exophytic type The tumour surface was irregular (Fig 8) In en face projection the contrast coating of the tumour was totally or partially irregular and could be absent in some parts Contrast spots of varying size on the surface of the tumour represented filling of crypts in a cauliflower like tumour These spots occurred mostly in infiltrative growths An indentation convex to the lumen appeared in the tangential projections Numerous spinose in place inconspicuous strips of contrast coating occurred at the margin of the indentation



a b

Fig 10 Same case as in Fig 9 a) Microphotograph The whole tumour is an adenoma with foci of infiltrating adenocarcinoma Htx E 12 b) Part of the tumour with focus of adenocarcinoma infiltrating into the submucosa Htx E × 35

These criteria indicated a peripheral or basal infiltrative growth Central infiltration within adenomas could not be demonstrated at radiography

Infiltrating adenocarcinoma of endophytic type This form of carcinoma in its early stages appeared only as a slight indentation of the mucosa protruding towards the lumen of the bowel En face the tumour surface had an irregular appearance as in polypoid infiltrating carcinoma (Figs 9, 10) In the later stages it appeared as a broad based more distinct elevation of the mucosa with a regular contrast coating

Discussion

From the results obtained it is clear that the double contrast examination offers excellent means for demonstrating abnormalities in the colon The diagnostic errors due to artifacts indicate the need for a proper cleansing of the bowel by enemas before the examination Therefore it must be emphasized that an adequate enema technique is of the utmost importance in minimizing diagnostic errors due to bowel contents (ANDRÉN et coll 1955) The technique for cleansing the bowel with enemas was described previously together with a detailed description of the examination technique (Part I ROSENGREN 1978)

By far the most common artifacts confused with polypoid tumours was fecal material Generally the differentiation between tumours (polypoid tumours and carcinomas) and fecal material was easy The latter had an irregular shape weak contrast coating and were mobile from one point to another within the bowel in



Fig 11 Fecal material adherent to the wall of the distal part of the colon a) A p and b) lateral projections

different positions of the animal However sometimes fecal material was adherent to the walls of the colon and repeated examinations were necessary to obtain a proper diagnosis (Fig 11) In the present material 10 examinations had to be repeated due to retained fecal material In 4 animals fecal material was misdiagnosed as carcinoma In these 4 animals repeat double contrast examinations could not be performed since the rats died soon after the examination

Another source of error in the diagnosis of polyps was air bubbles A thin peripherally fading margin of contrast medium surrounded the air bubbles Sometimes air bubbles were seen with many small satellite bubbles clustered close to a larger one This appearance in addition to the failure to demonstrate a base attachment to the wall of the bowel and the mobility from one point to another made it possible to differentiate air bubbles from polyps

Occasionally long slender defects occurred in the barium representing strands of mucus The appearance of these strands was typical and made their identification simple

To obtain a thin coating of barium on the mucosa it is necessary to distend the colon as much as possible Such a technique alone enables differentiation of true mucosal abnormalities from artifacts If the insufflated amount of air is insufficient the mucosal folds of the transverse and descending colon render the evaluation of the films extremely difficult, and several indentations of the mucosa may simulate tumours This source of error can usually be avoided when the indentation caused by the fold has another site in other projections Such an examination should be repeated In the present material 5 examinations had to be repeated due to insufficient air insufflation

A proper performance of the double contrast examination makes it possible to

detect very small changes in the mucosa of the colon During the elaboration of the method experience was gained from the examination of 55 Wistar rats of both sexes treated with the same carcinogenic agents as the present animals (ROSENGREN) Autopsy findings and microscopy of the lesions demonstrated in the films supplied considerable further information The criteria of different colon lesions obtained previously (Part I) were adjusted for the diagnostics in the present material

These experiences and the present results have made it possible to present the basis of a diagnostic system in order to define colonic lesions in the rat The normal anatomy microscopy and radiographic appearance of the colon in the rat is discussed in another report (LINDSTROM et coll 1978 b)

In the rat even small tumours are easily diagnosed in an optimally cleansed colon The adenomas are of varying size from microscopic glandular aggregations with epithelial atypias to several millimeter large tumours with plateau like polypoid form broad based or pedunculated They are usually demonstrable by double contrast examination if they are larger than 1 mm in diameter They arise as flat plaques of tissue which grow uniformly expanding with regular surface A well demarcated base visible in the tangential projection is characteristic of a true polyp The demonstration of the base may be used to differentiate the polyp from bowel contents not attached to the wall

The adenomatous diverticulum of the rat colon and its malignant development has previously been described (POZHARISSKI 1973)

One large polyp with marked inflammatory stromal reaction and cystic dilated glands resembled microscopically the so called retention polyp in man It was radiologically considered as a carcinoma because of an irregular indentation at the base which microscopically corresponded to a marked inflammatory stromal reaction (Fig 2 a b)

The malignant polyp i e the adenomatous polyp with a carcinoma in situ was difficult or impossible to differentiate from a benign adenomatous polyp

At radiography the diagnosis of infiltrating carcinomas cannot be made unless indications of invasiveness are demonstrated The irregular indentation at the base of the tumour is a reliable indication of malignancy and is practically always an indication of invasive growth (Figs 9 10) Theoretically a local inflammatory process may produce an irregular base indentation but the present material included only one such case The irregular indentation is however so common in carcinoma that it must be regarded as a definite indication of malignancy Nevertheless if absent this does not exclude malignancy It is often impossible to get a tangential projection of the whole base of the tumour If so the irregular surface of the tumour visible only at double contrast examination is a valuable indication of malignancy Around the malignant tumour a well demarcated but irregular boundary of contrast appears This distinguishes a malignancy from the benign adenomatous polyp and the carcinoma in situ A tumour with an irregular indentation at the base in profile projection and an irregular outline en face must be regarded as a carcinoma On the surface

of the tumour there may be spots of contrast of varying size due to filling of crypts in the cauliflower like tumour Such a rough surface instead of the smooth one is more common in malignant tumours In the adenomatous diverticulum such contrast spots were found However a smooth surface does not exclude malignancy

The distribution and appearance of the different tumours as well as the spread of metastases are discussed in another report (LINDSTROM et coll 1978 a)

The double contrast examination is profitably used for follow ups in attempts to correlate immunologic parameters with the appearance growth and possible regression of colon carcinomas (STEELE et coll 1975)

From this point of view the accuracy of the double contrast examination of the rat was shown to be very high (92%) No comparable figures are available for the accuracy of the double contrast examination in human beings, but due to technical reasons it is probably considerably lower

The radiographic criteria of different lesions set forth are probably valid also in examinations of man

SUMMARY

Experimentally induced tumours in the colon of the rats were examined with a double contrast method Carcinogenic agents were administered to 114 rats The development of the colonic tumours was recorded by repeated examinations In the dead rats a thorough necropsy was performed The radiographic and microscopic results were correlated and the radiographic appearances of colonic tumours were evaluated The diagnostic accuracy of the radiographic method in distinguishing between benign and malignant lesions was 92 per cent

ZUSAMMENFASSUNG

Experimentell induzierte Kolon Tumoren bei Ratten wurden mit der Doppelkontrast Methode untersucht Karzinogene Substanzen wurden an 114 Ratten verabreicht Die Entwicklung der Kolon Tumoren wurde durch wiederholte Untersuchungen verfolgt Tote Ratten wurden einer genauen Autopsie unterzogen Die radiologischen und mikroskopischen Resultate wurden mit einander in Beziehung gesetzt und das rontgenologische Bild der Kolon Tumoren wurde festgestellt Die diagnostische Genauigkeit der Rontgen untersuchung zwischen benignen und malignen Lasionen zu unterscheiden betrug 92 Prozent

RESUMÉ

Des tumeurs induites expérimentalement sur le colon de rats ont ete examinees par une methode en double contraste Des agents carcinogenes ont été administres a 114 rats Le développement de tumeurs du colon a eté suivi par des examens repetes Les rat morts ont ete soigneusement autopsies Les résultats radiographiques et microscopiques ont éte confrontés et les aspects radiologiques des tumeurs du colon ont eté juges L exactitude diagnostique de cette methode radiologique pour distinguer les lesions benignes des lesions malignes a été de 92 pour cent

REFERENCES

ANDRÉN L FRIEBERG S and WELIN S Roentgen diagnosis of small polyps in the colon and rectum Acta radiol 43 (1955) 201

DRUCKREY H PREUSSMANN R MATZKIES F und IVANKOVIC S Selektive Erzeugung von Darm Krebs bei Ratten durch 1 2 Dimethyl hydrazin Naturwissenschaften 54 (1967) 285

EKELUND G LINDSTROM C and ROSENGREN J E Appearance and growth of early carcinomas of the colon rectum Acta radiol Diagnosis 15 (1974) 670

LINDSTROM C ROSENGREN J E and EKBERG O (a) Experimental colonic tumours in the rat III Induction time distribution and appearance of induced tumours To be published in Acta radiol Diagnosis 19 (1978)

— — and FORK F T (b) Colon of the rat An anatomic histologic and radiographic investigation To be published in Acta radiol Diagnosis 19 (1978)

MARTIN M S MARTIN F MICHIELS R BASTIEN H JUSTRABO E BORDES M and VIRY B An experimental model for cancer of the colon and rectum Digestion 8 (1973) 22

POZHARISSKI K M Tumours of the intestines *In* Pathology of tumours in laboratory animals Vol 1 pt 1 p 119 Lyon International Agency for Research on Cancer 1973

ROBERTS D C Tumours of the large intestine of mammals other than man *In* Cancer of the rectum P 43 Edited by C E Dukes Livingstone London 1960

ROSENGREN J E Experimental colonic tumours in the rat I Preparation and technique of examination Acta radiol Diagnosis 19 (1978) 353

SPJUT H J and SPRATT J S Endemic and morphologic similarities existing between spontaneous colonic neoplasms in man and 3 2-dimethyl-4-aminobiphenyl induced colonic neoplasms in rats Ann Surg 161 (1965) 309

STEELE G JR, SJÖGREN H O ROSENGREN J E LINDSTROM C G LARSSON A and LEANDOER L Sequential studies of serum blocking activity in rats bearing chemically induced primary bowel tumors J nat Cancer Inst 54 (1975) 959

FROM THE DEPARTMENT OF DIAGNOSTIC RADIOLOGY (DIRECTOR U RUDHE) HUDDINGE SJUKHUS S 141 86 HUDDINGE THE DEPARTMENT OF DIAGNOSTIC RADIOLOGY (DIRECTOR B NORDENSTROM) KAROLINSKA SJUKHUSET, S-104 01 STOCKHOLM AND THE DEPARTMENT OF PATHOLOGY (DIRECTOR B ENGFELDT) HUDDINGE SJUKHUS S 141 86 HUDDINGE SWEDEN

MALIGNANCY OF COLONIC POLYPS

Diagnosis and management

N GABRIELSSON S GRANQVIST H OHLSEN and P SUNDELIN

The incidence of polyps in the colon reported in the literature varies In two major Swedish investigations polyps appeared in 12 5 per cent of cases one series was roentgenographic (WELIN 1967) and the other post mortem (EKELUND 1963) Colonic polyps have a clinical significance principally due to their widely testified risk of malignant degeneration (MORSON 1971 EKELUND et coll 1974) As the incidence of malignant tumours of the colon is rising in a large part of the western world the interest is focussed on the early diagnosis of malignancy and precancerous polyps The detection of polyps involves great difficulty as symptoms or signs may not be present (GRINNEL & LANE 1958) Radiography of the colon is basic for the purpose Many authors consider that the double contrast technique permits even very small colonic polyps to be discovered (WILLIAMS et coll 1974 WELIN & WELIN 1976) Colonoscopy is probably an even better means of diagnosis but is too complicated to be a primary method (MARKS 1974) However polyps may be overlooked even at endoscopy particularly when the polyp is situated immediately above a sharp bend of the intestine (LAUFER et coll 1976) With polyps revealed at roentgen examination but situated beyond the range of the rectoscope attempts have been made by means of various radiologic criteria to estimate the risk of malignancy (YOUKER

Submitted for publication 1 July 1977

REFERENCES

ANDRÉN L FRIEBERG S and WELIN S Roentgen diagnosis of small polyps in the colon and rectum Acta radiol 43 (1955) 201

DRUCKREY H PREUSSMANN R MATZKIES F und IVANKOVIC S Selektive Erzeugung von Darm Krebs bei Ratten durch 1 2 Dimethyl hydrazin Naturwissenschaften 54 (1967) 285

EKELUND G LINDSTROM C and ROSENGREN J E Appearance and growth of early carcinomas of the colon rectum Acta radiol Diagnosis 15 (1974) 670

LINDSTROM C ROSENGREN J E and EKBERG O (a) Experimental colonic tumours in the rat III Induction time distribution and appearance of induced tumours To be published in Acta radiol Diagnosis 19 (1978)

— — and FORK F T (b) Colon of the rat An anatomic histologic and radiographic investigation To be published in Acta radiol Diagnosis 19 (1978)

MARTIN M S MARTIN F MICHIELS R BASTIEN H JUSTRABO E BORDES M and VIRY B An experimental model for cancer of the colon and rectum Digestion 8 (1973) 22

POZHARISSKI K M Tumours of the intestines *In* Pathology of tumours in laboratory animals Vol 1 pt 1 p 119 Lyon International Agency for Research on Cancer 1973

ROBERTS D C Tumours of the large intestine of mammals other than man *In* Cancer of the rectum P 43 Edited by C E Dukes Livingstone London 1960

ROSENGREN J E Experimental colonic tumours in the rat I Preparation and technique of examination Acta radiol Diagnosis 19 (1978) 353

SPJUT H J and SPRATT J S Endemic and morphologic similarities existing between spontaneous colonic neoplasms in man and 3 2 dimethyl-4 aminobiphenyl induced colonic neoplasms in rats Ann Surg 161 (1965) 309

STEELE G JR SJÖGREN H O ROSENGREN J E LINDSTRÖM C G LARSSON A and LEANDOER L Sequential studies of serum blocking activity in rats bearing chemically induced primary bowel tumors J nat Cancer Inst 54 (1975) 959

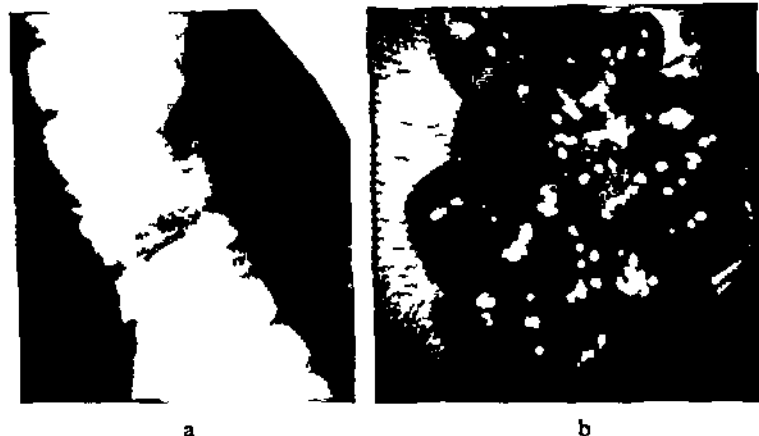


Fig 2 a) Polyp in the colon descendens with apparent smooth surface at radiography b) Same polyp depicted through the colonoscope after endoscopic polypectomy Very irregular surface

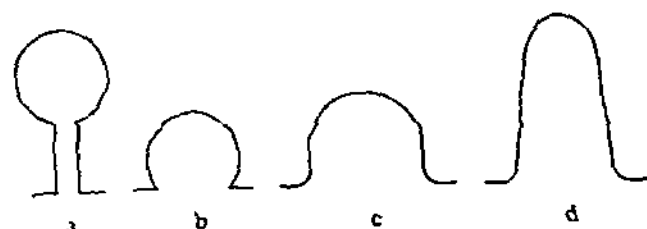


Fig 3 Types of attachment of polyp to the mucosa a) Pedunculated b) intermediate type c d) sessile

of the radiologic appraisal of polyps by comparison with the endoscopic findings The intention is also to compare the morphology of the polyp as estimated at colonoscopy with the microscopic appearance of the resectate In addition the microscopic appearance of the polyp removed in toto is compared with that of the preoperative endoscopic biopsy in order to evaluate the capacity of biopsy to correctly predict the nature of the polyp

Material and Method

The material consisted of 200 microscopically examined polyps removed from the colon in 154 patients (Table) In addition these patients had 130 very small polyps which could not be microscopically examined in their entirety as they were coagulated or extirpated in pieces They are therefore not included in the primary material No patient had more than 10 polyps and there was no case of familial adenomatous polyposis Roentgen examination of the colon and colonoscopy were performed on all patients

The roentgen examinations were performed at several hospitals and were carried out with conventional technique in 56 per cent and with double contrast technique in 19 per cent of the cases In the remaining 25 per cent both methods were used the double contrast examination being the supplementary one The films were re-evaluated in detail in order to obtain a uniform assessment The following criteria of malignancy of polyps set up by WELIN (1967) and WELIN & WELIN (1976) have been applied in both the roentgenologic and endoscopic assessments (1) Irregular surface (2) broad base (3) size exceeding 1 cm (4) indentation (i e protrusion) of intestinal wall at the base of the polyp The rate of growth could not be determined as most polyps once discovered were removed without delay

The colonoscopy was performed with a long fiberscope (Olympus) in order to examine the entire large bowel After biopsies had been taken from the polyps in most cases 158 polyps were extirpated with a diathermic snare The remaining 42 polyps were removed by surgery following laparotomy In the latter cases either the colonoscopy was performed before the adoption in 1972 of the technique of polypectomy via a colonoscope or the base of the polyp was considered to be too wide to allow endoscopic polypectomy

All biopsies and removed polyps were examined on sections stained with haematoxylin-eosin taken at three levels in the paraffin-embedded material




Fig 4 a) Pedunculated polyp with short and thick stalk b) Same polyp with a false image of a long stalk which was caused by a mucosal fold resulting from peristaltic traction on the polyp

The polyps were classified into neoplastic and non neoplastic according to criteria described by MORSON & DAWSON (1972) The non neoplastic group consisted principally of hyperplastic (metaplastic) polyps It also included hamartomas lipomas and inflammatory pseudopolyps The neoplastic polyps are customarily divided into mainly adenomatous and mainly villous This classification is somewhat arbitrary as polyps with mixed structure are very common Therefore in this investigation it was refrained from dividing the neoplastic polyps into different types

Dysplasia–malignancy

In the neoplastic polyps the deviations from the normal mucosal structure were graded as follows

Mild dysplasia The crypts are more densely packed than in normal mucosa and vary in form and size Most of the epithelial cells have retained polarity and the proportion of goblet cells is only slightly reduced No apparent atypia

Moderate dysplasia The crypts are more atypical and densely packed in many cases back to back The epithelial cells lie densely in the crypts with lost polarity and the number of goblet cells is relatively small In the epithelial cells some nuclear atypia exists

Severe dysplasia The crypts lie densely The epithelial cells form several layers in the crypts and exhibit no polarity The nuclear atypia is so advanced that the epithelial cells cannot be distinguished from malignant cells

Radiographic appearance

	Pedunculated	Intermediate	Sessile
Sessile	1 C1 D1	5 C2 D12	7 C7 D6
Intermediate	16 C16 D15	15 C15 D13	9 C7 D13
Pedunculated	43 C48 D34	3 C2 D6	1 C2 D0

Endoscopic appearance

Fig 5 Comparison of the appearance of the base of the polyp at radiography and colonoscopy All figures given in per cent Large figures represent total series and small figures separate conventional (C) and double contrast technique (D)

Infiltration For all polyps it has been recorded whether the epithelial cells infiltrate the underlying tissue In case of infiltration its depth in the mucosa has been noted Polyps with infiltration only in the mucosal stroma but without perforation of the lamina muscularis mucosae have been denoted intramucosal carcinoma These polyps have also exhibited severe dysplasia and epithelial cell bridges

Results

Comparison roentgenography–endoscopy

In assessing the surface appearance of the polyp a division was made into three groups smooth slightly irregular or lobulated and very irregular The roentgenologic and endoscopic assessments have been compared and the results are shown in Fig 1 In 57 per cent of the cases the assessments accorded Moderate discrepancies were present in 42 per cent the most common being that a smooth polyp on the film proved to have a slightly irregular surface at endoscopy The roentgen examination was entirely misleading in only 1 per cent of cases as it showed smooth polyp which at endoscopy proved to have a very irregular exterior (Fig 2) This endoscopic finding occurred in 21 cases in 10 of which radiography revealed a smooth or slightly irregular surface (false negative) Furthermore 5 polyps had an irregular surface at radiography which was found to be wrong at endoscopy (false positive) The choice of roentgenographic technique whether conventional or double contrast had no certain bearing on the reliability of assessment of the appearance of the polyp surface

Depending on their attachment to the mucosa the polyps were divided into three groups pedunculated sessile and intermediate (Fig 3) The previously often used

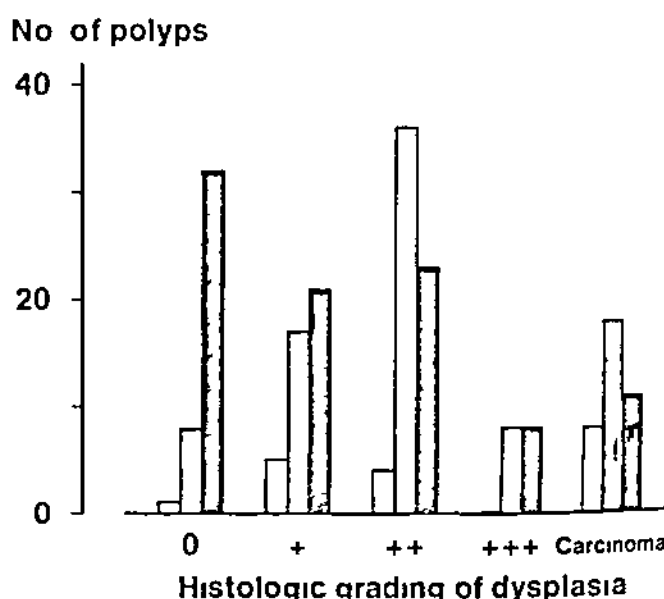


Fig 6 Correlation of polyp surface and histologic grading of dysplasia in 200 polyps ▭ Very irregular surface ▭ Slightly irregular surface ■ Smooth surface – Mild dysplasia – – Moderate dysplasia – + – Severe dysplasia

definition of broad based polyp—base greater than height—has not been applied because the height of a polyp may vary according to whether it rests against the wall or is freely suspended in the lumen Furthermore according to the previous definition certain types of polyps would be wrongly defined as non broad based (Fig 3 d) Polyps which are broadest at their attachment to the mucosa are broad based according to the definition used No assessment of the length of the stalk of the polyp when present was made on the film Such an estimate is uncertain because the peristalsis may dislodge the polyp so that the mucosa at the base of the stalk is lifted up in a fold which may erroneously be taken to represent part of the stalk (Fig 4)

The roentgenologic and endoscopic assessments of the base of the polyp were compared and the results are presented in Fig 5 In 65 per cent of cases the roentgenologic and endoscopic findings agreed entirely In 33 per cent roentgenography gave rise to somewhat erroneous assessments such as for example that a pedunculated polyp was considered as belonging to the intermediate group In a small number of cases (2%) roentgenography gave a seriously erroneous concept of the base of the polyp a pedunculated polyp being taken to be broad based or vice versa In the assessment of the appearance of the base no certain difference existed between examinations by conventional and double contrast techniques

The size of a polyp was difficult to assess by endoscopy Instead in 90 cases the polyp has been directly measured after removal of the polyp These measurements have been compared with the largest diameter of the polyp measured on representative films In about one third of the cases measurement on the film gave *10 to 30* per cent too high figures in relation to real size which roughly corresponds to the magnification present In 11 cases the polyp was considerably larger (more than 50%)




Fig 7 Polyps of intermediate type Accumulation of contrast medium in the furrow around the base a) Profile b) En face

on the film and in 12 cases smaller than by direct measurement In about one fourth of the cases accordingly the size measured on the film was misleading

Protrusion of the base of polyps into the intestinal lumen could be detected roentgenologically only in 4 cases all polyps proved to be malignant This criterion is poorly adapted to endoscopic assessment but in 3 of the cases other indications of polypous carcinoma were present at endoscopy

Comparison endoscopy–microscopy

The microscopic classification of the 200 polyps is given in the Table Of the 159 neoplastic polyps 26 had intramucosal carcinoma while 11 had carcinoma infiltrating through the lamina muscularis mucosae Of the remaining 122 neoplastic polyps 16 had severe 63 moderate and 43 mild dysplasia

The surface of the polyp assessed as smooth slightly or very irregular has been correlated with the degree of epithelial dysplasia found at microscopy (Fig 6) Polyps with very irregular surface contained carcinoma to a large extent The incidence of cancerous polyps was smaller in the groups with smooth or slightly irregular surface As the two latter types were considerably more common the number of malignant polyps was greater in these groups

The polyps classified in respect to their attachment to the mucosa into broad based and pedunculated and an intermediate group with a groove around the base of the polyp without distinct stalk (Fig 7) were compared with the degree of epithelial dysplasia (Fig 8) It appears that broad based polyps were fairly uniformly distributed between the various microscopic groups Malignancy was present in 23 of the

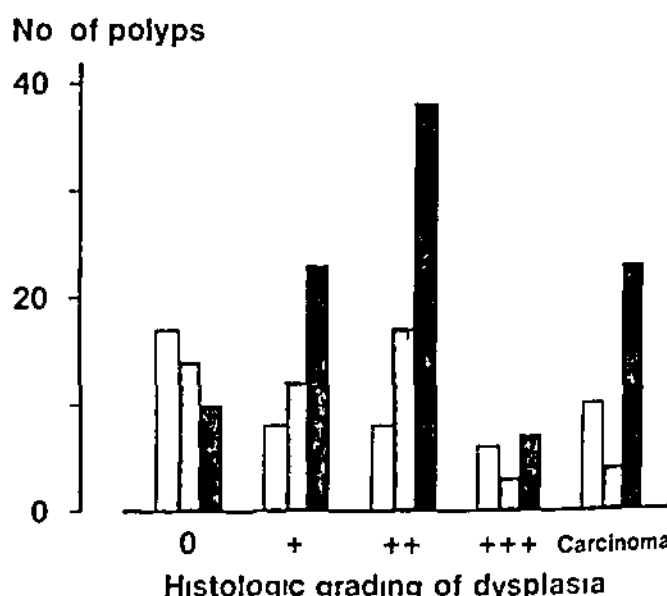


Fig 8 Correlation of mucosal attachment of polyps and histologic grading of dysplasia in 200 polyps [dotted box] Sessile polyps [white box] Intermediate type [black box] Pedunculated polyps + Mild dysplasia ++ Moderate dysplasia +++ Severe dysplasia

101 pedunculated polyps The incidence of pedunculated polyps in the entire malignant group was 23 out of 37 (62 %)

The size of polyps was correlated to the degree of dysplasia (Fig 9) In case that the size had been only grossly estimated but not actually measured at polypectomy measurement was made on the microscopic specimen This procedure involves a source of error as some shrinkage of the polyp may occur in the process of fixation of the specimen The polyps varied in size regardless of microscopic grouping Thus many large polyps were non neoplastic or only had slight to moderate dysplasia Five polyps smaller than 10 mm had intramucosal malignant foci The group of deep-growing carcinoma however contained no polyps smaller than 10 mm (Fig 10)

The number of concurrent criteria of malignancy (very irregular surface broad base size 10 mm or larger) applicable on each polyp was noted The presence of several positive criteria gave greater accuracy in the assessment of the risk of malignancy of the polyp The proportion of polyps with intramucosal or deep growing carcinoma for combinations of criteria appears in Fig 11 In the 5 polyps for which all three criteria were fulfilled malignancy was present With two concurrent criteria 7 of 24 polyps were malignant More than one criterion of malignancy occurred in 12 of 37 malignant polyps In 57 polyps in which none of the three criteria of malignancy were fulfilled intramucosal carcinoma was nevertheless present in 4 cases

Comparison biopsy-polyp in toto

One or more biopsies have been taken from 143 polyps before the polypectomy The microscopic appearance of the biopsy specimen was compared with that of the

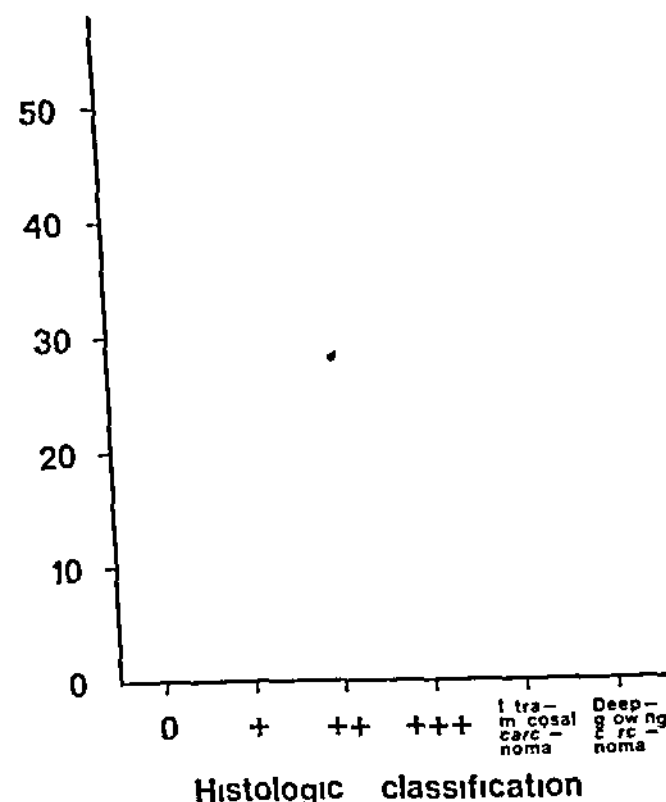


Fig 9 Size of polyps correlated to histologic grading of dysplasia and carcinoma in 200 polyps

entire polyp in 79 per cent total agreement was found including the degree of dysplasia In 8 cases in all of which only one biopsy was taken the material was too scanty to allow a definite assessment In 16 of the 23 polyps for which the biopsies were not representative only minor deviations in the grading of dysplasia were present Biopsies from 3 of the 7 other polyps gave misleading information as to whether the polyp was neoplastic or hyperplastic The remaining 4 polyps contained malignant foci but biopsies showed only grave dysplasia In the other polyps with cancerous growth from which biopsies were obtained of assessable quality a correct diagnosis was established

Reliability of roentgenologic diagnosis of polyps

In the present series 36 of 200 polyps were not found at radiography this was true even on re-evaluation of the films and in spite of the fact that their locations were then known These polyps were small and only one exceeded 10 mm in diameter The proportions of overlooked polyps were roughly equal for the two radiographic


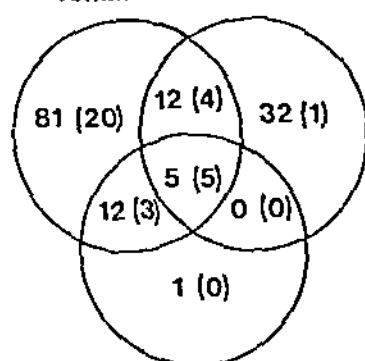


Fig 10 Smooth polyp with a diameter of 10 mm in sigmoid colon Microscopy revealed deep growing carcinoma restricted to the head of the polyp

methods Re evaluation of some 10 additional cases revealed so uncharacteristic appearances that a definite diagnosis of the polyp was impossible without knowledge of the results of colonoscopy Apart from the 36 at radiography not detected but extirpated and microscopically examined polyps colonoscopy revealed an additional 130 very small polyps (< 5 mm) which also had not been discovered at radiography Assessable biopsies from 127 of the latter showed that 32 per cent were neoplastic Such polyps were initially removed with biopsy forceps Later they have been coagulated by hot biopsy or with a diathermic snare It has not been possible to examine the very small polyps microscopically in their entirety as only fragmentary material was procured

Follow up of cases of polyps endoscopically removed from the colon

A second colonoscopy has been performed 6 months later if microscopy of the polyp showed malignant cells but no infiltration of the stalk or grave dysplasia Uncertain radicality present at endoscopic or microscopic examination has also necessitated repeat colonoscopy within 6 months regardless of the degree of dysplasia of the polyp The same principle has been applied to cases with several endoscopically removed polyps In the remaining cases with neoplastic polyps repeat radiography preferentially by double contrast technique has been made within one year No recurrence of the polyp has been revealed although new or primarily overlooked polyps have occasionally been discovered The follow up of polyp cases in the event of a negative first roentgenologic or endoscopic examination has included a roentgen examination every second year



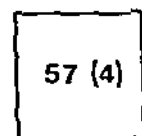


Fig 11 Three criteria of malignancy applied on 200 polyps Figures within parentheses represent cancerous polyps

Discussion

Incidence of malignancy in polyps of the colon

The distribution of polyps with different histologic structure conforms mainly with that previously reported (WILLIAMS et coll 1974 WOLFF & SHINYA 1973) The proportion of polyps with malignancy given in different series is often difficult to compare as the criteria of malignancy may vary and the composition of materials differs in respect of the size of the polyps In the present polyps microscopically examined in toto intramucosal carcinoma was present in 13 per cent and deeper infiltrating carcinoma in 5 5 per cent If polyps with a diameter less than 10 mm are excluded the corresponding figures were 19 and 10 per cent The incidence of invasive malignancy with deep infiltration is close to the figure resulting from compiled data of materials of polyps diagnosed at colonoscopy (OTTENJANN 1972) Intramucosal carcinoma is a somewhat controversial entity and is not generally considered as a true carcinoma as it does not metastasize It is not proved that further growth of intramucosal carcinoma invariably will result in deep infiltration of adjacent tissue but it is highly probable that this often occurs

Roentgenologic criteria of malignancy of polyps in the colon

A number of roentgenologic criteria indicating malignancy of polyps have been described The criteria are based on a detailed evaluation of the morphology of the polyp but the reliability of this procedure has not been analysed Whether the radiologic appearances accurately reflect the morphology of the polyp was evaluated by comparison with the findings at colonoscopy It has been maintained that roentgenography by double contrast technique provides a better means for analysis of

the polyp in detail In the present material where one third of the examinations were made by double contrast technique, no definite difference was found in this respect The roentgenographic examinations were carried out at several hospitals the majority of which do not use double contrast technique except in selected cases The double contrast examinations have therefore not always been performed under optimum conditions which might explain why better results with this method were not obtained

Assessment of the surface of polyps is important as polyps with very irregular surface are often malignant In 15 cases roentgenography gave falsely positive or negative information as to whether the polyp was greatly irregular or not This is probably due to adherent scybala which apparently smooth out the surface of a very irregular polyp or wrongly give the impression of irregularity of a smooth polyp The roentgenologic differentiation between smooth and slightly irregular surface is difficult but presumably has no clinical significance as the incidence of malignancy does not appreciably differ between these groups

The base of the polyp was to some extent not correctly evaluated on the films in more than one third of the cases but was entirely erroneous in only a few cases It is concluded that roentgen examination of the colon is a relatively unreliable method for assessment of the base of a polyp Malignancy of pedunculated polyps is believed to be uncommon but in the present material no less than two thirds of the malignant polyps were pedunculated This is partly due to the fact that the group with stalked polyps is over represented by selection but also that malignancy is relatively common in pedunculated polyps amounting to 23 per cent of the cases This means that assessment of the base of a polyp to estimate its risk of malignancy has a limited significance On the other hand with large sessile polyps a correct roentgenologic assessment is of value for their management since they often cannot be radically removed at endoscopy

Customarily the risk of malignancy of a polyp is assessed by measuring its size on the film Even a small increase of size between two examinations has been considered of significance (YOUKER et coll 1968) However possible sources of error in estimation of size have not always received proper attention Even taking into account the degree of magnification present at roentgen examination poor agreement was *found in one fourth of the cases between the size measured on films* and on extirpated polyps The chief source of error is deficient cleansing of the colon with scybala adhering to the polyp despite several enemas In all 7 cases of a polyp entirely covered with scybala it was situated in the caecum (Fig 12) A possible explanation is that the peristalsis of the caecum fails to massage the polyp and loosen the faecal material from it A further source of error is any asymmetry of the polyp which makes it difficult to measure the largest diameter on the film In the individual case therefore estimation of the risk of malignancy based on roentgenologically measured size is of doubtful value Furthermore the correlation between real size and malignancy of polyps is rather weak Admittedly no carcinoma with invasion beyond the lamina



a



b



c



d

Fig 12 a) Large polyp in the caecum with slightly irregular surface b) Same polyp at endoscopy completely hidden by faecal material c) On removal of some faecal material with biopsy forceps a small area of the mucosa of the polyp was uncovered d) After complete removal of the scybala the polyp in contrast to its roentgenographic appearance was found to be smooth and small

muscularis mucosae in polyps smaller than 10 mm occurred in the present series but a few such small polyps contained intramucosal carcinoma In addition there were many large polyps with only mild or no dysplasia at microscopy The occurrence of several criteria of malignancy of a polyp implies a greater risk of malignancy However more than one criterion existed only in one third of the malignant polyps

Endoscopic biopsy

The reliability of microscopic diagnosis from biopsy of rectal polyps has previously been reported and revealed conformity with that of the surgically removed polyp in 88 per cent of cases (HELLWIG & BARBOSA 1959) A similar comparison with biopsies taken through a colonoscope from 50 polyps showed somewhat poorer agreement as the significant histologic image was present in 74 per cent (LIVSTONE et coll 1974) In the present series as well the agreement was less (79°) than for biopsies taken through a rectoscope presumably because biopsy at colonoscopy yields smaller pieces of tissue In the present material only one biopsy was usually taken in order to avoid undesirable haemorrhage before extirpation of the polyp with a diathermic snare Despite the small pieces of tissue obtained from each polyp the representativity of the biopsy is surprisingly good In clinical practice therefore biopsies from colonic polyps give a better idea of the nature of the polyp than that obtained by assessment of various criteria of malignancy at radiography However, biopsies have the serious limitation that malignant foci may escape detection For an entirely reliable diagnosis the extirpated polyp must be carefully examined microscopically

Diagnosis of small polyps in the colon

In roentgenologic diagnosis of polyps deficient preparation with poor cleansing of the bowel often causes great problems In the present material all polyps of a diameter exceeding 10 mm except one have been discovered some admittedly only on re review of the films after the polyp had been revealed at colonoscopy A larger number of polyps with a diameter of 5 mm or less have not been possible to detect at radiography These polyps which were often very small are not without clinical interest as they revealed neoplastic changes including dysplasia to a fairly large extent (32°) Still higher figures have been found in a histologic investigation of polyps up to 5 mm in size 86 per cent being neoplastic and dysplasia occurring in 55 per cent (PAGTALUNAN et coll 1965) Other authors have reported 90 per cent of colonic polyps 3 mm in diameter or less to be hyperplastic (LANE et coll 1971) The relatively high incidence of small neoplastic polyps in the present series can not be directly applied to an unselected material as all patients have also had large polyps which were extirpated and in most cases were neoplastic The fact that polyps often occur in multiplicity—50 per cent in the present series—and that small polyps which are difficult to diagnose at radiography are not seldom neoplastic means that after detection of a polyp colonoscopy should cover the entire colon in the search for additional polyps

Management after polypectomy

The decisive factor governing the subsequent management of a case is the microscopic diagnosis In the event of malignant cells in a polyp the depth of penetration and the degree of differentiation of the malignant tissue must be established Spread from an intramucosal malignancy in a colonic polyp has never been reported Once the lamina muscularis mucosae has been penetrated a risk of spread of metastases is present This risk is small when the carcinoma has not reached the stalk of the polyp Metastases from such polyps have been reported only in some 20 cases (SHATNEY et coll 1976) Therefore when the malignant tissue is restricted to the head of the polyp endoscopic polypectomy is usually satisfactory as the risk of spread to local lymph nodes is considerably smaller than the operative mortality linked to colonic resection In the relatively rare cases of a poorly differentiated carcinoma confined to the head of the polyp local resection is advisable (SHATNEY et coll 1976 CARDEN & MORSON 1964 FENOGLIO et coll 1973) When the malignant cells extend to the stalk the polypectomy must be supplemented by local resection of the intestine (BIGELOW & WINKELMAN 1974 SHATNEY et coll 1976) This applies also to invasive carcinoma in a broad based polyp

Recurrence after colonoscopic polypectomy seems to be rare Even when the polyp has not been radically removed histologically viable tumour tissue may not remain owing to the coagulation at the site of resection (CARDEN & MORSON 1964 LIVSTONE et coll 1973) A greater risk is presumably new colonic polyps in another site and this risk is especially great if multiple polyps were present primarily Follow up of polypectomized patients is thus necessary but need probably not be done as often as was the case in the present series It takes presumably about 2 years before any new polyps have attained a size to be definitely diagnosed at radiography in view of the fact that the time for doubling of the volume of a colonic polyp has been calculated to be between 120 and 480 days (FIGIEL et coll 1965) For this reason a repeat roentgen examination within less than 2 years would appear to serve no purpose As colonoscopy is a relatively complicated technique it probably must be reserved for cases in which radical resection is doubtful and after extirpation of malignant polyps In the latter cases the risk of appearance of new polyps with grave dysplasia is considered to be especially serious When endoscopically non resectable polyps with invasive carcinoma have been removed by resection of the involved intestine regular colonoscopic and roentgen examinations should be made at fairly short intervals (about 6 months) during the first 2 years when the risk of local recurrence is greatest (GABRIELSSON et coll 1976)

Conclusions

Roentgen examination of the colon is the primary method for detection of polyps It is probably not as reliable as colonoscopy but is considerably less complicated On the other hand roentgenologic estimation of the potential risk of malignancy by

detailed evaluation of the appearance of the polyp would seem to have lost its significance A comparison between roentgenographic and endoscopic findings shows that roentgenography gives rise to errors in the assessment of the size and surface of polyps and of their attachment to the mucosa in a considerable number of cases Therefore when a polyp has been discovered by roentgenography colonoscopy should be performed except in the small number of cases of indentation of the base of the polyp which suggests invasive growth in the intestinal wall and renders radical endoscopic polypectomy impossible The entire colon should be examined due to the high frequency of multiple polyps Furthermore as the gross appearance of polyps is comparatively poorly correlated to their histologic appearance all detected polyps should be removed or coagulated whenever possible This applies also to very small polyps as these too are to a great extent neoplastic Biopsies from polyps are valuable when the polyp cannot be radically removed endoscopically The reliability of assessment of the histology of a polyp by means of biopsy is fairly high Surgery may therefore be refrained from if the polyp is non neoplastic with mild dysplasia of the polyp this also applies to patients of high surgical risk After extirpation of neoplastic polyps regular follow up examinations must be made Roentgenography of the colon at 2 year intervals should usually be sufficient In the case of malignant polyps the examinations should be more frequent and include colonoscopy

SUMMARY

The risk of malignant degeneration of colonic polyps has traditionally rested on various roentgenographic criteria such as broad base irregular surface and size larger than 1 cm With the aim of facilitating the choice of treatment of colonic polyps an appraisal is made of the morphology of 200 polyps removed from 154 patients The results of barium enema and double contrast techniques are compared with those obtained at colonoscopy Radiography is found to have considerable shortcomings in evaluation of the appearance of the polyp As the correlation of the gross morphology of the polyp to histology is weak endoscopic polypectomy should be performed whenever possible

ZUSAMMENFASSUNG

Das Risiko einer malignen Degeneration von Kolonpolypen stutzt sich traditionell auf verschiedene rontgenologische Kriteria wie eine breite Basis eine unregelmassige Oberflache und eine Grosse von mehr als 1 cm Mit dem Ziel die Wahl der Behandlung von Kolonpolypen zu erleichtern wird eine Auswertung der Morphologie von 200 Polypen die von 154 Patienten entfernt worden waren durchgefuhrt Die Resultate von Barium Einlaufen und der Doppelkontrast Technik werden mit denen bei der Kolonoskopie erhaltenen verglichen Die Rontgenuntersuchung erwies sich als mit nicht unbedeutenden Fehlern bei der Auswertung der Polypen behaftet Da die Korrelation der Morphologie der Polypen zur Histologie schwach ist sollte wenn uberhaupt möglich eine endoskopische Polypektomie vorgenommen werden

RESUME

Le danger de dégénérescence maligne des polypes du colon a ete base traditionnellement sur différents critères radiographiques tels que la largeur de la base d implantation l irregu

larité de la surface et les dimensions superieures a 1 cm Pour faciliter le choix du traitement des polypes du colon les auteurs ont fait une etude de la morphologie de 200 polypes enleves a 154 malades Ils comparent les resultats du lavement baryte et des techniques en double contraste avec les resultats de la colonoscopie La radiologie a des insuffisances considérables en ce qui concerne l appreciation de l aspect du polype Etant donné que la corrélation entre la morphologie macroscopique du polype et l histologie est faible la polypectomie endoscopique devrait etre faite le plus souvent possible

REFERENCES

BIGELOW B and WINKELMAN J Polyps of the colon and rectum Cancer 17 (1974) 1177

CARDEN A and MORSON B Recurrence after local excision of malignant polyps of the rectum Proc roy Soc Med 57 (1964) 559

EKELUND G On cancer and polyps of colon and rectum Acta path microbiol scand 59 (1963) 165

— LINDSTROM C and ROSENGREN J Appearance and growth of early carcinomas of the colon rectum Acta radiol Diagnosis 15 (1974) 670

FENOGLIO C KAYE G and LANE N Distribution of human colonic lymphatics in normal hyperplastic and adenomatous tissue Gastroenterology 64 (1973) 51

FIGIEL L FIGIEL S and WIETERSEN F Roentgenologic observations of growth rates of colonic polyps and carcinoma Acta radiol Diagnosis 3 (1965) 417

GABRIELSSON N GRANQVIST S and OHLSEN H Recurrent carcinoma of the colon in the anastomosis diagnosed by roentgen examination and colonoscopy Endoscopy 8 (1976) 47

GRINNEL R and LANE N Benign and malignant adenomatous polyps and papillary adenomas of the colon and rectum An analysis of 1 856 tumors in 1 335 patients Int Abstr Surg 106 (1958) 519

HELLWIG A and BARBOSA E How reliable is biopsy of rectal polyps? Cancer 12 (1959) 620

HULTBORN K A The causal relationship between benign epithelial tumors and adenocarcinoma of the colon and rectum Acta radiol (1954) Suppl No 113

LANE N KAPLAN H and PASCAL R Minute adenomatous and hyperplastic polyps of the *colon Divergent patterns of epithelial growth with specific associated mesenchymal* changes Gastroenterology 60 (1971) 537

LAUFER I SMITH N and MULLENS E The radiological demonstration of colorectal polyps undetected by endoscopy Gastroenterology 70 (1976) 167

LIVSTONE E GREENE F and TRONCALE F Colonoscopic polypectomy a caveat New Engl J Med 288 (1973) 1304

— TRONCALE F and SHEAHAN D The predictive value of fractional biopsies of colonic polyps Gastrointest Endoscopy 66 (1974) 733

MARKS B Flexible fiberoptic colonoscopy J Amer med Ass 228 (1974) 1411

MORSON B Precancerous conditions of the large bowel Proc roy Soc Med 64 (1971) 959

— and DAWSON I Gastrointestinal pathology Blackwell scientific publications Oxford 1972

OTTENJANN R Colonic polyps and coloscopic polypectomy Endoscopy 4 (1972) 212

PAGTALUNAN R DOCKERTY M JACKMAN R and ANDERSON M The histopathology of diminutive polyps of the large intestine Surg Gynec Obstet 120 (1965) 1259

SHATNEY C LOBER P GILBERTSON V and SOSIN H Management of focally malignant pedunculated adenomatous colorectal polyps Dis *Col Rect 19 (1976) 334*

WELIN S Results of the Malmo technique of colon examination J Amer med Ass 199 (1967) 119
— and WELIN G The double contrast examination of the colon experiences with the Welin modification Georg Thieme Verlag Stuttgart 1976
WILLIAMS C HUNT R LOOSE H RIDDEL H SAKAI Y and SWARBRICK E T Colonoscopy in the management of colon polyps Brit J Surg 61 (1974) 673
WOLFF W and SHINYA H A new approach to colonic polyps Ann Surg. 178 (1973) 367
YOUKER J WELIN S and MAIN G Computer analysis in the differentiation of benign and malignant polypoid lesions of the colon Radiology 90 (1968) 794

Book review

RADIODIAGNOSTIC OBSTETRICAL Second edition By P Magnin E P Naudin and J M Thoulon 341 pages with 182 illustrations and 17 tables Expansion Scientifique Française Paris 1975

Though the aim of this work is nowhere explicitly stated it is clearly intended for post graduate students and clinical reference The first half deals with radiation risks hysterosalpingography fetal radiography localisation of the placenta and diagnostic ultrasound the balance being devoted to pelvimetry Each chapter begins with short historical notes and proceeds with basic physical facts followed by clinical applications and conclusions Clinical aspects are given excellent presentation two of the authors being obstetricians The division into paragraphs is extensive in general this makes for clarity but sometimes is slightly excessive and in some instances apparent clarity conceals contextual inconsistency The use of proper names for anatomic data and radiologic methods is frequent but mercifully explanations are usually supplied Evocative metaphors such as ligne noire for subcutaneous fat and flocons de neige for disseminated ultrasound echoes are also far from uncommon The bibliography covers the literature in French comprehensively but also gives useful references to non French writers

Radiation risks receive ample presentation and discriminating discussion backed up by detailed and up-to date graphs and tables The chapter on hysterosalpingography surveys the most frequent probable causes of premature abortion as well as examination after cesarian section in early pregnancy and for diagnosis of trophoblastic tumors and extra uterine pregnancy The account of premature abortion is too slender to replace text books on hysterosalpingography while the remaining topics are either esoteric or obsolete

The authors conscientiously note that radiology has been almost entirely substituted by ultrasound in fetal examinations and localisation of the placenta The section on fetal radiography devoting nearly fifty pages to the determination of the number of fetuses gestational age intra uterine death anomalies and diabetes is impaired by unsatisfactory illustrations and reflects inadequate techniques The situations in which radiology must sometimes still be resorted to (primarily anomalies and diabetes) require optimum image quality obtainable only by rigorous attention to detail Similar reservations would apply to the account of localisation of the placenta dealing with soft tissue placentography only in this case however deficiencies are of no practical consequence since ultrasound is at present the method of choice The chapter on ultrasound much more important than the preceding ones is comprehensive and well illustrated compensating for most of the imperfections in some of the preceding chapters After an instructive survey of the physical principles of ultrasound the authors give a thorough description of B scan and A scan applications with special emphasis on follow up of the gestational age by cephalometry

The large section devoted to pelvimetry is elaborate clear and instructive with a detailed presentation of the anatomy and physiology Physical and geometric conditions are given a comprehensive elementary analysis which actually should be familiar to radiologists but probably will serve as a welcome recapitulation Graphs and tables are excellent A large number of methods are described and discussed—although without mention of a few recent developments—and finally evaluated as to their respective advantages However the authors attach remarkably small importance to the outlet leaving it mainly to clinical estimation due to difficulties in measuring the sagittal distance on their films This attitude is unjustified since correct application of conventional methods always permits measurements Here too the illustrations are rather poor

Thus while the imperfections are mainly confined to topics of minor interest the important chapters those on pelvimetry and ultrasound are so instructive that they make this volume a welcome contribution to the literature

Lars Ohlson

FROM THE DEPARTMENT OF DIAGNOSTIC RADIOLOGY (DIRECTOR PROF B NORDENSTRÖM)
KAROLINSKA SJUKHUSET S-104 01 STOCKHOLM SWEDEN

SOFT TISSUE ABNORMALITIES AT FRACTURE OF THE SCAPHOID

M HAVERLING and M SYLVÉN

In a retrospective review of 100 films demonstrating scaphoid fractures in children under 15 years of age MUSSBICHLER (1961) observed characteristic soft tissue alterations indicating an effusion in the joint TERRY & RAMIN (1975) in a series of 438 adults with injuries of the wrist found 15 cases with fracture of the scaphoid Two of these had no soft tissue abnormalities in the scaphoid fossa 9 had effusion in the soft tissue and 4 bulging of the joint capsule Using medium sensitive industrial roentgen film REICHMANN et coll (1974) obtained satisfactory demonstration of the soft tissues around the finger joints and DEICHGRABER & OLSSON (1975) of those around the shoulder joints

These experiences would indicate that provided a satisfactory technique is used the soft tissues within the scaphoid fossa may contribute to the diagnosis of fractures of the scaphoid in adults similarly to what has been reported for children

Material and Method

A retrospective review of films from 150 patients with suggested carpal bone fractures was performed No patient was under 15 years of age Routinely four projections were used postero anterior lateral anterior oblique and posterior oblique Most examinations were performed with CEA Non Screen Medical X ray Film Mammor X Type L or with CEA Non Screen Medical X ray Film Singul X and only 2 with Kodak Non Screen Medical X ray Film

Submitted for publication 28 October 1976

3 — 785835

Fig 1 Normal case Soft tissue structures of the scaphoid fossa well defined

Fig 2 Fracture of os triquetrum Effusion in the scaphoid fossa following rupture of the joint capsule



Fig 1



Fig 2

Results

The patients were divided into 4 groups

Group 1 45 patients without fracture Three were examined with a less satisfactory technique and 6 in inadequate projections In 36 cases the soft tissues could be evaluated and of these 11 patients had abnormal and 25 normal soft tissues (Fig 1)

Group 2 37 patients with fracture of carpal bones other than the scaphoid Six were examined in such a way that the condition of the soft tissues could not be evaluated and 5 in inadequate projections Of the remaining 26 cases 16 had abnormal soft tissues and 9 expansion of the joint (Fig 2) In 10 cases no abnormalities were detected

Group 3 52 cases primarily considered to have fracture of the scaphoid The soft tissues in the scaphoid fossa could not be evaluated in 10 of them and 2 other patients were considered to be free of fracture on a repeat examination 14 days later These latter cases had normal appearances of the soft tissues The remaining 40 patients had soft tissue abnormalities Eighteen of them had swelling of the joint (Fig 3)

Group 4 16 patients were considered to be free of fracture at the first examination but at a repeat examination 10 to 14 days after the actual trauma a fracture of the scaphoid was diagnosed Three were examined with a non optimum technique which did not permit an analysis of the soft tissues within the scaphoid fossa One finally was shown to have no fracture All the remaining 12 cases had soft tissue abnormalities 5 having expansion of the joint at the time of the first examination (Fig 4)

Films with satisfactory demonstration of the soft tissues within the scaphoid fossa were obtained in 115 cases Industrial film was used in 75 of them (Table)

Table

Type of film and quality of the views in the different examination groups

	Group 1		Group 2			Group 3		Group 4	
Type of film	CEA Type L	CEA Singul X	CEA Typ L	CEA Singul X	Kodak	CEA Type L	CEA Singul X	CEA Type L	CEA Singul X
Satisfactory views	29	7	18	6	2	20	22	8	5
Non-satisfactory views									
Incorrect projections	4	2	1	4		1	7	—	—
Under exposed film	1	2	2	4		1	1	—	3

Discussion

MUSSBICHLER reviewing a consecutive series of 100 children with fracture of the scaphoid was able to demonstrate soft tissue abnormalities in the scaphoid fossa in all of them. This reflects a satisfactory examination technique; the evaluation of the films was also facilitated by comparison with films of the contralateral wrist. In the material reported by TERRY & RAMIN 15 cases had fracture of the scaphoid; 2 of these were without soft tissue abnormalities in the scaphoid fossa. The reason for this result is not discussed by the authors, but they mention that at an examination within the first hour or more than 5 days after trauma the soft tissues may have a normal appearance. Presumably one hour is necessary for enough fluid or blood to accumulate in the scaphoid fossa to cause demonstrable alteration of the soft tissues; after 5 days edema or hemorrhage may subside.

In the present series 117 of 150 examinations demonstrated the soft tissues of the scaphoid fossa satisfactorily, 85 being performed with Mammor X Type L film. Thirty three gave no information on these tissues. This discouraging result was due to incorrect projections in 19 cases and not enough penetrating radiation in 14, the latter having been exposed on Mammor X Type L film in 4 cases and on Singul X film in 10.

In 53 cases with fracture of the scaphoid and examined with a satisfactory technique alterations of the soft tissues within the scaphoid fossa were demonstrated. This indicates that examination of the scaphoid in correct projections and with an exact exposure technique will make the soft tissue structures of the scaphoid fossa



Fig 3




Fig 4

Fig 3 Fracture of scaphoid with bulging joint capsule

Fig 4 Fracture of scaphoid Effusion in the scaphoid fossa following rupture of the joint capsule

available for evaluation Any type of Non Screen medical film may be used but the quality of the views obtained with Mammor X Type L film was superior to that with the other type of film

Conclusions With optimum technique including the use of industrial film absence of soft tissue abnormalities in the scaphoid fossa virtually excludes injury to the carpal bones If the examination reveals abnormal soft tissues but no fracture the wrist should be examined about 15 days later if a clinical suggestion of fracture still persists

SUMMARY

In a retrospective examination of the films from 53 cases with fracture of the scaphoid it was possible to demonstrate soft tissue alterations within the scaphoid fossa All these cases were examined adequately i e with correct projections and satisfactory penetrating exposure A somewhat higher quality of the views was obtained on industrial film

ZUSAMMENFASSUNG

Bei einer retrospektiven Untersuchung von Filmen von 53 Fällen mit Fraktur des Os scaphoideum war es möglich Weichgewebe Veränderungen innerhalb der Fossa navicularis festzustellen Alle diese Fälle wurden adäquat untersucht dass heisst mit richtigen Projektionen und einer hinreichend harten Exponierung Eine etwas bessere Qualität der Bilder wurde mit industriellen Filmen erhalten

RÉSUMÉ

L examen retrospectif des radiographies de 53 cas de fracture du scaphoïde a permis de mettre en évidence des lésions des parties molles dans la fosse scaphoïde Tous ces cas avaient été examinés de façon appropriée c est à dire avec des incidences correctes et une pénétration suffisante Des radiographies de qualité un peu meilleure ont été obtenues sur un film industriel

REFERENCES

DEICHGRABER A and OLSSON B Soft tissue radiography in painful schoulder Acta radiol Diagnosis 16 (1975) 393

MUSSBICHLER H Injuries of the carpal scaphoid in children Acta radiol 56 (1961) 361

REICHMANN S DEICHGRABER E STRID K G HEYMAN F and STRAND T Soft tissue radiography of finger joints Acta radiol Diagnosis 15 (1974) 439

TERRY D W and RAMIN J E The navicular fat stripe A useful roentgen feature for evaluating wrist trauma Amer J Roentgenol 124 (1975) 25

FROM THE DEPARTMENT OF DIAGNOSTIC RADIOLOGY (DIRECTOR PROF A EVENSEN)
ULLEVAAL SYKEHUS OSLO, NORWAY

AMIPAQUE AS CONTRAST MEDIUM FOR INTRAOSSEOUS PHLEBOGRAPHY

A SKJENNALD

Intravenous phlebography of the lower limbs may be impossible to perform on patients with ulcerations around the ankle or on the distal part of the leg mainly because of oedema and difficulties in applying compression to the ulcerated soft tissues

These difficulties may be overcome by intraosseous injection of the contrast medium although this procedure usually is accompanied by intense pain elucidated by the hypertonic medium

However the new contrast medium Amipaque (metrizamide) is non ionic and isotonic in low iodine concentrations (166 mg I/ml) and only moderately hypertonic in higher iodine concentrations Amipaque in a concentration of 280 mg I/ml has an osmolality of 0 456 mol/kg compared to 1 46 mol/kg for a meglumine metrizoate salt with an equal iodine content Amipaque has proved to be an excellent contrast medium in neuroradiology because of its low toxicity (OFTEDAL 1975) and this suggests that Amipaque could be a suitable contrast medium also for intraosseous administration

The present investigation was performed to determine whether the pain following intraosseous injection of Amipaque would be more tolerable to the patient than that of an ionic contrast medium with equal iodine content

Submitted for publication 12 January 1977



Fig 1 Filling of superficial and deep veins of the leg by injection into the calcaneus Arrow indicates skin ulceration

Material and Method

Four patients all with varicose ulcers around the malleoli were randomized in a double blind investigation using Amipaque 260 mg I/ml and Isopaque 260 mg I/ml (Nyegaard Norway) Isopaque 260 is mainly a sodium salt of metrizoic acid containing only small amounts of other salts

A local anesthetic was injected into the skin and subcutaneous tissue down to the periosteum on the lateral aspect of the calcaneous The puncture of the bone was performed with a bone marrow needle under fluoroscopy After the needle had been positioned as centrally in the bone as possible the position of the needle was confirmed by aspiration of bone marrow With an excentric position of the needle it was found that the pain increased

The intention was to inject 35 ml of contrast medium at each examination The phlebography was performed randomly Amipaque was injected first in one half of the patients Isopaque first in the other Neither the patients nor the radiologist knew which contrast medium was being injected

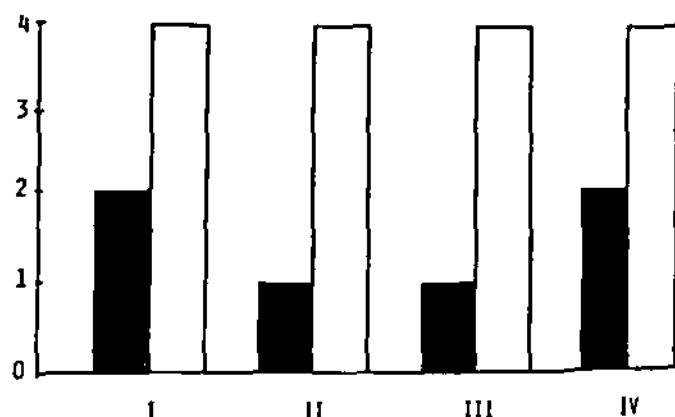


Fig 2 Black columns represent the degree of pain produced by Amipaque and white columns by Isopaque in 4 patients 0 = no pain 1 = mild pain 2 = moderate pain 3 = severe pain 4 extreme pain

After 10 min the examination was repeated with the other contrast medium using the same amount and the same injection speed The position of the puncture needle was not altered The injection time was 7 to 8 s If the puncture needle was centrally positioned the injection met no significant resistance (Fig 1) Pain was assessed subjectively by the patient at the time of injection and graded from 0 to 4 according to Fig 2

Results

After having examined 4 patients it was obvious that the difference in the degree of pain experienced by the patients between the two contrast media was so great that it was felt to be unethical to continue the double blind investigation The number of patients in whom a comparison between the two contrast media was made was therefore limited to 4

In only one of the 4 patients could the planned volumes of both media be injected In 3 patients the injection of Isopaque 260 had to be stopped because of intense pain All the injections with Amipaque could be completed without any intolerable pain

At present 30 patients have been examined with Amipaque Intraosseous administration of Amipaque has also been used in the diagnosis of deep vein thrombosis if puncture of a superficial vein was impossible Satisfactory filling of the deep veins of the leg and the femoral vein was obtained in most cases using 35 ml (Fig 3)

Discussion

Aspelin & Almén (1976) Salvesen (1973) and Skalpe et coll (1973) have demonstrated that the intravenous toxicity of Amipaque is very low compared with a water soluble ionic contrast medium Almén et coll (1977) also found a significant reduction in pain following injection of Amipaque in femoral angiography Animal experiments with Amipaque (Almén 1973 Salvesen Skalpe et coll) have shown



Fig. 3 Contrast medium in the deep veins in the popliteal and femoral regions

a reduction of side effects and complications compared to ionic contrast media SALVESEN found the LD$_{50}$ for Amipaque with an iodine concentration of 360 mg I/ml to be approximately 18 g I/kg body weight while Isopaque with an equivalent iodine concentration had an LD$_{50}$ of 10 g I/kg body weight AMUNDSEN et coll (1973) injected Amipaque intravenously into human volunteers without evidence of side effects or complications

The increase of the intraosseous pressure during the injection should be the same using the same amount of contrast medium and the same injection speed at the examinations The milder pain after Amipaque could therefore be explained by the lower osmolality compared to Isopaque

ISHERWOOD (1972) reported that bone necrosis may appear following intraosseous injection of contrast medium On the other hand SCHOBINGER (1960) did not observe bone infarction or osteomyelitis in 1 200 examinations but considered the calcaneal approach painful and hazardous nor did LEA THOMAS (1976) observe any bone necrosis in a series of 500 cases

None of the present patients had pain in the heel after the examination In the first 10 patients examined with Amipaque radiography of the calcaneus was performed after 10 months with lateral and axial films No structural abnormalities in the calcaneus were observed

SUMMARY

The degree of pain produced by Amipaque 260 and Isopaque 260 at intraosseous phlebography in patients with varicose ulcerations in the ankle region was compared Amipaque produced less pain than Isopaque No complications or side effects occurred during the observation period of about one year

ZUSAMMENFASSUNG

Die Schmerzen die durch Amipaque 260 und Isopaque 260 bei intraossaler Phlebographie von Patienten mit varikosen Ulzerationen im Knochelgebiet hervorgerufen werden wurden verglichen Amipaque ruft weniger Schmerzen als Isopaque hervor Keine Komplikationen oder Nebeneffekte traten während der Beobachtungsperiode von etwa einem Jahr auf

RÉSUMÉ

L auteur a comparé l intensité de la douleur produite par l Amipaque 260 et par l Isopaque 260 au cours de la phlébographie intra osseuse chez les malades atteints d ulcération variqueuse dans la région de la cheville L Amipaque provoque moins de douleurs que l Isopaque L auteur n a observé ni complication ni effet secondaire durant la période d observation d environ un an

REFERENCES

ALMÉN T Cardiovascular effects of injection of metrizamide and other contrast media into the aortic bulb of cats Acta radiol (1973) Suppl No 335 p 209

— BOIJSEN E and LINDELL S E Metrizamide in angiography I Femoral angiography Acta radiol Diagnosis 18 (1977) 33

AMUNDSEN P FOSS O P GODAL H C and NITTER HAUGE S Intravenous injections of metrizamide into human volunteers Acta radiol (1973) Suppl No 335 p 339

ASPELIN P and ALMÉN T Studies on the acute toxicity of ionic and non ionic contrast media following rapid intravenous injection Invest Radiol 11 (1976) 309

ISHERWOOD I Practical procedures in diagnostic radiology Second edition p 272 Edited by H M Saxton and B Strickland H K Lewis London 1972

LEA THOMAS M Intraosseous phlebography of the lower limbs *In* Complications in diagnostic radiology p 226 Edited by G Ansell Blackwell s Scientific Publications London 1976

OFTEDAL S I Amipaque (metrizamide) A new non ionic water soluble contrast medium for the subarachnoidal space Universitetsforlaget Oslo 1975

SALVESEN S Acute toxicity tests of metrizamide Acta radiol (1973) Suppl No 335 p 5

— Local toxicity of metrizamide on intravascular injection Effects on kidney liver and blood brain barrier Acta radiol (1973) Suppl No 335 p 166

SCHOBINGER R A Intra-osseous venography Grune & Stratton New York London 1960

SKALPE I O LAVENSEN A and STROMME J H Toxicity of metrizamide and metrizoate in selective coeliac angiography An experimental investigation in rabbits Acta radiol (1973) Suppl No 335 p 186

FROM THE SECTION FOR MAXILLO-FACIAL ROENTGENOLOGY CENTRAL HOSPITAL S 961 19 BODEN AND THE DEPARTMENT OF RADIATION PHYSICS UNIVERSITY OF UMEÅ S 901 85 UMEÅ SWEDEN

IMAGE DISTORTION IN NARROW BEAM ROTATION RADIOGRAPHY

A mathematical analysis

U WELANDER and G WICKMAN

The specific projection technique used in narrow beam rotation radiography causes distortion of the image of different objects Three main distortion phenomena have been defined and analysed previously angle distortion (SAMFORS & WELANDER 1974 a) area distortion (SAMFORS & WELANDER 1974 b) and form distortion (SJOBLOM et coll 1975) The mathematical analyses of these phenomena were based on separate deductions of expressions valid for each specific case However the various effects of image distortion in narrow beam rotation radiography are based on the same cause Outside the centre of the sharply depicted object layer different magnification factors are valid for the horizontal and vertical dimensions in the image Therefore it should be possible to deduce in the general form an expression for the relation between any defined object and its corresponding image Such a general expression should facilitate the calculation of the image distortion

Submitted for publication 13 June 1977

Image distortion

Definitions

A = distance tube target to film
D = distance tube target to object
r = distance from the rotation centre of the beam to the centre of the sharply depicted plane in the object object projection radius
Δ_r = positive or negative increment to the object projection radius r
M_d = magnification factor in the horizontal plane i e in the rotation plane
M_h = magnification factor in the vertical plane
d_o = horizontal distance in the object
d_f = horizontal distance in the image the distance d_o projected on the film
h_o = vertical distance in the object
h_f = vertical distance in the image the distance h_o projected on the film

Deduction Principally any object may be described by a series of related height and length measurements This is in its general form expressed by

$$h_o = f(d\ ) \tag{1}$$

The corresponding function valid for the image may be written

$$h_f = g(d_f) \tag{2}$$

The correlation between the functions (1) and (2) is found when the following relations are considered

$$h_o = \frac{h_f}{M_h} \quad \text{and} \quad d_o = \frac{d_f}{M_d}$$

After substitution of the function expressed in eq (1) the following is obtained

$$\frac{h_f}{M_h} = f\left(\frac{d_f}{Md}\right) \quad \text{or} \quad h_f = M_h \ f\left(\frac{d_f}{M_d}\right) \tag{3}$$

From eq (3) it is evident that the relation between the height and length measurements in the image of a specific object or object detail is found by dividing by the magnification factors valid for the vertical and horizontal dimensions respectively This simple rule to transform known object data to their corresponding image is generally applicable

In the inversed form this rule may also be used to calculate object data from known image data Substitution of eq (2) gives

$$h_o M_h = g(d_o M_d) \quad \text{or} \quad h_o = \frac{1}{M_h} \ g(d_o M_d) \tag{4}$$

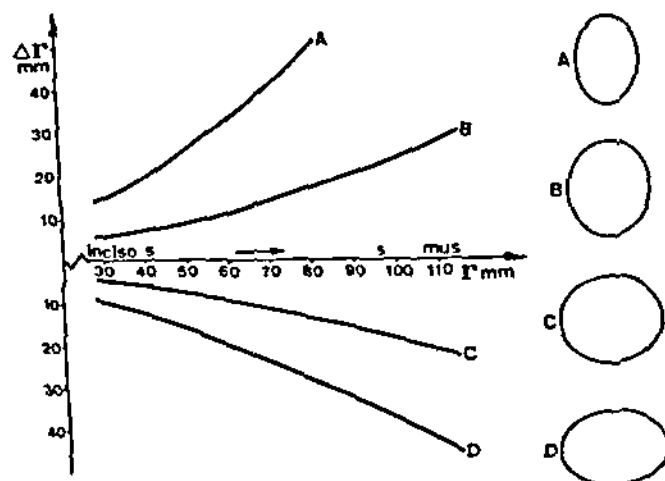


Fig 1 The distance from the centre of object plane Δr by which a circular object should be displaced to give rise to the elliptical image forms illustrated to the right The ellipses are defined by the following ratios a/b A $1/\sqrt{2}$ B $\sqrt{3}/2$ C $2/\sqrt{3}$ D $\sqrt{2}$ The tolerance towards distortion is considerable in the lateral parts of the image where the projection radius is great (The illustrated functions should be valid for the Orthopantomograph 3)

The magnification factors in the vertical and horizontal dimensions are expressed by

$$M_h = \frac{A}{D + \Delta r} \quad \text{and} \quad M_d = \frac{Ar}{D(r + \Delta r)}$$

Application The rules presented to transform data between object and image in narrow beam rotation radiography have many possible applications One example will be given that provides important information regarding the assessment of object morphology in panoramic images exposed with a rotating narrow beam

The circular object is a useful model when analysing the image characteristics with regard to distortion because its effects on the circle are easily perceived and evaluated

In the object the unit circle is expressed by

$$d_o + h_o^2 = 1 \tag{5}$$

Substitution of eq (5) according to the rule for transforming object data to image data eq (3) gives

$$\left(\frac{d_i}{M_d}\right)^2 + \left(\frac{h_i}{M_h}\right) = 1 \tag{6}$$

This substitution transforms the equation for the unit circle to the equation for the ellipse M_d and M_h correspond to the constants of the ellipse a and b respectively Thus the distortion of circular objects gives rise to elliptical image forms It should be observed however that in the specific case when $M_d = M_h$ eq (6) corresponds to the equation for the circle in its general form

$$d_i + h_i = M_d = M_h$$



Fig 2 Detail of a panoramic image which should be reliable with respect to the circular shape of the residual cyst If the patient has not been properly positioned at the exposure distortion effects are often evident in panoramic images Should the image be acceptable with regard to sharpness the distortion effects are limited Such an image is reliable for ordinary clinical demands when the object morphology is assessed

The conclusion drawn must be that when the magnification factors valid for the length and height dimensions are equal the circular object or an object of any other form will be demonstrated by an image which is magnified but not distorted This is the case in the centre of the sharply depicted object plane

As the distortion of a circular object gives an elliptical image certain image characteristics in narrow beam rotation radiography may be directly calculated e g the distance from the centre of the sharply depicted object plane where a circular object should be positioned in order to give an elliptical image of a defined form

An ellipse may be defined by the ratio a/b which means that in narrow beam rotation radiography

$$\frac{a}{b} = \frac{M_d}{M_h} = \frac{r(D + \Delta r)}{D(r + \Delta r)} \tag{7}$$

When the ratio a/b or M_d/M_h is expressed by k and Δr is removed in eq (7) the following is obtained

$$\Delta r = \frac{Dr(1 - k)}{kD - r} \tag{8}$$

It is presupposed that r is constant and also that the ratio between the velocities of the beam and the film is constant during the exposure In elliptical narrow beam rotation methods r varies continually during the exposure and this phenomenon results in more complex distortion effects (SAMFORS et coll 1978)

The solution of eq (8) is exemplified in Fig 1 where Δr is plotted as a function of r for four ellipses The figure demonstrates that in the lateral parts the circular object has to be placed at a considerable distance from the centre of the object plane

in order to give such a distortion that exemplified ellipses are formed In the central part of the object the limits are smaller

Discussion

It is of great importance to know the magnitude of the distortion when evaluating panoramic images with resp ct to the morphology of the object This statement is valid when the shape of a lesion e g a cyst or a tumour is to be assessed It is also of value to know the expected magnitude of the image distortion when estimating for instance the morphology of congenital malformations or post traumatic and post operative deformations

The presented general expression for the relation between object and image form demonstrates in a lucid manner the cause of the distortion phenomena it also demonstrates the essential parameters and their interdependence The deduction of the general expression for the distortion phenomena thus gives a comprehensive explanation for the image formation with regard to morphologic reproduction in narrow beam rotation radiography

In the lateral parts of the image a considerable tolerance towards distortion exists which may be considered of clinical significance The limits are less in the central region However not only the distortion effects but also blurring occur in the image when the object is positioned outside the centre of the object plane which is depicted free of both blurring and distortion The simultaneous effects of blurring and distortion are such that the morphology of an object or an object detail is reliable within ordinary clinical demands when the object or the object detail is demonstrated without significant blurring (Fig 2) This finding is in agreement with the results regarding the reliability of angle measurements in orthopantomography (FRYKHOLM et coll 1977)

For users of narrow beam rotation radiography it should be of value to know the distortion effects to be expected in images exposed by different equipment This could be achieved by presenting the limits within which the object may be positioned away from the centre of the object plane without the occurrence of defined distortion effects (c f Fig 1) When the values of the different parameters are known the expected distortion effects valid for a specific piece of equipment are easily calculated

SUMMARY

A general mathematical analysis of the image distortion in narrow beam rotation radiography has been performed Distortion effects are often evident in panoramic images exposed in clinical practice It is found that in spite of this general experience panoramic images exposed with the aid of a rotating narrow beam are reliable for ordinary clinical demands when the object morphology is to be assessed This statement is valid provided that the object has been properly positioned at the exposure

ZUSAMMENFASSUNG

Eine allgemeine mathematische Analyse der Bildverzerrung bei der Exposition mit einem rotierendem schmalen Strahl wurde vorgenommen Distortionseffekte sind haufig bei Panoramabild Expositionen in der klinischen Praxis vorhanden Es wurde gefunden dass trotz dieser generellen Erfahrung mit Panoramabildern exponiert mit Hilfe eines feinen Strahlengangs diese fur den klinischen Gebrauch geeignet sind wenn die Morphologie des Objektes festgestellt werden soll Diese Feststellung ist gultig unter der Voraussetzung dass das Objekt in der richtigen Lage bei der Exposition steht

RESUME

Les auteurs ont effectué une analyse mathématique genérale de la distorsion d images en radiographie rotatoire avec faisceau étroit Les effets de distorsion sont souvent évidents sur les images panoramiques prises en pratique clinique Ils ont constaté que malgré ce fait général les images panoramiques prises au moyen d un faisceau etroit rotatif sont valables pour les besoins cliniques ordinaires quand il faut étudier la morphologie de l objet Ceci est vrai à condition que l objet ait eté mis convenablement en place pour la prise de la radiographie

REFERENCES

FRYKHOLM A MALMGREN O SAMFORS K A and WELANDER U Angular measurements in orthopantomography Dentomaxillofac Radiol 6 (1977) 77

SAMFORS K A and WELANDER U (a) Angle distortion in narrow beam rotation radiography Acta radiol Diagnosis 15 (1974) 570

— — (b) Area distortion in narrow beam rotation radiography Acta radiol Diagnosis 15 (1974) 650

— — and WICKMAN G Elliptical narrow beam rotation radiography Acta radiol Diagnosis 19 (1978) 129

SJÖBLOM A SAMFORS K A and WELANDER U Form distortion in narrow beam rotation radiography Acta radiol Diagnosis 16 (1975) 565

FROM THE DEPARTMENT OF DIAGNOSTIC RADIOLOGY III (DIRECTOR C G HELANDER)
SAHLGRENSKA SJUKHUSET S-411 32 GOTHENBURG SWEDEN

MEDICHROME FILM AS AN ALTERNATIVE TO SILVER FREE RECORDING SYSTEMS

S REICHMANN C G HELANDER and K SELIN

The raw materials for production of roentgen films are becoming increasingly expensive This certainly applies to the silver halide emulsion since the sources of silver available today will not last for more than a limited period Thus silver prices will not even remain at the high levels of today In this situation it is natural to look for silver free recording media as a substitute for the films used at present Despite a great deal of research rather few results have bene published for reasons of secrecy However some different ways to cope with the silver problem have emerged In the present report these techniques are compared and experiences of colour radiography presented

Magnetic video disc recorders apparently offer a possibility of silver free storage of images but certain disadvantages exist One is the need for play back equipment when the images are to be inspected In the radiologic department this may easily be solved but in the operation theatre out patient department etc similar equipment should also be available since the images must be possible to inspect in these locations as well A change to consistent use of magnetic recordings will certainly be expensive as will the maintenance of all the equipment required A second dis advantage is encountered when simultaneous inspection of many views is required for diagnosis as is usual in tomography and angiography Simultaneous display

Submitted for publication 15 April 1977

of many images inevitably makes the play back equipment complicated, especially if high image quality is desirable

Any type of recording which produces images on film obviously has great advantages As regards silver free recording of this type, electroradiography appears to be the most interesting approach In the form of xeroradiography this principle is utilised in a commercially available system giving full size images on paper The roentgen photons are absorbed in a layer of amorphous selenium which has been electrostatically charged before the exposure When photons are absorbed a local change in the charge is induced so that after the exposure the image information is stored in a charge relief made visible by means of charged pigment powder being sprayed over the plate The image is transferred to paper This recording medium is very resistant to the influence of secondary radiation (SELIN et coll 1975) Therefore the Bucky grid needs not to be used even in skull radiography at 120 kV (SCHERTEL et coll 1974) The main disadvantage of the xerox plates is their sensitivity which is too low Serious attempts are being made to replace the selenium layer by xenon gas under high pressure (JOHNS et coll 1974) or by a fluid containing tin (JOHNS 1976) in order to provide acceptable sensitivity Certain experiences have been published (JOHNS STANTON et coll 1976 WALLNER et coll 1976) However the true clinical usefulness of these methods remains to be established The development for example may be performed by means of powder as in xeroradiography or fluid developer Image quality then differs as to edge enhancement and precision to what extent the useful exposure latitude is affected simultaneously remains unclear Furthermore it is often maintained that electroradiography yields much higher resolution in line pairs/mm than screen film systems of the same speed However no data on the usefulness of this higher resolution appear obtainable It is not clear if it gives more information about the object or if it only leads to improved and more disturbing depiction of the quantum mottle

Even if progress in electroradiography seems promising it appears justified to consider whether the type of recording in use at present may be modified so as to be available even during periods of silver shortage Actually silver halide emulsions constitute a high quality recording medium which has been successively improved during a whole century (ROSE 1973) It should not be expected to be an easy task to replace this recording medium within a not too distant future In principle the usefulness of silver halide emulsions should be expected to increase either if the total amount of silver per m^2 may be lowered or if the turnover of silver may be increased so that the filing of large amounts of silver is avoided The Agfa Gevaert Curix RP 1 which is a conventional black and white film today contains 8 4 g of Ag/m^2 During development about 50 per cent of this amount is dissolved in the fixing bath and may be immediately recovered for new film production (data from the manufacturer) The rest goes into the files remaining there for many years In the following the implications of a lowering of the total silver amount will be considered and subsequently—since this is not a useful solution of the problem—certain techniques for

increa ing the immediate recovery of silver (miniature copying of black and white films and colour radiography) are discussed

The roentgen film quality has been assumed by most authors to be measurable by means of sensitometry it being supposed that the characteristic curve gives valid information in this respect However none of the different parameters of the charac teristic curve (gamma value basal fog level exposure latitude etc) is directly related to the absolute silver content of the film This appears to be the reason why the latter factor has been largely neglected in the general discussion The aim of the film manufacturers seems to imply the making of films with as little silver as possible without the characteristic curve being adversely affected to any great degree However accumulating evidence indicates that there is another property of the film which is not correlated to the parameters of the characteristic curve in any simple way namely the number of grains per unit area (DAINTY & SHAW 1974 SELIN et coll 1975 SELIN & REICHMANN 1977 REICHMANN et coll 1978) The film is equivalent to the memory of a computer since it is the storage component of the imaging system The characteristic curve gives information about how signals are transformed when stored and displayed by the film The number of grains determines how many separate bits of information can be stored in the film per unit area Thus the characteristic curve only gives information about those signals which have been stored in the film Still a number of signals may be left completely unrecorded if the number of grains is insufficient Actually the silver content of modern films appears to be so low as to approach such a state of grain number insufficiency (SELIN & REICHMANN 1977 REICHMANN et coll) The peculiar property of a an image on a film with too few silver grains is a haziness or grayishness which is subjectively experienced as low contrast even if the gamma value is satisfactory If the same object is depicted on a film with abundant silver grains a comparison will reveal that this image is richer in very fine details of low contrast such as fine lung vessels on a chest film The film with too few grains has left many fine details unrecorded obviously due to low storage capacity Complaints are often heard from radiologists dissatisfied with their image quality that they consider their films to be foggy to be lacking in brilliance or contrast One important factor contributing to this effect is a lack of silver grains

Further lowering of the silver content of traditional films thus appears inadvisable However if the average size of the grains is diminished a lowering of the silver content may be achieved without any reduction of grain number Smaller grains lead to decreased sensitivity This means that if the radiographic system can be adapted to films of lower sensitivity without an increased radiation dose to the patient films of diminished silver content may be used In fact this mechanism seems to have stimulated the intensive search for new screen phosphors with higher sensitivity than that of the traditional calcium tungstate Several of the new screen film combina tions based on rare-earth screens (Kodak Ilford) have very fast screens and films of low sensitivity However the high screen sensitivity also leads to a high degree of

screen unsharpness Thus the saving of silver achieved in this way does not leave the image quality unaffected

If silver emulsions are to be used during periods of silver shortage the filing of large amounts of silver should be avoided Still the films should have a silver content not differing too much from that of present day films This means that the immediate silver recovery should be increased from 50 per cent as it is today up to near 100 per cent If black and white films are used the full size images should be reproduced in diminished size in films with very low sensitivity This may yield the necessary number of grains per unit area in the object and yet require only small amounts of silver per image This miniature copy is filed while the original film is left for silver recovery This method is rather expensive since specialists must be employed to handle the copying process At least in Sweden this technique has not gained wide acceptance Image intensifier fluorography with a 70 or 100 mm camera may be looked upon as a special form of miniature copying For this purpose high speed films are used with grain sizes not differing much from those of conventional full size films Thus the number of grains per unit film area cannot be expected to be higher than that of double emulsioned full size films This implies that the grain number per unit area in the object will be more insufficient than in full size radiography It has also been demonstrated (WIHED & REICHMANN unpublished results) that the 70-mm film constitues an important factor limiting image quality due to lack of silver grains If this limitation is to be removed so that an image quality fully comparable to that of a full size image should be obtained films of lower sensitivity containing more grains must be used This in turn requires an increased conversion factor in the image intensifier which is not easily obtained (BIRKEN 1976) Thus fluorography does not provide any general solution to the silver problem

In colour photography a silver recovery of 100 per cent is theoretically possible from the bleaching and fixing solutions There is at present only one radiographic colour film on the market viz Agfa Gevaert Medichrome The film is intended for conventional roll machines hence no bleaching is included in the process From the fixer about 90 per cent of the total silver is recovered (data from the manufacturer) this total being 7 4 g/m The remaining silver is left in the emulsion In principle this silver is recovered if a four bath machine is constructed and a somewhat longer time is accepted Thus the film in question offers a possibility of high silver recovery without any time consuming miniature photography being necessary However the Medichrome film is not widely used Its character of being in some way special is stressed by the fact that it has not been imitated by other manufacturers Before the technology underlying this film is employed as a solution to the silver problem the usefulness of the Medichrome film must be considered The increased silver recovery should not be obtained at the price of impaired image quality In the following three key problems associated with the use of the Medichrome film will be considered the depicting quality of the film the choice of proper intensifying screens and the conditions of inspection

The Medichrome film

Depicting quality When the Medichrome film was introduced its constructors presented a new method for evaluation of the depicting quality of roentgen films This parameter could be graphically represented by the so-called perceptibility curve (DE BELDER & BOLLEN 1971) This function was based on psycho-physical evaluations of the smallest possible density steps discernible against different back ground densities High film quality implied the demonstration of very small density steps without reduction of exposure latitude The Medichrome film was claimed to have a more favourable perceptibility curve than conventional black and white films Preliminary experiences from clinical tests were published by the manu facturer these accounts generally being very enthusiastic (BORIES 1971 COLLARD 1971 FUGGAZOLA 1971 CLAUS 1971 D ARCHAMBEAU & METDEPENNINGHEN 1975 KUNKEL 1976 KLEMM 1976) Systematic comparison with black and white film was not undertaken in any of these tests When such comparisons were made the Medichrome film appeared to be advantageous in certain types of examination but not in others (ZEITLER & HÜRING 1972 BERGQUIST et coll 1973) The value of all these partly contradictory tests is doubtful Only scattered data were presented about the radiographic techniques In none of these reports were any data obtainable regarding choice of intensifying screens or temperature of the developer However the mode of development strongly affects the sensitivity of the Medichrome film so that great differences in screen film speed might have existed between the recordings on black and white and recordings on colour films If such a difference occurs the low speed system should give better image quality at least if no signi ficant object motion occurs Thus it must be concluded that in most clinical tests no black and white reference film was used and when it was used no measures appear to have been taken to compare screen film systems of identical sensitivity

In the present investigation the recording properties of the Medichrome film regardless of exposure and development were first established Since this film has a lower sensitivity than the films commonly used such as Curix RP 1 the next step was to find an intensifying screen which could compensate for the loss of speed without adversely affecting the image quality

The recording properties of the Medichrome film were compared with those of Curix RP 1 by means of a method devised by REICHMANN & HELANDER (1974) This technique implied exposure without roentgen rays Instead an image was projected onto the film by means of a photographic enlarger containing a negative film of very fine grain where an image of small spots of low contrast had been recorded Since a direct light exposure was used the difference in sensitivity between the recording films did not give rise to any significant differences in quantum mottle as would have been the case with an exposure using intensifying screens With this technique any difference in final image quality would be directly referrable to a difference in film quality A series of different exposures were performed several

Table

A survey of different screen film combinations used in radiography of a skull phantom at 90 kV. The screen phosphors are calcium tungstate (CT), barium strontium sulphate (BSS), lanthanum oxybromide (LOB), gadolinium lanthanum oxysulphide (GLOS) and barium fluorochloride (BFC). Screens are presented in approximate speed groups as regards blue sensitive film. The films are Curix RP 1 (C) and Medichrome (M). Films within parentheses have been somewhat more exposed than the rest, without being overexposed

Screen	Phosphor	Speed			
		Par	Par × 2	Par × 3	Par × 4
Ilford Standard	CT	C			
Kyokko LT II	CT	C			
Siemens Saphir	CT	C			
Ilford Fast Tungstate	CT	M	C		
Siemens Diamant Super	CT	M	C		
Kyokko LH II	CT	M	C		
Kodak X-omatic Regular	BSS	M	C		
Kodak Lanex Regular	GLOS		C		
Agfa-Gevaert MR 200	LOB	M	C		
Siemens Special	CT		M	C	
Philips Massiot Azuray II	BFC		M	(C)	C
Agfa-Gevaert MR 400	LOB		M	(C)	C
Ilford Rapid	LOB		M	(C)	C
Agfa-Gevaert MR 600	LOB			M	
Siemens Titan	LOB			M	

such a screen is used in conjunction with a high speed film of the Curix type a disturbing mottle is likely to occur. Consequently, despite the high sharpness, image quality would deteriorate so much as to make this extremely sensitive screen film combination unsuitable for general use. On the other hand, if the same screens were combined with a film of lower sensitivity, implying more ordinary levels of exposure, the quantum mottle would be reduced to acceptable levels. Since the Medichrome film is sensitive to blue and ultraviolet light only, the number of available high speed screen phosphors to be considered for use with this film is reduced to three: yttrium oxysulphide, lanthanum oxybromide and barium fluorochloride. These substances were thoroughly discussed from a theoretic physical point of view by STEVELS (1975). He claimed that yttrium oxysulphide is of minor interest, mainly because of its low absorption capacity for commonly used wavelengths of diagnostic radiation. In the present investigation the two remaining phosphors have been tested and compared with traditional calcium tungstate screens as well as with the Kodak X-omatic Regular screens containing barium strontium sulphate.

A skull phantom embedded in plastic was exposed in an axial projection at 90 kV, nominal focus 0.6 mm × 0.6 mm. The absorption of the phantom corresponded to

about 22 cm of plexiglass Secondary screening was carried out by a Siemens Pb 12/40 grid which was tested by STRID (1976) finding it to be of high selectivity The high tube potential was chosen in order to decrease the bone structure contrast so that image quality would be limited not only by unsharpness but by quantum mottle as well Curix RP 1 and Medichrome films were used The Curix film was consistently developed in 2 5 min in a Pakorol machine developer G 138 temperature 25 5 The Medichrome film was developed in G 43 at 37 Processing times were adjusted between 2 5 min and 3 5 min in order to achieve varying sensitivity in the film so that Curix and Medichrome films obtained at the same exposure could be compared Images were taken at different levels of exposure viz par speed (roughly corresponding to 1 mR cf HOLJE & SVAHN 1974) par speed ×2 par speed ×3 and par speed ×4 (≃0 25 mR) In the last speed group no Medichrome exposures were obtained The screen–film combinations are listed in the Table All films were inspected directly They were also photographed onto Agfapan 100 Professional film a yellow filter being used in the reproduction of the Medichrome films to yield uniform contrast in the whole material The negatives obtained were enlarged to a final magnification of 3 2 times This procedure made visible even details which were difficult for the naked eye to discern in the original films

Within each sensitivity group the magnified films were placed in a ranking order from highest to lowest image quality This evaluation was based mainly on the amount of information obtained so that a film displaying more details within the object was considered better even if the unsharpness was higher the noise was more intense or the contrast was less In many instances this ranking order was difficult to establish precisely and so the list in question is not published but certain general observations were possible

The differences in image information were rather small both within the groups and between them but the best film of the par speed group differed significantly from the most inferior one of par speed ×4 However the best recording of the par speed ×3 group was only slightly inferior to the best quality par speed film (Fig 2) Within each group the Medichrome films were exposed by means of screens of higher speed than were the Curix films Nevertheless the Medichrome recordings were not generally inferior to the Curix ones If only the calcium tungstate screens are considered the Medichrome images generally suffered from being exposed by high speed screens The new phosphors however made the colour film appear at many quality levels In the groups of par speed and par speed ×3 the best recordings were actually made on Medichrome film It was also observed that *differences in image quality* were not closely linked to the type of screen phosphor used In certain cases good recordings were obtained with calcium tungstate while less satisfactory quality resulted from one of the more recently constructed screen types Generally the new phosphors appeared to be slightly preferable For use with Medichrome film at par speed ×2 and par speed ×3 several screens were useful At higher speed MR 600 was slightly better than Titan but both were useful At the lower speed the

Table

A survey of different screen film combinations used in radiography of a skull phantom at 90 kV The screen phosphors are calcium tungstate (CT) barium strontium sulphate (BSS) lanthanum oxybromide (LOB) gadolinium lanthanum oxysulphide (GLOS) and barium fluorochloride (BFC) Screens are presented in approximate speed groups as regards blue sensitive film The films are Curix RP 1 (C) and Medichrome (M) Films within parentheses have been somewhat more exposed than the rest without being overexposed

Screen	Phosphor	Speed			
		Par	Par × 2	Par × 3	Par × 4
Ilford Standard	CT	C			
Kyokko LT II	CT	C			
Siemens Saphir	CT	C			
Ilford Fast Tungstate	CT	M	C		
Siemens Diamant Super	CT	M	C		
Kyokko LH II	CT	M	C		
Kodak X omatic Regular	BSS	M	C		
Kodak Lanex Regular	GLOS		C		
Agfa Gevaert MR 200	LOB	M	C		
Siemens Special	CT		M	C	
Philips Massiot Azuray II	BFC		M	(C)	C
Agfa-Gevaert MR 400	LOB		M	(C)	C
Ilford Rapid	LOB		M	(C)	C
Agfa Gevaert MR 600	LOB			M	
Siemens Titan	LOB			M	

such a screen is used in conjunction with a high speed film of the Curix type a disturbing mottle is likely to occur Consequently despite the high sharpness image quality would deteriorate so much as to make this extremely sensitive screen film combination unsuitable for general use On the other hand if the same screens were combined *with a film of lower sensitivity* implying more ordinary levels of exposure the quantum mottle would be reduced to acceptable levels Since the Medichrome film is sensitive to blue and ultraviolet light only the number of available high speed screen phosphors to be considered for use with this film is reduced to three yttrium oxysulphide lanthanum oxybromide and barium fluorochloride These substances were thoroughly discussed from a theoretic physical point of view by STEVELS (1975) He claimed that yttrium oxysulphide is of minor interest mainly because of its low absorption capacity for commonly used wavelengths of diagnostic radiation In the present investigation the two remaining phosphors have been tested and compared with traditional calcium tungstate screens as well as with the Kodak X-omatic Regular screens containing barium strontium sulphate

A skull phantom embedded in plastic was exposed in an axial projection at 90 kV nominal focus 0 6 mm × 0 6 mm The absorption of the phantom corresponded to

filter technique appears dubious Their figures refer to an over all estimation whether the Medichrome film yielded better images than the Curix film Thus it may still be possible that some special type of image detail which was lost in the statistical treatment may profit from the use of filters Actually the existence of such a sub group was suggested by SELIN & REICHMANN (1977) It was found that all types of films tend to yield impaired image quality for fine details of low contrast at high image density For black and white films this was assumed to be a consequence of a relative lack of grains so that certain image details were left unrecorded by the film In the Medichrome film these details were recorded by the film but the eye was unable to perceive the information at high densities In this case the information was recorded but not suitably displayed Enhanced visibility by means of filters was expected to compensate for this drawback

Two different types of light sources were used to test whether the filter technique is of special value in dense Medichrome images They both had in common the property of yielding red or orange light of very high intensity One of them was a projector with a 150 W halogen lamp At the place of the slide a thin velvet sheet of plastic was inserted together with a red filter The plastic sheet gave rise to so much scattering of light that the filament of the lamp became invisible The second light source was tested after a recommendation from BOLLEN (1975) at Agfa Gevaert The light came from a monochromatic sodium lamp of 100 W Medichrome films from both the experimental series described above were inspected in the projector light the sodium lamp was used for the skull films only Part of the result appears in Fig 1 which displays Curix and Medichrome images at exposures giving rise to moderate densities The difference between the films was visible in any type of light (white yellow red) However in dense Medichrome images the details were only seen in intense red light In the skull films the impression was gained that orange or red light is most useful at moderate and high densities

Medichrome images were also inspected in the light of high pressure sodium lamp which yields a polychromatic type of orange light This was considered to be completely unsuitable

Besides these aspects of the colour of the inspection light the proper choice of fluorescent tubes for conventional light boxes must also be considered The different types manufactured by Philips were tested including the new type TLH/84 which gives a white light of broad spectral distribution and a colour temperature of 4000 K The conventional warmwhite light (2 950 K) from the tubes of type TL/29 contained less blue and more yellow light these tubes being regarded as preferable for inspection of Medichrome films without coloured filters

Discussion

A shortage of silver will probably affect the technique of image recording in radiography within a not too distant future The initial survey of techniques already

available for solving this silver problem shows that there are three methods which may be used without loss of information electroradiography miniature copying of conventional full size films with subsequent silver recovery, and colour radiography The first mentioned technique is not yet available and reliable data as to image quality are still sparse albeit promising Miniature copying gives the additional advantage that the space required for filing is diminished but the technique is expensive Colour radiography makes possible a high degree of silver recovery However the only film available on the market has not gained wide acceptance Therefore most film manufacturers apparently do not consider this alternative to be a solution to the silver problem or to have any place whatsoever in radiography in the future

The Medichrome film was introduced during a period when its low sensitivity was a disadvantage which could not be compensated for by any acceptable measures Either high unsharpness had to be accepted or increased patient dose and tube load were unavoidable Recent progress in screen making has led to screens with such high speed in combination with favourable sharpness properties that films of low sensitivity are actually mandatory for these screens lest the quantum mottle should be too disturbing Certain new screens containing barium fluorochloride or lanthanum oxybromide phosphor seem to be the most suitable for the Medichrome film at present

The Medichrome film shares with all colour emulsions the property of requiring very stable time/temperature conditions of the developer In a sense this is a disadvantage since very close attention has to be paid to the operating parameters of the processing machines (cf DOBRIN et coll 1974) From another point of view the same property of the film may be considered as an advantage A reasonably small change in development may be utilised to obtain a considerable change in film sensitivity There are situations in the clinical routine when an extremely high screen film speed is desirable (pelvimetry of pregnant women certain routine controls of infants which have to be repeated at short intervals radiography with movable equipment etc) In most departments these examinations form a minority Usually the higher sensitivity is obtained by means of screens of extra high speed but films of extra high sensitivity may also be used In the former case a special set of cassettes with high speed screens is needed This is generally more feasible than having an additional set of films With the Medichrome film neither is necessary

Modern screen technique may permit the use of the Medichrome film even in high speed radiography The present experiments indicate that quantum noise is the most important factor limiting image quality Much has been written about the increased quantum detection efficiency of the new phosphors (BUCHANAN et coll 1972 STEVELS 1975 STEVELS & PINGAULT 1975) Therefore it was somewhat surprising that no great difference in information was found when modern screen film combinations were compared with a calcium tungstate system of the same speed Some explanation for this observation has recently been published by STEVELS &

SCHRAMA DE PAUW (1976) They analysed the light output from phosphor powder in relation to the light output from screens containing the same phosphors In principle certain powders of new phosphors including barium fluorochloride lost proportionately more of their light output when incorporated into a screen than did calcium tungstate The authors concluded that screen making is an art where many decades of empirical work has led to a greater degree of refinement in the case of calcium tungstate Further improvements of the new screens may thus be possible so that the difference between the phosphors will to a larger extent be reflected in improved screen quality

Another factor of the Medichrome films concerns the special conditions of inspection The aesthetic blue colour is apt to make many reluctant the belief is often encountered that the blue colour and the filter effects are nothing but marketing tricks From the present results it is suggested that Medichrome films should be inspected in light from traditional warm white fluorescent tubes in ordinary light boxes Dense areas should be inspected in very intense orange or red light preferably from a monochromatic sodium lamp Under these viewing conditions the Medichrome film yields high film quality The problem with the colour technique appears to be a matter of attitudes rather than the actual information content of the films Most are so used to black and white films that they may feel insecure when confronted with a colour emulsion which demands different colours of inspection light for different image densities A certain degree of re training must probably take place when black and white films are replaced by Medichrome film

The traditional screen film technique has one great advantage over the recently developed electroradiographic systems (cf JOHNS 1976) The material absorbing photons is in a solid state which yields excellent reliability Examinations may often have to be discontinued due to various radiographic components breaking down The more complicated the equipment the more vulnerable are the examinations Intensifying screens hardly ever break down momentarily due to their solid state If they are replaced by photon receptors with chambers containing fluid or highpressure gas this type of disturbance is far more likely to occur

SUMMARY

A shortage of silver is forcing film manufacturers to lower the silver content of radiographic films No further lowering seems possible without film quality being adversely affected Various ways to solve the silver problem in the future are discussed and colour radiography is regarded as one solution since it makes possible a high degree of immediate recovery of silver The feasibility and proper use of the only colour film available Medichrome is discussed Suitable screens in order to compensate for the low sensitivity of the film without loss of image quality and a strong light source containing a monochromatic sodium lamp for inspection of dense areas are recommended

ZUSAMMENFASSUNG

Silberknappheit kann Filmhersteller dazu zwingen den Silbergehalt von Rontgenfilmen zu erniedrigen Keine weitere Erniedrigung scheint moglich zu sein ohne die Filmqualitat nachteilig zu beeinflussen Verschiedene Wege um das Silberproblem in der Zukunft zu losen werden diskutiert und die Farbfilmdarstellung als eine der Losungen angesehen da sie einem hohen Grad von unmittelbarer Wiederverwertung von Silber ermoglicht Die Anwendbarkeit und der richtige Gebrauch des einzig zuganglichen Farbfilms Medichrome werden diskutiert Es werden geeignete Schirme um die niedrige Empfindlichkeit des Films ohne Verlust in der Bildqualitat zu kompensieren und eine starke Lichtquelle mit einer monochromatischen Natriumlampe zur Inspektion von dichten Gebieten empfohlen

RESUME

La raréfaction de l argent oblige les fabricants de surfaces sensibles a abaisser la teneur en argent des films radiographiques Il ne parait pas possible de l abaisser davantage sans nuire a la qualité des films Les auteurs envisagent différentes manières de résoudre le problème de l argent dans le futur et considerent que la radiographie en couleur est une solution car elle permet de récuperer immediatement une grande proportion d argent Les auteurs étudient la possibilite et les conditions convenables de l utilisation du seul film en couleur existant le Medichrome Ils recommandent des ecrans convenables pour compenser la faible sensibilité de ce film sans perte de qualité d image et une forte source de lumière contenant une lampe au sodium monochromatique pour l examen des régions denses

REFERENCES

D ARCHAMBEAU R and METDEPENNINGHEN C Arthrography of the knee on Medichrome film X ray Bulletin (published by Agfa Gevaert) 22 (1975) 19

DE BELDER M and BOLLEN R Medichrome a new X ray film yielding more detail X ray Bulletin (published by Agfa Gevaert) 18 (1971) 3

BERGQUIST E BERGSTRÖM K BRONGE A DAHLIN H HEMMINGSSON A JORULF H LINDGREN P G NYLEN O PERSSON R SAHLSTEDT B WELANDER U and WILBRAND H A clinical comparison between monochrome colour film and black and white RP film as a universal X ray film Fortschr Rontgenstr 118 (1973) 705

BIRKEN H Personal communication 1976

BOLLEN R Personal communication 1975

BORIES J Radiographic images on Medichrome film X ray Bulletin (published by Agfa Gevaert) 18 (1971) 14

BUCHANAN R A FINKELSTEIN S I and WICKERSHEIM K A X ray exposure reduction using rare-earth oxysulfide intensifying screens Radiology 105 (1972) 185

CLAUS E Note on the use of Medichrome film in otoradiology X ray Bulletin (published by Agfa-Gevaert) 18 (1971) 34

COLLARD M The diagnostic contribution of Medichrome film in radiological practice X ray Bulletin (published by Agfa Gevaert) 18 (1971) 16

DAINTY J C and SHAW R Image science Principles analysis and evaluation of photographic type imaging processes Academic Press London 1974

DECKER K Medichrome film in neuroradiology X ray Bulletin (published by Agfa Gevaert) 18 (1971) 22

DOBRIN R KRICHEFF I FITE W and WEATHERS R The effect of the variability of automatic film processing systems on the quality of radiographs Radiology 113 (1974) 545
FUGAZZOLA F Mammography—practical hints and critical considerations X ray Bulletin (published by Agfa Gevaert) 18 (1971) 30
HOLJE G och SVAHN G Test av forstarkningsskarmar (In Swedish) SPRI Report No 6030 9
JOHNS H E New methods of imaging in diagnostic radiology Brit J Radiol 49 (1976) 745
— FENSTER A PLEWES D BOAG J W and JEFFERY P N Gas ionization methods of electrostatic image formation in radiography Brit J Radiol 47 (1974) 519
KLEMM J Clinical aspects of radiography of the bones and joints with Medichrome film X ray Bulletin (published by Agfa Gevaert) 23 (1976) 9
KUNKEL B Selective angiography of the branches of the external carotid X ray Bulletin (published by Agfa Gevaert) 23 (1976) 3
MATTSSON O Aspects of the interpretation of contrast and detail in radiographs Acta radiol 38 (1952) 477
REICHMANN S and HELANDER C G High voltage radiography Theory and clinical application Acta radiol Diagnosis 15 (1974) 561
— ÅSTRAND K and KUNZ G Testing of roentgen film quality Acta radiol Diagnosis 19 (1978) 106
ROSE A Vision Plenum Press New York 1973
SCHERTEL L ZUM WINKEL K MOTZKUS F und KRASKA H Die Xeroradiographie des Schadels Fortschr Rontgenstr 121 (1974) 541
SELIN K and REICHMANN S High density failure of radiographic films Acta radiol Diagnosis 18 (1977) 95
— Unpublished results 1977
— DEICHGRABER E and REICHMANN S Influence of secondary radiation on image quality Acta radiol Diagnosis 16 (1975) 529
STANTON L BRADY L W WALLNER P NOCE J and SWEIGART K Image characteristics of liquid developed electron radiographs Radiology 120 (1976) 421
STEVELS A L N New phosphors for X ray screens Medicamundi 20 (1975) 12
— and PINGAULT F BaFCl Eu³ a new phosphor for X ray intensifying screens Philips Res Repts 30 (1975) 277
— and SCHRAMA DE PAUW A D M Theoretical and experimental efficiencies of X ray screens J electrochem Soc 123 (1976) 886
STRID K G Analysis of secondary screening with special reference to grids for abdominal radiography Acta radiol (1976) Suppl No 351
WALLNER P E BRADY L W and STANTON L Clinical evaluation of electron radiography Current status Radiology 120 (1976) 203
WIHED A and REICHMANN S Unpublished results 1977
ZEITLER E und HURING H G Das Medichrome Verfahren in der Rontgen Aufnahmetechnik Fortschr Röntgenstr 116 (1972) 402

Book review

PATHOLOGIE UND RADIOLOGIE VON HOCHDRUCK UND NIERENERKRANKUNGEN Herausgegeben von T Kröpelin Georg Thieme Verlag Stuttgart 1977 Price DM 78 —

This is a documentation in book form of a Symposium held in March 1976 in Freiburg Germany Twenty four lectures have been published as articles together with a large number of illustrations and references as well as contributions to the discussion

Four main subjects are treated Renal hypertension adrenal glands inflammatory kidney diseases and expanding processes in the kidneys Most of the space deals with pathology clinical features and radiologic diagnosis about one third of the book being devoted to radiology

Some of the advantages offered by the symposial arrangement with contributions from many experts within a special field and discussions in which different points of view can be presented are to some extent illustrated by this publication Certain disadvantages such as the difficulty of achieving a satisfactory balance between the different sections as well as a certain amount of repetition are apparent Too much space has in the reviewer's opinion been devoted to pheochromocytoma repetition having also arisen in several of the articles and too little to inflammatory renal diseases nephroangiography has not been given much attention whereas urography in different conditions and adrenal gland phlebography are treated relatively exhaustively one article reports on lumboscopic renal biopsy while renal biopsy in general is not given any space at all

The sections on renal hypertension and the adrenal glands are the largest in the book and these are also the best and the most comprehensive The clinical and pathologic sections on primary and secondary malignant nephrosclerosis and the renin angiotensin aldosterone system in different hypertensive states are excellent and provide valuable information not least for radiologists

The section on inflammatory renal diseases consisting of 54 pages seems inadequate A more fruitful treatment of the cooperation between pathology and diagnostic radiology especially angiography would have been welcome The latter field unfortunately is given hardly any attention

As regards expanding processes in the kidneys the section on these is short and the subject is treated in general terms and in review form However it contains one useful article by W A Fuchs on roentgen diagnosis and differential diagnosis of inflammatory pseudo tumours in the kidneys

The book is attractive with a clearly arranged lay out and good illustrations The best section that on renal hypertension can be recommended

Bo Lundström

ACTA RADIOLOGICA

PUBLISHED BY THE SOCIETIES OF MEDICAL RADIOLOGY IN
DENMARK FINLAND NORWAY AND SWEDEN

Vol 19
Fasc 4 DIAGNOSIS 1978

CONTRAST ENHANCEMENT OF CRANIAL LESIONS IN COMPUTED TOMOGRAPHY

R LEWANDER M BERGSTRÖM and U BERGVALL

In the first clinical report on computed tomography (CT) AMBROSE (1973) observed that circulating contrast medium sometimes passed into and could be retained in abnormal tissue for a relatively long period of time the intravenous injection of sodium iothalamate increased the attenuation of a variety of tumours appreciably

The sensitivity of CT (HOUNSFIELD 1973 PAXTON & AMBROSE 1974 GAWLER et coll 1974 NEW et coll 1974 GREITZ 1975) in detecting intracranial lesions and the accuracy of differential diagnosis can undoubtedly be increased by contrast enhancement (HATAM et coll 1975 NEW & HOCHBERG 1975)

KRAMER et coll (1975) emphasized that contrast enhancement was of particular value in the detection of posterior fossa and suprasellar tumours and in metastatic disease

The time course of enhancement during the first 3 hours after intravenous injection of contrast medium was investigated from the differential diagnostic point of view by HATAM et coll The enhancement response was more or less prominent in various tumours while only slight or no response at all occurred in edema and in tissue considered normal The results were promising but the number of patients was small The present work is an extension of the preceding one—an evaluation in a larger series of patients of whether temporal analysis of contrast enhancement is

From the Department of Diagnostic Radiology (Director U Rudhe) Huddinge Sjukhus, S-141 86 Huddinge the Institute of Radiation Physics (Director R Walstam) Karolinska Institutet and the Department of Neuroradiology (Director T Greitz) Karolinska Sjukhuset S-104 01 Stockholm Sweden Submitted for publication 28 June 1977

clinically useful for differentiation of intracranial lesions Since examination times of the order around 3 h are impractical a second question is whether the evaluation of enhancement dynamics during 60 min or even 30 min is sufficient from the differential diagno tic point of view

Method

Regional changes in attenuation properties after intravenous bolus administration of Isopaque Cerebral (Nyegaard Oslo) in a dose of 1 ml (280 mg I) per kg body weight have been analyzed in CT scans using the first generation EMI head scanner with the 160 160 matrix The first EMI scale of ±500 attenuation units from water level has been used throughout From preliminary scans the most appropriate level was selected and the same level was scanned after rapid intravenous injection of the contrast medium starting at time 0 at the end of the injection with repeat scans at 15 30 and 45 to 60 min from the end of injection In several cases the time schedule was modified for practical reasons

With an EMI diagnostic program the mean attenuation value can only be calculated for a rectangular region or a combination of rectangular regions However most intracranial lesions are rounded making variable rounded shapes more suitable Furthermore in the EMI program the region to be measured must be reintroduced for each image of a series making the use of this program a hard and time consuming work BERGSTRÖM & SUNDMAN (1976) designed a program for calculating the mean attenuation coefficient and the standard deviation of a given region—elliptical or rectangular with the orientation varied as required This program can be introduced by the computer into all images in a time sequence even with several overlapping regions in each image In order to correct for small positional changes of the patient in the plane of the tomogram during the sequence the program automatically aligns the defined region of interest (ROI) to any change in image position so as to retain the topographic relationship determined at the outset The CT sections to be analyzed are transferred from storage tape to a disc containing the program Following calculation the sections with one or more ROI outlined are transferred back to tape and displayed The program is written in Fortran and run on the Nova 820 connected to the EMI scanner using a real time disc operating system When possible lesions with inhomogeneous enhancement were broken down into regions with a more uniform attenuation For instance lesions with rim enhancement were calculated in the following way one ROI was positioned to include the entire lesion another merely the low attenuating centre of the lesion The difference between these two the mean attenuation of the periphery was calculated according to the formula

$$\frac{M_t \times n_t - M \times n}{n_t - n_c}$$

where M_t and M_c represent the mean attenuation of the entirety and the centre of the lesion respectively n_t the total number of matrix cells in the lesion and n_c the number of cells in the central ROI

In the results the enhancement characteristics for the different groups of lesions have been described as linear functions of time The enhancement at time 0 and the slope of the curves were determined by a lea t squares fit

Material

In the previous series (HATAM et coll) characteristic lesions were selected for repeat examination after injection of contrast medium while for the present series 100 consecutive routine examinations including intravenous administration of con trast medium were pulled from the tape files Cases with unsatisfactory reproducibility of repeat scans and cases with disturbing movement artifacts were excluded only 41 patients remained for evaluation of regional attenuation response to administration of contrast medium (Table 1)

A ROI with apparently normal brain tissue was defined for reference in 41 cases in 8 a zone of low attenuation around the lesion postulated to be edema could be reasonably well outlined as a second ROI (3 astrocytomas grade II–IV 2 ependymomas 1 abscess 1 hematoma and 1 metastasis from an adenocarcinoma of the lung)

Glioma A glioma microscopically confirmed in all but one case was diagnosed in 16 patients Four tumours were classified microscopically as glioblastoma multiforme or astrocytoma grade III–IV 4 as astrocytoma grade II–III 2 as astrocytoma grade I–II 2 were cerebellar astrocytomas and 3 ependymomas In one patient no microscopic confirmation was obtained the clinical diagnosis of a non operable partially central malignant glioma was reached from evaluation of a combination of CT encephalography angiography and scintigraphy radiation treatment was instituted without operation or biopsy For practical reasons this case was grouped with the astrocytomas I–II as the tumour had a similar response at CT after contrast medium injection as the other two cases in this group (Table 1) In the angiographic evaluation of the gliomas specific diagnostic findings included malignant neovascularization rapid arteriovenous shunting and short lasting accumulation of contrast medium while absence of these properties has been labelled non specific in Table 1

Meningioma In this group 6 of the 7 patients were operated upon The clinical diagnosis of frontal convexity meningioma in the patient not operated upon a man aged 76 was reached by CT and $^{99}Tc^{m}$ scintigraphy

Acoustic neuromas Of the 6 acoustic neuromas 3 were microscopically confirmed after open surgery Two of these were recurrent tumours after non radical surgery 3 and 4 years previously In 3 patients the diagnosis was based upon clinical

Table 1

Lesions evaluated for contrast enhancement with time Diagnostic results by other methods

Group	No	Diagnosis	Sex	Age	Site
I a	1	Glioblastoma	F	39	Splenium
	2	and	M	68	Thalamus R
	3	astrocytoma	F	60	Corp callos
	4	III-IV	F	72	Corp callos
I b	1	Astrocytoma	F	25	Front R
	2	II-III	F	54	Corp callos
	3		M	46	Temp R
	4		F	55	Front L
I c	1	Astrocytoma	M	35	Pariet L
	2	I II	M	34	Front bilat
	3		F	50	Front pariet R
I d	1	Ependymoma	F	18	Brain stem
	2		M	54	Corp callos
	3		M	55	Pariet L
I e	1	Cerebellar	M	25	Vermis
	2	astrocytoma	F	10	Cerebellum R
II	1	Meningiomas	M	76	Front L
	2		F	66	Front pariet L
	3		F	58	Temp pariet L
	4		F	58	Pariet L
	5		M	69	Central
	6		F	70	Temp R
	7		F	65	Pont angl R
III	1	Acoustic	M	43	Pont angle R
	2	neuromas	F	41	Pont angle L
	3		F	42	Pont angle L
	4		F	28	Pont angle R
	5		F	60	Pont angle L
	6		F	16	Pont angl L
IV	1	Suprasellar	F	56	Suprasellar
	2	tumours	M	41	Suprasellar
V	1	Metastases	M	63	Occip
	2		F	46	Cerebellar
	3		M	62	Occip R
	4		M	65	Vermis and front L
VI	1	Miscellanous	F	25	Pariet -occip R
	2		M	48	Central
VII	1	Infarcts	M	6[illegible]	Pariet bilat
	2		M	65	Cerebellar
	3		M	68	Pariet L
			F	69	Occip I

Table 1 (*cont*)

Angiography		Scintigraphy	Cisternography (C) CT-cisternography (CTC) Pneumography (P)
− normal specific (−) non specific 0 not done	v vascular (v) avascular	+ consistent with diagnosis (+) non specific normal 0 not done	characteristic (−) non specific
( )	(v)	+	−(P)
	v	+	
	v	+	
0		+	
( )	(v)	0	
	v	0	
+	v	0	
−	v	(+)	
( )	(v)	−	
(−)	(v)	0	
( )	(v)	−	
(−)	v	0	−(P) (C)
( )	(v)	−	
( )	(v)	0	
( )	(v)	0	
0		+	
0		+	
(−)		+	
(−)	v	+	
	v	+	
( )	(v)	0	
( )	(v)	+	
( )	(v)	(+)	
0		0	+(P)
0		0	+(P)
0		0	−(C)
0		0	+(C) +(P)
0		0	+(P) −(CTC)
0		0	+(P) +(CTC)
0		0	−(P)
0		0	+(P)
(−)	(v)	+	
0		(+)	
(−)	(v)	+	
( )	v	+	
( )	(v)	+	+(P)
(−)	(v)	+	+(P)
0		+	
0		+	
(−)		+	
0		+	

Angiography of the external carotid artery not performed

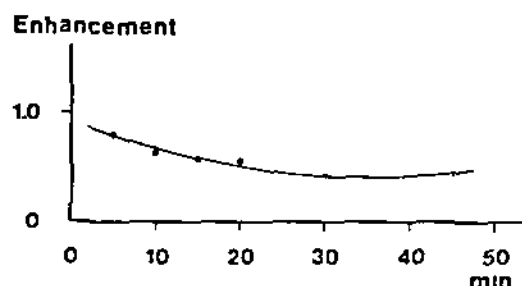


Fig 1

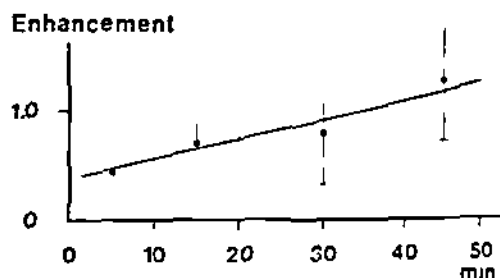


Fig 2

Fig 1 Enhancement response in apparently normal brain tissue after intravenous bolus injection of contrast medium Measurements from 41 patients interpolated in time and normalized to 0 (I 1 SE) Mean attenuation value before contrast medium injection 17 3 u (SD = 1 7)

Fig 2 Enhancement response of edema after intravenous bolus injection of contrast medium Measurements from 8 patients interpolated in time and normalized to 0 (I = 1 SE)

examination including otoneurologic analysis pneumography cisternography with positive contrast medium or CT-cisternography (GREPE et coll 1975) Of these 3 patients 2 had been treated with stereotactic gamma lesions 2 and 4 years previously respectively using the technique described by LEKSELL (1971 a) One of these patients had a recurrent tumour The second patient had a small tumour which had diminished in size after treatment

Suprasellar lesions Two suprasellar tumours were examined one cystic craniopharyngeoma confirmed at a stereotactic puncture and one intra and suprasellar chromophobe pituitary adenoma confirmed by microscopy of a needle biopsy specimen

Metastases Of the 4 patients in this group one had a poorly differentiated primary bronchial carcinoma with one cerebellar metastasis confirmed at autopsy The second patient had an occipital lesion microscopically a poorly differentiated malignant tumour probably secondary to a urinary tract carcinoma The third patient had a mainly occipital lesion demonstrated by $^{99}Tc^{m}$ scintigraphy angiography and CT Microscopy of a spiral needle biopsy was consistent with a metastasis from a renal carcinoma The fourth patient with one infratentorial and one frontal metastasis had been operated upon for a pulmonary adenocarcinoma

Infarction In the 4 patients with brain infarcts of varying age (15–51 days) the diagnosis was based upon history and clinical findings combined with angiography pertechnetate scintigraphy and spectrophotometric analysis of cerebrospinal fluid (SÖDERSTRÖM et coll 1975)

Miscellaneous Two lesions have not been referable to any other group One abscess in the right occipital lobe microscopically confirmed containing anaerobe

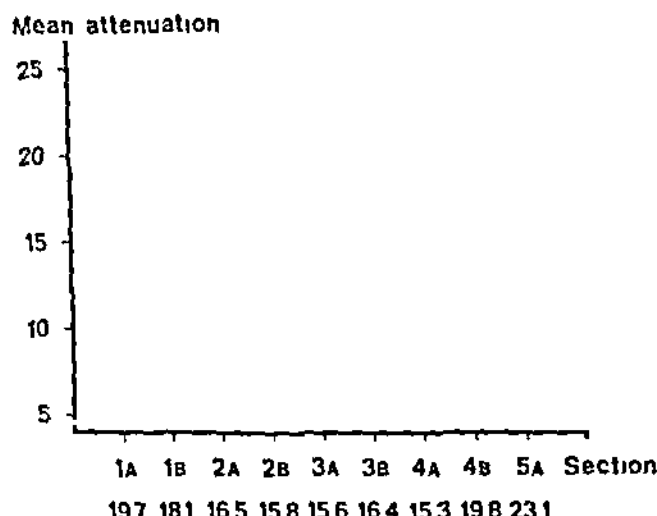


Fig 3 Mean attenuation of apparently normal brain tissue (before contrast medium injection) correlated to scan level (13 mm consecutive sections 1 A 5 A from skull base to vertex)

streptococci one slowly growing tumour in the posterior part of the third ventricle by angiography and pneumography diagnosed as a pinealoma but not confirmed by biopsy

Results and Discussion

Normal brain tissue The curves of the enhancement response of apparently normal brain tissue were constructed after time interpolation from measurements in 41 patients (Fig 1) The criterion of normality in these cases was the appearance at CT—the ROI was usually chosen in the hemisphere not involved by the lesion Evidently such apparently normal regions of the brain cannot be regarded as normal in a strict sense since mass effects and altered circulation might influence the tissues at a considerable distance from the lesion

The ROI of apparently normal brain tissue was deliberately positioned to cover both grey and white matter regions since separation in the images is not possible from a practical point of view Care was taken not to include the dural structures of the falx and the tentorium The mean attenuation value before administration of contrast medium was 17 3 *units* (u) SD = 1 7 SE = 0 3 of the EMI scale ($\pm$500 from water level) The mean enhancement response varied within a range of 1 μ

Edema Regions of low attenuation defined as edema may be impossible to separate from a highly deformed ventricle if situated close to the ventricular system such cases have not been included in the series The problem of separating edema from low attenuation tumour tissue has also been taken into consideration in positioning of the ROI The mean attenuation value of the 8 edema regions before administration of contrast medium was 11 3 μ (SD = 1 4 SE = 0 5) The enhance

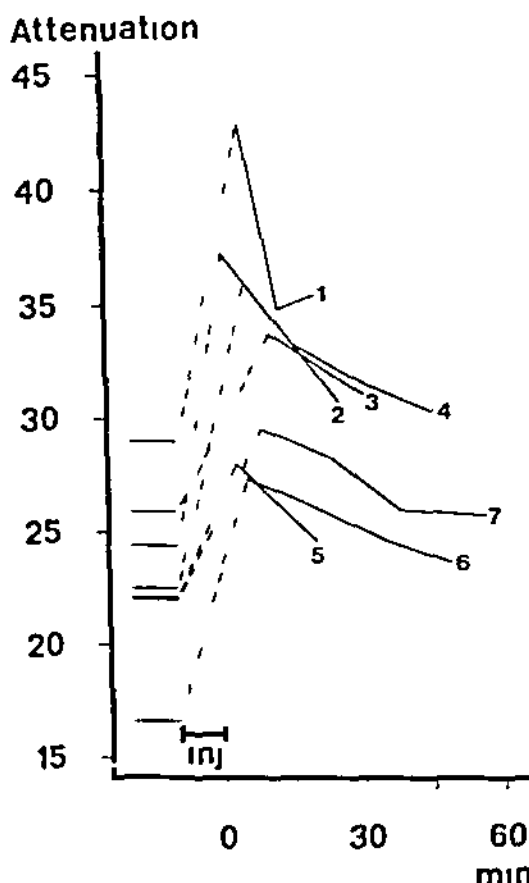


Fig 4

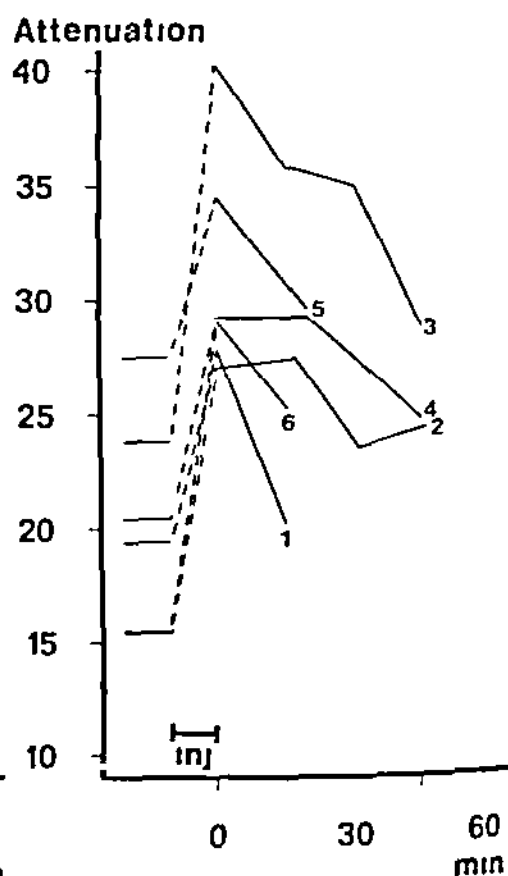


Fig 5

Fig 4 Enhancement response of 7 meningiomas The curves are constructed from the mean values of each case measuring sequence The symbol for injection of contrast medium covers a disproportionately long time as when appearing int eh following diagrams All injections were rapid bolus mode

Fig. 5 Enhancement response curves of 6 acoustic neuromas constructed as in Fig 4

ment curves of edema regions rise slightly during the first 45 min (Fig -) althou h there is no significant separation of the extreme mean values at the 1 SE level

Meningioma The mean attenuation of tumour tissue before injection of contrast medium varies considerably in this group of 7 patients (16 6–29 0 u) probably due to a varying amount of calcific deposits in the tumour but also to some extent depending on the site and level of the lesion (Fig 3 cf the discussion on normal brain tissue page 546) The high initial peak and the steep slope is characteristic of this group of curves (range of increase 7 3–13 4 u M = 10 6 Fig 4) However no correlation between the curve amplitude and the degree of vascularization at angiography was found pointing to the fact that the blood concentration is not the single determinator of the curve shape in this early phase

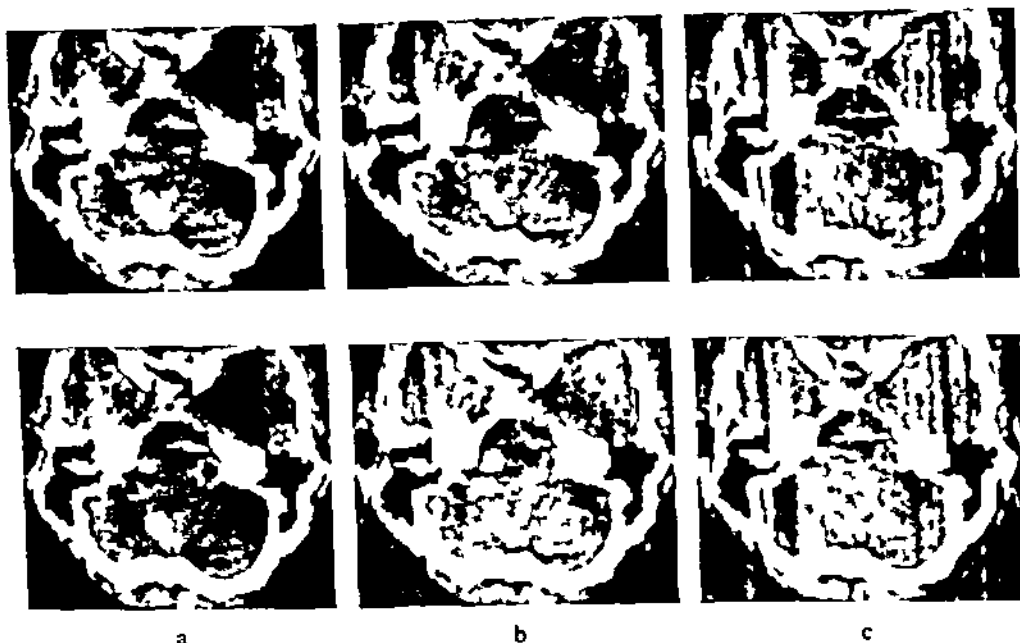


Fig 6 III 1 Small right sided acoustic neuroma (Fig 5 1) a) Before b) immediately after and c) 15 min after intravenous contrast medium injection Lower row with region of interest (ROI) outlined In c) the patient had changed position and the ROI is partly outside the border of the tumour Despite the high reproducibility from a) to b) the interpyramidal dark streak artifact across the brain stem varies and may influence measurements to a variable degree Still more important with the position of ROI close to the high attenuation region of the bony pyramid is the varying partial volume effect unavoidable with a small tumour in this region

Acoustic neuroma A high initial peak is characteristic also of these 6 curves (Fig 5) With two exceptions a rapid decrease of attenuation was recorded already at the 15 min measurement In one case the attenuation peak was measured 17 min after injection (Fig 5 2 before treatment) in the other case only a slight decrease at the 15 min measurement was found (Fig 5 4 recurrence after partial extirpation) A typical attenuation response of this group is illustrated in Fig 6

It must be emphasized that acoustic neuromas have a difficult location for measuring purposes The tumour is located in close proximity to tissues with widely diverging attenuation properties neural tissue thick bone possibly widened cisterns and finally dural tissue of the tentorium The dura may be considerably enhanced by contrast medium accumulation Thus even small changes of positioning may cause large measurement deviations dependent on complex combinations of partial volume effects The situation is still worse if the tumour region is small or irregular so that the region of measurement has to be narrow Furthermore the common interpyramidal dark streak artifact across the brain stem may interfere with the measurements (Figs 5 6) Obvious change of position of the skull was the cause of the short ob ervation time in 3 of the cases (Fig 5) More subtle positional changes

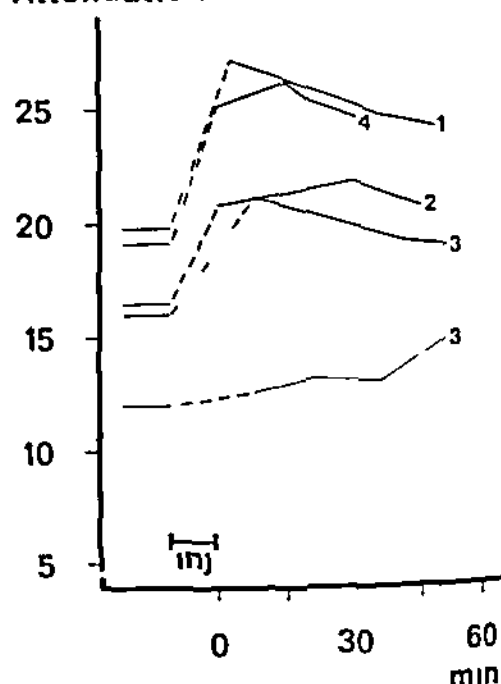


Fig 7 Enhancement response curves of 4 cases of glioblastoma-astrocytoma grade III-IV constructed as in Fig 4 In case 3 the thick curve represents the peripheral part and the thin curve the central part of the same tumour (cf Fig 8)

may have influenced the initial stage of these as well as the remaining acoustic neuroma curves Two of the acoustic neuroma curves have an unusually flat initial peak during the first 15 to 20 min of observation In one of these the explanation may simply be measurement problems while the second curve at least in part probably represents the true enhancement response of the tumour (Fig 5 2)

Glioma This highly heterogeneous group of altogether 16 patients had a very divergent time response after contrast medium injection However the glioma group may be broken down further into histologically more homogeneous subdivisions resulting in more similar curves in the separate groups The findings in the previous work (HATAM et coll) indicating that all gliomas reach a higher attenuation level after 1 h has not been confirmed in this larger series Still the response is different from that of neuromas and meningiomas The contrast accumulation of meningiomas and neuromas is generally fairly homogeneous while grossly inhomogeneous distribution is more common in the glioma group

Glioblastoma and astrocytoma grade III-IV In the group of glioblastoma and astrocytoma grade III-IV (4 patients) all curves have an initial rise in attenuation immediately after the injection of contrast medium (Fig 7) Two curves (Fig 7 4 2) reached a maximum after 15 to 30 min while the other curves (Fig 7 1 3) both had their maxima directly after injection with a slow slope during the following 45 min



Fig 8 1a 3 Central glioblastoma multiforme a) without and b) with 2 ROI measured 8 min after contrast medium injection —one including the whole the other only the central part of the tumour For technical reasons, partial inclusion of the falx was unavoidabl

One tumour (Fig 7 3) had a high peripheral enhancement with a maximum at 8 min and a low attenuating central part The measurements in this case were taken from both the periphery and the central part (Figs 7 8) Following injection of the contrast medium only a slight response occurred in the central part of the tumour with a slow rise of 2 5 u during 50 min The attenuation response of the central part is clearly different from that of the tumour periphery and al o separates this from the other 3 tumours with a more homogeneous appearance Rim enhancement was encountered in a variety of lesions in this series one glioblastoma one astrocytoma II III two cerebellar astrocytomas one ependymoma one metastasis from a pulmonary carcinoma and one abscess This is also in accordance with reports of so-called doughnut lesions in various conditions (GONZALES et coll 1976) The relationships of varying histologic structure to different types of enhancement response in gliomatous tumours has been approached using a stereotactic technique (BOETHIUS et coll 1977)

Two glioblastomas (Table 1) were highly vascular with a rapid arteriovenous shunting at angiography while one was poorly vascularized without shunting No angiography was obtained in the remaining glioblastoma patient

In conformity with the meningioma group no correlation was found between an initial rise of the curve and the degree of vascularization at angiography

Astrocytoma grade II-III One of the 4 tumours in this group had a rim enhancement while 3 had an irregular and inhomogeneous distribution of contrast medium

With one exception these tumours had a very similar time response to contrast medium injection (Fig 9) Before injection the mean attenuation values were 17 5 17 5 and 18 3 u respectively After injection the curves rose immediately to a maximum and then continued in a tardy slope during the next 45 min The curves never diverged more than 2 5 u during the measurement The fourth tumour

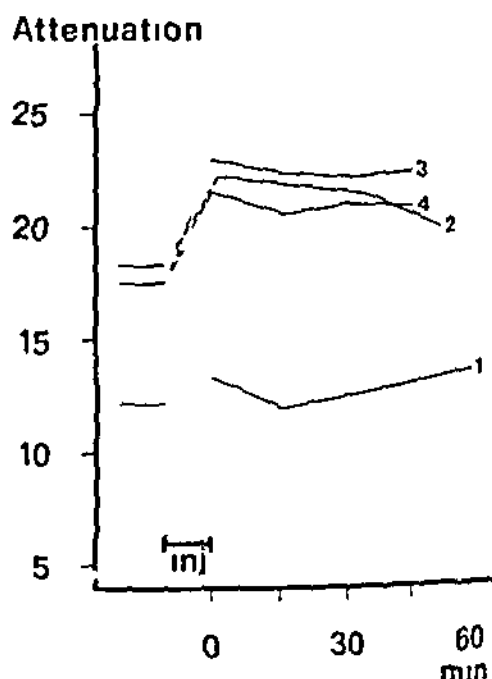


Fig 9 Enhancement response curves of 4 astrocytomas grade II–III constructed as in Fig 4

classified microscopically as an astrocytoma grade II–III had an initial mean attenuation of 12 5 u and remained practically unchanged after injection of contrast medium rather like the group of astrocytomas of grade I–II

Astrocytoma grade I–II These 3 tumours form a group of expanding lesions with low attenuation and diffuse border lines From an initial mean attenuation level of 13 8 to 16 7 u they did not significantly respond to contrast medium administration the curves running parallel courses at a distance not exceeding 3 u (Fig 10)

Cerebellar astrocytoma These 2 tumours were grouped together with regard to their clinically comparatively benign properties One patient a 9 year old girl had a right cerebellar astrocytoma and the other a man of 24 years had an astrocytoma of the vermis grade II (Fig 11) Both tumours had a mean attenuation below that of normal brain tissue before the injection of contrast medium The attenuation response with a peripheral accumulation of contrast medium was immediate In one case this accumulation proceeded for 30 min after which the examination had to be terminated In the other case the accumulation reached a maximum directly after the injection Both tumours demonstrated an increa in contrast accumulation in the central part during the examination Depending on movement artifacts this was only possible to measure in one case

Ependymoma This special type of glioma forms a group of 3 tumours all with an immediate enhancement after injection of contrast medium (varying between

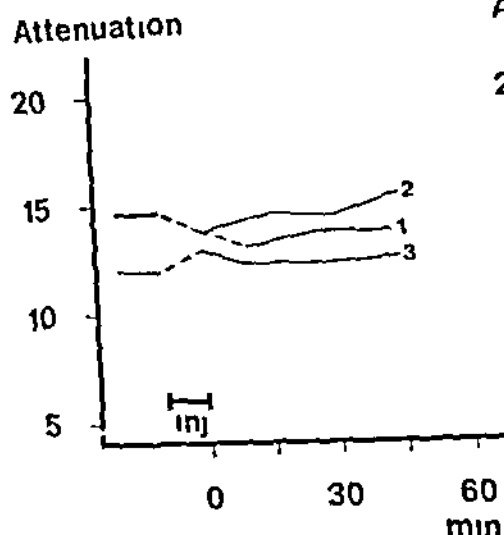


Fig 10

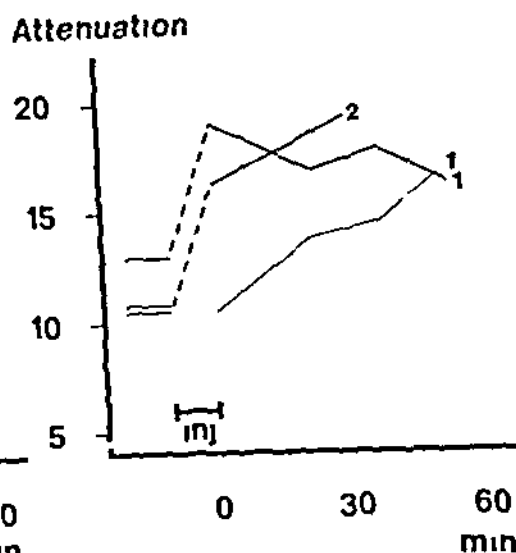


Fig 11

Fig. 10 Enhancement response curves of 3 astrocytomas grade I-II constructed as in Fig 4

Fig 11 Enhancement response curves of 2 cerebellar astrocytomas, constructed as in Fig 4 1 thick line represents periphery thin line center of lesion

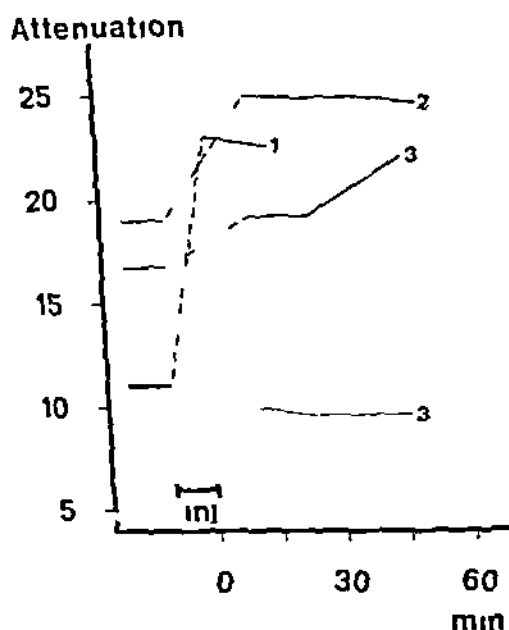


Fig 12 Enhancement response curves of 3 ependymomas constructed as in Fig 4 3 thick line represents periphery thin line center of lesion (cf Fig 13)

11 1 and 19 0 u) but then an almost unchanged or slightly increasing attenuation (Fig 12) One tumour (Fig 12 3) had a central region with low attenuation sur rounded by a slightly irregular rim of high enhancement (Fig 13)

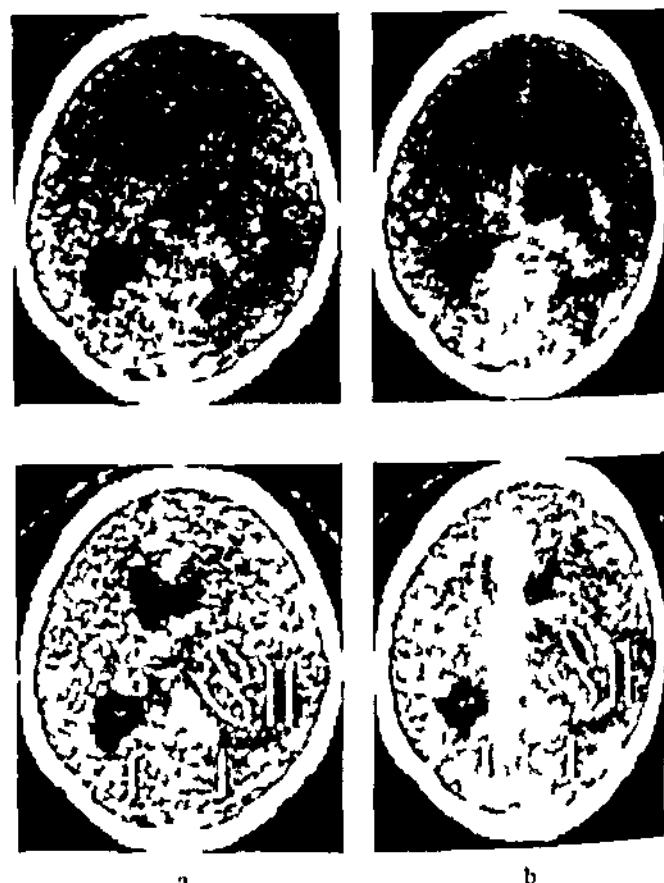


Fig. 13. Id. Case 3, right thalamic ependymoma a) before and b) 10 min after contrast medium injection. Upper row without and lower row with indications of ROI, from right to left: edema, center of tumour, periphery of tumour, normal brain tissue.

Suprasellar tumours. The native attenuation of the cystic craniopharyngeoma did not differ significantly from that of the surrounding structures but moderate initial peripheral enhancement of the tumour was recorded after injection of contrast medium (Fig. 14: 1). The central cystic part (later confirmed by stereotactic puncture) had a comparatively high mean attenuation of 12.9 u before injection, to some extent possibly a partial volume effect. The ROI had to be kept narrow and also with regard to slight positional changes of the patient in the axial direction, the subsequent increase of enhancement may be artifactual rather than indicating a transport of contrast medium to the cyst.

The enhancement curve of the chromophobe adenoma had a similar course to that of the peripheral part of the craniopharyngeoma (Fig. 14: 2).

Metastases. The lesions in this group of 4 patients had a very heterogeneous response to the administration of contrast medium. One patient with a poorly differentiated primary bronchial carcinoma had a metastasis with low attenuation practically unaffected by the contrast medium (Fig. 15: 2). Another patient with metastases from a urinary tract tumour had a large parieto-occipital lesion with an

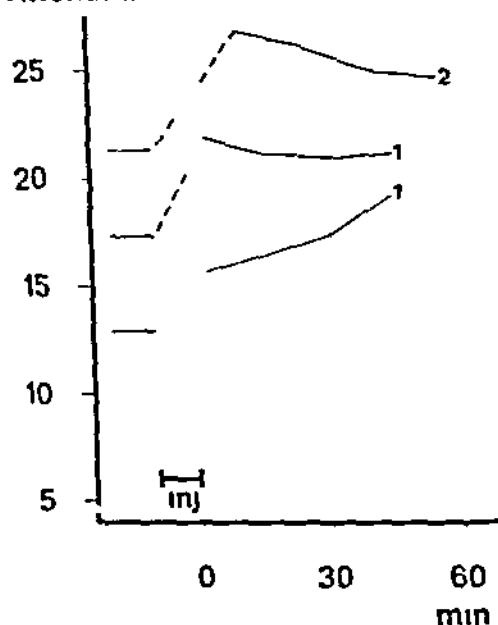


Fig 14 Enhancement reponse curves of 2 suprasellar tumours (1 partly cystic cranio-pharyngeoma 2 chromophobe adenoma) constructed as in Fig 4 1 thick line represents solid part thin line cystic part of tumour

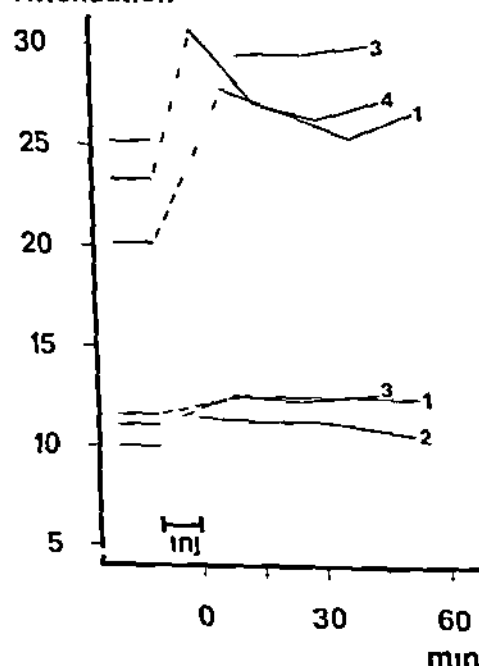


Fig 15

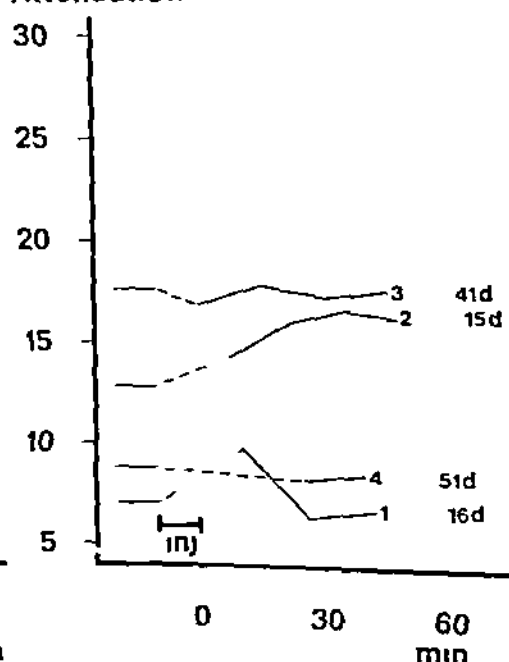


Fig 16

Fig 15 Enhancement response curves of 4 cases of metastases constructed as in Fig 4 In cases 3 and 1 low as well as high attenuating regions were measured

Fig 16 Enhancement response curves of 4 infarcts constructed as in Fig 4 Time (in days) from onset of symptoms to date of examination indicated at each curve

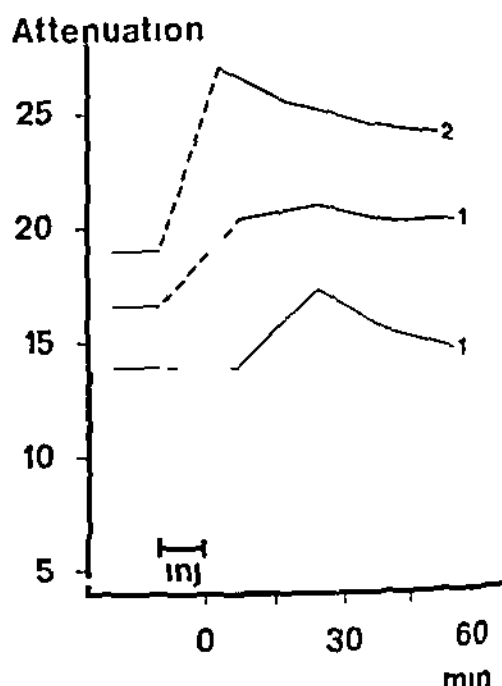


Fig 17 Enhancement response curves of one abscess (1 thick line represents periphery thin line center of lesion) and one pinealoma (2) constructed as in Fig 4

irregular distribution of attenuation values and only a faint general enhancement response (Fig 15 3) However in one peripheral part of the lesion a definite accumulation of contrast medium occurred immediately after injection (Fig 15 3) One further patient with brain and bone metastases of uncertain origin probably from a renal carcinoma had a similar appearance One part of the brain lesion had low attenuation without significant enhancement and could not be distinguished from a perifocal edema while a small part of the lesion had a *fairly marked* accumulation of contrast medium of early onset and lasting for at least one hour (Fig 15 1) Finally one pulmonary adenocarcinoma metastasis had a peripheral accumulation of contrast medium while the central region did not respond significantly The curve from the peripheral region had an early peak and then a fairly high attenuation level remaining during the first 45 min (Fig 15 4)

Infarctions The 4 infarcts examined 15 to 51 days after clinical onset had only a faint or practically no response after injection of contrast medium (Fig 16)

Miscellaneous The septic abscess initially had an attenuation almost equal to that of the surrounding brain tissue This lesion responded with a peripheral accumulation of contrast medium it increased to a maximum at 24 min and then remained almost constant (Fig 17 1) The central part of the abscess did not reveal any significant increase of attenuation after 24 min

The lesion considered to be a pinealoma had a prompt and maximum response after injection of the contrast medium the curve then had a very slight decrease of

Table 2

Survey of parameters describing the enhancement curves of the different groups (SD = one standard deviation)

Parameter	Acoustic neuroma	Meningioma	Metastases	Suprasellar lesions	Glioma	Infarction
Number	6	7	4	2	16	4
Mean value without contrast medium	20 3	23 2	19 6	19 3	15 5	11 6
SD	4 7	3 8	6 8	2 8	3 0	4 7
Enhancement	11 1	10 6	4 8	2 9	4 2	0 8
SD	3 5	3 3	2 6	4 2	3 6	1 9
Slope 0–60 min	−0 24	−0 19	−0 03	−0 04	−0 01	−0 01
SD	0 15	0 13	0 04	0 03	0 05	0 06

3 u during the remaining 51 min (Fig 17 2) The curve had the same shape as one of the astrocytomas grade III–IV (Fig 7 1) but clinically the tumour did not reveal any characteristics of malignant glioma

Data analysis

A survey of the parameters describing the enhancement curves of the different groups is presented in Table 2 mean attenuation values before injection of contrast medium and corresponding standard deviations calculated enhancement levels at time 0 and the slope of the straight line approximation of the 0–60 min part of the enhancement curves are tabulated

Table 3 presents significant differences using the Student s t test ($p < 0\ 05$) between the various groups of lesions in terms of pre-enhancement attenuation values enhancement at time 0 and slope displayed at observation times 0 to 30 min and 0 to 60 min respectively A comparison of the results discloses that the diagnostic accuracy is only slightly improved by extending the observation period from 30 to 60 min

Comments

Examination technique As pointed out previously the practical problem of prime importance in CT sequential procedures is patient movement and difficulties in obtaining reproducibility in repeat scans (HATAM et coll) This is further emphasized by the fact that about 60 per cent of the consecutive series of 100 patients had to be rejected mainly because of patient movements and if protocol requirements had

Table 3

Separation of each group from other groups of lesions (Stud nt s t test $p < 0\ 05$) in terms of preenhanced attenuation (R) enhancement at time 0 (E) and slope of attenuation curve (S) at 30 min (left below the diagonal) and at 60 min observation time For instance metastases within 30 min separate from acoustic neuroma and meningioma groups by E (read hori ontally) while extending the observation time to 60 min yields separation also by S from the same groups (read vertically) and in addition from the infarction group by E


OBSERVATION TIME 0 30 MIN / IN 0 60 MIN

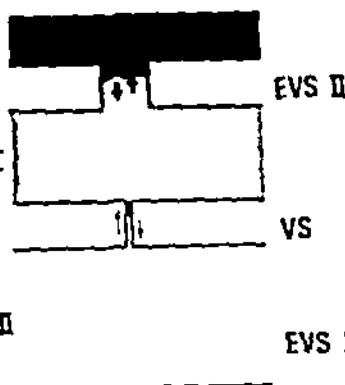
	ACOUST NEUR	MENINGIOMA	METASTASES	UPRASELL L	GLIOMA	INFARCTION
COUST NE R			ES	E	RES	RES
MENINGIO A			ES	E	RES	RES
METASTASES	E	E				E
U RASE L L		E				
GLIOMA	RES	RES				R
N A C O	PE	R			R	

included a full 60 min observation period in every case still more patients would have been excluded In the analysis of small regions of interest positional reproducibility is fundamental Correction for movements in the plane of the tomographic section was achieved by computer program alignment of the ROI to changes in the position of the skull However in many cases the movements were so great and the lesion so small as to locate the ROI to a position outside the lesion (Fig 6) Furthermore as correction for movements not parallel to the tomographic plane seems impossible with a data program and as such movements are often encountered everything points to the fact that some kind of rigid fixation of the patient s head is a sine qua non in repeat measurements A type of individual plastic mask which is applied around the head has been worked out (BERGSTRÖM & GREITZ 1976) and will be evaluated in another series of patients The fixation system has been aligned to the stereotactic system of LEKSELL (1949 1951 1966 1971 a b) used at this department

Another way to improve and simplify the evaluation of dynamic enhancement is to develop the computer hard ware A light pen or joystick system would make it possible to analyse irregular ROI and reduce the time of the procedure as well Sequential CT analyses with a high degree of reproducibility will be practicable only when these problems have been solved

Normal brain tissue variation The mean attenuation values of apparently normal brain tissue vary greatly systematically related to the scan level used One reason for this may be the relatively higher percentage of grey matter present at the levels 1 A and 4 B–5 A grey matter attenuating about 3 μ more than white (PHELPS et coll 1975) Another possibly contributing factor is that the ROI in the central levels 2 B–4 A despite attempts to avoid it in some cases have included part of the ventricles cisterns or Sylvian fissures A technical factor probably of dominant importance is the error in data processing known as the spectral shift artifact or the





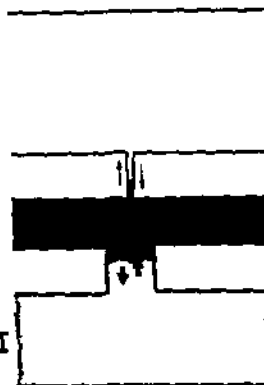


Fig 18

Fig 19

Fig 18 Two-compartment model of rapid exchange of contrast medium between the vascular (VS) and extravascular (EVS) spaces

Fig 19 Three-compartment model of exchange of contrast medium between the vascular (VS) and different extravascular (EVS I+II) spaces with rapid and slow diffusion rates, respectively EVS I and II can be connected both in series (left) and parallel (right) to VS

beam hardening effect This artifact is due to the filtering of the radiation especially in tissues containing elements of high atomic number such as bone As GADO et coll (1975) have shown the artifact varies across the image Conceivably it also varies with the scan level i e with various fractions of bone tissue in the section (Fig 3) Curves like the one in Fig 3 may be constructed for each type of instrument and should be used for correction in all kinds of quantitative measurement using CT scanners

Blood brain barrier breakdown In the first clinical CT work of ÉTHIER et coll (1974) it was postulated that contrast enhancement was completely due to the vascularity of the lesion AMBROSE (1974) HATAM et coll and GADO et coll (1975) ascribed the enhancement to two factors vascularity and breakdown of the blood brain barrier (BBB) So far a comprehensive model has not been elaborated to explain the temporal course of enhancement in different lesions One tentative model is a two compartment system within which the contrast medium is distributed (Fig 18) One compartment should then correspond to the intravascular space the other compartment to the extravascular part of the lesion into which the medium may leak through the injured blood brain barrier Possible active transport mechanisms are disregarded in this model for the sake of simplicity neither has the fact been taken into account that the membrane outlining the vascular space in extracerebral lesions is by definition not identical with the blood brain barrier The relative sizes of the compartments and transport capacity per unit time reflecting the extent of the damage of the BBB would then determine the shape of the curves Thus the concentration curve of a highly vascular tumour with a small extravascular

compartment would follow the concentration of contrast medium in blood This would also be the case of a lesion with scant vascularization but a rapid passage of indicator substance to the extravascular space and back again Such characteristics of the theoretical model may explain the discrepancy between the high initial enhancement phase of some of the meningioma curves and the low degree of vasculari zation as demonstrated by angiography of the same tumours However it does not explain why gliomas may have a high initial enhancement peak followed by a very slow decrease and still appear to be poorly vascularized at angiography This implies a more complex system than was first assumed and at least one more com partment has to be introduced to explain the shape of these curves (Fig 19)

The extended model would thus include one vascular compartment one extra vascular compartment to which there is a rapid passage and at least one further to which there is a slow passage of contrast medium The morphologic correlates to the postulated extravascular compartments may be assumed to range from extra cellular or CSF spaces to different cell populations within various lesions intra or extracerebral but no conclusions as to their nature are warranted from the present results The three-compartment model also explains the curve indicating a slow continuous uptake of contrast medium in a lesion (Fig 12 3) In normal brain tissue the relative vascular volume is less than 5 per cent The extravascular space could then be at most 20 times larger than the vascular space and therefore the enhancement may be increasing by a slow diffusion into this compartment even during the phase of decreasing blood concentration as long as a concentration gradient still exists The same theory would also hold for radioactive non diffusible indicators (cf HATAM et coll) According to this model differential diagnosis from the enhancement curves would require that each group of lesions have specific diffusion characteristics in common and that the various groups differ in this respect In the present series the enhancement characteristics of the different groups of lesions have been described as linear functions of time and not as sums of exponential functions—an approach necessitated by the low number of observa tions and the relative uncertainty of each value

The meningiomas have a similar initial phase This may in some cases be due mainly to a high degree of vascularization and in other cases more to a rapid diffusion of contrast medium to the extravascular space However the steep decrease of the curves indicates that the possible contribution from a hypothetical compartment with slow diffusion is very small

The gliomas are very heterogeneous from a morphologic point of view and demonstrate great variations in the initial phase of the curves but almost all of them have a slower decrease than do the meningiomas indicating a contribution from a compartment with slow diffusion No systematic difference in the early phase of CT enhancement separated tumours with AV shunting from those without shunt at angiography which could in part be explained simply by the great differences in measuring times

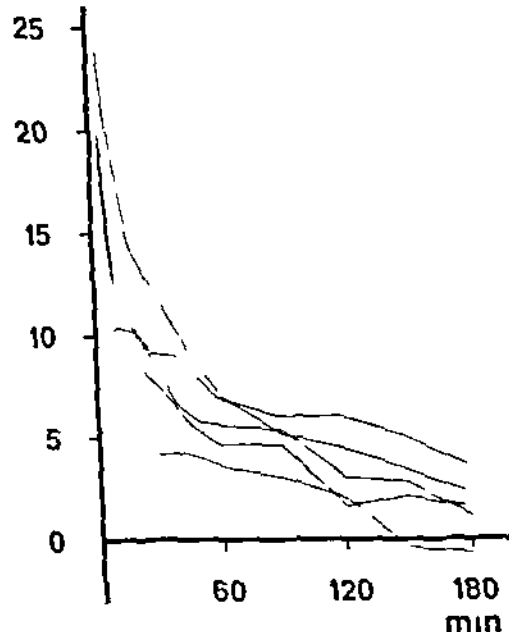


Fig 0 Blood clearance curves from 5 patients after intravenous bolus injection of Isopaque Cerebral 1 ml per kg body weight

The group of astrocytomas grade I-II differed distinctly from the other types of gliomas having only a slight or no enhancement All the infarctions in the present series demonstrate a similar lack of enhancement and this method cannot be used for differential diagnosis in such cases The infarct response in the present series is not in accordance with other reports (YOCK & MARSHALL 1975 WING et coll 1976) where contrast enhancement of infarctions has been observed in 20 to 60 per cent of cases Enhancement is a phenomenon dependent on many factors such as extent and degree of blood brain barrier lesion time after onset of symptoms and tech nique of the CT procedure (contrast medium injected as a bolus or by infusion amount of medium and time of scanning after injection) While differences in these respects may contribute to explain the discrepant features of the present series of infarcts considering the small number of cases they may be largely incidental

An important question is if the time resolution of the present scanner is satis factory each scan taking approximately 6 5 min Blood samples taken at short intervals following a bolus injection of contrast medium demonstrate clearance rates with time according to Fig 20 In the initial phase the contrast enhancement of blood varies so rapidly that a scanning time down to a few seconds would of course provide more correct information on the attenuation dynamics of the vascular compartment but factors such as recirculation and variations of injection technique would then complicate the evaluation Only further clinical research can demonstrate whether a faster scanner would make it possible to distinguish between true vascular

and rapid diffusion extravascular compartments In the later phase of the curve the variation of contrast enhancement is so slow that a scanning time of about 5 min is not critical

Administration of contrast medium The general drawbacks with the bolus injection for enhancement investigations have already been pointed out i e variations of injection rate and recirculation Lesions which according to the model presented appear to have an extravascular compartment with a very slow diffusion rate call for special attention As evident from Fig 20 the high clearance rate of the contrast medium from the systemic circulation implies that such lesions reach a low maximum enhancement A bolus injection followed by an infusion to give a constant concentration level of contrast medium in the blood should be a more relevant mode of administration for such lesions and would also enable a more accurate determination of slow diffusion rates

Conclusion

Temporal analysis of contrast enhancement may be used to improve differential diagnosis of intracranial lesions To be applicable in practical work the method requires the use of simple but reliable head fixation more rigid than that of the water bag of the first EMI scanner to allow repeat measurements of sufficient reproducibility An observation time of 30 to 60 min constitutes the upper limit of what can be done without access to special head fixation facilities Further analysis of the 30 to 60 min enhancement phase using fast scanning equipment as well as 3 to 6 h measurements with high reproducibility will be necessary in order to take full advantage of the differential diagnostic potential of contrast enhancement

Acknowledgement

This work was in part supported by grants from the Swedish Cancer Society and Carl Berthel Nathorst Foundation for Science and Public Utility

SUMMARY

The time course of enhancement in apparently normal brain tissue edema and focal lesions during 30 to 60 min after intravenous injection of vascular contrast medium was evaluated in a series of 41 patients with different intracranial lesions The attenuation of apparently normal unenhanced brain tissue varied with the level of the scan mainly an effect of beam hardening Different types of enhancement response are discussed in terms of a 3-compartment model The differential diagnostic potential of contrast enhancement in the early phase needs further evaluation using instruments with short scanning time while the late phase of enhancement must be recorded with the use of a reliable head fixation to provide reproducibility of repeat measurements

ZUSAMMENFASSUNG

Der Zeitverlauf der Verstarkung des Strahlenschwachungsvermogen in offenbar normalem Gehirngewebe und in Gewebe mit Ödem oder fokaler Lasion wahrend 30 bis 60 Minuten nach intravenoser Injektion von einem vaskularen Kontrastmittel wurde bei 41 Patienten mit verschiedenen intrakraniellen Lasionen festgestellt Das Strahlenschwachungsvermogen von normalem Gehirngewebe mit nicht verstarktem Schwachungsvermogen variiert mit dem Niveau des Scans uberwiegend ein Effekt der Wellenlange der Strahlen Verschiedene Typen von erhohtem Schwachungsvermogen werden mit Hilfe eines 3 Kompartment Modells diskutiert Die differentialdiagnostischen Moglichkeiten der Schwachungsverstarkung in der fruhen Phase verlangt eine weitere Untersuchung unter Verwendung von Geraten mit kurzer Aufnahmedauer wahrend die Schwachungsverstarkung der spaten Phase unter Verwendung einer geeigneten Schadelhalterung registriert werden muss um die Reproduzierbarkeit von wiederholten Messungen zu sichern

RESUME

L évolution en fonction du temps du renforcement de l attenuation dans le tissu cerébral apparemment normal dans l oedème et dans les lésions focales de 30 à 60 minutes apres injection intraveineuse de moyen de contraste vasculaire a eté etudiee sur une serie de 41 patients ayant differentes lesions intracraniennes L attenuation du tissu cerebral apparemment normal sans renforcement varie avec le niveau de la coupe surtout en raison du durcissement du faisceau Differents types de renforcement d attenuation sont etudiés suivant un modele tri-compartimental Le diagnostic differentiel potentiel du renforcement par le contraste dans la phase precoce nécessite d autres recherches faites avec des instruments ayant un temps de balayage court alors que la phase tardive du renforcement doit etre etudiée avec une fixation convenable de la tete permettant la reproductibilite de mesures repetees

REFERENCES

AMBROSE J Computerized transverse axial scanning (tomography) Part 2 Clinical application Brit J Radiol 46 (1973) 1023

— Computerized X ray scanning of the brain J Neurosurg 40 (1974) 679

BERGSTROM M and SUNDMAN R Analysis of regions of interest in EMI scans Brit J Radiol 49 (1976) 549

— and GREITZ T Stereotaxic computed tomography Amer J Roentgenol 127 (1976) 167

BOËTHIUS J COLLINS V P EDNER G LEWANDER R and ZAJICEK J Stereotactic biopsies and computer tomography in gliomas Accepted for publication in Acta neurochir (1977)

ETHIER R SHERWIN A TAYLOR S LEPPIK I and THOMPSON C First International C A T Symposium Montreal 1974

GADO M H and PHELPS M E The peripheral zone of increased density in cranial computed tomography Radiology 117 (1975) 71

— — and COLEMAN E R An extravascular component of contrast enhancement in cranial computed tomography Radiology 117 (1975) 595

GAWLER J DU BOULAY G H BULL J W D and MARSHALL J Computer assisted tomography Its place in investigation of suspected intracranial tumours Lancet 2 (1974) 419

GONZALES C GROSSMAN C and PALACIOS E Computed brain and orbital tomography John Wiley & Sons New York 1976

GREITZ T Computer tomography for diagnosis of intracranial tumours compared with other neuroradiologic procedures Acta radiol (1975) Suppl No 346 p 14

GREPE A GREITZ T and NORÉN G Computer cisternography of extracerebral tumours using lumbar injection of watersoluble contrast medium Acta radiol (1975) Suppl No 346 p 51

HATAM A BERGVALL U LEWANDER R LARSSON S and LIND M Contrast medium enhancement with time in computer tomography Acta radiol (1975) Suppl No 346 p 63

HOUNSFIELD G Computerized transverse axial scanning (tomography) Part I Description of system Brit J Radiol 46 (1973) 1016

KRAMER R A JANETOS G P and PERLSTEIN G An approach to contrast enhancement in computed tomography of the brain Radiology 116 (1975) 641

LEKSELL L A stereotaxic apparatus for intracerebral surgery Acta chir scand 99 (1949) 229

— The stereotaxic method and radiosurgery of the brain Acta chir scand 102 (1951) 316

— Some principles and technical aspects of stereotaxic surgery *In* Pain p 493 Little Brown and Company Boston 1966

— (a) A note on the treatment of acoustic tumours Acta chir scand 137 (1971) 763

— (b) Stereotaxis and radiosurgery Charles C Thomas Springfield Ill 1971

NEW P F J and HOCHBERG F H Computed tomography with the EMI scanner in the diagnosis of primary and metastatic intracranial neoplasms Radiology 114 (1975) 75

— SCOTT W R SCHNUR J A DAVIS K R and TAVERAS J M Computerized axial tomography with the EMI scanner Radiology 110 (1974) 109

PAXTON R and AMBROSE J The EMI scanner A brief review of the first 650 patients Brit J Radiol 47 (1974) 530

PHELPS M E HOFFMAN E J and TER POGOSSIAN M M Attenuation coefficients of various body tissues fluids and lesions at photon energies of 18 to 136 keV Radiology 117 (1975) 573

SÖDERSTRÖM C E KJELLIN K G and CRONQVIST S Computer tomography compared with spectrophotometry of cerebrospinal fluid in cerebrovascular lesions Acta radiol (1975) Suppl No 346 p 130

WING S D NORMAN D POLLOCK J A and NEWTON M D Contrast enhancement of cerebral infarcts in computed tomography Radiology 121 (1976) 89

YOCK D H and MARSHALL W H Recent ischemic brain infarcts at computed tomography Appearances pre and postcontrast infusion Radiology 117 (1975) 599

FROM THE DEPARTMENT OF RADIOLOGY FONDATION OPHTALMOLOGIQUE A DE ROTHSCHILD F 75019 PARIS FRANCE SECTION OF NEURORADIOLOGY UNIVERSITY HOSPITAL S 221 85 LUND SWEDEN DEPARTMENT OF NEURORADIOLOGY HOPITAL BICETRE F 94270 LE KREMLIN BICETRE AND THE DEPARTMENT OF NEURORADIOLOGY CENTRE HOSPITALIER REGIONAL ET UNIVERSITAIRE F 14000 CAEN FRANCE

RECURRENT CAVERNOUS BRANCHES OF THE OPHTHALMIC ARTERY

P LASJAUNIAS J BRISMAR J MORET and J THERON

Recurrent branches of the ophthalmic artery have been known for a long time A constant anastomotic channel between the intra orbital ophthalmic artery and the internal carotid artery has been described in several reports since the end of the 19th century (SAPPEY 1888 POIRIER 1896 LASJAUNIAS et coll 1975) The embryologic basis of this collateral is still unknown (PADGET 1948 DE LA TORRE & NETSKY 1960 LIE 1968) A similar ophthalmo-carotid anastomotic channel exists in the dog (MILLER et coll 1965) and some other vertebrates This channel must not be confused with the recurrent meningeal vessel arising from the ophthalmic artery as described before (STATTIN 1961 SCHNURER & STATTIN 1963 KURU 1967)

The intention of the present report which constitutes one part of a more extensive radiologic and anatomic analysis of the arterial blood supply of the base of the skull (LASJAUNIAS 1975 LASJAUNIAS et coll 1975 LASJAUNIAS & THERON 1976) is to combine experiences from neuroradiology and neuroanatomy in order to evaluate the embryologic and clinical significance of these recurrent branches of the ophthalmic artery

Material

The dissection material consisted of bilaterally injected orbits with the cavernous regions in 10 humans and 7 dogs i e 20 and 14 orbits and cavernous regions respec

Submitted for publication 21 January 1977



Fig 1



Fig 2

Fig 1 Normal case Angiography of the internal maxillary artery Lateral view Filling of infero-lateral trunk (4) of carotid siphon through cavernous branch (8) of middle meningeal artery (9) The deep recurrent ophthalmic artery (2) is filled in retrograde direction from the ophthalmic artery (1) and anastomoses with the infero lateral trunk (4) Artery of the foramen rotundum (6)

Fig 2 Meningeoma of the anterior clinoid process Angiography of the internal carotid artery Lateral view The deep recurrent ophthalmic artery (2) originating from the ophthalmic artery (1) participates in the supply of the tumor and anastomoses with the infero lateral trunk (4) of the carotid siphon (3)



Fig 3 Arteriovenous malformation of the superior petrosal sinus Angiography of the internal carotid artery Lateral view The deep recurrent ophthalmic artery (2) originating from the ophthalmic artery (1) participates in the supply of the malformation

tively The injections were performed on specimens 24 to 48 hours after death using a radiation absorbing coloured plastic material The technique has previously been described in detail (LASJAUNIAS et coll)

Part of the angiographic material was selected from 120 intracranial arterio-venous malformations and 40 meningeomas of the falx and tentorium cerebelli examined at the University Hospital of Lund the other part has been chosen from magnification angiographies of the orbit made at the Fondation Ophtalmologique A de Rothschild

Table

Origin of the marginal tentorial artery in 10 human cadavers with bilaterally injected orbits and cavernous regions

Origin	No of cases
C5 part of carotid siphon (posterior group of branches)	7
C4 part of carotid siphon (infero-lateral trunk)	6
C4–C5 part of carotid siphon (common lateral and posterior trunk)	1
Middle meningeal artery	2
Accessory meningeal artery	1
Intra-orbital ophthalmic artery	1
Lacrimal artery	2

Results

Two discrete recurrent branches of the ophthalmic artery have been identified One supplies the deep cavernous region adjacent to the neural wall of the cavernous sinus and anastomoses with the C4 part of the internal carotid siphon This branch is called the deep recurrent ophthalmic artery The second branch supplies the dural roof of the cavernous region and is a true dural branch of the ophthalmic artery which sometimes courses caudally to continue as the marginal tentorial artery This branch is called the superficial recurrent ophthalmic artery

The deep recurrent ophthalmic artery constantly present in the dissection material arises from the first part of the intra orbital ophthalmic artery and courses caudally through the tendon of Zinn and the medial part of the superior orbital fissure to reach the cavernous region It then passes medial to the oculomotor nerve and the ophthalmic branch of the trigeminal nerve usually following and supplying the fourth nerve It consistently anastomoses with the antero-medial branch of the infero lateral trunk of the intracavernous carotid artery This connection (Fig 1) is usually narrow but in some cases the deep recurrent ophthalmic artery may constitute the main artery of the lateral part of the cavernous region (Figs 2 3)

In normal cases this anastomotic channel may be identified at superselective angiography of the internal maxillary artery (Fig 1) or angiography of the internal carotid artery using magnification and subtraction

In pathologic cases this anastomotic channel has been identified without magnification 3 times in one case the deep recurrent ophthalmic artery was enlarged and with its collaterals constituted the main blood supply of a meningeoma of the anterior clinoid process (Fig 2) in a second case it supplied an arteriovenous fistula of the




Fig 4 Normal case. Angiography of the internal maxillary artery a) A p b) lateral view The superficial recurrent ophthalmic artery (17) arises from the lacrimal artery (16) and continues posteriorly as the artery of the free margin of the tentorium Ophthalmic artery (1) Middle meningeal artery (9)

superior petrosal sinus (Fig 3) and in a third case a meningeoma of the basal tentorium cerebelli

The angiographic appearance of this vessel is characteristic in the lateral projection It fills from the ophthalmic artery and courses backwards initially projecting above the ophthalmic artery but further posterior below this artery (Figs 1–3) In the cavernous region it projects below the C5 and C4 parts of the carotid siphon (Figs 2, 3)

The superficial recurrent ophthalmic artery The variability of the origin of the marginal tentorial artery in 20 human anatomic preparations (bilateral dissection in 10 cadavers) appears from the Table It originated from the ophthalmic artery inside the orbit 3 times in 2 cases from the lacrimal artery and in one case from the second part of the intra-orbital ophthalmic artery In these 3 cases the recurrent artery passed backwards through the most lateral part of the superior orbital fissure and coursed under the ipsilateral anterior clinoid process to reach the cavernous roof where it supplied the intradural parts of the third and fourth nerves More caudally it followed the free margin of the tentorium cerebelli supplying its marginal third The superficial recurrent ophthalmic artery was identified in 5 of 100 normal internal carotid angiographies using magnification and photographic subtraction It may also be identified at angiography of the internal maxillary artery when filling of the ophthalmic artery is achieved (Fig 4) in one case it supplied a meningeoma of the clivus.

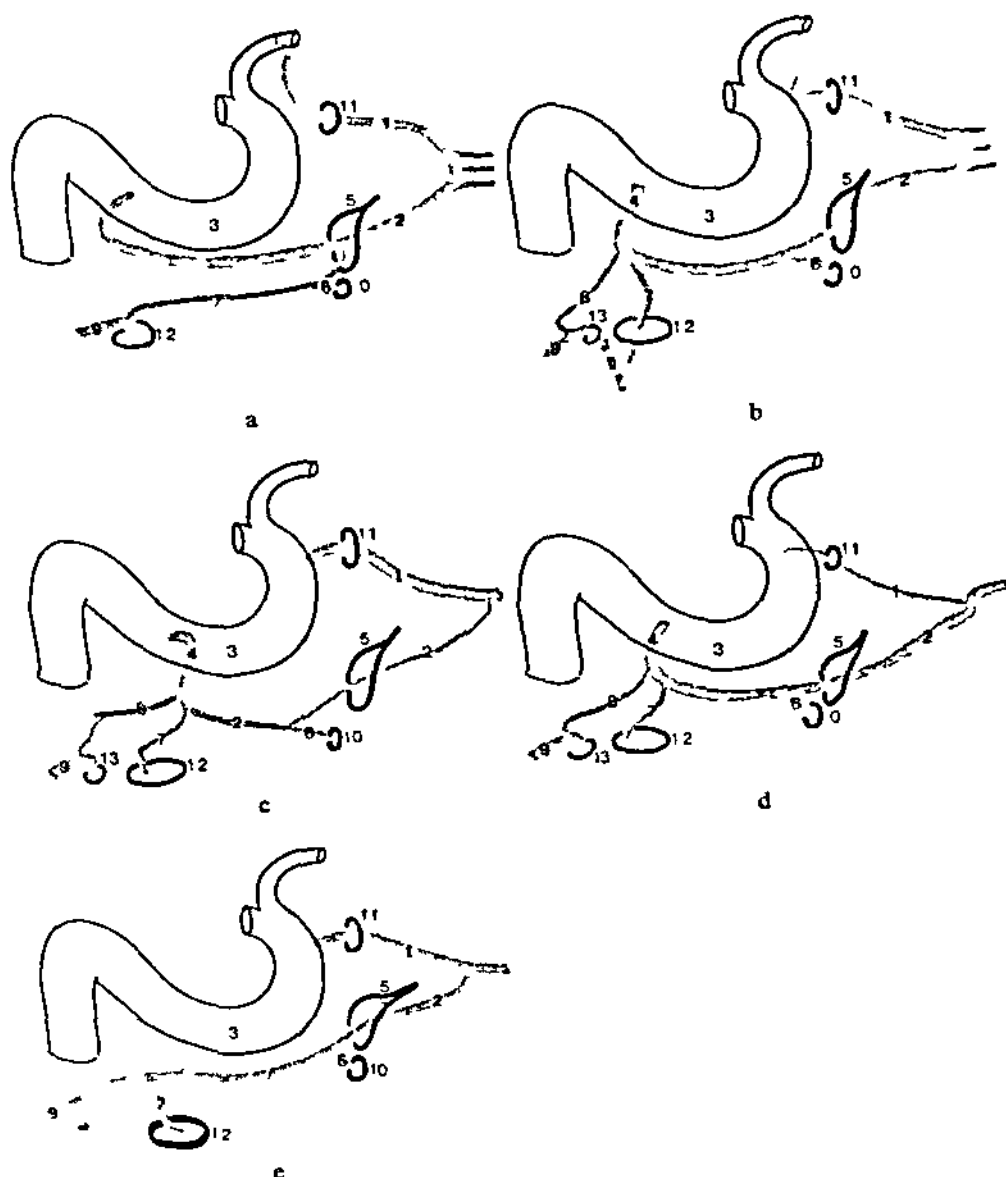


Fig 5 Development of the ophthalmic artery and of the arterial supply of the cavernous region (schematic) a) Dog, b) human foetus (8 mm) c d e) human adult The ventral ophthalmic artery of the foetus (b 1) and the ophthalmic artery in the dog (a 1) originate from the anterior cerebral artery (a 18) In both species it is connected to the carotid siphon through an anastomotic channel the anastomotic artery of the dog (a, 2) and the dorsal ophthalmic artery (b 2) in the foetus This channel is connected to the middle meningeal artery (9) through the anastomotic ramus in the dog, through the accessory meningeal artery (b 7) in the foetus In the adult the ophthalmic artery through an anastomotic loop achieves its normal origin (c 1) from the carotid siphon (3) and the dorsal ophthalmic artery only remains as the infero-lateral trunk (4) still connected to the accessory meningeal artery (c 7) Persistent dorsal ophthalmic artery (d) with regression of the ventral ophthalmic artery accounts for the cavernous origin of the ophthalmic artery In the adult a persistent dorsal ophthalmic artery with proximal regression in combination with a normal ophthalmic artery explains the occurrence of the deep recurrent ophthalmic artery (e 2) which supplies the territory of the infero-lateral trunk

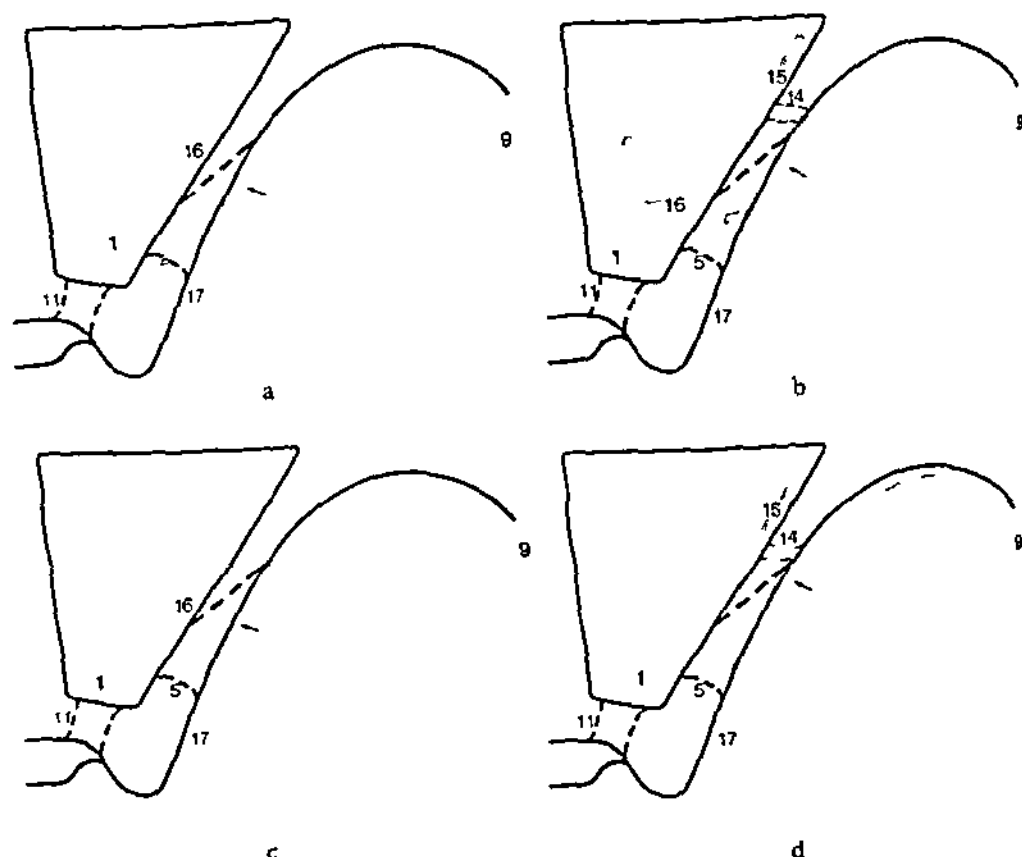


Fig 6 Explanation of intra orbital origin of marginal tentorial artery Right orbit (roof removed) and right cavernous region viewed from above Ophthalmic artery (1) lacrimal artery (16) middle meningeal artery (9) superficial recurrent ophthalmic artery (17) meningo-lacrimal artery (15) superior orbital fissure (5) optic canal (11) Hyrtl s canal (14) a b) Postulated situation in the embryo with an arterial arch connecting possible trunks of origin for the marginal tentorial artery a) Lacrimal type b) Menigo-lacrimal type c d) Different origins of the marginal tentorial artery from the intra orbital arteries in the adult Supposed embryologic site of regression (→)

The angiographic appearance of this vessel is characteristic in the a p view (Fig 4) In the lateral view it projects above the C4 part of the carotid siphon crossing the C3 part under or on the anterior clinoid process and thus has a course somewhat more cephalad than that of the deep recurrent ophthalmic artery

Discussion

In the dog the internal carotid siphon gives rise to an artery (the anastomotic artery) which enters the orbit through the superior orbital fissure and anastomoses with the internal ophthalmic artery (arising from the anterior cerebral artery MILLER et coll Fig 5 a)

The C4 part of the carotid siphon in the human embryo gives rise to a transient

ophthalmic artery (PADGET Fig 5 b) which enters the orbit through the superior orbital fissure In the orbit this artery anastomoses with the ventral ophthalmic artery (future ophthalmic artery of the adult) which initially originates from the anterior cerebral artery and migrates to the C3 part of the internal carotid artery by an anastomotic loop (PADGET Fig 5 b) Thus it appears as if the infero lateral trunk of the C4 part of the carotid siphon in man is homologous to the proximal part of the anastomotic artery of the dog as well as to the dorsal ophthalmic artery of the human embryo The deep recurrent ophthalmic artery might be a remnant of these two systems (Fig 5 c) A persistence of the transient dorsal ophthalmic artery of the embryo combined with regression of the ventral ophthalmic artery (Fig 5 d) would account for the cavernous origin of the ophthalmic artery observed in 2 per cent of normal carotid angiographies The unusual regression of the most proximal part of the dorsal ophthalmic artery will account for a main supply of the cavernous region by the deep recurrent ophthalmic artery (Fig 5 e)

The marginal tentorial artery in the dissection material had a markedly varying point of origin This may be explained by postulating an embryologic arterial arch connecting the different possible trunks of origin of the marginal artery (Fig 6) Regression of different parts of this arch during development may explain the variants encountered regression of the extra orbital (i e proximal) part of the orbital branch of the middle meningeal artery (the meningo ophthalmic or recurrent meningeal artery LASJAUNIAS) may for example explain the orbital origin of the marginal tentorial artery (Fig 6)

SUMMARY

Two arteries arising from the orbit coursing through the superior orbital fissure to supply the cavernous region and the tentorium may be identified at angiography The radiologic and anatomic appearances of these arteries are discussed on the basis of the embryologic development

ZUSAMMENFASSUNG

Zwei Arterien die von der Orbita ausgehen und Fissura orbitalis superior zur Versorgung der Cavernosusregion und das Tentorium passieren konnen bei der Angiographie identifiziert werden Das radiologische und anatomische Aussehen dieser Arterien wird auf Basis der embryologischen Entwicklung diskutiert

RESUMÉ

L angiographie permet d identifier deux artères provenant de l orbite traversant la fente sphénoidale pour irriguer la region caverneuse et la tente du cervelet Les aspects radiologiques et anatomiques de ces arteres sont discutes sur la base du développement embryologique

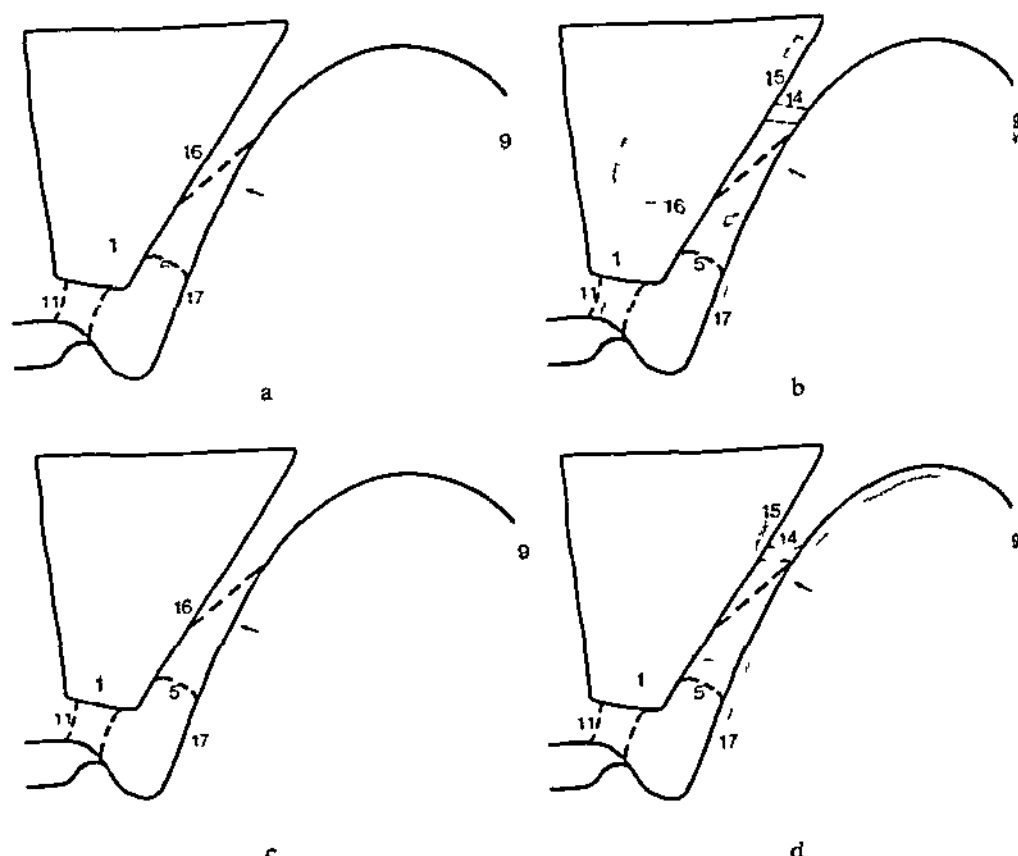


Fig 6 Explanation of intra-orbital origin of marginal tentorial artery Right orbit (roof removed) and right cavernous region viewed from above Ophthalmic artery (1) lacrimal artery (16) middle meningeal artery (9) superficial recurrent ophthalmic artery (17) meningo-lacrimal artery (15), superior orbital fissure (5) optic canal (11) Hyrtl s canal (14) a b) Postulated situation in the embryo with an arterial arch connecting possible trunks of origin for the marginal tentorial artery a) Lacrimal type b) Menigo-lacrimal type c d) Different origins of the marginal tentorial artery from the intra orbital arteries in the adult Supposed embryologic site of regression (→)

The angiographic appearance of this vessel is characteristic in the a p view (Fig 4) In the lateral view it projects above the C4 part of the carotid siphon crossing the C3 part under or on the anterior clinoid process and thus has a course somewhat more cephalad than that of the deep recurrent ophthalmic artery

Discussion

In the dog the internal carotid siphon gives rise to an artery (the anastomotic artery) which enters the orbit through the superior orbital fissure and anastomoses with the internal ophthalmic artery (arising from the anterior cerebral artery MILLER et coll Fig 5 a)

The C4 part of the carotid siphon in the human embryo gives rise to a trans rt

FROM THE DEPARTMENT OF NEURORADIOLOGY (DIRECTOR B LILIEQUIST) UMEÅ UNIVERSITY HOSPITAL, S 901 85 UMEÅ AND THE DEPARTMENT OF NEURORADIOLOGY (DIRECTOR T GREITZ) KAROLINSKA SJUKHUSET S 104 01 STOCKHOLM SWEDEN

CISTERNAL CHANGES PRODUCED BY EXPERIMENTAL BALLOON TUMOURS IN THE POSTERIOR CRANIAL FOSSA

A post mortem investigation

M LINDQVIST

The development of stereotactic methods for the diagnosis and treatment of intracranial lesions (LEKSELL 1949 1971) has increased the demand for precision in preoperative localization The recent introduction of the non ionic water soluble contrast medium metrizamide has prompted new clinical methods for radiography of the intracranial cisterns both by *conventional radiologic technique* (GREPE 1975 b ROBERSON et coll 1976) and by computed tomography (GREITZ & HINDMARSH 1974 GREPE et coll 1975 ROBERSO et coll GREPE & GREITZ 1977) These factors have increased the need for detailed knowledge about the cisternal deformities associated with intracranial expanding lesions

The normal radiographic anatomy of the subarachnoid cisterns was reported in detail by LILIEQUIST (1959 a) Technical developments including easy application of tomography in pneumographic examinations have made it possible to routinely outline even small cisternal structures (VALENTINO 1956 DI CHIRO 1961 THIEBAUT et coll 1963 GREITZ & GREPE 1967 WACKENHEIM & ESCUDERO 1969) Some normal variations in the appearance of the vallecula on p a pneumographic tomograms were

Supported by grants from the Swedish Cancer Society and the Swedish Society of Medical Radiology Submitted for publication 27 June 1977

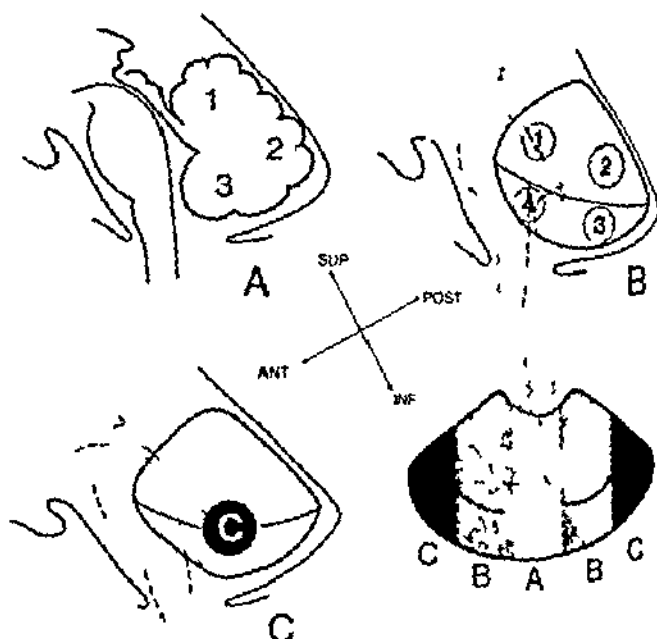


Fig 1 Main directions and classification of tumour locations (modified from Corrales & Greitz 1972)

described by HAMMER & SCHERRER (1973) The relation of the peritonsillar spaces to the veins of the posterior fossa was described by HUANG et coll (1969) while MÖLLER (1974) defined the pneumographic appearance of the peritonsillar spaces GREPE (1975 a) described the appearance of the cranial nerves in the basal cisterns

Pneumographic diagnosis of tumours of the posterior fossa has mainly been based on deformities and displacements of the fourth ventricle (LYSHOLM 1939 1946 TWINING 1939 DAVIDOFF & EPSTEIN 1950 ROBERTSON 1957 MCRAE & ELLIOTT 1958 CORRALES & GREITZ 1972 CORRALES 1972 MÖLLER)

Since the introduction of lumbar encephalography (ROBERTSON 1941 LINDGREN 1949) the appearances of the cisterns have also been used in the diagnosis of tumours in the posterior fossa mainly for the diagnosis of extraaxial tumours (LINDGREN 1950 CASTELLANO & RUGGIERO 1953 FALK 1953 RUGGIERO 1956 LILIEQUIST 1959 b)

The use of cisternal deformities in the diagnosis of intraaxial tumours in the posterior fossa has been limited (RUGGIERO 1957 LILIEQUIST 1963 KRAUSOVA & JIROUT 1963 PRIBRAM 1966 MÖLLER) and the reported findings are partly contradictory No systematic description of the detailed appearance of the cisterns with different locations of the tumours has previously been published An analysis of the deformities of the subarachnoid cisterns associated with experimental expanding lesions in the posterior cranial fossa outside the brain stem was therefore made using the stereotactic balloon technique Lesions in the fourth ventricle and brain stem could not be positioned with satisfactory precision with this technique and have therefore not been included in the series

Definitions The orientation of the structures of the posterior fossa is that given by CORRALES & GREITZ i e anteriorly posteriorly perpendicular to the clivus superiorly and inferiorly at right angles (Fig 1)

The balloons are located either in the vermis (section A) or in the hemispheres (sections B C) Three vermis locations (positions A1 A2 and A3) are termed superior posterior and inferior vermis tumours respectively Hemispheric lesions are medial (section B) or lateral (section C) As the hemisphere extends more anteriorly than the vermi section B is divided into four quadrants with one dividing line roughly parallel to the horizontal fissure and the other at right angles The supero anterior quadrant (position B1) is close to the tentorial notch the supero-posterior quadrant (position B2) is close to the tentorium the infero-posterior quadrant (position B3) is close to the occipital bone and the infero-anterior quadrant (position B4) is close to the pontine angle Extraaxial lesions of the pontine angle are denoted B4 ex Due to the shape of the posterior fossa and the hemispheres section C is considerably smaller and corresponds to the lateral part of the cerebellar hemisphere All these definitions are in agreement with those used by CORRALES & GREITZ with the exception that the C position has not been subdivided

The terminology used to describe the subarachnoid cisterns is in agreement with the nomenclature used by LILIEQUIST and additional definitions used by HAMMER & SCHERRER HUANG et coll and MÖLLER (Fig 2)

Material and Methods

Post mortem examination of mostly elderly patients without signs of intracranial disease was carried out using a separate case for the analysis of each of nine predetermined experimental tumour positions Previously the cisternographic technique has been reported in detail (LINDQVIST & MOLLER 1978) and is here only briefly described From a p and lateral films of cisternography with water soluble contrast medium the position of the balloon tumour was decided and defined by coordinates in the stereotactic system used (GREITZ et coll 1972) After repeated cisternography following the replacement of the water soluble contrast medium by a mixture of fluid plastic and red lead a balloon tumour was introduced to the previously determined position The balloon was inflated with 20 ml of air (equivalent to a diameter of about 3 cm) and a final cisternography with a p and lateral projections was obtained When the plastic material had solidified the posterior fossa and its contents were removed in one piece and a plastic cast of the cisterns was produced For analysis of the cisternal deformities photographic subtraction was used (Fig 3) as well as composite drawings inspection and also radiography of the plastic casts including tomography All the lateralized balloons were placed on the right side By the combination of subtraction with the stereotactic technique giving identical projections before and after the introduction of the balloon tumours very small changes were discernible on the lateral projections of the cisterns in situ The analysis of the a p projections

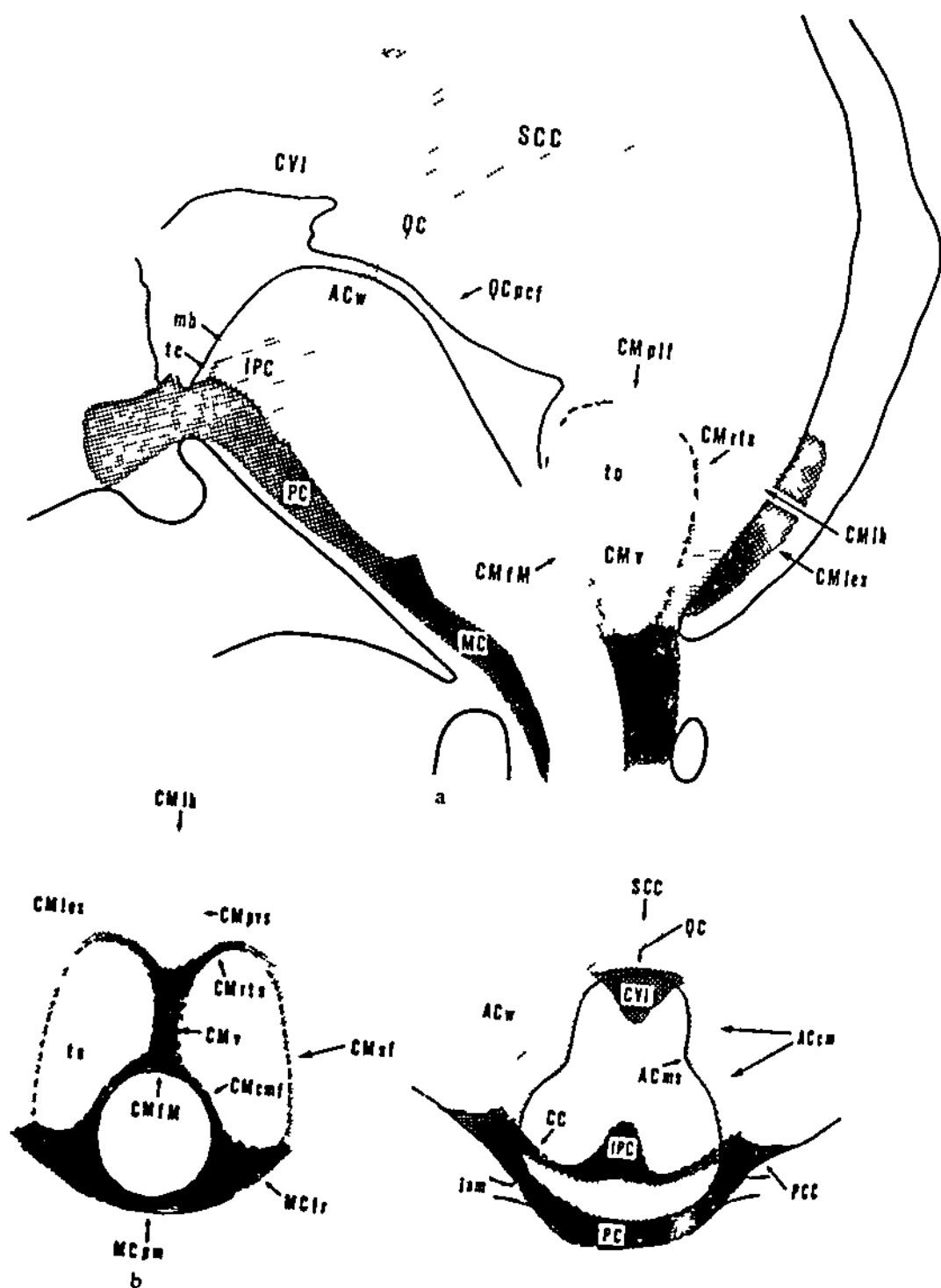


Fig 2 (For legend see opposite page)

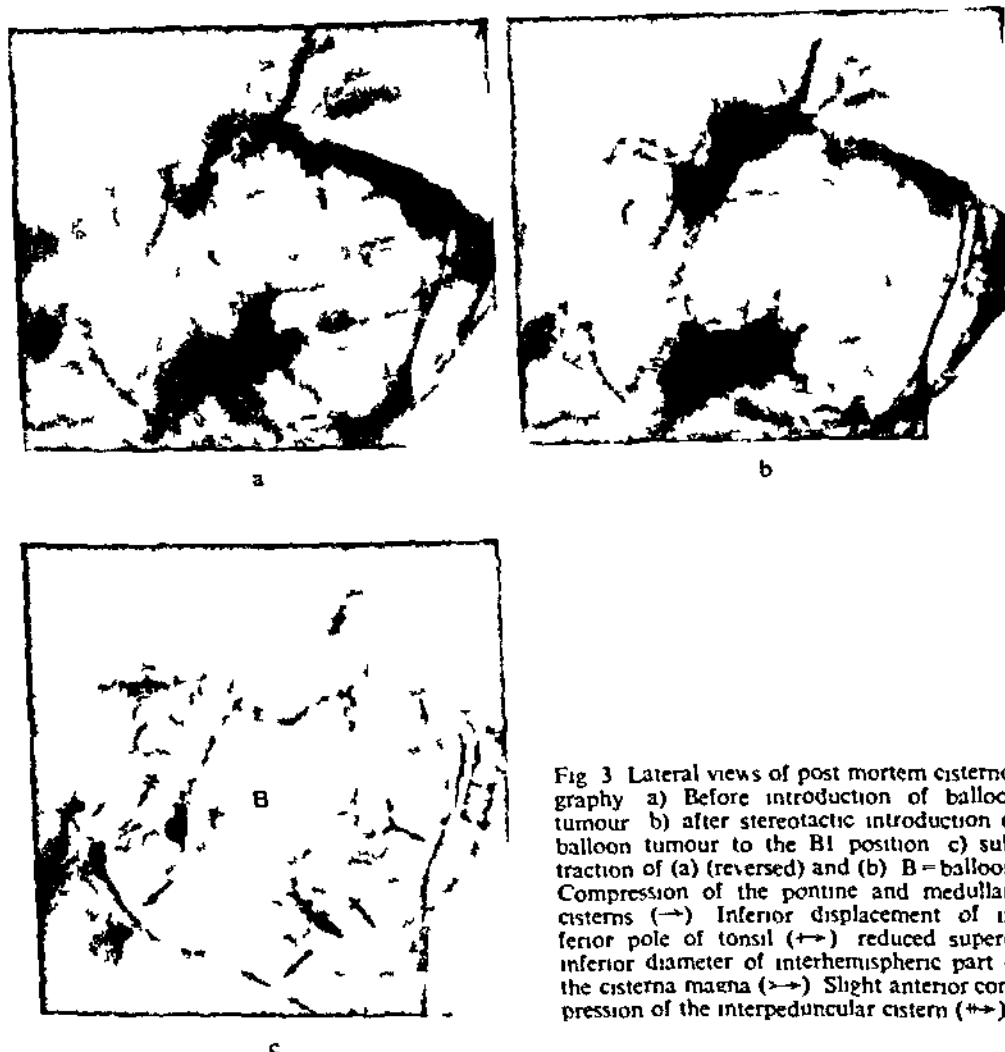


Fig 3 Lateral views of post mortem cisternography a) Before introduction of balloon tumour b) after stereotactic introduction of balloon tumour to the B1 position c) subtraction of (a) (reversed) and (b) B = balloon. Compression of the pontine and medullary cisterns (→) Inferior displacement of inferior pole of tonsil (↔) reduced supero-inferior diameter of interhemispheric part of the cisterna magna (>→) Slight anterior compression of the interpeduncular cistern (↠)

Fig 2 Schematic drawings of the subarachnoid cisterns a) Lateral view b) Axial view of the cisterns inferior to the fourth ventricle c) Axial view of the cisterns adjacent to the tentorial notch

Labelled structures
AC = ambient cistern
(cm – circummesencephalic part ms = mesencephalic sulcus w = wing)
CC = crural cistern
CM = cisterna magna
(cmf – cerebellomedullary fissure IM = foramen of Magendi ih – interhemispheric part lex = lateral extension plf = posterolateral fissure pvs = paravermian sulcus rts = retrotonsillar space sf = secondary fissure v = vallecula)
CVI – cisterna veli interpositi
iam = internal auditory meatus
IPC interpeduncular cistern
mb = mamillary body
MC medullary cistern
(lr = lateral recess pm = premedullary part)
PC = pontine cistern
PCC = pontocerebellar cistern
QC quadrigeminal cistern
(pcf = precentral fissure)
SCC = superior cerebellar cistern
tc = tuber cinerum
to = tonsil

was in part difficult because of superimposition and the additional information obtained from the rinsed plastic cast was often necessary to establish the appearances of the cisterns

Results

A synthesis of the cisternal changes produced by the balloon tumours as observed in situ and by inspection and radiography of the plastic casts is given in Tables 1 to 3 The balloon tumours in the positions A2 and A3 were situated a few mm to the right of the midline which explains the asymmetry of the tonsils the vallecula and some other structures The balloon in the position A3 extended down to the occipital bone compressing the interhemispheric part of the cisterna magna so that it could not be evaluated With the balloon position B4 ex filling of the cisterna magna was insufficient probably for technical reasons The retrotonsillar spaces could be evaluated in most of the cases Other parts of the secondary fissure as well as the posterolateral fissures were in general poorly defined and these structures have not been included in the tables In some cases also other cisternal structures have been excluded from the tables because of insufficient filling by contrast medium

The cisterna magna Table 1 The interhemispheric part was compressed against the occipital crest in all cases assessable (Fig 3 c) and as a rule with a predominance in midline balloon positions This part of the cistern had increased width transversely with position A1 while the width was decreased with positions C and B3 and unaltered with positions A2, B1 B3 and B4 It was not possible to evaluate this space with the balloon in positions A3 and B4 ex The interhemispheric part when identifiable was displaced towards the contralateral side with all lateral balloon positions and with position C it was also convex towards the contralateral side

The inferior pole of the tonsils with all positions with the exception of B3 was displaced inferiorly on one or both sides and in all lateral positions the inferior displacement was more evident on the side of the balloon A slight anterior displacement of the inferior pole of the tonsils was present on both sides with position A3 but only on the side of the balloon in positions B2 and B3 A slight ipsilateral posterior displacement of the inferior pole of the tonsil was observed only with balloon position B4 ex

The foramen of Magendi was displaced anteriorly in all cases most evident with balloon positions A2 and A3 least with position B4 ex

The vallecula was compressed and displaced towards the contralateral side with most lateral balloon positions The lateral displacement of the vallecula was usually greater posteriorly than anteriorly (B1 B2 B4 and C) while a tendency to more marked lateral displacement anteriorly was recorded with positions B3 and B4 ex With positions B2 and B4 ex the vallecula was also convex towards the contralateral side

The retrotonsillar spaces were not significantly deformed with the balloon in posi

Table 1

Distortion of the cisterna magna produced by balloon tumours positioned according to Corrales & Greit (197?) All balloons in B and C positions are on the right side Symbols and abbreviations a = anterior p posterior s = superior i = inferior R = right L = left 0 = no change (+) = minimal or questionable change or increase + = moderate change or increase + + = marked change or increase (−) = minimal or questionable decrease − = moderate decrease − − − = marked decrease open space = structure not demonstrable or not possible to evaluate

Site of balloon	A1	A2	A3	B1	B2	B3	B4	B4 ex	C
Cisterna magna									
1 Interhemispheric part posterior to uvula									
s i diameter	−	− −			−	( )	(−)		(−)
width	+	0		0	(−)	0	0		−
lateral displacement	0	0		0	L −	L −	L +		L −
convex towards	0	0		0	0	0	0		L −
2 Inferior pole of the tonsils									
a right									
a p displacement	0	0	a −	0	a −	a −	0	p(−)	0
s i displacement	i +	i + +	i −	i − −	i −	0	i + +	i −	i +
lateral displacement	0	0	L +	L −	L( )	L +	L +	L −	L +
b left									
a p displacement	0	0	a +	0	0	0	0	0	0
s i displacement	i +	i + +	i +	i(+)	0	0	0	i(−)	i(+)
lateral displacement	0	0	0	L −	0	L +	L +	L(+)	I +
3 Foramen of Magendi									
a p displacement	a	a + +	a + +	a +	a −	a −	a +	a(+)	a +
4 Vallecula									
a anterior part									
width	0	0	(−)	−	0	−	−	−	−
lateral displacement	0	L(+)	L +	L +	L(+)	L +	L +	L +	L +
b posterior part									
width	0	0	(−)	−	0	−	−	−	−
lateral displacement	0	L +	L(−)	L −	L +	L(+)	L + +	L(+)	L + +
c convexity in axial projection towards	0	0	0	0	L +	0	0	L +	0
5 Retrotonsillar spaces									
a right									
a p displacement	0	0	p +	p +	a +	a + +	p +		p + +
lateral displacement	0	0	L −	L −	L +	L +	L +		L +
b left									
a.p displacement	0	0	0	0	0	0	0		0
lateral displacement	0	0	L(−)	L( )	0	L +	L +		L +
6 Cerebellomedullary fissures									
a right									
a p displacement				a +		a(+)	a +		
lateral displacement	0	0		L +		L(+)	L +		L +
b left									
a p displacement				0	0	0	0		0
lateral displacement	0	0	L(+)	0	0	0	L +		L +

Table 2

Distortion of the medullary cistern pontine cistern pontocerebellar cisterns and interpeduncular cistern produced by balloon tumours Positions symbols and abbreviations as in Table 1 Additional abbreviations Ra = right side rotated anteriorly Rp = right side rotated posteriorly

Site of balloon	A1	A2	A3	B1	B2	B3	B4	B4 ex	C
Medullary cistern									
1 Premedullary part									
width	— —	—	— —	—	— —	—	— —	—	— —
2 Lateral recesses									
a right									
a p diameter	0	0	—	—	— —	0	—	+	+
lateral extension	0	0	—	+	0	+	+	+	+
b left									
a p diameter	0	0	—	(+)	(+)	0	0	0	—
lateral extension	0	0	—	—	0	0	—	— —	—
3 Rotation of medulla oblongata around axis parallel to the clivus	0	0	0	Ra +	Ra +	0	Ra(+)	Rp +	Rp +
Pontine cistern									
1 Lateral projection									
a superior part									
a p diameter	— —	—	— —	—	— —	—	—	— —	— —
b inferior part									
a p diameter	— —	—	— —		— —	—	—	— —	— —
c tendency of superior part of pons to recede from clivus	0	0	0	0	0	0	0	+	0
2 Axial projection									
a middle part									
a p diameter	—	—	— —	—	— —	—	—	—	—
b right lateral part									
a p diameter	—	—	— —	—	— —	0	—	—	0
c left lateral part									
a p diameter	— —	—	— —	— —	— —	—	—	— —	—
d rotation of pons around axis parallel to the clivus	0	0	0	0	0	0	0	Rp +	Rp +
Pontocerebellar cisterns									
1 Right cistern									
a lateral part									
width	(—)	—	—	—	— —	—	—	—	—
b medial part									
width	(—)	—	—	—	— —	0	—	+	—

Table 2 (*cont*)

Site of balloon	A1	A2	A3	B1	B2	B3	B4	B4 ex	C
2. Left cistern									
a lateral part width	(−)	−	−	0	−	−	−	−	0
b medial part width	(−)	−	−	0	− −	−	−	− −	0
Interpeduncular cistern									
a p diameter	−	−			0	−		−	−
lateral displacement	0	0	0	0	0	0	0	0	0
superior displacement of the pons	(+)	+	+	0	+	+ −	+	−	−

tions A1 and A2 and not appreciable in B4 ex With lateral balloon positions a posterior displacement was present on the same side as the artificial tumour in positions B1 B4 and C and an anterior displacement with positions B2 and B3 No antero-posterior displacement could be recorded on the contralateral side With several of the lateral balloon positions the retrotonsillar spaces on both sides were displaced towards the contralateral side

The cerebellomedullary fissures when demonstrable with lateral balloon positions were displaced towards the contralateral side (B1 B3 B4 and C) usually more on the side of the balloon than on the contralateral side In those cases where anterior displacement of the cerebellomedullary fissure could be evaluated (B1 B3 and B4) anterior displacement was recorded on the side of the artificial tumour but not on the contralateral side

The medullary cistern Table 2 The balloon tumour in all positions caused a moderate to marked anterior displacement of the medulla oblongata with compression of the premedullary part of the medullary cistern A symmetric compression of the premedullary part and of both the lateral recesses was recorded with position A3 due to compression from behind of the medulla oblongata With balloon positions B4 ex and C the a p diameter of the lateral recess on the side of the artificial tumour increased and a posterior rotation of the anterior surface of the medulla oblongata was present on the tumour side (Fig 4) Anterior rotation of the medulla oblongata on the side of the artificial tumour was recorded with positions B1 B2 and B4 With positions B1 B3 (Fig 5) B4 B4 ex and C the balloon caused an increased width of the lateral recess of the medullary cistern on the ipsilateral side and in most cases a decrease of the lateral recess of the contralateral side was recorded as a sign of displacement of the medulla towards the contralateral side

The pontine cistern Table 2 In the lateral projection the pons was displaced towards the clivus with all balloon positions—approximately the same in the superior

Table 2

Distortion of the medullary cistern pontine cistern pontocerebellar cisterns and interpeduncular cistern produced by balloon tumours Positions symbols and abbreviations as in Table 1 Additional abbreviations Ra – right side rotated anteriorly Rp = right side rotated posteriorly

Site of balloon	A1	A2	A3	B1	B2	B3	B4	B4 ex	C
Medullary cistern									
1 Premedullary part width	– –	–	– –	–	– –	–	– –	–	– –
2 Lateral recesses									
a right									
a p diameter	0	0	–	–	– –	0	–	+	+
lateral extension	0	0	–	+	0	+	+	+	+
b left									
a p diameter	0	0	–	(+)	(+)	0	0	0	–
lateral extension	0	0	–	–	0	0	–	– –	–
3 Rotation of medulla oblongata around axis parallel to the clivus	0	0	0	Ra+	Ra+	0	Ra(+)	Rp+	Rp+
Pontine cistern									
1 Lateral projection									
a superior part									
a p diameter	– –	–	– –	–	– –	–	–	– –	– –
b inferior part									
a p diameter	– –	–	– –	–	– –	–	–	– –	– –
c tendency of superior part of pons to recede from clivus	0	0	0	0	0	0	0	+	0
2 Axial projection									
a middle part									
a p diameter	– –	–	– –	–	– –	–	–	–	–
b right lateral part									
a p diameter	– –	–	– –	–	– –	0	–	–	0
c left lateral part									
a p diameter	– –	–	– –	– –	– –	–	–	– –	–
d rotation of pons around axis parallel to the clivus	0	0	0	0	0	0	0	Rp+	Rp+
Pontocerebellar cisterns									
1 Right cistern									
a lateral part									
width	( )	–	–	–	– –	–	–	–	–
b medial part									
width	(–)	–	–	–	– –	0	–	–	–

Table 3

Distortion of the ambient cistern quadrigeminal cistern superior cerebellar cistern and the cisterna veli interpositi produced by balloon tumours Positions symbols and abbreviations as in Tables 1 and 2 Additional abbreviations fr = rotated frontally sag = rotated sagittally ia = inferior end rotated anteriorly ip inferior end rotated posteriorly

Site of balloon	A1	A2	A3	B1	B2	B3	B4	B4 ex	C
Ambient cistern									
1 Circummesencephalic part									
a right side									
width	(−)	0	0	(+)	0	0	0	+	(+)
rotation around sagittal axis perpendicular to the clivus	fr +	0	0	fr +	fr +	fr +	fr (+)	fr - +	fr + +
b *left side*									
width	(−)	0	0	−	0	0	0	0	(−)
rotation around sagittal axis perpendicular to the clivus	fr +	0	0	sag +	sag +	sag +	sag (+)	sag (+)	sag +
2 Wings of ambient cistern									
a right									
width	(−)	0	0	( )	0	0	0	0	0
s i displacement	0	0	0	0	s+	s+	0	0	0
b left									
width	(−)	0	0	0	0	0	0		0
s i displacement	0	0	0	0	0	0	0		0
Quadrigeminal cistern									
1 Quadrigeminal plate									
a p displacement	a+	a+	p(+)	a+	0	a+	0	0	a+
s i displacement	s+	s+	s+	s+	0	s+ +	0	s+	s+
rotation around frontal axis perpendicular to the clivus	0	ia +	ip (+)	0	0	0	0	0	0
kinking of the quadrigeminal plate	0	0	(+)	0	0	0	0	0	0
2 Precentral fissure									
width	0	0	0	0	0	0	0	0	0
a p displacement	a+	a+	a(+)	a+	a+	a+	a+	0	a+
s i displacement	s+	s+	s+	s+	s+	s+	s+	s+	s+
Superior cerebellar cistern									
width	− −	−	−	(−)		−	−	(−)	−
Cisterna veli interpositi									
1 Medial part									
lateral displacement		0	0	R+	R+	R+		0	R+
2 Right lateral part									
a p displacement		0	0	p+	p+	p+	0	p+	0
3 Left lateral part									
a p displacement		0	0	a(+)	0	0	0	0	0

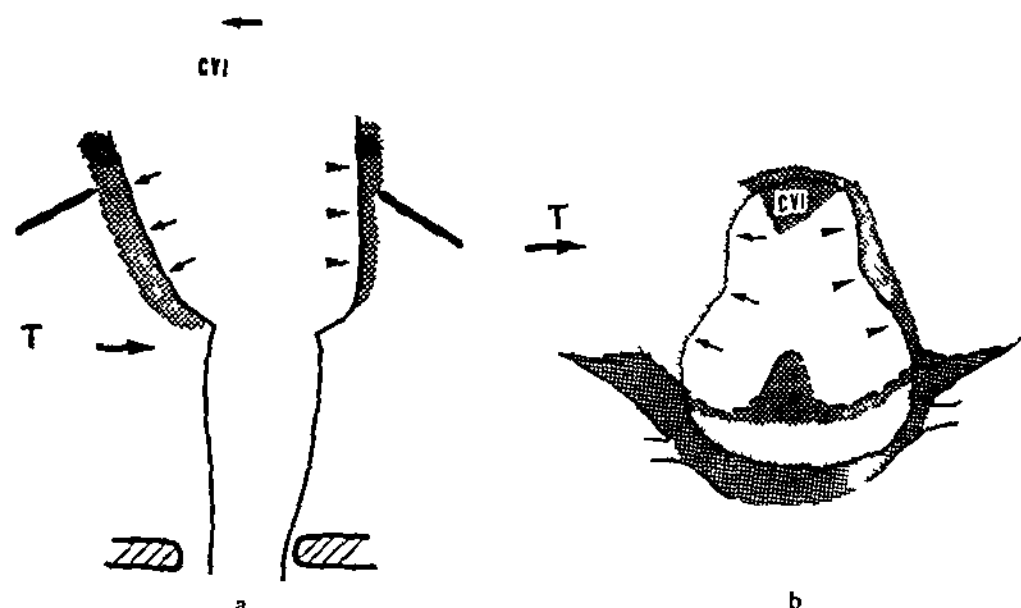


Fig 6 Cisternal deformities adjacent to the tentorial notch Balloon tumour = T a) A p view The infratentorial part of the brain stem displaced to the left supratentorial part and cisterna veli interpositi (CVI) slightly *displaced* towards the ipsilateral side On the tumour side the circummesencephalic part of the ambient cistern (→) is oblique to the sagittal plane on the contralateral side (▸) it is parallel to this *plane* b) *Axial* view The circummesencephalic part of the ambient cistern (→) on the tumour side wide but indistinct whereas on the contralateral side (▸) narrow but distinct. The cisterna veli interpositi (CVI) displaced towards th tumour side

The interpeduncular cistern Table 2 With balloon positions A1 A2 B1 B3 B4 ex and C a decrease of the antero-posterior diameter of the interpeduncular cistern was *found* With position B2 this diameter was unchanged and with positions A3 and B4 *it* was *not* possible to evaluate The supero inferior diameter of the cistern could not be evaluated with any position A significant lateral displacement of the cistern was *not recorded* in any of the cases With position A1 the superior displacement of the *pons* was insignificant and with B1 no such displacement occurred With all oth r balloon positions a superior displacement of the pons was evident most marked with the balloon in position B3

The ambient cistern Table 3 Normally the circummesencephalic part of the am*bient cistern* is slightly oblique to the axial beam due to the fact that the brain stem is wider in its superior part

All the lateralized balloons displaced the infratentorial part of the brain stem towards the contralateral side This made the cistern on the *ipsilateral* side ro ate so that it became more oblique to the axial beam whereas on the contralateral side it rotated so as to be more parallel to the axial beam (Figs 6 7) With the balloon positions B1 B4 ex and C also a widening of the ipsilateral cistern and a compression of the cistern on the contralateral side occurred



Fig 7 Plastic cast of specimen with balloon tumour in the C position a) A p tomography through the circummesencephalic part of the ambient cistern The tumour side is widened and oblique to the sagittal plane (→) the contralateral side compressed and parallel to the sagittal plane (↔) b) Axial tomography through the tentorial notch Tumour side (→) wider than contralateral side (↔)

With the balloon position A1 a tendency was recorded towards symmetric rotation frontally of the cistern on both sides of the brain stem and a slight compression of the cistern on both sides could also be found With positions B2 and B3 the ipsilateral ambient wing cistern was slightly displaced superiorly otherwise no changes of these parts of the ambient cistern were recorded

The quadrigeminal cistern Table 3 Superior and anterior displacement of the quadrigeminal plate and the precentral fissure was recorded with balloon positions A1 A2 B1 B3 and C With position A3 the quadrigeminal plate was displaced superiorly and slightly posteriorly while the precentral fissure was displaced superiorly and slightly anteriorly With positions B2 and B4 the quadrigeminal plate was not displaced while the precentral fissure was displaced anteriorly and superiorly With balloon position B4 ex the quadrigeminal plate and the precentral fissure were displaced superiorly but not anteriorly

An evident tendency to kinking of the quadrigeminal plate was recorded only with position A3

The superior cerebellar cistern Table 3 With balloon position B2 the superior cerebellar cistern could not be evaluated In all other cases the cistern was compressed most markedly with balloon position A1 least with positions B1 and B4 ex

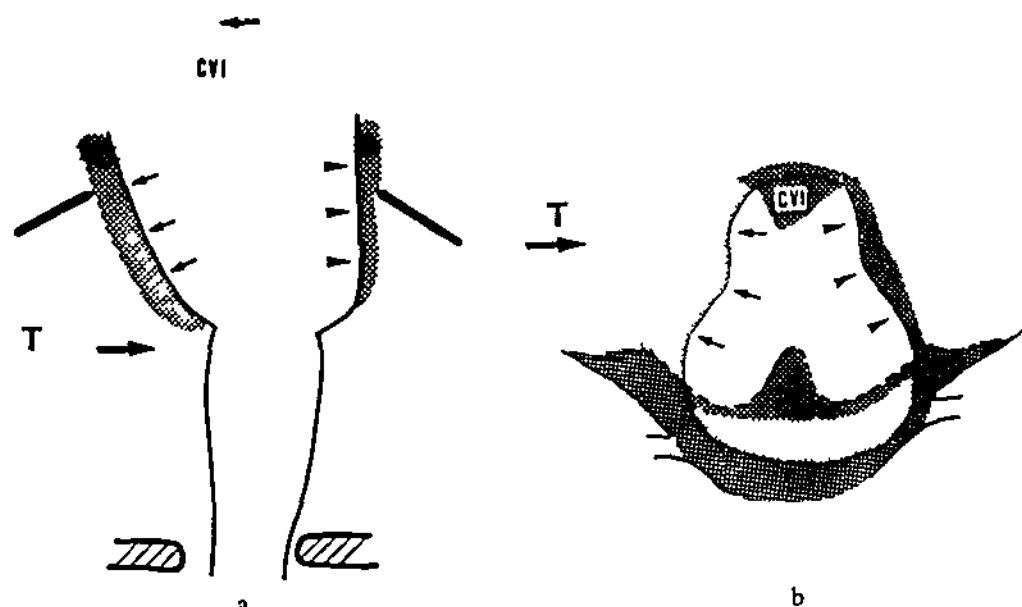


Fig 6 Cisternal deformities adjacent to the tentorial notch Balloon tumour = T a) A p view The infratentorial part of the brain stem displaced to the left supratentorial part and cisterna veli inter positi (CVI) slightly displaced towards the ipsilateral side On the tumour side the circummesencephalic part of the ambient cistern (→) is oblique to the sagittal plane on the contralateral side (▸) it is parallel to this plane b) Axial view The circummesencephalic part of the ambient cistern (→) on the tumour side wide but indistinct whereas on the contralateral side (▸) narrow but distinct The cisterna veli interpositi (CVI) displaced towards the tumour side

The interpeduncular cistern Table 2 With balloon positions A1 A2 B1 B3 B4 ex and C a decrease of the antero posterior diameter of the interpeduncular cistern was found With position B2 this diameter was unchanged and with positions A3 and B4 it was not possible to evaluate The supero inferior diameter of the cistern could not be evaluated with any position A significant lateral displacement of the cistern was not recorded in any of the cases With position A1 the superior displacement of the pons was insignificant and with B1 no such displacement occurred With all other balloon positions a superior displacement of the pons was evident most marked with the balloon in position B3

The ambient cistern Table 3 Normally the circummesencephalic part of the ambient cistern is slightly oblique to the axial beam due to the fact that the brain stem is wider in its superior part

All the lateralized balloons displaced the infratentorial part of the brain stem towards the contralateral side This made the cistern on the ipsilateral side rotate so that it became more oblique to the axial beam whereas on the contralateral sid it rotated so as to be more parallel to the axial beam (Figs 6 7) With the balloon positions B1 B4 ex and C also a widening of the ipsilateral cistern and a compression of the cistern on the contralateral side occurred

SUMMARY

Post mortem cisternography before and after stereotactic introduction of balloon tumours to predetermined positions in the posterior fossa was carried out Radiography in situ as well as radiography and inspection of plastic casts of the cisterns were used for the systematic analysis of the appearances of the cisterns

ZUSAMMENFASSUNG

Postmortale zisternographische Untersuchungen vor und nach stereotaktischer Ein fuhrung von Ballontumoren in vorausbestimmte Positionen in der hinteren Schadelgrube wurden ausgefuhrt Ausserdem wurde die Rontgenaufnahme und Inspektion der Plastaus gusse der Zisternen fur die systematische Analyse benutzt

RÉSUME

L auteur a fait une cisternographie post mortem avant et après *introduction stéreo* tactique de ballons simulant des tumeurs dans des positions predeterminées dans la fosse posterieure La radiographie in situ ainsi que la radiographie et l inspection de moules plastiques des citernes ont été utilisees pour l analyse systématique des aspects des citernes

REFERENCES

CASTELLANO F and RUGGIERO G Meningiomas of the posterior fossa Acta radiol (1953) Suppl No 104

CORRALES M Fourth ventricle III Intra and extra axial tumours Acta radiol Diagnosis 13 (1972) 370

— and GREITZ T Fourth ventricle II Tumours of the cerebellum Acta radiol Diagnosis 12 (1972) 241

DAVIDOFF L M and EPSTEIN B S The abnormal pneumoencephalogram Lea & Febiger Philadelphia 1950

DI CHIRO G An atlas of detailed normal pneumoencephalographic anatomy Charles C Thomas Springfield 1961

FALK B Encephalography in cases of intracranial tumour Acta radiol 40 (1953) 220

GREITZ T and GREPE A Mimer II and rotating chair Application in neuroradiology Elema Schonander Stockholm 1967

— and HINDMARSH T Computer assisted tomography of intracranial CSF circulation using a water soluble contrast medium Acta radiol Diagnosis 15 (1974) 497

— CORRALES M and MÖLLER A Stereotaxic methods in the investigation of experimentally produced intracranial displacements Acta radiol Diagnosis 12 (1972) 776

GREPE A (a) Anatomy of the cranial nerves in the basal cisterns A radiologic post mortem investigation Acta radiol Diagnosis 16 (1975) 17

— (b) Cisternography with the non ionic water soluble contrast medium metrizamide A preliminary report Acta radiol Diagnosis 16 (1975) 146

— and GREITZ T C A T investigation of the subarachnoid space *In* The first European seminar on computerised axial tomography in clinical practice Edited by G H du Boulay and I F Moseley Springer Verlag Berlin Heidelberg 1977

— — and NORÉN G Computer cisternography of extracerebral tumours using lumbar injection of water soluble contrast medium *Acta radiol (1975) Suppl No 346 p 51*

HAMMER B and SCHERRER H Pneumoencephalographic radio anatomical variants in the posterior cranial fossa Neuroradiology 5 (1973) 107

HILAL S K TOOKOIAN H and WOOD E H Displacement of the aqueduct of Sylvius by posterior fossa tumours Acta radiol Diagnosis 9 (1969) 167

HUANG Y P WOLF B S and OKUDERA T *Angiographic anatomy of the inferior vermian* vein of the cerebellum Acta radiol Diagnosis 9 (1969) 327

KRAUSOVA L und JIROUT J Das pneumographische Bild der subtentorialen Arachnoidalräume im normalen Zustand und bei raumfordernden Prozessen Fortschr Röntgenstr 98 (1963) 733

LEKSELL L A stereotaxic apparatus for intracerebral surgery Acta chir scand 99 (1949) 229

— A note on the treatment of acoustic tumours Acta chir scand 137 (1971) 763

LILIEQUIST B (a) The subarachnoid cisterns An anatomic and roentgenologic study Acta radiol (1959) Suppl No 185

— (b) Pontine angle tumour Acta radiol (1959) Suppl No 186

— Lumbar encephalography in pontine and intracerebellar tumours Acta radiol Diagnosis 1 (1963) 593

LINDGREN E Some aspects on the technique of encephalography Acta radiol 31 (1949) 161

— Encephalographic examination of tumours in the posterior fossa Acta radiol 34 (1950) 331

LINDQVIST M and MÖLLER A Postmortem radiography of the subarachnoid cisterns Acta radiol Diagnosis 19 (1978) 1

LYSHOLM E Ventriculography of the fourth ventricle Amer J Roentgenol 41 (1939) 18

— Experiences in ventriculography of tumours below the tentorium Brit J Radiol 19 (1946) 437

McRAE D L and ELLIOTT A W Radiological aspects of cerebellar astrocytomas and medulloblastomas Acta radiol 50 (1958) 52

MÖLLER A Pneumography in paraventricular and intraventricular tumours of the posterior fossa Acta radiol (1974) Suppl No 342

PRIBRAM H F W *The differentiation of extrinsic from intrinsic intracranial tumors with* particular reference to posterior fossa tumors Amer J Roentgenol 98 (1966) 452

ROBERSON G H BRISMAR J DAVIS K R TAVERAS J M and WEISS A Metrizamide cisternography with hypocycloidal tomography Preliminary results Amer J Roentgenol 127 (1976) 965

ROBERTSON E G *Encephalography Macmillan Melbourne 1941*

— Pneumoencephalography Blackwell Scientific Publications Oxford 1957

ROTH M KORBICKA J and TOMAN I Cisternal dilatation in infratentorial tumours Experimental reproduction of the probable pathogenetic mechanism in the cadaver Acta radiol Diagnosis 13 (1972) 467

RUGGIERO G Diagnostic value of encephalographic examination of the subarachnoid space Acta radiol 46 (1956) 99

— L Encéphalographie fractionnée Masson et Cie Paris 1957

SCHECHTER M M BULL J W D and CAREY P Two new encephalographic signs of pressure hydrocephalus Brit J Radiol 31 (1958) 318

THIEBAUT F WACKENHEIM A et VROUSOS C Radioanatomie normale des citernes du tronc cerébral superieur en pneumostratigraphie horizontale J Radiol Électrol 44 (1963) 465

TWINING E Radiology of the third and fourth ventricles Brit J Radiol 12 (1939) 385 569

WACKENHEIM A et ESCUDERO L Neuroradiologie Encéphalographie gazeuse fractionée normale et pathologique Doin Paris 1969

VALENTINO V Some experiences with tomography in neuroradiology Acta radiol 45 (1956) 101

PATELLA ALTA AND GONARTHROSIS

S AHLBACK and S MATTSSON

The sesamoid bone patella may have different positions in the quadriceps tendon When it is located unusually high it is called patella alta ever since this term was introduced by SCHULTHESS (1899)

Patella alta is known to be a predisposing factor in recurrent dislocation of the patella the bone mostly slipping laterally beyond the lateral femoral condyle Also with no history of dislocation symptoms may appear from a high located patella such as aching and tiredness in the knee after walking or standing feeling of instability catching of the patella and recurrent effusion (BRATTSTRÖM 1970)

In a series of gonarthrosis particularly of the patellar type the frequency of patella alta was examined Gonarthrosis was defined and classified according to AHLBACK (1968) and patella alta by the method of INSALL & SALVATI (1971)

Method

Different methods have been proposed for determining the position of the patella in relation to the femoral condyles BOON ITT (1930) seems to be the first to have published a measuring method though according to INSALL & SALVATI too complicated for practial use

BLUMENSAAT (1938) considered patella alta to be present when the apex of the patella was located above the extension of a line along the bottom of the intercondylar fossa (B in Fig 1) This method demands that the knee be held in 30 flexion a fact that limits the usefulness of the method INSALL & SALVATI found it inaccurate as in 44 films of normal knees flexed exactly 30 they found no case in which the

Submitted for publication 7 July 1977

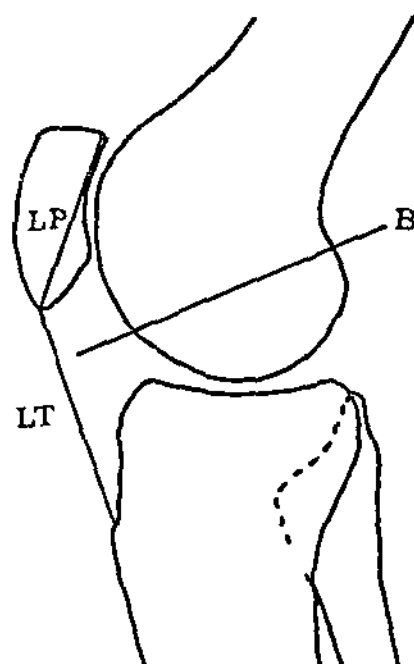


Fig 1 Measured lengths of patellar ligament (LT) and patella (LP) with the method of INSALL & SALVATI BLUMENSAAT s line (B)

lower pole of the patella lay on BLUMENSAAT s line rather the patella was positioned above this line

INSALL & SALVATI described another method relating the length of the patellar ligament to the length of the patella (Fig 1) The ligament (LT) is measured on its posterior surface from its origin at the apex of the patella to its insertion into the tibial tuberosity This is usually represented by a clearly defined notch which may be used as a point of reference if the ligament is not adequately seen This is not infrequently met with as the insertion is often spread over quite a distance The length of the patella (LP) is measured from its apex to its superior posterior edge

The length of the ligament is somewhat depending upon whether the film is taken with taut or slackened ligament (Fig 2) In order to avoid this error the film should be exposed with the quadriceps muscle contracted The method can be applied on films exposed at varying degrees of flexion and is independent of such factors as the degree of magnification small errors of projection and the size of the knee

INSALL & SALVATI concluded that normally the patellar ligament is equal in length to the patella making the ratio LT/LP = 1 The length of the ligament should *not* surpass that of the patella by more than 20 per cent (LT/LP = 1 2) In the material of INSALL & SALVATI 98 per cent of the normal cases were lying between 0 8 and 1 2

Osteoarthrosis was defined as cartilage destruction appearing as narrowing of the articular space For evaluation of the femoro-tibial articulation films in weight bearing position were used The femoro patellar joint was examined in the axial projection with the knee in semi flexed position



Fig 2 Distance between tibial tuberosity and apex of patella shorter with slackened than with taut ligament

Material

The material of gonarthrosis was that previously published by AHLBÄCK enlarged with a later consecutive series

It consisted of 376 knees (Fig 3) comprising 197 knees with isolated patellar osteoarthrosis 53 knees with combined patellar and medial osteoarthrosis and 10 knees with combined patellar and lateral osteoarthrosis As a control group 116 knees with medial but without patellar osteoarthrosis were included

The sex distribution was determined by using 91 normal knees and 56 cases of patella alta without gonarthrosis The distribution of age and sex was also determined in an arthrography material of 103 knees with meniscus lesions

Finally 30 knees with dislocations of the patella were examined with regard to the presence of patella alta This group includes acute and traumatic as well as recurrent luxation of the patella

Results

In knees with patellar osteoarthrosis patella alta occurred in 89 of 260 knees (34 Table 1 Fig 4) The frequency of patella alta in the total material of patellar osteoarthrosis equals that in the largest subset (P in Fig 3) Subset MP had a somewhat lower frequency whereas patella alta existed in 60 per cent of knees with combined patellar and lateral osteoarthrosis (subset LP) In the normal material of INSALL & SALVATI only 5 out of 114 knees (4 %) had a ratio higher than 1 2 In the present group of medial osteoarthrosis with normal femoro-patellar joint the corresponding number was 7 out of 116 knees (6 %) The frequency of patella alta was thus about six times higher in knees with patellar osteoarthrosis than in those with normal articular cartilage thickness at the femoro-patellar joint

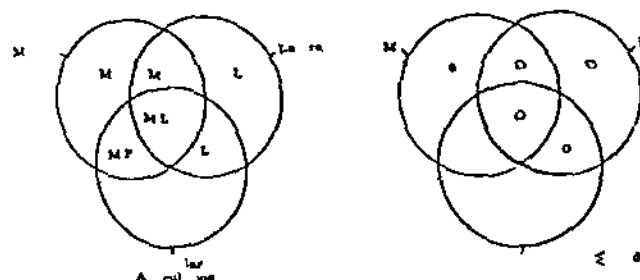


Fig 3 Venn diagram of 260 knees with patellar osteoarthrosis Subsets are isolated patellar (P) combined medial and patellar (MP) and combined lateral and patellar (LP) types 116 knees with pure medial osteoarthrosis (M)

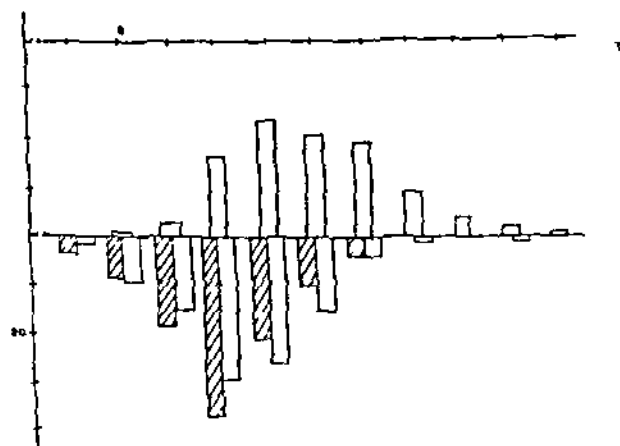


Fig 4 Relative frequencies of LT/LP ratios in 260 knees with patellar osteoarthrosis (above) compared to (below) 114 normal knees (from INSALL & SALVATI hatched bars) and 116 knees with pure medial osteoarthrosis (unfilled bars)

Age and sex INSALL & SALVATI did not report the age and sex distribution of their arthrography material but experiences from other arthrography materials suggest a male preponderance and a relatively low age

In the present survey of 103 knees in which arthrography had demonstrated a torn meniscus (i e the similar type of material as used by INSALL & SALVATI) 86 patients were men and only 24 (20 men and 4 women) were over 50 years of age

Gonarthrosis on the other hand is mainly found in women above the age of 50 (AHLBACK) As meniscus lesions mostly occur in men below 50 the materials are quite different regarding the distribution of age and sex In the present material of patellar osteoarthrosis females greatly outnumbered males (Table 2)

In knees without osteoarthrosis patella alta was found twice as often in women as in men A female dominance was observed in the group with ratios between 1 0 and 1 2 while there were more males than females in the group with a ratio of 1 0 or less

Patella alta and dislocation of the patella In the group of 30 knees with dislocation of the patella patella alta was found in 13 (43 %) The highest LT/LP ratio of the whole material (1 9) was observed in a woman with habitual dislocation of the patella

Table 1

Ratio LT/LP in 114 normal knees (from INSALL & SALVATI) *116 knees with medial but not patellar osteoarthrosis and in 260 knees with patellar osteoarthrosis*

	Ratio LT/LP			Patella alta (per cent)
	<1 0	>1 0 1 2	>1 2	
Knees without patellar osteoarthrosis				
Normal	74	35	5	4
Medial osteoarthrosis	62	47	7	6
Total	136	82	12	5 2
Knees with patellar osteoarthrosis				
Subset P	34	96	67	34
Subset MP	19	18	16	30
Subset LP	1	3	6	60
Total	54	117	89	34

Table 2

Sex distribution related to ratio LT/LP in 147 knees without and in 153 with patellar osteoarthrosis

	Ratio LT/LP			Patella alta (per cent)
	<1 0	>1 0<1 2	>1 2	
Knees without patellar osteoarthrosis				
Female	27	30	21	
Male	37	22	10	
Ratio female male	0 7	1 4	2 1	
Knees with patellar osteoarthrosis				
Female	22	63	49	37
Male	4	9	6	32
Ratio female male	5 5	7 0	8 2	

Discussion

In the literature no report has been found on the relationship between patella alta and gonarthrosis The present investigation was initiated by the observation of some knees where patella alta coexisted with osteoarthrosis of the patellar type As it seemed reasonable that a high located patella could predispose to patellar osteoarthrosis the frequency of patella alta was determined in different categories of knees with and without osteoarthrosis

Patella alta was defined using the method of INSALL & SALVATI On a lateral film the lengths of the patellar ligament and of the patella were measured and the ratio between them calculated If this ratio is 1 2 or more patella alta is present

In the normal material of INSALL & SALVATI patella alta was found in only 4 p r cent In the present control group of knees with medial osteoarthrosis but with a normal femoro patellar joint patella alta was found in 6 per cent

In knees with patellar osteoarthrosis patella alta was found in 34 per cent (Table 1) In the knees with combined lateral and patellar osteoarthrosis an exceptionally high frequency of patella alta was present (6 of 10) This combination (subset LP) is comparatively rare as only 10 of 260 knees with patellar osteoarthrosis belonged to this subset In patellar dislocation with patella slipping laterally over the lateral femoral condyle an injury will often be afflicted upon the cartilage of the condyle and osteoarthrosis at the lateral femoro tibial articulation may develop secondarily to the dislocation Such a mechanism has been shown by SCHELLEI & MÅRTENSSON (1974) to follow traumatic luxations At the same time a lesion to the cartilage of the patella is likely to occur and a patellar type of osteoarthrosis to develop This might explain the high incidence of patella alta in subset LP since patella alta is a predisposing factor in patellar dislocation

A massive female dominance is found in gonarhtrosis In knees without osteoarthrosis (Table 2) the female/male ratio approximately equals 1 if the 2 groups with ratios LT/LP 1 0 and LT/LP > 1 0 1 2 (i e knees without patella alta) are con sidered as one entity However knees without osteoarthrosis were twic as frequent in women as in men with patella alta In fact there is a steady increase of the female/ male ratio with increasing LT/LP ratio This trend is still more conspicuous in the knees with patellar osteoarthrosis where patella alta is more than eight times as frequent in women than in men Thus patella alta is more common in women especially in connection with patellar osteoarthrosis which in itself has a high female dominance On the other hand the frequency of patella alta in women with patellar osteoarthrosis (37°) only slightly exceeds that in men (32)

The finding that patella alta is about six times as frequent in knees with pat llar osteoarthrosis as in those without (Table 1) indicates that patella alta is a pathogenetic factor in patellar osteoarthrosis No evidence exists that the patellar ligament should lengthen second inly to osteoarthrosis instead the ratio LT/LP remains unchanged and does not increase with progressing osteoarthrosis However it is evident that patella alta is not present in all knees with patellar osteoarthrosis in two thirds the ratio is normal Thus other factors must also exist and a multi factorial etiology to patellar osteoarthrosis will have to be considered

In 41 patients with patella alta the other knee was examined as well These patients were divided into two groups those with normal femoro-patellar joint space and those with patellar osteoarthrosis In the first group a bilateral patella alta was found in 15 of 18 patients while it was unilateral in 3 In the second group consisting of 23 patients 14 had bilateral patella alta while 9 had a normal ratio in one of the knees In other words patella alta is often but not always bilateral

SUMMARY

The frequency of patella alta as defined by the method of INSALL & SALVATI in knees with femoro-patellar osteoarthrosis was determined Patella alta was six times as frequent in knees with osteoarthrosis than in those with a normal femoro-patellar joint Patella alta is more common in women and is often bilateral

ZUSAMMENFASSUNG

Die Haufigkeit einer Patella alta entsprechend der Methode von INSALL & SALVATI definiert wurde bei Knien mit Osteoarthrosis des Femoro Patellar Gelenks festgestellt Die Patella alta war sechs mal haufiger in Knien mit Osteoarthrosis als in denen mit einem normalen Femoro Patellar Gelenk Patella alta ist gewohnlicher bei Frauen und ist oft bilateral

RESUME

Les auteurs ont étudié la frequence de la patella alta telle qu elle est definie par la methode de INSALL & SALVATI sur des genoux atteints d osteoarthrose fémoro patellaire La patella alta a éte six fois plus frequente sur les genoux atteints d ostéoarthrose que sur les genoux ayant une articulation femoro patellaire normale La patella alta est plus fréquente chez les femmes et est souvent bilaterale

REFERENCES

AHLBACK S Osteoarthrosis of the knee Acta radiol (1968) Suppl No 277

BLUMENSAAT C Die Lageabweichungen und Verrankungen der Kniescheibe Ergebn Chir Orthop 31 (1938) 149

BOON ITT S B The normal position of the patella Amer J Roentgenol 24 (1930) 389

BRATTSTRÖM H Shape of the intercondylar groove normally and in recurrent dislocation of patella A clinical and X ray anatomical investigation Acta orthop scand (1964) Suppl No 68

— Patella alta in non-dislocating knee joints Acta orthop scand 41 (1970) 578

HUGHSTON J C Subluxation of the patella J Bone Jt Surg 50-A (1968) 1003

INSALL J and SALVATI E Patella position in the normal knee joint Radiology 101 (1971) 101

SCHELLER S and MÅRTENSSON L Traumatic dislocation of the patella A radiographic investigation Acta radiol (1974) Suppl No 336

SCHULTHESS W Zur Pathologie und Therapie des spastischen Gliederstarres Z Orthop Chir 6 (1899) 1

WIBERG G Roentgenographic and anatomic studies on the femoropatellar joint with special reference to chondromalacia patellae Acta orthop scand 12 (1941) 319

FROM THE DEPARTMENT OF DIAGNOSTIC RADIOLOGY, AALBORG SYGEHUS AFSNIT SYD, DK 9000 AALBORG DENMARK

ARTHROGRAPHY OF THE ANKLE

Value in diagnosis of rupture of the lateral ligaments

E LINDHOLMER N FOGED and J TH JENSEN

The present report constitutes an assessment of the value of arthrography of the ankle in the diagnosis of recent ruptures of the anterior talofibular ligament and the calcaneofibular ligament especially with reference to the differential diagnosis of isolated rupture of the talofibular ligament and combined ruptures of these ligaments

Arthrography was introduced by WOLFF (1940) and by HANSSON (1941) for the diagnosis of injuries around the talocrural joint Subsequently arthrography of the ankle was recommended as an accurate and safe method for the diagnosis of ruptures of the lateral ligaments of the ankle joint (LINDBLOM 1952 ARNER et coll 1957 GLASTRUP 1965 BROSTROM et coll 1965 HAAGE 1967 OLSON 1969 PERCY et coll 1969 GORDON 1970 HAAGE & FISCHEDICK 1973) In 1965 BROSTROM et coll gave a detailed description of the arthographic appearances of the various types of rupture based upon 105 cases of arthrography of the ankle subsequently explored surgically They stated that filling of the peroneal sheath was a reliable indication of rupture of the calcaneofibular ligament This statement was confirmed by GORDON FONDYCE & HORN (1972) and PERCY et coll (1969) although STAPLES (1975) considered it a less reliable indication On the other hand other arthrographic indications of

Submitted for publication 31 March 1977




Fig 1 Rupture of the *anterior tibiofibular* ligament a) Oblique a p projection Interosseous spread of contrast medium b) Lateral projection Contrast medium posterior to the distal anterior surface of the tibia *to such an extent* that contrast medium must have spread into the ligament Operation revealed partial rupture

rupture of the calcaneofibular ligament were reported by PERCY et coll CALLAGHAN *et coll* (1970) STAPLES and others These discrepancies prompted us to perform the investigation now reported

Material During the 4-year period from 1 January 1970 to 31 December 1973 arthrography of the ankle was performed in 338 patients with clinically suggested rupture of the lateral ligaments Swelling with or without distinct tenderness over the anterior talofibular ligament or calcaneofibular ligament In 223 cases abnormalities indicating rupture of the joint capsule and ligaments were encountered Surgical measures were omitted in cases which according to the clinical and arthrographic examination had a less severe lesion and only 117 patients were operated upon Seven cases were excluded due to incomplete examination lost films or incomplete exploration Five cases with a typical isolated rupture of the anterior tibiofibular ligament (Fig 1) were excluded from the analysis of the anterior talofibular and calcaneofibular ligament ruptures Thus 105 cases remained in which arthrography was performed within 24 hours of the injury 34 women and 71 men aged between 12 and 60 years Of the patients 77 per cent were between 15 and 30 years of ag

Table 1

Value of various arthrographic signs of rupture of the calcaneofibular ligament as assessed at operation in 105 cases The value of the individual signs is expressed by the number of false positives and negatives and by the diagnostic percentages PV_{pos} PV_{neg} and sensitivity The two last columns give the χ^2 and p values of the statistical analysis

Diagnostic criteria		No false pos	No false neg	Per cent PV_{pos}	Per cent PV_{neg}	Per cent sensitivity	χ^2	p <
A	Type III	8	24	82	60	61	17	0.001
B	Peroneal sheath filling	13	30	70	51	51	3.9	0.05
C	Lateral contrast	17	15	73	64	75	13	0.001
D	Posterolateral contrast	7	35	79	51	43	7.3	0.01
E	Contrast extension index >20 cm²	15	25	71	54	59	5.4	0.05
F	*Poor joint filling*	6	43	75	47	30	2.8	*0.1*
Combined criteria								
G	C and E	9	28	79	55	54	11	0.001
H	B and C	8	32	78	53	48	8.4	0.01
K	C and F	3	43	86	49	30	6.9	0.01
L	B and F	1	48	93	47	21	6.5	0.02

Methods

The technique of arthrography of the ankle has been described in detail by Broström et coll and Percy et coll After aspiration of blood and intraarticular exudate 5 to 10 ml of meglumine iothalamate (Conray meglumin 282 usually 6 to 7 ml) was injected into the joint Four projections were used anteroposterior lateral and two oblique (a p projections with 40 internal and external rotation of the foot respectively the former being the most important projection) The films were evaluated retrospectively without knowledge of the surgical diagnoses

Diagnostic criteria The spread of the contrast medium was divided into three types by Percy et coll

I Isolated rupture of the capsule contrast medium anterior to the distal tibia only

II Anterior talofibular and capsule ruptures contrast medium anterior and lateral to the lateral malleolus mainly anteriorly

III Combined ruptures of anterior talofibular and calcaneofibular ligaments (Table 1) contrast medium anterior and lateral to the lateral malleolus mainly laterally often around the tip of the lateral malleolus and sometimes with characteristic spread upwards along the lateral aspect of the fibula

The films were also evaluated according to a new principle taking into particular

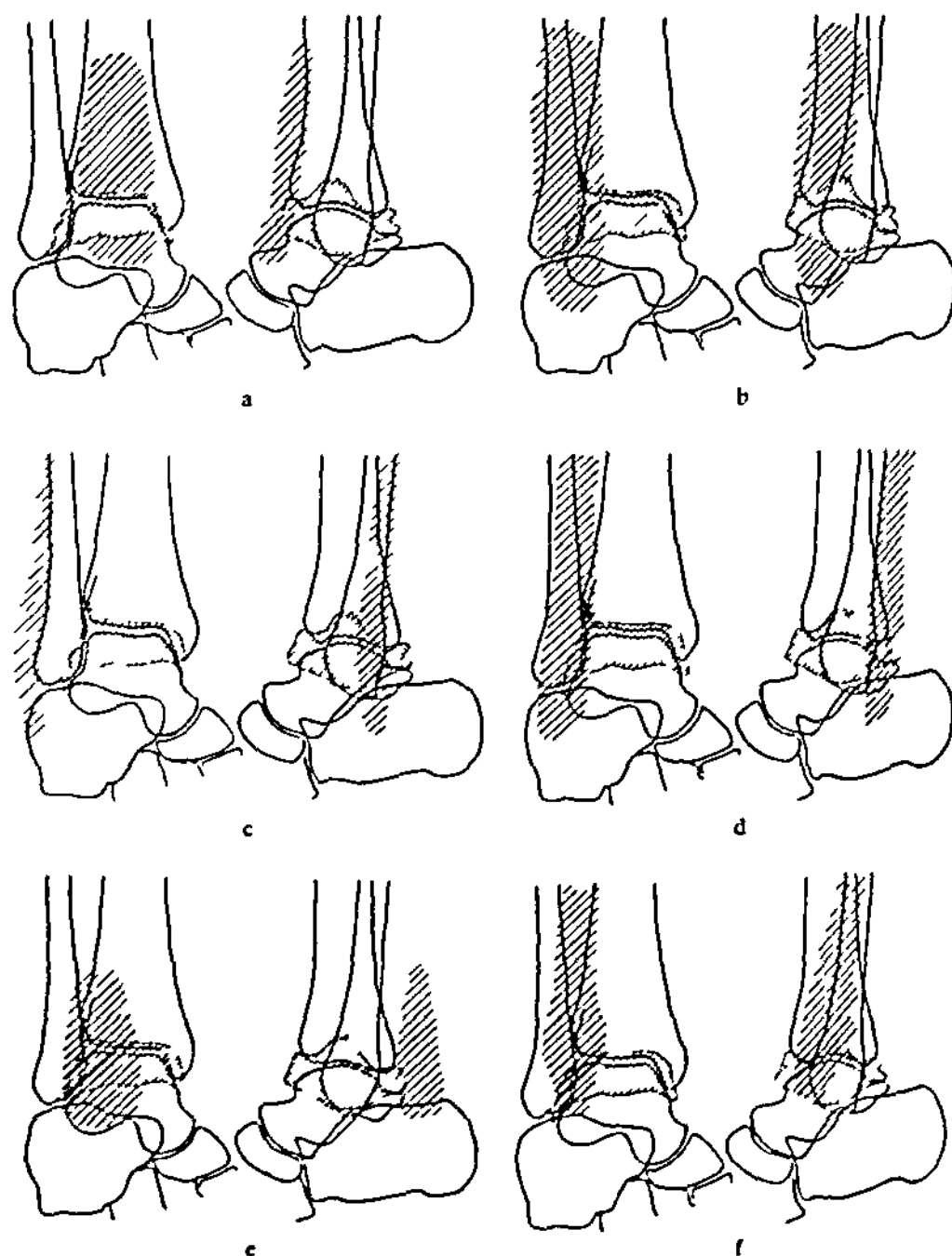


Fig 2 Spread of contrast medium around the lateral malleolus when lateral ligaments of the ankle are ruptured a) Anterior b) Anterolateral c) Lateral d) Posterolateral e) Posterior f) Following rupture of the anterior tibiofibular ligament contrast medium spreads in the interosseous space with blurring of the recess but not anterior to the tibia [ ] Extraarticular contrast medium [ ] Intraarticular contrast medium



Fig 3 Isolated rupture of the anterior talofibular ligament (PERCY type II) Contrast medium anterior and anterolateral to the lateral malleolus but no medium laterally i e spread of contrast medium posterior to the middle of the lateral malleolus is not visible in the lateral projection No filling of the peroneal sheath Talar tilt Operation revealed complete isolated rupture of the anterior talofibular ligament

consideration the posterolateral border of the extraarticular contrast medium The definition is as follow (Fig 2)

Anterior Anterior to the distal tibia (Fig 2 a)

Anterolateral Anterior to the lateral malleolus assessed on the internally rotated oblique view (Fig 2 b)

Lateral Posterior to the middle of the lateral malleolus in the lateral projection (Fig 2 c)

Posterolateral Posterior to the posterior margin of the lateral malleolus in the lateral projection (Fig 2 d)

Posterior Considerable spread of contrast medium posteriorly visible in all projections (Fig 2 e)

Peroneal sheath filling Usually visible only as a narrow vertical deposit below the tip of the lateral malleolus in a p projection (Fig 4 a)

Contrast spread index Maximum vertical spread of contrast medium multiplied by maximum horizontal spread in cm Index in cm

Filling of the talocrural joint Good or poor in particular considering the recess filling

Extraarticular extension of contrast medium at the tip of the lateral malleolus Total extension from the tip of the lateral malleolus downwards and laterally from the tip at an angle of 45 to the fibular axis

Filling of the talocalcaneal joints

Defects in extraarticular contrast medium possibly clots

Talar tilt with widening of the joint space laterally

Blurred or distinct demarcation of the extraarticular contrast medium

Comments on criteria The PERCY types are in particular based on the total spread of the extraarticular contrast medium and an estimation of its centre The new criteria defined by the present authors are based on an estimation of the posterolateral border of the extraarticular contrast medium

At arthrography of the ankle within a few days of rupture of the anterior talofibular ligament the contrast medium has a blurred flame shaped appearance anterior




Fig. 4. Combined rupture of the anterior talofibular and calcaneofibular ligaments (PERCY type III). a) A.p. projection. Contrast medium around the tip of the lateral malleolus extending proximally along the lateral aspect of the lateral malleolus. Distinct filling of peroneal sheath. b) Oblique a.p. projection with internal rotation. Contrast medium visible lateral to the lateral malleolus. c) Lateral projection. Contrast medium covering most of the lateral malleolus. d) Lateral projection, soft tissue view. Spread of medium posterior to lateral malleolus. Operation revealed complete rupture of both ligaments.

to the lateral malleolus (PERCY et coll.). After one week the amount of the extraarticular contrast medium has diminished and is also better outlined, and after some months only small well defined recesses remain (ARNER et coll., BROSTRÖM et coll.).

A PERCY type II with anterolateral localization of the medium but no spread posterior to the middle of the lateral malleolus on the lateral projection is illustrated in Fig. 3. Combined ruptures appear in Figs. 4 and 5, Fig. 4 having the typical appearance as described by PERCY et coll. The value of lateral contrast medium for exact localization of the ruptures is evident from Figs. 6 and 7. Assessed by the PERCY criteria, both represent type II, but the lateral spread of contrast medium indicates rupture of the calcaneofibular ligament, which was also revealed at the operation.

Statistical evaluation. The material is selected inasmuch as it consisted of patients with possible rupture of the lateral ligaments of a severity indicating surgery. The present results are therefore comparable only with those in materials selected in a similar way. There are several terms for an assessment of a diagnostic procedure (WULFF 1976). PV_{pos} = predictive value of a positive test = diagnostic specificity (the percentage of patients with pathologic arthrography, i.e. rupture of the ligaments). PV_{neg} = predictive value of a negative test = diagnostic sensitivity (percentage of patients with a normal arthrography, i.e. no rupture of the ligaments). Specificity = nosographic specificity (percentage of patients with no rupture of the ligaments, i.e. normal arthrography). Sensitivity—nosographic sensitivity (percentage of patients with rupture of the ligaments, i.e. pathologic arthrography).




Fig 5 Complete rupture of the ant talofibular ligament and partial rupture of the calcaneofibular Less *extension of contrast medium than in Fig 4 a)* b) A p projection Lateral spread of contrast medium with filling of peroneal sheath c) Lateral projection Lateral and posterolateral extension of contrast medium

As the value of suture of the isolated rupture of the anterior talofibular ligament is not universally recognized a diagnostic procedure with high specificity for rupture of the calcaneofibular ligament is required i e with so few falsely pathologic results that only a minimum of patients are subjected to an unnecessary operation There fore arthrographic criteria of a high PV_{pos} are to be desired On the other hand the criteria must not be so exclusive and the sensitivity consequently so low that too few patients with such a rupture will be subjected to operation The nosographic specificity *which in this context is of minor interest* was omitted For each diagnostic criterion χ^2 was calculated with Yate s correction

Surgical technique The operations were in all essentials performed in accordance with the method of BROSTROM et coll but with one significant exception viz that the peroneal tendon sheath was not routinely opened Under general anaesthesia and in a bloodless area a curved incision was made anterior to and below the lateral malleolus The anterior talofibular ligament the anterior aspect of the calcaneofibular ligament and the peroneal tendon sheath were dissected free and inspected The repair of ruptured ligaments was performed with 2-0 Mersilene sutures

Results

Rupture of the anterior talofibular ligament Assessed by the extension of contrast medium both according to PERCY et coll and to the new definitions all 105 cases had rupture of this ligament viz extraarticular spread of contrast medium anterior and to some extent lateral to the lateral malleolus (anterolaterally) No type I (PERCY) case and no case of only anterior spread of contrast medium were found Operation



Fig 6 a) Oblique a p and b) lateral projections Spread of contrast medium with centre at the ant tal fibular ligament considered to be PERCY type II Contrast medium posterior to the middle of the lateral malleolus in the lateral projection suggests rupture of the calcaneofibular ligament. No filling of peroneal sheath The medial recess of the talocrural joint is faintly filled filling of the posterior talocalcaneal joint Operation revealed complete rupture of the ant talofibular and partial rupture of the calcaneofibular ligament

revealed 102 cases with rupture (97 complete and 5 partial) i e 3 falsely considered as rupture One had an anterolateral and lateral distribution of contrast medium and was an unquestionable type II rupture In the second case slight anterolateral spread of medium occurred (index less than 10 cm) and the anterior part of the tendon sheath was filled This might be due to extraarticular injection of medium, but the arthrography was classified as type II In the third case substantial inter osseous distribution of contrast medium occurred indicating rupture of the tibiofibular ligament but there was also some anterolateral spread of medium PV_{pos} was thus 97 per cent PV_{neg} or sensitivity could not be calculated as only patients with pathologic arthrography underwent operation

Rupture of the calcaneofibular ligament No case of isolated rupture was found. Among the 105 cases 61 were combined ruptures of both this ligament and the anterior talofibular 48 complete and 13 partial In the statistical analysis no distinction was made between complete and partial ruptures The relationship between the arthrographic and surgical diagnoses appears in Table I The following abnormalities, which had slight or no significance for the diagnosis of rupture of



Fig 7 a) Oblique a p and b) lateral projections Slight spread of contrast medium with centre at the ant talofibular ligament considered to be PERCY type II Lateral contrast posterior to the middle of the lateral malleolus in the lateral projection suggests rupture of the calcaneofibular ligament No filling of peroneal sheath Operation revealed combined complete ruptures of the ant talofibular and calcaneofibular ligaments

the calcaneofibular ligament are not included in the table Extension of extraarticular contrast medium at the tip of the lateral malleolus filling of the talocalcaneal joints clot defects in the contrast medium and tilting of the talus The matrix arrangement of type III and the filling of the peroneal sheath are shown in Tables 2 and 3 as well as the calculation of the diagnostic percentages The type III criterion is most reliable with a PV_{pos} of 82 per cent (95 % confidence limits 68–92 %) whereas the peroneal sheath filling criterion has a PV_{pos} of 70 per cent (95 % confidence limits 55–83 %) The type III criterion is less precisely defined than the other criteria and an endeavour was therefore made to find a combination of criteria which could provide greater certainty than the individual ones The G H K and L combination criteria are such attempts (Table 1) G is positive with both lateral spread of contrast medium and a spread index of more than 20 cm H is positive with both peroneal sheath filling and lateral spread K is positive with both lateral spread and poor filling of the talocrural joint L is positive with both peroneal sheath filling and poor filling of the talocrural joint From G to L PV_{pos} increases to 93 per cent and the sensitivity decreases to 21 per cent An important factor which was observed in 2 cases is the time interval between the injection of contrast medium and the exposure of the

Table 2

Value of the type III criterion in the arthrographic diagnosis of rupture of the calcaneofibular ligament as assessed at operation in 105 cases The calculations of the diagnostic percentages PV$_{pos}$ (= predictive value of a positive test = diagnostic specificity) PV$_{neg}$ (= predictive value of a negative test = diagnostic sensitivity) and sensitivity (= nosographic sensitivity) are also shown

	Calcaneofibular ligament rupture	No calcaneofibular ligament rupture		
Type III	37	8	45	$PV_{pos} = \frac{37 \cdot 100}{45} = 82$
Not type III	24	36	60	$PV_{neg} = \frac{36 \cdot 100}{60} = 60$
	61 Sensitivity $= \frac{37 \cdot 100}{61} = 61$	44	105	

lateral projection All films were marked with time and name immediately after exposure If two lateral exposures were made at an interval of a few minutes the extraarticular contrast medium was located more posteriorly at the second exposure than at the first The extraarticular contrast medium spread after some time especially posteriorly *It is therefore necessary that the exposures are made immediately after the injection if the extension of the contrast medium is to be used as a diagnostic criterion* In addition the spread of the medium to some degree also depends on the amount of medium injected

Over the five years during which ankle arthrography has been performed in this department no complication has occurred

Discussion

The reliability of ankle arthrography differs considerably in rupture of the anterior talofibular and calcaneofibular ligaments In ruptures of the former ligament the degree of accuracy is fully acceptable with a PV_{pos} of 97 per cent The diagnostic reliability in cases with a normal arthrography is unknown because these patients are usually not operated upon However after the period covered by this investigation 2 patients with severe signs of ligament rupture were operated upon despite a normal arthrography no ligament rupture was revealed The literature attests to the same experience BROSTRÖM et coll operated upon 6 patients with normal arthrography and found 4 without ligament rupture and 2 with rupture of the anteri

Table 3

Value of criterion of peroneal tendon sheath filling in the arthrographic diagnosis of rupture of the calcaneofibular ligament as assessed at operation in 105 cases The calculations of the diagnostic percentages PV_{pos} PV_{neg} and sensitivity which are defined in the text are also shown

	Calcaneofibular ligament rupture	No calcaneofibular ligament rupture		
Peroneal sheath filling	31	13	44	$PV_{pos} = \frac{31 \cdot 100}{44} = 70$
No peroneal sheath filling	30	31	61	$PV_{neg} = \frac{31 \cdot 100}{61} = 51$
	61	44		
	Sensitivity $= \frac{31 \cdot 100}{61} = 51$			

talofibular ligament in both the latter cases arthrography had been performed several days after the injury

Among 21 patients reported by FORDYCE & HORN one had a normal arthrography but operation revealed an old ligament rupture It is therefore likely that the frequency of falsely normal arthrography in anterior talofibular ligament rupture is low

In ruptures of the calcaneofibular ligament the diagnostic reliability is less The best results are achieved with the criteria for the extension of contrast medium as PV_{pos} for PERCY type III is 82 per cent This is not significantly different from the PV_{pos} of 70 per cent for the peroneal sheath criterion The 13 filled peroneal sheaths falsely considered as indicating rupture (Table 3) cannot be explained by assuming that filling of the peroneal sheath is common since only 2 cases of such filling occurred in 106 normal arthrographies On the other hand filling of the sheaths may in some cases be explained by the assumption that partial rupture of a calcaneofibular ligament was overlooked at the operation because the tendon sheath was not opened However this may have occurred only in rare cases as a relatively larger number of partial ruptures occurred in the present series than in that of BROSTRÖM et coll (21 against 12°) A survey of the results obtained by various authors in patients with filling of the peroneal sheath is given in Table 4

Statistical analysis shows no significant difference in the PV_{pos} of the various series but there is a significant difference in the sensitivity of the filling of the peroneal sheath in the series of BROSTRÖM et coll and in the present one This cannot be explained by differences in the surgical technique but may be due to differences in the composition of the series or in the arthrographic technique

Table 4

Diagnostic value of peroneal tendon sheath filling in different investigations

	No. of operated	False positive	False negative	PV_{pos}	PV_{neg}	Specificity	Sensitivity
Broström et coll.	105	2	2	92	97	97	97
Fordyce & Horn	16	2	2	80	67	67	80
Staples							50
Present series	105	13	30	70	51	70	51

BROSTRÖM et coll. (p. 495) described 2 cases in which arthrography was repeated 1 to 7 days after the first examination and in which the peroneal sheath was not filled. At the second examination, where the ankle joint was moved more forcibly after the injection, a filling occurred. This suggests that a change in the technique with more vigorous movements of the ankle joint after injection, possibly combined with the injection of a larger amount of local anaesthetic, may improve the sensitivity of the examination. A large dose of local anaesthetic injected into the joint has the further advantage that leakage around the lateral malleolus gives better local anaesthesia. This will increase the value of stress inversion radiography of the joint as the final step in the arthrography. As an isolated measure, other methods of examination, such as examination for anterior talar instability and stress inversion examination, have greater uncertainty in the presence of rupture of the calcaneofibular ligament than arthrography and they require a local anaesthesia which may be more painful than arthrography (BROSTRÖM 1965, LINDSTRAND 1976). It must be concluded that the criteria of contrast medium extension are better than the peroneal sheath criterion and that in particular their sensitivity is higher. A filling of the peroneal sheath is a useful supplementary indication of rupture of the calcaneofibular ligament since such a filling in combination with lateral escape of contrast medium (Table 1) has a higher PV_{pos} value than each of these conditions per se. No or only little escape of medium in connection with filling of the sheath may be a sequela of a previous lesion and is thus of slight value. Absence of peroneal sheath filling does not provide sufficient evidence for the exclusion of calcaneofibular ligament rupture (PV_{neg} = 51). One disadvantage of the criteria based on the extension of the contrast medium is their dependence on the dose and on the time lag between the injection and exposure. Arthrography of the ankle is reliable in the diagnosis of rupture of the anterior talofibular ligament. If only the combined ligamentous rupture is considered as an indication for surgery, arthrography also provides good information as the PV_{pos} on strict criteria may be increased to 93 per cent at the cost of a reduction in the sensitivity to 20 per cent. At the same time the examination provides information as to whether instability of the joint is due to fresh or old ligament rupture and furthermore whether other than the lateral ligaments are ruptured, in particular the anterior tibiofibular ligament and the deltoid ligament.

SUMMARY

Arthrography was performed in 105 cases with freshly sprained ankles and signs of rupture of the anterior talofibular ligament They were subsequently operated upon The arthrographic films were examined retrospectively to assess the value of different criteria for the differential diagnosis between rupture of the anterior talofibular ligament and combined rupture of this and the calcaneofibular ligament The diagnostic value of arthrography was found to be high in isolated rupture of the anterior talofibular ligament and is acceptable in the combined ruptures

ZUSAMMENFASSUNG

Arthrographie wurde bei 105 Fallen mit frischer Knochelverrenkung und Zeichen einer Ruptur des vorderen Talo Fibular Ligaments vorgenommen Die Patienten wurden im Anschluss daran operiert Die arthrographischen Filme wurden retrospektiv uberpruft um den Wert der verschieden Kriterien fur die Differentialdiagnose zwischen einer Ruptur des vorderen Talo Fibular Ligaments und einer kombinierten Ruptur dieses und des Calcaneo-Fibular Ligaments festzustellen Der diagnostische Wert der Arthrographie war hoch bei einer isolierten Ruptur des vorderen Talo-Fibular Ligaments und ist akzeptabel bei einer kombinierten Ruptur

RESUME

Une arthrographie a ete faite dans 105 cas d entorse recente de la cheville et de signes de rupture du ligament peroneo astragalien antérieur Ces chevilles ont eté opérees par la suite Les films d arthrographie ont été examines retrospectivement pour déterminer la valeur des différents critères de diagnostic differentiel entre la rupture du ligament peronéo astragalien antérieur et l association de cette rupture et de celle du ligament peroneo calcaneen Les auteurs ont constate que la valeur diagnostique de l arthrographie est grande dans la rupture isolee du ligament peroneo astragalien antérieur et est acceptable dans les ruptures combinees

REFERENCES

ARNER O EKENGREN K HULTING B and LINDHOLM Å Arthrography of the talo-crural joint Acta chir scand 113 (1957) 253

BROSTROM L Sprained ankles III Clinical observations in recent ligament ruptures Acta chir scand 130 (1965) 560

— LILJEDAHL S O and LINDVALL N Sprained ankles II Arthrographic diagnosis of recent ligament ruptures Acta chir scand 129 (1965) 485

CALLAGHAN J E PERCY E C and HILL R O The ankle arthrogram J Canad Ass Radiol 21 (1970) 74

FORDYCE A J W and HORN C V Arthrography in recent injuries of the ligaments of the ankle J Bone Jt Surg 54 B (1972) 116

GLASTRUP H Arthrographies in acute ankle joint injuries Radiographica 12 (1965) 281

GORDON R B Arthrography of the ankle joint J Bone Jt Surg 52 A (1970) 1623

HAAGE H Die Arthrographie des Sprunggelenkes Radiologe 7 (1967) 137

— und FISCHEDICK O Arthrographie des Sprunggelenkes *In* Handbuch der Medizinischen Radiologie Band V Teil 2 p 543 Springer Berlin New York 1973

HANSSON C. J. Arthrographic studies of the ankle joint. Acta radiol. 22 (1941) 281.
LINDBLOM K. Arthrography. J Fac Radiol 3 (1952) 151.
LINDSTRAND A. Lateral lesions in sprained ankles. Thesis. Studentlitteratur, Lund 1976.
OLSON R. W. Arthrography of the ankle. Its use in the evaluation of ankle sprains. Radiology 92 (1969) 1439.
PERCY E. C., HILL R. O. and CALLAGHAN J. E. The sprained ankle. J Trauma 9 (1969) 972.
STAPLES O. S. Ruptures of the fibular collateral ligaments of the ankle. J Bone Jt Surg. 57 A (1975) 101.
WOLFF AA. Artrografi av ankelled. (In Norwegian.) Nord Med 8 (1940) 2449.
WULFF H. R. Rational diagnosis and treatment. First edition. Blackwell, Oxford 1976.

FROM THE DEPARTMENT OF RADIOLOGY LULLÅ LASARETT S 951 20 LULEÅ SWEDEN

RADIOLOGIC DETERMINATION OF ROTATIONAL INSTABILITY OF THE KNEE JOINT

HANS LEVEN

The knee joint is protected from injury by the investing muscles the joint capsule and the intra and extra articular ligaments also menisci have a protective function (SMILLIE 1973) When the knee joint is subjected to excessive trauma and the protective mechanisms are inadequate the ligaments may be over stretched and even ruptured This may lead to instability of the joint and hence render it still more vulnerable to injury It is therefore important that any injury to the knee is diagnosed and treated without delay the earlier any required surgical repair is carried out the better the chances of a successful outcome (PALMER 1957 O DONOGHUE 1950)

In the clinical examination of an injured knee joint the presence of any instability should be noted and its magnitude estimated—especially sagittal mobility between the tibia and the femur (the drawer test) and latero medial laxity Another type of laxity to which attention has been drawn by SLOCUM & LARSSON (1968) is rotational instability in which the range of the rotation of the tibia about its longitudinal axis is abnormally great The position of the axis is dependent on which part of the joint capsule and ligamentous apparatus has been injured is the medial ligament injured then the axis of rotation is displaced laterally Experiments conducted on specimens by BRANTIGAN & VOSHELL (1941) showed that in 90 degrees of flexion the intact knee joint could be rotated through an angle ranging from 6 to 24 In similar experiments SHAW & MURRAY (1974) confirmed the statement of KAPLAN (1962) that the axis of rotation normally passes through the medial part of the intercondyloid eminence

Submitted for publication 11 July 1977

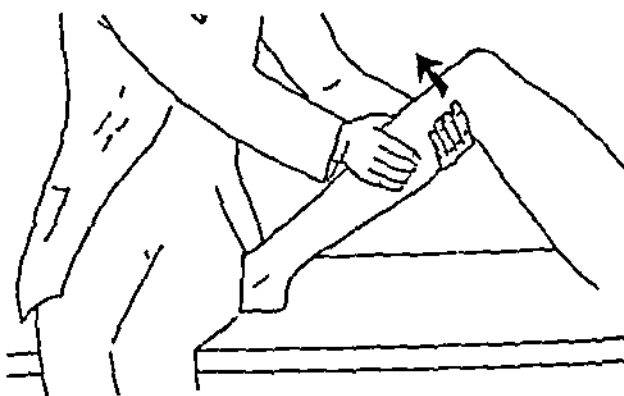


Fig. 1 Position for testing the sagittal instability of the knee joint with the foot and lower leg immobilized as described by SLOCUM & LARSSON. The drawer test is performed with inward and outward rotation of the lower leg

A clinical method for demonstrating rotational instability has been evolved by SLOCUM & LARSSON. The investigator is seated facing the patient who is in turn seated on a couch with the affected leg drawn up and the knee flexed to 90 (Fig. 1). The tibia is now pulled forward on the femur as in testing for sagittal instability with the foot and leg in two different positions inward rotation some 30 so as to tighten the lateral ligaments preventing forward displacement and outward rotation some 15 so as to relax the lateral ligaments and the anterior cruciate ligament thus permitting a forward swinging movement of the medial tibial condyle if the posteromedial capsular and ligamentous apparatus are injured. The exact position of the axis of rotation of the tibia is not known (Fig. 2). The method enables a rough evaluation of rotational instability to be made

Clinical methods for appraising the instability of the knee joint are usually very approximate the diagnosis beeing based partly on a visual impression of the laxity of the joint and partly on the magnitude of the displacement that is felt during manipulation. A clinical method for determining the sagittal instability of the knee joint to a greater degree of accuracy has been designed by SYLVIN (1975)

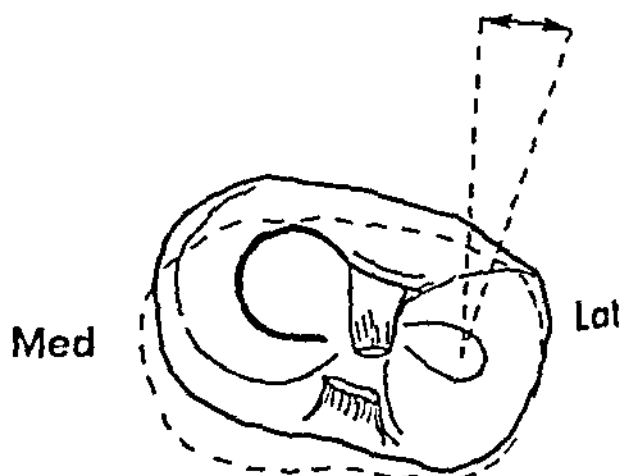


Fig. 2. The upper articular surface of the tibia the menisci and the severed cruciate ligament seen from above. There is pathologic increased mobility of the medial part of the tibia which swings forwards (after SLOCUM & LARSSON)

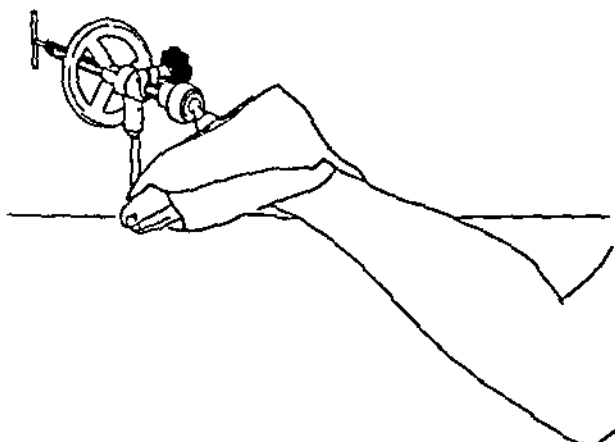


Fig 3 Device for holding the foot during rotation of the lower leg

An attempt to measure the normal and pathologic mobility of the knee joint with a clinical stress machine has been deviced by KENNEDY & FOWLER (1971) In this device the lower leg can be displaced in the dorso ventral and latero medial directions and rotated about its long axis The magnitude of the forces required to cause displacement can be graded The movements are measured by comparing lateral and a p views of the knee joint in the different positions KENNEDY & FOWLER expressed the sagittal mobility of the joint as the greatest displacement of the two tibial condyles in the sagittal plane and the rotational instability as the sagittal displacement of one tibial condyle in relation to the other the rotational movement was thus estimated by means of a kind of drawer test for each tibial condyle separately No mention was made of any reference points defining the distances measured Presumably the displacement of the posterior contours of the two tibial condyles was measured However in the case of rotational movement of the tibia it is not the same part that forms the contour on the film at the end as at the beginning of the movement This discrepancy incurs an error that makes it difficult to assess what is being measured A similar technique has been applied by JACOBSEN (1977)

Unfortunately no report has appeared describing a practicable objective and reproducible method for determining the rotational instability of the injured knee joint and for comparing the magnitude of such laxity before and after an operation

A method evolved by LEVÉN (1977) for measuring the sagittal mobility of the knee joint utilizes a system of reference points on the femur and tibia On the basis of this method a procedure has been developed for determining the rotational mobility

Method

The method for measuring the rotational instability of the knee joint involves the use of three reference points one each on the femur the tibia and the fibula The rotation of the tibia in relation to the femur is assumed to occur about an axis that

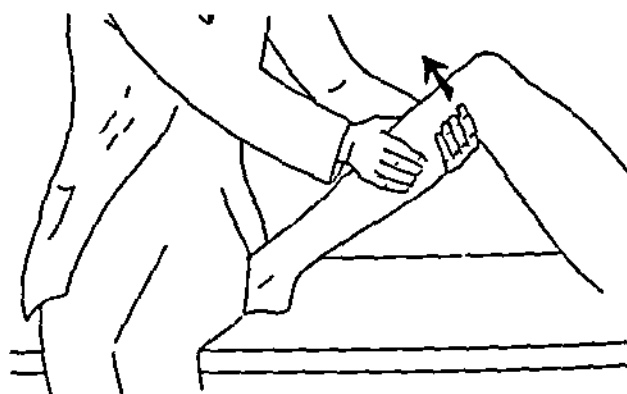


Fig 1 Position for testing the sagittal instability of the knee joint with the foot and lower leg immobilized as described by SLOCUM & LARSSON The drawer test is performed with inward and outward rotation of the lower leg

A clinical method for demonstrating rotational instability has been evolved by SLOCUM & LARSSON The investigator is seated facing the patient who is in turn seated on a couch with the affected leg drawn up and the knee flexed to 90 (Fig 1) The tibia is now pulled forward on the femur as in testing for sagittal instability with the foot and leg in two different positions inward rotation some 30 so as to tighten the lateral ligaments preventing forward displacement and outward rotation some 15 so as to relax the lateral ligaments and the anterior cruciate ligament thus permitting a forward swinging movement of the medial tibial condyle if the posteromedial capsular and ligamentous apparatus are injured The exact position of the axis of rotation of the tibia is not known (Fig 2) The method enables a rough evaluation of rotational instability to be made

Clinical methods for appraising the instability of the knee joint are usually very approximate the diagnosis beeing based partly on a visual impression of the laxity of the joint and partly on the magnitude of the displacement that is felt during manipulation A clinical method for determining the sagittal instability of the knee joint to a greater degree of accuracy has been designed by SYLVIN (1975)

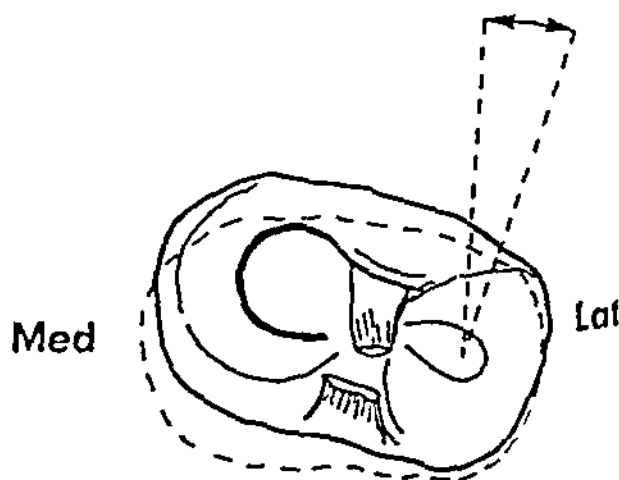


Fig 2 The upper articular surface of the tibia the menisci and the severed cruciate ligament seen from above There is pathologic increased mobility of the medial part of the tibia which swings forwards (after SLOCUM & LARSSON)

Moreover in the absence of any sagittal movement the position of the point in relation to the tibia is relatively constant even for different angles of flexion of the knee joint (LEVEN)

The tibial reference point (E) is taken as the highest point on the medial inter condylar eminence and the fibular reference point (F) as the highest point on the head of the fibula (Fig 4)

A line drawn parallel to the upper articular surface of the tibia is taken to represent a plane parallel to the rays and it is on this plane that the rotation is reconstructed The three reference points in each of the two films define three rays one passing through each of the corresponding anatomic structures The projections of these three rays on the construction plane are represented by the feet of the perpendiculars from the three points on to the line parallel to the upper articular surface of the tibia The construction plane may be regarded as fixed in relation to the femur i e the femur is considered to be incapable of rotation about the axis of rotational instability of the tibia The construction plane is represented diagrammatically on a separate sheet of paper The path of the rays in the plane is now constructed by drawing three parallel lines separated by a distance corresponding to that between the three rays on one of the films (Fig 4) The lines through the tibial and the fibular reference points are denoted by E_1 and F_1 In the same diagram the rays from the second film are drawn (E and F_2) the ray through the femoral reference point is coincident with the ray in the first film and is thus regarded as fixed in relation to the femur The rays are represented as parallel lines the error so incurred being small compared with other errors and thus negligible since in this case the divergence of the rays is small

On an a p film of the knee joint the tibial (E) and the fibular (F) reference points are marked (Fig 4) and a line corresponding to the construction plane is drawn From the reference points perpendiculars to this line are drawn to represent a parallel projection on the construction plane of the rays in a p projection Separated by the distance between the perpendiculars two lines are drawn in the diagram at right angles to the previous system of lines to represent the two rays in a p projection (E_0 and F_0) The a p film is now regarded as a perpendicular projection of the knee with the tibia in its midway position between the two extreme positions of the rotation The extreme positions of the tibial and fibular reference points in relation to the femoral reference point can therefore be reconstructed as shown in Fig 5 thus giving a centre of rotation (R) This reconstruction incurs an error because the loci of the points during the rotation are represented by straight lines instead of arcs or circles However because of the moderate angle of rotation this error is negligible The motion of the tibia in relation to the point R (Fig 5) might deviate from the true motion since it is reconstructed only with the aid of two lateral and one a p films The displacement of the tibia in the latero medial direction in relation to the femoral reference point is not known and the true centre of rotation then need not coincide with the constructed point R That the locus of the centre of rotation must

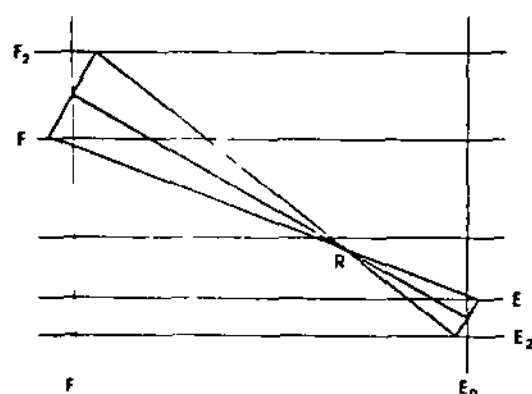


Fig 5

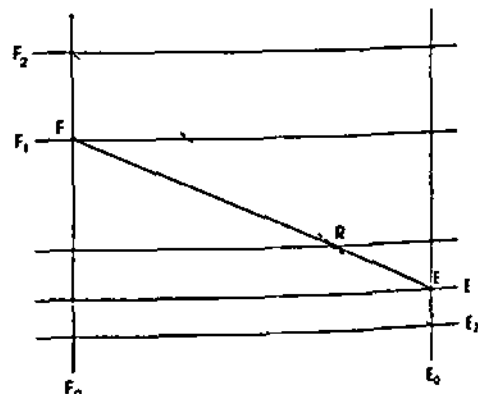


Fig 6

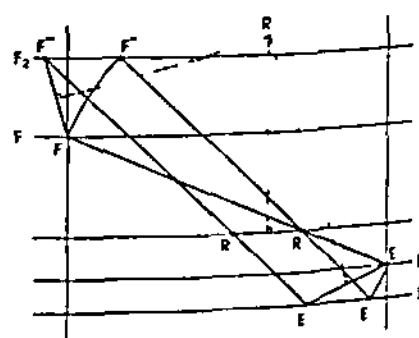


Fig 7

Fig 5 Reconstruction of the position of the tibial and fibular reference points in relation to the plane through the femoral reference point

Fig 6 Determination of the point R

Fig 7 A rotation about R together with a translation may be represented as a rotation about the point R

lie on a more or less sagittal line passing through the constructed point is evident from the following geometric reasoning

The construction plane is presented again in Fig 6 Suppose one a p film is exposed with the tibia rotated to one extreme position On this film the rays E_0 and F_0 define the positions of E and F on E_1 and F_1 Let these positions be denoted by E and F respectively The positions of E and F in the other extreme position on the lines E_2 and F_2 are known When the line joining the reference points E and F is rotated some points in it are displaced dorsally and some ventrally but one point in the line that does not move sagittally and its lateral projection ray must therefore be unchanged Let this point be denoted by R its position is located as follows Since the sagittal displacement of the distance of a point on the line EF is directly proportional to the distance of the point from R the lines EF and FR bear the same relationship to each other as the sagittal displacement of E and F Thus

$$\frac{R-E}{F'-R}=\frac{E_1-E_2}{F_1-F'}$$

R is found if the points of intersection for the lines F_0 and F are joined as well as for the lines E_0 and E_2 By the theorems on similar triangles R lies on the point where this line intersects the line between F and E

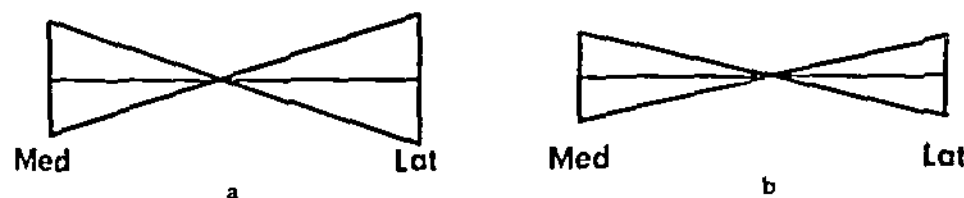


Fig 8 Instability of both knee joints (perceived subjectively) in a football and ice hockey player Sagittal mobility of a) right knee 12 mm and b) of left knee 10 mm At operation total rupture of the anterior cruciate ligament of the right knee was found

Suppose that the centre of rotation is located at R The reference points then move from positions E and F to E and F respectively (Fig 7) Suppose now that the rotation occurs about a centre R_t which is not coincident with R and that the rotation produces a displacement of R to R Since R has not moved sagittally R lies on the same lateral ray as R in accordance with the conditions governing the position of R The centre of rotation then lies on the perpendicular from the midpoint of the line RR The distances between R and the fibular and tibial reference points respectively being constant the displacement of R to R implies a translation of the line E –F to the position E –F The centres of rotation R_t will then lie on the perpendiculars from the midpoints of the lines E –E F –F and R–R The displacement may be considered either as a single rotation about R_t or as a rotation about R with a subsequent translation

Table 1

Results of determination

	Stable knee joints			Unstable knee joints		
	Mobility of medial tibial border (mm)	Rotation (degrees)	Mobility of lateral tibial border (mm)	Mobility of medial tibial border (mm)	Rotation (degrees)	Mobility of lateral tibial border (mm)
	20	21	20	20	26	18
	10	15	14	29	35	25
	23	29	24	29	33	26
	15	19	15	25	37	27
	18	24	19	26	37	26
	12	17	12	30	37	28
	15	24	21	32	37	26
	25	27	25	34	38	35
	11	15	10	17	21	16
	7	10	8	30	32	27
	10	11	8			
	30	32	27			
Mean	16	0	17	27	33	25

Table 2

Reproducibility of the technique. Repetitive determination of tibial rotation

Test 1	Test 2
26	26
35	35
21	21
15	15
29	31
19	19
33	35
17	20
24	24
37	37
38	38
15	14
10	9
37	37
27	27

The angle of rotation is the same in both cases. The difference lies in the position of the centre of rotation and on the basis of one a.p. film and two lateral films this position cannot be uniquely defined. However, the centre of rotation must lie on the line passing through R and R_t. This line is thus the geometric locus of the centre of rotation and follows a mainly sagittal course. It is not likely that the centre of rotation deviates more than about one centimeter sagittally; therefore, for all practical purposes its position may be regarded as coincident with R.

Material and Results

The technique described has been applied in the examination of 22 knee joints. All the patients had been referred from the Department of Surgery for radiography because of knee joint symptoms; the joints were regarded as unstable by the patients themselves. A control material of 10 healthy joints was also examined. The position of R was determined and the angle of rotation V measured. For each joint a diagram was drawn to show the movement of a point on the lateral border of the tibia and a point on the medial border (Fig. 8). For the sake of simplicity the displacements of the points were represented as straight lines. The results of the determinations for the two groups are presented in Table 1. The mean rotation for the control material was 20.3° and for the patients regarding their joints as unstable 33.3°. In 15 patients replicate determinations were performed to examine the reproducibility of the method (Table 2).

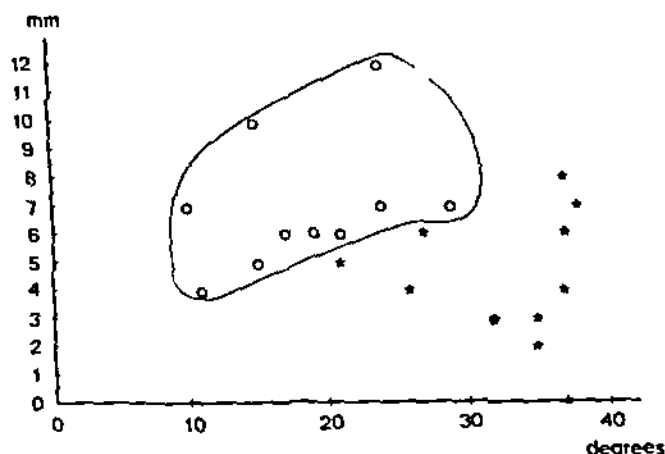


Fig 9 Difference between the lateral and the medial mobility plotted against the rotation of the tibia O Stable group
Unstable group

Discussion

The relationship between on the one hand the mobility of points on the medial and lateral borders of the tibia and on the other the angle of rotation of the tibia is shown graphically in Fig 9 This indicates that the axis of rotation was lateralized in the case of a medial injury and when the angle of rotation was increased When considering this diagram it should be borne in mind that the decision as to whether a knee joint was unstable or not was based solely on the patient s impression a knee with abnormal mobility might be considered to be stable due to compensatory muscular support or limited functional demands on the joint

In 9 patients the sagittal instability was also measured Of these 7 patients had subjectively unstable joints and 2 stable In all cases the medial and the lateral mobility—that is the displacement of a point on the medial and lateral borders of the tibia—were appreciably greater than the purely sagittal mobility As shown by LEVEN the sagittal mobility undergoes no systematic change when the angle of flexion is varied This means that the sagittal instability might be as great at 90 flexion (at which angle the rotation was measured) as at about 135 flexion (when the sagittal instability was determined) It follows that within fairly wide limits the sagittal mobility of the knee joint is not restricted by the collateral ligament or the articular capsule That persistent damage to the collateral ligament was formerly considered to be present in case of evident sagittal instability (PALMER 1957) is probably due to the fact that there has hitherto been no possibility to perform more than a rough estimate of such instability or to discriminate between sagittal and rotational instability

SUMMARY

A n ethod for measuring rotational instability of the knee joint at radiog aphy is de scribed Together with determination of sagittal instability the method might w ll serv as a simple guide in choo ing the appropriate technique for surgery It also enables an assess ement of the operative results since the method is simple and reproducible

ZUSAMMENFASSUNG

Eine Methode zur Bestimmung der Rotationsinstabilitat des Kniegelenks bei der Rontgen untersuchung wird beschrieben Zusammen mit der Bestimmung der sagittalen Instabilitat kann die Methode in einfacher Weise die Wahl der geeigneten chirurgischen Technik er lei htern Sie ermoeglicht auch eine Bewertung der chirurgischen Ergebnisse da die Methode einfach und reproduzierbar ist

RESUME

Description d une methode radiographique de mesure de l instabilité rotatoire de l arti culation du genou En meme temps qu une etude de l instabilité sagittal c tte méthode pourrait servir comme guide simple pour choisir la technique chirurgical appropriée Elle pern et aussi d evaluer les resultats opératoires car cette méthode est simple et reproductible

REFERENCES

BRANTIGAN O C and VOSHELL A F The mechanics of the ligaments and menisci of the knee joint J Bone Jt Surg 23 A (1941) 44

JACOBSEN K Radiologic technique for measuring instability of the knee joint Acta radiol Diagnosis 18 (1977) 113

KAPLAN E B Some aspects of functional anatomy of the human knee joint Clin ortop 23 (1952) 1?

KENNEDY J C and FOWLER P J Medial and anterior instability of the knee J Bone Jt Surg 53 A (1971) 1257

LEVEN H Determination of sagittal instability of the knee joint Acta radiol Diagnosis 18 (1977) 689

O DONOGHUE D H Surgical treatment of fresh injuries to the major ligaments of the knee J Bone Jt Surg 32 A (1950) 721

PALMER I Inju ies to the crucial ligaments of the knee as a surgical problem Reconstruc Surg Traum 4 (1957) 181

SHAW J A and MURRAY D G The longitudinal axis of the knee and the role of the cruciate ligaments in the controlling transverse rotation J Bone Jt Surg 56 A (1974) 1603

SLOCUM D B and LARSSON R L Rotatory instability of the knee J Bone Jt Surg 50 A (1968) 211

SMILLIE I S Injuries of the knee joint Fourth edition Livingstone Churchill London 1971

SYLVIN L E A more ex t measurement of the sagittal stability of the kne joint Acta orthop scand 46 (1975) 1008

FROM THE DEPARTMENT OF DIAGNOSTIC RADIOLOGY (DIRECTOR PROF H LODEN)
AKADEMISKA SJUKHUSET S 750 14 UPPSALA, SWEDEN

GASTROCNEMIO SEMIMEMBRANOSUS BURSA AND ITS RELATION TO THE KNEE JOINT

IV Clinical considerations

PER GUNNAR LINDGREN

The present part of the investigation was intended (1) to determine on patients (Material I) and on autopsy cases (Material II) (a) the frequency of communication between the gastrocnemio semimembranosus bursa and the knee joint (referred to in the following as a communicating bursa) with respect to age sex and laterality (right left) (Materials I and II) (b) the importance of certain technical factors for the demonstration of a communicating bursa (Materials I and II) (c) the frequency of communications in knee joints with and without abnormalities established at radiography (Material I) and (2) to examine the flow of fluid between the knee joint and the gastrocnemio semimembranosus bursa in a selected material of patients with and without clinical signs of a Baker s cyst (Material III)

Material

I During 4 periods in 1971 to 1976 arthrography was performed on 543 patients Of these 24 were not included in the material for technical reasons as well as 15 patients referred for a possible Baker s cyst These 15 patients are included in Material III The remaining material thus consisted of 504 patients

II Autopsy material In 154 cases of varying ages 248 knee joints were examined 234 of them by arthrography None of these cases had had joint disease or joint

Submitted for publication 20 December 1976

symptoms according to their clinical case journals This material compris d an extension of the material presented in Part I (LINDGREN & WILLEN)

III This clinical material of 40 patients was examined with special regard to the gastrocnemio-semimembranosus bursa For 21 of them the indication for arthrography was a possible Baker s cyst In all cases an enlarged bursa had been felt on palpation in 17 an enlarged bursa and fluid effusion were palpable at the time of arthrography In the other 4 cases the question was whether a Baker s cyst had recurred after previous excision Two of these patients had no symptoms while 2 had the same symptoms at the back of the knee as before the operation

In the remaining 15 patients the indication for arthrography was suggested injury to the menisci or to the cruciate or collateral ligaments In 2 of them meniscus l sions were demonstrated and another 2 had incipient arthrosis In the remainder no abnormality was found In these 15 patients the bursa was not palpable and neither had the patients had any symptoms that could be attributed to communication between the bursa and the knee joint The patients were evaluated by a physician experienced in affections of the knee joint

Methods

I The clinical arthrography was performed by the method of LINDBLOM (194) In 425 patients 10 to 14 ml of Urografin 45 % were injected into the knee joint and in 119 randomly selected patients 20 ml were injected The joint was then examined with respect to lesions of the menisci and of the collateral and cruciate ligaments Following the clinical arthrography the patients flexed the knees five times by squatting after which further films of the knee joint region were taken including a lateral view with the knee flexed about 90 i e when the gastrocnemio-semimembranosus bursa if communicating with the joint would be well filled

All patients were examined with respect to arthrosis bone injury loose bodies in the joint meniscus lesions cruciate ligaments capsular injury and communication between the gastrocnemio-semimembranosus bursa and the joint

The length and the sagittal width of the bursa were measured in the lateral vi w at approximately 90 knee flexion The product of these two dimensions indicating the size of the bursa and also the sex and age of the patient the duration of symptoms (in 402 cases) and the knee examined were processed in a computer

II Of the 248 knee joints in the autopsy material 14 were dissected without previous radiography and 234 were submitted to arthrography In these 193 joints Urografin 45 % was injected 20 ml in adults and smaller amounts in children the amount depending upon the size of the child The knee was then flexed and extended 5 to 6 times Films were taken of the knee joint region as a rule including one lateral view with the knee flexed 90 In 20 cases only fluoroscopy of the knee at 90 flexion was performed In 41 of the 234 knee joints the contrast medium was injected stepwise 5 ml at a time up to a total of 20 ml After each 5 ml injection the knee was flexed

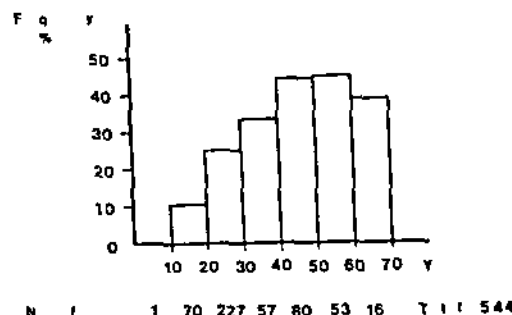


Fig 1 The frequency of communication between the gastrocnemio-semimembranosus bursa and the knee joint in different age groups (Material I 544 cases)

and extended alternately a few times and a lateral film of the joint was then exposed with the knee flexed 90 The sex and age of the subject and the knee examined were noted The menisci and the cruciate and collateral ligaments were not examined as this could not be done in detail with the available apparatus

In 84 cases the length and sagittal width of the bursa were measured on the lateral films with the knee in approximately 90 flexion The product of the two dimensions was used to express the size of the bursa

In 116 cases the roentgenographic findings were checked at subsequent dissection of the knee In no case did dissection reveal an opening between the joint and the bursa which had not been observed at arthrography

III In 40 patients both cineradiography (15 frames per second 35 mm) and clinical arthrography of the knee following injection of contrast medium were performed In 35 patients cineradiography was carried out directly after injection of 20 ml Urografin 45 % into the knee joint and in 5 patients after completion of conventional arthrography Following the injection the patient with the knee still extended was placed on his side in such a position that the lower leg could be moved freely During the cine recording the knee was flexed and extended In addition an attempt was made by manual compression to empty the bursa both with the knee semi flexed and at maximum extension

In 8 patients the examination was complemented with percutaneous puncture of the bursa aspiration of its content and injection of contrast medium after which the above mentioned movements and manoeuvres were repeated In addition to cine radiography films of the knee were exposed at different degrees of knee flexion and at maximum extension

Ten of the 15 patients with possibly injury to the menisci cruciate ligaments or collateral ligaments were examined on two occasions On the first occasion arthro graphy was carried out to answer the question for which the patient had been referred the second examination was performed in cases with a communicating bursa including cineradiography

The length and sagittal width of the bursa were measured with the knee flexed 90 and the product of the two dimensions was used to express the size of the bursa

Table 1

Frequency of communicating bursa in men and women (Material I)

Sex	Communicating bursa		
	Yes	No	Total
Females	30	99	129
Males	131	284	415
Total	161	383	544

Table 2

Frequency of communicating bursa in the right and left knee (Material I)

Side	Communicating bursa		
	Yes	No	Total
Right	84	191	275
Left	77	192	269
Total	161	383	544

Table 3

Frequency of communicating bursa in knees with and without abnormalities of the knee joint at radiography (Material I)

Pathology	Communicating bursa		
	Yes	No	Total
Yes	85	198	283
No	66	161	227
Total	151	359	510

Statistical methods

In the statistical analyses the χ^2 test with a 5% significance level ($\chi_{0.05}$ = 3.84) was used with one degree of freedom unless otherwise stated.

The χ^2 method was extended to a homogeneity test in two analyses regarding the distribution of the size of the bursa and the duration of knee symptoms.

Mean value analysis with normal approximation was used when comparing the size of the bursa between the different materials (confidence level 95).

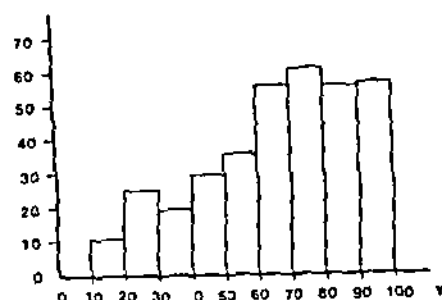


Fig 2 Frequency of communication between the gastrocnemio semimembranosus bursa and the knee joint in different age groups (Material II 248 joints)

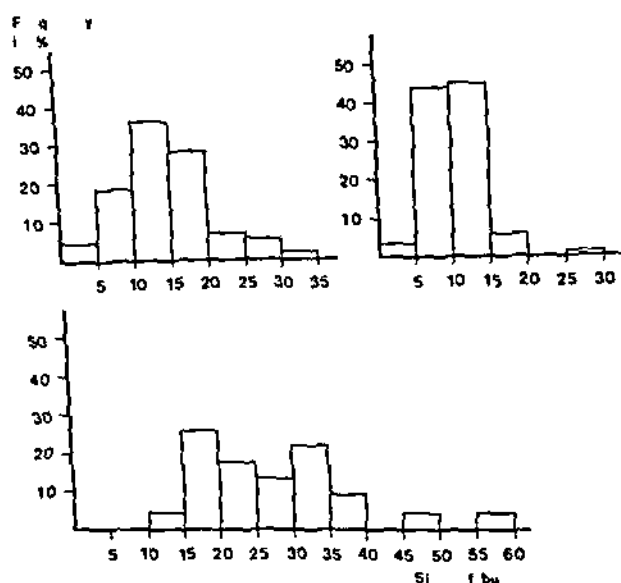


Fig 3 Size of the gastrocnemio-semimembranosus bursa in the different materials The product of the length of the bursa and the sagittal width measured on lateral films at 90 knee flexion is used to express the size of the bursa in mm² 100 Material I = patients without symptoms (upper left) Material II = autopsy material (upper right) Material III = patients with bursal symptoms (lower)

Results

Material I In one group of patients 10 to 14 ml of contrast medium were injected and in another group 20 ml In 128 of 425 and 33 of 119 patients respectively the joint communicated with the bursa

No difference in the frequency of communicating bursa was found between the two groups $\chi^2 = 0\ 20$

The frequency of communicating bursa was greater in the higher age groups (Fig 1) the age distribution of the material is also given

No sex difference in the frequency of communicating bursa was found (Table 1 $\chi^2 = 3\ 12$) and neither was there any difference between the right and left knee (Table 2 $\chi^2 = 0\ 32$)

The frequency of communicating bursa did not differ between knee joints with

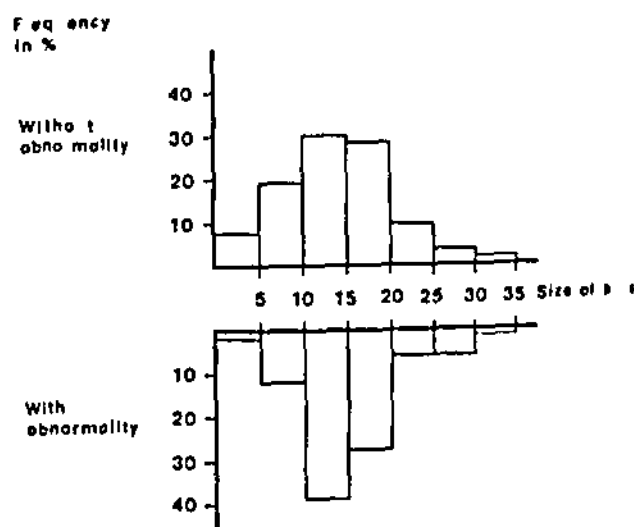


Fig 4 Size of the bursa in Material I (in mm 100) The upper part of the figure represents patients without abnormalities of the knee joint demonstrated at radiography (including arthrosis) The lower part of the figure represents patients with abnormality

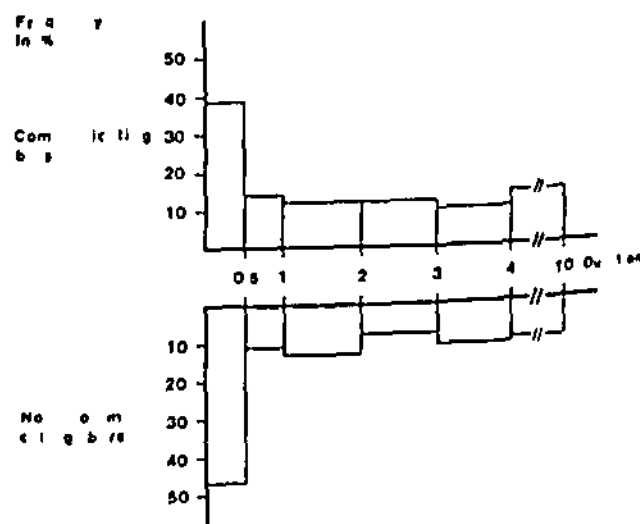


Fig 5 Duration (in years) of symptoms in patients with and without communication between the gastrocnemio-semimembranosus bursa and the knee joint (Material I)

or without abnormalities established at radiography (excluding arthrosis Table 3 χ^2 - 0 04) Each individual type of abnormality, e g lesion of bone or of medial meniscus was also examined and in all these analyses χ^2 was less than 3 84

No difference in the frequency of communicating bursa was found between patients with and without arthrosis in different age groups (Both in the group with and in that without arthrosis other joint lesions were present in some cases) 40-49 years χ^2 0 14 50-59 years χ^2 0 00 60 69 years χ^2 ~ 1 01

The size of the bursa is given in Fig 3 The mean value was 1 410 mm² (range 300-3 400)

The distribution of the size did not differ between the group with and the one

Table 4

Frequency of communicating bursa in men and women (Autopsy material II)

Sex	Communicating bursa		
	Yes	No	Total
Females	39	69	108
Males	63	77	140
Total	192	146	248

Table 5

Frequency of communicating bursa in the right and left knee (Autopsy material II)

Side	Communicating bursa		
	Yes	No	Total
Right	55	83	138
Left	47	63	110
Total	102	146	248

without roentgenographic abnormalities (including arthrosis) (Fig 4) A homogeneity test was performed χ = 5 15 $\chi_{0\,05}$ = 12 6 (6 degrees of freedom)

The duration of symptoms had no influence on the frequency of joints with and without communication between the joint and bursa (Fig 5) A homogeneity test was performed χ = 4 78 $\chi_{0\,05}$ = 11 1 (5 degrees of freedom)

In 11 cases the bursa was not observed at radiography until after the movements

Rupture of the bursa was observed in 21 of the 544 examined patients the bursa ruptured during the squatting movements at amination In 9 patients (2 1 %) 10 to 14 ml of contrast and in 6 patients (5 1 %) 20 ml Only one of these patients joint at the time of examination

Material II In the knee joints in which increasing were injected the bursa was filled after injection of a total of in which the joint and the bursa communicated In 1? well after injection of only 5 ml whereas in 5 cases but the bursa was visible In 4 cases the bursa was only total of 10 ml of contrast medium

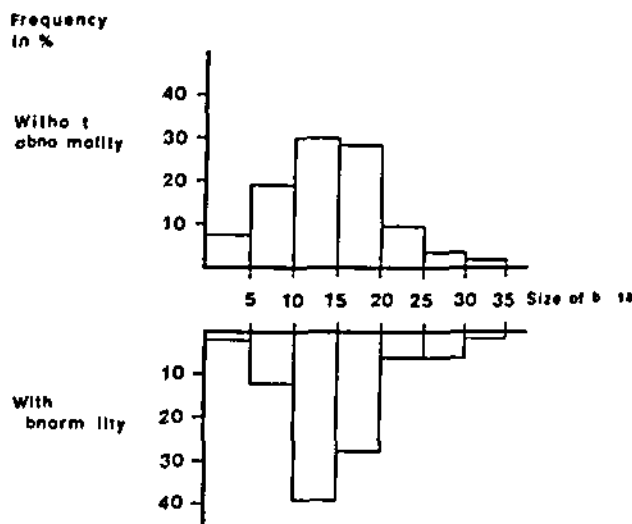


Fig 4 Size of the bursa in Material I (in mm 100) The upper part of the figure represents patients without abnormalities of the knee joint demonstrated at radiography (including arthrosis) The lower part of the figure represents patients with abnormality

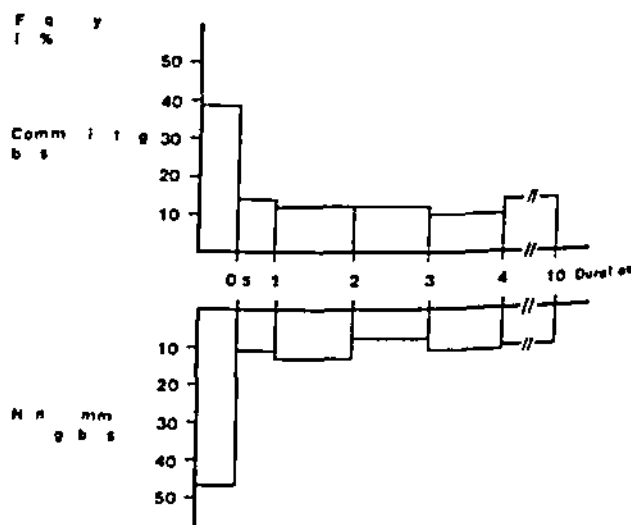


Fig. 5 Duration (in years) of symptoms in patients with and without communication between the gastrocnemio-semimembranosus bursa and the knee joint (Material I)

or without abnormalities established at radiography (excluding arthrosis Table 3 χ^2 0 04) Each individual type of abnormality e g lesion of bone or of medial meniscus was also examined and in all these analyses χ was less than 3 84

No difference in the frequency of communicating bursa was found between patients with and without arthrosis in different age groups (Both in the group with and in that without arthrosis other joint lesions were present in some cases) 40-49 years χ^2 = 0 14 50-59 years χ^2 = 0 00 60-69 years χ^2 = 1 01

The size of the bursa is given in Fig 3 The mean value was 1 410 mm² (range 300 3 400)

The distribution of the size did not differ between the group with and the one

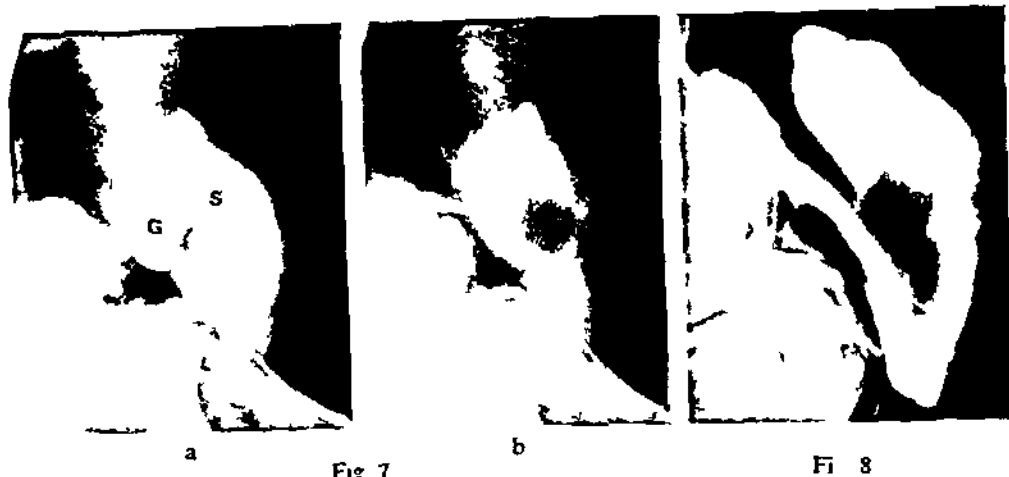


Fig 7 Fi 8

Fig. 7 Effusion in the knee joint the gastrocnemio-semimembranosus bursa palpable G = impression of the gastrocnemius muscle S impression of the semimembranosus muscle b) The same knee position The bursa partially emptied by manual compression

Fig. 8 Patient operated upon for a Baker s cyst. The contrast filled cavity has the same appearance as a normal bursa

Material III With the knee extended intraarticularly injected contrast medium accumulated mainly in the suprapatellar recess On flexion of the knee about 90 the suprapatellar recess was compressed and the contrast medium flowed into the posterior part of the joint and into the gastrocnemio-semimembranosus bursa (Fig 6 a) The site of communication between the joint and bursa was only observed in the lateral view and the sagittal width of the passage between them was 3 to 5 mm

With the knee in the semiflexed position and with the quadriceps relaxed some of the contrast medium flowed back from the bursa into the joint and from the posterior part of the joint to its central and anterior parts (Fig. 6 b) On manual compression of the bursa more contrast medium but not all of it could be forced into the joint (Figs 6 c 7)

When the knee was maximally extended the anterior and middle parts of the bursa were compressed particularly the middle part In no case did any contrast medium pass from the bursa to the joint with the knee in full extension Neither could contrast medium be forced into the joint on manual compression of the bursa with the knee in this position

These findings refer to (1) patients who had not had symptoms from the gastrocnemio-semimembranosus bursa and in whom the bursa was not palpable (2) 12 of the 17 patients who had or had had a palpable bursa and effusion of fluid in the joint and (3) 4 patients operated upon for a Baker s cyst In these 4 cases a cavity with the same appearance as a normal bursa was filled (Fig 8) Two of these patients were free from symptoms The bursa was not palpable and there was no fluid effusion in the joint Two had the same symptoms as before the operation They had a palpable bursa and also fluid in the joint

In 5 patients the filling and emptying of the bursa occurred in another way. In 3 of them a valvular mechanism was found. One had a slight amount of fluid in the joint and an enlarged palpable bursa. Contrast medium passed from the joint to the bursa but not in the other direction. The bursa was punctured during the examination and its content of fluid, which was of normal viscosity, was emptied. Contrast medium of low viscosity was then injected into the bursa and this could not be forced from the bursa to the joint despite manual compression of the bursa.

In the 2 other patients the bursa was enlarged but no effusion was present in the joint. After puncture of the bursa part of its content was aspirated, which was highly viscous, almost gelatinous. Contrast medium was injected directly into the bursa but could not be forced into the joint. On the other hand, on flexion of the knee contrast medium passed from the joint to the bursa.

In another 2 patients a chronically enlarged bursa gave symptoms for 3 to 5 months. No definite fluid effusion was present, but the bursa was palpable. The bursa contained fluid that was more viscous than normally. The bursa did not empty spontaneously but contrast medium, mixed with the content of the bursa, could be forced into the joint by manual compression. A partial valvular mechanism was thus present in these cases.

Thus in all cases with a palpable gastrocnemio-semimembranosus bursa contrast medium was able to pass from the joint to the bursa and in all except 5 it could also easily pass in the other direction. In these 5 cases the flow from the bursa to the joint was partially or completely hindered.

The mean size of the bursa (length × sagittal width) in patients with symptoms from the bursa was 2 765 mm² (range 1 125–5 500) and in patients without symptoms 1 410 mm² (range 300–3 400). A comparison of the size of the bursa in these two groups revealed a statistically significant difference at the 95 % level (u = 7.89 > 1.96).

In all the 5 patients in whom cineradiography was performed after completion of the conventional arthrography, the contrast concentration in the bursa and the joint had decreased so much that the flow between the two cavities could not be evaluated with certainty.

Discussion

Materials I and II. The frequency of communicating bursa was greater in the higher age groups both in the clinical and in the autopsy material. No statistically significant difference in this frequency was found in the different age groups between the two materials (Figs 1, 2). Degenerative changes in the joint capsule and reduced elasticity of the tissue with advancing age increase the probability that an opening between the joint and the bursa will occur (LINDGREN & WILLÉN 1977, LINDGREN 1977). In the 11 patients in whom the bursa was filled only after knee flexion by squatting, these movements may have caused a communication between the bursa and joint as a result of the increased pressure in the posterior part of the joint

LINDGREN & WILLEN 1977, LINDGREN 1978). However, this possibility does not appreciably affect the frequency figures in Fig. 1.

It has been reported previously that the frequency of popliteal cysts is higher in men than in women (WILSON et coll. 1938, GRISTINA & WILSON 1964, MALLOCH 1970) and higher on the right side (REINHARDT 1972). No such differences in frequency were found in the present material.

The frequency of gastrocnemio-semimembranosus bursae that become filled at arthrography has been claimed to be higher in the presence of intraarticular lesions, especially torn menisci (WOLFE & COLLOFF 1972). No such conclusion could be drawn from the present results. Thus no difference in the frequency of communicating bursa was found between cases with and without joint abnormalities. In 34 cases it was difficult to determine whether abnormalities were present or not and these were excluded from the analyses in Table 3, which therefore only includes 510 patients. χ^2 testing was also performed with these 34 patients included as positive, i.e. that they had joint abnormalities. When, in addition, arthrosis was considered in contrast to the calculation in Table 3, χ^2 was 1.33. Thus even in this extended material no difference in frequency was found.

The results of these analyses indicate that no direct relationship exists between knee joint lesions established at radiography and the frequency of communicating bursa. However, a specific trauma, e.g. hyperextension of the knee, or fluid in the joint, may contribute to such a communication (LINDGREN & WILLEN 1977).

The product of the length and sagittal width measured in the lateral view at 90° knee flexion was used as an expression of the size of the bursa for the following reasons:

1) Enlargement of the bursa occurs most readily in the posterior direction (Part I).

2) At arthrography when the knee is flexed 90° the bursa is well filled and easily defined in the lateral view, whereas on extension of the knee its middle and often its anterior part are compressed between the gastrocnemius and semimembranosus muscles anteriorly; it is then often difficult to define.

3) In the a.p. view the bursa is often difficult to define because of superimposition of bone and the presence of contrast medium in the joint.

No difference in the size of the bursa between patients with and without knee joint lesions was found in Material I. An enlargement of the bursa may be caused by prolonged or marked effusion in the joint, e.g. as in rheumatoid arthritis. Only 4 patients with this disease were included in Material I. In only one of these did the joint and bursa communicate, and the size of this bursa did not differ from the average size of the other bursae in this material.

This size of the bursa differed between the two materials and the size and the range of variation were smaller in the autopsy material than in the patients without symptoms, i.e. in Material I (Fig. 3). This is probably due to reduced elasticity of the tissues post mortem, in part due to the low body temperature (+4° C).

The autopsy material was used as a normal material for comparison with the

clinical material A more representative normal material would have been obtained if arthrography could have been performed on randomly selected healthy subjects but this was not feasible

Material III In 5 of the 21 patients with symptoms of a Baker s cyst a partial or complete impediment to flow from the bursa to the joint was found In 2 of these some contrast medium could be forced from the bursa to the joint while in 3 patients this was not possible However in all 5 patients the contrast could be forced in the other direction In 4 of these 5 patients the bursa contained a highly viscous fluid

A partial or complete impediment to emptying of the bursa may have different conceivable explanations

1) The bursa may contain a fluid of such high viscosity that it does not empty spontaneously but which may be forced back into the joint by manual compression The reason why the fluid in the bursa may be more highly viscous than the fluid in the joint is not known

It is conceivable that the concentration of hyaluronic acid is higher giving a higher viscosity in the fluid of the bursa than in the intraarticular fluid This higher concentration could be due to efflux of water through the wall of the bursa by ultra filtration at a high pressure within the bursa An increase in this pressure occurs on marked flexion and on extension of the knee (LINDGREN 1978)

2) A membranous septum may partially bridge the opening between the joint and bursa (LINDGREN & WILLÉN 1977) impeding the flow between the two cavities and possibly also giving rise to a valve mechanism of the type found in the foramen ovale in the heart

3) A combination of the above two alternatives is conceivable

Of the 4 patients who had been operated upon for a Baker s cyst and who had a normal sized bursa postoperatively 2 were free from symptoms In these 2 patients the bursa was not palpable and neither was there any effusion into the joint which was found in the two symptomatic patients In none of the 4 patients was there any hindrance to flow between the joint and bursa in either direction At operation the posterior part of the bursa had been resected while the slit between the joint and the anterior part of the bursa had been left untouched which explains why a bursa like cavity was observed at postoperative arthrography

Patients with symptoms generally had a larger bursa than those without symptoms the mean size in these groups being 2 765 mm² and 1 410 mm respectively (Fig 3) However a large bursa does not necessarily mean that it will give rise to symptoms The symptoms usually do not appear until the bursa has become filled with fluid Symptoms may also be due to concrement in the bursa but this rarely occurs

At cineradiography of the knee after intraarticular injection of contrast medium a good idea of the conditions of flow between the joint and bursa is obtained The same has been reported by DOPPMAN (1965) Following conventional arthrography

he performed cineradiography of the knee joint on patients with no symptoms of Baker s cyst

An advantage of the cineradiographic technique is that the entire flow may be recorded for later examination No videotape recordings were made but these are a possible alternative to cineradiography For routine purposes it is usually sufficient to take conventional films of the knee in the lateral projection followed by flexion of the knee to allow the contrast medium to pass into the bursa films should also be taken before and after an attempt at manual compression of the bursa with the knee semiflexed It is important to fix the knee in position allowing comparison of the films taken before and after the compression with respect to the amount of contrast in the bursa (Fig 7) A p films will give no further information of value as the opening between the joint and bursa cannot be observed in this view

In cases where it is difficult to decide whether any hindrance to emptying of the bursa is present direct puncture of the bursa may be of value A sample of the bursal fluid may then be taken for determination of its viscosity and contrast medium injected allowing a more reliable assessment of the flow conditions

In 15 of the 544 cases the bursa ruptured during the squatting movements In none of these patients did the rupture cause accentuation of symptoms following the examination but rupture of a bursa may give rise to thrombosis like symptom in the leg especially in patients with rheumatoid arthritis (Hall & Scott 1966 among others) The present results therefore indicate that squatting should be avoided in case of doubt as to whether the joint and bursa are communicating Passive knee flexions should be performed in the supine position in which the pressure increase in the joint on flexion is less

At present about 200 to 300 cases of Baker s cyst are operated upon annually in Sweden The frequency of recurrence is high (Rausching & Lindgren to be published) A careful selection of these patients seems necessary Information on the flow between the joint and the bursa is important as this may influence the decision as to whether or not surgery should be undertaken

SUMMARY

The frequency of communication between the gastrocnemio-semimembranosus bursa and the knee joint was investigated in a clinical material and in autopsy cases The frequency was higher in the older age groups No increase in this frequency or in the size of the bursa was found in patients with knee joint lesions at arthrography By cineradiography and in the majority of cases by conventional arthrography alone a good idea of the flow between the joint and the bursa was obtained A valvular mechanism between the joint and bursa was demonstrated in 5 cases

ZUSAMMENFASSUNG

Die Frequenz einer Kommunikation zwischen der Bursa musculi gastrocnemii et semimembrasnosi und dem Kniegelenk wurde bei einem klinischen Material und einem Sektionsmaterial untersucht Die Frequenz war hoher in den alteren Altersgruppen Kein Anstieg

in der Frequenz oder in der Grosse der Bursa wurde bei Patienten mit Kni gelenkläsionen bei der Arthrographie gefunden Durch Kinematographie und in den meisten Fallen durch konventionelle Arthrographie wird eine gute Auffassung über den Fluss zwischen dem Gelenk und der Bursa erhalten Ein Klappenmechanismus zwischen dem Gelenk und der Bursa wurde bei funf Fallen nachgewiesen

RÉSUME

L auteur a étudié la frequence de la bour e commune au jumeau et au semimembraneux communiquant avec l arti ulation du genou sur un matériel clinique et sur des cas d autopsie La fréquence est plus élevée dans le groupe de sujets agés La fréquence ou les dimensions de cette bourse ne sont pas augmentées chez les malade qui ont des l ions de l articulation du genou a l arthrographie Le radiocinéma et dans la majorité des cas l arthrographie simple donnent une bonne idee de l écoulement entre l articulation et la bourse Un mécan isme de soupape entre l articulation et la bourse a été mis en évidence dans 5 cas

REFERENCES

LIND REN P G and WILLE R Gastrocnemio-semimembranosus bursa and its rela tion to the knee joint I Anatomy and histology Acta radiol Diagnosis 18 (1977) 497 (For further references see part I)

FROM THE MAMMOGRAPHY SECTION GAVLE SJUKHUS S 800 07 GAVLE SWEDEN

MALIGNANT FEATURES OF BREAST TUMOURS AT RADIOGRAPHY

B LUNDGREN

The abnormalities which indicate that a mammary tumour is malignant are well known and generally accepted the most common being a dominant mass but the so called malignant microcalcifications have attracted greatest interest (BJURSTAM et coll 1974 BUCHWALD et coll 1970 EGAN 1960 1963 1964 GALLAGHER & MARTIN 1969 GERSHON COHEN et coll 1962 1966 1969 HASSLER 1969 KOEHL et coll 1970 LEBORGNE 1951 PAULUS 1971 RASMUSSEN 1969 ROSEN et coll 1970)

Calcifications are common in the human female breast The majority appear in benign conditions and are easily identified such as those in the walls of small cysts They are well circumscribed and often spherical Calcifications in fibro adenomas are usually relatively large and irregular and are also readily identified Solitary or two or three round and clearly defined microcalcifications u ually of the size of a dot or smaller may occur They may also be present in clusters or be diffusely spread through the glandular tissue and are found in benign diseases such as fibroadenosis sclerosing adenosis cystic disease or other conditions They are usually of fairly uniform size

Calcific deposits appearing together with carcinoma are usually small and irregular the radiographic contrast and the size of the deposits vary even in the same tumour They often appear in clusters or follow ducts generally giving an impression of disorder HAS LER suggested that these calcifications are formed in ducts that have been occluded by the growing carcinoma

Submitted for publication 11 January 1977

in der Frequenz oder in der Grosse der Bursa wurde be[illegible] bei der Arthrographie gefunden Durch Kinematographi[illegible] konventionelle Arthrographie wird eine gute Auffassun[illegible] Gelenk und der Bursa erhalten Ein Klappenmechanism[illegible] Bursa wurde bei funf Fallen nachgewiesen

RESUME

L auteur a etudie la frequence de la bourse commune au jur[illegible] communiquant avec l articulation du genou sur un matériel cliniq[illegible] La frequence est plus elevée dans le groupe de sujets ages La fr[illegible] de cette bourse ne sont pas augmentees chez les malades qui ont d[illegible] du genou a l arthrographie Le radiocinéma et dans la majorit[illegible] simple donnent une bonne idee de l ecoulement entre l articulation [illegible] isme de soupape entre l articulation et la bourse a eté mis en évidn[illegible]

REFERENCES

LINDGREN P G and WILLEN R Gastrocnem o-semimembranosus [illegible] tion to the knee joint I Anatomy and histology Acta radiol D[illegible] 497 (For further references see part I)

Table 2

Detection at Department of Oncology and at screening and detection modalities

Carcinomas detected	Malignancy at						Total
	Radiography alone		Clinical examination alone		Both modalities		
	No	Per cent	No	Per cent	No	Per cent	
At Dept of Oncol	38	21	14	8	127	71	179
At screening	54	44	7	6	62	50	123
Total	92	31	21	7	189	62	302

The age distribution of the patients with malignancy at the time of detection appears in Table 1 Patients with tumours found at radiography but not at clinical examination i e preclinical or occult cases were on the average 4 years younger than those detected by both modalities and patients with carcinomas found at clinical examination but not at radiography were 13 years younger

In Table 2 the material is divided according to where the tumour was detected —at the Department of Oncology or at screening—and to the detection modality The total frequency of false negatives at radiography was about 7 per cent the overall rate of carcinoma detected by radiography only was 31 per cent The frequency was higher at screening of unselected women (44%) than at the Department of Oncology (21%)

Methods

Clinical examination was carried out by experienced oncologists Mammary radiography was performed with the compression technique and with three standard views cranio caudal latero medial and an oblique view All films from the occasion when a diagnosis of malignancy was reached were reviewed and the type of abnormality and size of the tumour recorded

Types of abnormality

Tumour mass A note was made of whether the outline of the mass was entirely or partly diffuse or whether the mass was well circumscribed

Tumour vicinity Distortion of the normal structure of the tissues around the tumour may occur mostly appearing as spiculae i e long or short fine and straight strands of tissues radiating from the tumour Retraction of tissues in the direction of the tumour also occurred as well as a diffuse general disturbance of tissues These abnormalities have all been referred to the heading Adjacent tissues in the present report

Table 3

Prevalence of radiologic abnormalities indicating malignancy

Abnormalities	No of cases	Per cent
1 Tumour mass	266	88
2 Adjacent tissues	260	86
3 Calcifications	93	31
4 Asymmetry	9	3
5 Secondary abnormalities	59	20
6 No abnormalities	17	6
Total	302	100

Calcifications at the site of the tumour were noted Obviously benign calcifications such as those appearing in cysts or fibroadenomas were considered incidental and were excluded

These three types of abnormality have been called primary abnormalities indicating malignancy

Other abnormalities were prominent veins dilated ducts and asymmetry Asymmetry was always present when one or more of the primary abnormalities were found in one breast However when these are slight or absent the presence of glandular tissues in one site in one breast but not in the other may facilitate the diagnosis

Secondary abnormalities Skin thickening nipple or skin retraction and local or general oedema of the breast were also noted although these abnormalities generally are of little radiographic importance They are generally quite evident clinically and occur usually with advanced growth

Size of carcinoma

Whenever possible the size of the malignant tumour was calculated by measuring its longest diameter and at right angles to this another diameter This was done in as many projections as possible An average diameter for each tumour was calculated The possibility of optical magnification has been disregarded since the object was generally close to the film

In some cases it was not possible to use this method e g in the 21 cases considered to be normal at the primary reporting These tumours were measured by the pathologist on the specimens except in one case where the outline of the tumour was too diffuse The latter also prevented measurement of 14 tumours found at radiography These 15 cases were not included in the determination of tumour sizes which thus covers 287 mammary carcinomas

Table 4

Prevalence of malignant abnormalities in relation to detection modality

Abnormalities	Radiography alone		Clinical examination alone		Both modalities	
	No	Per cent	No	Per cent	No	Per cent
1 Tumour mass	83	90	4	19	179	95
2 Adjacent tissues	82	89	2	9	176	93
3 Calcifications	28	30	—	—	65	34
5 Secondary abnormalities	—	—	—	—	59	31
Total	92		21		189	

Table 5

Prevalence of malignant abnormality and average number of abnormalities per case in 189 patients with mammary carcinoma demonstrated both at clinical examination and at radiography

Abnormalities	At screening (62 cases)		At Dept of Oncol (127 cases)	
	No	Per cent	No	Per cent
1 Tumour mass	59	95	120	95
2 Adjacent tissues	61	98	115	91
3 Calcifications	25	40	40	32
5 Secondary abnormalities	21	34	38	30
Average No of primary abnormalities	2 4		2 3	

Results

The heading Other abnormalities has been changed to Asymmetry in the following since this was the only other abnormality recorded when the review was completed Table 3 displays the whole material of 302 carcinomas in 294 patients including the 21 in whom no abnormality was found at mammary radiography

A tumour mass generally accompanied by some distortion of adjacent tissues was the most common indication of malignancy 88 and 96 per cent respectively

Calcifications occurred in 31 per cent of all cases Asymmetry was considered helpful in a few cases only (3°)

Secondary abnormalities usually caused by advanced malignant growth occurred in 20 per cent and no radiologic abnormality at all in 6 per cent In 21 cases the primary radiographic report was normal (Table 2) However on review of the films a tumour was observed in 4 of these and in 2 of them distortion of tissue was also present These 4 may thus be called truly missed at the mammary radiography since they were reported as normal in the remaining 17 cases no evidence of malignancy (Table 4) was present

Table 6

Prevalence of malignant abnormalities and average number of abnormalities per case in 92 patients with mammary carcinoma demonstrated at radiography alone

Abnormalities	At screening (54 cases)		At Dept of Oncol (38 cases)	
	No	Per cent	No	Per cent
1 Tumour mass	54	100	29	76
2 Adjacent tissues	52	96	30	79
3 Calcifications	15	26	13	34
Average No of primary abnormalities	2 3		1 9	

Table 7

Solitary abnormalities indicating malignancy at radiography leading to further investigation Prevalence in total material

Abnormalities	No of cases	Per cent
1 Tumour mass	4	1 3
2 Adjacent	2	0 6
3 Calcifications	11	3 6
Total	17	5 5

In Table 4 the 302 cases have been divided according to the detection modality i e at radiography only at clinical examination only or at both modalities (cf Table 2)

No significant difference in the frequency of primary abnormalities (tumour adjacent tissues calcifications) existed between carcinomas found at radiography alone and those found at both modalities Secondary abnormalities only occurred when a carcinoma could be detected by both modalities

In Table 5 the material has been divided into cases detected at screening and at the Department of Oncology respectively Only tumours found at both modalities appear in this table (189 cases)

No significant difference was found either in prevalence of the various abnormalities or in average number of abnormalities per case among carcinomas detected by both clinical examination and radiography

The cases with a tumour found at mammary radiography only that is preclinical cases have been divided according to the same principle (Table 6) Tumour mass and distortion of adjacent tissues were the most common abnormalities in cases detected at screening less so in cases detected at the Department of Oncology Calcifications seemed to be more usual at the Department of Oncology than at

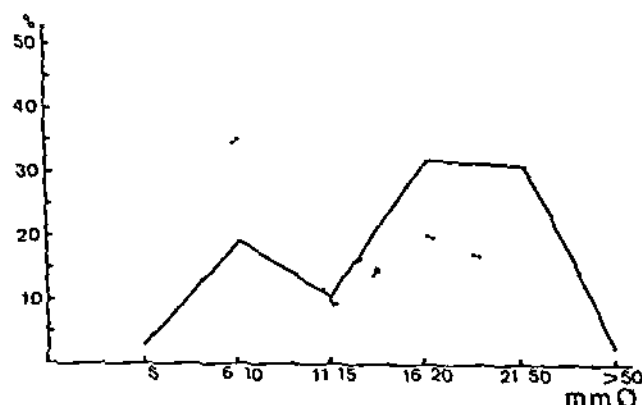


Fig 1 Distribution of tumour sizes according to mode of detection 287 measurable breast carcinomas Per cent of number of carcinomas in each subgroup **** Radiography only positive (84 cases) Clinical examination only positive (20 cases) —— Both modalities positive (183 cases)

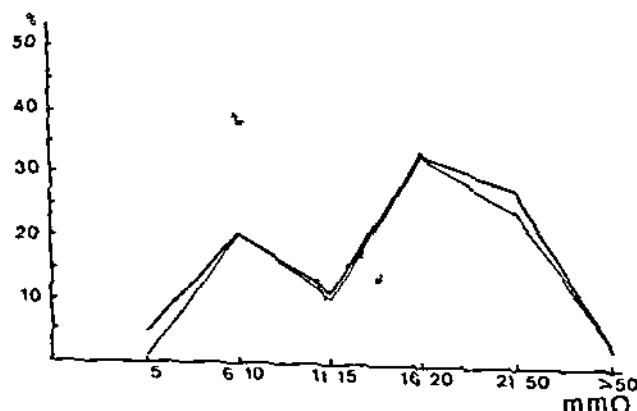


Fig 2 Distribution of tumour sizes according to mode of detection 287 measurable breast carcinomas Per cent of number of carcinomas in each subgroup * Radiography only positive at screening (53 cases) ---- Radiography only positive at Dept of Oncol (31 cases) Clinical examination only positive (20 cases) —— Both modalities positive at screening (60 cases) —— Both modalities positive at Dept of Oncol (123 cases)

screening The average number of abnormalities per case was higher at screening (2 3) than at the Department of Oncology (1 9)

In a small number of cases a solitary indication of malignancy was considered sufficient to warrant selection for further examination and definite diagnosis One of these 17 cases was encountered at screening the rest at the Department of Oncology (Table 7) Calcifications of malignant type as a sole indication of malignancy occurred in 11 cases (3 6 %) 7 of these were detected by mammary radiography alone Thus malignant calcifications as a solitary abnormality led to early detection in 2 per cent of all cases and in 7 of 92 cases (8 %) detected by mammary radiography alone

Tumour si es Although the average diameter of each tumour was measured to the nearest millimeter they are presented here in size classes <5 mm 6 to 10 mm 11 to 15 mm 16 to 20 mm 21 to 50 mm >50 mm

In the figures the frequency of tumours in each size class is used instead of absolute numbers to facilitate comparison The distribution of the tumour sizes according to detection modality appears in Fig 1

Table 8

Average diameters and range (in mm) in 287 cases of mammary carci noma

	Radiography alone	Clinical exami national alone	Both mo-dalities
Average	9 6 8 3* 11 9	14 9	20 6
Range	2–20 2–20* 4–20**	4–40	4–50

At screening
* *At Dept of Oncol*

In Fig 2 they have been further split according to whether the tumours were detected at screening or at the Department of Oncology except for those found at clinical examination only their number was 20 It is apparent that the size distribu tion was equal both at screening and at examination at the Department of Oncology when both modalities were positive

The average diameters and ranges are presented in Table 8

The average size of the carcinomas detected at screening with radiography alone was smaller than that of corresponding tumours detected at the Department of Oncology 8 3 mm and 11 9 mm respectively

Discussion

Two indications of malignancy in breast tumours at mammary radiography mentioned in the literature (DODD & WALLACE LEVITAN et coll 1964) do not appear in the present material i e wide veins and dilatation of ducts No widened veins were found in the vicinity of the malignant tumours in the present series This may partly be explained by the fact that compression of the breasts was used at the radiography It is then common that superficial veins are also compressed and thus do not appear in the images Another reason may be that carcinomas must reach a fairly large size before the veins are widened It is hardly possible to conceive widened veins as an early radiologic finding

Dilatation of ducts was not unusual since a fair proportion of patients with mammary carcinoma also have benign cystic disease where such dilatations are common When dilatations were observed in this material they were consistently bilateral and could not be used as an indication of malignancy Dilatation of ducts is common in patients with breast complaints

If they are considered to indicate malignancy the frequency of erroneous diagnosis at radiography would be considerable

The frequency of calcifications as an indication of malignancy in this material (31 %) agreed with that found in other series (EGAN 1960 1963 GERSHON COHEN et coll 1962 1966 LEBORGNE LEVITAN et coll) The number of cases in which calcifications were the only indication of malignancy and led to an early diagnosis was low 7 of 302 (2 3 %) This is somewhat surprising considering the great importance attached to malignant calcifications in the literature In a number of other cases in which other abnormalities indicating malignancy were also present calcifications may well have contributed to the diagnosis

A tumour mass and distortion of the adjacent tissues were found in more than 90 per cent of the cases with abnormalities Practically no difference was found in average size or frequency of secondary abnormalities (skin thickening skin or nipple retraction) when both clinical examination and radiography indicated malignant tumour irrespective of whether the tumours were detected at screening or at the Department of Oncology Average diameters were 21 mm in both cases and size distribution was parallel for these two groups The frequency of secondary abnormalities was 34 and 30 per cent respectively The average ages for these two groups were also identical

When these factors—size of the carcinoma and presence of secondary abnormalities—which have prognostic importance are considered nothing seems to have been gained by screening in cases in which the tumours were detected both at the clinical examination and at radiography

The difference in average ages between patients with carcinomas detectable by both modalities and those detected by radiography alone (4 years) may be a suggestion of the so-called lead time or the time gained in detection of mammary carcinoma by using radiography

The average age of the 21 patients in whom the tumours were not demonstrated at mammary radiography was 51 years substantially lower than the average age of the remaining patients in this material The reason for the tumours not being detected was not that these patient had breasts with compact glandular or fibrous tissues thus making the images difficult to evaluate In fact 11 were of the type considered easy to evaluate 10 were moderately difficult and none had breasts of the compact or fibrous type Four cases in fact had abnormalities indicating malignancy which were overlooked In the remaining cases nothing suggests malignancy not even asymmetry This may be due to a very infiltrative cancer growth The follow up time in these cases is still short but there are reasons to believe that they may be of a very malignant type with early metastases

Seventeen cases in this series had only one abnormality indicating malignancy One case was found at screening and 16 at the Department of Oncology It is quite possible that a radiologist is more inclined to suggest malignancy when confronted with a referral note stating clinical findings and sometimes suggestions than at a

Table 8

Average diameters and range (in mm) in 287 cases of mammary carcinoma

	Radiography alone	Clinical examinational alone	Both modalities
Average	9 6 8 3 11 9	14 9	20 6
Range	2–20 2–20* 4–20*	4–40	4–50

At screening
* At Dept of Oncol

In Fig 2 they have been further split according to whether the tumours were detected at screening or at the Department of Oncology except for those found at *clinical examination only their number was 20 It is apparent that the size distribu*tion was equal both at screening and at examination at the Department of Oncology when both modalities were positive

The average diameters and ranges are presented in Table 8

The average size of the carcinomas detected at screening with radiography alone was smaller than that of corresponding tumours detected at the Department of Oncology 8 3 mm and 11 9 mm respectively

Discussion

Two indications of malignancy in breast tumours at mammary radiography mentioned in the literature (DODD & WALLACE LEVITAN et coll 1964) do not appear in the present material i e wide veins and dilatation of ducts No widened veins were found in the vicinity of the malignant tumours in the present series This may partly be explained by the fact that compression of the breasts was used at the radiography It is then common that superficial veins are also compressed and thus do not appear in the images Another reason may be that carcinomas must reach a fairly large size before the veins are widened It is hardly possible to conceive widened veins as an early radiologic finding

Dilatation of ducts was not unusual since a fair proportion of patients with mammary carcinoma also have benign cystic disease where such dilatations are common When dilatations were observed in this material they were consistently bilateral and could not be used as an indication of malignancy Dilatation of ducts is common in patients with breast complaints

If they are considered to indicate malignancy the frequency of erroneous diagnosis at radiography would be considerable

The frequency of calcifications as an indication of malignancy in this material (31 %) agreed with that found in other series (EGAN 1960 1963 GERSHON COHEN et coll 1962 1966 LEBORGNE LEVITAN et coll) The number of cases in which calcifications were the only indication of malignancy and led to an early diagnosis was low 7 of 302 (2 3 %) This is somewhat surprising considering the great importance attached to malignant calcifications in the literature In a number of other cases in which other abnormalities indicating malignancy were also present calcifications may well have contributed to the diagnosis

A tumour mass and distortion of the adjacent tissues were found in more than 90 per cent of the cases with abnormalities Practically no difference was found in average size or frequency of secondary abnormalities (skin thickening skin or nipple retraction) when both clinical examination and radiography indicated malignant tumour irrespective of whether the tumours were detected at screening or at the Department of Oncology Average diameters were 21 mm in both cases and size distribution was parallel for these two groups The frequency of secondary abnormalities was 34 and 30 per cent respectively The average ages for these two groups were also identical

When these factors— ize of the carcinoma and presence of secondary abnormalities—which have prognostic importance are considered nothing seems to have been gained by screening in cases in which the tumours were detected both at the clinical examination and at radiography

The difference in average ages between patients with carcinomas detectable by both modalities and those detected by radiography alone (4 years) may be a suggestion of the so-called lead time or the time gained in detection of mammary carcinoma by using radiography

The average age of the 21 patients in whom the tumours were not demonstrated at mammary radiography was 51 years substantially lower than the average age of the remaining patients in this material The reason for the tumours not being detected was not that these patient had breasts with compact glandular or fibrous tissues thus making the images difficult to evaluate In fact 11 were of the type considered easy to evaluate 10 were moderately difficult and none had breasts of the compact or fibrous type Four cases in fact had abnormalities indicating malignancy which were overlooked In the remaining cases nothing suggests malignancy not even asymmetry This may be due to a very infiltrative cancer growth The follow up time in these cases is still short but there are reasons to believe that they may be of a very malignant type with early metastases

Seventeen cases in this series had only one abnormality indicating malignancy One case was found at screening and 16 at the Department of Oncology It is quite possible that a radiologist is more inclined to suggest malignancy when confronted with a referral note stating clinical findings and sometimes suggestions than at a

screening where no information of this kind is available This point is further illustrated by the average number of abnormalities indicating malignancy (Table 6) Tumours detected by radiography alone had an average of 1 9 abnormalities per case at the Department of Oncology whereas at screening the average was 2 3

SUMMARY

A consecutive series of 302 cases of microscopically confirmed mammary carcinoma was reviewed mainly with regard to abnormalities indicating malignancy at mammary radiography Most important was the demonstration of a tumour mass and distortion of adjacent tissues Calcifications of malignant type were present in 31 per cent of all cases but led alone to a preclinical diagnosis of malignancy in only 2 per cent of the cases Carcinomas detectable by both clinical examination and mammary radiography seemed to be as advanced irrespective of whether they were detected at a referral clinic or at screening of asymptomatic women

ZUSAMMENFASSUNG

Eine Übersicht uber eine konsekutive Serie von 302 Fallen mit mikroscopisch nachgewiesenem Brustkarzinom wesentlich in Hinblick auf Abnormalitaten die bei der Rontgenuntersuchung der weiblichen Brust auf Malignitat hinweisen wird gegeben Am bedeutungsvollsten war der Nachweis einer Tumormasse und einer Verschiebung des anliegenden Gewebes Kalzifikationen von malignem Typus lagen in 31 Prozent der Fälle vor fuhrten jedoch alleine zu einer praklinischen Diagnose von Malignitat nur in 2 Prozent der Falle Karzinome die bei sowohl der klinischen Untersuchung wie der Rontgenuntersuchung nachweisbar waren schienen unabhangig davon ob diese in einer Einweisungsklinik oder bei einer Screeninguntersuchung von asymptomatischen Frauen vorgenommen worden war gleicherweise fortgeschritten zu sein

RÉSUMÉ

Une série consecutive de 302 cas de cancer du sein confirmés à l examen microscopique a eté revue principalement pour rechercher des anomalies qui caractérisent la malignité sur la radiographie mammaire L anomalie la plus importante est la mise en évidence d une masse tumorale et d une distortion des tissus adjacents Les calcifications de type malin étaient présentes dans 31 pour-cent de tous les cas mais n ont conduit à elles seules au diagnostic pre clinique de malignité que dans deux pour cent des cas Les cancers detectables aussi bien à l examen clinique qu à la radiographie mammaire ont semblé être aussi avances soit qu ils aient été détectés sur la base d un soupçon clinique soit qu ils aient été détectés sur l examen systématique de femmes sans symptome

REFERENCES

BJURSTAM N HEDBERG K HULTBORN K A JOHANSSON N T and JOHNSÉN C Diagnosis of breast carcinoma *In* Progress in surgery Vol 13 p 65 Karger Basel 1974

BUCHWALD W HULSE R und FASSL H Zur Differential Diagnose des malignen Herdschattens in der Mammographie Fortschr Rontgenstr 112 (1970) 3

DODD G D and WALLACE S D The venous diameter ratio in the radiographic diagnosis of breast cancer Radiology 90 (1968) 900

EGAN R L Experience with mammography in a tumor institution Evaluation of 1 000 studies Radiology 75 (1960) 894
— Mammography Amer J Surg 106 (1963) 421
— Mammography Charles C Thomas Springfield Illinois 1964
GALLAGHER H S and MARTIN J F Early phases in the development of breast cancer Cancer 24 (1969) 1170
GERSHON COHEN J and SCHORR S The diagnostic problems of isolated circumscribed breast tumors Amer J Roentgenol 106 (1969) 863
— BERGER S M and CURCIO B M Breast cancer with microcalcifications Radiology 87 (1966) 613
— YIU L S and BERGER S M The diagnostic importance of calcareous patterns in roentgenography of breast cancer Amer J Roentgenol 88 (1962) 1117
HASSLER O Microradiographic investigation of calcifications of the female breast Cancer 23 (1969) 1103
JACOBSSON S LUNDGREN B MELANDER O and NORIN T Early breast cancer detection in a Swedish city *In* Advances in tumour prevention detection and characterization Int Congr Ser 322 Vol 2 Excerpta Medica Foundation Amsterdam 1974
— — — — Mass screening of a female population for detection of early carcinoma of the breast Acta radiol Ther Phys Biol 14 (1975) 424
KOEHL R H SNYDER R HUTTER R V P and FOOTE F W The incidence and significance of calcifications within operative breast specimens Amer J clin Path 53 (1970) 3
LEBORGNE R L Diagnosis of tumors of the breast by simple roentgenography Amer J Roentgenol 65 (1951) 1
LEVITAN L H WITTEN D M and HARRISON E G Calcification in breast disease Mammographic pathologic correlation Amer J Roentgenol 92 (1964) 29
LUNDGREN B and JAKOBSSON S Single view mammography A simple and efficient approach to breast cancer screening Cancer 38 (1976) 1124
PAULUS D D Radiological detection of clinically occult carcinoma of the breast Cancer Bull 23 (1971) 107
RASMUSSEN T Mammografi (In Danish) Hjorring 1969
ROSEN P SNYDER R FOOTE F W and WALLACE T Detection of occult carcinoma in the apparently benign breast biopsy through specimen radiography Cancer 26 (1970) 944
WOLFE J N Ducts as a sole indicator of breast carcinoma Radiology 89 (1967) 206

FROM THE DEPARTMENT OF DIAGNOSTIC RADIOLOGY MALMÖ ALLMANNA SJUKHUS
S 214 01 MALMÖ SWEDEN

RADIOLOGIC APPEARANCE OF COMPLETE GASTRIC EROSIONS


B TRÄGÅRDH L WEHLIN and K OHASHI

A gastric erosion is a superficial defect which unlike an ulcer does not extend into the submucosa and usually is too shallow to be demonstrated at radiography Sometimes it is located on top of an edematous swelling and is thereby elevated up to one centimeter above the surrounding mucosa (FRIK 1965 Fig 1 a) called complete erosion by KAWAI et coll (1968) and ROESCH & OTTENJANN (1970) It may appear on the films as a rounded or elongated protrusion with a characteristic central barium deposit representing the mucosal defect (Fig 2 b c)

The roentgenologic manifestations of complete erosions have been reported by several authors (HENNING & SCHATZKI 1933 ABEL 1954 WALK 1955 BUCKER 1964) They were considered to represent a form of gastritis by KONJETZNY (1930) and seem to have been largely forgotten when the unreliability of the radiologic diagnosis of other forms of gastritis was realized However the increased use of the fiber optic gastroscope has led to a renewed interest in gastric erosions (KAWAI et coll 1970 ROESCH & OTTENJANN) Recently POPLACK et coll (1975) and HUNT & ANDERSON (1976) reported on gastric erosions but the radiologic possibility of detecting these lesions need to be further stressed

Different opinions exist about the frequency of gastric erosions (KONJETZNY ROESCH & OTTENJANN) Furthermore there is no agreement as to how often they can be demonstrated at radiography of the stomach (BERG 1953 WALK 1955 FRIK &

Submitted for publication 22 July 1976



a



b

Fig 1 Endoscopy a) Complete erosions b) Complete erosions many appearing as widened folds simulating polyps

Table 1

Radiologic findings in 33 patients with complete erosions

No of cases	Time span between radiology and gastroscopy	Preliminary diagnosis of complete erosions	Findings on re-examination		
			Typical	Possible	No abnormality
33	1 month	7	14	7	12
13	1–3 months	1	3	1	9

HESSE 1956) In order to elucidate these problems a series of cases with complete erosions detected by gastroscopy is now reported and their radiographic appearances discussed

Material and Methods

The material consisted of 656 patients in whom gastroduodenoscopy was performed by the authors at this department during 1975 These patients comprised 73 per cent of all gastroscopic examinations performed at this hospital during that year

All patients with one or several complete erosions in the stomach or in the duodenum at gastroscopy were included in the material The films from radiographic examinations and the reports were collected and the films re-examined by the authors The findings on re-examination were classified into three groups Typical complete erosions possible complete erosions and no evidence of complete erosions The examination method giving the best demonstration of the lesion was also analyzed

Results

Among the 656 patients 58 (11 %) were found to have one or several complete erosions most frequently in the antrum of the stomach but in a few patients also in the duodenum or in the corpus of the stomach In order to exclude malignancy biopsy was performed in 39 of the 58 patients

Radiology of the stomach and the duodenum was performed in 46 patients in 33 of these less than one month and in 13 patients one to 3 months before the endoscopy (Table 1) Gastric erosions were suggested in the preliminary report of 7 of the patients examined less than one month before the endoscopy but only in one patient examined one to 3 months previously (Table 1)

On re-examination of the films typical or possible complete erosions were observed in 21 of the 33 patients (64 %) examined less than one month before the endoscopy but in only 4 of the 13 patients (31 %) examined one to 3 months before gastroscopy (Table 1)

Double contrast films with a proper amount of air and films with graded compression of the barium filled antrum were both found to give satisfactory demonstration of erosions at this location

Table 2

Preliminary diagnosis compared with re-evaluation of the films from 46 patients with complete erosions at gastroscopy

Re-evaluation	Preliminary diagnosis				
	Erosion	Polyps	Ulcer	Large folds	Negative
Typical	5	5	8	7	1
Possible	3	1	4	2	0
No abnormality	0	0	7	7	7

The preliminary resports suggested various diagnoses in the 46 patients (Table 2)

The correct diagnosis of gastric erosions was made in 8 patients in 2 of these large gastric folds and gastric erosions were suggested

In 6 patients the findings were considered to be gastric polyps In addition to polyps ulcer was suggested in 2 of these patients but gastroscopy confirmed ulcer in one only

Ulcers were suggested in 19 patients (Table 2) The ulcer was located in the stomach in 13 in the duodenum in 3 and both in the stomach and the duodenum in 3 patients Gastroscopy confirmed ulcer in 13 of these patients 8 in the stomach and 5 in the duodenum One unreported ulcer was also found at gastroscopy three of the patients who were not readiographically examined had ulcers also at gastroscopy Thus at gastroscopy 9 of the 58 patients (16 %) with complete erosions were found to have gastric ulcers in addition and 8 of the patients (14 %) had also duodenal ulcers

Large or irregular folds were reported in 16 patients (Table 2) In 6 of these it was the only reported finding. Ulcers were detected in addition to prominent mucosal folds in 7 patients In 2 patients erosions and folds were suggested and in one polyps and large folds were observed

Discussion

At gastroscopy an area with wide protruding mucosal folds sometimes simulating polyps is observed usually in the antrum and at close inspection on top of a fold a red or greyish fleck representing the erosion (Fig 1 b) Such erosions may be found also in the corpus of the stomach or in the duodenum but less frequently At radiography complete erosions usually appear as multiple rounded or elongated mucosal protrusions with a central shallow barium deposit (Fig 3) The erosions in the corpus of the stomach (Fig 4 a) and in the duodenum (Figs 4 b 5) are more difficult to detect than in the antrum

In the literature the radiologic appearances characteristic of complete gastric erosions have been described as erosive gastritis *Dellengastritis* ulcerous verrucous or varioloform gastritis (FRIK & HESSE, KAWAI et coll 1968) Erosive gastritis has

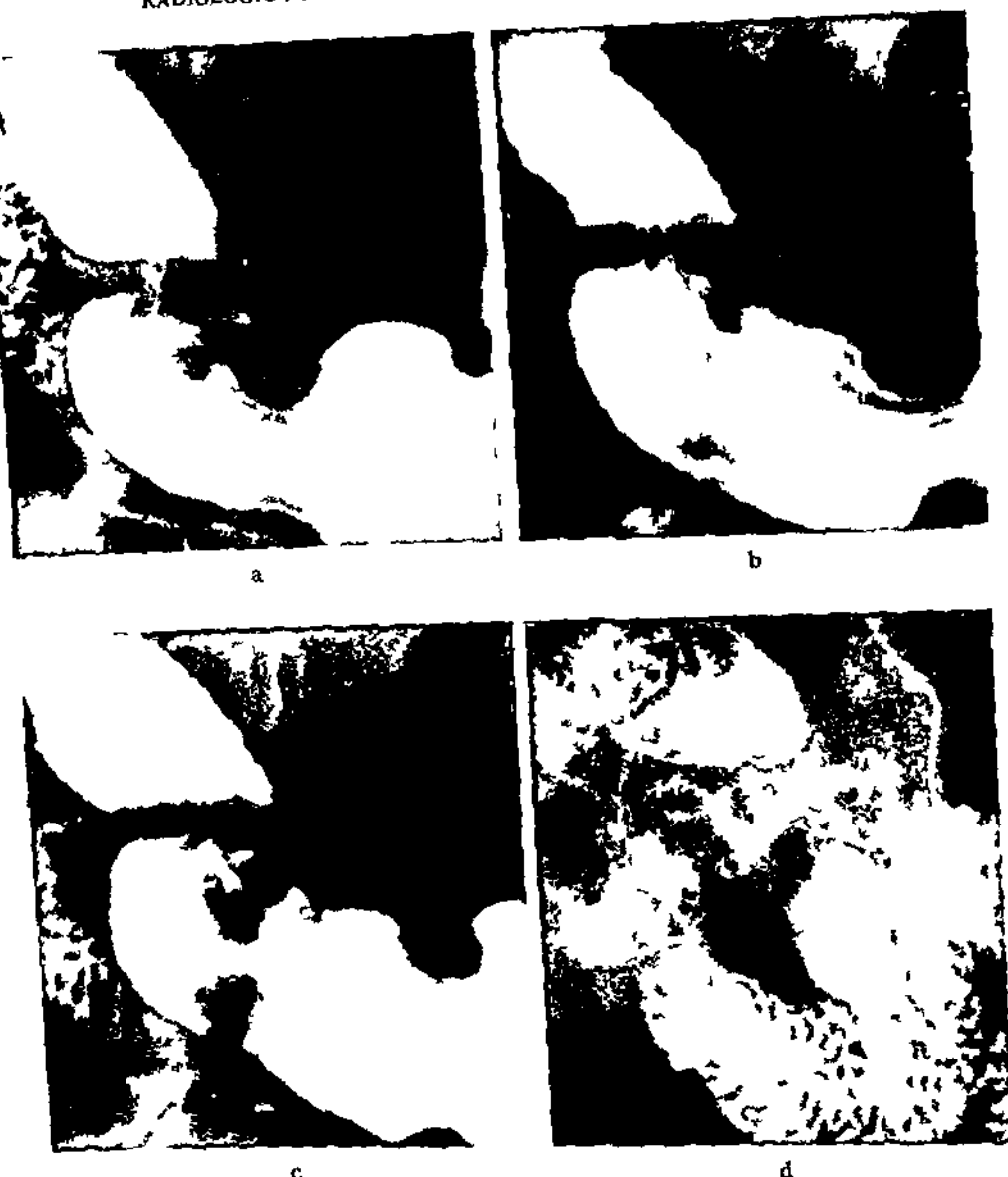


Fig 2 Large complete erosions a b c) Gradually increased pressure applied to the barium filled antrum d) Double contrast

been the most extensively used term However it must be noticed that in clinical pathologic or endoscopic terminology the term erosive gastritis sometimes includes superficial erosive gastritis or hemorrhagic erosive gastritis These latter types of erosive gastritis have superficial incomplete erosions which are not surrounded by an edematous or fibrotic elevation Such incomplete erosions cannot be detected at

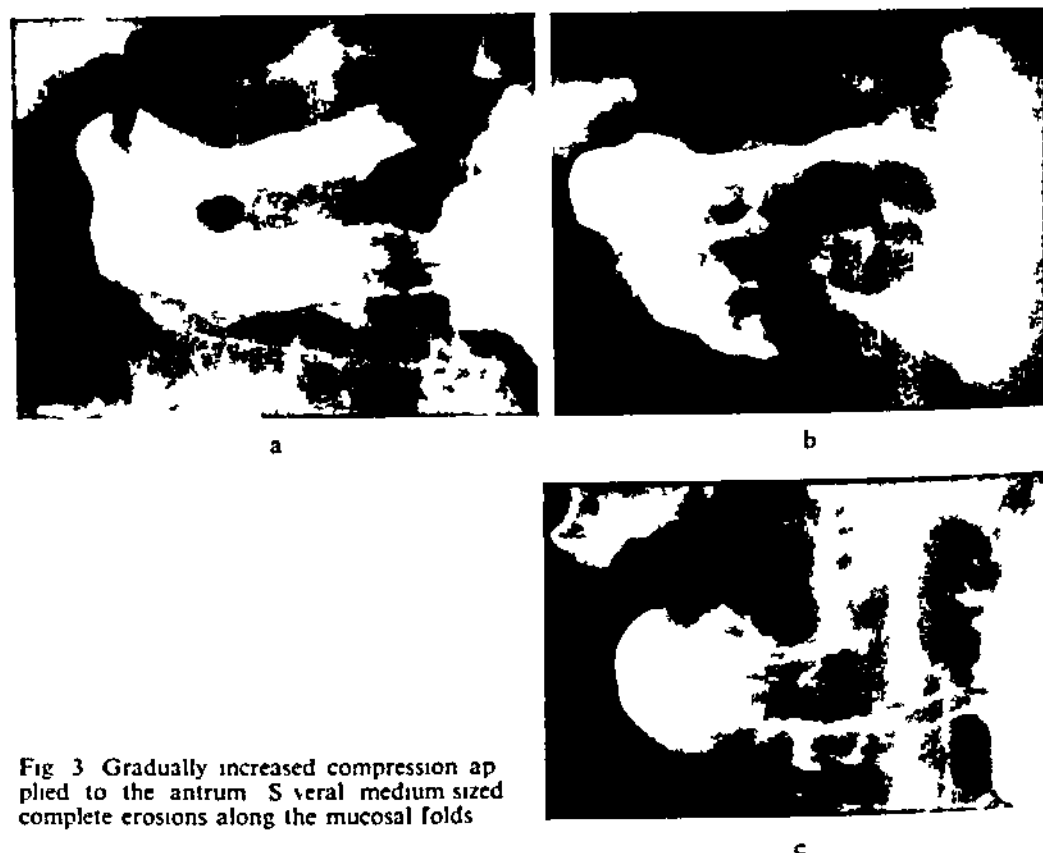


Fig 3 Gradually increased compression applied to the antrum Several medium sized complete erosions along the mucosal folds

radiology and therefore it is suggested to use the term complete gastric erosions only for the radiologic appearance described in the present report

At gastroscopy 58 patients (11 %) with complete gastric erosions were found In a Japanese gastroscopic material (KAWAI et coll 1970) complete gastric erosions were reported in 2 1 per cent ROESCH & OTTENJANN reported complete erosions in 2 7 per cent of their material The considerably higher frequency at gastroscopy now reported may be explained by an increased attention to these often discrete abnormalities possibly also to a more selective choice of patients for gastroscopy

At radiology of the stomach FRIK & HESSE found erosions in 0 5 per cent of cases the majority of these erosions representing complete erosions In the present material complete erosions were found in 25 patients (Table 1) representing 0 45 per cent of the stomach examinations performed at this department during 1975 This figure agrees well with that of FRIK & HESSE provided that their erosions represent complete erosions

Thus it may be concluded that complete gastric erosions are a common finding at gastroscopy and that this lesion is not infrequently detectable at radiology of the stomach




Fig 4 Small complete erosions along the mucosal folds a) In the corpus of the stomach b) In the duodenum No characteristic barium fleck

On re examining the films typical or possible complete erosions were found in 21 of the 33 patients examined less than one month before the gastroscopy (Table 1) but only in 4 of the 13 patients examined one to 3 months earlier The short duration these erosions may have is stressed by KAWAI et coll (1968) and SATA et coll (1971) and the lesions may sometimes disappear completely in a few days (ROESCH & OTTENJAMN) Possibly the present percentage of typical findings would have been furtherin creased with a shorter time span between radiology and gastroscopy

At first the edema surrounding the complete erosions is soft and comp essible but in a chronic phase the protrusion may have a fibrotic character Several authors (HENNING & SCHATZKI FRIK) have pointed out that it is essential when using a conventional radiographic method to apply a graded compression to the antrum to demonstrate the lesion Otherwise the elevated erosions may either be concealed by a thick barium layer or they may be flattened under excessive pressure (Figs 2 3) These difficulties are avoided if a double contrast technique is used This may explain why some authors (FRIK & HESSE POPLACK et coll) state that the double contrast method is superior to the conventional examination However the double contrast technique has drawbacks as well The amount of air i critical for the proper demonstration of the lesions and the anterior wall of the stomach is often less well demonstrated than the posterior wall At this department a double contrast method supplemented with a few compressed films over the barium filled antrum is used The complete erosions in most cases in this material were well demonstrated by both techniques The compressed films excellently demonstrate the lesions on the anterior wall of the antrum whereas the double contrast films better demonstrate erosions in the corpus of the stomach

The proper evaluation of the films is as important as the examination technique In the present material erosions were suggested in only 8 of the 25 patients which on the re-examination had abnormalities regarded as typical or possible complete





Fig 5 Fig 6

Fig 5 The central barium fleck appears in some of the complete erosions in the duodenum
Fig 6 Film of the appropriately compressed antrum discloses the central barium fleck differentiating the lesion from gastric polyps

erosions (Table 2) On the other hand only one examination with such findings was preliminarily reported as entirely negative (Table 2)

Gastric polyps were suggested in 6 patients (Table 2) The diameter of the complete erosions may sometimes considerably exceed one centimeter and these large erosions are particularly difficult to differentiate from gastric polyps (WALK 1972) A careful scrutiny of the appropriately compressed films may reveal the characteristic barium fleck indicating the true nature of the lesion (Fig 6) However leiomyomas and heterotopic pancreatic islands may present identical radiologic appearances including the central barium fleck In the corpus of the stomach or in the duodenum the barium fleck is more difficult to depict and sometimes it is not detected in spite of an optimum examination technique (Fig 4 b) In such cases the findings cannot be differentiated from polyps or enlarged Brunner s glands in the duodenum

Ulcers in the stomach or in the duodenum are often found together with complete erosions KAWAI et coll (1970) reported complete erosions coexistent with ulcers in the stomach in 31 per cent and with duodenal ulcers in 18 per cent In the present gastroscopic material the corresponding figures were 16 and 14 per cent respectively

Preliminarily stomach or duodenal ulcers were reported in 19 of the 46 radiographically examined patients (Table 2) Gastroscopy confirmed 13 of these ulcers In 2 patients large erosions were probably erroneously considered to be ulcers but often the presence of an ulcer seems to have caused that the simultaneous presence of abnormalities typical of complete erosions were overlooked These abnormalities were often minute and in 7 patients even a careful re examination of the films did not reveal any abnormality suggesting complete erosions (Table 2)

Large and irregular mucosal folds were stated in the preliminary report in 16 patients in 8 of these together with an ulcer On re examination of these films 4 patients were

found to have complete erosions The presence of the ulcer seems to have caused that the erosions were overlooked

Complete erosions often exist with ulcers but also when they are the only lesions they may be clinically significant Symptoms or signs similar to those of gastritis or ulcers have been connected with complete gastric erosions (FRIK KAWAI et coll 1970) Therefore it is important to recognize these lesions in patients with gastric symptoms particularly in the absence of ulcers

SUMMARY

At gastroscopy of 656 patients complete gastric erosions were found in 58 (11 %) Radiography performed in 46 of these demonstrated erosions in 21 of 33 with a time span less than one month between radiography and gastroscopy but in only 4 of 13 with a time span of one to 3 months Double contrast technique supplemented with films of compressed barium filled antrum demonstrate the lesions best Complete erosions have often appearances simulating gastric polyps or large mucosal folds and are often found together with ulcers

ZUSAMMENFASSUNG

Bei der Gastroskopie von 656 Patienten wurden komplette Magenerosionen bei 58 Patienten (11 %) gefunden Röntgenuntersuchung bei 46 dieser Patienten zeigte Erosionen bei 21 von 33 innerhalb eines Zeitverlaufs von weniger als einem Monat zwischen Röntgenuntersuchung und Gastroskopie aber nur bei 4 von 13 bei einem Zeitintervall von ein bis drei Monaten Die Doppelkontrasttechnik ergänzt mit Filmen des komprimierten barium gefüllten Antrums zeigten die Läsionen am besten Komplette Erosionen haben oft das Bild vorgetäuschter Magenpolypen oder grosser Magenschleimhautfalten und werden oft zusammen mit Ulcerationen gefunden

RESUME

La gastroscopie de 656 malades a montré des érosions gastriques complètes chez 58 malades (11 %) Les radiographies faites chez 46 de ces malades ont montré des érosions chez 21 malades sur 33 chez qui l intervalle entre la radiographie et la gastroscopie était inférieur à 1 mois mais chez seulement 4 des 13 malades chez qui cet intervalle de temps était de 1 à 3 mois C est la technique en double contraste complétée par des films en replétion barytée de l antre et avec compression qui montre le mieux les lésions Les érosions complètes ont souvent un aspect qui simule des polypes gastriques ou de gros plis muqueux et sont souvent associées avec des ulcères

REFERENCES

ABEL W Die Röntgendiagnose der Gastritis erosiva Fortschr Röntgenstr 80 (1954) 39

BERG H Grundlagen der Darstellung von Gastritis und Ulcus im Röntgenbild Med Klin 35 (1953) 1245

BUCKER J Zur Rontgendiagnostik der Gastritis erosiva Radiologe 4 (1964) 78
FRIK W Erosionen der Magenschleimhaut *In* Lehrbuch der Rontgendiagnostik Band V p 5 George Thieme Verlag Stuttgart 1955
— und HESSE R Die rontgenologische Darstellung von Magenerosionen Dtsch med Wschr 81 (1956) 1119
HENNING N und SCHATZKI R Gastrophotographisches und rontgenologisches Bild der Gastritis ulcerosa Fortschr Rontgenstr 48 (1933) 177
HUNT J H and ANDERSON I F Double contrast upper gastrointestinal studies Clin Radiol 27 (1976) 87
KAWAI K MISAKI F MURAKAMI K and MASUDA M The evolution of the erosion Gastroent Jap 1 (1968) 377
— SHIMAMOTO K MISAKI F MURAKAMI K and MASUDA M Erosions of gastric mucosa Pathogenesis incidence and classification of the erosive gastritis Endoscopy 3 (1970) 168
KONJETZNY G E *Die entzundliche Grundlage der typischen Geschwursbildung im* Magen und Duodenum Ergebnisse inn Med 37 (1930) 184
POPLACK W PAUL R E GOLDSMITH M MATSUE H MOORE J P and NORTON R Demonstration of erosive gastritis by the doublecontrast technique Radiology 117 (1975) 519
ROESCH W and OTTENJANN R Gastric erosions Endoscopy 2 (1970) 93
SATA H KONDO D TAKADA H and SAI S Endoscopic observations and bioptic findings of varioloform erosions of the stomach Stomach and Intest 11 (1971) 1148
WALK L Erosive gastritis Gastroenterologia 84 (1955) 87
— Polypous formations caused by gastric erosions Presented at 2nd European Congress of Gastrointestinal Endoscopy Paris 1972

FROM THE DEPARTMENT OF DIAGNOSTIC RADIOLOGY UNIVERSITY HOSPITAL, S-221 85 LUND
SWEDEN

PERCUTANEOUS TRANSHEPATIC PORTOGRAPHY

J HOEVELS A LUNDERQUIST and U TYLEN

The percutaneous transhepatic approach to the portal venous system and its main tributaries has proven to be an ideal method for selective demonstration of the large splanchnic veins the pancreatic veins the portal vein with its intrahepatic ramifications and the parenchyma of the liver Moreover hemodynamic parameters and collateral circulation in portal hypertension can be evaluated selectively Recently the same access was used for successful obliteration of esophageal varices (LUNDERQUIST & VANG 1974 GUNTHER et coll 1976 1977 RUSSELL et coll 1976 LUNDERQUIST et coll 1977) and localization of small hormone active tumors in the splanchnic organs (INGEMANSSON et coll 1975 1976 1977)

Following the first description by BIERMAN et coll (1952) and STEINBACH et coll (1953) using the ventral route percutaneous transhepatic portography was combined with direct measurement of the portal pressure in various lesions of the liver by NUNEZ et coll (1954) Decisive refinement of the technique towards selectivity was reported by WIECHEL (1971) who performed portography applying the same puncture site in the right midaxillary line that he described in 1964 for percutaneous transhepatic cholangiography BURCHARTH et coll (1974) localized the porta hepatis by ultrasonic scanning before percutaneous transhepatic portography in 31 of 32 patients WIDRICH et coll (1976) demonstrated the feasibility of percutaneous transhepatic portal phlebography for demonstrating portal and splanchnic venous anatomy as well as determining the hemodynamics following selective splenoportal shunt surgery with 24 successful selective examinations in a series comprising totally 31 cases At this department percutaneous transhepatic portography has been performed routinely since 1972 VIAMONTE et coll (1957) published a preliminary report based on experiences of 90 cases the majority of which were examined at this institution and RUSSELL et coll in a more extensive analysis stressed the im

Submitted for publication 7 February 1977

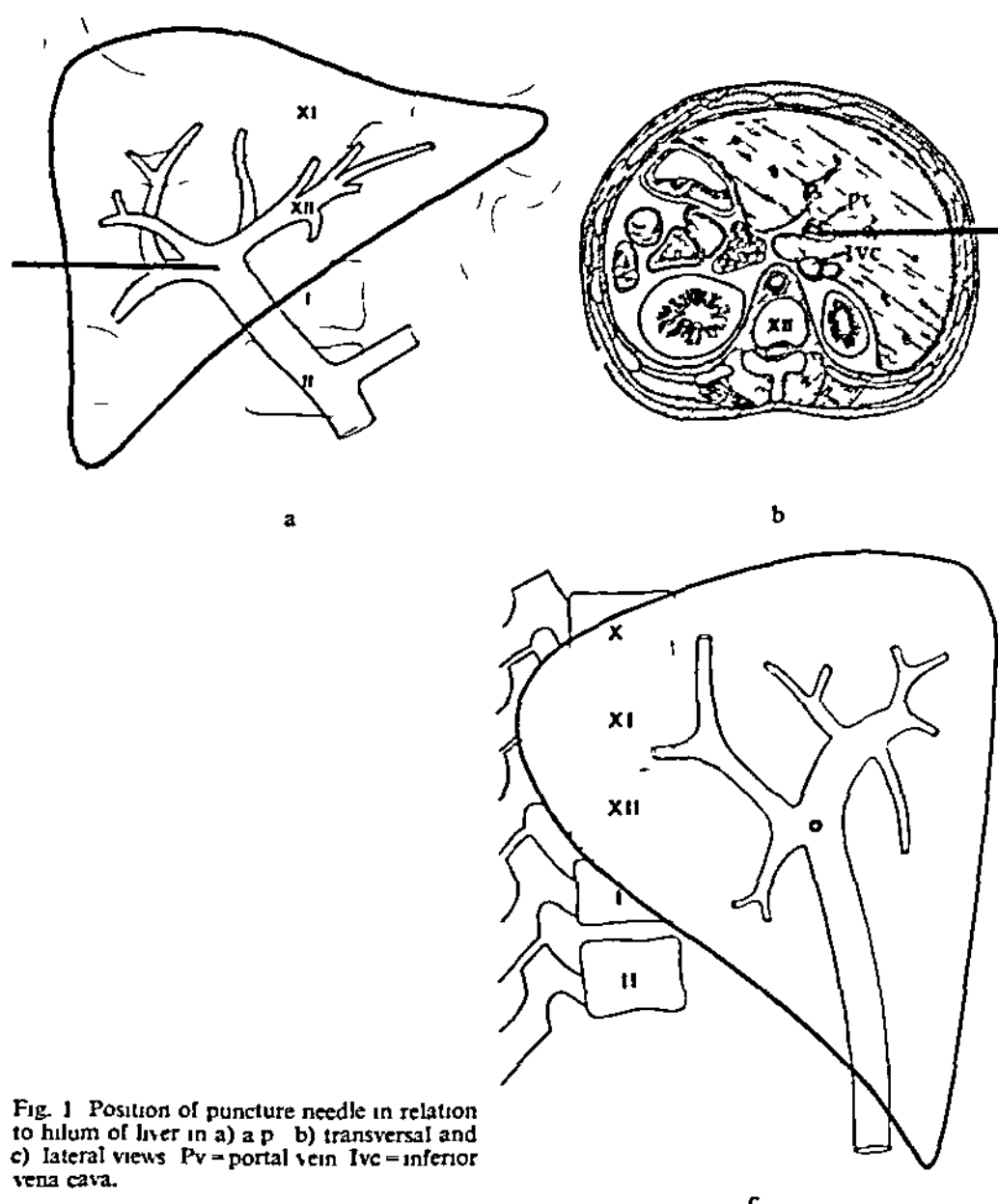


Fig. 1 Position of puncture needle in relation to hilum of liver in a) a p b) transversal and c) lateral views Pv = portal vein Ivc = inferior vena cava.

portance of percutaneous transhepatic cholangiography and portography in the examination of hepatobiliary diseases Because interest in this examination is increasing it may be of value to report the experiences gained at this department from 200 cases

Method

Guided by fluoroscopy and a survey film of the upper abdomen the approximate location of the hilum of the liver is estimated This is often facilitated by gas in the

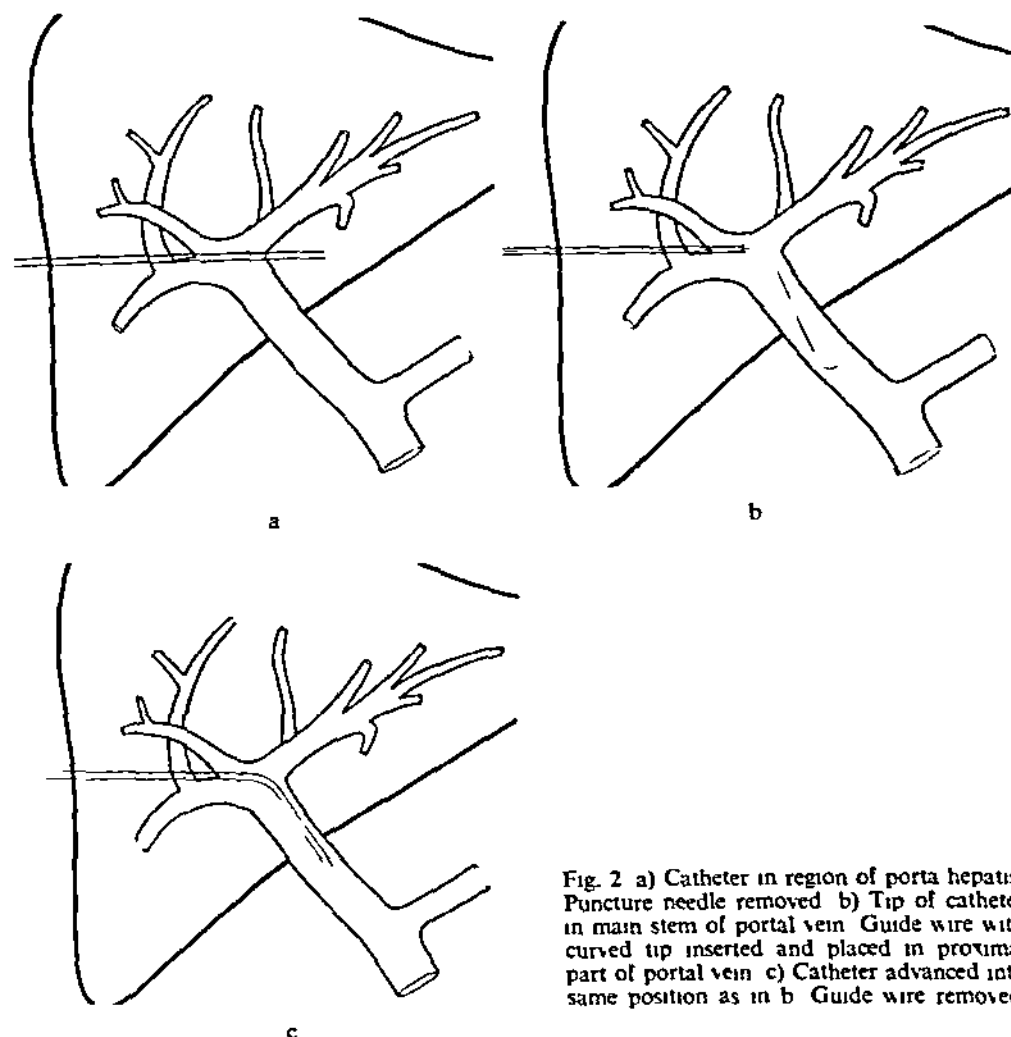


Fig. 2 a) Catheter in region of porta hepatis Puncture needle removed b) Tip of catheter in main stem of portal vein Guide wire with curved tip inserted and placed in proximal part of portal vein c) Catheter advanced into same position as in b Guide wire removed

duodenal bulb Interposition of the hepatic flexure of the colon between the liver and the abdominal wall is excluded by this means The examination is performed with the patient supine The puncture site is chosen in the right midaxillary line corresponding to the estimated level of the porta hepatis Local anesthesia is applied in the subcutaneous tissue the intercostal muscles near the intercostal nerve and the parietal peritoneum allowing the anesthesia needle to penetrate the liver capsule and enter its parenchyma about one centimeter Following penetration of the skin and intercostal muscles with a large bore needle the puncture is performed cranially to the lower rib of the chosen costal interspace thus preventing bleeding from the intercostal vessels A 25-cm long needle coated with a polyethylene catheter (ID/OD

1 60/1 0 mm) is used The needle may be allowed to pass through the pleural sinus but not through the lung The puncture is performed quickly and without interruption during fluoroscopy towards the estimated position of the hilum of the liver in a plane parallel to the table top (Fig 1) The puncture should not be deeper than the estimated location of the porta hepatis After reaching this point the needle is immediately withdrawn leaving the catheter in place (Fig 2 a) During this manoeuvre the patient is asked to hold his breath or if this is not possible to breathe gently After removal of the puncture needle the polyethylene cather is withdrawn slowly and stepwise until blood can be aspirated A 10 ml syringe filled with heparinized saline is connected to the catheter Easy aspiration of blood and easy flushing with saline indicate a satisfactory position of the tip of the catheter within the blood vessel To identify the position of the catheter and the nature of the punctured vessel a few milliliters of 60 per cent contrast medium is injected during fluoroscopy If the catheter is located within the main stem of the portal vein or the right portal vein branch a guide wire with a slightly curved soft tip (Fig 3 a) is advanced through the catheter until its tip reaches the spleno mesenteric junction (Fig 2 b c) If a portal vein branch is not found while the catheter is retracted from the central part of the liver the original puncture needle is reinserted before the catheter has passed out from the liver parenchyma and a new puncture is performed directing the needle towards the hilum of the liver Thus additional puncture holes of the capsule of the liver are avoided and the risk of bleeding into the abdominal cavity is reduced The reinsertion of the needle must be performed with great care to avoid perforation of the wall of the catheter The needle can be reinserted even if the catheter is kinked between the abdominal wall and the liver by asking the patient to hold his breath in a position straightening the course of the catheter The number of puncture attempts should not be rigidly limited In strong indication the benefit of this examination in terms of valuable diagnostic information and therapeutic possibilities (in bleeding esophageal varices) should encourage proceeding with the examination Puncture of the more ventrally located left branch of the portal vein or its sub branch makes selective catheterization of the mesenteric veins pancreatic veins and left and short gastric *veins more difficult Therefore catheterization of the main left branch* of the portal veins should be avoided and instead repuncture in a more dorsal direction should be attempted in order to find a right portal vein branch Even puncture of a second or third order sub branch often allows successful catheterization of the main stem of the portal vein but the catheterization procedure in such a case may be more difficult If the first guide wire cannot pass through the portal vein branch a J guide wire with the core pulled out a few centimeters will sometimes enter the portal vein branch even if this is punctured perpendicularly to its course When the guide wire has entered a larger branch of the portal venous system the catheter is advanced over it into a stable position The floppy J guide wire is then exchanged for the first used slightly bent guide wire with a soft tip which usually can be manipulated into the main stem of the portal vein The catheter is then pushed over it into the same posi

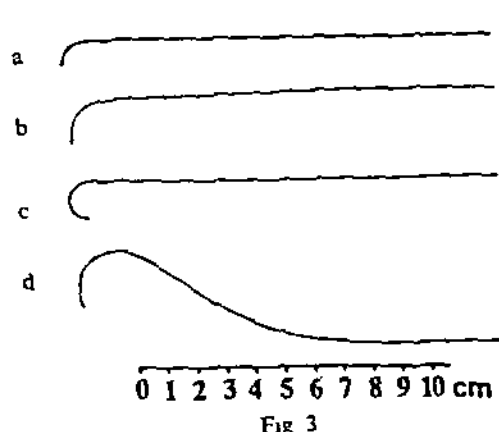


Fig 3

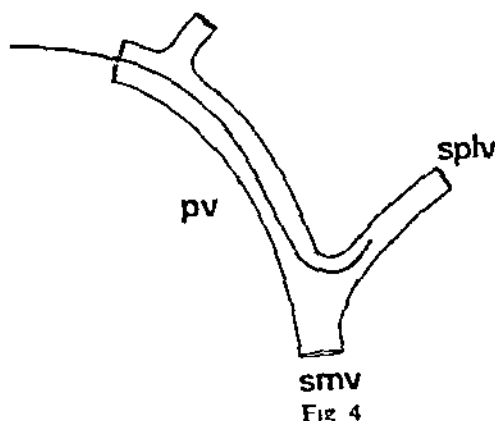


Fig 4

Fig 3 Different shapes of guide wire may facilitate catheterization of portal venous system and its tributaries a) 0 9 mm guide wire with slightly bent soft tip b) 0 9 mm guide wire with somewhat more curved tip c) 0 9 mm J guide wire with 12 mm curve and movable core d) 0 9 mm guide wire with markedly curved tip and slight bending of proximal 10–15 cm to facilitate catheterization of splenic vein when joining portal vein at acute angle

Fig 4 Guide wire illustrated in Fig 3 d in portal vein and splenic vein Pv = portal vein Splv = splenic vein Smv = superior mesenteric vein

tion Although catheterization of the main stem of the portal v in is possible by passing several sub-branches it is often wise to p rform another puncture towards the hilum in order to find the right branch or the main st m of the portal vein

The presence of ascites is no contraindication In such a case s l ctive catheteriza tion of the portal vein and its various tributaries must be performed cautiously to prevent kinking of the catheter between the liver and the abdominal wall For s lective examinations of the superior and inferior mesenteric veins including their branches a longer catheter than the initial one coating the puncture needle may be necessary Depending on the individual anatomy s lective examination of the left gastric vein the splenic vein and the pancreatic veins requires a longer catheter After inserting a guide wire with a curved tip the original catheter is removed and replaced by a longer catheter of the same diameter During this procedure the patient is asked to breathe slowly to avoid kinking of the guide wire b tween the lateral abdominal wall and the surface of the liver

The choice of guide wire is of great importance in the performance of selective catheterization of branches of the portal vein as well as its tributaries The best type seems to be a straight 0 9 mm guide wire with a soft tip which can be shaped by hand Different shapes of guide wires may be chosen depending on the anatomy and the entrance site of the catheter in the portal venous system (Figs 3 4) Before guiding a catheter selectively into any small vein injection of contrast medium for demon strating the portal vein and its main tributaries is mandatory to identify the specific topographic anatomy By rotating the coiled part of the guide wire outside the patient



Fig 5 A p view *Tip of catheter in main stem* of portal vein a) Normal distribution of portal ramification b) Normal parenchymal phase




Fig 6 Selective catheterization of left branch of portal vein A p view Normal distribution of portal vein branches

the tip of the guide wire preshaped as described can be manoeuvred even into very small pancreatic veins and the catheter advanced into the desired position

When the parenchyma of the liver is to be evaluated the tip of the catheter is placed in the proximal part of the main stem of the portal vein With the patient in the supine and right posterior position two series (5 films/5 s 8 films/4 s 3 films/6 s 40 ml contrast medium 370 mg I/ml flow rate 8 ml/s) with vertical beam are taken (Fig 5) To achieve an adequate filling of the portal venous system of the left liver lobe one series may be exposed with the patient in prone position However optimum demonstration of the left liver lobe is achieved by selective catheterization of the left branch of the portal vein (Fig 6) Because of the acute bending when branching off from the main stem of the portal vein selective catheterization of the left branch must be performed cautiously The tip of the catheter should not be directed against the wall of the vessel if a subintimal deposition of contrast medium is to be avoided Lateral views of the portal vein (Fig 7) are essential when expanding lesions of the porta hepatis or left liver lobe are present



a



b


Fig 7 Anomalous portal ramification a) A p view Common origin of branches to left lobe and ventro-cranial segment of right lobe b) Lateral view




Fig 8

Fig 8 Portal hypertension Tip of catheter in lateral part of splenic vein Contrast filling of esophageal varices via gastric coronary vein

When the portal venous system is examined in patients with portal hypertension *the tip of the catheter must be placed in the lateral part of the splenic vein to allow* evaluation of the blood flow to the various venous collaterals (8 films/8 s 8 films/16 s 40 ml of contrast medium 370 mg I/ml flow rate 8 ml/s) (Fig 8) The inferior mesenteric vein and branches of the superior mesenteric vein are examined in the search for hormone producing intestinal tumors combined with selective blood sampling for radioimmunoassay Pancreatic veins and branches of the mesenteric veins are filled by manual injection



a



b

Fig 9 Selective catheterization of vein draining a) head and b) tail of pancreas. Normal appearances

When the examination is finished and the catheter is withdrawn a small piece of gelfoam is injected through the catheter into the parenchyma of the liver b neath the surface of the liver to avoid bleeding This must be performed cautiously to prevent the gelfoam from passing through the puncture canal into the portal vein branch It is best accomplished by placing the piece of gelfoam at the tip of a 2 ml syringe filled with contrast medium The gelfoam particle is injected through the catheter and is seen during fluoroscopy approaching its tip When the gelfoam is about 2 to 3 cm from the tip of the catheter a guide wire is introduced and used to push it out of the catheter into the parenchyma of the liver

Material

The series comprised 200 examinations in 170 patients 95 men and 75 women ranging from 28 to 83 years of age The indications for percutaneous transhepatic portography appear in Table 1

Table 1

Indications for percutaneous transhepatic portography

Indication	No of cases
Cirrhosis portal hypertension esophageal varices	105
Possible liver metastases and malignancies adjacent to porta hepatis	79
Hormone active tumor in splanchnic area	16

* In 65 pancreatic phlebography was performed in addition because of possible tumor of pancreas

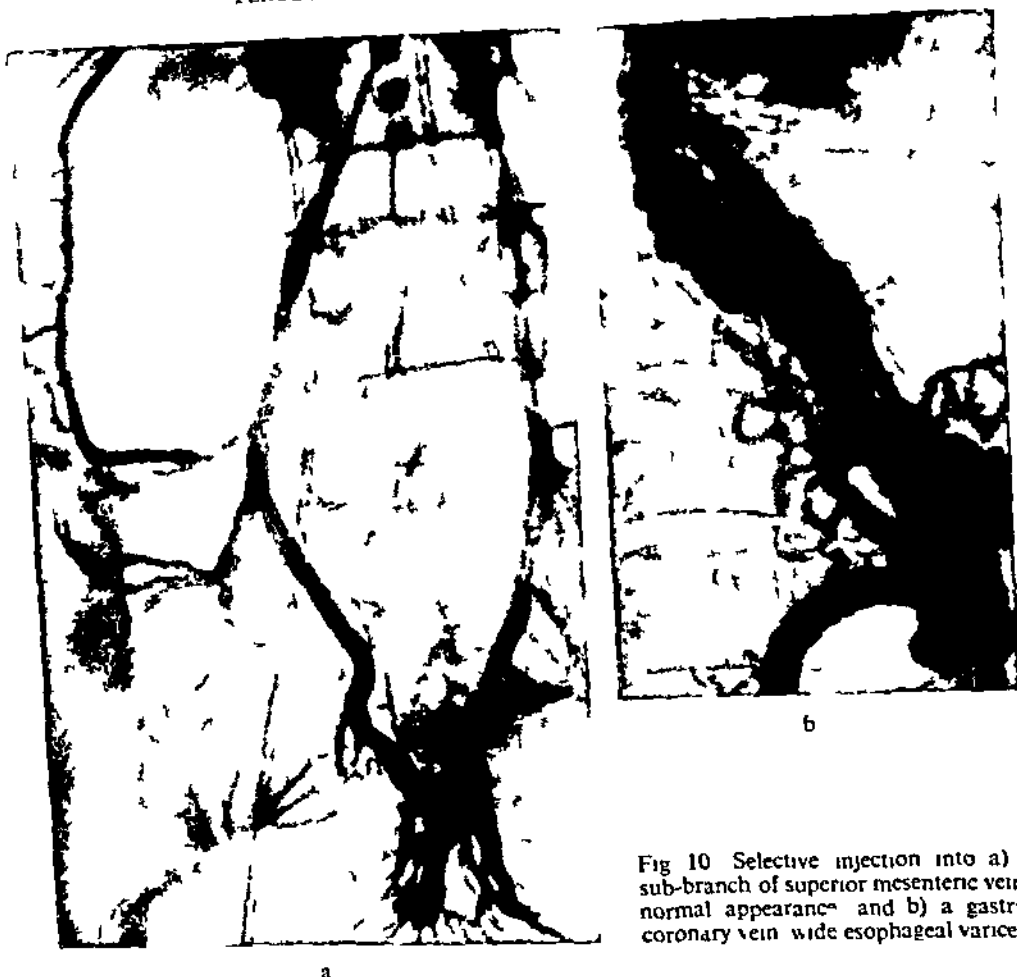


Fig 10 Selective injection into a) a sub-branch of superior mesenteric vein normal appearance and b) a gastric coronary vein wide esophageal varices

Results

Puncture and catheterization of the portal venous system was successful in 197 examinations Selective catheterization of the veins draining the head of the pancreas (Fig 9 a) was performed in 55 cases and in 10 cases veins of the body and the tail of the pancreas were catheterized (Fig 9 b) Blood sampling from branches of the superior (Fig 10 a) and inferior mesenteric veins because of possible hormone active tumors located in the bowel and the mesentery was performed in 16 cases The main indications for percutaneous transhepatic portography however were portal hyper tension in cirrhosis of the liver (Figs 8 10 b) and possible metastases or primary tumor of the liver adjacent to the porta hepatis

Complications Serious complications occurred in 4 cases due to intraperitoneal bleeding and in 2 cases due to bile leakage into the abdominal cavity after accidental

puncture of the gallbladder Blood transfusion or emergency operation was p r formed in totally 3 cases No fatal outcome occurred A detailed account of the complications in connection with p*rcutaneous transhepatic portography will be the subject of a s*parate report

Discussion

During the past 25 years various techniques have been develop d to demonstrate the portal venous system Step by step the methods have been refined and by now there are 3 selective approaches to the portal vein and its ramifications and to the major and minor splanchnic veins GONZALEZ CARBALHAES (1959) introduced portography via the umbilical vein and predicted in his preliminary report the application of this method in the diagnosis of pathology of both the liver the portal system and organs drained by it including pressure measurements chemical and enzymatic determination of prehepatic blood and introduction of chemotherap utic ag nts in malignant tumors of the liver as well In recent years numerous authors (BOLLAERT et coll 1970 MATEEV 1972 GÖTHLIN et coll 1974 1975 MATEEV & WIRBATZ 1976) have contributed to solving the technical problems and have furth*r analysed the application diagnostic value and complications of transumbilical cath*t rization of the portal vein WIECHEL et coll (1974) develop*d a techniqu for ins rting multiple catheters into the portal venous system through the reopened umbilical vein in local anesthesia This method among others allows simultaneous determination of portal venous and hepatic arterial blood flow in both hepatic lobes in patients with pre hepatic portocaval shunting of blood

RÖSCH et coll (1969) described the transjugular transvenous approach to the portal venous system and selective c theterization of its tributaries in animals and regarded the method as ready for clinical use (RÖSCH & DOTTER 1975 RÖSCH et coll 1975 a b) GOLDMAN et coll have recently published the results of selective catheterization and sclerosing of esophag*al varic*s by transjugular approach to the portal venous system

The percutaneous transhepatic access to the portal vein was inaugurated by BIERMAN et coll (1952) by direct puncture from the epigastrium Not until WIECHEL et coll used the lateral approach in the right axillary line and applied the catheter technique did this method become applicable for selective examinations Nevertheless percutaneous transhepatic portography has not yet gained widespread acceptance although its complication rate is low (in the present material 3 per cent) Sel ctive catheterization of the veins draining the body and the tail of the pancreas and smaller branches of the superior and inferior mesenteric veins is facilitated as the guide wire and the catheter can be manoeuvred over a relatively short distance as compared with the transjugular approach Tr nsumbilical portography implies minor surgery and increased radiation of the hands of the examiner in comparison with the transjugular and percutaneous transhepatic approaches Additionally acute bending of the catheter at the junction of the umbilical vein and the left main portal branch and

Table 2

Advantages and drawbacks of the different techniques

Access to the portal venous system and its tributaries	Advantage	Drawback
Percutaneous transhepatic	Easy puncture Easy selective catheterization	Risk of intraperitoneal bleeding Risk of bile leakage
Transjugular transhepatic	Low complication rate	Difficult puncture Difficult catheterization of small visceral branches
Transumbilical	Low complication rate	Surgical procedure High radiation dose to the hands of the examiner Complicated catheterization of visceral branches

at the origin of the left main branch from the portal vein renders selective catheterization of the portal tributaries more difficult These problems do not exist in percutaneous transhepatic portography which therefore is regarded as superior to the transjugular and transumbilical approaches However the method implies certain risks of serious complications such as bleeding into the abdominal cavity and bile leakage (2 and one per cent respectively in the present material) A comparison of advantages and drawbacks of the 3 different approaches to the portal venous system is summarized in Table 2

Contraindications In possible occlusion of the portal vein and its main tributaries percutaneous transhepatic portography is contraindicated Arterial portography should therefore always be performed before the transhepatic procedure to rule out portal vein thrombosis Percutaneous transhepatic portography should not be performed in patients with a platelet count below 50000/mm³ as these patients represent a high risk of bleeding into the abdominal cavity during and after the examination If this examination is strongly indicated despite low platelet count fresh blood transfusion or infusion of platelet concentrate is to be recommended

SUMMARY

The technique indications contraindications and complications of percutaneous transhepatic portography and selective catheterization of the major and minor veins draining the splanchnic organs based on the experience of 200 cases are described The advantage of this method is discussed and compared with transjugular and transumbilical portography

ZUSAMMENFASSUNG

Technik Indikationen Kontraindikationen und Komplikationen der perkutanen trans hepatischen Portographie und der selektiven Katheteruntersuchung der grossen und kleinen Venen des Splanchnikusgebietes werden anhand der Erfahrungen beschrieben die bei 200 Untersuchungen gesammelt wurden Die Vorteile dieser Methode gegenuber der transjugularen und transumbilikalen Portographie werden diskutiert

RESUMÉ

Les aut urs décrivent sur la base de 200 cas la technique les indications les contre indications et les complications de la portographie transhépatique percutanee et du catheter isme sel ctif des veines principales et accessoires drainant les organes splanchniques L avan tage de c tt- métode est étudie et comparé avec la portographie transjugulaire et trans ombilicale

REFERENCES

BIERMAN H R STEINBACH H L WHITE L P and KELLY K H Portal vein puncture A percutaneous transhepatic approach Proc Soc exp Biol 79 (1952) 550

BOLLAERT A LAMBILIOTTE J P DAGNELIE J et PECTOR J C L hépatographie transombilicale J belge Radiol 53 (1970) 266

BURCHARTH F and RASMUSSEN S N Localization of the porta hepatis by ultrasonic scanning prior to percutaneous transhepatic portography Brit J Radiol 47 (1974) 598

GOLDMAN M L FAJMAN W and GALAMBOS J Transjugular obliteration of the gastric coronary vein Radiology 118 (1976) 453

GONZALEZ CARBALHAES O Hepatoportografia por via umbilical (In Spanish) Rev Sanid milit (Méx) 42 (1959) 42

— Portography A preliminary report of a new technique via the umbilical vein Clin Proc Child Hosp (Wash) 15 (1959) 120

GOTHLIN J LUNDERQUIST A and TYLÉN U Selective phlebography of the pancreas Acta radiol Diagnosis 15 (1974) 474

— DENCKER H and TRANBERG K G Technique and complications of transumbilical catheterization of the portal vein and its tributaries Radiology 125 (1975) 431

GUNTHER R GEORGI M KURTENBACH P BRUNNER H und SCHMIDT H D Perkutane transhepatische Pfortadersondierung mit Verodung blutender Ösophagusvarizen Dtsch med Wschr 41 (1976) 1491

— KURTENBACH P GEORGI M SCHMIDT H D und FARAK U Perkutane transhepatische Thrombosierung der Vena coronaria ventriculi bei Ösophagusvarizenblutung Fortschr Rontgenstr 126 (1977) 6

INGEMANSSON S LUNDERQUIST A and HOLST J Selective catheterization of pancreatic veins for radioimmunoassay in glucagon secreting carcinoma of pancreas Radiology 119 (1976) 555

— HOLST J LARSSON L I and LUNDERQUIST A Localization of glucagonomas by pancreatic vein catheterization and glucagon assay To be published in Surg Gynec Obstet

— LARSSON L I LUNDERQUIST A and STADIL F Pancreatic vein catheterization with gastrin assay in patients with the Zollinger Ellison syndrome To be published in Amer J Surg

— LUNDERQUIST A LUNDQUIST I LOVDAHL R and TIBBLIN S Portal and pancreatic vein catheterization with radioimmunologic determination of insulin Surg Gynec Obstet 141 (1975) 705

— KUHL C LARSSON L I LUNDERQUIST A and NOBIN A Isl t c ll hyperplasia localized by pancreatic vein catheterization and insulin radioimmunoassay To be published in Amer J Surg 133 (1977) 643
— BENGMARK S LARSSON L I LUNDERQUIST A and NILSSON G Aortal caval and in testinal vein catheterization with substance P determination in patients with carcinoid tumours To be published in Ann Surg
LUNDERQUIST A and VANG J Transhepatic catheterization and obliteration of the coronary vein in patients with portal hypertension and esophageal varices New Engl J Med 291 (1974) 646
— — Sclerosing injection of esophageal varices through transhepatic selective catheterization of the gastric coronary vein A preliminary report Acta radiol Diagnosis 15 (1974) 546
— SIMERT G TYLÉN U and VANG J Follow up of patients with portal hypertension and esophageal varices treated with percutaneous obliteration of gastric coronary vein Radiology 122 (1977) 59
MATEEV B Portohepatographie zur Tumordiagnostik der Leber Rontgenanatomische Untersuchungen zur Verbesserung der Methode Inaug Diss Humboldt Universitat Berlin 1972
— und WIRBATZ W Transumbilicale Portohepatographie *In* Encyclopedia of Medical Radiology Vol XII Part I (1976) 215
NUÑEZ V B REGUERA M E PIRE A GUILARTE R S y GARCES S R Hepatografia y hepatomanometría (In Spanish) Rev cuba Gastroent 3 (1954) 258
ROSCH J and DOTTER CH T Retrograde pancreatic venography An experimental study Radiology 114 (1975) 275
— ANTONOVIC R and DOTTER CH T (a) Transjugular approach to the liver biliary system and portal circulation Amer J Roentgenol 125 (1975) 602
— GOLDMAN M L and DOTTER CH T (b) Experimental catheter obstruction of the gastric coronary vein Possible technique for percutaneous intravascular tamponade of the gastroesophageal varices Invest Radiol 10 (1975) 206
— HANAFEE W N and SNOW H Transjugular portal venography and radiologic portocaval shunt An experimental study Radiology 92 (1969) 1112
RUSSELL F LE PAGE J R VIAMONTE M JR LEVI J U and MEIER W L An angiographic approach to hepatobiliary diseases Surg Gynec Obstet 143 (1976) 414
STEINBACH H L BIERMAN H D MILLER E R and WASS W A Percutaneous transhepatic portal venography A preliminary report Radiology 60 (1953) 368
VIAMONTE M JR LE PAGE J LUNDERQUIST A PEREIRAS R RUSSELL E VIAMONTE M and CAMACHO M S lective catheterization of the portal vein and its tributari s Preliminary report Radiology 114 (1975) 457
WIDRICH W C ROBBINS A H NABSETH D C O HARA E T JOHNSSON W C and LOUGH LIN K V Portal hyp rtension changes following selective splenorenal shunt surgery Radiology 121 (1976) 295
WIECHEL K L Percutaneous transhepatic cholangiography Acta chir scand (1964) Suppl No 330
— Tekniken vid perkutan transhepatisk portapunktion (PTP) (In Swedish) Nord Med 86 (1971 b) 912
— KULLING K G MARIONS O ERWALD R and LINDBERG K Direkt portografi (In Swedish) Nord Med 86 (1971) 1255
— ERWALD R KULLING K G LUNDBERGH P MARIONS O and STRANDELL T Technique for simultaneous catheterization of different parts of the portal vein Acta med scand 191 (1972) 137
— — — — — — Multiple catheterization technique of the portal venous system for regional blood flow studies Surg Gynec Obstet 138 (1974) 406

ZUSAMMENFASSUNG

Technik Indikationen Kontraindikationen und Komplikationen der perkutanen transhepatischen Portographie und der selektiven Katheteruntersuchung der grossen und kleinen Venen des Splanchnikusgebietes werden anhand der Erfahrungen beschrieben die bei 200 Untersuchungen gesammelt wurden Die Vorteile dieser Methode gegenuber der transjugularen und transumbilikalen Portographie werden diskutiert

RESUME

Les aut urs decrivent sur la base de 200 cas la technique les indications les contre indications et les complications de la portographie transhépatique percutanée et du cathéter isme sel ctif des veines principales et accessoires drainant les organes splanchniques L avan tage de c tte métode est etudie et compare avec la portographie transjugulaire et trans ombilicale

REFERENCES

Bierman H R Steinbach H L White L P and Kelly K H Portal vein puncture A p rcutaneous transhepatic approach Proc Soc exp Biol 79 (1952) 550

Bollaert A Lambilliotte J P Dagnelie J et Pector J C L hépatographie transombilicale J belge Radiol 53 (1970) 266

Burcharth F and Rasmussen S N Localization of the porta hepatis by ultrasonic scanning prior to percutaneous transhepatic portography Brit J Radiol 47 (1974) 598

Goldman M L Fajman W and Galambos J Transjugular obliteration of the gastric coronary vein Radiology 118 (1976) 453

Gonzalez Carbalhaes O Hepatoportografia por via umbilical (In Spanish) Rev Sanid milit (Mex) 42 (1959) 42

— Portography A preliminary report of a new technique via the umbilical vein Clin Proc Child Hosp (Wash) 15 (1959) 120

Gothlin J Lunderquist A and Tylén U Selective phlebography of the pancreas Acta radiol Diagnosis 15 (1974) 474

— Dencker H and Tranberg K G Technique and complications of transumbilical *catheterization of the portal vein and its tributaries Radiology 125 (1975)* 431

Gunther R Georgi M Kurtenbach P Brünner H und Schmidt H D Perkutane transhepatische Pfortadersondierung mit Verodung blutender Ösophagusvarizen Dtsch med Wschr 41 (1976) 1491

— Kurtenbach P Georgi M Schmidt H D und Farak U Perkutane transhepatische Thrombosierung der Vena coronaria ventriculi bei Ösophagusvarizenblutung Fortschr Rontgenstr 126 (1977) 6

Ingemansson S Lunderquist A and Holst J Selective catheterization of pancreatic veins for radioimmunoassay in glucagon-secreting carcinoma of pancreas Radiology 119 (1976) 555

— Holst J Larsson L I and Lunderquist A Localization of glucagonomas by pancreatic vein catheterization and glucagon assay To be published in Surg *Gynec Obstet*

— Larsson L I Lunderquist A and Stadil F Pancreatic vein catheterization with gastrin assay in patients with the Zollinger Ellison syndrome To be published in Amer J Surg.

— Lunderquist A Lunderquist I Lovdahl R and Tibblin S Portal and pancreatic vein catheterization with radioimmunologic determination of insulin Surg Gynec Obstet 141 (1975) 705

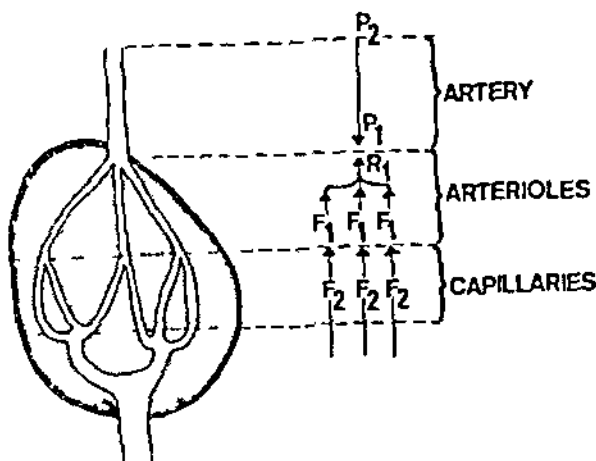


Fig 1 Diagram of an end arterial system in an organ with a non scalar vector diagram showing the sites of action of the various factors involved in its injection

possible to differentiate between arterioles and venules on the films Since Micropaque cannot cross the normal capillary bed it must be presumed that venous filling occurs via arterio venous anastomoses or abnormal capillaries These arterio venous fistulas will offer a line of less resistance than some arterioles which will therefore be by passed

The failure of contrast medium to enter all the arteries and arterioles has been called technical avascularity by SEVITT who used a microangiographic technique Even using the supernatant from a 7 4 % suspension of Micropaque injected for many hours into the renal artery LJUNGQVIST (1963) found on microscopy of the kidney that not every artery had been injected Technical avascularity complicates the evaluation of the films because the number size and distribution of unfilled arteries cannot be assessed radiographically

The ideal microarteriographic injection may not be attainable in human material However an injection technique which results consistently in the demonstration of a known high proportion of arteries and arterioles will provide information which can be statistically analysed

An injection technique has been developed on theoretical principles to achieve maximum arteriolar filling without venous filling in the highly anastomotic arterial system of the human lumbar vertebrae The results from this technique are compared histologically with result obtained using a previously described technique

Theoretical principles

A simplified model of an organ supplied by one artery such as the kidney is illustrated in Fig 1 An injection of contrast medium is made at a pressure P The pressure at the periphery of the organ P_1 is less than P P_1 may be called the effective pressure of injection

There is a resistance to the injection of an artery or an arteriole which is the sum of two separate resistances to flow F_1 and F_2 F_1 is the resistance to the flow of

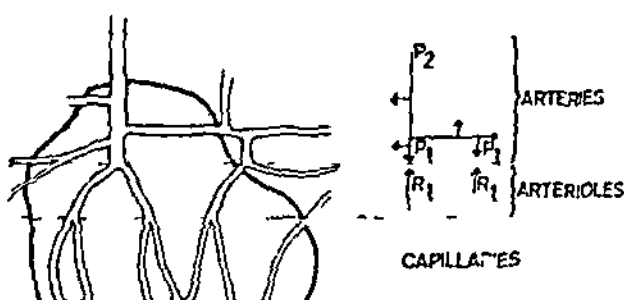


Fig 2 Diagram of an anastomotic arterial system in an organ which has been excised with a small vector diagram of some of the factors involved in its injection

contrast medium within the vessel itself and is a function of the apparent viscosity of the medium and the surface area of vessel injected F is the resistance to flow of the blood or serum which is to be displaced by the medium through the capillaries into the venous side In order to inject a single vessel the pressure at the mouth of the vessel must be greater than the sum of F_1 and F_2 The total resistance to injection R_1 in the system can be derived from the formula

$$\frac{1}{R_1} = \sum \frac{1}{F_1 + F_2}$$

In order to fill all the arteries and arterioles in this organ the effective pressure of injection P_1 must be greater than the total resistance to injection R_1 This is a dynamic state and flow will continue until a new resistance is created

The particles of Micropaque flow through the arteriole into capillaries where they impact This impaction gives origin to a new resistance to flow F_3 the maximum value of which is equal to the rupturing pressure of the capillary The development of the new resistance to flow F_3 raises the total resistance to injection to a higher level R This resistance increases proportionately to any increase in the effective pressure of injection until capillary rupture occurs Thus flow in the arteries and arterioles is halted and the pressures within the arterial system become equilibrated for any actual pressure of injection P_2 which equilibrates at an intracapillary pressure less than F_3 max This is a static state

The actual pressure of injection P_2 and the effective pressure of injection P_1 will be approximately equal and should not exceed the physiologic blood pressure because there will be no arteriolar tone to protect the capillaries from rupture The apparent viscosity of Micropaque is immaterial providing that it does not raise F_1 so high that the sum of $F_1 + F_2$ exceeds P_1 Efflux from veins is permitted so that F_2 is not raised also

In the anastomotic arterial system the anastomotic outflow branches complicate the process of injection because these will have a larger diameter and therefore a

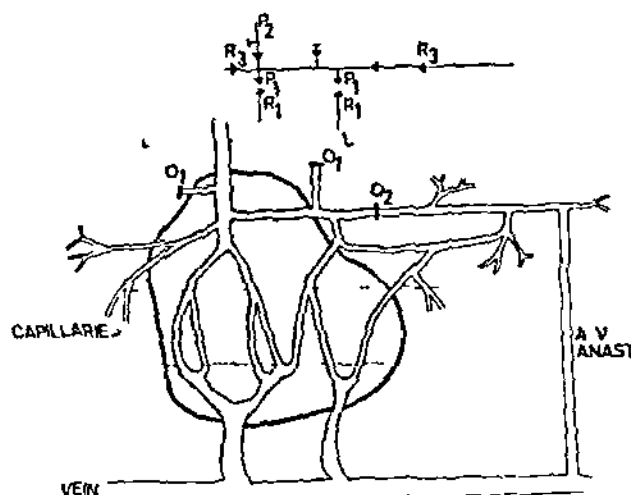


Fig 3 Diagram of an anastomotic arterial system in an organ similar to that illustrated in Fig 2 but which has not been excised with a vector diagram O_1 represents obstruction by ligature to leaking arteries O_2 represents obstruction by ligature in continuity of major out flow anastomotic arteries L to the left is shorter than L to the right becaus the vessel diameters on the left are narrower and thus R_3 (resistance to out flow) is greater in a shorter distance L must always be less than the distance to arteriovenous anastomoses (A V anastomoses)

lower resistance to flow Micropaque will by pass the small arterioles of the organ which in most organs will form an end arterial system distal to the anastomotic branches Such a system is illustrated diagrammatically in Fig 2 In this system the location of the effective pressure of injection P_1 is in the depths of the organ at the junction of the most distal anastomotic branch The problem is to equilibrate P_1 at this site with the actual pressure of injection and at a value which exceeds R_1

In the excised organ all the divided anastomotic arteries might be ligatured or obstructed by compression This would result in satisfactory equilibration producing good arteriolar filling and is the basis of a previously described technique for the injection of excised parts of gut (MARGULIS 1964)

In practice it is impossible to ligature all the anastomotic arteries many of which are of arteriolar size It is also impossible to compress the periphery of the cut tissues to obstruct the arterial anastomoses without also obstructing the venous efflux This results in raising F_2 and arteriolar filling will be *irregular*

If the arterial anastomotic channels were of infinite length a resistance to flow within them would develop at a distance L from the site of injection which would *equal the* pressure of injection The resistance to outflow along the anastomotic channels R_3 will be greater than R_1 and will thus raise P_1 within the organ so that P_1 is greater than R_1 Because of the anastomoses within or surrounding the organ P_1 will be uniform throughout the organ and therefore arteriolar filling within the organ will be uniform

Arterial anastomoses are not of infinite length and a simplified model of a practical anastomotic system is illustrated in Fig 3 The distance L may be reduced to practical lengths by the use of Micropaque of relatively high apparent viscosity The distance L may be greatly reduced by the selective ligature of all the larger ana tomotic arteries permitting only the narrower anastomotic arteries to fill to create R_3 The distance L is subject to individual variation and cannot be

predicted The organ must be injected while surrounded by a large block of tissue The apparent viscosity of the Micropaque must not be so high that F_1 will exceed $P_1 - I$ Injection of a 50% suspension of Micropaque has resulted in good arteriolar filling (BROOKES & HARRISON 1957)

If arterio venous anastomoses exist in the organ or close to it at a distance less than L flow will occur into the venous side and a stable state will not be achieved

If flow does not cease at a constant pressure of injection a complete arterial filling cannot be presumed Continued flow indicates a failure to raise R_3 sufficiently to equilibrate with P This will be because of the presence of a patent wide bore anastomotic artery an arterial leak or an arterio venous anastomosis

For the application of this technique it is desirable that the organ be left in situ without divided anastomoses but with the wider anastomotic arteries ligatured that the organ and its surrounding tissues should contain no arterio-venous anastomoses that the actual pressure of injection should be physiologic and that the apparent viscosity of the Micropaque should be as high as possible while allowing complete arteriolar filling

It is necessary to retain the injected Micropaque in the arterioles until processing and radiography are complete Fixation of tissue results in the solidification of intravascular Micropaque (BROOKES & HARRISON) Fixation of large blocks of tissue in which the anastomotic out flow vessels have been left intact by chemical methods is impossible Excision of only the organ for fixation results in the division of these vessels and efflux of fluid Micropaque from the arterioles If the organ is excised intact it is only within the anastomoses that solidification of the Micropaque is necessary before chemical fixation Since R_1 is exceeded by the pressure of injection before R_3 equilibrates with P it is possible to differentially fill the end arterial arteriolar system and the anastomotic system with two different suspensions of Micropaque If the second suspension solidifies quickly within the anastomotic system it will retain the first aqueous suspension within the organ until this also is solidified by chemical fixation The injection of a suspension of Micropaque in a warm weak (3–5%) solution of gelatin does not reduce the degree of filling of small vessels (RUBIN 1964 WENDELIN & LINDGREN 1970) The gelatin will solidify as it cools within the specimen

Thus an aqueous suspension of 50% Micropaque should be injected first and followed when the arterial system is nearly filled by a warm suspension of 50 Micropaque in 5% gelatin

The total volume of Micropaque injected depends on the total arterial cross sectional area and an average of L It will vary from subject to subject and is immaterial to the extent of vascular filling The rate of change of volume at a constant pressure tends to zero as filling progresses which is at the rate that P_2 equilibrates with R_3 Thus the rate of change of volume could be used as an indicator of vascular filling so that the point might be recognised at which to change from the aqueous to the gelatin suspension of Micropaque

Small rates of change of volume are difficult to measure in practice when the volumes are small compared to the total volume In an elastic system however the rate of change of volume at constant pressure is equal to the rate of change of pressure at a constant volume Small rates of change of pressure can be more easily measured

The injection apparatus should contain means of observing changes of pressure and a small elastic chamber

These theoretic principles have been tested in the human cadaver lumbar spine

Material and Methods

The material used was the lumbar vertebrae from 18 human cadavers subjected to routine autopsy 10 were males and 8 females and their ages ranged from 6 months to 70 years

Twelve were injected by the newly devised technique technique A which depended on the development of a resistance (R_3) within the anastomotic collaterals which would equilibrate with the pressure of injection (P_2)

Six acted as a control group and were injected by a previously described technique technique B which depended on the obstruction of the anastomotic collaterals (MARGULIS)

Recognised factors which might have influenced arterial filling such as atherosclerosis or anti-coagulation were distributed in both groups (Table 1)

Subject 3 died in gram negative septicaemic shock and uraemia Histology of several organs showed multiple micro-infarcts and many small arteries were obstructed by ante mortem plugs of inspissated red blood cells These were not recognised before the injection

Micropaque for the first part of the injection was diluted with an equal volume of hot water and for the second part with an equal volume of hot 10% gelatin solution This resulted in barium sulphate suspensions of 47% w/v at a temperature of 45 to 50 C

Technique A The apparatus illustrated diagrammatically in Fig 4 was used The barometer from an anaeroid sphygmomanometer was used to monitor pressure of injection and the rates of change of pressure within the system when the volume was made constant by the application of a clamp at point × to the tubing Approximately 100 ml of air within the barium trap to prevent contamination of the barometer acted as the elastic chamber

The abdominal aorta if intact was cannulated or 3 adjacent pairs of lumbar arteries were cannulated The injection was controlled by hand at the subject s ante mortem blood pressure All cut arteries from which Micropaque effluxed and all arteries which were seen directing Micropaque away from the lumbar spine were

Table 1

Eighteen subjects on whom the two techniques of injection (A or B) for microarteriography were used with indication of presence of atherosclerosis at post mortem examination and use of anticoagulants in the terminal illness

Subj No	Age and sex	Athero sclero sis	Anti coagu lants
Technique A			
1	42 M	+	0
2	15 M	0	0
3	27 M	0	0
4	14 M	0	0
5	60 F	+	0
6	7 F	0	0
7	56 F	+	0
8	69 F	+	+
9	½ M	0	0
10	49 M	+	+
11	69 F	+	+
12	65 M	+	0
Technique B			
13	62 M	+	0
14	60 F	+	+
15	41 M	0	+
16	71 F	+	+
17	23 M	0	0
18	9 F	0	0

ligatured As arterial filling progressed blood and serum were permitted to efflux from arteries and veins

At the beginning of injection the rate of change of volume of Micropaque in the syringe was rapid As arterial filling progressed the rate slowed and from time to time a clamp was applied to point × Observation of the rate of fall of pressure in this fixed volume state demonstrated that the rate of change of pressure fell as arterial filling progressed When the rate of fall of pressure was 665 Pa (5 mmHg) in 10 min the aqueous suspension of Micropaque was replaced with the 5% Micropaque gelatin suspension A needle with a syringe attached was inserted into the rubber tubing as near to the specimen as possible or into a branch of the aorta if the intact aorta had been cannulated Aqueous suspension was aspirated and gelatin suspension injected thus shunting the aqueous suspension out of the dead space without the introduction of air between the two suspensions The aspirating needle and syringe

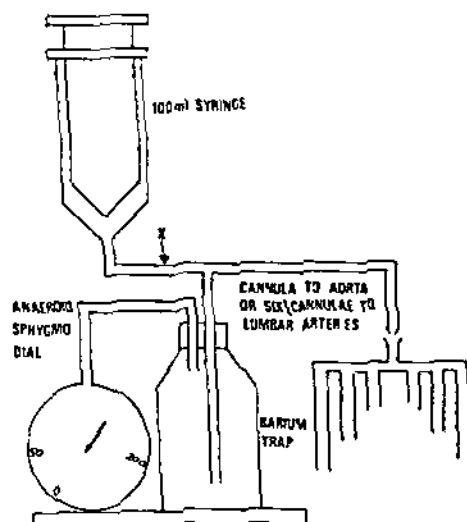


Fig 4

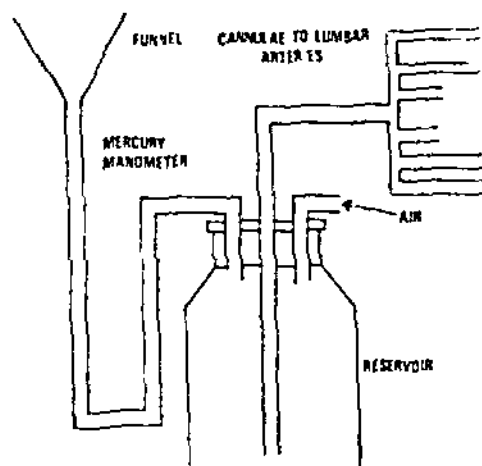


Fig 5

Fig 4 Diagram of injection apparatus used in the new technique technique A The six branched cannula was used to cannulate the 3 adjacent pairs of lumbar arteries in subjects in which the aorta had been removed A clamp was applied intermittently at point in order to observe the rate of fall of pressure

Fig 5 Diagram of the apparatus used in injection technique B The mercury manometer was adjustable in height so that air could escape if the pressure rose above the desired level The volume of the reservoir was 3 l

were then removed and injection of Micropaque in gelatin was continued until no more entered the specimen at a constant pressure Equilibration between the pressure of injection and the resistance to flow within the anastomotic channels was confirmed by the absence of fall of pressure when the volume was maintained constant by the application of the clamp The spine was left undisturbed until the gelatin had set and it was then excised for fixation

Technique B The lumbar spine with a mass of surrounding soft tissue was excised and the soft tissues adjacent to the spine were compressed between clamps Three adjacent pairs of lumbar arteries were cannulated and many divided arteries were ligatured Injection of the arteries was made using the apparatus illustrated in Fig 5 by raising the pressure within the apparatus to the subject s ante mortem blood pressure One litre of 50 % aqueous Micropaque was injected and followed by 500 ml of 50 % Micropaque in 5 % gelatin Efflux of blood was permitted from the spinal veins Widespread spill of Micropaque from divided arterioles on the cut surfaces occurred as well as from within the vertebral canal in spite of all attempts to control this by mattress suturing of muscle and the application of additional compression When the 1 500 ml of Micropaque had been injected the pressure was reduced and the gelatin allowed to set before excess soft tissues were removed

Table 2

Results of counting injected arteries (column 2) and all arteries (column 3) in each microscopic section

Subject No	No of arteries containing barium	Total No of arteries in section	Percentage of arteries containing barium
Technique A			
1	44	49	90
2	60	69	86
3	12	56	21
4	60	61	98
5	40	46	86
6	40	43	93
7	44	58	76
8	31	34	90
9	32	32	100
10	41	47	85
11	46	50	92
12	57	62	92
Technique B			
13	33	90	36
14	8	36	22
15	16	40	40
16	1	29	3
17	16	60	27
18	4	51	8

Processing The 18 lumbar spines were fixed in normal formol saline for 2 weeks The remaining fat and muscle were then dissected off and the spines decalcified in 10% nitric acid

A block which included periosteum cortex and spongiosa was cut from one vertebral body of each of the lumbar spines Any one of the 5 lumbar vertebrae of the spines injected by technique A was selected In the group injected by technique B a vertebra was selected in which the corresponding lumbar arteries had been cannulated The blocks were relabelled randomly by an assistant and two adjacent sections 5 μ thick were cut from each block One section was stained with haematoxylin and eosin the other by Verhoeff s method for elastin

The sections were examined microscopically It was not known at the time of examination which injection technique had been used in each section The total number of arterial cross sections in each histologic section and the total number of arterial cross sections which contained barium sulphate granules were counted Barium sulphate is easily identified under light microscopy as refractile granules Where doubt existed as to the nature of a vessel reference was made to the section stained by Verhoeff s method if a lamina elastica was present the vessel was counted as an artery

Table 3

Final results calculated from the data of Table 2 (technique A subjects 1 to 12 technique B subjects 13 to 18)

Technique	Barium-containing arteries	Total No of arteries	Percentage	Range of counts ( )	Standard deviation ( )
A	495	551	89 8	24	6 1
B	78	306	25 5	37	13

Pearson s coefficient of variance = standard deviation mean 100 as per cent Technique A = 7 technique B = 50

Results

In technique A the system equilibrated with the pressure of injection in every case and a predicted flow halted at a constant pressure of injection after a variable volume of Micropaque had been injected In adults this volume varied between 200 and 300 ml the larger volumes tending to be necessary for the younger adults In technique B the system did not equilibrate although five times the volume of Micropaque was used It proved impossible to prevent spill in technique B

The results of arterial counting are set out in Table 2

It wa demonstrated histologically that some of the arteries in subject 3 were obstructed ante mortem Arterial obstruction was not demonstrated in the vertebral sections of any other subject The results from subject 3 are excluded from Table 3 which is an analysis of the efficacy of the two techniques to *inject patent arteries* Table 3 shows that technique A resulted in the injection of 89 8 per cent of all *arteries* with a standard deviation of 6 1 per cent These results are significantly better than the results obtained by technique B By using Pearson s coefficient of variance technique A is 7 times more consistent in its results than technique B

Micropaque was not observed to efflux from veins nor was it observed within veins microscopically in either technique

Discussion

Technique A is the *method* of choice for microarteriographic injection in the present *material* No other figures have been found with which it may be compared

It was originally assumed that all vascular cross sections observed microscopically which had a *lamina* elastica would be part of the arterial tree in functional luminal continuity with the lumbar arteries and without interposed capillaries Therefore it was assumed that *it would* be possible to inject all these vessels The fortuitous finding of ante *mortem obstruction* of some of the arteries of subject 3 lead to the revision of these anatomic assumptions Investigation of the blood supply of the adult human vertebral body (*not* yet published) shows that all intra osseous arteries

are end arterial Ante mortem embolism of one of these arteries will sequestrate the arterial branches distal to the embolus These branches will be non functional and it will be impossible to inject them with any contrast medium Atheromatous embolism has been observed in the arteries of a vertebral body (ZAK & ELIAS 1949) To search for minute emboli in thousands of serial histologic sections of whole lumbar vertebrae in order to estimate the potential capacity of the arterial tree would be almost impossible It has been suggested that intraspinal anoxic respiration may in some cases be a cause of back pain (NACHEMSON 1969) An injection technique such as technique A might help to clarify this hypothesis when used in selected cadavers

It is an interesting observation that the results obtained from subjects under 45 years of age injected by technique A and excluding subject 3 had on the whole a higher percentage of injected arteries The series is too small for any conclusion to be drawn

Another possible anatomic cause for the failure of technique A to inject 100 per cent of all vessels designated as arterial is that some of the unfilled vessels may have been arterialised veins Arterialisation of veins may occur if the venous pressure is high The spinal veins are valveless (BATSON 1957) and the pressure in some individuals may be sufficient to cause arterialisation

If the original assumptions concerning the anatomy of the vascular cross sections were false it could be suggested that technique A injected a higher percentage of patent arteries and arterioles than the observed figures indicate The variables such as pressure of injection and concentration of Micropaque were chosen empirically using such information as was available in the literature Further work with technique A comparing the results with different variables may result in a higher percentage of arterioles being injected It may also reveal whether the assumptions as to the anatomic nature of vessels with a lamina elastica are true or false

A significant benefit of this technique is the relative consistency of arterial injection This means that valid statistical conclusions may be made from films of material injected by technique A

Acknowledgement

For advice and a great deal of encouragement the author thanks Professor J H Middlemiss Department of Radiodiagnosis University of Bristol Financial help was provided by the Hospital Medical Research Committee of the Bristol Royal Infirmary

SUMMARY

The theory and practice of a new technique of microarteriographic injection which depends on the development of a resistance to outflow in anastomoses are described using 18 human cadaver lumbar spines Histology demonstrated that this technique injected

90 per cent (SD 6°) of arterial vessels which was significantly better than another technique Possible reasons for not achieving 100 per cent injection are discussed This technique may form a basis for the radiographic evaluation of the vertebral microcirculation

ZUSAMMENFASSUNG

Die Theorie und die Praxis einer neuen Technik zur mikroarteriographischen Injektion welche auf der Entwicklung eines Widerstands fur den Abfluss in den Anastomosen beruht wird unter Verwendung von 18 menschlichen autoptischen Wirbelsaulen beschrieben Die Histologie zeigte dass bei dieser Technik 90 Prozent (SD 6 ₀) der arteriellen Gefasse gefullt werden was signifikant besser ist als bei anderen Techniken Die moglichen Grunde dafur dass keine 100-prozentige Fullung erreicht wurde werden diskutiert Diese Technik kann die Basis fur eine rontgenologische Beurteilung der vertebralen Mikrozirkulation bilden

RESUME

L auteur decrit la théorie et la pratique d une nouvelle technique d injection micro-arteriographique qui dépend du developpement d une resistance à l écoulement dans les anastomoses ce travail a éte fait sur 18 colonnes lombaires de cadavres humains L histologie a montré que cette technique injecte 90 pour-cent des vaisseaux artériels (SD 6°₀) ce qui est significativement meilleur que toute autre technique Il examine les raisons possibles qui empechent d atteindre une injection a 100 pour-cent Cette technique peut constituer la base d une évaluation radiographique de la microcirculation vertébrale

REFERENCES

BARCLAY A E Microarteriography Blackwell Scientific Publications Oxford 1951

BATSON O V The vertebral vein system Amer J Roentgenol 78 (1957) 195

BELLMAN S Microangiography Acta radiol (1953) Suppl No 102

BERGLJUNG L Vascular reactions after tendon suture and tendon transplantation Scand J plastic reconstr Surg (1968) Suppl No 4

BROOKES M The blood supply of bone Butterworths London 1970

— and HARRISON R G The vascularisation of the rabbit femur and tibio-fibula J Anat 91 (1957) 61

HARRISON R G The selection and injection of contrast media *In* Microarteriography Edited by A E Barclay Blackwell Scientific Publications Oxford 1951

LEXER E KULIGA P und TURK W Untersuchungen uber Knochenarterien mittlest Rontgenaufnahmen injizierter Knochen Hirschwald Berlin 1904

LJUNGQVIST A The intrarenal arterial pattern in the normal and diseased kidney Acta med scand (1963) Suppl No 401

MARGULIS A R Arteriography of tumours Difficulties in interpretation and need for magnification Radiol Clin N Amer 2 (1964) 543

NACHEMSON A Intradiscal measurements of pH in patients with lumbar rhizopathies Acta orthop scand 40 (1969) 23

ROTHMAN S L G KIER E L and DEUKER D K Microangiographic anatomy of the cat s eye Invest Radiol 10 (1975) 53

RUBIN P Microangiography facts and artefacts Radiol Clin N Amer 2 (1964) 499
SEVITT S Avascular necrosis and revascularisation of the femoral head after intracapsular fracture J Bone Jt Surg 46 B (1964) 270
WENDELIN H and LINDGREN I Microangiography of the renal vessels in the rabbit Acta radiol Diagnosis 10 (1970) 49
ZAK F and ELIAS K Embolisation with material from atheromata Amer J med Sci 218 (1949) 510

FROM THE DEPARTMENT OF DIAGNOSTIC RADIOLOGY KAROLINSKA SJUKHUSET S 104 01
STOCKHOLM SWEDEN

TOPOGRAPHY OF OVARIAN VEINS IN PREGNANCY

LARS OHLSON

The ovarian vessels and the ureters have been found to run symmetric but different courses in the non pregnant retroperitoneal space distal to the cranial part (part 1) of the artery (OHLSON 1973 a) This part corresponds to the course in the para aortic section At autopsy the ovarian vessels were found to be surrounded by a common connective tissue sheath similar to that of the ureter The vessels could be readily displaced in relation to the ureter the peritoneum and the muscles but they could also be separated from one another within the sheath

In pregnancy the course of the ovarian artery changes according to a regular pattern (OHLSON 1973 b) Because of the close connection within the sheath the vein could be expected to follow the same displacement as the artery although since the sheath is rather loose it should be possible for the vein to deviate to a certain extent from the artery

HUNTER (1774) examined the ovarian vessels distal to the ovary in pregnancy He described them as being hypertrophied though to a widely varying extent in individual cases In his drawings the vein is seen to consist of a plexus of large irregular branches whereas the artery is single has an even calibre and winds along the upper aspect of the venous plexus No reports on radiography of the ovarian vein in pregnancy appear to have been published

The material consisted of 52 uterine angiographies in pregnant women performed between 1962 and 1971 i e when angiography was still used to determine the site

Submitted for publication 7 October 1976

RUBIN P Microangiography facts and artefacts Radiol Clin N Amer 2 (1964) 499
SEVITT S Avascular necrosis and revascularisation of the femoral head after intracapsular fracture J Bone Jt Surg 46 B (1964) 270
WENDELIN H and LINDGREN I Microangiography of the renal vessels in the rabbit Acta radiol Diagnosis 10 (1970) 49
ZAK F and ELIAS K Embolisation with material from atheromata Amer J med Sci 218 (1949) 510




Fig 2 Left ovarian vein in non pregnancy

Results

The course and configuration of the left ovarian vein in the individual cases are illustrated in Fig 1 The course of the vein was the same as that of the artery ($p<0.001$) The turning point of the vein coincided with that of the artery (ovarian artery $x=+10.9\pm1.5/y=-6.9\pm2.1$ (n 26) ovarian vein $x=+10.2\pm1.3/y=-7.3\pm2.1$ (n=15)) The positions for the two vessels were thus not significantly separated at any level but the data showed that part 2 of the vein was located more laterally than the corresponding part of the artery whereas part 3 of the vein was located more medially than the artery

The displacement of the ureter was consistently different from that of the ovarian vessels ($p<0.001$)

The vein from 16 weeks onwards formed an angle to the y axis (the median line) of about 25 to 30 except in Case 23 which exhibited a marked lateral deviation near the transition between part 2 and part 3 Smaller deviations were present in Cases 12 16 21 and 25




Fig 3 Left ovarian vein in late pregnancy Cases 16 and 21

The width of the vein was in part 2 about 11 ± 3 range 6–16 mm (n 34) and in part 3 about 12 ± 4 range 6–20 mm (n = 26) The width increased from non pregnancy to pregnancy ($p < 0.001$) but from 30 weeks there was no significant alteration The difference in width between part 2 and part 3 was not significant In 5 cases the medial or lateral outline of the vein or both outlines presented local irregularities and in Cases 24 and 31 the irregularities also involved the anterior or posterior aspect of the vessel In Case 21 part 2 was duplicated and it was the smaller of the two branches that exhibited the irregularities In Case 44 the vein divided into two branches in the proximal portion of part 3 The pampiniform plexus was not found to extend into part 3 This agrees with the findings at dissection of the autopsy specimens

There was no correlation between the width of the vein and that of the artery

Part 2 of the artery generally passed along the medial aspect of the vein whereas part 3 usually coiled along the lateral aspect of the vein and in Cases 21 32 and 33 passed entirely lateral to the vein The turning point of the artery was located in 10 cases

within the area of the upper portion of the turning point of the vein and in one case within the lower portion In 5 cases, the turning point of the artery was cranial and lateral to the turning point of the vein and in one case below it

The flow in the right ovarian vein was in a proximal direction in 6 of the 7 cases In the remaining case the direction of flow could not be determined On the right side flow in the distal direction could thus not be demonstrated On the left side the flow was in a distal direction in all cases but 9 In 7 of these 9 cases the angiography was done before the 20th week of pregnancy in one case in the 32nd week and in the remaining one in the 35th week In the last two cases the right ovarian vein also filled the direction of flow being proximal on both sides

Discussion

The course of the ovarian veins that filled on the right side was symmetric with that of the left ovarian veins but they were too few to permit a statistical analysis of the state of symmetry The left ovarian vein was displaced along with the artery on that side Since the dissections accounted for in a previous report (OHLSON 1973 a) showed the connections of the ovarian vein to the artery to be the same on both sides the right vein could be expected to move with the artery on that side in a way analogous to that on the left side Thus filling of a sufficiently large number of veins on the right side would be expected to exhibit the same asymmetry as did the arteries (OHLSON 1973 b)

The dilated ovarian veins in pregnancy might be expected to affect the appearance of the artery but this was not found apparently because the connections between the two vessels were sufficiently loose The ovarian vein thus reacted to the expansion of the uterus in the same way as the artery reflecting the forces that are operative in the pregnant abdomen i.e the pressure from the uterus and the traction transmitted from the uterus to its peritoneal duplication (the mesometrium)

SUMMARY

The course of the ovarian vessels and the ureters in pregnancy was evaluated by a topographic coordinate system presented previously The vein was found to be displaced with the artery whereas the displacement of the ureters was distinct from that of the vessels The vessels thus reflected both the pressure and traction transmitted from the uterus to the abdomen whereas the ureters reflected only the pressure applied to the posterior abdominal wall

ZUSAMMENFASSUNG

Der Verlauf der Gefasse der Ovarien und des Uterus wahrend der Graviditat wurde durch ein fruher beschriebenes topographisches System festgestellt Es wurde gefunden dass sich die Vene mit der Arterie verschiebt wahrend sich die Verschiebung der Uretären

von der der Gefasse unterscheidet Die Gefasse geben somit sowohl den Druck wie den Zug, der vom Uterus auf das Abdomen uberfuhrt wird wieder wahrend die Uretaren nur den Druck der auf die vordere abdominale Wand ausgeubt wird wiedergibt

RÉSUME

Le trajet des vaisseaux ovariens et des ureteres pendant la grossesse a eté étudié par un systeme de coordonnees topographique présenté auparavant L auteur a constaté que la veine est déplacée avec l artere alors que le déplacement des uretères est distinct de celui des vaisseaux Les vaisseaux reflètent donc à la fois la pression et la traction transmises à partir de l uterus a l abdomen alors que les uretères reflètent seulement la pression appliquée à la paroi postérieure de l abdomen

REFERENCES

HUNTER W *The anatomy of the human gravid uterus London 1774*

OHLSON L (a) Non pregnant anatomy of the posterior abdominal wall as reflected in the course of the ovarian artery and the ureter Acta radiol Diagnosis 14 (1973) 145

— (b) Ovarian vessels and ureter as indicators of the expansion of the uterus in pregnancy Acta radiol Diagnosis 14 (1973) 467

FROM THE DEPARTMENT OF PHYSIOLOGY UNIVERSITY OF AACHEN D-5100 AACHEN GERMANY

EFFECT OF IONIC AND NON IONIC CONTRAST MEDIA ON MORPHOLOGY OF HUMAN ERYTHROCYTES

P ASPELIN

Many reports on changes of the morphology of the red blood cells following exposure to water soluble contrast media have appeared most based on ordinary light microscopy The usual finding has been crenation of the red cell (BJÖRK 1970 BROWN et coll 1968 CHAPLIN & CARLSSON 1961 MEYER & READ 1964 RAND & LACOMBE 1964 SVOBODA & FIALA 1960 1964 WIEDEMAN 1963 1964) sometimes connected with shrinkage of the red cell or reduction of its diameter (BERNSTEIN et coll 1964 BRÅNEMARK et coll 1969 LASSER et coll 1962 MCINTOSH et coll 1967) In 1973 however SCHIANTARELLI et coll and PERONI et coll used scanning electron microscopy They clearly demonstrated that the red cells in contact with ionic contrast media changed from the normal disc into crenated spheres (echinocytes) independent of the osmolality of the media They also found a positive correlation between the degree of deformation of the red cells and the intravenous toxicity Using a new method interference contrast optics the effects of non ionic and ionic media were compared in vivo and the results are now reported

Material and Methods

Blood from healthy human subjects was obtained by vein puncture and anticoagulated with EDTA (1 5 mg/ml) After centrifugation the hematocrit was ad

Supported by the Swedish Medical Research Council, Project No 3483 (The author is now at Department of Diagnostic Radiology Malmo Allmanna Sjukhus S-214 01 Malmo) Submitted for publication 3 August 1977

Table 1

Iodine content osmolality and viscosity of the investigated contrast media

Contrast medium	Iodine content (mg I/ml)	Osmolality (osm)	Viscosity (cps) 37 C
Isopaque Cerebral*	55	0 3	
Isopaque Cerebral	280	1 5	4 0
Isopaque Coronar*	55	0 3	
Isopaque Coronar	370	2 1	8 5
Urografin*	55	0 3	
Urograin 60	290	1 5	4 5
Urografin 76	370	2 1	8 5
*Dimer X**	*80*	*0 3*	
Dimer X	280	1 1	7 2
Amipaque + mannitol*	55	0 3	
Amipaque	170	0 3	1 8
Amipaque	280	0 5	5 0
Amipaque	370	0 7	14 0
Sodium Metrizoate*	55	0 3	
Meglumine Metrizoate	55	0 3	

extemporaneous solution

justed to 10 or 45 per cent by adding or removing plasma The different contrast media solutions were then added in order to obtain different volume ratios contrast medium/blood

The following volume ratios were prepared 2 5 20 and 90 per cent At each volume ratio five solutions with blood from different subjects were examined The samples obtained were studied in a microscopic flow chamber (rheoscope) with a counter rotating cone and plate fitted on an inverted microscope (SCHMID SCHÖNBEIN et coll 1975) Interference contrast optics were used (objective 100/1 30) For each sample the number of cells in each viewing field in the rheoscope was counted and the percentage of the morphologically changed cells were calculated At each sample ten fields were counted For photography the image of the blood in the chamber was projected into a camera (Exacta Varex 2 B) For illumination a stroboscopic flash light (Strobex Model 136) synchronized to the camera was used By this new method it was thus possible to examine the morphologic changes of the erythrocytes in plasma This procedure may be more advantageous than scanning electron microscopy where the cells have to be subjected to special fixation procedures before microscopy

The effect of the following compounds was compared A Ionic monomeric contrast media Urografin (meglumine/sodium diatrizoate) Isopaque Coronar (meglumine/

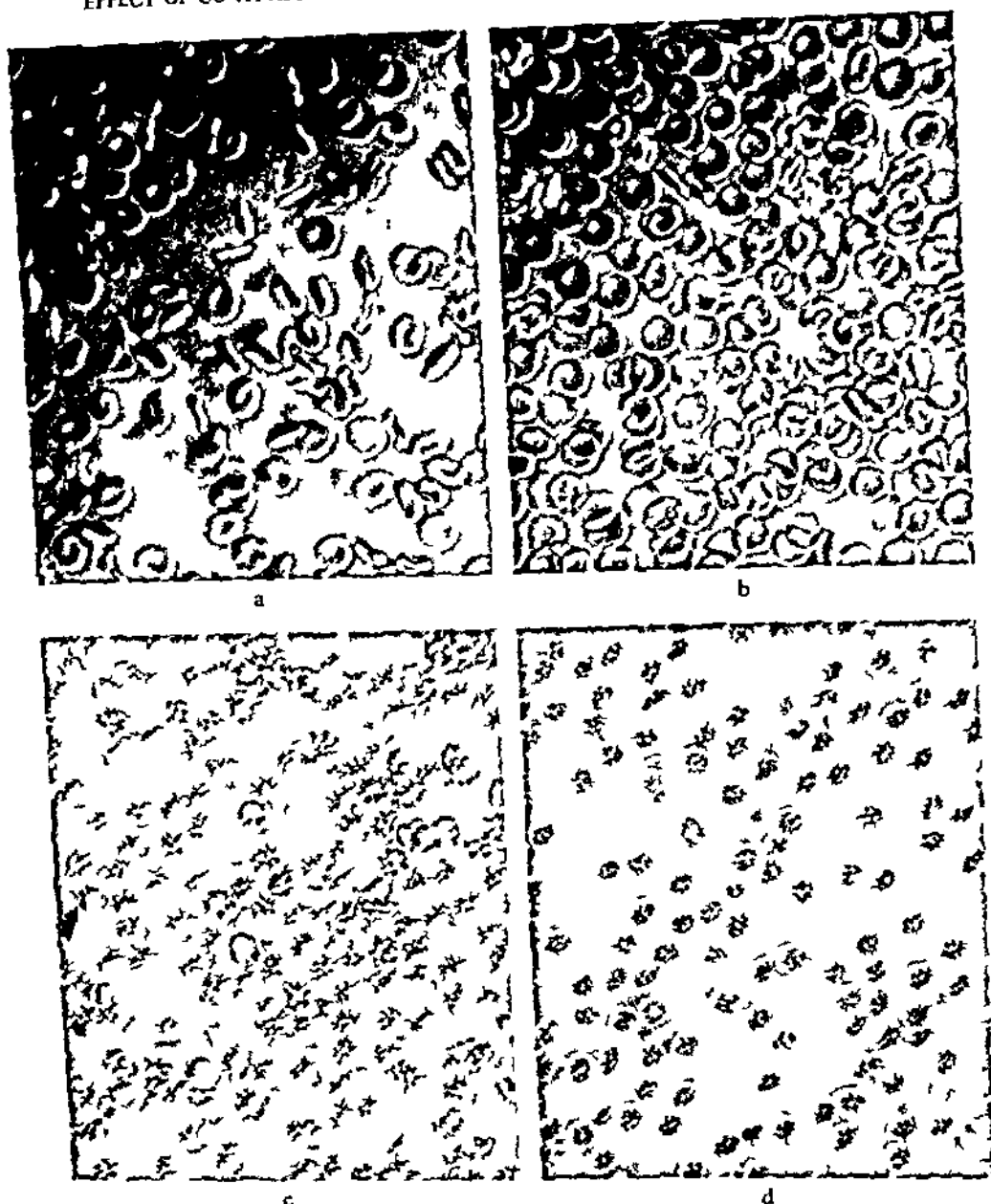


Fig 1 Human erythrocytes exposed to isotonic (0 3 osm) solutions in 90 volume ratio (contrast medium blood) of a) Iocarmate (Dimer X) b) diatrizoate (Urografin) c) metrizoate (Isopaque Cerebral) d) metrizamide + mannitol (Amipaque)

sodium/calcium metrizoate) Isopaque Cerebral (meglumine/calcium metrizoate) Sodium metrizoate and Meglumine metrizoate B Ionic dimeric contrast medium Dimer X (meglumine iocarmate) C Non ionic contrast medium Amipaque (metriz amide) D NaCl (1 5 osm)




Fig 2 Normal human erythrocytes

The iodine content the osmolality and the molar concentration of the tested contrast media solutions are presented in Table 1 Since other concentrations were used than those commercially available extemporaneous solutions were prepared by dilution with sterile water or by adding mannitol in order to increase the osmolality of the solution Mannitol acts exclusively extracellularly and does not per se in isotonic (0 3 osm) solution cause any deformation of the red cell The osmolality of the extemporaneous solutions was measured by freezing point determination (Knauer Osmometer)

Results

The effect on red blood cell morphology of the different contrast media was the same at 10 per cent and 45 per cent hematocrit but at 45 per cent the red blood cells were in such close contact with each other that the single cell morphology was difficult to evaluate Therefore only the images at 10 per cent hematocrit were evaluated

Changes produced by iso osmotic (0 3 osm) contrast media In 90 per cent volume ratio iocarmate (Dimer X Fig 1 a) and diatrizoate (Urografin Fig 1 b) produced less changes ($p < 0\,001$) in the red cell morphology than metrizoate (Isopaque Fig 1 c) and metrizamide (Amipaque Fig 1 d)

In the presence of iocarmate and diatrizoate only a few cells (< 10 %) were slightly deformed but compared with normal blood (Fig 2) there was a reduced formation of rouleaux Both metrizoate and metrizamide deformed almost all cells (90–100 %) The types of red cells produced are similar to those first described by PONDER (1948) and by BESSIS et coll (1973) called echinocytes Pure sodium and meglumine salts of metrizoate also produced this echinocyte deformation of the red cells and no difference in degree of deformation between the two salts was found



a



b



c

Fig 3 Human erythrocytes exposed to 90 volume ratio (contrast medium/blood) of a) Iocarmate (Dimer X 280 mg I/ml) b) diatrizoate (Urografin 60 290 mg I/ml) c) metrizoate (Isopaque Cerebral, 280 mg I ml)



Fig 4




Fig 5

Fig 4 Human erythrocytes exposed to 10 NaCl in 90 volume ratio (saline/blood)

Fig 5 Human erythrocytes exposed to 90 volume ratio (contrast medium/blood) of metrizamide (Amipaque 280 mg I ml)

Changes produced by hyperosmotic contrast media Microscopy revealed difference in deformation between the high osmotic ionic and low osmotic non ionic contrast media at high volume ratio (90 %) contrast media/blood (Fig 3) At both 290 mg I/ml and 370 mg I/ml in 90 per cent volume ratio all the ionic media produced markedly shrunken erythrocytes similar to those that were produced by hypertonic saline (Fig 4) These shrunken cells have been called desiccocytes by NATHAN & SHOHET (1970)

At lower concentrations (5 % and 20 %) all the ionic contrast media produced echinocytes In these hypertonic solutions the effect on red cell morphology was similar when the media were compared in iodine equivalent doses

On the other hand the non ionic contrast medium produced no desiccocytes but at the concentration 5 20 and 90 per cent the erythrocytes were transformed into echinocytes (Fig 5) The degree and type of morphologic changes induced by both iso and hypertonic contrast media are summarized in Table 2 From this table it is clear that all the contrast media produced changes (echinocytes or desiccocytes) and that changes were also produced in iso tonic solutions It is also evident that with increasing volume ratio (molar concentration) contrast media to blood the number of deformed cells increases

Table 2

Effect of different contrast media on morphology of human erythrocytes

Contrast	Osmolality (osm)	Volume ratio (c m /blood)	Final conc of compound mg I/ml	Final conc of compound mM	Degree of RBC deformation
Urografin	0.3	20	11	28	(+)
		90	50	126	+
Urografin 60	1.5	2	5.8	15	(+)
		5	15	38	+
		20	58	152	+ +
		90	261	684	DDD
Urografin 76	2.1	2	7.4	19	(+)
		5	19	49	+ +
		20	74	194	+ + +
		90	333	873	DDD
Isopaque Cerebral	0.3	20	11	28	(+)
		90	50	126	+ +
Isopaque Cerebral	1.5	2	5.6	15	(+)
		5	14	36	–
		20	56	146	+ +
		90	252	657	DDD
Dimer X	0.3	20	16	20	(+)
		90	72	90	+
Dimer X	1.1	2	5.6	8	(+)
		5	14	18	+
		20	56	73	+ +
		90	252	328	DDD
Isopaque Coronar*	0.3	20	11	28	+
		90	50	126	+ + +
Isopaque Coronar	2.1	2	7.4	19	+
		5	19	49	+ +
		20	74	194	+ + +
		90	330	873	DDD
Amipaque + mannitol	0.3	20	11	28	+ +
		90	50	126	+ + +
Amipaque	0.3	20	34	90	+ +
Amipaque	0.5	2	5.6	15	(+)
		5	14	36	+ +
		20	56	146	+ +
		90	252	657	+ + +
Amipaque	0.7	2	7.4	19	+
		5	19	49	+ +
		20	74	194	+ + +
		90	333	873	+ + +
Sodium-Metrizoate	0.3	20	11	28	+
		90	50	126	+ + +
Meglumine Metrizoate	0.3	20	11	28	+
		90	50	126	+ + +

* extemporaneous solution

( ) minor deformation no echinocytes, + = minor deformation < 10 echinocytes + + = 10–50 echinocytes, + + + = 90–100 echinocytes DDD = 90–100 desiccocytes

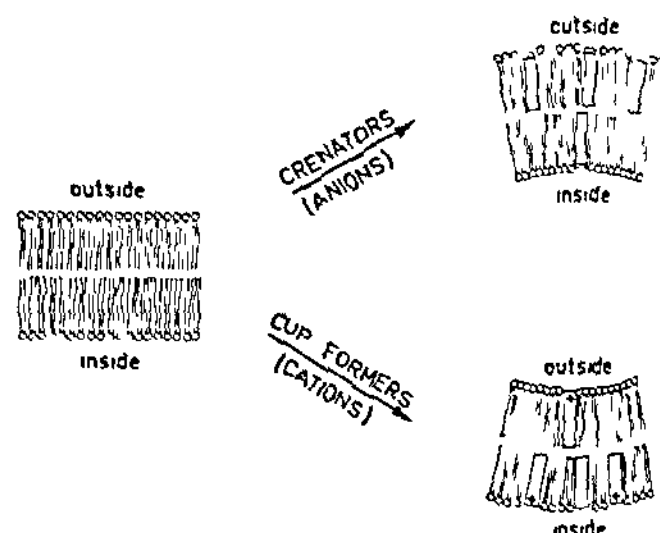


FIG. 6. Bilayer couple hypothesis of the erythrocyte membrane (to the left) and the proposed binding of amphipathic compounds that are crenators or cup formers (to the right). The anions interpolate preferentially into the exterior half of the bilayer causing it to expand relative to the cytoplasmatic half producing the observed crenation. The cations do the opposite.

Discussion

Two main types of changes in the morphology of the erythrocytes were produced by the different contrast media.

(1) The echinocyte which was produced by the iso-osmotic solutions indicates that this effect is a chemotoxic effect of the contrast molecule per se on the erythrocyte membrane.

(2) The desiccocyte which was produced by both the ionic contrast media of high osmolality and by the hypertonic saline but not by the low osmotic non-ionic medium indicates that this effect is a result rather of the high osmolality of the solution than of the contrast molecule per se.

The observation that the different contrast media change the morphology of the red cells in solutions isotonic with blood agrees with the findings of SCHIANTARELLI et coll. They also found by electron microscopy that the onset of echinocyte deformation was nearly instantaneous and reversible. This has been confirmed by CHAPLIN & CARLSSON (1961) and SVOBODA & FIALA (1964), who also found this echinocyte deformation to be reversible. The present results show no correlation between the capacity to produce changes in erythrocyte morphology and the protein binding ability or the general intravenous toxicity of the different contrast media as was found by SCHIANTARELLI et coll. They demonstrated that contrast media which had a great protein binding capacity and high intravenous toxicity produced the most marked changes of erythrocyte morphology. In the present experiments metrizamide, which has a low protein binding capacity (SALVESEN & FREY 1973) and a l[illegible] venous toxicity (ASPELIN & ALMÉN 1976, SALVESEN & FREY) produced m[illegible] s in iso-osmotic solution than metrizoate and diatrizoate wh[illegible]h have [illegible] tra venous toxicity (ASPELIN & ALMÉN, SALVESEN & FREY). T[illegible] xact n



Fig 7 Cup-chaped (stomatocytes) deformation of human erythrocytes produced by chlor promazine

known but recently SHEETS & SINGER (1974) have published theories on changes in red cell morphology which might be applicable They propose a model of the eryth rocyte membrane where the matrix is a bilayer of phospholipids with their hydrophilic ends protruding both to the external and to the cytoplasmatic surface of the membrane and their hydrophobic ends hidden in the depth of the membrane (Fig 6) The phospholipids are asymmetrically distributed (ZWAAL et coll 1975) in a way which may impose a negative charge on the cytoplasmatic surface of the membrane relative to the external surface The origin of this asymmetric distribution is not known The hypothesis for the morphologic changes to appear is that the two halves of the membrane bilayer may respond differently to various pertubations Thus one half of the bilayer may through effects on the lipid component expand in the plane of the membrane relative to the other half of the bilayer resulting in changes in the intact red cell

It is well known that red blood cells in the biconcave disc shape may be induced to assume in vitro other appearances (BESSIS et coll 1973) Among the most examined alternative forms are the crenated (echinocyte Fig 1 c BESSIS et coll BRECHER & BESSIS 1973) and the cup shaped (stomatocyte Fig 7 BESSIS et coll) red cell The echinocyte may be produced by many factors e g depletion of intracellular ATP (FEO & LEBLOND 1974 HARADIN et coll 1969 NAKAO et coll 1960 WEED et coll 1969) cell aging (BRECHER & BESSIS) elevation of pH (SALVESEN 1973) and exposure to anionic agents (DEUTICKE 1968 MOHANDAS & FEO 1975) The stomatocyte may be produced by e g decreased pH (BESSIS & BRICKA 1950) chlorpromazine (WEED & BESSIS 1973) and exposure to cationic agents (DEUTICKE MOHANDAS & FEO) Interesting findings correlated with the crenation following exposure to contrast media were made by DEUTICKE and MOHANDAS & FEO They found that the echinocyte was

produced mainly by anionic and the stomatocyte by cationic organic compounds. The reason for this may be explained by the described bilayer couple hypothesis. Thus the cations would, due to their electrical charge, preferably be distributed into the negatively charged cytoplasmatic half of the membrane causing this half to expand relative to the exterior half, inducing the observed invagination (Figs. 6, 7). The anions would, according to the same rationale, remain in the outer layer (away from the negatively charged inner layer) and thus cause the outer layer to expand relative to the cytoplasmatic, causing the crenation (Figs. 1 c, 6). This would thus indicate that it is the anion in the contrast medium molecule that produces the morphologic changes. This is in agreement with the present findings and those of SCHIANTARELLI et coll., in which changing the cation (meglumine or sodium salts) did not affect the type of change in the erythrocyte morphology. The varying degrees of crenation according to the same theory depend on different amphipathic properties of the different anions, e.g. the more hydrophilic an molecule is the greater its tendency to remain in the middle of the membrane causing less crenation.

The crenation produced by the non-ionic (non-charged) metrizamide may also be explained by this theory. Non-charged molecules might be assumed to remain preferably in the outer layer and thus cause this to expand, resulting in crenation.

This theory is also supported by the findings of PIKONI et coll. (1973) who found that the addition of chlorpromazine (that produces cup-shaped cells, WEED & BESSIS 1973) to contrast media exposed erythrocytes could prevent the cells from becoming crenated. However, it should be stated that contrast media are relatively weak crenators of the red cell. The concentrations (mM) required to induce crenation are markedly higher than those reported for most other anionic compounds that produce crenation (DEUTICKE 1968).

The clinical relevance of the morphologic changes is not clear. At urography, i.e. when 0.4–2.0 per cent volume ratio (contrast medium/blood) are used, only a few cells crenate. This deformation may be of minor importance since it is reversed when the red cells are no longer in contact with the contrast molecules. In selective angiography, where high (up to 90 %) volume ratios (contrast medium/blood) are obtained, the organs investigated are reached by a great number of shrunken erythrocytes which may cause considerable changes in the flow properties of the blood. The important finding may thus not be the morphologic changes per se but rather to what degree these deformed cells interfere with the rheology of blood, i.e. red cell aggregation and red cell deformation.

SUMMARY

The effects of solutions of the ionic contrast media diatrizoate, ioxaglate and metrizoate and the non-ionic metrizamide on red cell morphology were compared by interference contrast optics in vitro. All the media produced changes, in solutions both isotonic and hypertonic to blood. The changes increased with increasing volume ratio (c[illegible]st medium/

blood) At low volume ratio the cells were transformed into crenated cells (echinocytes) in ionic solutions both hypertonic and isotonic to blood At high volume ratio the hypertonic ionic media caused the red cells to become shrunken (desiccocytes) corresponding to the shrinkage caused by hypertonic saline The low osmotic non ionic metrizamide never produced desiccocytes but echinocytes also in high volume ratio In solutions isotonic with blood metrizoate and metrizamide transformed more cells into echinocytes than the diatrizoate and iocarmate solutions

ZUSAMMENFASSUNG

Die Wirkungen von Losungen der ionisierten Kontrastmittel Diatrizoat Iocarmat und Metrizoat und des nicht ionisierten Metrizamid auf die Morphologie der roten Blutzellen wurde durch Interferenz Kontrast Optische Messungen in vivo verglichen Alle diese Mittel verursachten Veranderungen in Losungen die sowohl isotonisch als hypertonisch zum Blut sind Die Veranderungen stiegen mit hoherem Volumenverhaltnis (Kontrastmittel/Blut) Bei einem niedrigen Volumenverhaltnis wurden die Zell n in gezahnte Zellen (Echinozyten) bei ionisierten Losungen die sowohl hypertonisch wie isotonisch zum Blut waren uberfuhrt Bei einem hohen Volumenverhaltnis verursachten die hypertonischen ionisierten Mittel Schrumpfung der roten Blutzellen (Desiccozyten) entsprechend der Schrumpfung hervor gerufen durch hypertonische Salzlosungen Das niedrig-osmotische nicht ionisierte Metrizamid verursachte niemals Desiccozyten jedoch Echinozyten ebenfalls bei einem hohen Volumenverhaltnis Bei isotonischen Losungen zum Blut verandert Metrizoat und Metrizamid mehr Zellen in Echinozyten als Diatrizoat und Iocarmat Losungen

RESUME

Les effets de solution de moyens de contraste ioniques diatrizoate iocarmate et metrizoate et du métrizamide non ionique sur la morphologie des globules rouges ont ete compares par une methode optique de contraste d interference in vitro Tous les moyens de contraste ont produit des modifications en solutions aussi bien isotoniques qu hypertoniques au sang. Ces modifications augmentent quand augmente le rapport des volumes (moyens de contraste sur sang) Avec un faible rapport des volumes les cellules sont transformees en cellules crenelees (échinocytes) dans les solutions ioniques qu elles soient hypertoniques ou isotoniques au sang Pour un haut rapport des volumes les moyens de contraste ioniques hypertoniques provoquent une retraction des globules rouges (desiccocytes) correspondant à la retraction causée par le serum sale hypertonique Le métrizamide non ionique a faible pouvoir osmotique n a jamais donne lieu à des dessiccocytes mais a des echinocytes meme pour un rapport de volume elevé *En solutions isotoniques au sang* le metrizoate et le metrizamide ont transforme plus de globules en echinocytes que les solutions de diatrizoate et de iocarmate

REFERENCES

ASPELIN P and ALMEN T Studies on the acute toxicity of ionic and non-ionic contrast med a following rapid intravenous injection Invest Radiol 11 (1976) 309

BERNSTEIN E. EVANS R and SALTZMAN G F Physico-chemical properties of blood fol lowing exposure to methylglucamine iodopamide and other contrast media Acta radiol Diagnosis 2 (1964) 401

BESSIS M et BRICKA M Etude au microscope électronique sur l hemolyse l agglutination, la forme et la structure des globules rouges Rev Hematol 5 (1950) 396

— WEED R J and LEBLOND P F Red cell shape Physiology Pathology Ultrastructure Springer Verlag, Heidelberg 1973

BJORK L Effect on erythrocytes of large doses of contrast medium in clinical angiocardiography Acta radiol Diagnosis 10 (1970) 151

BRÅNEMARK P I JACOBSSON P and SORENSEN S E Microvascular effects of topically applied contrast media Acta radiol Diagnosis 8 (1969) 547

BRECHER G and BESSIS M Present status of spiculated red cells and their relationship to the discocyte-echinocyte transformation Blood 40 (1973) 333

BROWN R YOUMANS R LIVANEC G DERRICK J BOND T and GUEST M Cinemicrographic observations of the effects of contrast media on the microcirculation Vasc Surg 2 (1968) 109

BULL B and BRAILSFORD J D The biconcavity of the red cell An analysis of several hypothesis Blood 41 (1973) 833

CANHAM P B The minimum energy of energy of bending as a possible explanation of the biconcave shape of the human red blood cell J theor Biol 26 (1970) 61

CHAPLIN H and CARLSSON E Changes in human red blood cells during in vitro exposure to several roentgenologic contrast media Amer J Roentgenol 86 (1961) 1127

DEUTICKE B Transformation and restoration of biconcave shape of human erythrocytes induced by amphiphilic agents and changes of ionic environment Biochim biophys Acta 163 (1968) 494

FARRANT J and WOOLGAR A E Human red cells under hypertonic conditions A model system for investigation freezing damage Cryobiology 9 (1972) 9

FEO C J and LEBLOND P F The discocytes-echinocyte transformation Comparison of normal and ATP enriched human erythrocytes Blood 44 (1974) 639

HARADIN A WEED R and REED C Changes in physical properties of stored erythrocytes Relationship to survival in vivo Transfusion 9 (1969) 229

LASSER E FARR R FUJIMAGARI T and TRIPP W The significance of proteinbinding of contrast media in roentgen diagnosis Amer J Roentgenol 87 (1962) 338

MCINTOSH H HURST V THOMPSON H MORRIS J and WHALEN R The hemodynamic effects of the injection of contrast medium (Isopaque) Angiology 18 (1967) 306

MEYER M and READ R C Red cell aggregation from concentrated saline and angiographic media Radiology 82 (1964) 630

MOHANDAS N and FEO C A quantitative study of the red cell shape changes produced by anionic and cationic derivates of phenothiazine Blood Cells 1 (1975) 375

NAKAO M NAKAO T and YAMAZOE S Adenosine three-ephosphate and maintenance of the shap of the human red cell Nature 187 (1960) 945

NATHAN D G and SHOHET S B Erythrocyte ion transport defects and hemolytic anemia Hydrocytosis and Desiccocytosis Semin Hematol 7 (1970) 381

PERONI F SCHIANTARELLI P ROSATI G and TIRONE P Effects of iodinated contrast media on erythrocytes II Effect of some drugs on alterations induced by meglumine acetrizoate Invest Radiol 8 (1973) 205

PONDER E Hemolysis and related phenomena Grune and Stratton New York 1948

RAND P and LACOMBE E Hemodilution tonicity and blood viscosity J clin Invest 43 (1964) 2214

SALVESEN S Acute toxicity test of metrizamide Acta radiol (1973) Suppl No 335 p 5

— and FREY K Protein binding of metrizamide and the effect of various enzymes Acta radiol (1973) Suppl No 335 p 247

SCHIANTARELLI P PERONI F TIRONE P and ROSATI G Effects of iodinated contrast media on erythrocytes I Effects on canine erythrocytes on morphology Invest Radiol 8 (1973) 199
SCHMID SCHONBEIN H Erythrocyte rheology and the optimization of mass transport in the microcirculation Blood Cells 1 (1975) 285
— v GOOSEN J HEINICH L. KLOSE H and VOLGER E A counter rotating rheoscope chamber for the study of the microrheology of blood cell aggregation by microscopic observation and microphotometry Microvasc Res 6 (1973) 366
SHEETS M and SINGER S Biological membranes as bilayer couples A molecular mechanism of drug-erythrocyte interactions Proc nat Acad Sci (Wash) 71 (1974) 4457
SVOBODA M und FIALA J Über die Beziehung verschiedener positiver Rontgenkontrast mittel zu roten Blutkorperchen Radiol diagn (Berl) 1 (1960) 336
— — Der Einfluss jodierter wasserloslicher Rontgenkontrastmittel auf die roten Blut korperchen im Verlauf der Kontrastuntersuchungen Radiol diagn (Berl) 5 (1964) 207
— — Morphologische Veranderungen der roten Blutkorperchen nach verschiedenen wasserloslichen jodhaltigen Rontgenkontrastmitteln Radiologe 4 (1964) 404
WEED R I and BESSIS M The discocyte stomatocyte equilibrium of normal and pathological cells Blood 41 (1973) 471
— LACELLE P L and MERRILL E. W Metabolic dependence of red cell membrane deformability J clin Invest 48 (1969) 795
WIEDEMAN M Vascular and intravascular responses to various contrast media Angiology 14 (1963) 107
— Influence of low molecular weight dextran on vascular and intravascular responses to contrast media Amer J Roentgenol 92 (1964) 682
ZWAAL R F ROELFSEN B COMFURIUS P and VAN DEENEN L Organization of phospholipids in human red cell membranes as detected by the action of various purified phospholipases Biochim biophys Acta 406 (1975) 83

FROM THE DEPARTMENTS OF INTERNAL MEDICINE I AND DIAGNOSTIC RADIOLOGY, MALMO ALLMÄNNA SJUKHUS S 214 01 MALMÖ SWEDEN

EFFECT OF METRIZAMIDE ON WHOLE BLOOD OXYGEN AFFINITY

S BERGLUND T ALMEN and B W JOHANSSON

Metrizamide (Amipaque) is a water soluble contrast medium with a lower subarachnoid and intravascular toxicity (Acta radiol Suppl No 335 1973) than currently used water soluble media such as diatrizoate metrizoate and iothalamate Each of these media forms an ionic solution of high osmolality while metrizamide forms a non ionic solution of lower osmolality than the previous media in iodine equivalent concentrations

ROSENTAHL et coll (1973) reported an increase in whole blood oxygen affinity in the presence of contrast media This was demonstrated both in vitro and in vivo following cardioangiography in children with congenital heart disease The contrast media used were different salts of diatrizoate (Renovist II and Hypaque 50) The clinical significance of the findings was considered unclear The conclusions of these authors were criticized by LICHTMAN et coll (1975) who considered the increased oxygen affinity to be an artifact and stressed the importance of measuring the intra erythrocytic pH If this pH was taken into consideration the oxygen affinity was not changed This was shown in vitro using diatrizoate salts (Hypaque 50 and *Renografin* 76)

The aim of the present investigation was to assess the effects in vitro on whole blood oxygen affinity following the addition to human blood of either an ionic contrast medium (diatrizoate) or a non ionic medium (metrizamide)

Submitted for publication 29 April 1977

Material and Methods

Blood from 12 healthy 48 year-old non smoking male volunteers was used for the experiments Urografin 60° (meglumine/sodium diatrizoate) was added to the blood of 6 of the volunteers and Amipaque (metrizamide) was added to the blood of the remaining 6 volunteers Both contrast media were used in an iodine concentration of 0 29 g I/ml

Increasing amounts of contrast medium solution (0 005 0 01 0 02 0 04 and 0 06 ml) were added to the blood to a final volume of 1 ml The concentrations in the blood were of a magnitude that may occur in patients at urography or angiography

In order to obtain baseline values double analyses on blood without contrast medium were performed on each volunteer and the mean values of P 50 stand P 50 ery P 50 act pH pl and pH ery were determined The same parameters were then measured in single analyses on blood to which increasing amounts of contrast medium solution had been added The deviation of these parameters from the base line value of each single individual was then calculated Carboxyhemoglobin (COHb) was determined in all samples except one and was normal in all (<1 %) except one in which it was slightly increased (1 37%) Analysis of 2 3 diphosphoglycerate (2 3 DPG) was not performed

P 50 The P 50 value the oxygen tension in kPa required to half saturate the hemoglobin was determined on freshly drawn heparinized venous blood The blood was drawn in the morning anaerobically from the fasting volunteers Actual values of oxygen tension ($P\,O_2$) carbon dioxide tension ($P\,CO_2$) plasma pH (pH pl) oxygen saturation ($S\,O_2$) and COHb were determined at 37 C O_2 CO_2 and pH electrodes (Instrumentation laboratories Inc model 213) were used $S\,O_2$ was measured with a Beckman B spectrophotometer according to HOLMGREN & PERNOW (1959) COHb was measured according to SUNDSTRÖM (1972) The analyses were carried out immediately or after storage at +4 C for up to two hours In order to correct *pH to* 7 40 a Bohr factor of −0 48 (SEVERINGHAUS 1966) was used The value of n indicating heme–heme interaction was assumed to be 2 6 (SEVERINGHAUS) and the P 50 value was determined by extrapolation using the logarithmic form of the empirical equa*tion of* HILL *(1910)* The normal values with this technique and at $S\,O_2$ values ranging between 42 2 and 82 3 per cent were calculated in 26 healthy 48 *year old* non smoking men and were found to be 3 60 kPa ± 0 48 (2 SD)

In the experiments with contrast media this P 50 value was designated P 50 stand which means that pH pl was used and *corrected to pH 7 40* as described P 50 ery denotes the P 50 value obtained using the intra-erythrocytic pH (pH ery) from the same sample This was *converted* to corresponding plasma pH value using the formula pH ery = 0 743 × *pH plasma* + *1 710* (LICHTMAN et coll 1975) after which correction to plasma pH 7 40 was performed By P 50 act is meant the P 50 value obtained at the actual *plasma pH* without correction to pH 7 40

Table

Deviation of P 50 stand P 50 ery P 50 act pH pl and pH ery after addition to whole blood of increasing amounts of Urografin 60 and Amipaque Each figure represents the mean of 6 single analyses obtained in 6 volunteers N signifies the number of single analyses performed r is the correlation coefficient measuring the change in the above variables with increasing concentration of contrast medium and p gives the significance limits

ml/1 ml blood	P 50 stand	P 50 ery	P 50 act	pH pl	pH ery
Urografin 60					
0 005	0 05	+0 03	0 05	−0 03	−0 01
0 01	0 08	0 04	+0 03	−0 03	−0 0
0 02	0 15	0 04	+0 07	0 06	−0 01
0 04	0 37	0 0	0 08	−0 12	−0 02
0 06	0 48	0 0	+0 05	0 15	−0 01
N	30	30	30	30	30
r	0 79	0 01	0 02	0 90	0 01
p	0 001	0 1	0 1	< 0 001	0 1
Amipaque					
0 005	−0 08	−0 07	0 01	0 02	−0 01
0 01	0 11	0 07	−0 03	0 02	−0 02
0 02	0 04	0 03	0 04	−0 02	−0 02
0 04	0 32	−0 17	0 16	0 05	−0 01
0 06	−0 23*	+0 01*	0 0*	−0 06	−0 01
N	29	29	29	30	30
r	0 38	0 02	0 11	0 68	0 16
p	0 05	0 1	0 1	0 001	> 0 1

* mean of 5 observations

Intra erythrocytic pH Two capillary tubes with an inner diameter of 2 5 mm were used for each measurement One end was closed with putty the tube was filled with blood and centrifuged at 1 100 *g* for 10 *min (occluded end down)* After repeated thawing and freezing a clear hemolysate was obtained The plasma containing part of the tube was sawn off and the pH of the hemolysate determined

Results

In the blood without additive from the 12 volunteers P 50 stand P 50 ery and P 50 act ranged from 3 14 to 3 75 from 2 83 to 3 84 and from 3 18 to 4 04 kPa respectively pH pl ranged from 7 34 to 7 43 and pH ery from 7 08 to 7 23

A significant decrease in P 50 stand and pH plasma occurred when increasing amount of Urografin 60° was added to the blood but no change in P 50 ery P 50 act or pH ery Also when Amipaque was used similar results were obtained a significant decrease in pH plasma and in P 50 stand but P 50 ery P 50 act and pH ery were not affected However when maximum amount of Amipaque was added to

the blood the pH plasma was significantly less affected than when Urografin 60 % was used ($p<0.0025$) and P 50 stand was also less affected when Amipaque was used ($p<0.01$) (Table)

Discussion

The oxygen affinity of hemoglobin is affected by the four physiologic ligands i e protons CO_2 2 3 DPG and CO pH is usually measured in plasma and it is assumed that a change in plasma pH is accompanied by a concomitant change in intra erythrocytic pH The relation between plasma pH and intra-erythrocytic pH on addition of acid or alkali to blood was described by LICHTMAN et coll who emphasized that impenetrant non ionic compounds such as sucrose and poorly penetrating anionic contrast media such as Hypaque 50 and Renografin 76 cause a redistribution of anions by creating diffusion potentials This results in acidification of plasma and reduction in extracellular pH while only slight if any increment in intra erythrocytic pH occurs In this situation plasma pH cannot be used to estimate oxygen affinity because the affinity of hemoglobin for oxygen is influenced by the intra erythrocytic pH P 50 stand thereby becomes factitiously low If however the P 50 value is determined using the intra-erythrocytic pH no significant change occurs

The present investigation confirms the results of LICHTMAN et coll and shows that similar changes although of less magnitude are caused by the non ionic contrast medium Amipaque The decrease in P 50 stand on addition of Urografin 60 % and Amipaque is thus an artifact and shows the importance of measuring the intra erythrocytic pH If attention is paid to this no change in oxygen affinity occurs nor is P 50 act affected This parameter more truly reflects the real oxygen affinity than P 50 stand under these experimental conditions

In the present investigation Amipaque at highest dose produced significantly less ($p<0.0025$) change in plasma pH than Urografin 60 % This difference may be explained by the fact that the non ionic Amipaque solution has a lower buffer capacity than ionic Urografin solution It also has a lower osmolality which causes a less marked redistribution of anions between plasma and red cells and hence a less marked decrease in plasma pH

Acknowledgement

Thanks for laboratory facilities are extended to Professor S F Lindell Department of Clinical Physiology Malmo Allmanna Sjukhus The present investigation was partly supported by the Swedish Medical Research Council (Project No 3483)

SUMMARY

The effects on whole blood oxygen affinity following addition to human blood of either ionic (diatrizoate) or non ionic (metrizamide) contrast medium were investigated in vitro No medium changed whole blood oxygen affinity Solutions of metrizamide produced less

changes in plasma pH than solutions of diatrizoate This difference is explained by lower buffer capacity and lower osmolality of metrizamide solutions Low osmolality gives less redistribution of anions between plasma and red cells and therefore less decrease in plasma pH

ZUSAMMENFASSUNG

Die Wirkung auf die Gesamt Blut Sauerstoff Affinitat des menschlichen Blutes nach Zugabe von entweder ionisiertem (Diatrizoat) oder nicht ionisiertem (Metrizamid) Kontrast mittel wurde untersucht Losungen von Metrizamid verursachten weniger Veranderungen in Plasma pH als Losungen von Diatrizoat Diese Differenz erklart sich aus der niedrigeren Pufferkapazitat und der niedrigeren Osmolalitat von Metriziamid Losungen Niedrige Osmolalitat fuhrt zu einer geringeren Redistribution von Anionen zwischen Plasma und roten Blutkorperchen und vermindert deshalb weniger das Plasma pH

RESUME

Les auteurs ont etudie in vitro l effet sur l affinité pour l oxygène du sang complet apres addition au sang humain de moyens de contraste soit ionique (Diatrizoate) soit non ionique (Métrizamide) Aucun moyen de contraste ne modifie l affinite pour l oxygène du sang complet Les solutions de Metrizamide produisent des changements moins importants du pH du plasma que les solutions de Diatrizoate Cette difference s explique par une moindre capacite de tampon et une osmolalité inferieure des solutions de metrizamide La faible osmolalite donne moins de redistribution des anions entre le plasma et les hématies et diminue donc moins le pH du plasma

REFERENCES

HILL A V The possible effects of the aggregation of the molecules of haemoglobin on its dissociation curves J Physiol (Lond) 40 (1910) 4

HOLMGREN A and PERNOW B Spectrophotometric measurement of oxygen saturation of blood in the determination of cardiac output A comparison with the van Slyke method Scand J clin Lab Invest 11 (1959) 143

LICHTMAN M WHITBECK A and MURPHY M Factitious changes in binding of oxygen to hemoglobin when based on extracellular pH in the presence of certain blood additives like radiographic contrast media Invest Radiol 10 (1975) 225

METRIZAMIDE—a non ionic water soluble contrast medium Acta radiol (1973) Suppl No 335

ROSENTHAL A LITWIN S and LAVER M Effect of contrast media used in angiocardiography on hemoglobin-oxygen equilibrium Invest Radiol 8 (1973) 191

SEVERINGHAUS J Blood gas calculator J appl Physiol 21 (1966) 1108

SUNDSTROM G Blood carboxyhemoglobin Results with conventional standards compared with those with a submicroliter reference of gaseous CO Clin Chem 18 (1972) 188

FROM THE MUNICIPAL PUBLIC HEALTH SERVICE CENTRE (DIRECTOR TERO SALMENPERA)
SF 26100 RAUMA FINLAND

LECITHINE AS AN ADJUVANT IN RESORPTION OF CONTRAST MEDIUM IN ORAL CHOLECYSTOGRAPHY

ILMARI LINDGREN

A considerable controversy regarding the preparation of the patient for chole cystography still persists According to most manufacturers instructions and to some standard text or handbooks (SCHINZ et coll 1952 PAUL & JUHL 1972 SAXTON & STRICKLAND 1972) the patient should be fasting or on a fat free diet before the ex amination The reason for this seems to be obscure and the arguments in its favour have not been clearly stated On the other hand PARKIN (1974) MOUZON et coll (1975) and SHOPFNER (1975) have shown that a significantly better filling of the gall bladder occurs after a fatty meal than after a fat free meal

This is especially true in the case of iopanoic acid (Telepaque) (STANLEY et coll 1974) Bile salts form micelles which are capable of increasing the solubility of water insoluble substances by their detergent like property Iopanoic acid like other cholecystographic contrast media is insoluble in water but soluble in lipids A marked increase in the aqueous solubility of iopanoic acid in bile salt solutions has been demonstrated in vitro In experiments on dogs intestinal resorption of the contrast medium in the presence of bile salts increased (BERK et coll 1974) Observa tions in man show that when bile salts are sequestrated by an anion exchange resin (Secholex) poor or no filling at all of the gallbladder is obtained (LINDGREN 1976) Cholestyramine seems to have a similar effect (NELSON 1974) Thus it would appear

Submitted for publication 10 February 1977





Fig 1 Poor contrast filling of the gallbladder of a 41 year old man after an unrestricted meal and 3 g of Solu Biloptin

Fig 2 Same case Well filled gallbladder at repeat examination 18 days later following an unrestricted meal and administration of 3 g of Solu Biloptin and 13 g of lecithine

Fig 1 Fig 2

that bile salts are necessary for the intestinal resorption of cholecystographic contrast media They are apparently resorbed similarly to fatty acids which are resorbed as micelles on the microvillar surfaces However the formation of micelles requires the presence of detergents Pure bile salts lower the interfacial tension of an oil water interface only moderately and are poor emulsifiers (DASHER 1952) The addition of an amphipathic polar lipid such as lecithine and fatty acid results in a much greater lowering of the interfacial tension and the resultant mixture has a higher emulsifying power (HOFMANN 1968) It is probable that the triglyceride and the cholecystographic contrast medium entering the small intestine are emulsified by a mixture of lecithine and bile salts in bile Therefore it might be presupposed that in case of poor contrast filling of the gallbladder the addition of lecithine would improve the filling by increasing the resorption of the contrast medium

Method

Twenty one patients from an out patient radiology department with poor or no filling of the gallbladder at cholecystography were examined once again The minimum interval between the first and the second examination was at least 10 days in order to avoid the effect of the first one The preparation of the patients before the examination was identical in both examinations they were instructed to refrain from eating and drinking following an unrestricted evening meal (at 6–7 p m) Smoking and drinking were not allowed At 9 p m 3 g of calcium ipodate (Solu Biloptin Schering) were given usually 2 to 3 hours after the evening meal and at the same time 13 g of lecithine in the form of magasin de la sante preparation (Biolecin Salco Finland) This preparation consisted of Lecithine 13 % Aethanol 11 5 % Fructose 25 % purified water 49 % Corrigentia q s

The lecithine (Lucas Meyer Hamburg Germany) in this preparation was ex

tracted from soya beans The radiography commenced at 9 a m the following morning A standard examination technique was used with films in erect and supine positions The films were exposed with 75 kV 640 mA and 0 032 to 0 04 s Kodak Lanex Regular intensifying screens were used

Results

On the first examination poor contrast filling of the gallbladder was obtained in 15 patients and no filling at all in 6 At the second examination good contrast filling was obtained in all subjects The difference between the first and the second examination was unequivocal (Figs 1 2) No stones or other gallbladder pathology were found No untoward reactions from the contrast medium and the added lecithine were recorded

Comment

Lecithine is a normal component of human blood brain tissue and bile The biliary lecithine plays an important role together with bile salts in the resorption of fatty acids from the intestinal lumen This happens by way of emulsification and micelle formation (HOFMANN) The present results indicate that lecithine favours even the resorption of cholecystographic contrast media from the intestine Thus it may be concluded that both bile acids and lecithine are necessary for the resorption of the cholecystographic contrast media and the mechanism is the same as that for the resorption of fatty acids The poor contrast filling of the gallbladder in the first examination may be explained by the fact that fasting resulted in insufficient secretion of bile salts or biliary lecithine or both and a total lack of dietary lecithine necessary for intestinal resorption The addition of lecithine to the cholecystographic contrast media is strongly recommended Since the price of the lecithine is low compared with the total cost of the examination its addition would appear to be justified in order to obtain a more consistently satisfactory result Similarly the addition of bile salts should theoretically be of benefit An endeavour to improve the barium meal with the aid of bile salts and lecithine has been made with promising results (LINDGREN et coll 1978)

SUMMARY

No or poor filling of the gallbladder was obtained in 21 patients at cholecystography They were re-examined after 10 days or later with the addition of lecithine to the contrast medium The filling of the gallbladder which was without abnormality was improved in all cases The mechanism of this effect is discussed

ZUSAMMENFASSUNG

Bei 21 Patienten wurde keine oder eine schlechte Füllung der Gallenblase während der Cholezystographie erhalten Diese wurden nach 10 Tagen oder später erneut mit Zugabe

von Lecitin zum Kontrastmittel untersucht Die Fullung der Gallenblase die ohne pathologische Veranderungen war war in allen Fallen verbessert Der Mechanismus dieses Effekts wird diskutiert

RÉSUME

Une opacification mauvaise ou nulle de la vesicule biliaire a eté obtenue chez 21 malades par cholecystographie Ils ont été réexaminés 10 jours après ou plus tard avec addition de lecithine au moyen de contraste Le remplissage de la vèsicule biliaire qui etait sans anomalie a ète ameliore dans tous les cas L auteur examine le mécanisme de cet effet

REFERENCES

BERK R N LOEB P M GOLDBERGER L E and SOKOLOFF J Oral cholecystography with iopanoic acid New Engl J Med 290 (1974) 204

DASHER G F Surface activity of naturally occurring emulsifiers Science 116 (1952) 660

HOFMANN A F Functions of bile in the alimentary canal *In* Handbook of physiology Section 6 Alimentary canal Volume V p 2507 American Physiological Society Washington D C 1968

LINDGREN I A cause of non opacification of the gall bladder Treatment with Secholex Brit J Radiol 49 (1976) 734

— NEVALAINEN T and MAKI J Scanning electron microscopy of the spreading of barium sulfate suspensions on the gastric mucosa of the rat Effect of wetting agents bile salt and lecithine Acta radiol Diagnosis 19 (1978) 361

MOUZON A DOYON D JOUNDE L VADROT D et POMARÈDE D Préparation inhabituelle lors de la cholécystographie le repas gras J Radiol Electrol 56 (1975) 604

NELSON J A Effect of cholestyramine on Telepaque oral cholecystography Amer J Roentgenol 122 (1974) 333

PARKIN G J Dietary preparation for oral cholecystography a critical reappraisal Brit J Radiol 470 (1974) 452

PAUL W L and JUHL J H The essentials of roentgen interpretation Harper & Row Publishers Hagerstown Maryland 1972

SAXTON H M and STRICKLAND B Practical procedures in diagnostic radiology Lewis London 1972

SCHINZ H R BAENSCH W E FRIEDL E und UEHLINGER E Lehrbuch der Rontgendiagnostik Band IV Innere Organe p 3498 Georg Thieme Stuttgart 1952

SHOPFNER C E Cholecystographic modifications to improve initial study opacification J Amer med Ass 234 (1975) 479

STANLEY R J MELSON G L CUBILLO E and HESKER A E A comparison of three cholecystographic agents A double blind study with and without a prior fatty meal Radiology 112 (1974) 513

FROM THE SECTION FOR MAXILLO-FACIAL ROENTGENOLOGY DEPARTMENT OF RADIOLOGY
CENTRALLASARETTET S 961 19 BODEN SWEDEN

POSITION, FORM, AND THICKNESS OF THE IMAGE LAYER IN NARROW BEAM ROTATION RADIOGRAPHY

A SJÖBLOM and U WELANDER

Narrow beam rotation radiography is essentially based on a specific projection technique (HECKMANN 1939 1967 WELANDER 1974) The rotation centre of the continuously moving beam acts as the functional focus of the projection of the object usually the jaws Incorporated in the technique is also the formation of a layer which although not tomographic according to definitions given by EDHOLM (1960) and by WELANDER (1975) has certain similarities to a tomographic layer

It was empirically put forward by TAMMISALO & NIEMINEN (1964) that the position of the centre of the sharply depicted object plane is dependent on the ratio between the velocity of the film in relation to the beam and the velocity of the beam in relation to the object With this as the basis TAMMISALO (1964) analysed mathematically the position and form of the image layer in images exposed with one specific equipment the Orthopantomograph 2 A mathematical deduction later on confirmed by ex perimental tests has shown that the empirical postulation quoted above is correct (WELANDER 1974 WELANDER & WICKMAN 1977) A further experimental confirma tion was recently presented by OGURA et coll (1977) The form and thickness of the image layer created by different equipment designed for narrow beam rotation radio graphy has also been analysed experimentally by among others LUND & MANSON HING (1975 a b)

In spite of several communications on the position form, and other characteristics of the image layer in narrow beam rotation radiography some confusion still seems

Submitted for publication 1 September 1977

to persist and apart from the report of TAMMISALO no mathematical analysis is available in the literature OGURA et coll also point out that if the linear speed of the film could be optionally controlled and the location of the desired layer determined an optimum panoramic imaging system could be achieved

Therefore it was considered of value to extract this particular subject in the image formation in narrow beam rotation radiography and to analyse the factors determining the position and form of the image layer mathematically The purpose was also to analyse the relationship between the position of the image layer its magnification and the layer thickness

Mathematical analysis

Definitions (See Fig 1)

A = distance tube target to film

D = distance tube target to the centre of the sharply depicted object plane

C = distance tube target to the rotation centre of the beam

r = distance from the rotation centre of the beam to the centre of the sharply depicted object plane object projection radius

Δr = positive of negative increment to the object projection radius

b_f width of the beam at the film

M magnification factor in the centre of the sharply depicted object plane

M_a = magnification factor in the rotation plane around the centre of the sharply depicted object plane

v = velocity of the beam in relation to the object

v_f = velocity of the film in relation to the beam

U_{wr} = relative length of a theoretically ideal line spread function relative value of the characteristic blurring of narrow beam rotation radiography

z = thickness of the image layer

The specific characteristics of narrow beam rotation radiography are found in the rotation plane and the conditions in this plane only will be considered in the following A theoretical model of the method based on a circular movement system will be used in the fundamental calculations The curvature of the object and the beam within the narrow beam will be neglected (TAMMISALO & NIEMINEN 1964) Furthermore the tube target will be considered a point source

Equations

It has previously been demonstrated that the centre of the sharply depicted image layer is created in narrow beam rotation radiography (TAMMISALO & NIEMINEN 1964 TAMMISALO 1964 WELANDER 1974 1975) where

(1)

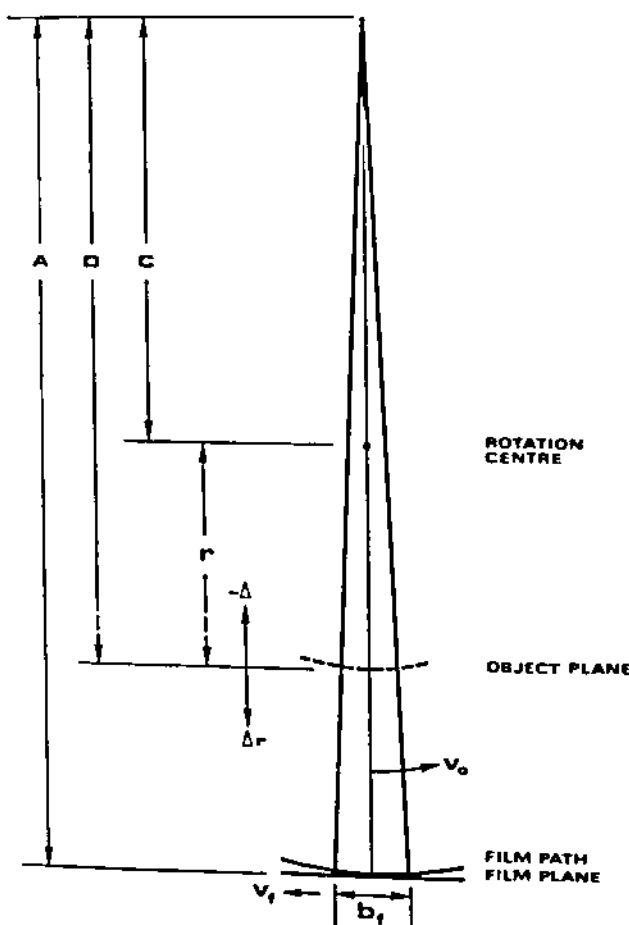


Fig 1 Essential parameters in circular narrow beam rotation radiography when calculating the position and form of the image layer In relation to the beam the film moves in the reversed direction

According to definitions D is expressed by C + r thus after substitution and removal of r the following expression is obtained

$$r = \frac{Av}{v_f} - C \tag{2}$$

The solution of eq (2) gives the length of the object projection radius and thereby also the position of the centre of the sharply depicted object plane

Using the relative value of the blurring the layer thickness is expressed by (WELANDER 1975 WELANDER & WICKMAN 1977)

$$z = 2\left|\frac{rAU_w}{b_f(r-D)}\right| = \frac{2rAU_{wr}}{b_f C} \tag{3}$$

The magnification factor in the rotation plane is expressed by (WELANDER 1974 WELANDER & WICKMAN 1977)

$$M_a = \frac{Ar}{(C+r)(r+\Delta r)} \tag{4}$$

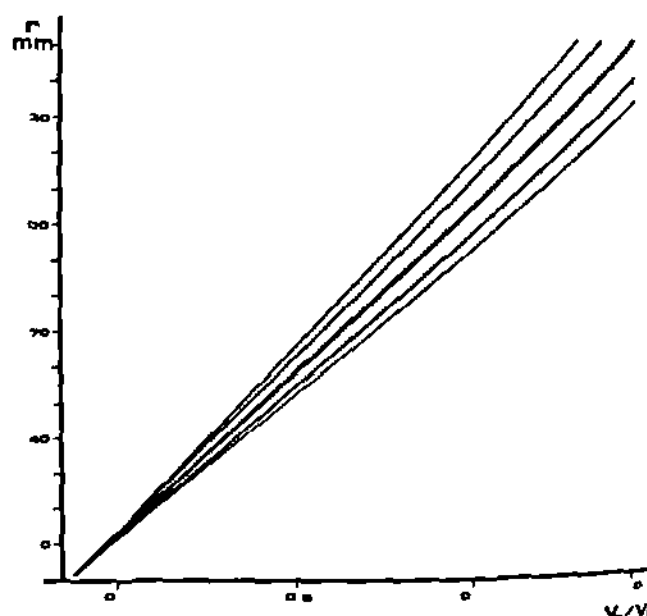


Fig 2 The object projection radius r as a function of the ratio between the velocity of the beam and the film v_o/v_f (thick line) The resulting layer thickness is marked outer borders are valid for the tolerable blurring $U_{wr}=0.5$ mm inner borders are valid for $U_{wr}=0.3$ mm The functions are valid for a theoretical circular movement system $A=460$ mm $C=310$ mm $b_f=6$ mm

In the specific case when $\Delta r=0$ eq (4) gives the magnification factor in the centre of the sharply depicted object plane for any given object projection radius

$$M=\frac{A}{C+r}=\frac{A}{D} \tag{5}$$

Calculated results

When the distance between the tube target and the film and the tube target and the rotation centre of the beam are constant the position of the centre of the object plane or the centre of the sharply depicted image layer is determined by the ratio v_o/v_f i e the ratio between the velocities of the beam and the film The layer thickness is however proportional to the object projection radius cf eq (3) Thus there is an apparent interdependence between the projection radius which is a measure of the position of the centre of the object plane and the layer thickness This interdependence is graphically illustrated in Fig 2 It appears that when the ratio v_o/v_f increases the object projection radius increases and following this the layer thickness also increases

In a circular movement system the object plane or image layer may be placed at any position between the rotation centre of the beam and the film When the ratio v_o/v_f is low i e when the velocity of the film is great in relation to the velocity of the beam the object projection radius is small and the sharply depicted image layer is narrow When the ratio $v_o/v_f=1$ the centre of the image layer coincides with the film plane the layer thickness reaches its theoretical maximum value at a short distance in

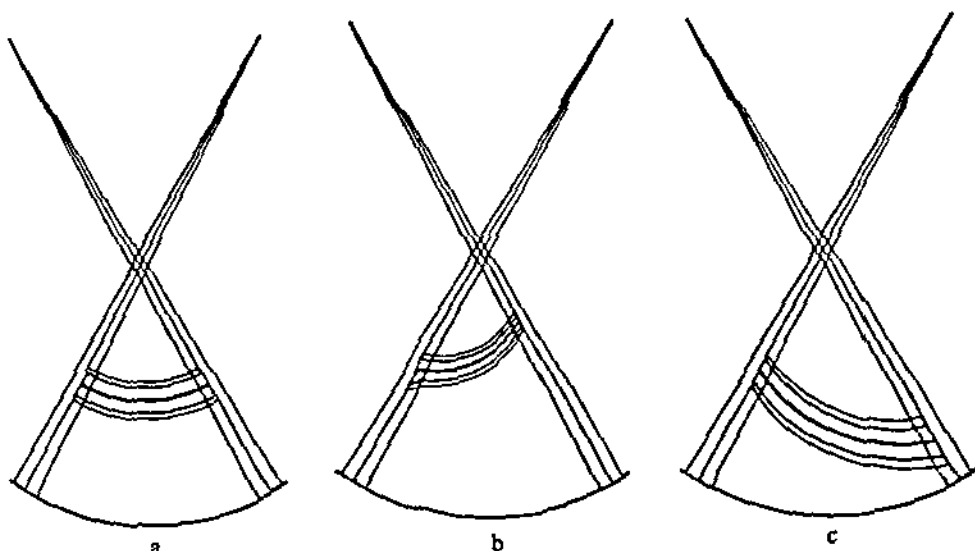


Fig. 3 Position and layer thickness in a circular movement system a) Ratio between the velocities of the beam and the film is constant during the exposure The layer is circular and the thickness of the image layer constant b) Film speed accelerated during the exposure The image layer is successively displaced towards the rotation centre of the beam the layer thickness decreases successively c) Film speed retarded during the exposure The image layer is successively displaced towards the film the layer thickness increases Outer borders of the layer are valid for $U_{wr} = 0.5$ mm inner borders are valid for $U_{wr} = 0.3$ mm Basic data are the same as in Fig. 2

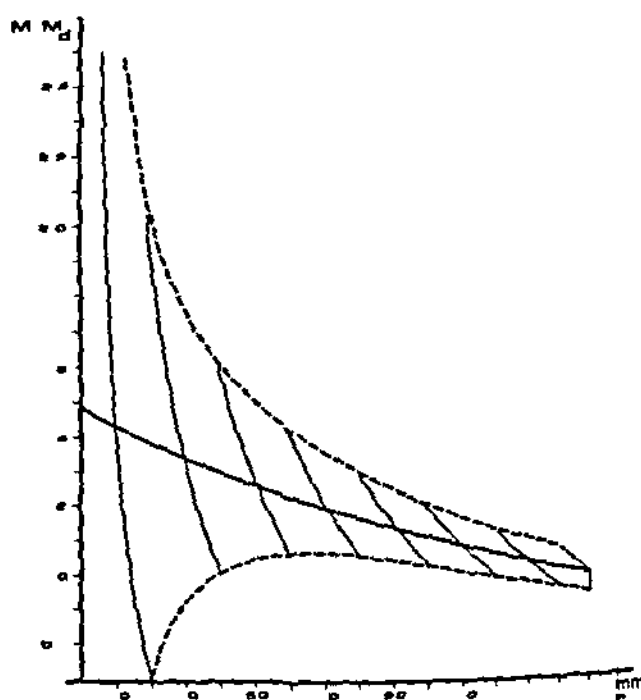
front of the film plane this distance being dependent on the definition of the tolerable blurring of the image

The circular movement system creates a circular image layer only when the ratios A/C and v /v_f are constant during the exposure (Fig 3 a) The effects of acceleration and retardation of the film speed in relation to the beam are illustrated in Fig 3 b and c respectively Acceleration of the film speed displaces the position of the image layer successively towards the rotation centre of the beam and simultaneously the layer thickness decreases Retardation of the film speed has the opposite effect

Variation of the object projection radius results in varying magnification of the image In this connection two different magnification effects interact but should be separated First an increase in the length of the object projection radius successively decreases the magnification factor at the centre of the sharply depicted object plane cf eq (5) this magnification factor M expresses the average magnification of the total image Secondly a positive or negative increment to the object projection radius results in a relatively marked variation of the magnification factor M_d outside the centre of the sharply depicted object plane cf eq (4) this second magnification factor expresses the variation of the magnification within the image layer The interaction between the magnification factors M and M_d as functions of r and Δr is illustrated in Fig 4

Elliptical movement systems In principle the above analysis is applicable also to elliptical narrow beam rotation radiography but in this case mathematical calcula

Fig 4 The magnification factor M as a function of the object projection radius r (thick line) At the centre of the sharply depicted object plane the magnification factor decreases as the object projection radius increases Outside the sharply depicted object plane the variation of the magnification factor M_d is relatively marked which is represented by thin lines for object projection radii of 10 30 50 70 90 110 130 and 150 mm the functions are valid within the limits Δr − 10 mm (upper broken line) and Δr ~ 10 mm (lower broken line) Basic data equal to those in Figs 2 and 3



tions will lead to more complex expressions The equations valid for circular movement systems may however be applied to elliptical systems when the following expression is used for substitution (SAMFORS et coll 1977)

$$C = k - \frac{a}{b}\left(1 \quad \frac{(a^2 - b\ )x}{a^4}\right)^{1\,5}$$

where k denotes the distance between the tube target and the ellipse

Analogous to circular movement systems elliptical movement may be utilized to create an image layer of the desired form by adjusting the ratio v_o/v_f accordingly A theoretical example is demonstrated in Fig 5 where an elliptical movement is the basis but the centre of the image layer is given a true parabolic form

Discussion

It is self-evident that the direction of the beam in every part of its movement is the factor that determines the projection of the object in narrow beam rotation radiography In circular systems the rotation centre of the beam thus constitutes a functional focus of the projection In the case of elliptical movement systems it is the evolute of the ellipse that forms a functional focus which slides along the evolute during the exposure (WELANDER 1974 SAMFORS et coll 1978) The position of the image layer is however mainly dependent on the velocities of the film and of the

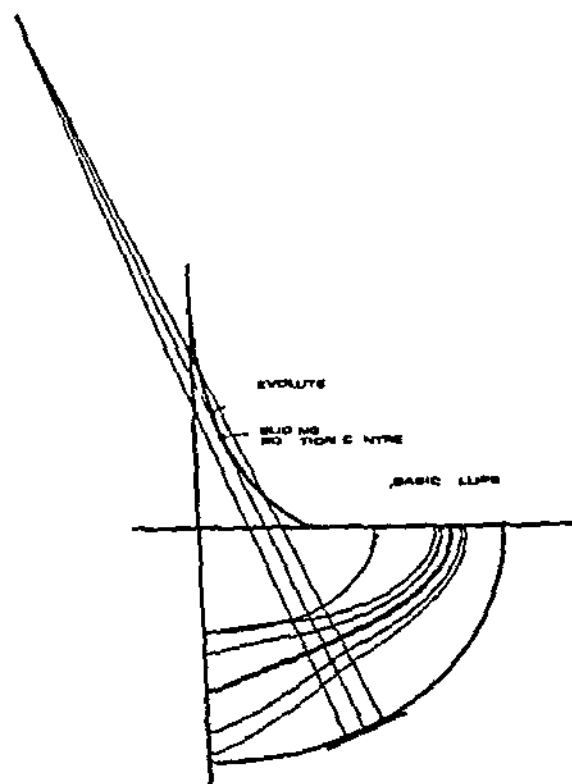


Fig 5 In a basic elliptical movement system a theoretical example is demonstrated where the centre of the image layer is given a true parabolic form The resulting layer thickness is marked when $U_{wr} = 0.5$ mm and 0.3 mm outer and inner borders respectively

beam Thus the projection of the object and the position of the sharply depicted object plane are governed by parameters which within certain limits may be varied irrespective of each other Consequently circular elliptical or any other basic movement system does not give an image layer of the corresponding form

In the centre of the sharply depicted image layer the magnification factor will be constant in all parts of the image provided that the ratio between the distances tube target to film and tube target to object is constant during the exposure (Fig 3 a) When the ratio between the velocities of the film and the beam is varied during the exposure a series of image characteristics varies and the position the form the magnification and the thickness of the image layer is changed In future development of narrow beam rotation radiography one important aim should be to find an optimum compromise considering all the aforementioned image characteristics

SUMMARY

The parameters which determine the position form and thickness of the image layer in narrow beam rotation radiography are analysed mathematically The interdependence between the aforementioned image characteristics is described

ZUSAMMENFASSUNG

Die Parameter welche die Lage Form und Dicke der Bildebene bei der Rotationsradiographie mit einem feinen Strahl bestimmen werden mathematisch analysiert Die Abhangigkeit zwischen den oben genannten Bild Charakteristika wird beschrieben

RÉSUME

Les auteurs etudient mathématiquement les paramètres qui déterminent la position la forme et l epaisseur de la couche d image en radiographie rotatoire avec faisceau étroit Ils decrivent l interdependance entre les caractéristiques d images mentionnées ci dessus

REFERENCES

EDHOLM P The tomogram Its formation and content Acta radiol (1960) Suppl No 193

HECKMANN K Die Rontgenperspektive und ihre Umwandlung durch eine neue Aufnahmetechnik Fortschr Rontgenstr 60 (1939) 144

— Pseudofokale und bivisuelle Aufnahmetechnik Kapitel VIII *In* Handbuch der medizinischen Radiologie Band III Redigiert von Vieten H Springer Verlag Berlin Heidelberg New York 1967

LUND T M and MANSON HING L R (a) A study of the focal throughs of three panoramic dental x ray machines Part I The area of sharpness Oral Surg 39 (1975) 318

— — (b) Part II Image dimensions Oral Surg 39 (1975) 647

OGURA K KANNO T SUZUKI Y and SHIMANO T Changes in image layer due to variable film speed in pantomography Paper read at The 4th International Congress of Dento-Maxillo Facial Radiology Malmo 1977

SAMFORS K A WELANDER U and WICKMAN G Elliptical narrow beam rotation radiography Acta radiol Diagnosis 19 (1978) 129

TAMMISALO E H Determination of the form of the image layer and calculation of its location in orthopantomography Suom Hammaslaak Toim 60 (1964) 14

— and NIEMINEN T The thickness of the image layer in orthopantomography Suom Hammaslaak Toim 60 (1964) 119

WELANDER U A mathematical model of narrow beam rotation methods Acta radiol Diagnosis 15 (1974) 305

— *Layer formation in narrow beam rotation radiography* Acta radiol Diagnosis 16 (1975) 529

— and WICKMAN G Blurring and layer thickness in narrow beam rotation radiography Acta radiol Diagnosis 18 (1977) 705

ACTA RADIOLOGICA

PUBLISHED BY THE SOCIETIES OF MEDICAL RADIOLOGY IN
DENMARK, FINLAND NORWAY AND SWEDEN

Vol 19 DIAGNOSIS 1978
Fasc 5

COMPUTER TOMOGRAPHY OF THE BRAIN AND SPECTROPHOTOMETRY OF THE CSF IN CEREBRAL CONCUSSION AND CONTUSION

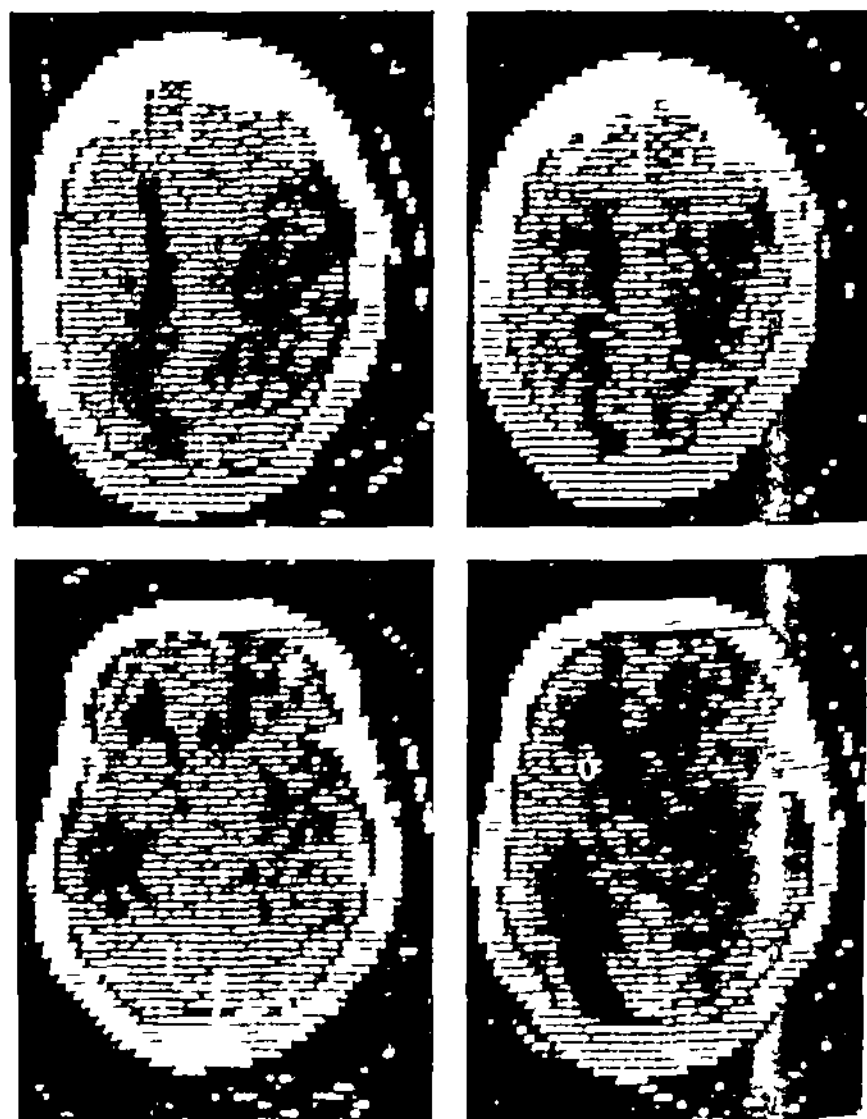
U Bergvall K G Kjellin B Levander P Svendsen and C E Söderström

In various reports (Ambrose 1973 New et coll 1974 Levander et coll 1975, Kazner et coll 1975) the computer tomography (CT) appearances of intra and extracerebral haematomas have been described The nature of these lesions is often and easily confirmed at operation or autopsy which for obvious reasons is not the case with cerebral concussion and contusion In a previous report on traumatic head injuries (Levander et coll) post mortem confirmation was obtained in only one out of 5 cases of cerebral contusion diagnosed clinically (Fig 1)

The CT appearance of a cerebral contusion has been described as regions of increased attenuation merged with regions of decreased attenuation often with an increase in volume of the injured part of the brain (Fig 2) (New et coll Levander et coll Kazner et coll) (Fig 1) Ambrose et coll (1976) described the CT appearance of cerebral contusion as areas of low density On the other hand Merino-deVilla sante & Taveras (1976) were of the opinion that a contusion appeared as a heterogeneous area with an average density higher than that of surrounding normal tissue

In an attempt to evaluate the diagnostic significance of CT in cerebral concussion and contusion clinically diagnosed the CT findings were compared with clinical data and the results of quantitative CSF spectrophotometry (CSF SPE) devised by Kjellı ı (see Kjellin & Söderström 1974 for references)

From the Departments of Neuroradiology Neurology and Neurosurgery Karolinska Sjukhuset S-104 01 Stockholm and Diagnostic Radiology Sahlgrenska Sjukhuset S-413 45 Gothenburg Sweden Financial support was obtained from the Goteborg Medical Society and the Swedish Cancer Soc e y Submitted for publication 21 February 1977



..g 1 Cerebral contusion in the right frontal and temporal region confirmed at autopsy (Not included in the present series)

Spectrophotometry of CSF has an extremely high sensitivity in detecting xanthochromic substances which makes the method suitable for the diagnosis of intracranial bleedings Different appearances of bleeding at CSF SPE were described by KJELLIN & SÖDERSTRÖM (1974) and labelled with the symbols H (haematoma curve) and S (subarachnoid haemorrhage curve) (Fig 3)

The S curve is characterized by the successive transformation of oxyhemoglobin released at the haemolysis of red cells into bilirubin The S curve may be further subdivided into S_1 and S_2 curves during the first week after onset of disorder



Fig 2 Cerebral contusion in the right cerebellar hemisphere mixing of areas of increased and decreased attenuation The CSF SPE showed a S_2-curve

(KJELLIN & SÖDERSTRÖM 1974) The differences between the shape of these latter curves are related to the time between onset and lumbar puncture The S curve looks older than the corresponding S_1-curve i e the ratio of bilirubin to oxyhaemo globin is greater The S_1 shape is found in bleedings to the subarachnoid space as in aneurysm haemorrhage The S shape is predominantly found in diffuse bleedings to the extracellular space as in cerebral contusion the conceivable reason being that the decomposition of oxyhaemoglobin to bilirubin to a great deal occurs already *in the extracellular space Combination of S and H appearance occurs the latter* indicating the presence of haematoma in addition to bleeding into the subarachnoid (S_1) or extracellular (S_2) spaces

Material and Method

Patients admitted between January 1974 and April 1976 with recent head trauma examined with CSF SPE and with CT constitute the present series On admission all patients were clinically classified by a neurologist or a neurosurgeon as cerebral con cussion or cerebral contusion Criterion of cerebral concussion was unconsciousness of less than 30 min duration and of contusion more than 30 min No attention was given to the presence or duration of post traumatic or retrograde amnesia

Patients with angiographic or CT diagnosis of intracerebral subdural or epidural haematomas were usually operated upon shortly after the trauma and not examined

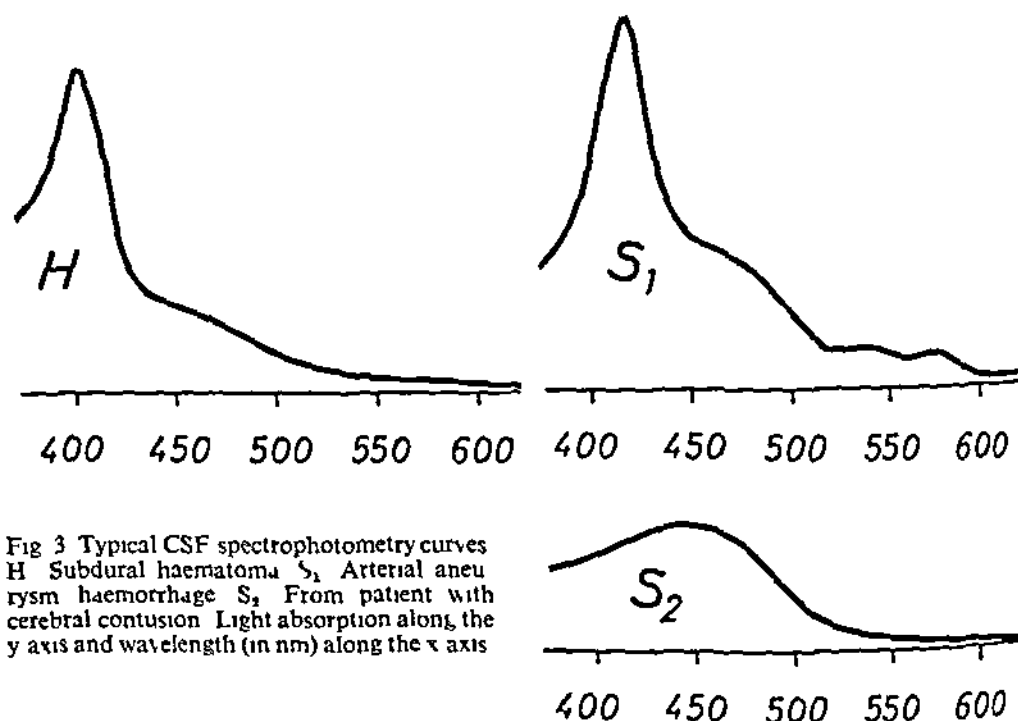


Fig 3 Typical CSF spectrophotometry curves H Subdural haematoma S_1 Arterial aneurysm haemorrhage S_2 From patient with cerebral contusion Light absorption along the y axis and wavelength (in nm) along the x axis

with CSF spectrophotometry they were thus excluded from the series Patients with CSF examination performed later than 7 days after the trauma were also excluded Thirty patients with the clinical diagnosis of cerebral concussion or contusion remained CT was usually performed in close connection with the CSF analyses Only 8 patients were scanned later than 4 days after the CSF examination

In this series the CT appearance of cerebral contusion has been defined as regions of decreased attenuation merged with regions of increased attenuation or diffuse regions of only decreased attenuation Diffuse areas of only increased attenuation were also looked for

Results

Out of 9 CT contusions with regions of varying attenuation 5 had mainly decreased and 2 mainly increased attenuation while 2 had about equally distributed regions of decreased and increased attenuation A further 4 patients had only unsharp foci of decreased attenuation This accounts for the 13 patients with CT contusion 11 of whom had S-curves at CSF SPE No patient had CT lesions of only increased attenuation

Out of the 20 patients with typical S curves 11 also had CT evidence of contusion (Fig 2) The majority of these patients was scanned within 4 days after CSF SPE and only 3 patients at a later stage (after 6 6 and 12 days respectively) Of the 8 patients without contusion at CT 6 were scanned within 4 days after CSF SPE

Table 1

Nine patients with S_2-curve at CSF SPE but no evidence of contusion at CT (N = normal)

Day of examination after trauma		Diagnosis	
CSF	CT	CT	Clinical
3	15	N	Contusion
4	18	N	Contusion
3	3	Epidural	Contusion
7	6	N(+hydrocephalus)	Contusion
4	4	N	Contusion
1	2	N	Contusion
5	5	N	Concussion
1	1	N	Concussion
1	1	N	Concussion

2 were scanned after 12 and 14 days respectively and comparison is therefore not valid One patient (Fig 4) had no evidence of cerebral contusion at CT but an epidural haematoma was confirmed at operation

In the group of 10 patients with no S curve at CSF SPE 2 had CT evidence of contusion one of these was scanned 22 days after the injury and had CSF SPE indication of a haematoma which could not be diagnosed at angiography The final clinical diagnosis in this patient was cerebral contusion In the second of these patients CSF SPE displayed a non specific S curve

Seven of the 8 patients (Table 2) without S_2 curve and without CT evidence of contusion had a completely normal CT one patient with a mixed (S+H) appearance of the CSF SPE curve indicating the presence of a haematoma had CT findings considered to be bifrontal hygromas At operation a left frontal chronic subdural haematoma and a right frontal hygroma were found Two patients in this group had CSF SPE indications of blood brain barrier lesion which might point to a cerebral concussion One further patient with a curve shape of S_t+H (Table 2) possibly caused by a ruptured aneurysm with a haematoma was 85 years old He recovered and no further examinations were carried out The remaining 4 patients in this group had normal CSF SPE findings

In this series 8 patients were clinically classified as having cerebral concussion (Table 3) All of these had normal CT 4 had normal CSF and one had evidence of a barrier lesion indicating a minor brain injury Three of the patients had spectro photometry S_2 curve consistent with minor cerebral contusions

In the entire material only 4 patients had severe lesions other than cerebral con tusion (Table 4) These lesions were all diagnosed at CT One patient had a small intracerebral haematoma which was not operated upon Another had an intracerebral haematoma and a cerebral contusion diagnosed by CT the day after the trauma

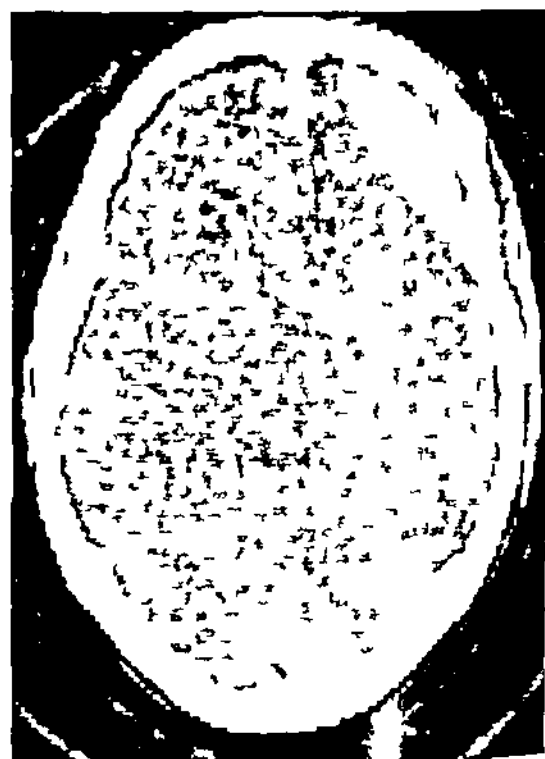


Fig 4 Right frontal epidural haematoma confirmed at operation No evidence of contusion at CT The CSF SPE showed S_2-curve

The haematoma was evacuated and the CSF SPE analysis 4 days after the trauma displayed a typical S_2 curve which is difficult to evaluate after open surgery Finally 2 patients had surgically confirmed epidural haematomas CT in one of them disclosed a cerebral contusion as well but in the other no further evidences of brain injury (Fig 4)

Discussion

This material comprised only patients with a clinical diagnosis of cerebral concussion or contusion without focal neurologic deficit Patients with clinical concussion all had a normal CT The CSF examinations were normal or showed evidence of barrier injury or S curves in a few cases Although the material is limited this indicates that unless neurologic suggestion of more severe brain injury is present these patients need not be examined with CT

All the 13 patients with CT appearance of cerebral contusion had the clinical diagnosis of cerebral contusion and CSF SPE pathology consistent with cerebral contusion except the 2 previously mentioned with invalid results and not representative in this context Nine of the 13 patients had lesions of mainly decreased or only decreased attenuation which corresponds to the definition given by AMBROSE et coll Four patients in the present series had decreased and increased attenuation regions about equally mixed or mainly increased attenuation lesions altogether

Table 2

Eight patients without evidence of contusion by either CSF SPE or CT (N = normal)

Day of examination after trauma		Diagnosis		
CSF	CT	CSF	CT	Clinical
5	12	S + H	Hygroma	Contusion
1	8	S_1 + H?	N	Contusion
6	9	Barrier lesion	N	Contusion
6	6	Barrier lesion	N	Concussion
1	3	N	N	Concussion
3	3	N	N	Concussion
1	1	N	N	Concussion
1	1	N	N	Concussion

there were 9 patients with regions of increased and decreased attenuation MERINO-DEVILLASANTE & TAVERAS described the CT abnormalities in contusion as a heterogeneous area with an average attenuation higher than that of surrounding normal tissue The present observations differ in some way from both reports mentioned in so far that the CT appearance may be different i e lesions of mainly increased equally mixed mainly decreased or only decreased attenuation No patient had a lesion with increased attenuation only as described by MERINO-DEVILLASANTE & TAVERAS From the diagnostic point of view with lesions of mainly increased attenuation there may be a transitional change of appearance from small intracerebral haematomas to cerebral contusion in the same regions without a distinct separating border line (Fig 2)

The appearance of contusion at CT did not consistently vary with time The patients were however examined relatively soon after the trauma and decrease in attenuation may not be apparent until later (BERGSTROM et coll 1977)

Patients with cerebral contusion may have a normal CT If the history is in favour of cerebral contusion and the CT is normal there would seem to be no need for further neurologic examination If the CT shows contusion the diagnosis is confirmed

Of the 30 patients in this clinical material 4 had severe and unexpected brain lesions all clearly displayed at CT The appearance of intracerebral and subdural haematomas at CT are known (AMBROSE LEVANDER et coll SVENDSEN NEW et coll KAZNER et coll) and epidural haematomas have been reported to have a typical biconvex appearance (SVENDSEN KAZNER et coll)

Theoretically CSF could be normal in epidural haematomas at spectrophotometry since the haematoma is clearly separated from the subarachnoid space On the other hand epidural haematomas are often combined with intradural lesions. This is

Table 3

Eight patients with clinical diagnosis of concussion Normal CT findings in all patients (N = normal S_2 consistent with cerebral contusion)

Day of examination after trauma		Diagnosis (CSF)
CSF	CT	
5	5	S_2
1	1	S_2
1	1	S_2
6	6	Barrier lesion
1	3	N
3	3	N
1	1	N
1	1	N

exemplified in Fig 4 where the CSF spectrophotometry showed an S_2-curve but no evidence of contusion was observed at CT

In a few patients with apparently primary head trauma the history may be unreliable or doubtful The patient may have had a cerebral lesion before the trauma, e g subarachnoid haemorrhage from a ruptured arterial aneurysm In such cases the combination of CT and CSF spectrophotometry may offer the only clue to the origin of trauma causing cerebral contusion CSF SPE findings consistent with aneurysm rupture are an indication for angiography In patients with cerebral contusion CT and CSF SPE seem to be diagnostic methods that are complementary to each other

Conclusions Computer tomography seems to be unnecessary in patients with uncomplicated cerebral concussion

Although only about 60 per cent of patients with the clinical diagnosis of cerebral contusion without neurologic deficit had CT-evidence of contusion CT is indispen

Table 4

Four patients with the clinical diagnosis of contusion with severe unexpected lesions detected at CT All patients had S_2-curves at CSF SPE All were operated upon except one patient with possible intracerebral haematoma and contusion

Day of examination after trauma		Diagnosis (CT)
CSF	CT	
3	3	Epidural haematoma
5	4	Epidural haematoma + contusion
0	6	Intracerebral haematoma? + contusion
4	1	Intracerebral haematoma + contusion

sable for locating the lesion and determinating its extension Furthermore some patients with the clinical diagnosis of contusion do have additional and unexpected lesions which can be diagnosed at CT such as intracerebral haematomas and extracerebral lesions

SUMMARY

Computer tomography (CT) and spectrophotometry of CSF were performed in 30 patient with the clinical diagnosis of cerebral concussion or contusion The patients with concussion all had normal CT findings Spectrophotometry of CSF was sometimes positive for cerebral contusion with normal CT findings but the two methods were complementary so that the extent of the lesion was determined by CT and spectrophotometry of CSF indicated the cause

ZUSAMMENFASSUNG

Eine Computertomographie (CT) und Spektrophotometrie der CSF wurde bei 30 Patienten mit der klinischen Diagnose einer zerebralen Konkussion oder Kontusion vorgenommen Die Patienten mit Konkussion hatten alle normalen CT Befunde Die Spektrophotometrie der CSF war gelegentlich positiv bei zerebraler Kontusion mit normalen CT Befunden jedoch erganzten beide Methoden einander indem das Ausmass der Lasion durch die CT bestimmt wurde und die Spektrophotometrie der CSF die Ursache anzeigte

RESUME

Une tomodensitometrie (TD) et une spectrophotometrie du liquide cephalo-rachidien ont été effectuees chez 30 malades ayant le diagnostic clinique de commotion ou de contusion cérébrale Les malades atteints de commotion avaient tous une tomodensitométrie normale La spectrophotometrie du L C R a ete positive dans certains cas de contusion cérébrale avec une TD normale mais ces deux méthodes sont complementaires de sorte que l etendue de la lesion a été déterminée par la tomodensitométrie et la spectrophotometrie du L C R a indique la cause

REFERENCES

AMBROSE J Computerized transverse axial scanning (tomography) Part 2 Clinical application Brit J Radiol 46 (1973) 1023

— GOODING M R and UTTLEY D EMI scan in the management of head injuries Lancet I (1976) 847

BERGSTROM M ERICSSON K LEVANDER B SVENDSEN P and LARSSON S Variation with time of the attenuation values of intracranial haematomas J comp ass Tomogr 1 (1977) 57

CRONQVIST S BRISMAR J KJELLIN K and SÖDERSTRÖM C E Computer assisted axial tomography in cerebrovascular lesions Acta radiol Diagnosis 16 (1975) 135

KAZNER E LANKSCH W STEINHOFF H und WILSKE J Die axiale Computer Tomographie des Gehirnschadels — Anwendungsmoglichkeiten und klinische Ergebnisse Fortschr Neurol Psychiat 43 (1975) 487

KJELLIN K G and SODERSTROM C E Diagnostic significance of CSF spectrophotometry in cerebrovascular diseases J neurol Sci 23 (1974) 359
— — Cerebral haemorrhages with atypical clinical patterns A study of cerebral haematomas using CSF spectrophotometry and computerized transverse axial tomography (EMI scanning) J neurol Sci 25 (1975) 211
— — and CRONQVIST S Cerebrospinal fluid spectrophotometry and computerized transverse axial tomography (EMI scanning) in cerebrovascular diseases Europ neurol 13 (1975) 315
LEVANDER B STATTIN S and SVENDSEN P Computer tomography of traumatic intra and extracerebral lesions Acta radiol (1975) Suppl No 346 p 107
MERINO DE VILLASANTE J and TAVERAS J Computerized tomography (CT) in acute head trauma Amer J Roentgenol 126 (1976) 765
NEW P SCOTT W SCHNUR J DAVIS K and TAVERAS J Computerized axial tomography with the EMI scanner Radiology 110 (1974) 109
SÖDERSTROM C E KJELLIN K G and CRONQVIST S Computer tomography compared with spectrophotometry of cerebral fluid in cerebrovascular diseases Acta radiol (1975) Suppl No 346 p 130
SVENDSEN P Computer tomography of traumatic extracerebral lesions Brit J Radiol 49 (1976) 1004

FROM THE SECTION OF NEURORADIOLOGY UNIVERSITY HOSPITAL S 221 85 LUND SWEDEN

THERAPEUTIC EMBOLIZATION IN THE EXTERNAL CAROTID ARTERY REGION

J BRISMAR and S CRONQVIST

Selective infusion of drugs balloon catheter installations and particularly trans catheter embolization are therapeutic applications of arterial catheterization tech nique based upon selective angiography The history of embolization in external carotid and vertebral medullary pathology has been described in detail by DJINDJIAN (1975) Though first employed as early as 1930 (BROOKS) larger materials have only recently been presented following the introduction of superselective angio graphy The aim of this report is to present personal experiences with transcatheter embolization of external carotid artery branches and to discuss the indications and techniques for embolization in that region

Material and Technique

During the period 1972 to 1977 17 patients were treated at this department with transcatheter embolization in the region of the external carotid artery Some were treated on multiple occasions so that a total of 24 embolization procedures were performed The age and sex distribution of the material as well as the clinical diagnoses appear in the Table In 8 patients (3 meningeomas Cases 5 10 14 and 5 ENT tumours Cases 6 9 15 16 17) the embolization was performed as a preoperative procedure but one of the patients was not operated upon because of complications related to the procedure (Case 10) In the remaining 9 patients embolization was intended to be the only treatment as the lesions were considered

Submitted for publication 29 June 1977

Table

Summary of cases. Results were classified as excellent (+ + +) when the arterial supply was completely (or almost completely) eliminated, as good (+ +) when a marked effect on vascularity or symptoms occurred, and as fair (+) when only a slight or moderate reduction of vascularity or symptoms was achieved. The arterial supply was classified as follows: (+ + +) = major feeders, (+ +) = significant contribution to the arterial supply, (+) = minor contribution. Abbreviations used are explained in Fig. 1.

Case	Age sex	Diagnosis	Arterial supply	Embolization
1	F 67	Spontaneous carotid cavernous fistula	eca R (ama ma apha) + + + eca L + + ica R + ica L + +	3 times 1) ma R 2) ma R (2 mo later) 3) ma L (1 w later)
2	M 25	Right-sided retro-auricular arteriovenous malformation	oa R ligated raa R + + +	2 times 1) eca R 2) raa R (2 mo later)
3	M 71	Left-sided retro-auricular arteriovenous malformation	oa L + + + raa L + +	oa L
4	M 68	Left-sided retro auricular arteriovenous malformation	oa L + + + raa L + + +	2 times 1) eca L 2) eca L (2 mo later)
5	F 41	Left sphenoidal ridge meningeoma	mma L + + ma L + oa L +	ma L
6	M 11	Nasopharyngeal angiofibroma	ma R + + + ica R + ma L + +	ma bilat
7	M 35	Left-sided glomus jugulare tumour inoperable	apha L + + + raa L + + ica L + apha R + +	2 times 1) apha L, raa L 2) apha R (2 w later)
8	F 63	Right glomus jugulare tumour	apha R + + + raa R + va R +	2 times 1) apha R 2) apha R (3 mo later)
9	M 56	Nasopharyngeal hemangiopericytoma	ma R + + + fa R + + + ma L + + + fa L + + +	ma bilat fa bilat

Table (*cont.*)

Immediate results	Surgery	Late results	Comments
	0	+ + (2 yrs later)	
	0	+ (1 mo later)	Subjective reduction of bruit
	0	+ (1 mo later)	Post-embolization dysphasia restituted in 24 h
	0	?	
	9 days later. No effect of embolization	1 w after embolization revascularization via collaterals	
	2 days later. Markedly facilitated by embolization		
	0	+ + - (14 mo later)	Subjectively free from bruit 14 mo later
	0	?	
	2 days later. Markedly facilitated by embolization		

Table

Summary of cases Results were classified as excellent (+ + +) when the arterial supply was completely (almost completely) eliminated as good (+ +) when a marked effect on vascularity or symptoms ocurred, a as fair (+) when only a slight or moderate reduction of vascularity or symptoms was achieved The arter supply was classified as follows (+ +) = major feeders (+ +) = significant contribution to the arter supply (+) = minor contribution Abbreviations used are explained in Fig 1

Case	Age sex	Diagnosis	Arterial supply	Embolization
1	F 67	Spontaneous carotid cavernous fistula	eca R (ama ma apha) + + + eca L + + ica R ica L + +	3 times 1) ma R 2) ma R (2 mo later) 3) ma L (1 w later)
2	M 25	Right sided retro auricular arteriovenous malformation	oa R ligated raa R + + +	2 times 1) eca R 2) raa R (2 mo later)
3	M 71	Left-sided retro-auricular arteriovenous malformation	oa L + + + raa L + +	oa L
4	M 68	Left-sided retro auricular arteriovenous malformation	oa L + + + raa L + + +	2 times 1) eca L 2) eca L (? mo la ?r)
5	F 41	Left sphenoidal ridge meningeoma	mma L + + ma L + oa L +	ma L
6	M 11	Nasopharyngeal angiofibroma	ma R + + + ica R + ma L + +	ma bilat
7	M 35	Left-sided glomus jugulare tumour inoperable	apha L + + + raa L + + ica L + apha R + +	2 times 1) apha L, raa L 2) apha R (w later)
8	F 63	Right glomus jugulare tumour	apha R + + + raa R + va R +	2 times 1) apha R 2) apha R (3 mo later)
9	M 56	Nasopharyngeal hemangiopericytoma	ma R + + + fa R + + + ma L + + + fa L + + +	ma bilat fa bilat

Table (*cont*)

Immediate results	Surgery	Late results	Comments
—	Cancelled	—	During procedure a left-sided hemiparesis only partially clearing during the following 2 yrs
	0	?	
	0	?	
	0	?	Almost complete revascularization before second embolization
	7 days later. No significant effect of embolization		
	1 day later. Markedly facilitated owing to de-arterialization of cranial part of tumour		
	1 day later. Impossible without previous embolization		
	1 day later. No marked effect of embolization		*Heparin by mistake added to saline flush*

mine the possibility of a subsequent selective transcatheter embolization. Indications and contra-indications were then discussed with the referring clinician and embolization performed at a second session. For the angiographic evaluation as well as for the embolization routine angiographic techniques were used. When possible, transfemoral catheterization was used in order to reduce the radiation dose to the examiner, but in some cases the procedure was performed after percutaneous cannulation of the common carotid artery. For transcarotid catheterization a thin

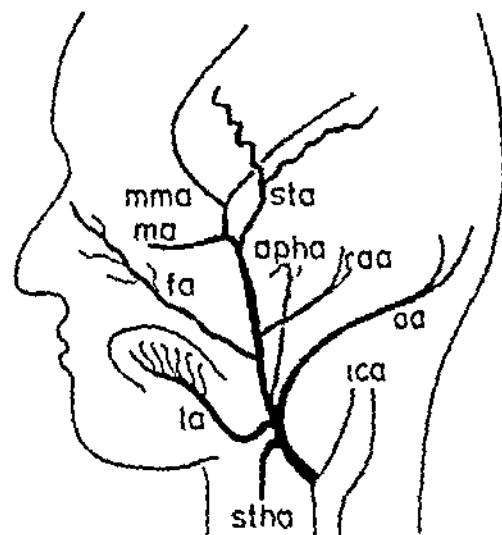


Fig. 1. Major external carotid artery branches. apha = ascending pharyngeal artery; fa = facial artery; ica = internal carotid artery; la = lingual artery; ma = maxillary artery; mma = middle meningeal artery; oa = occipital artery; raa = retro-auricular artery; sta = superficial temporal artery; stha = superior thyroid artery.

walled catheter with an inner diameter of 1.14 mm was used (Radiopath cerebral adult, Radiplast). For the transfemoral approach three different catheters were used, all with an inner diameter between 1.1 and 1.14 mm (Mediplast red special ID 1.1 mm or yellow 52 A, ID 1.14 mm; Cook P 5.0, red, ID 1.12 mm). The shape of the catheter was individualized with regard to the arterial anatomy (Fig. 1). At the embolization procedure no heparin was added to the saline flush. For embolization spongostan sponge was cut in strips measuring about 1 mm × 1 mm × 8 mm. Each spongostan cylinder was put into the tip of a syringe filled with saline—one spongostan cylinder in each syringe. After correct positioning of the catheter in the branch to be embolized (as confirmed by angiography), the catheter was filled with contrast medium. The syringe with the embolus was then attached to the catheter without aspiration and the embolus injected under continuous fluoroscopy. Thus the embolus during injection was preceded by the contrast medium in the catheter so that an immediate pre-embolization control of the catheter position was obtained. Following the introduction of each embolus a small amount of contrast medium (1 to 2 ml) was injected during fluoroscopy in order to control whether further embolization was needed and possible. Further angiographic information was occasionally required for these decisions. The number of emboli needed for occlusion of a feeding vessel varied from one to more than twenty, depending on the type of lesion and the size of the vessel. The end result was always documented angiographically before withdrawal of the catheter from the external carotid artery. To reduce the risk of dislodging embolic material possibly attached to the catheter tip no further injections were made into the common carotid artery.

Side effects and complications. Side effects due to ischemia and probably also to the outflow of pyrogenic substances secondary to tissue necrosis were common



a

Fig 2 Case 6 Nasopharyngeal angiofibroma a) A p view tumour supply from left external carotid artery b) Lateral view right maxillary artery contribution c) essentially eliminated following embolization d) Lateral view left maxillary artery supply e) almost completely eliminated by embolization The arteries appear wider after embolization (c e) than before (b d) but different degrees of magnification prevent direct comparison



b



c



d



e

as described in other materials Pain sometimes severe enough to necessitate the use of potent analgetics was almost regularly encountered during the first few days following the embolization Fever of a moderate degree also frequently occurred Slight edema of the soft tissues in the region supplied by the embolized artery was sometimes noted No necrosis of the skin has been observed

Complications occurred in two patients In one (Case 3) the left occipital artery was embolized because of a retro auricular vascular malformation During emboliza tion the catheter tip was placed proximally in the occipital artery No symptoms or signs had been noted when the patient left the department but after arrival in the ward the patient developed dysphasia which disappeared completely within 24 hours

In another patient (Case 10) a preoperative embolization was performed for sphenoidal ridge meningeoma The catheter was introduced from the right femoral artery and its tip during fluoroscopy placed in the maxillary artery proximal to the origin of the superficial temporal artery After injection of a few emboli (without continuous fluoroscopy) the patient developed a complete left sided hemiparesis The position of the catheter tip was then found to have changed to the internal carotid artery The symptoms and signs have only partially cleared during the following 2 years

Results

The results are summarized in the Table In 7 patients the embolization was followed by surgery in 5 patients (Cases 6 9 15 16 17) within 1 to 2 days In 4 of these patients the surgical procedure was considered to be markedly facilitated by the embolization because of less bleeding than is usually encountered (Fig 2) In 2 patients operation was for various reasons postponed until the 7th (Case 14) and 9th (Case 5) day following the embolization In neither of these cases was the embolization considered to have been of any benefit in one (Case 5) revasculariza tion was in fact demonstrated angiographically before surgery (Fig 3)

In 9 cases embolization was intended to be the single method of therapy Four of *these patiets (Cases 2 3 4 11) had a retro auricular pulse synchronous* bruit caused by an arteriovenous fistula in these patients the bruit disappeared or decreased markedly following the embolization However it soon returned although subjectively it was not as disturbing as before the embolization At angiography no significant effect of the embolization was observed in 2 of these patients (Cases 2 11) In the remaining 2 patients a significant reduction of the shunting was achieved im mediately after embolization but angiography after 1 week (Case 3) and 2 months (Case 4) in conjunction with a repeat embolization procedure demonstrated re arterialization

In Case 1 a spontaneous carotid cavernous fistula was present fed by branches emanating from the external and *internal carotid arteries* bilaterally The vision was rapidly deteriorating and branches from the two external carotid arteries were



Fig 3 Left sphenoidal ridge meningeoma Lateral projections a) Supply from middle meningeal (→) and other maxillary artery branches b) Immediately after embolization marked reduction of tumour supply emboli (↔) in arterial branches c d) One week later two films from same series Proximal occlusion of maxillary artery but peripheral filling including tumour through collaterals (⇸)




Fig 4 Case 8 Right jugular glomus tumour fed mainly by right ascending pharyngeal artery originating as a branch from the internal carotid artery a) Immediately after embolization emboli (→) in ascending pharyngeal artery b) Three months later re vascularization

embolized The shunting decreased noticeably and the patient s vision improved Repeat examination one and a half years later demonstrated persistent reduction of the shunting through the fistula

Three patients were treated with embolization for glomus jugulare tumours considered to be inoperable (Cases 7 8 12) with excellent immediate results In 2 patients repeat angiography performed 3 months (Case 8 Fig 4) and 2 weeks (Case 7) *after the first embolization* demonstrated *partial re vascularization* and a second embolization was undertaken In Case 7 the demonstrable arterial supply was completely eliminated following the second embolization no further angiography was performed Before treatment this patient suffered from an almost intractable bruit 14 months after embolization he was still essentially free from symptoms In Case 8 the second embolization only moderately reduced the flow to the tumour In the third case (No 12) no repeat angiography has been performed In Case 13 (Fig 5) embolization was tried in order to impede further growth of an extensive largely intraosseous meningeoma of the sphenoidal ridge The immediate result of the first embolization was excellent but an angiography 11 days later demonstrated



a

Fig. 5 Case 1? Le[illegible] meningeoma La[illegible] embolization [illegible] from middle [illegible] maxillary a[illegible] media cly a[illegible] tion of tum[illegible] later without [illegible] propagation of [illegible] filled segmen[illegible] (→) d) 4 mon[illegible] tion, persisten[illegible] artery (↔) e) [illegible] more elimina[illegible]



b



c



d



e

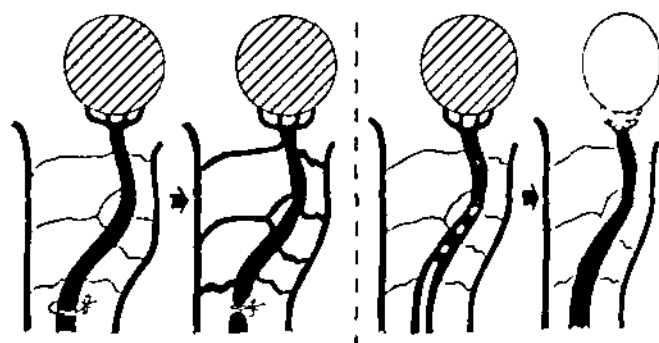


Fig 6 A ligation or other type of proximal occlusion of the feeding artery is followed by dilatation of collaterals (left) embolization, by giving a more distal occlusion is less prone to result in re vascularization (right)

partial re vascularization which was almost complete at angiography 4 months after the first embolization The feeding arteries were then once more successfully occluded no further angiography has been made

Discussion

De vascularization by embolization is indicated in tumours and vascular malformations either as a complement to surgery or as a single occlusive measure Facilitation of surgery by preoperative embolization or the occasional transformation of an inoperable lesion into one that is surgically accessible is of practical interest according to the literature as well as to the limited experience from the present series

Embolization of tumours was tried in 8 patients MANELFE et coll (1975) used it as a routine procedure before operation of tumours such as middle fossa and convexity meningeomas and LACOUR et coll (1975) in chemodectomas Following ligation of a feeding artery to a vascular malformation or a highly vascular tumour re vascularization regularly occurs by dilatation of small collateral branches always present A more distal occlusion of the vessel might reduce the number of collaterals possibly involved in re vascularization (Fig 6) thereby improving the result Embolization offers the possibility of occluding arteries far peripherally by selecting emboli of a suitable size The ideal would be to begin with small emboli to occlude the peripheral branches and then to continue with larger emboli in order to achieve a more proximal occlusion of the feeding arteries (PICARD et coll 1975) However re vascularization commonly occurs (Figs 3 4 5 6) How soon after the occlusion this happens probably varies depending on the nature of the lesion and its vascular reactions on the one hand and the embolization technique on the other In 4 of the 5 cases operated upon within 1 to 2 days after embolization surgery was considerably facilitated in the 5th case heparin had inadvertently been added to the saline flush In 2 patients in whom surgery was postponed for more than a week embolization was considered not to have had any beneficial influence Based upon these observations it is recommended that when spongostan is used as embolic material preoperatively in order to decrease the bleeding at a subsequent operation the operation

should be performed within the first few days following embolization before re vascularization has taken place

The embolization of feeding arteries to arteriovenous malformations is also a well documented form of therapy (NEWTON & ADAMS 1968 BOULOS et coll 1970 KRICHEFF et coll 1972 DJINDJIAN et coll 1973 HILAL et coll 1974 PICARD et coll 1975) It is known that certain forms of malformations i e the spontaneous carotid cavernous fistulas have a significant tendency to heal by means of thrombosis (BRISMAR & BRISMAR 1976) and that such healing often seems to be initiated by minor alterations in the blood flow (angiography digital compression of the common carotid artery) In 2 additional patients with such lesions not included in the present series the fistula closed spontaneously after intermittent occlusion of the internal carotid artery with a balloon catheter It is therefore likely that an embolization even if only causing incomplete and temporary occlusion of the feeders by altering the blood flow may initiate definite healing through thrombosis One patient (Case 1) belonged to this category and embolization was successful in that patient Four patients had other types of arteriovenous malformations In these patients the intention was relief of subjective symptoms rather than a complete occlusion of the fistula If symptoms again became disturbing repeat embolization was carried out The angiographic appearance after embolization in these patients was not impres sive with only partial occlusion of feeding arteries A complete de arterialization in this type of disorder is a difficult achievement as a large number of feeding arteries often exist and as the risk of extensive embolization must be balanced against the severity of the patient s clinical situation

Embolization of inoperable tumours is controversial It has yet to be established whether this form of therapy is warranted in view of the inherent risk and if so in which types of tumour a positive effect is to be expected

Variations in the vascular anatomy are not uncommon and may complicate embolization One example is the anomalous origin of the ophthalmic artery from the middle meningeal artery—an anomaly which for obvious reasons must be excluded before embolization that may possibly affect the middle meningeal artery is con templated Accidental dislodgement of emboli to the internal carotid artery with resulting cerebral sequelae is another source of complication in embolization of external carotid artery branches Continuous fluoroscopy is advocated during final positioning of the catheter tip and injection of embolic material This should provide a reliable means to detect inadvertent movement of the catheter tip to a more proxi mal external carotid artery position or even to the internal carotid artery (as in Case 10) caused by possibly retained torque tension of the catheter sometimes at a considerable distance from the viewing field of fluoroscopy

Even with a correct position of the catheter tip after occlusion of one vessel subsequent emboli may flow in the reverse direction and thus be caught in another branch (Fig 7) It is less obvious that this may also occur when previous emboli have occluded only peripheral branches of an artery If an injection containing an embolus

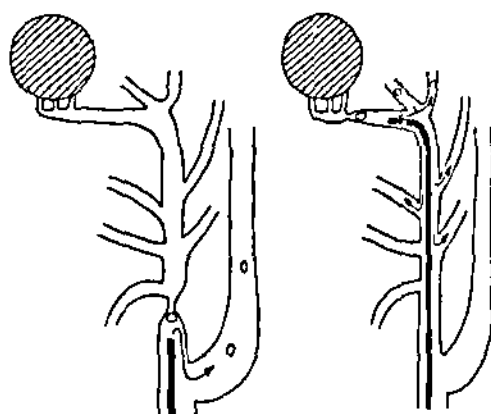


Fig 7 Advantages of superselective emboliza tion technique With a proximal catheter posi tion (left) an occlusion (or spasm) will facilitate subsequent emboli spilling over into the internal carotid artery A distal superselective catheter position (right) will leave multiple alternative routes for subsequent emboli before the internal carotid artery is involved

is more rapid than the target vascular bed can accept part of the injection (and possibly also the embolus) will fill adjacent parts of the vascular system It is of major importance that the embolization be terminated in time before this risk becomes too great Furthermore an occlusion caused by an embolus may propagate in the proximal direction during the first few minutes (PICARD et coll 1974) (Fig 5 b c) In order to keep the embolization under control it is necessary to inject only one embolus at a time and to observe the flow after each injection of an embolus with a small amount of contrast medium Initially a different technique was used the syringe was filled with several emboli soaked in saline This technique may have been responsible for the transient complication in Case 3 As selective a catheteriza tion technique as possible should be used so that a possible spill over embolus will pass into another external carotid artery branch and not into the internal carotid artery Consequently indications for embolization of proximal branches of the external carotid artery are kept within comparatively narrower limits (Fig 8)

It has been stated that catheter wedging is an absolute prerequisite for safe embolization of the external carotid system (HILAL & MICHELSEN 1975) On the other hand it may be argued that it is important to avoid wedging as this would eliminate the possibilities to evaluate the flow in the arterial branches distal to the catheter–the most important criterion for a complete embolization being a stagnation of flow in these branches

Our experience with embolization is limited to the use of gelatine sponge emboli Several other materials are available compressible as well as non compressible Superselective catheterization in the external carotid region requires narrow catheters This excludes the use of non compressible pellets such as lead pellets (NEWTON & ADAMS) as in such cases the diameter of the pellet has to be less than 1 1 mm to pass through the catheter and pellets of such limited size would not be sufficient if used alone (NEWTON & ADAMS MANELFE & DJINDJIAN 1975) they have to be used in conjunction with some sort of compressible emboli Muscle emboli as well as autogenous blood clots have been used as compressible emboli but have the



Fig 8 Glomus caroticum tumour Lateral view External carotid angiography with slight spill-over outlining the internal carotid artery (→) Tumour fed by branches (↦) originating close to the internal carotid artery Embolization would be associated with high risks of spill-over of emboli into the internal carotid artery and was therefore omitted

disadvantage of being rapidly dissolved Intravasal tissue adhesives constitute another category of embolic material the use of which has given promising results reported from different centers (SANO 1966 DOPPMAN et coll 1971 HILAL et coll 1974 CLARISSE et coll 1975) These plastic materials polymerizing after injection into the blood stream are difficult to handle however especially with respect to the risk of deposition of embolic material in the internal carotid artery on withdrawal of the catheter so far this has limited a more widespread use

Therapeutic embolization is a procedure which like surgical procedures is associated with a certain morbidity and even mortality Not only the neuroradiologist performing the procedure and the referring physician but also the patient must be aware of this fact It is important that the patient be informed well in advance The risks associated with embolization must in each case be carefully weighed against possible benefits such as expected decrease of symptoms and signs or reduction of risks in conjunction with subsequent surgery This usually precludes embolization in the same session as the angiography

Therapeutic embolization in the external carotid artery region will remain a relatively rare procedure which should be restricted to a few therapeutic centers and be performed only by experienced neuroradiologists This would probably minimize the complication rate as well as promote the collection of clinical materials large enough for an extensive evaluation of the indications for embolization

SUMMARY

Therapeutic transcatheter embolization with spongostan in the region of the external carotid artery has been employed in 17 patients in some of them on several occasions The technique is presented and different means of avoiding complications are discussed in detail. Embolization has been used preoperatively and as the single mode of treatment of ENT tumours or meningeomas, and also as the only treatment in arteriovenous malformations. The technique has proven particularly useful in preoperative de arterialization of ENT tumours when surgery follows in 1 to 2 days In cases with arteriovenous shunts a subjective improvement has been achieved

ZUSAMMENFASSUNG

Therapeutische Transkatheter Embolisierung mit Spongostan im Gebiet der Arteria carotis externa wurde bei 17 Patienten verwendet bei einigen von diesen mehrmals Die Technik wird beschrieben und die verschiedenen Möglichkeiten Komplikationen zu vermeiden, werden im Einzelnen diskutiert Die Embolisierung wurde vor der Operation und als einzigste Behandlung von Tumoren im Ohren–Nasen–Hals Gebiet Meningeomen oder arteriovenosen Missbildungen verwendet Die Technik erwies sich als besonders nützlich bei der praoperativen De Arterialisierung von Ohren–Nasen–Hals Tumoren, bei denen die Operation innerhalb von 1 bis 2 Tagen danach vorgenommen wurde Bei Fällen mit arteriovenosen Shunts wurde eine subjektive Verbesserung erreicht

RESUME

L embolisation therapeutique par catheter avec du spongostan dans la region de l artere carotide externe a ete utilisee chez 17 malades a plusieurs reprises chez certains. Les auteurs decrivent la technique et etudient en detail les differents moyens d eviter les complications. L embolisation a ete utilisee en pre-operatoire et comme seul traitement de tumeur oto-rhino–laryngologique ou de meningiome et aussi comme seul traitement dans des malformations arterioveineuses. Cet e technique s est montree particulierement utile pour la desafferentation arterielle pre-operatoire des tumeurs oto–rhino–laryngologiques quand l'operation suit dans 1 a 2 jours Dans les cas de shunt arterioveineux une amelioration subjective a ete obtenue

REFERENCES

BOULOS R., KRICHEFF T and CHASE N Value of cerebral angiography in the embolization treatment of cerebral arteriovenous malformations Radiology 97 (1970) 65

BRISMAR G and BRISMAR J Spontaneous carotid-cavernous fistulas Phlebographic appearance and relation to thrombosis. Acta radiol Diagnosis 17 (1976) 180

BROOKS B The treatment of traumatic arteriovenous fistula Sth med. J (Bham Ala) 23 (19 0) 100

CLARISSE J GOZET G., CORNIL J P., JOMIN M., DELANDSHEER J M et LAINE E. Les emboles plastiques fluides Etude experimentale et rapport de deux cas cliniques de fistules arterioveineuses traitees. J Neuroradiol 2 (1975) 29

DJINDJIAN R L embolisation en pathologie carotidienne externe et vertebro-medullaire Historique J Neuroradiol 2 (1975) 5

— COPHIGNON J THÉRON J MERLAND J J and HOUDART R Embolisation by super selective arteriography from the femoral route in neuroradiology Review of 60 cases 1 Technique indications complications Neuroradiology 6 (1973) 20

DOPPMAN J L DI CHIRO G and OMMAYA A K Percutaneous embolization of spinal cord arteriovenous malformations J Neurosurg 34 (1971) 48

HEKSTER R E M LUYENDIJK W and MATRICALI B Transfemoral catheter embolization a method of treatment of glomus jugulare tumors Neuroradiology 5 (1973) 208

HILAL S K and MICHELSEN J W Therapeutic percutaneous embolization for extra axial vascular lesions of the head neck and spine J Neurosurg 43 (1975) 275

— MICHELSEN W J DRILLER J and LEONARD E Magnetically guided devices for vascular exploration and treatment Radiology 113 (1974) 529

KRICHEFF I I MADAYAG M and BRAUNSTEIN P Transfemoral catheter embolization of cerebral and posterior fossa arteriovenous malformations Radiology 103 (1972) 107

LACOUR P DOYON D MANELFE C PICARD L SALISACHS P et SCHWAAB G L embolisation artérielle thérapeutique dans les chémodectomes (tumeurs glomiques) J Neuroradiol 2 (1975) 275

MANELFE C et DJINDJIAN R Techniques de l embolisation therapeutique par cathetérisme percutane J Neuroradiol 2 (1975) 11

— ESPAGNO J GUIRAUD B TRÉMOULET M GERAUD G et RASCOL A Embolisation therapeutique des tumeurs craniocérebrales J Neuroradiol 2 (1975) 257

NEWTON T H and ADAMS J E Angiographic demonstration and nonsurgical embolization of spinal cord angioma Radiology 91 (1968) 873

PICARD L ANDRE J M DJINDJIAN R ROLAND J MANELFE C SIGIEL M WAYOFF M et KISSEL P Angiographie superselective et embolisation des localisations O R L de l angiomatose de Rendu Osler J Neuroradiol 1 (1974) 351

— — ROLAND J SIGIEL M MONTAUT J et LEPOIRE J L embolisation dans les malformations vasculaires meningo-cranio-cutanées complexes J Neuroradiol 2 (1975) 233

SANO K JIMBO M SAITO I TERAO H and HIRAKAWA K Artificial embolization with liquid plastic Neurol med-chir (Tokyo) 8 (1966) 198

FROM THE DEPARTMENT OF MEDICAL STATISTICS AND EPIDEMIOLOGY THE LONDON SCHOOL OF HYGIENE AND TROPICAL MEDICINE LONDON ENGLAND

PHYSICAL CORRELATES OF RADIOLOGIC HEART VOLUME

DAVID CHRISTIE

Radiologic heart volume as estimated by the ellipsoid approximation technique (JONSELL 1939) has been widely used in clinical practice but less frequently in epidemiologic investigations The Civil Service Health Survey (REID et coll 1974) included p a and lateral 100 mm chest films of 12 630 men over the age of 40 thus providing an opportunity to examine some of the associations of radiologic heart volume with other physical characteristics

Methods

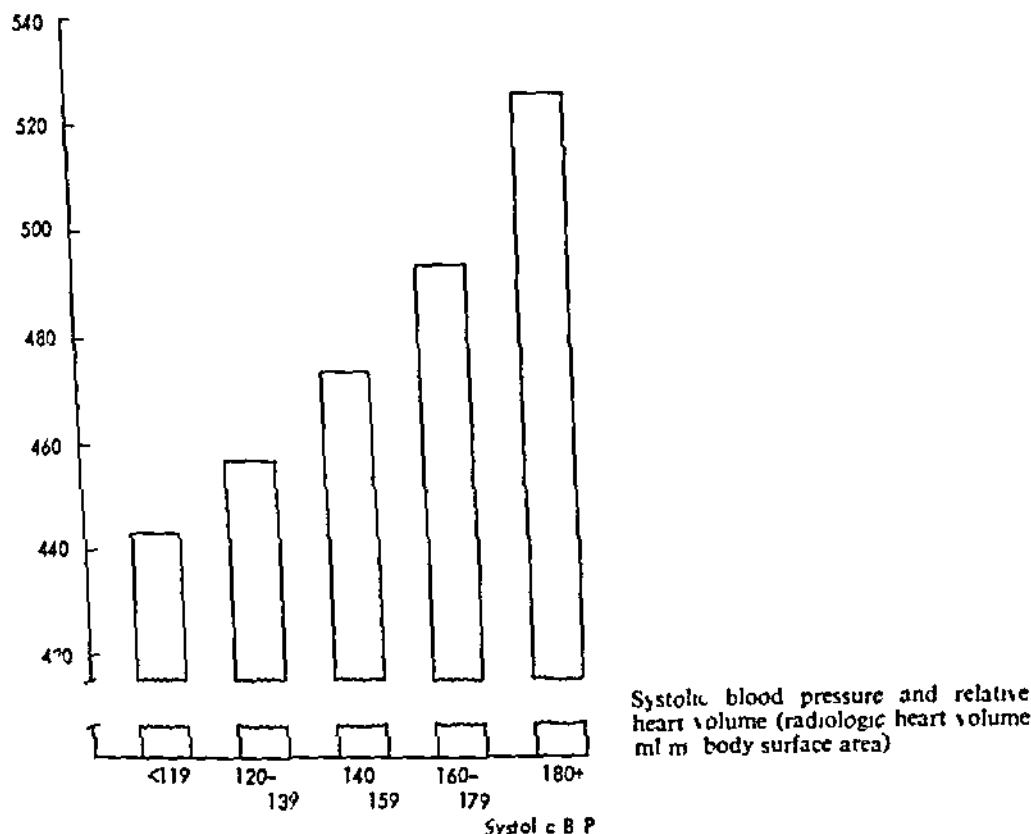
A random sample of 1 263 subjects was selected and in 1 188 of these radiologic heart volume could be computed The most frequent reason for rejection was technical inadequacy of the lateral film but other reasons included extensive post tubercular scarring and gross kyphoscoliosis

For estimation of radiologic heart volume by the ellipsoid approximation technique the long and broad axes are measured on the p a film and the longitudinal axis on the lateral film (JONSELL) An additional measure of relevance to the present report was the transverse thoracic diameter defined as the distance between the internal rib margins at the level of the dome of the right hemi diaphragm

The radiologic heart volume (RHV) was computed as follows

RHV (ml) $= l \times b \times d(\pi/6\ 46\ 52)/1\ 000$ where π is a constant and 46 52 a constant

The author is now at Department of Community Health University of Melbourne Victoria Australia Submitted for publication 29 June 1977



Systolic blood pressure and relative heart volume (radiologic heart volume ml m body surface area)

to correct for magnification and consequent reduction in the size of the cardiac image (CHRISTIE 1975)

All films were taken with an unmodified Odelca 100–X111–S photofluorographic camera under survey conditions with no special subject preparation Measurements on each film were to the nearest 0 5 mm using a scale printed on a transparent plastic overlay

The chest film was but part of a multiphasic screening examination the components of which have been described in detail elsewhere (REID et coll)

Results

The relationship between radiologic heart volume and other physical characteristics was initially examined by step-wise multiple regression analysis progressively reducing the number of explanatory variables in the model With eight such variables 45 per cent of between subject variability in radiologic heart volume can be accounted for The partial regression coefficient of each variable was then ex

Table 1

Multiple regression analysis dependent variable is radiologic heart volume (916 cases)

Explanatory variable	Partial regression coefficient	SD of regression coefficient	t value	Regression coefficient in standard units
Weight (kg)	3.9767	0.2334	17.04***	86.61
Transverse thoracic diameter (mm)	0.6653	0.1232	5.40***	27.98
Systolic blood pressure	1.1620	0.2124	5.47***	25.29
Heart rate	−2.1176	0.3715	−5.70***	−25.26
Age (years)	3.0064	0.7516	4.00***	21.13

***$p < 0.001$

pressed in standard units enabling ranking to be carried out. Data relating to the five most important variables appear in Table 1.

Weight and transverse thoracic diameter are both measures of body size and in any comparison of heart volume between individuals correction for body size is essential. The usual practice in the Scandinavian literature has been to correct the radiologic heart volume by relating it to body surface area, the resultant index being termed relative heart volume. The other important confounding variables that need to be taken into account are age and heart rate. The increase in heart volume with age found in this material is similar to that described in a Norwegian population (HUMERFELDT 1963) and the inverse relationship of heart rate with radiologic heart volume is also well recognised.

Table 2

Relative heart volume (ml m) by age and systolic blood pressure

Age (years)	Systolic blood pressure			F ratio
	< 125 mm	125–149 mm	≥ 150 mm	
40–49	435.26 ± 63.83 (200)	448.63 ± 68.30 (204)	468.65 ± 67.47 (80)	7.42 ($p < 0.01$)
≥ 50	464.03 ± 87.82 (185)	465.61 ± 71.32 (312)	506.04 ± 90.05 (206)	18.40 ($p < 0.01$)
All ages	449.09 ± 77.55 (385)	458.90 ± 70.57 (516)	495.56 ± 85.88 (286)	32.30 ($p < 0.01$)

Table 1 demonstrates that after body size age and heart rate have been taken into account the level of blood pressure has a major influence on heart volume The progressive increase in relative heart volume (ml/m) with increasing systolic blood pressure is illustrated in the Figure and a similar relationship can be demonstrated with diastolic pressure To confirm the relationship suggested by the multiple regression analysis in Table 2 the change in relative heart volume with increasing blood pressure is seen to hold within ten year age groups After the variables describing body size the level of the blood pressure is the most important single factor influencing the radiologic heart volume

Discussion

Development of mass miniature radiography for tuberculosis case finding has resulted in a screening device with the attractions of being relatively cheap rapid in application causing no discomfort and being acceptable to a large part of the population Many reports have shown that radiologic heart volume as estimated by the ellipsoid approximation technique is a valid index of anatomic heart size and TOURU KAISILA (1970) confirmed that valid estimates could be made from miniature photofluorograms The strong association between blood pressure and radiologic heart volume found in the present material suggests that mass miniature radiography may have a useful role in cardiovascular screening programmes For comparisons within and between populations it is essential to standardize for body size and age Even when the exposure is triggered by a pre determined part of the cardiac cycle correction for heart rate is desirable as its major influence is physiologic with steady cardiac output the heart rate is inversely related to the end diastolic volume

The potential value of radiologic heart volume estimation to cardiovascular screening does not lie solely in the demonstrated relationship with blood pressure MASTERS (1954) demonstrated that following myocardial infarction radiologic enlargement of the heart may occur and BJERKELUND (1957) that such enlargement has prognostic significance Thus other aspects of cardiovascular pathology influence heart volume but because of low prevalence their influence cannot be demonstrated in a cross sectional investigation of an apparently well population It is proposed to report prospectively the mortality in this cohort in a subsequent communication

Acknowledgements

The material presented in this article originally formed part of an M D thesis University of London 1973 In this as in so many more important things I am indebted to the late Professor D D Reid for guidance and encouragement

SUMMARY

Radiologic heart volume was calculated on a 10 per cent random sample of subjects examined in the London Civil Service Health Survey Data were available for 1 188 men

Tabl

Multiple regression analysis dependent vari

Explanatory variable	Partial regression coefficient	St reg coef
Weight (kg)	3 9767	0 2334
Transverse thoracic diameter (mm)	0 6653	0 1232
Systolic blood pressure	1 1620	0 2124
Heart rate	2 1176	0 3715
Age (years)	3 0064	0 7516

***p < 0 001

pressed in standard units enabling ranking to be carried five most important variables appear in Table 1

Weight and transverse thoracic diameter are both measu any comparison of heart volume between individuals corr essential The usual practice in the Scandinavian literature h radiologic heart volume by relating it to body surface area the termed relative heart volume The other important confou need to be taken into account are age and heart rate The incre with age found in this material is similar to that described in a Nor (HUMERFELDT 1963) and the inverse relationship of heart rate wit volume is also well recognised

Table 2

Relative heart volume (ml/m) by age and systolic blood pressure

Age (years)	Systolic blood pressure			F ratio
	125 mm	125–149 mm	≥150 mm	
40–49	435 26 ± 63 83 (200)	448 63 ± 68 30 (204)	468 65 ± 67 47 (80)	7 4? (p<0 01)
~50	464 03 ± 87 82 (185)	465 61 ± 71 32 (312)	506 04 ± 90 05 (?06)	18 40 (p<0 01)
All ages	449 09 ± 77 55 (385)	458 90 ± 70 57 (516)	495 56 ± 85 88 (286)	3? 30 (p<0 01)

FROM THE DEPARTMENTS OF DIAGNOSTIC RADIOLOGY CARDIOLOGY AND CLINICAL PHYSIOLOGY AKADEMISKA SJUKHUSET S 750 14 UPPSALA SWEDEN

LEFT VENTRICULAR FUNCTION EVALUATED BY VIDEODENSITOMETRY IN PATIENTS WITH CORONARY HEART DISEASE

U ERIKSON L BJORK I CULLHED E E GHOFF L NORDGREN and G RUHN

In patients with coronary artery disease estimation of left ventricular (LV) function is of great importance for the prognosis and for decisions concerning surgery (BRUSCHKE et coll 1973 HAMMERMEISTER & KENNEDY 1973) The LV volume may be measured from cardioangiograms but the form of the ventricle and the ventricular function are as a rule only estimated subjectively

The LV function is expressed most simply by measuring the ventricular volume in diastole and systole From this the stroke volume (SV) is calculated and related to the end-diastolic volume (LVEDV) to determine the ejection fraction (EF)

$$EF = SV/LVEDV$$

However all volume determinations based on cineangiograms are relatively inaccurate (DAVILA & SANMARCO 1966 LAHDE 1976) The assumption that LV is a regular ellipsoid in both diastole and systole is obviously an *approximation* This is even more evident in patients with coronary artery disease with scars or aneurysms in the LV wall (ELLIOTT & GORLIN 1966)

Detection of the outline of the LV cavity is difficult and the LV stroke volume calculated *from* cardioangiograms is in most instances larger than that obtained by hemodynamic methods (ENGHOFF 1972)

Submitted for publication 27 June 1977

Acta Rad I g a D ag os s 19 (1978) Fasc 5

47 – 785839

It would appear more accurate to measure the amount of blood in the ventricle in diastole and systole respectively and to calculate the stroke volume and ejection fraction from these values Such a method has been developed and has been in practical use at this hospital since 1973 (BJÖRK et coll 1974) This method is based upon measurements of the amount of contrast medium present in a cardiac chamber in different phases of the cardiac cycle during cardioangiography and the equipment is called videodensitometer (Svenska Philips AB Stockholm Sweden) The density signal is proportional to the amount of contrast medium By means of this video densitometric technique the ejection fraction can be determined The LV ejection fraction in angina pectoris and its correlation with some clinical and hemodynamic parameters are now reported

Materials and Methods

The material consisted of 121 patients (Group A) with angina pectoris and 32 patients (31 men and one woman Group B) in whom more complete data were available Thus the preoperative investigation was limited to angiography and densitometry in a majority of patients In Group B the mean age was 54 years and the mean body weight 75 kg All patients in this group had a routine examination on admission including physical examination conventional chest radiography in the standing and supine positions ECG a graded exercise test cardiac catheterization with pressure recording and cardiac output determination at rest and during exercise LV cineangiography LV videodensitometry and selective coronary angiography All patients in Group B except one who had atrial fibrillation were in sinus rhythm

Hemodynamic methods With the patient in supine position the pressures were measured with transducers connected to electromanometers ECG and pressure curves were recorded on a direct writing six channel ink jet recorder The reference level for zero pressures in the supine position was placed at the midpoint of the thoracic depth Before each recording the system was calibrated with a water manometer

Right heart catheterization was performed in the conventional way using a superficial cubital vein for introduction of the catheter Transseptal left heart catheterization was done in 4 cases with a teflon catheter with one end hole and four side holes the catheter being introduced percutaneously through the right femoral vein

Pressures and cardiac output were determined at rest After the measurements at rest the patient still in the supine position performed a graded exercise test on an electrically braked bicycle ergometer Each work load period comprised approximately 6 min during which the ECG and the pressures were recorded continuously

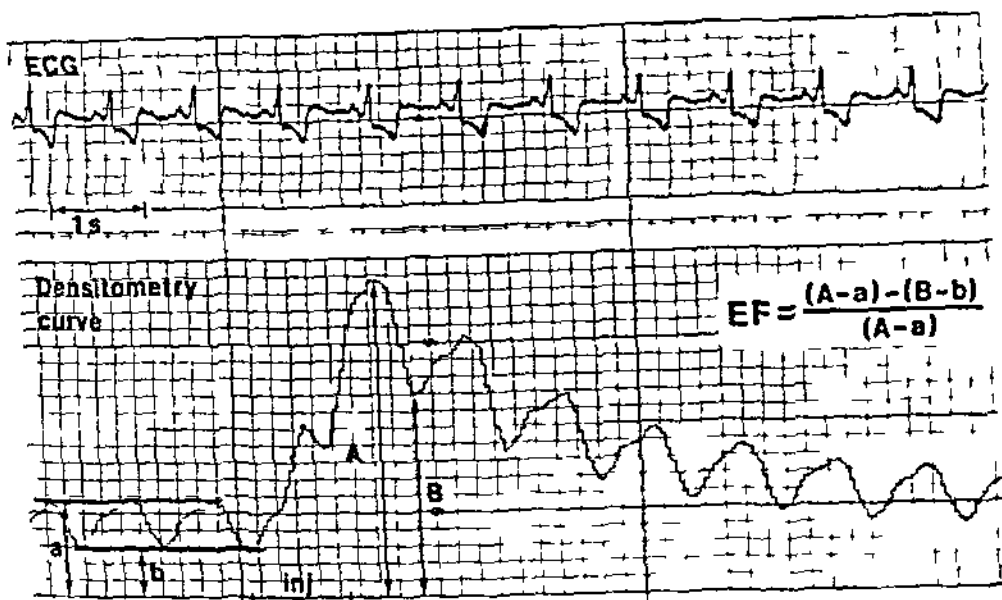


Fig 1 Typical videodensitometric recording following a left ventricular injection of 15 ml Urografin 60 The ejection fraction (EF) is calculated from the formula where (A–a) is proportional to the amount of contrast medium in diastole and (B–b) in systole

Angiographic methods In 28 patients retrograde LV cardioangiography was performed and in 4 patients LV cardioangiography with injection into the left atrium through a transseptally introduced catheter (Group B) Videodensitometry and selective coronary angiography were also carried out

The procedure for videodensitometry was as follows A gray Ödman Ledin catheter was introduced percutaneously into the right femoral artery and advanced into LV In cases where transseptal puncture was performed the tip of the catheter was placed in the left atrium The patient was turned into a right anteriorly oblique position so that the longitudinal axis of LV was approximately perpendicular to the central beam of the roentgen recording system The patient was instructed to take a moderately deep breath and then hold it in inspiration and the video recording was started After about five heart beats 15 ml of Urografin 60° (iodine content 292 mg/ml) was injected in one s with a Contrac injector The recording continued during 10 to 15 heart beats after the end of the injection For the video recording fluoroscopic settings on the roentgen generator were used Great care was taken in positioning the catheter for injection so that no premature beats were induced ECG was recorded continuously during the examination In 10 patients (Group A) two measurements with an interval of 3 min were performed in order to determine the error of analysis

After an interval of about 10 min a conventional LV cardioangiography was per formed with injection of 30 ml of Urografin 60° in 2 s and cinerecording in two right angle projections with an exposure frequency of 75 frames per s Philips cine

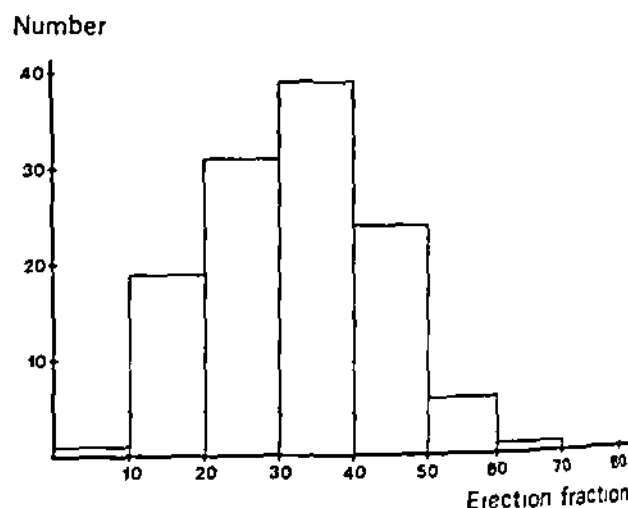


Fig 2 Ejection fraction (per cent) in 121 patients with angina pectoris (Group A)

pulse generators cesium iodide image intensifiers and plumbicon TV cameras were used

The LV catheter was then replaced by catheters for selective coronary angiography which was performed in the standard manner Following the examination the films were used for determination of the LV volumes by the area length method (DAVILA & SANMARCO)

The curves from the videodensitometer were used for calculating the ejection fraction (Fig 1)

The coronary angiograms were viewed in a Tagarno projector and the appearances of each coronary artery were graded from 0–4, where 0 = no abnormality 1 = steno is comprising less than 50 per cent of the diameter 2 = one stenosis more than 50 per cent 3 = several stenoses more than 50 per cent and 4 = occlusion This codification was then used when evaluating coronary angiograms of the main stem of the left coronary artery its descending branch and its circumflex branch and the right coronary artery The maximum sum was thus 16

Results

A total of 121 videodensitometric determinations of the LV ejection fraction were performed (Group A) (Fig 2) Most patients had an ejection fraction below 50 per cent with a mean ejection fraction of 31 Two cases with pain simulating angina pectoris and normal coronary arteries had an ejection fraction of 60 and 70 per cent, respectively Duplicate determinations of the ejection fraction showed a mean difference of $-1\,9 \pm 4\,2$ % between stroke I and II The difference in the mean value of ejection fraction for two injections was $0\,6 \pm 2\,2$ % Between the LV ejection fraction and the LV end-diastolic volume a correlation seemed to be present (Fig 3) The correlation between the supine total heart volume and the LV ejection fraction

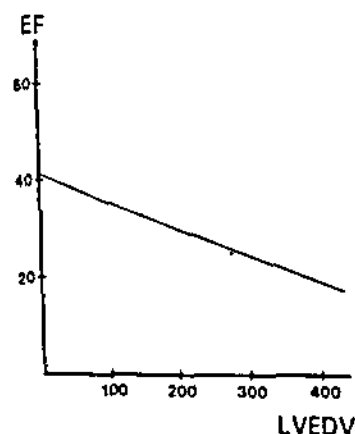


Fig 3

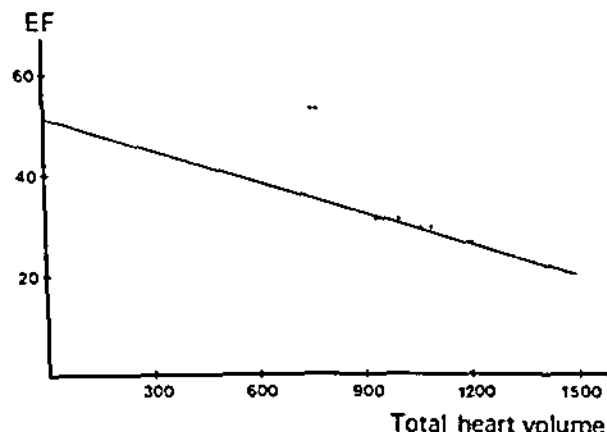


Fig 4

Fig 3 Relation between ejection fraction (EF per cent) and left ventricular end-diastolic volume (LVEDV ml) in 67 patients (Group A) y = 41 3 − 0 055 x r = −0 34 S_{yx} 11 4

Fig 4 Relation between ejection fraction (EF per cent) and total heart volume (ml) in the supine position measured in 92 patients (Group A) y 51 1 − 0 0[illegible]1 x r − 0 36 S_{yx} = 11 5

(Fig 4) was weaker than the correlation between the LV end diastolic volume and the total heart volume (Fig 5) The patients were investigated in supine position with perpendicular beam directions and the JONSELL formula was used with correction for the magnification (BACKLUND et coll 1974)

The correlation between the LV ejection fraction and abnormalities of coronary arteries was also assessed (Fig 6) No correlation was found between the degree of stenosis in the coronary arteries and the ejection fraction This is partly explained by the difficulties in assessing coronary artery stenosis on the angiograms (BJORK et coll 1975 BJÖRK & O KEEFE 1976)

In 25 patients (included in Group B) the ejection fraction and the left ventricular end-diastolic pressure (Fig 7) were correlated and the increase in left atrial or PCV pressure during an exercise test (Fig 8) determined The patients with the lowest ejection fractions also had the highest end diastolic pressures Patients with low ejection fractions tended to have a greater increase in left atrial or PCV pressure during exercise than those with a normal ejection fraction

The poor correlation between the functional classification according to the New York Heart Association and the ejection fraction is evident from Fig 9

No case of mitral insufficiency was found

Discussion

The main advantage of videodensitometry is that the ejection fraction can be measured in a practical and objective way The videodensitometric recordings and measurements are easily incorporated into the conventional catheterization pro-

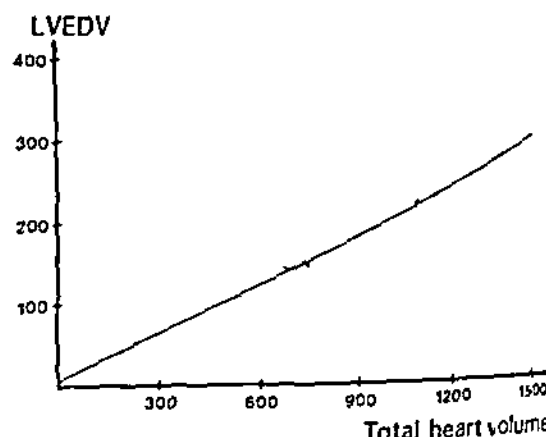


Fig 5 Relation between left ventricular end diastolic volume (LVEDV ml) and total heart volume (ml) in 54 patients (Group A) $y = 6\,8 + 0\,19\,x$ r 0 50 $S_{yx} =$ 67 1

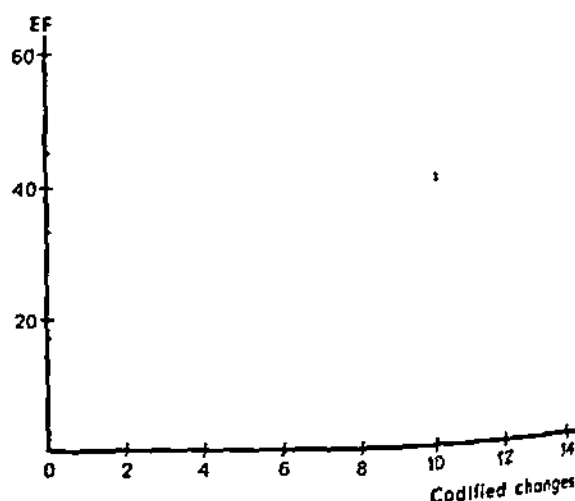


Fig. 6 Relation between ejection fraction (EF ml) and the sum of the codified changes in the left and right coronary arteries in 116 patients (Group A)

cedure and the additional risk and discomfort for the patient is insignificant The videodensitometric measurements take only a few minutes as compared with the time-consuming tracings and calculations from cineangiograms Further they theoretically can be automatized and may easily be combined with pressure data e g to derive pressure volume loops

Results of repeated LV injections for densitometry have shown good reproducibility

The volume of contrast medium injected is smaller than at cardioangiography and should therefore have less effect on the circulation

However in patients with angina pectoris a biplane LV cineangiography must also be performed for evaluation of local abnormalities of the LV wall and any ischemic injury to the papillary muscles causing mitral regurgitation With LV densitometry the regurgitant fraction may be determined provided the projections are chosen so that the left atrium and ventricle are not superimposed

For the densitometry the patient must hold his breath for about 15 heart beats.

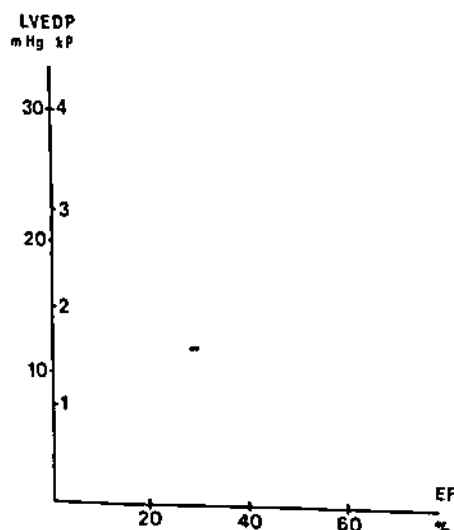


Fig 7

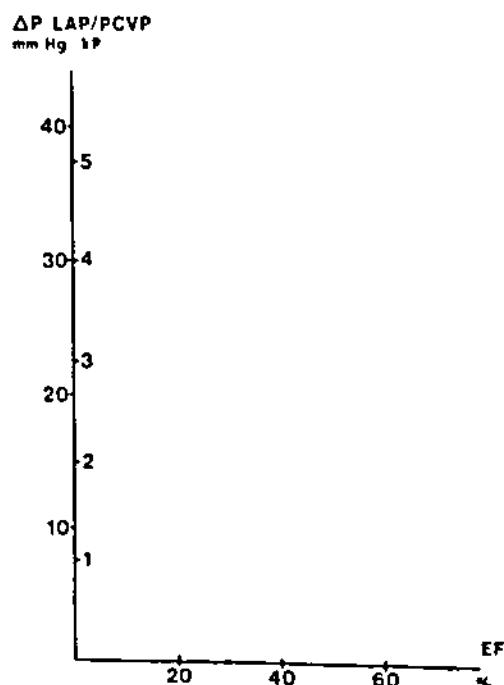


Fig 8

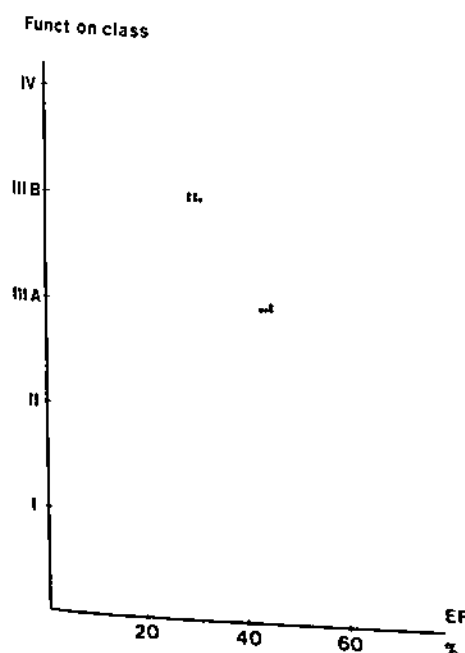


Fig 9

Fig 7 Relation between left ventricular end diastolic pressure (LVEDP) and ejection fraction (EF) in 25 patients ● angina pectoris ○ normal (Group B)

Fig 8 Relation between the increase in mean blood pressure in left atrium (LAP) or pulmonary capillary vein (PCVP) during exercise and ejection fraction (EF) in 23 patients (Group B) ■ angina during exercise test ○ normal

Fig 9 Relation between functional classification and ejection fraction (EF) in 32 patients (Group B)

This was nearly always possible A useful aid is a noseclip The patient should be instructed to avoid a Valsalva manoeuvre during the apnoea as this would be unnecessarily tiring and would influence the results Tachycardia or bradycardia will not within certain limits invalidate the method Premature beats and arrhythmia such as atrial fibrillation will give results difficult to evaluate

In the majority of cases in the total material the ejection fraction was low The normal ejection fraction is larger than 50 per cent (DYKE et coll 1974) Most of the 32 patients in Group B were severely incapacitated from angina pectoris and had sustained at least one episode of myocardial infarction Patients without infarction may have diffuse fibrosis of the LV myocardium resulting in a low ejection fraction

In different series of patients with coronary heart disease the ejection fractions have varied NELSON et coll (1975) found that 37 per cent in a series of 144 patients had ejection fractions below 50 per cent and VLIESTRA et coll (1977) reported a corresponding value in 40 per cent of cases

Three patients with no or only very slight disability have had an infarction They did not seem to differ from the others with regard to physical work capacity coronary artery abnormalities or ejection fraction This was as expected since patients with angina pectoris will often more or less consciously adjust their way of life and physical activity to avoid anginal attacks thus making a classification from their symptoms difficult

From Fig 3 a regression line could be calculated although with a large residual variation This variation is partly explained by the fact that only the ejection fraction of the whole ventricle was measured However the equipment permits two simultaneous measurements of different parts of the LV The contractions may vary within one ventricle from akinetic to normal areas The large variation between the ejection fraction and the total heart volume is to be expected as there must be considerable differences in the left atrial and right heart dimensions in these patients A negative correlation between heart size and LV ejection fraction has been found (AINTABLIAN et coll 1976)

It has been shown repeatedly that a history of myocardial infarction occlusion of a coronary artery and a local myocardial scar are correlated The large variations in the number and size of myocardial infarcts and scars in the present material probably explains the absence of a correlation between the coronary artery score and the ejection fraction

The LV end diastolic pressure at rest immediately before the densitometry was normal in most cases (Fig 7) As a rule most patients with angina pectoris without severe LV failure have normal LV filling pressures at rest The 4 patients with an LV end diastolic pressure of at least 2 7 kPa (20 mmHg) had a low ejection fraction During exercise in supine position the PCV or left atrial mean pressure increased to above 2 7 kPa in 13 of 23 cases (Fig 8) The increase in pressure rise was not correlated to the ejection fraction at rest However most patients had some degree of anginal pain during the exercise test and it has been shown at cardioangiography

that local LV akinesis may develop or become more severe during physical work (RAPHAEL & STEINER 1975) Thus the pressure rise during exercise should be compared with the ejection fraction under the same condition of work

SUMMARY

The ejection fraction of the left ventricle was determined by videodensitometry in 121 patients with angina pectoris The mean value was 31 per cent This estimation which is easily performed by the method described gives important and accurate information on the left ventricular function which added to other parameters should increase the reliability of the clinical evaluation of the patient

ZUSAMMENFASSUNG

Die Ejektions Fraktion vom linken Ventrikel wurde durch Videodensitometrie bei 121 Patienten mit Angina pectoris bestimmt Der Mittelwert war 31 Prozent Diese Bestimmung welche leicht mit der beschriebenen Methode auszuführen ist gibt wertvolle und genaue Information über die Funktion des linken Ventrikels welche zusammen mit anderen Parametern die Genauigkeit der klinischen Bewertung des Patienten steigern sollte

RESUME

La fraction d ejection du ventricule gauche a été determinee par vidéodensitometrie chez 121 malades atteints d angine de poitrine La valeur moyenne a été de 31 % Cette estimation qui est aisement effectuee par la methode decrite donne des renseignements importants et exacts sur la fonction du ventricule gauche qui combines avec d autres parametres devraient augmenter la fiabilite de l evaluation clinique du malade

REFERENCES

AINTABLIAN R I HAMLEY Z and CAERSMAN J Correlation of heart size with clinical and hemodynamic findings in patients with coronary artery disease Amer Heart J 91 (1976) 21

BJORK L and O KEEFE A Estimation of coronary artery stenosis Limitations of present methods Acta radiol Diagnosis 17 (1976) 777

— ERIKSON U and HALLSTRÖM A The videovolumeter Ups J med Sci 79 (1974) 148

— SPINDOLA FRANCO H VAN HOUTEN F X COHN P F and ADAMS D F Comparison of observer performance with 16 mm cinefluorography and 70 mm camera fluorography in coronary arteriography Amer J Cardiol 36 (1975) 474

BRUSCHKE A V G PROUDFIT W L and ZONES JR F M Progress study of 590 consecutive nonsurgical cases of coronary disease followed 5-9 years I Arteriographic correlations Circulation 47 (1973) 1147

BÄCKLUND L BERGSTROM K ERICSSON P ERIKSON U HUITFELDT B and RENCK H Choice of variables for predicting the heart volume Ups J med Sci 79 (1974) 97

DAVILA J C and SANMARCO M E An analysis of the fit of mathematical models applicable to the measurement of left ventricular volume Amer J Cardiol 18 (1966) 31

This was nearly always possible A useful aid is a noseclip The patient should be instructed to avoid a Valsalva manoeuvre during the apnoea as this would be unnecessarily tiring and would influence the results Tachycardia or bradycardia will not within certain limits invalidate the method Premature beats and arrhythmia such as atrial fibrillation will give results difficult to evaluate

In the majority of cases in the total material the ejection fraction was low The normal ejection fraction is larger than 50 per cent (DYKE et coll 1974) Most of the 32 patients in Group B were severely incapacitated from angina pectoris and had sustained at least one episode of myocardial infarction Patients without infarction may have diffuse fibrosis of the LV myocardium resulting in a low ejection fraction

In different series of patients with coronary heart disease the ejection fractions have varied NILSON et coll (1975) found that 37 per cent in a series of 144 patients had ejection fractions below 50 per cent and VLIESTRA et coll (1977) reported a corresponding value in 40 per cent of cases

Three patients with no or only very slight disability have had an infarction They did not seem to differ from the others with regard to physical work capacity coronary artery abnormalities or ejection fraction This was as expected since patients with angina pectoris will often more or less consciously adjust their way of life and physical activity to avoid anginal attacks thus making a classification from their symptoms difficult

From Fig 3 a regression line could be calculated although with a large residual variation This variation is partly explained by the fact that only the ejection fraction of the whole ventricle was measured However the equipment permits two simultaneous measurements of different parts of the LV The contractions may vary within one ventricle from akinetic to normal areas The large variation between the ejection fraction and the total heart volume is to be expected as there must be considerable differences in the left atrial and right heart dimensions in these patients A negative correlation between heart size and LV ejection fraction has been found (AINTABLIAN et coll 1976)

It has been shown repeatedly that a history of myocardial infarction occlusion of a coronary artery and a local myocardial scar are correlated The large variations in the number and size of myocardial infarcts and scars in the present material probably explains the absence of a correlation between the coronary artery score and the ejection fraction

The LV end diastolic pressure at rest immediately before the densitometry was normal in most cases (Fig 7) As a rule most patients with angina pectoris without severe LV failure have normal LV filling pressures at rest The 4 patients with an LV end diastolic pressure of at least 2 7 kPa (20 mmHg) had a low ejection fraction During exercise in supine position the PCV or left atrial mean pressure increased to above 2 7 kPa in 13 of 23 cases (Fig 8) The increase in pressure rise was not correlated to the ejection fraction at rest However most patients had some degree of anginal pain during the exercise test and it has been shown at cardioangiography

DEVIATION OF THE DESCENDING AORTA ASSOCIATED WITH ENLARGED LEFT ATRIUM

K VATNE and T AAKHUS

Several classical abnormalities indicating enlargement of the left atrium are used in the radiologic evaluation of mitral valve disease Very little attention has however been focused on the deviation of the descending aorta to the left described by BEDFORD (quoted by DEE 1974) and later termed Bedford s sign

DUNNE (1967) mentioned this deviation and DEE found that it occurred in 55 per cent of patients under 50 years of age with dominant mitral stenosis CHEN et coll (1974) demonstrated a similar deviation in cases of mitral insufficiency They also demonstrated that deviation of the descending aorta to the left and the esophagus to the right was caused by wedging of the enlarged left atrium in between these structures and coined the designation posterior wedging sign

The aim of the present investigation was to compare the frequency of deviation of the descending aorta with that of more commonly used signs of mitral disease and left atrial enlargement A control material was included to decide if this deviation might be confused with the physiologic unfolding of the aorta

Material

The material consisted of 96 patients 71 females and 25 males aged between 12 and 70 years (mean 50 years) examined at this department for mitral disease during 1973 and 1974 In all cases cardioangiography and cardiac catheterization with pressure measurements were performed in addition to conventional roentgen examina

Submitted for publication 8 November 1977




Fig 1 a) 49 year old male with deviation of the aorta (→) and esophagus due to posterior wedging of the enlarged left atrium b) 32 year old normal individual with straight descending aorta (→) c) 67 year-old male with unfolded aorta (→)

tions It was thus confirmed that true mitral disease with enlarged left atrium and increased pressure in the pulmonary circulation was present In 80 per cent of the patients the diagnosis was also confirmed by operation

The control material consisted of 102 patients 41 females and 61 males aged between 17 and 74 years (mean 41 years) randomly selected with no indication of cardio-pulmonary disease

Table

Findings in patients with mitral disease and in control group (in per cent)

	Enlarged left atrium	Control group
Posterior displacement of the esophagus	96 8	0
Double contour of the right heart border	91 6	8 8
Enlargement of the right ventricle	83 2	0
Deviation of the descending aorta	82 2	4 9
Distension of the pulmonary arteries	78 9	0
Distension of the left auricle	63 2	0
Right displacement of the esophagus	48 4	3 9
Enlargement of the left ventricle	45 3	0
Mitral valvular calcification	27 4	0
Impression on the left main bronchus	25 0	0
Left displacement of the esophagus	4 2	0

Results

Deviation of the aorta caused by an enlarged left atrium appears in Fig 1 A normal individual and a control patient with unfolding of the aorta are also shown for comparison

The abnormalities indicating mitral disease in the present material are listed in the Table A deviation of the descending aorta was a rather frequent finding It was found almost as often as posterior displacement of the esophagus double contour of the right heart border and enlargement of the right ventricle and pulmonary artery It i evidently more frequent than distension of the left auricle deviation of the esophagus to the right enlargement of the left ventricle calcification of the mitral valve and impression on the left main bronchus Deviation of the aorta always occurred in combination with one or more of the other abnormalities indicating left atrium enlargement Posterior displacement of the esophagus was present in all but one of the 79 cases with aortic deviation

Some of the findings suggestive of enlarged left atrium were occasionally also observed in the control group Thus a deviation or unfolding of the aorta at the level of the left atrium indistinguishable from the displacement associated with enlarged left atrium occurred in 4 9 per cent of the controls Furthermore physiologic unfolding of the aorta was found in 7 8 per cent of the controls while this was considered to occur in only 2 1 per cent of the patients with enlarged left atrium

The frequency of deviation of the aorta associated with enlarged left atrium increased with higher age more or less paralleling the increasing frequency of unfolding of the aorta in higher age groups of the control material (Fig 2) A markedly increased frequency of both these parameters was found in patients above 50 years of age

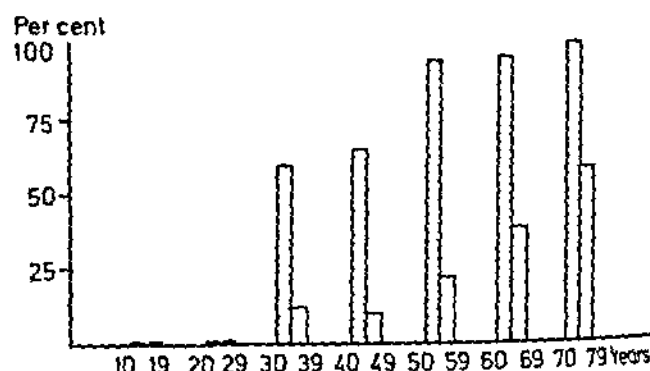


Fig 2 Frequency of aortic deviation in patients with left atrial enlargement (hatched columns) and unfolding of aorta in controls (open columns) in different age groups

The significance of the depth of the chest appears in Fig 3 As might be expected deviation of the aorta was more frequent in patients with a small sagittal diameter or a small distance between the heart and the spine

Discussion

The investigation by DEE was restricted to patients below 50 years of age as he considered the physiologic unfolding of the aorta to be a differential diagnostic problem in higher age groups However no further analysis of this matter seems to have been performed Therefore in the present series all age groups were included to elucidate if such an unfolding is a problem of real significance

The point of maximum deviation of the unfolded aorta is independent of the position of the normal left atrium while this point of the deviation associated with mitral disease is distinctly corresponding to the enlarged atrium Further the unfolded aorta is usually widened with a prominent aortic arch as opposed to the small aortic arch usually present in mitral disease Still the distinction between these two types

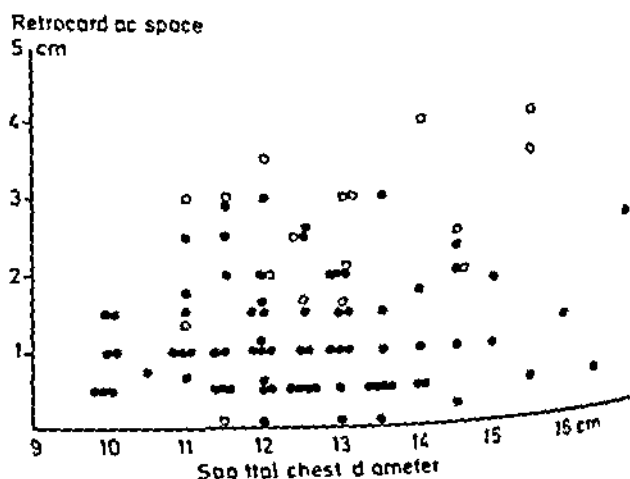


Fig. 3 Distribution of patients with enlarged left atrium with (●) and without (○) aortic deviation related to sagittal chest diameter and retrocardiac space

of aortic displacement may be difficult and physiologic unfolding at the level of the left atrium seems to be indistinguishable from displacement of the aorta caused by an enlarged left atrium This explains why Bedford s sign was considered to occur in some cases (4 9 per cent) of the control series as well as the low frequency (2 1 per cent) of physiologic unfolding of the aorta in the patients with left atrial enlargement The parallel increase with age of the frequency of the two types of aortic displacement (Fig 2) also indicates that a confusion is near at hand

Thus the present series confirms the suggestion of DEE that a deviation of the descending aorta is of limited diagnostic value in patients above 50 years of age Below that age this deviation seems to be supportive of the diagnosis of left atrial enlargement

Considering the close relation between the atrium aorta and the spine in normal patients the mechanism of the deviation of the aorta to the left is easily understood The aorta is closely related to the anterior aspect of the spine slightly to the left and under a pressure from in front the aorta will slide backwards and to the left of the spine It is also easily understood then that the deviation may be less marked or absent in patients with a great sagittal diameter or a relatively great distance between the heart and the spine (Fig 3) In 3 cases no deviation of the descending aorta was found in spite of a small sagittal diameter and a small retrocardiac space In one of these the heart was moderately rotated and the enlargement of the atrium extended mainly to the right of the spine In the remaining 2 a moderate scoliosis with left concavity was present and this probably compensated for a deviation of the descending aorta

SUMMARY

The deviation to the left of the descending aorta associated with enlarged left atrium was analysed in 96 patients with mitral disease confirmed by angiography and cardiac catheterization The opinion that this finding may be of value in patients below the age of 50 years was supported In older age groups it is easily confused with the physiologic unfolding of the aorta when this occurs at the level of the left atrium

ZUSAMMENFASSUNG

Die Abweichung der Aorta descendens nach links im Zusammenhang mit einem vergrösserten linken Atrium bei 96 Patienten mit nachgewiesener Mitralisklappenerkrankung wurde durch Angiographie und Herzkatheter Untersuchung analysiert Die Auffassung wird gestutzt dass diese Befunde bei Patienten unter einem Alter von 50 Jahren von Wert sein konnen In alteren Altersgruppen kann diese leicht mit der physiologischen Ausbreitung der Aorta verwechselt werden wenn diese auf dem Niveau des linken Atriums vorkommt

RESUME

La déviation vers la gauche de l aorte descendante associee avec une augmentation de volume de l oreillette gauche a ete etudiee chez 96 malades atteints de maladie mitrale confirmee par angiographie et par cathèterisme cardiaque Ce travail confirme l intérêt de ce

signe chez les malades ages de moins de 50 ans Chez les sujets plus agés ce signe est aise ment confondu avec le deroulement physiologique de l aorte quand il apparait au niveau de l oreillette gauche

REFERENCES

CHEN J T T LESTER R G and PETER R H Posterior wedging sign of mitral insufficiency Radiology 113 (1974) 451

DEE P M Deviation of the descending thoracic aorta as a sign of left atrial enlargement Radiology 112 (1974) 57

DUNNE E F Cardiac radiology pp 6 10 Lea & Febiger Philadelphia 1967

FROM THE DEPARTMENT OF DIAGNOSTIC RADIOLOGY AKADEMISKA SJUKHUSET S 750 14
UPPSALA SWEDEN

ROENTGENOLOGIC EXAMINATION OF TRACHEAL STENOSIS

ANDERS HEMMINGSSON and PER GUNNAR LINDGREN

The increased use of prolonged tracheal intubation and tracheostomy for ventilatory support has led to a rising frequency of tracheal stenosis (WEBB et coll 1974 HALTTUNEN et coll 1974 GERWAT & BRYCE 1974 COULSON et coll 1974 MEYER 1972 and others) Up to 10 per cent of surviving patients who have undergone this treatment have thus been reported to develop stenosis (ANDREWS & PEARSON 1971 WESTGATE & ROUX 1970) These lesions are located mainly at the site of the tracheostoma or the endotracheal tube (LINDHOLM 1969 HALTTUNEN et coll COULSON et coll) Instances of external trauma against the cervical part of the trachea with stenosis caused by partial or total tracheal rupture also seem to have increased in recent years (BERGSTRÖM et coll 1977)

The treatment of significant stenosis i e with a reduction of the cross sectional area of the trachea 30 to 50 per cent (KORNMESSER 1974 HOMMERICH & FLEMMING 1974 LANGE & ZIEGLER 1975) generally consists in resection of the stenotic area and end to-end anastomosis or dilatation Whatever method is chosen it is essential to determine the location length and width of the stenosis before treatment This is possible to some extent by means of tracheoscopy but in most cases an exact determination requires radiography in addition (WEBB et coll 1974 LANGE & ZIEGLER HALTTUNEN et coll FRIEDMAN et coll 1975 COULSON et coll) The type of roentgen examination that is considered adequate varies from conventional radiography (HALTTUNEN et coll) and tomography (LANGE & ZIEGLER COULSON et coll) to radiography with positive contrast medium (FRIEDMAN et coll WEBB et coll) It is thus not clear which roentgenologic method is preferable for evaluation of

Submitted for publication 4 February 1977

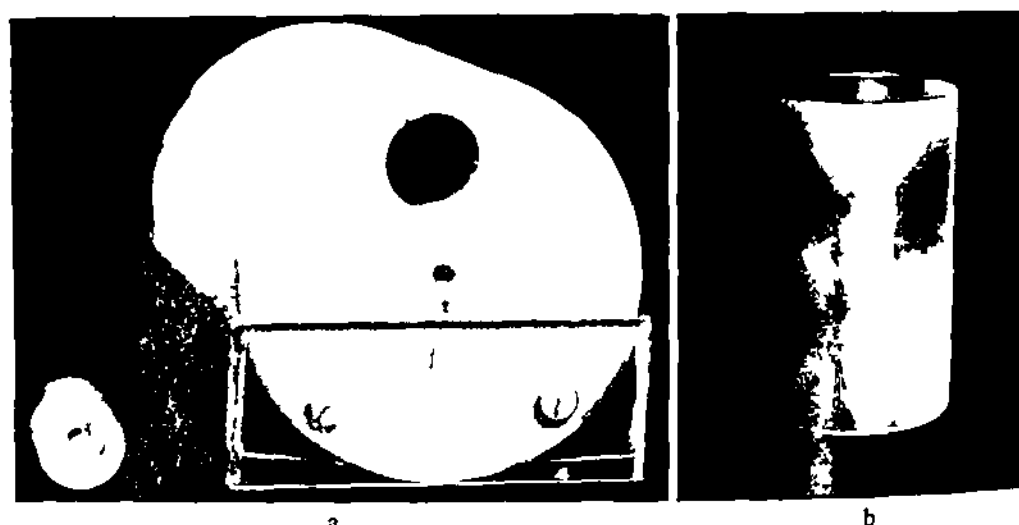


Fig 1 a) The cervical phantom with the stenosis b) The stenosis alone

tracheal stenosis A comparison has therefore been made between conventional roentgenography tomography and tracheography in phantom experiments and in clinical examinations of 55 patients with this condition The location of the stenoses and their appearance before during and after dilatation are also described

Material and Methods

Phantom experiments A cervical phantom constructed of a cervical vertebral column embedded in the soft tissue substitute Mix D (HEMMINGSSON 1971) was used in combination with a tracheal stenosis of plexiglass which was inserted into a drilled hole in the phantom representing a trachea (Fig 1) A thin layer of Dionosil suspension (Glaxo) was applied to the inner surface of the tracheal stenosis in the tracheographies

Conventional roentgenography tracheography and linear tomography at angles of 20 and 44 using an MT 2 (Philips) tomograph, were performed A focal spot of 1 2 mm × 1 2 mm was used and the tube potential was 150 kV with an extra 1 mm brass filter The film focus distance was 140 cm and the film object distance 20 cm A grid with a ratio of 7 1 was employed Circular tomography at an angle of 29 was performed on a Philips Polytome with a focal spot of 0 6 mm × 0 6 mm 120 kV film focus distance 150 cm and film object distance 40 cm No grid was used in circular tomography

The exposure time in conventional roentgenography and tracheography was 0 1 s and in linear tomography at exposure angles of 20 and 44° it was 0 4 s and 1 0 s respectively In circular tomography at 29 it was 2 8 s X omatic H film with X omatic Regular intensification screens (Kodak) was used in all examinations

Table 1

Length and width of the stenosis in phantom experiments

Method	Position of phantom	Stenosis Length (mm)		Width (mm)	
		20	50	5	30
Conventional radiography	horizontal	20	50	5	30
	inclined	18	46	5	30
Tracheography	horizontal	20	50	5	30
	inclined	18	46	5	30
Tomography linear 20	horizontal	20	50	5	30
linear 20	inclined	20	49	5	29 30
linear 44	horizontal	20	50	5	30
linear 44	inclined	22	52	4 5–5 5	27 5–30
circular 29	horizontal	20	50	5	30
circular 29	inclined	23	53	3 2–5 8	17–33

The examinations were performed with the trachea of the phantom both horizontal i e with its longitudinal axis perpendicular to the beam and inclined 20 from the horizontal plane i e at an angle of 70 to the beam Linear tomography was carried out both in the longitudinal axis of the trachea and perpendicular to this axis

The length and width of the simulated tracheal stenosis were measured on optimum films obtained by different methods (Table 1) The values in the table have been reduced by the respective magnification factors

Clinical examinations Fifty five consecutive cases of tracheal stenosis were examined during the period 1968 to 1975 The distribution of the patients by age and sex in relation to the site of the stenosis is given in Table 2

Table 2

Distribution of the 55 patients by age sex and location of the tracheal stenosis

	Years 0–9 F	M	10–19 F	M	20–29 F	M	30–39 F	M	40–49 F	M	50–59 F	M	60–69 F	M	70–79 F	M	80–98 F	M	Total
Subglottic region					1	1					1								3
Cervical part	2	2		1		4		1			5	3	3	5	4	2			32
Intrathoracic part				3	1	1	4	1			3	4	1	1		1			20
Total	2	2		4	2	6	4	2			9	7	4	6	4	3			55

The probable causes of the stenoses are listed in Table 3 Patients were assigned to the first two groups on the basis of information on the site of the tracheostoma or the length of the endotracheal tube and the position of its cuff during intubation The group various includes 3 cases of tracheal rupture with consequent stenosis 3 cases of collagenosis and one case of radiation injury In one patient the cause of the stenosis could not be established

Information on the location length and width of the stenosis was obtained from the tracheoscopy and operation reports when available Otherwise the findings at the different roentgen examinations were combined The trachea was divided into a subglottic a cervical and a thoracic part located 0–2 2–6 and 6–16 cm respectively below the vocal cord plane

Conventional roentgenography and tracheography were performed in the p.a oblique and lateral projections with a tube potential of 150 kV and an extra 1 mm brass filter (HEMMINGSSON 1972) A p and lateral linear tomography at an angle of 20 was performed in the longitudinal axis of the trachea with a tube potential of 150 kV at an exposure time of 0 1 s Conventional roentgenography in the lateral projection with a low tube potential (about 60 kV) was also carried out in cases of bone grafting to the anterior wall of the trachea for evaluation of the position and appearance of the graft For tracheography the contrast medium Dionosil was administered by the technique described by POWERS et coll (1957) for laryngography In patients undergoing dilatation with a T tube contrast medium was sometimes also administered via a catheter inserted through the T tube after anaesthesia

Table 3

Cause and location of the 55 stenoses

	Stoma	Cuff	Various	Total
Subglottic region	1		2	3
Cervical part	22	5	5	32
Intrathoracic part	1	18	1	20
Total	24	23	8	55

Table 4

Number of patients in whom a correct evaluation of the length and width of the stenosis in relation to its cause was possible with the different methods (absolute figures and percentages)

Cause of stenosis	Conventional radiography		Tomography		Tracheography	
	Length	Width	Length	Width	Length	Width
Tracheostoma	20/24	18/24	7/9	4 9	20 0	19 20
Tube cuff	21/23	16 23	4/5	3 5	23/23	23/23
Various	5/8	5/8	0 3	0 3	8/8	8 8
Total	46/55 (84)	39 55 (71)	11/17 (65)	7/17 (41)	51/51 (100)	50 51 (98)

The three methods of roentgen examination were compared with respect to the possibility of assessing the length and width of the stenoses (Tables 4 5) Conventional roentgenography was performed in all 55 patients while 51 underwent tracheography and 17 tomography In some cases cineradiography was also carried out to evaluate variations in the width of the stenosis in different respiratory phases

Results

Phantom experiments The length and width of the tracheal stenosis could be evaluated with a good degree of accuracy both at conventional roentgenography and at tracheography with the longitudinal axis of the trachea perpendicular to the beam (Table 1 Fig 2 a b) The evaluation was more reliable however at the latter than at the former examination Similarly both in linear and in circular tomography the stenosis could be evaluated correctly with the beam perpendicular to the longi

Table 5

Number of patients in whom a correct evaluation of the length and width of the stenosis in relation to its cause and location was possible with the different methods (absolute figures) Cause of stenosis s = tracheostoma c = tube cuff v = various

	Conventional radiography						Tomography						Tracheography					
	Length			Width			Length			Width			Length			Width		
	c	s	v	s	c	v	s	c	v	s	c	v	s	c	v	s	c	v
Subglottic region	0/1		1/2	0/1		1/2	0/1		0/1	0/1		0/1	1/1		2/2	1/1		2/2
Cervical part	20 22	5/5	4/5	18/22	4/5	4/5	7/8	0/1	0 1	4/8	0/1	0/1	18/18	5/5	5/5	17/18	5/5	5/5
Intra thoracic part	0 1	16/18	0/1	0/1	12/18	0/1		4/4	0/1		3/4	0/1	1/1	1/1	18/18	1/1	18/18	1/1

tudinal axis of the trachea when the tomographic plane was in the centre of the stenosis (Fig 2 d f) When in linear tomography in the longitudinal axis of the stenosis the tomographic plane lay 1 cm outside the centre of the stenosis the length of the stenosis could not be determined exactly and values 3 to 7 mm too high were obtained (Fig 2 e) Such distortion did not occur at tomography perpendicular to the longitudinal axis of the stenosis At circular tomography with the tomographic plane 0 5 cm eccentrically the stenosis appeared to have a double contour

When the phantom was inclined 20 to the horizontal plane (70 to the direction of the beam) both at conventional roentgenography and at tracheography the stenosis was shortened by 2 to 3 mm while its width was evaluated correctly (Fig 2 c) Both at linear and at circular tomography with the trachea of the phantom in this position the stenosis was lengthened by 3 to 4 mm At tomography in this projection the width of the proximal and distal parts of the stenosis varied by up to about 2 5 mm and the width of the trachea proximal and distal to the stenosis by up to 16 mm (Table 1 Fig 2 g h)

Clinical examinations Three of the stenoses were subglottic one of these was caused by a high tracheostomy and the other two by collagen disease (Table 3) The majority of the stenoses (32 of them) were located 2 to 6 cm below the vocal cord plane Of these 22 were believed to have been caused by a tracheostomy and 5 by a high endotracheal tube cuff Three further stenoses in this area were due to tracheal rupture and one to radiation damage and in one patient the cause of the stenosis could not be established Low stenosis 6 to 16 cm below the vocal cord plane was present in 20 patients in 18 of them the stenosis was considered to be located at the site of the tube cuff In one patient it was due to collagenosis and in another patient to a low tracheostomy

The length of the stenoses varied from 3 mm to 4 cm the majority being 1 to 2 cm long The width varied from 3 to 14 mm generally being 6 to 7 mm

A correct evaluation of the length and width of the stenosis could be made in 100 and 98 per cent respectively at tracheography in 84 and 71 per cent at conventional roentgenography and in 65 and 41 per cent at tomography (Table 4) In the patient who could not be evaluated correctly at tracheography parts of the stenosis were not satisfactorily coated with contrast medium At conventional roentgenography it was mainly the width of the more distally located stenoses caused by an endotracheal tube cuff that was difficult to evaluate correctly (Table 5) Furthermore marked short stenoses were difficult to measure both at conventional roentgenography and at tomography

For evaluating the position of a tube inserted for dilatation in relation to the stenosis and vocal cords or carina complementary examination with positive contrast medium was often necessary (Fig 6)

In 5 patients the appearance of the mucous membrane in the stenotic area appeared irregular at tracheography indicating granulation tissue (Fig 3) This was not visible

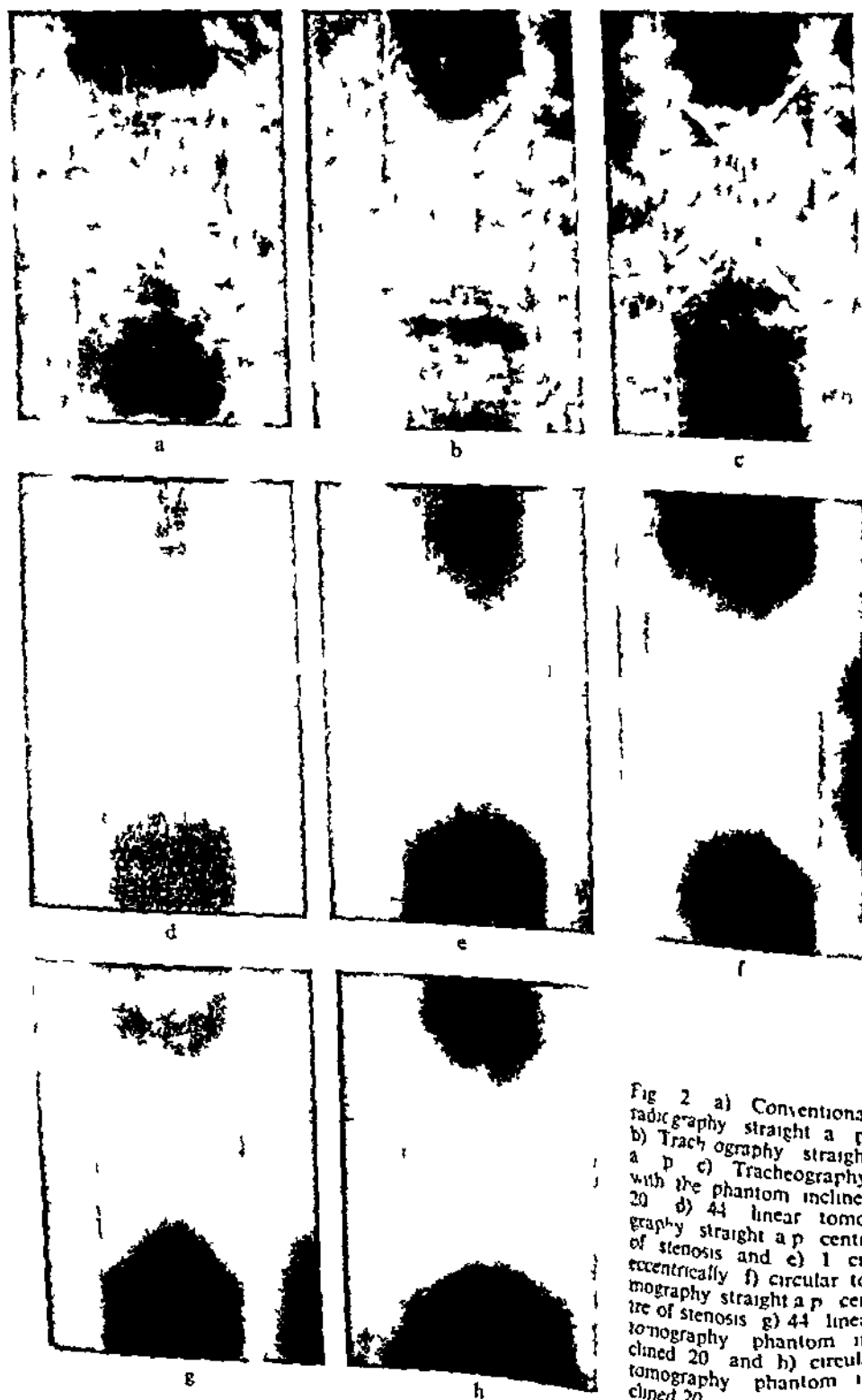


Fig 2 a) Conventional radiography straight a p b) Tracheography straight a p c) Tracheography with the phantom inclined 20 d) 44 linear tomography straight a p centre of stenosis and e) 1 cm eccentrically f) circular tomography straight a p centre of stenosis g) 44 linear tomography phantom inclined 20 and h) circular tomography phantom inclined 20




Fig 3 Tracheography of stenosis at the site of the tracheostoma (a b) before and (c d) after 1 year of dilatation treatment Before treatment the smallest diameter of the stenosis is 5 mm in the frontal plane with a lip from the right (→) The mucosal surface is irregular (a b) After treatment the stenosis is more regular in outline and the smallest diameter is 9–10 mm (c d)

at the other types of examinations Further in 14 of the patients with stenosis at the site of a tracheostomy a lip formation was observed in the a p and lateral views but was only clearly outlined at examination with positive contrast medium (Fig 3) Variations in the width of the stenosis in different respiratory phases were noted in a few cases as a sign of instability of the tracheal wall

A typical stenosis caused by a tracheostomy is illustrated in Fig 3 a high cuff stenosis in Fig 4 and a cuff stenosis mid way between the high and low sites in Fi 5 A typical case demonstrating the difficulties in evaluating low stenoses is depicted in Fig 6 where the lower end of the cuff stenosis is located close to the branching of the trachea Because of the length of the stenosis—just over 3 cm—dilatation was chosen in preference to resection The difficulty in estimating the position of the tube is demonstrated in Fig 6 In the a p view the tube appeared to cover the stenosis (Fig 6 b) while in the lateral view it was evident that dorsally it did not cover it (Fig 6 c) This evaluation could not be made without examination with positive contrast medium

Discussion

Phantom experiments The width of the stenosis could be evaluated correctly at conventional roentgenography and tracheography both with the beam perpendicular to the longitudinal axis of the trachea and with the trachea inclined 20 to the horizontal plane which corresponds to its normal course

The shortening of the stenosis by 2 to 3 mm at conventional roentgenography and tracheography on the a p film when the trachea of the phantom was inclined 20 is in accord with the geometric projection conditions This should be kept in mind

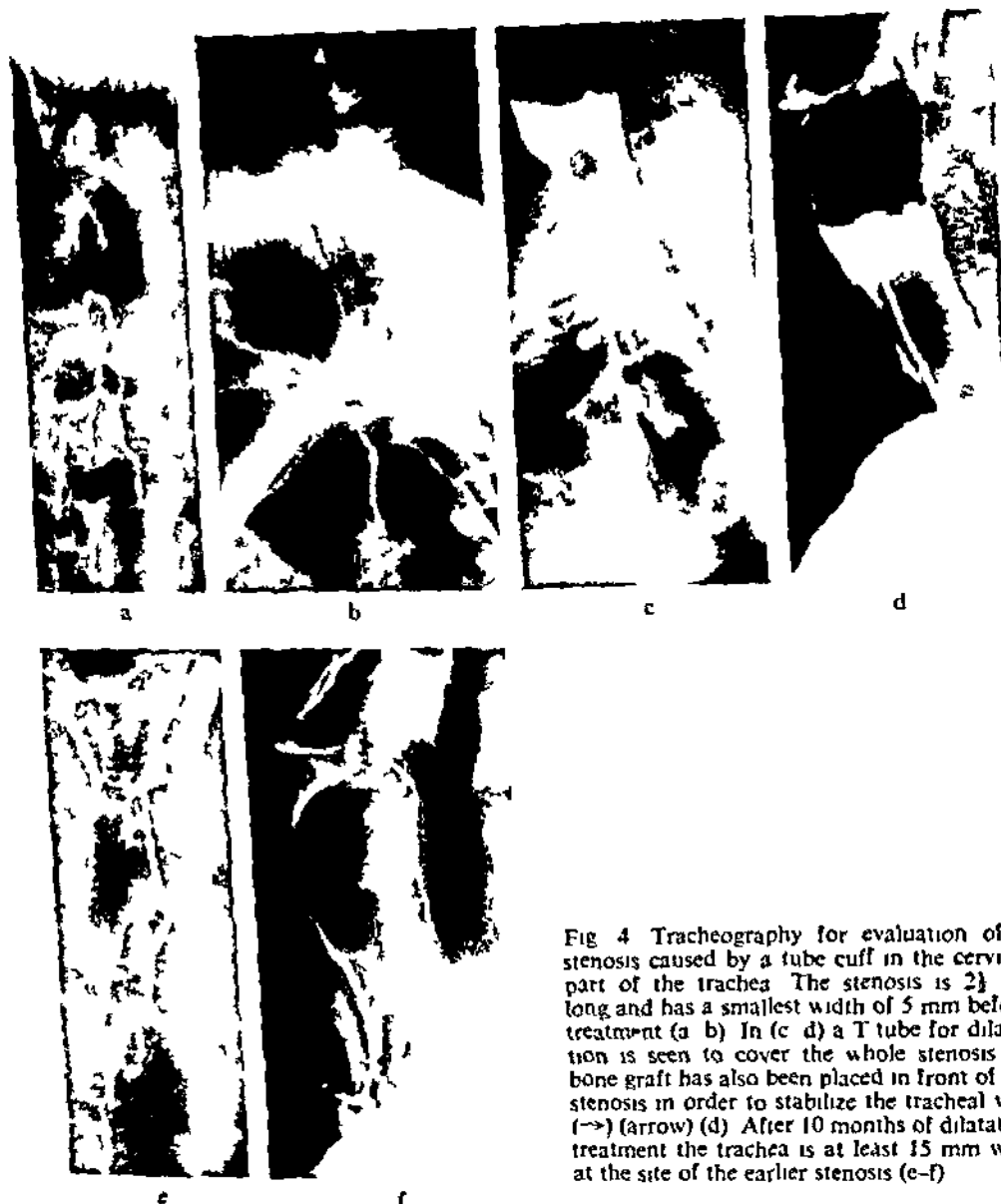


Fig 4 Tracheography for evaluation of a stenosis caused by a tube cuff in the cervical part of the trachea The stenosis is 2½ cm long and has a smallest width of 5 mm before treatment (a b) In (c d) a T tube for dilatation is seen to cover the whole stenosis A bone graft has also been placed in front of the stenosis in order to stabilize the tracheal wall (→) (arrow) (d) After 10 months of dilatation treatment the trachea is at least 15 mm wide at the site of the earlier stenosis (e–f)

in clinical examinations which for an exact evaluation of the length of the stenosis require that the beam be directed at right angles to the trachea

When the longitudinal axis of the phantom trachea lay perpendicular to the beam the length and width of the stenosis could also be evaluated correctly at tomography However when the tomographic plane lay outside the centre of the stenosis the image was geometrically distorted This was more distinct when the phantom was inclined 20° to the horizontal plane At tomography in this position the width of the



Fig 5 Tracheography of a cuff stenosis at middle level in the intrathoracic part of the trachea The stenosis is 1½ cm long and has a smallest diameter of 12–13 mm In this case the stenosis was resected with end to-end anastomosis

proximal and distal parts of the stenosis thus varied both at linear and at circular tomography (Table 1 Fig 2) On the film the stenosis also appeared lengthened with this oblique course of the trachea This erroneous length and width of the stenosis at tomography with the object inclined 20 to the horizontal plane is probably due to the false outlines described among others by LODIN (1953) and REICHMANN (1972) which appear at tomography of cylindrical objects These false images mean that tomography in the a p projection is an unsatisfactory method for examination of tracheal stenoses unless correction is made for the oblique course of the trachea in the sagittal plane

Clinical examinations The finding that the majority of the stenoses 32 of 55 were located in the cervical part of the trachea is in agreement with previous reports (LANGE & ZIEGLER among others) The two main causes of the stenoses were tracheostomy injury (22/55) and injury caused by the cuff of an endotracheal tube (23/55) (Table 3) which corresponds to the findings reported by WEBB et coll and HALTTUNEN et coll The length of the stenosis generally 1 to 2 cm and its smallest width about 6 to 7 mm are also in agreement with the observations by these authors

The length and width of the stenoses could best be evaluated at tracheography which corresponds to the findings in the phantom experiments In cases of high and low stenoses that are to be treated by dilatation it is of particular importance to be able to demonstrate their boundaries exactly as the length and width of the dilatation tube must be adapted exactly to the stenosis (Fig 6)




Fig 6 Tracheography of a low cuff stenosis (a) before and (b c) during dilatation treatment The length of the irregular stenosis is about 3 cm and the smallest width 4 mm (a) The dilatation tube does not pass through the stenosis in the lowest posterior part adjacent to the carina (→)

The stenoses that were most difficult to evaluate without positive contrast medium were mainly of the short type with a narrow lumen This was probably due to the small amount of contrast giving air within these stenoses Moreover at conventional roentgenography it was difficult to assess the width of the thoracic stenoses correctly due to disturbance from the pulmonary and skeletal structures

At tomography about half of the stenoses could not be evaluated correctly as in the a p projection the trachea is not parallel with the tomographic plane A correction is difficult as the trachea has a slightly curved course in the sagittal plane These facts cause a false reproduction of the length and width of the stenosis This is in agreement with observations in the phantom experiments

Irregularities of the mucosal surface reflect the occurrence of granulation tissue and could only be demonstrated clearly at examination with positive contrast medium as has also been found in examination of the larynx (HEMMINGSSON 1972) Further variations in the width of the stenosis in different respiratory phases could only be perceived at positive contrast examinations most clearly in combination with cine radiography

Conclusions

In this series of patients the two main causes of clinically significant tracheal stenosis were injury by the cuff of an endotracheal tube and tracheostomy which occurred in an equal frequency In addition during the 7 year period in question a few stenoses were caused by tracheal rupture or collagen disease

The investigation has shown that the location length and width of the stenosis is best evaluated by examination with positive contrast medium—tracheography This method is also superior for evaluating the position of a dilatation tube relative to the stenosis If tracheography is not possible, conventional roentgenography with a high tube potential is recommended *Tomography in the a p projection gives a false image* of the stenosis as the trachea is not parallel with the frontal plane of the body this method is therefore not recommended

SUMMARY

Conventional roentgenography tomography and tracheography were compared for evaluation of tracheal stenosis in phantom experiments and in 55 patients It was found that the stenosis as well as the relative position of a tube inserted for dilatation is best evaluated by tracheography If this method cannot be used conventional roentenography with a high tube potential gives a better result than tomography

ZUSAMMENFASSUNG

Die konventionelle Rontgenuntersuchung die Tomographie und die Tracheographie wurden verglichen um eine Trachealstenose in Phantomexperimenten und bei 55 Patienten festzustellen Die Stenose sowie die relative Lage eines eingesetzten Tubus zur Dilata on wurde am besten durch die Tracheographie festgestellt Wenn diese Methode nicht ver wendet werden kann gibt die *konventionelle Rontgenuntersuchung* mit hoher Rohren spannung ein besseres Resultat als die Tomographie

RÉSUME

Les auteurs ont comparé la radiographie simple la tomographie et la trachéographie pour le diagnostic des stenoses trachéales *par une étude expérimentale* sur des fantomes et sur 55 malades Ils ont constaté que c est la trachéographie qui permet le mieux d apprécier la stenose ainsi que la position relative d un tube introduit pour la dilatation Si cette méthode ne peut pas etre utilisee la radiographie simple en haute tension donne un meilleur résultat que la tomographie

REFERENCES

Andrews M J and Pearson F G Incidence and pathogenesis of tracheal injury follow g cuffed tube tracheostomy with assisted ventilation Analysis of a two-year prospective study Ann Surg 173 (1971) 249

Bergström B Ollman B and Lindholm C E Endotracheal excision of fibrous tracheal stenosis and subsequent prolonged stenting An alternative method in selected cases Chest 71 (1977) 6

Coulson A S Rossiter S J and Guernsey J M Progressive tracheal obstruction J thorac cardiovasc Surg 67 (1974) 733

Friedman W H Biller H F and Som M L Repair of extended laryngotracheal stenosis. Arch Otolaryngol 101 (1975) 152

GERWAT J and BRYCE D P The management of subglottic laryngeal stenosis by resection and direct anastomosis Laryngoscope 84 (1974) 940
HALTTUNEN P MATTILA S and MEURALA H Tracheal resection in the treatment of tracheal strictures Ann Chir Gynaec Fenn 63 (1974) 358
HEMMINGSSON A Cervical phantom for evaluation of different methods of roentgen examination of the larynx Acta radiol Diagnosis 11 (1971) 515
— Roentgenologic examination of the larynx A clinical comparison Acta radiol Diagnosis 12 (1972) 433
HOMMERICH K W and FLEMMING I Classification of laryngotracheal stenoses Oto Rhinol Laryngol 36 (1974) 100
KORNMESSER H J Segmentresektion der Trachea im Kindesalter Laryng Rhinol Otol 53 (1974) 395
LANGE G and ZIEGLER K Therapeutic problems in laryngo-tracheal stenoses ORL 37 (1975) 48
LINDHOLM C E Prolonged endotracheal intubation Acta anaesth scand (1969) Suppl No 33
LODIN H The value of tomography in examination of the intrapulmonary bronchi Acta radiol (1953) Suppl No 101
MEYER R New concepts in laryngotracheal reconstruction Trans Amer Acad Ophthal Otolaryng 76 (1972) 758
REICHMANN S Development of spurious contours of spherical and cylindrical objects in tomography Acta radiol Diagnosis 12 (1972) 317
POWERS W E McGEE H H and SEAMAN W B Contrast examination of the larynx and pharynx Radiology 68 (1957) 169
WEBB W R OZDEMIR I A IKINS P M and PARKER F B Surgical management of tracheal stenosis Amer Surg 179 (1974) 819
WESTGATE H D and ROUX JR K L Tracheal stenosis following tracheostomy Incidence and predisposing factors Anesth Analg 49 (1970) 393

FROM THE DEPARTMENT OF PHYSIOLOGY UNIVERSITY OF AACHEN D-5100 AACHEN GERMANY

EFFECT OF IONIC AND NON-IONIC CONTRAST MEDIA ON RED CELL AGGREGATION IN VITRO

P ASPELIN and H SCHMID SCHÖNBEIN

In 1959 three different groups (SOBIN et coll MARGOLIS et coll READ et coll) first reported retardation of blood flow and increased red cell aggregation following the intravascular injection of ionic contrast media

SOBIN et coll found increased red cell agglutination in the conjunctival vessels following urography

MARGOLIS et coll observed an increased aggregation in the vessels of the spinal cord following retrograde aortic injections of ionic contrast media in dogs They also noticed that the agglutination was followed by an increased resistance in the vascular bed in the spinal cord and suggested that this increased resistance might explain the toxicity of the media in this region

An increased red cell aggregation in the pulmonary vascular bed following right heart injection of ionic contrast media in dogs was found by READ et coll Furthermore they found a correlation between this increased red cell aggregation and an increased resistance in the pulmonary vessels resulting in a rise in pulmonary artery pressure They also found that the presence of red cells was necessary to induce this rise in pulmonary artery pressure Other hypertonic solutions than contrast media induced similar increase in pulmonary artery pressure and this resistance to flow

Supported by the Swedish Medical Research Council Project No 3483 (P A is now at Department of Diagnostic Radiology Malmo Allmänna Sjukhus S-214 01 Malmö Sweden) Submitted for publication 21 September 1977

through the lung capillaries increased with increasing osmolality of the injected solutions

Recent reports on blood rheology have clearly shown that red cell aggregation increases the viscosity of blood This in turn causes a flow retardation but also the opposite may occur

Thus a flow retardation (of any cause) induces an increased red cell aggregation followed by an increased viscosity and stasis (SCHMID-SCHÖNBEIN et coll 1972) Numerous authors have confirmed that intravenous injection of hypertonic solutions produces pulmonary arterial hypertension (ALMEN 1973 ALMÉN & ASPELIN 1975 BINET & BURSTEIN 1951 1953 ELIAKIM et coll 1958 1961 READ et coll 1959 1960 1961 SNIDER 1973 WATSON 1964) The clinical importance of this rise in pulmonary artery pressure has been discussed by READ (1959) READ & MEYER (1959) SNIDER and WATSON This elevation may be fatal especially in patients with obstruction in the pulmonary circulation (SNIDER WATSON)

With the development of non ionic contrast media (ALMÉN 1969 HOLTERMANN 1973) a contrast medium is now available that in iodine equivalent concentrations has a much lower osmolality than presently used ionic contrast media In experi mental investigations on rabbits this low osmotic medium has proved to induce less rise in pulmonary artery pressure than the high osmotic ionic contrast media with which it was compared (ALMÉN 1973 ALMEN & ASPELIN) This would thus be explained according to the theories of READ et coll (1960) by the assumption that the low osmotic non ionic contrast medium induces less red cell aggregation than the high osmotic ionic contrast media

It is an old observation that the light transmission of flowing blood varies with the rate of flow and KRAMER (1935) was the first to measure this phenomenon quantita tively Later it was shown that this optical phenomenon was caused by red cell aggregation (BRINKMAN et coll 1963) and axial migration (TAYLOR & ROBERTSSON 1954) i e the same factors that are responsible for the non Newtonian flow properties of blood (GOLDSMITH & MASON 1965) Red cell aggregation at low shear rates and red cell deformation at high shear rates were responsible for this anomalous vis cosity of blood in vitro (SCHMID SCHÖNBEIN & WELLS 1969)

These properties of the blood have been thoroughly investigated and confirmed with the development of the rheoscope (KLOSE et coll 1972 SCHMID SCHÖNBEIN et coll 1969) This is a counter rotating viscometer in which the cone plate has been made transparent thereby making it possible to measure the light transmission through the blood in viscometric flow and to analyse the microrheologic behavior of the blood in a microscope or by microphotography

The transmitted light is monitored with a photocell and the photometric events can thus be correlated with the microphotogram Previously KLOSE et coll (1972) and SCHMID-SCHONBEIN et coll (1972 1975) demonstrated that the light transmission of normal human blood presents a biphasic behavior when plotted as a function of shear rate Between 0 and 60 s^{-1} the light transmission decreases with shear rate

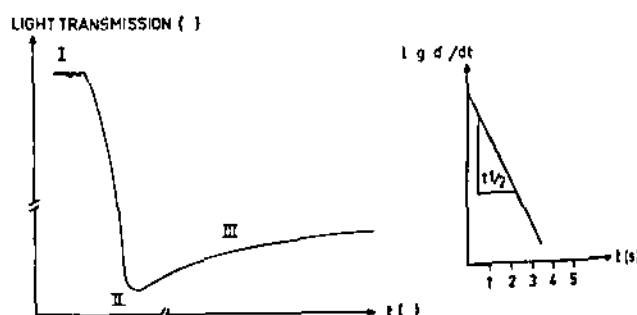


Fig 1 Normal blood Changes of light transmission (v) during aggregate formation To the left the obtained syllectogram I represents the light transmission (photovoltage) at shear rate 400 s^{-1} II the decrease in photovoltage at stop (0 s^{-1}) and III the increase in photovoltage during red cell aggregate formation To the right the exponential decay of the derivate of the syllectogram expressed as log (dv/dt) plotted against time and the half time of the decay is evaluated

corresponding to red cell aggregate dispersion Above 60 s^{-1} an increase in light transmission with shear rate occurs corresponding to red cell deformation and axial migration Thus with the development of the rheoscope a method has become available for the objective quantification of red cell aggregation (KLOSE et coll SCHMID SCHÖNBEIN et coll 1969 1972) The present communication reports the effect of a low osmotic non ionic contrast medium on red blood cell aggregation and compares it with that of currently used high osmotic ionic contrast media

Principle of the method

When normal blood is subjected to rapid viscometric flow all the red blood cells are dispersed and aligned in flow When the flow is abruptly stopped the cells rapidly turn from the aligned state to a state of random distribution and then to the formation of red cell aggregation In transmission photometry performed when flowing blood is abruptly stopped the following occurs The light transmission first reaches a minimum when the cells are randomly distributed and then it increases rapidly at first and then more slowly when the red cell aggregation occurs The photometric changes (light transmission v) are plotted as a function of time which gives what is called a syllectogram (Fig 1)

The photovoltage signal thus contains three components A steady state voltage *I corresponding to the light transmission at 400* s^{-1} *where the red cells are aligned* and dispersed Upon stop the light transmission and thus the photovoltage decreases to a minimum II where the red cells are randomly distributed and then starts to increase again reaching a steady state value III after 60 seconds This stage corresponds to the red cell aggregate formation and is obtained only in aggregating samples Thus differences between an increased or reduced aggregation compared with normal blood are shown in differences in the slope of the curve between II and III The rise in photovoltage with an increased aggregation is much steeper and with decreased aggregation less steeper than that of normal blood These differences become even more evident when the first derivate (dv/dt) is plotted semilogarith

Table 1

Osmolality and iodine concentration

Contrast media	Osmolality (osm)	Iodine content (mg I/ml)
Urografin 76	2.1	370
Urografin 60	1.5	290
*Urografin**	0 3	55
Isopaque Cerebral	1 5	280
Isopaque Cerebral	0 3	55
Isopaque Coronar	2 1	370
Isopaque Coronar*	0 3	55
Dimer X	1 1	280
Dimer X	0 3	80
Amipaque	0 7	370
Amipaque	0 5	280
Amipaque	0 3	170
Amipaque* + (mannitol)	0 3	55
Meglumine metrizoate	0 3	55
Sodium metrizoate*	0 3	55

* Extemporaneous solution

mically as a function of time (Fig 1) Then the $t_{1/2}$ (when dv/dt decays to the half) can be evaluated Thus a high $t_{1/2}$ compared with normal blood denotes a decreased ability of the red cells to aggregate and a low $t_{1/2}$ denotes an increased red cell aggregation

Material and Methods

Blood from 7 healthy human subjects was obtained by vein puncture and anticoagulated with EDTA (1 5 mg/ml) After centrifugation the hematocrit was adjusted to 45 per cent Plasma was then removed and replaced with contrast medium solution in order to prepare different volume ratios between contrast media and blood

The effect of the following compounds on red cell aggregation was investigated

A Ionic contrast media Urografin (meglumine/sodium diatrizoate) Isopaque Cerebral (meglumine/calcium metrizoate) Isopaque Coronar (meglumine/sodium/calcium metrizoate) Dimer X (meglumine iocarmate) Sodium metrizoate and Meglumine metrizoate

B Non ionic contrast media Amipaque (metrizamide)

C NaCl 10 NaCl 0 9 % and Dextran T250 (1 5)

The iodine content and the osmolality of the tested contrast media solutions are presented in Table 1 Since other concentrations were needed than those commercially available extemporaneous solutions were prepared either by a dilution with sterile

Table 2

Effect of different test solutions on half time of red cell aggregation ($t_{1/2}$) $t_{1/2}$ of blood without additive 2 3±0.2 s The values presented are mean values ± SD (n=7)

Test solutions	Volume ratio ( ) (test solution/blood)			
	0 5	2 0	5 0	10 0
Amipaque – mannitol 55 mg I/ml	2 4±0 3	3 4±0 9	7 2±1 5	∞
Amipaque 280 mg I/ml	2 8±1 0	35 7±11 0	∞	∞
Amipaque 370 mg I/ml	3 6±1 3	44 0±14 0	∞	∞
Dimer X 80 mg I/ml	2 4±0 4	2 6±0 7	3 7±1 0	7 3±1 0
Dimer X 280 mg I/ml	2 6±0 4	3 7±0 8	7 2±2 3	10 0±2.1
Isopaque Cerebral 55 mg I/ml	2 6±0 6	3 0±0 7	6 6±1 6	10 [illegible]±2.8
Isopaque Cerebral 280 mg I/ml	2 6±0 6	5 4±1 7	28 4±4 5	∞
Isopaque Coronar 370 mg I/ml	*2 7±0 4*	*5 9±0 6*	*44 0±4 7*	∞
Urografin 55 mg I/ml	2 4±0 4	2 5±0 4	4 0±0 6	8 4±1 1
Urografin 290 mg I/ml	2 6±0 4	4 2±0 6	10 5±5 3	∞
Urografin 370 mg I/ml	2 7±0 4	4 5±1 3	14 1±9 0	∞
Meglumine metrizoate 55 mg I/ml	2 4±0 3	2 9±0 8	5 1±1 0	11 0±2 0
Sodium metrizoate 55 mg I/ml	2 5±0 3	3 1±0 7	5 5±1 2	10 0±1 9
NaCl 10	3 4±0 8	10 1±1 5	40 0±5 7	∞
NaCl 0 9	2 3±0 3	2 4±0 3	2 7±0 3	3 [illegible]±0 4
Dextran T250 1 5 g (volume ratio 45)		1 3±0 4		

water or by adding mannitol in order to increase the osmolality The osmolality of the extemporaneous solutions was measured by freezing point determination (Knauer Osmometer)

The following volume ratios contrast medium/blood were prepared 0 5 2 5 and 10 per cent respectively

The samples obtained were evaluated in a microscopic flow chamber (see Principle of method) For photometry the light transmitted through the sample was projected into a photocell mounted on an ocular The photocell was connected via an amplifier to a DC-compensation recorder (RE 520 Metrawatt) One syllectogram at each volume ratio (contrast medium/blood) was obtained from each of the blood donors and the corresponding t_{1} was evaluated

For photography the image of the blood in the chamber was projected into a camera (Exacta Varex 2B) For illumination a stroboscopic flash light (Strobex model 136) synchronized to the camera was used

Results

The $t_{1/2}$ (mean values ± SD) calculated from the obtained syllectograms (n=7) at each volume ratio are presented in Table 2

Effect on red cell aggregation ($t_{1/2}$) of contrast media solutions isotonic (0 3 osm) with blood

At 0 5 and 2 per cent volume ratio No significant difference between the $t_{1/2}$ of the different contrast media or between the contrast media solutions and the physiologic saline (0 9 %) (p > 0 02) was found

At 5 per cent volume ratio The $t_{1/2}$ of Amipaque + mannitol (7 2 ± 1 5) and Isopaque Cerebral (6 6 ± 1 6) was higher (p < 0 001 and p < 0 01 respectively) than those of Dimer X (3 7 ± 1 0) Urografin (4 0 ± 0 6) and saline (2 7 ± 0 3) No significant difference between the latter three solutions (p > 0 02) was observed

At 10 per cent volume ratio The $t_{1/2}$ of Amipaque + mannitol (∞) was higher (p < 0 001) than those of Dimer X (7 3 ± 1 0) Isopaque Cerebral (10 2 ± 2 8) and Urografin (8 4 ± 1 1) Between the latter three $t_{1/2}$ no significant difference (p > 0 2) existed but they were all higher (p < 0 01) than that of 0 9 % saline (3 2 ± 0 4)

The $t_{1/2}$ of the metrizoate solutions were not significantly changed (p > 0 4) when the cation was changed from sodium to meglumine salt

Effect on red cell aggregation ($t_{1/2}$) of contrast media solutions hypertonic with blood

280–290 mg I/ml solutions At 0 5 per cent volume ratio No significant difference was found between the $t_{1/2}$ of the different contrast media or between the contrast media solutions and the 0 9 % saline solution (p > 0 02)

At 2 per cent volume ratio The $t_{1/2}$ of Amipaque (35 7 ± 11 0) was higher (p < 0 001) than those of Dimer X (3 7 ± 0 8) Isopaque Cerebral (5 4 ± 1 7) and Urografin (4 2 ± 0 6) no significant difference (p > 0 1) between the $t_{1/2}$ of the latter three solutions existed The $t_{1/2}$ of all the contrast media solutions were higher (p < 0 001) than that of 0 9 saline (2 4 ± 0 3)

At 5 per cent volume ratio The $t_{1/2}$ of Amipaque (∞) was higher (p < 0 001) than those of Dimer X (7 2 ± 2 3) Isopaque Cerebral (28 4 ± 4 5) and Urografin (10 5 ± 5 3) Also the $t_{1/2}$ of the Isopaque Cerebral solution was higher (p < 0 001) than those of Dimer X and Urografin Between the $t_{1/2}$ of the latter two no significant difference (p > 0.2) was observed The $t_{1/2}$ of all four contrast media were higher (p < 0 001) than that of 0 9 % saline (2 7 ± 0 3)

At 10 per cent volume ratio The $t_{1/2}$ of Amipaque (∞) Isopaque Cerebral (∞) and Urografin (∞) were all higher (p < 0 001) than that of Dimer X (10 0 ± 2 1) The $t_{1/2}$ of all four contrast media were higher (p < 0 001) than that of 0 9 % saline (3 2 ± 0 4)

370 mg I/ml solutions At 0 5 per cent volume ratio No significant difference between the $t_{1/2}$ of the different contrast media or between the contrast media solutions and that of 0 9 saline (p > 0 05) was observed

At 2 per cent volume ratio The $t_{1/2}$ of Amipaque (44 0 ± 14 0) was higher (p < 0 001)

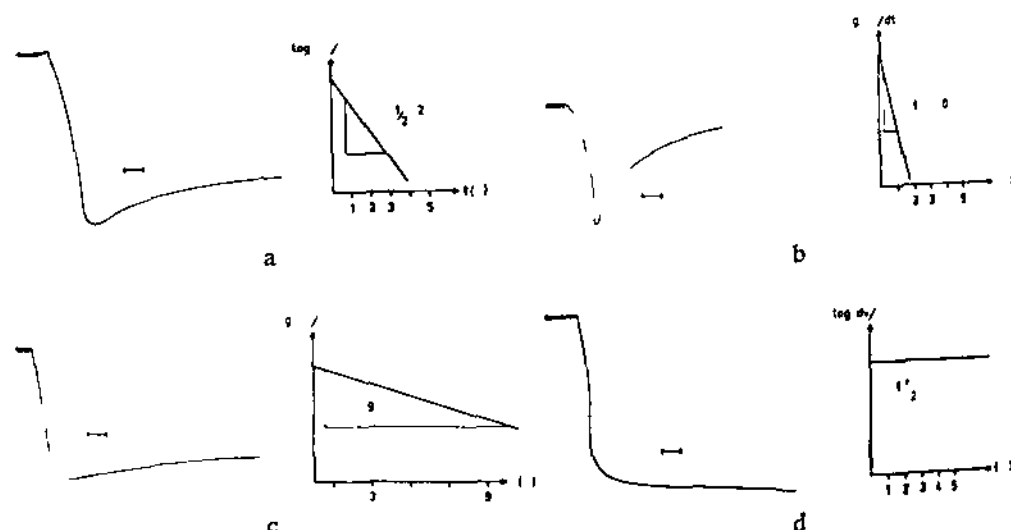


Fig 2 To the left a syllectogram and to the right the calculated $t_{1/2}$ a) Normal blood hematocrit 45 b) Dextran T250 (1 5 g) in 45 volume ratio to blood c) Dimer X 280 mg I/ml in 10 volume ratio to blood d) Amipaque 280 mg I/ml in 10 volume ratio to blood

than those of Isopaque Coronar (5 9 ± 0 6) and Urografin (4 5 ± 1 3) Between the t_1 of the latter two no significant difference ($p > 0\ 05$) existed The $t_{1/2}$ of the three contrast media were all higher ($p < 0\ 001$) than that of 0 9 % saline

At 5 per cent volume ratio The $t_{1/}$ of Amipaque (∞) was higher ($p < 0\ 001$) than those of Isopaque Coronar (44 0 ± 4 7) and Urografin (14 1 ± 9 0) Also the $t_{1\ 2}$ of Isopaque Coronar was higher ($p < 0\ 001$) than that of Urografin The $t_{1/}$ of all three contrast media were higher ($p < 0\ 001$) than that of 0 9 % saline

At 10 per cent volume ratio The $t_{1/2}$ of all three contrast media were the same (∞) and higher ($p < 0\ 001$) than that of 0 9 % saline

From the results obtained it is evident that both ionic and non ionic contrast media increase the $t_{1\ 2}$ (decrease red blood cell aggregation) with increasing volume ratio more than a corresponding dilution with physiologic saline does This finding was further confirmed by the microscopic and microphotographic examination in the rheoscope Four representative syllectograms and their calculated $t_{1\ 2}$ are shown in Fig 2 Figs 3 to 6 illustrate photographs corresponding to the syllectograms in Fig 2 at maximum shear rate (400 s^{-1}) at stop (0 s^{-1}) and 5 seconds after stop From these it is clear that normal blood cells were fully dispersed and axially migrated at 400 s^{-1} (Fig 3 a) but at stop became randomly distributed (Fig 3 b) and 5 seconds after stop had started to form aggregates (Fig 3 c) These aggregates increased in number and size when Dextran T250 (1 5 %) was added in 45 per cent volume ratio (Dextran/blood Fig 4) When iocarmate was added in 10 per cent volume ratio this aggregation was reduced (Fig 5) and was totally abolished when metrizamide was added in the same volume ratio (Fig 6) It is also evident that this desaggregating





Fig 3 Microphotogram of normal blood a) Shear rate 400 s^{-1} b) Stop (0 s^{-1}) c) 5 s after stop



a




b




c

Fig 4 Microphotogram of Dextran T250 (1 5 g%) in 45 volume ratio to blood a) Shear rate 400 s^{-1} b) Stop (s^{-1}) c) 5 s after stop



a



b



c

Fig 5 Microphotogram of Dimer X 280 mg I/ml in 10 volume ratio to blood a) Shear rate 400 s^{-1} b) Stop (0 s^{-1}) c) 5 s after stop

ability of contrast media is obtained with both hypertonic and isotonic (with blood) solutions of the different contrast media

Table 2 shows that the dilution of blood with 0 9 % saline at volume ratio (salin / blood) 0 5 2 and 5 per cent respectively did not significantly change the $t_{1/2}$ ($p > 0 01$) At 10 per cent volume ratio the $t_{1/2}$ of 0 9 % saline was higher ($p < 0 001$) than that of normal blood

When the blood was diluted with hypertonic saline (10 %) the $t_{1/2}$ was higher ($p < 0 001$) than that of physiologic saline at 2 5 and 10 per cent volume ratio

The $t_{1/2}$ of the high molecular Dextran solution (T250 1 5 %) was significantly lower (increased aggregation) than that of blood ($p < 0 001$) at 45 per cent volume ratio

Discussion

Evidently both ionic and non ionic contrast media decrease red cell aggregation in vitro This is in accordance with the recent findings by ASPELIN (1978) that red cells in contact with ionic and non ionic contrast media become crenated echinocytes or osmotically shrunken desiccocytes and that the rouleaux formation of red cells is reduced It was also shown by EHRLY & MULLER (1966) SCHMID SCHÖNBEIN & WELLS (1969) SCHMID SCHÖNBEIN et coll (1975) that when red cells become crenated this produces desaggregation of the cells The explanation for this is believed to be that in the formation of the rouleaux the surfaces of two adjacent red cells are parallel to each other and the cells themselves are able to deform and flatten in order to produce the binding surface required to overcome the electric repulsing forces of the erythrocytes The echinocyte or desiccocyte are believed to be unable to deform and flatten enough to produce this binding surface necessary to overcome the re pulsing forces (CHIEN 1973) It was also shown by ASPELIN that the contrast media which created most echinocytes (metrizoate and metrizamide) also produced more desaggregation than those that formed less echinocytes (iocarmate and diatrizoate)

The fact that contrast media decrease red cell aggregation appears to be in opposi tion to what most previous authors have found both in vivo and in vitro Thus, BERNSTEIN & EVANS (1960) BERNSTEIN et coll (1964) BJORK (1967) BROWN et coll (1968) CHAPLIN & CARLSSON (1961) JOHNSON & KNISELY (1962) KUTT et coll (1963) MARGOLIS et coll (1959) MEYER & READ (1964) POIESZ (1973) READ (1959) READ & MEYER (1959) SVOBODA & FIALA (1964) WIEDEMAN (1964) have demon strated that ionic contrast media increase red cell aggregation A few authors have not found any effect (BRÅNEMARK et coll 1969 DATTA & BLUMING 1973 MCINTOSH et coll 1967 STALLWORTH 1972) none of them has reported a desaggregating ability of contrast media A possible explanation of these controversial findings might be the different and sometimes inadequate methods that previously have been availabl for analysing the formation of red cell aggregates and that the causal relations be tween blood flow retardation and red cell aggregation might have been erroneously evaluated Thus LASSER et coll (1962) KUTT et coll (1963 1966) JOHNSON &




Fig 6 Microphotogram of Amipaque 280 mg I/ml in 10 volume ratio to blood a) Shear rate 400 s^{-} b) Stop (0 s^{-1}) c) 5 s after stop

KNISELY (1962) and MEYER & READ (1964) demonstrated in vitro that the red cells were clumped together when they were mixed with different contrast media but none of these authors reported having seen any clear red cell aggregates in the microscope CHAPLIN & CARLSSON (1961) found that red cells in contact with contrast media underwent rapid shrinkage and no immediate aggregation but after the mixture had stood undisturbed for several minutes an increasing number of clumps of red cells occurred They were however easily dispersed by shaking the test tube Aggregation was rarely seen by BERNSTEIN et coll (1964)

In the in vivo investigations also an increased cell aggregation was usually found but the methods used have often been inadequate for evaluating red cell aggregate formation

Thus BERNSTEIN et coll (1964) BJÖRK (1967) KUTT et coll (1963 1966) LINDGREN et coll (1964) and SOBIN et coll (1959) recorded the aggregation of red cells in the conjunctival vessels which is not a reliable method (ROBERTSSON et coll 1950 SCHMID-SCHÖNBEIN & WELLS 1969) It has thus been shown that the formation of red cell aggregates in the conjunctival vessels is highly dependent on the flow rate in the vessels and that merely a decrease in blood pressure can increase the cell aggregation in the conjunctival vessels Other in vivo investigations have been microscopy of the microvascular bed

The effect of contrast media on the pial mesenteric lung and leg vessels was recorded by READ et coll (1959 1964) and on mesenteric vessels by JOHNSON & KNISELY (1962) KUTT et coll (1963 1966) LARCAN et coll (1971) STALLWORTH et coll (1972) and BROWN et coll (1968) These reports have been controversial Most of the authors have reported an increased red cell aggregation but what they actually describe in most reports are such finding as slowing of blood flow precapillarily crenation of red cells and sometimes a sludging of blood and stasis with an increased red cell aggregate formation

DATTA & BLUMING (1973) in vitro and BRÅNEMARK et coll (1969) MCINTOSH et coll (1967) and STALLWORTH et coll (1972) in vivo found no increased red cell aggregation following contrast media exposure to blood

The finding that contrast media solutions desaggregate red cells in vitro also explains the finding that contrast media inhibit the sedimentation rate of erythrocytes. It was first postulated by FÅHREUS (1921) and later by THORSEN & HINT (1950) that substances which increase red cell aggregation also increase erythrocyte sedimentation rate according to the law of Stoke It was therefore surprising to both LINDGREN et coll (1964) and BERNSTEIN et coll (1964) that contrast media were the first substances that apparently decreased the erythrocyte sedimentation rate and still produced what was believed to be increased red cell aggregation The present finding that both metrizoate and metrizamide desaggregate red cells is also confirmed by the report of ALMEN (1973) who found that these substances decrease the erythrocyte sedimentation rate

The present results thus show that contrast media also follow the rules of Stoke s law between red cell aggregation and the erythrocyte sedimentation rate

The fact that contrast media per se desaggregate red cells also supports the finding that the protective action of low molecular weight dextran on contrast media toxicity must depend on other factors than the desaggregating effect of the dextran BERNSTEIN & EVANS (1960) and BERNSTEIN et coll (1961) consider the protective action of low molecular weight dextran on contrast media toxicity to be related to the ability of the dextran to reduce or prevent the increased red cell aggregation that was believed to be produced by the contrast media SESSION et coll (1962) also found this protective action of low molecular weight dextran on contrast media toxicity GARBER & READ (1962) demonstrated protective action against the pulmonary vascular effects of contrast media with low molecular weight dextran but achieved the same protective action with whole blood saline or even high molecular weight dextran Consequently they attributed this protective action to the effect of the induced hypervolemia Later these findings were confirmed by WIEDEMAN (1964) and JAMES et coll (1965) who found the beneficial effects of low molecular dextran to be related to its plasma volume expanding effect Thus READ et coll (1959) found an increased resistance to the blood flow through the pulmonary capillaries and an increase in pulmonary arterial pressure following injection of hypertonic solutions into the right heart They also observed in the microscope an increased red cell aggregation in the pulmonary vessels precapillarily and assumed that these aggregates were blocking the capillaries and causing the elevation in the pulmonary arterial pressure

Thus if contrast media desaggregate the red cells and do not increase red cell aggregation it cannot be red cell aggregates that first block the capillaries and increase the intravascular pressure It is evident that the red cells play an important role and READ et coll (1959) showed that the presence of red cells was necessary to obtain a slowing of blood flow and an increased capillary resistance in the lung When they perfused the lungs of dogs with highly hypertonic solutions without any red cells in the perfusate no pressure changes in the pulmonary artery occurred No signs of vasoconstriction that would explain the increased resistance were recorded (BROWN et coll 1968 JOHNSON & KNISELY 1962 KUTT et coll 1963 MARGOLIS et coll 1959 READ & MEYER 1959 STALLWORTH et coll 1972 WIEDEMAN 1963)

A possible explanation for the retardation of flow and the cause of the increased resistance to flow through the capillaries following contrast media injection may be that the individual red cell per se when rigidified might block the capillaries Following exposure to contrast media the red cells change from their normal disc shape into crenated cells (echinocytes) or highly osmotically shrunken cells (desiccocytes) (ASPELIN 1978 SCHIANTARELLI et coll 1973) At rheologic investigations these types of cells were found to be markedly less deformable than the normal discoid erythrocyte (ASPELIN 1978 BESSIS & MOHANDA 1975 SCHMID SCHONBEIN & WELLS 1969 SCHMID SCHÖNBEIN et coll 1973 WELLS & SCHMID-SCHONBEIN 1969)

It is also well known that the erythrocytes must bend and deform as they pass through the capillaries which at many points have a diameter less than the erythro

cyte itself (BRÅNEMARK & LINDSTRÖM 1963, FÅHREUS & LINDQVIST 1931) A decreased ability of the erythrocyte to deform might thus increase its resistance to pass through the capillaries which thus may explain the elevated precapillary pressure and the slowing of flow This retardation of flow per se then stimulates the formation of red cell aggregates which further decreases the flow and still more aggregates are formed etc This circle may thus explain the previous in vivo findings The cause of the retardation of flow has not been possible to establish the stasis of the red cells precapillarily has been observed and as a consequence of the flow retardation an increased red cell aggregation

This explanation of the increase in resistance to flow by the single red cells is in agreement with the findings of BROWN et coll (1968) They recorded the effect of ionic contrast media on the microcirculation of the small bowel in dogs by high speed cinemicrography and found that the red cells in contact with the contrast media became crenated and these altered red cells were unable to enter the capillaries and thus red cell flow in the capillaries almost ceased

The observation that after both the injection of hypertonic solutions or of different contrast media into the right side of the heart the elevation in pulmonary artery pressure increases with increasing osmolality of the injected solution may thus be explained by the fact that the red cells became more rigidified with increasing osmolality of the solution ALMEN et coll (1975) and ALMEN & ASPELIN (1975) showed that the low osmotic non ionic contrast medium metrizamide induced less elevation of the pulmonary arterial pressure than the high osmotic ionic contrast media iocarmate and metrizoate

However ASPELIN found that in low volume ratio (contrast media/blood) metrizamide transformed more erythrocytes into echinocytes than iocarmate On the other hand in high volume ratio iocarmate and metrizoate produced red cells that were markedly osmotically shrunken (desiccocytes) while at the same volume ratio metrizamide still produced echinocytes RAND & LACOMBE (1965) demonstrated that the blood osmolality in the pulmonary artery after cardioangiography on dogs is high and may even exceed 1 000 mosm and at this osmolality the red cells become highly shrunken desiccocytes These findings might indicate that the echinocytes produced by the non ionic metrizamide may produce less resistance to deformation than the desiccocytes produced by the ionic contrast media Further investigations on this subject are in progress

SUMMARY

The effect of solutions of the ionic contrast media diatrizoate iocarmate and metrizoate and the non ionic metrizamide on red cell aggregation in vitro was examined The aggregation was recorded by both microphotography and photometry in a counter rotating rheoscope chamber All the contrast media decreased the formation of red cell aggregates This desaggregating ability increased with both increasing volume ratio (contrast media/blood) and with increasing osmolality of the contrast media The desaggregating effect was

al o obtained with the contrast media solutions isotonic with blood The iocarmate and diatrizoate solutions induced less reduction in red cell aggregation than the metrizoate and metrizamide solutions

ZUSAMMENFASSUNG

Die Wirkung von Losungen der jonisierten Kontrastmittel Diatrizoat Iocarmat und Metrizoat und dem nicht jonisierten Metrizamid auf die Aggregation von roten Blutzellen wurde in vitro untersucht Die Aggregation wurde durch sowohl Mikrophotographie wie Photometrie in einer gegeneinander rotierenden Rheoskopkammer festgestellt Alle unter suchten Kontrastmittel verminderten die Bildung von roten Blutzellaggregaten Dieses Vermogen die Aggregation herabzusetzen stieg mit steigendem Volumenratio (Kontrast mittel/Blut) wie mit steigender Osmolalitat der Kontrastmittel Der herabsetzende Effekt wurde auch mit Kontrastmittellosungen die isotonisch mit dem Blut waren erzielt Die Iocarmat und Diatrizoatlosungen verursachten eine geringere Herabsetzung in der Aggre gation von roten Blutzellen als die Metrizoat und Metrizamidlosungen

RESUME

Les auteurs ont etudie l effet de solutions de moyen de contraste ioniques le diatrizoate l iocarmate et le metrizoate et de métrizamide non ionique sur l agregation in vitro des globules rouges L agregation a ète enregistree par microphotographie et par photométrie dans une chambre rheoscope compteur rotative Tous les moyens de contraste diminuent la formation d agregats de globules rouges Ce pouvoir désagrégatif augmente à la fois quand on augmente le rapport des volumes (moyen de contraste-sang) et quand on augmente l osmolalité des moyens de contraste L effet desagrégatif est aussi obtenu avec des solutions de moyens de contraste isotoniques au sang Les solutions iocarmate et de diatrizoate re duisent moins l agregation des globules rouges que les solutions de métrizoate et de metri zamide

REFERENCES

AGARWAL J BAILE E and PALMER W Reflex systemic hypotension due to hypertonic solutions in the pulmonary circulation J appl Physiol 27 (1969) 251

ALMEN T Contrast agent design J theoret Biol 24 (1969) 216

— Effects of metrizamide on the sedimentation rate of red blood cells Acta radiol (1973) Suppl No 335 p 229

— and ASPELIN P Cardiovascular effects of ionic monomeric and ionic dimeric and non ionic contrast media. Effects in animals on myocardial contractile force pulmonary and aortic blood pressure and aortic endothelium Invest Radiol 10 (1975) 557

— — and LEVIN B Effect of ionic and non ionic contrast media on aortic and pulmonary arterial pressure An angiographic study in rabbits Invest Radiol 10 (1975) 519

ASPELIN P Effects of ionic and non ionic contrast media on morphology of human erythrocytes Acta radiol Diagnosis 19 (1978) 675

BERNSTEIN E and EVANS R Low molecular weight dextran J Amer med Ass 174 (1960) 161

— — and SALTZMAN G F Physico-chemical properties of blood following exposure to methylglucamine iodipamide and other contrast media Acta radiol Diagnosis 2 (1964) 401

— — BLUM J and AVANT R Further experimental and early clinical ob ervations concerning the protective action of low molecular weight upon intravenous Hypaque toxicity Radiology 76 (1961) 260
BESSIS M and MOHANDA N Deformability of normal shape altered and pathological red cells Blood cells 1 (1975) 315
— WEED R J and LEBLOND P F Red cell shape Physiology pathology ultrastructure Springer Verlag New York Heidelberg Berlin 1973
BINET L et BURSTEIN M Sur l action vasoconstrictrice du serum sale hypertonique au niveau de la petite circulation C R Soc Biol (Paris) 145 (1951) 1766
— — Sur les effets cardiovasculaire du serum salé hypertonique C R Soc Biol (Paris) 147 (1953) 1997
BJORK L Effect of angiocardiography on erythrocyte Aggregation in the conjunctival vessels Acta radiol Diagnosis 6 (1967) 459
BRANEMARK P I and LINDSTROM J Studies in the function of nutritive capillaries in the connective tissue in rabbits ear chamber J Anat (Lond) 97 (1963) 323
— — Shape of circulating blood corpuscles Biorheology 1 (1963) 139
— JACOBSSON B and SORENSEN S E Microvascular effects of topically applied contrast media Acta radiol Diagnosis 8 (1969) 547
BRINKMAN R ZIJLSTRA W G and JANSONIUS J Quantitative evaluation of the rate of roleaux formation of erythrocytes by measuring light reflexion (syllectometry) Proc kon ned Akad Wet Ser 6 66 (1963) 237
BROWN R YOUMANS R LIVANEC G DERRICK J BOND T and GUEST M Cinemicrographic observations of the effects of contrast media on the microcirculation Vasc Surg 2 (1968) 109
CHAPLIN H and CARLSSON E Changes in human red blood cells during in vitro exposure to several roentgenologic contrast media Amer J Roentgenol 86 (1961) 1127
CHIEN S Electrochemical and ultrastructural aspects of red cell aggregation Bibl anat 11 (1973) 244
DATTA S and BLUMING A Red cell clumping after intravenous contrast medium New Engl J Med 289 (1973) 1253
EHRLY A und MULLER H Aggregation und Desaggregation von Erythrocyten Acta haemat (Basel) 36 (1966) 323
ELIAKIM M ROSENBERG S and BRAUN K Effect of hypertonic saline on the pulmonary and systemic pressures Circulat Res 6 (1958) 357
— STERN S and NATHAN H Site of action of hypertonic saline in the pulmonary circulation Circulat Res 9 (1961) 327
FÅHREUS R Suspension stability of blood Acta med scand 55 (1921) 1
— and LINDQVIST T The viscosity of the blood in narrow capillary tubes Amer J Physiol 96 (1931) 562
FRIESINGER G SCHAFFER J CRILEY M GAERTNER R and ROSS R Hemodynamic consequences of the injection of radiopaque material Circulation 31 (1965) 730
GARBER G and READ R Protective effect of hypervolemia in cardioangiography J Amer med Ass 180 (1962) 376
GOLDBERG S LINDE L and GYEPES M Hemodynamic influence of sodium iothalamate on controlled pulmonary circulation Invest Radiol 3 (1968) 267
GOLDSMITH H and MASON S Some model experiments in heamodynamics II Bibl anat (Basel) 7 (1965) 353
HOLTERMANN H Metrizamide Introduction Acta radiol (1973) Suppl No 335 p 1
JAMES L MATOOLF J DAVIS H and HODGSON P Morphologic responses to renal arterial perfusion with Hypaque Amer J Roentgenol 93 (1965) 916

JOHNSON J and KNISELY M *Intravascular agglutination of the flowing blood following the injection of radiopaque contrast media* Neurology 12 (1962) 560
KLEINERMANN L GHITESCU T BUSU I INESCU N *und* LUPU A Der Einfluss der Ausdehnung des linken Vorhofes auf den pulmonalen Arteriendruck Cardiologia 31 (1957) 475
KLOSE H VOLGER E BRECHTELSBAUER H HEINRICH L and SCHMID-SCHÖNBEIN H Microrheology and light transmission of blood I The photometric effects of red cell aggregation and red cell orientation *Pflugers Arch* ges Physiol 333 (1972) 126
KRAMER K Ein Verfahren zur fortlaufenden Messung des Sauerstoffgehaltes im stromenden Blut an uneroffneten Gefassen Z Biol 96 (1935) 61
KUTT L MILHORAT T and McDOWELL F The effect of iodinized contrast media upon blood proteins electrolytes and red cells Neurology 13 (1963) 492
— VEREBELY K BANG N STREULI F and McDOWELL F Possible mechanisms of complications of angiography Acta radiol Diagnosis 5 (1966) 276
LARCAN A STOLTZ M and STOLTZ J F Effects of various iodic substances on the mesenteric circulation of the rat Microvasc Res 3 (1971) 207
LASSER E FARR R *FUJIMAGARI* T *and* TRIPP W The significance of proteinbinding of contrast media in roentgen diagnosis Amer J Roentgenol 87 (1962) 338
LINDGREN P LOFSTROM B and SALTZMAN G F *Intravascular erythrocyte aggregation* after intravenous injection of contrast media Acta radiol Diagnosis 2 (1964) 334
MARGOLIS G GRIFFIN A T KENAN P D TINALL G T RIGGINS R and FORT L Contrast medium injury to the spinal cord The role of altered circulatory dynamics J Neurosurg 16 (1959) 390
McINTOSH H HURST V THOMPSON H MORRIS J and WHALEN R The hemodynamic effects of the injection of contrast medium (Isopaque) Angiology 18 (1967) 306
MEYER M *and* READ R C *Red cell aggregation from concentrated saline and angiographic media* Radiology 82 (1964) 630
POIESZ B J *Clumping of* red cells after intravenous contrast medium New Engl J Med 289 (1973) 868
RAND P and LACOMBE E Effects of angiocardiographic injections on blood viscosity Radiology 85 (1965) 1022
READ R Cause of death in angiocardiography J thorac cardiovasc Surg 38 (1949) 685
— and MEYER M The role of red cell *agglutination in arteriographic complications* Surg Forum 10 (1959) 472
— VICK J *and* MEYER M *Influence* of perfusate characteristics on the pulmonary vascular effects of hypertonic solutions Fed Proc 18 (1959) 124
— — — *Influence* of dextran infusion on the pulmonary hypertensive effect of concentrated saline Circulat Res 9 (1961) 1240
— JOHNSON J VICK J and MEYER J Vascular effects of hypertonic solutions Circulat Res 8 (1960) 538
ROBERTSSON S WOLF S and WOLFF H G Blood sludge phenomen in human subjects Amer J med Sci 29 (1950) 534
SCHIANTARELLI P PERONI F TIRONE P and ROSATI G Effects of iodinated contrast media on erythrocytes I *Effects of canine erythrocytes* on morphology Invest Radiol 8 (1973) 199
SCHMID-SCHONBEIN H and WELLS R Quantification of the dynamics of red cell aggregation Bibl anat 10 (1969) 45
— — *Rheological* consequences of osmotic red cell crenation Arch ges Physiol 307 (1969) 59

— — Rheological properties of human erythrocytes and their influence upon the anomalous viscosity of blood Ergebn Physiol 63 (1971) 146
— Weiss J and Ludwig H A simple method for measuring red cell deformability in models of the microcirculation Blut 24 (1973) 369
— Wells R and Schildkraut R Microscopy and viscometry of blood flowing under uniform shear rate (rheoscopy) J appl Physiol 26 (1969) 674
— Volger E and Klose H J Microrheology and light transmission of blood II The photometric quantification of red cell aggregate formation and dispersion in flow Pflugers Arch ges Physiol 333 (1972) 140
— — — and Weiss J Blood microrheology and the development of stasis in the microvasculature after injury Advanc exp Med Biol 33 (1972) 65
— Kline K A Heinich L Volger E and Fischer T Microrheology and light transmission of blood III The velocity of red cell aggregate formation Pflugers Arch 354 (1975) 299
Session R Killen D and Foster J Low molecular weight dextran as a protective agent against the toxic effects of Urokon Amer Surg 28 (1962) 455
Snider G Primary pulmonary hypertension A fatality during pulmonary angiography Chest 64 (1973) 628
Sobin S Frasher W G Jacobsson G and VanEeckhoven F A Nature of adverse reactions to radiopaque agents J Amer med Ass 170 (1959) 1546
Stallworth M Rodriguez O and Barrington B Microcirculatory responses to commonly used therapeutic drugs Amer Surg 38 (1972) 145
Svoboda M und Hala J Der Einfluss jodierter wasserloslicher Rontgenkontrastmittel auf die roten Blutkorperchen im Verlauf der Kontrastuntersuchungen Radiol diagn (Berlin) 5 (1964) 207
— — Morphologische Veranderung der roten Blutkorperchen nach verschiedenen wasserloslichen jodhaltigen Rontgenkontrastmitteln Radiologe 4 (1964) 404
Taylor M and Robertsson J S The flow of blood in narrow tubes I A capillary microphotometer an apparatus for measuring the optical density of flowing blood Aust J exp Biol 32 (1954) 721
Thorsen G and Hint H Aggregation sedimentation and intravascular sludging of erythrocytes Acta chir scand (1950) Suppl No 154
Watson H Severe pulmonary hypertensive episodes following angiocardiography with sodium metrizoate Lancet 2 (1964) 732
Wells R and Schmid-Schönbein H Red cell deformation and fluidity of concentrated cell suspensions J appl Physiol 27 (1969) 213
Wiedeman M Influence of low molecular weight dextran on vascular and intravascular responses to contrast media Amer J Roentgenol 92 (1964) 682
— Vascular and intravascular responses to various contrast media Angiology 14 (1963) 107

Table 1

Definition of the four groups of rats regarding injection routes and doses of 1 2-dimethyl hyd a ine 2HCl (DMH) and N methyl N nitro-N nitroso-gi anid ne (MNNG)

	Groups			
	I	II	III	IV
Age of the rat at first injection	2–3 months	3 months	3 months	2 5 12 5 months
No of rats	15	108	38	28
Sex ratio	Females 15	Females Males 98 10	Males 38	Females Males 9 19
Type of injection	0 2 ml = 20 mg DMH 3 times weekly for 11 weeks Intra peritoneally	0 15–0 25 ml = 15–25 mg DMH once a week for 15 weeks Sub-cutaneously	0 5 ml 0 25 MNNG once a week for 11–16 weeks Intra rectally	15–45 mg/kg/ week DMH for 4–12 weeks Subcutaneously
Total doses	660 mg/kg	225–375 mg/kg	41 60 mg/kg	180 mg kg

tested by DRUCKREY (1970) Intraperitoneal or subcutaneous injections of this drug induce a high yield of malignancies in the intestinal tract Another carcinogen nitroguanidine is effective by direct contact after intrarectal infusion (NARISAWA et coll 1971)

The induction time distribution and appearance of colonic tumours of rats given the two carcinogens mentioned are now reported

Material and Methods

The total material consisted of 189 rats 161 adult inbred Wistar/Furth rats obtained by continuous single line brother to siter mating and 28 adult rats of race BD (DRUCKREY et coll 1967) of both sexes (67 males and 122 females) All animals were fed on a standard pellet diet and water ad libitum

All the rats were given either 1 2 dimethylhydrazine (DMH) or N methyl N nitro N nitrosoguanidine (MNNG) The carcinogens were given intraperitoneally or sub cutaneously in the DMH series and intrarectally in the MNNG series The adminis tration technique and the doses given are presented in Table 1 Based on the different routes and doses of injection the rats were divided into four groups The mean weight of the rats in groups I to III was 200 g at the first injection The rats in group IV were imported from Houston Texas U S A at the age of about one year and their weights at the time of the first injection of DMH were not known Radiography was performed in these animals about one year after the first injec

FROM THE RESEARCH LABORATORIES DEPARTMENTS OF DIAGNOSTIC RADIOLOGY AND PATHOLOGY MALMÖ ALLMANNA SJUKHUS S-214 01 MALMO SWEDEN

EXPERIMENTAL COLONIC TUMOURS IN THE RAT

III Induction time distribution and appearance of induced tumours

C G LINDSTRÖM J E ROSENGREN and O EKBERG

During the last 20 years much interest has been focused on the induction of colon carcinomas in experimental animals by administration of different carcinogens (KING & VARASDI 1959, DRUCKREY et coll 1967 SCHOENTAL & BENSTED 1968 DRUCKREY 1970 NARISAWA et coll 1971 SPJUT & NOALL 1971 WARD 1974) Appropriate animal models to induce colon carcinomas with different carcinogens are of value for elucidating radiographic pathologic immunologic and therapeutic problems The time necessary to produce colon carcinomas has however been estimated only by necropsy In a previous report a simple and accurate technique for double contrast examination of the colon was described (Part I ROSENGREN 1978) This technique facilitates early in vivo diagnosis of adenomas and carcinomas in the colon of the rat and detailed information on the induction time of these tumours is obtained (ROSENGREN & LINDSTROM 1978) Tumours of the intestines can be induced by several carcinogens of various types and by different routes of administration

The carcinogens may act directly at the point of application or may require biochemical activation and be converted into an ultimate carcinogen (WEISBURGER 1973) One of the most effective carcinogens in the colon appears to be the plant product cycasin and its synthetic analogue dimethyl hydrazine an alkyl hydrazine

Supported by grants from the University of Lund Faculty of Medicine (No 59442900-3) the John and Augusta Persson Foundation and the Swedish Cancer Society (No 795 B74-03XA)
Submitted for publication 10 March 1977

RESUME

Une angiographie du pied a ete faite chez 32 diabétiques avec et sans injection intra artérielle de tolazoline (Priscoline) La qualite angiographique est améliorée avec la tolazoline se traduisant par un debit augmente avec une acceleration du temps de transit arterio-veineux une plus grande frequence d injection arterielle complete par le moyen de contraste dans des regions cliniquement importantes et la mise en évidence de segments arteriels considérablement plus longs dans des regions de mesure delimitees

REFERENCES

CHRISTENSEN N J Muscle blood flow measured by Xenon[133] and vascular calcifications in diabetics Acta med scand 183 (1968) 449

ERIKSON U Peripheral arteriography during bradykinin induced vasodilatation Acta radiol Diagnosis 3 (1965) 193

— Effect of local intraarterial administration of bradykinin and hydergine in obstructive arterial disease Acta radiol Diagnosis 10 (1970) 449

FERRIER T M Comparative study of arterial disease in amputated lower limbs from diabetics and non diabetics (with special reference to feet arteries) Med J Aust 1 (1967) 5

HISHIDA Y Peripheral arteriography using reactive hyperemia Jap Circulat J 27 (1963) 349

JACOBS J B and HANAFEE W N The use of priscoline in peripheral arteriography Radiology 88 (1967) 957

KAHN P C and CALLOW A D Selective vasodilatation as an aid to angiography Amer J Roentgenol 94 (1965) 213

NEUBAUER B A quantitative study of peripheral arterial calcification and glucose tolerance in elderly diabetics and non diabetics Diabetologia 7 (1971) 409

— Tilted and non tilted postischaemic exercise peak blood flow in the legs of long term diabetic and normal subjects Diabetologia 15 (1978) 9

SGALITZER M Unterscheidung funktioneller und organischer Erkrankungen der Extremitatenarterien durch die Rontgenuntersuchung Das Doppelinjektionsverfahren Fortschr Rontgenstr 56 (1937) 387

TAMISIER J N HOEFFEL J C and ROYER J R Arteriography of the lower limbs with papaverine vasodilators J belge Radiol 56 (1973) 121

WEGELIUS U Angiography of the hand Clinical and postmortem investigations Acta radiol (1972) Suppl No 315

the medium reached the first metatarsal artery and the two distal measuring points in about a quarter of the time recorded without the drug (Fig 2)

The arteriovenous transit time in the first toe assessable in only about half of the cases in the non tolazoline series decreased from a mean 9 7 s to 3 9 s through the use of tolazoline

Discussion

Injection of tolazoline before a foot angiography leads to a considerable improvement in the quality

The major gain is an opening up of many large and above all small foot arteries not demonstrated without the use of the drug (Fig 1) Furthermore there is a substantial increase in the visible length of other arteries as well as a more striking effect in the tiny arteries Thus the tolazoline technique almost invariably provides an adequate image of the most peripheral part of the vessels the digital arteries and thereby the prerequisite for the diagnosis of occlusion in these tiny arteries

The tolazoline series were always performed after the non tolazoline series because the duration of the drug effect on the vascular wall is unknown Therefore an effect from the contrast medium itself must be taken into account However previous investigations have indicated that the effect of contrast medium on the arteries is a minor one disappearing after about 15 min (WEGELIUS 1972) In the present investigation the interval between the non tolazoline and the tolazoline series was more than 15 min In a few experiments two series of injections of contrast medium preceded the tolazoline series and only a very small effect or none at all from the first injection on the flow rate of the second contrast bolus was observed

The effect of tolazoline now demonstrated in the foot is similar to the improvement of angiographic qualities obtained by plexus anaesthesia in hand angiography (WEGELIUS)

SUMMARY

Foot angiography was performed in 32 diabetic patients with and without intraarterial injection of tolazoline (Priscoline) The angiographic quality was improved with tolazoline manifested as an increased flow rate with acceleration of the arteriovenous transit time a higher incidence of complete arterial filling with contrast medium in clinically important regions and considerably longer arterial segments demonstrated within defined regions of measurement

ZUSAMMENFASSUNG

Fussangiographie wurde bei 32 diabetischen Patienten mit und ohne intraarterielle Injektion von Tolazoline (Priscoline) vorgenommen Die angiographische Qualitat wurde durch Tolazoline verbessert, nachweisbar an einer gesteigerten Durchblutung mit einer Steigerung der arteriovenosen Durchflusszeit einem hohen Vorkommen von vollstandiger arterieller Fullung mit Kontrastmittel in klinisch bedeutungsvollen Abschnitten und wesentlich langeren arteriellen Segmenten nachgewiesen innerhalb bestimmer Regionen der Messung

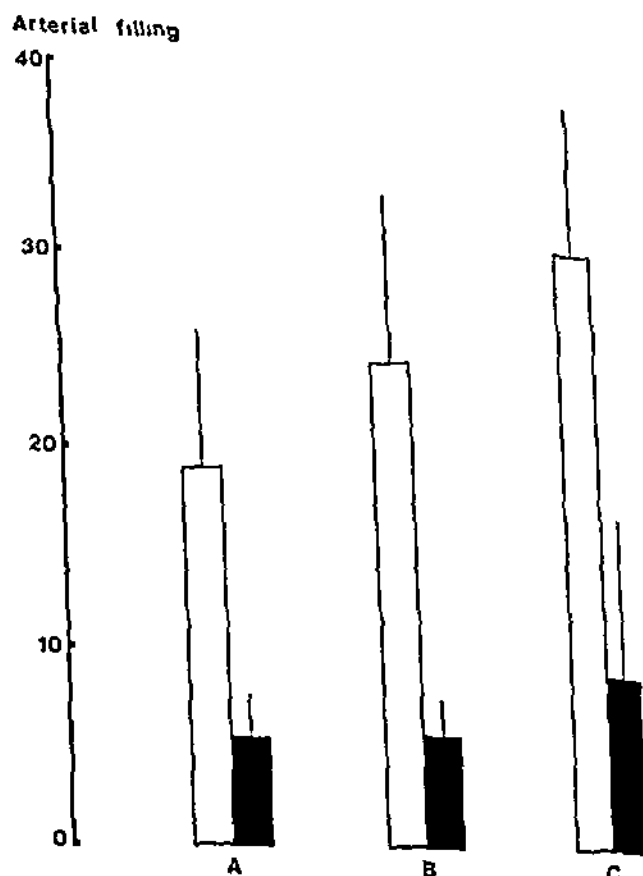


Fig. 2 Effect of tolazoline on the linear flow rate of contrast medium at three measuring points of the first interdigital space A The metatarso-tarsal joint B The proximal joint of the first toe C The distal joint of the first toe The vertical bars indicate SD Ordinate Time in s. □ without tolazoline ■ with tolazoline

illustrate the effect obtained in the remaining patients Most of the lines ascend to meet at the top at right indicating that the arterial segments were demonstrated in their entire length after the tolazoline injection The posterior tibial artery was entirely demonstrated in the measuring region in 91 per cent of the cases with tolazoline against 59 per cent without the drug the dorsal foot artery in 84 per cent against 63 per cent and the lateral plantar artery in 84 per cent against 31 per cent with and without tolazoline respectively A few horizontal lines indicate that tolazoline had no effect however in all these cases an occlusion was present. Some lines do not ascend to the top at right indicating that the arteries are demonstrated to a greater extent after the use of tolazoline although not completely so In almost all these cases a local explanation could be found i e the artery was narrow and irregular or an anatomic variation made a bend of the artery fall outside the measuring region In the remaining cases the proximal feeding artery was severely diseased with the exception of one of the dorsal foot arteries one of the posterior tibial arteries and four digital arteries of the first toe

The linear flow rate of the contrast medium increased considerably after tolazoline




Fig. 1 Effect of tolazoline on the demonstrated length of the dorsal foot artery (DP) the posterior tibial artery (TP) the lateral plantar artery (LP) the first metatarsal artery (FM) and the digital artery of the first toe (FT) For each of these arteries the non tolazoline values are shown to the left and the tolazoline values to the right in percentage of the length of the measuring region Thin lines connect the non tolazoline and tolazoline values of each individual case The horizontal thick lines at the top of the columns illustrate the cases (number inserted) in which the arteries were fully demonstrated in both series The thick corresponding lines and figures at the bottom illustrate the number of arteries remaining undemonstrated even after injection of tolazoline

Within the measuring region of 60 mm the demonstrated length of the posterior tibial artery increased by 12 9 mm ± 3 6 (mean difference ± SEM) (2p < 0 001) through the use of tolazoline For the dorsal foot artery the corresponding increase was 6 ? ± 2 1 (2p < 0 006) over 40 mm for the lateral plantar artery 8 1 ± 2 0 (2p 0 001) over 30 mm for the first metatarsal artery 10 3 ± 2 2 (2p < 0 001) and for the digital artery of the first toe 13 3 ± 2 2 (2p < 0 001) the last two also over a measuring length of 30 mm

Fully demonstrated arterial segments i e arteries demonstrated in the entire length contained within the individual measuring region, were observed much more frequently after the use of tolazoline

Fig 1 illustrates the effect of tolazoline in the individual cases A number of arteries (top of columns) were demonstrated in the entire length of the measuring region already before the use of tolazoline Some arteries (bottom of columns) were not filled at all with contrast medium even after injection of tolazoline in all but 2 of these cases the proximal feeding arteries were occluded The thin oblique lines

In all patients two angiographic series of the right foot were carried out with an interval of 20 min The second series was performed after injection of tolazoline (Priscoline) with the foot in exactly the same position as during the first series All patients were given 75 mg pethidine intramuscularly 30 min before the examination By percutaneous puncture of the femoral artery a polyethylene catheter (OD 2 1 mm) with six side holes was placed with its tip in the external iliac artery just distal to the branching off of the internal iliac artery under TV fluoroscopy Twenty ml of contrast medium (Isopaque Cerebral Nyegaard & Co) were automatically injected at a rate of 5 ml/s the slow injection rate was chosen to avoid pain

Alternating a p and lateral films were exposed with the aid of two coupled generators and automatic film changers using an exposure rate of 1 film/2 s on each tube The film series were timed to start before the arterial phase and to stop with the fading off of the venous phase

The first series of 36 films was started 10 s after the beginning of the injection of contrast medium The tolazoline series 20 min later comprised 20 films and was started 2 s after the beginning of injection The procedure including injection and exposures was recorded by a Mingograf

Before the second angiographic series tolazoline 40 mg in 25 ml 0 9 per cent NaCl was injected manually in the catheter in the course of one minute After an interval of one minute the injection of contrast medium was started

Quantitative evaluation was standardized by determining the lengths in millimeters of contrast filled arterial segments in pre selected measuring regions defined by the distance to easily identified osseous landmarks For the posterior tibial artery the measuring region was 60 mm in length with the distal borderline at the level of the talocrural joint The dorsal foot artery was measured over a length of 40 mm from the talocrural joint distally The lateral plantar artery was measured over a length of 30 mm with the upper borderline placed 10 mm proximal to the calcaneo cuboid joint The first metatarsal artery was measured over 30 mm between lines placed 15 and 45 mm proximal to the metatarso-phalangeal joint of the first toe The digital artery of the first toe was measured at the lateral side of the toe from the metatarso-phalangeal joint 30 mm distally

The flow rate was determined as the time from the start of the injection of contrast medium to its appearance at three points of the first interdigital space the first metatarso-tarsal joint and the proximal and distal joints of the first toe

The arteriovenous transit time was defined as the interval from the start of filling of the first metatarsal artery to the start of filling of the corresponding veins

Student s t test for paired comparisons was used for the statistical analysis

Results

Intraarterial injection of tolazoline one minute before foot angiography opened up many arteries and very considerably increased the demonstrated length of others (Fig 1)

FROM THE DEPARTMENT OF DIAGNOSTIC RADIOLOGY (DIRECTOR B MADSEN) AND THE SECOND UNIVERSITY CLINIC OF INTERNAL MEDICINE (DIRECTOR K LUNDBÆK) KOMMUNEHOSPITALET DK 8000 AARHUS DENMARK

INTRAARTERIAL TOLAZOLINE IN ANGIOGRAPHY OF THE FOOT

BENT NEUBAUER

Diabetic macroangiopathy involves in particular the leg and foot arteries In a previous investigation it was shown that calcific deposits in the media of large leg arteries are a characteristic feature in long term diabetic patients and that the extent is related to the degree of carbohydrate intolerance in elderly controls (NEUBAUER 1971) It is generally believed that such calcific deposits do not affect the arterial lumen but FERRIER (1967) demonstrated that calcification of the media is accompanied by thickening of the intima Later it was also demonstrated (CHRISTENSEN 1968 NEUBAUER 1978) that the maximum blood flow in the legs of long term diabetics is reduced and this reduction is more advanced in patients with media calcification

At angiography of peripheral arteries spasm may prevent accurate evaluation of the abnormalities of the arterial wall it may even conceal the presence of an arterial occlusion

Selective vasodilatation by intraarterial administration of drugs is a well established procedure (SGALITZER 1937 HISHIDA 1963 ERIKSON 1965 1970 KAHN et coll 1965 JACOBS & HANAFEE 1967 TAMISIER et coll 1973) No quantitative estimation of the effect seems to have been published and the tiny foot arteries have scarcely been evaluated

Material and Methods

The material consisted of 32 diabetics 23 men and 9 women with a mean age of 38 5 years (± 11 3 SD) The mean duration of the disease was 19 9 years (± 10 1 SD)

Submitted for publication 1 June 1977

HOLLENBERG N K EPSTEIN M ROSEN S M BASCH R J OKEN D E and MERRILL J P Acute oliguric renal failure in man Evidence for preferential renal cortical ischemia. Medicine 47 (1968) 455

— ADAMS D F OKEN D E ABRAMS H L and MERRILL J P Acute renal failute due to nephrotoxins renal hemodynamic and angiographic studies in man New Engl J Med. 282 (1970) 1329

JONSSON K LUNDERQUIST A PETTERSSON H and SIGSTEDT B Subintimal injection of contrast medium as a complication of selective abdominal angiography Acta radiol Diagnosis 18 (1977) 55

KELLY K M CRAVEN D JORGENS J and BARENFUS M Experimental renal artery trombo-embolism Invest Radiol 11 (1976) 88

KUPIC E A and ABRAMS H L Renal vascular alterations induced by haemorrhagic hypotension Invest Radiol 3 (1968) 345

LANG E K Arteriography in the assessment of renal trauma The impact of arteriographic diagnosis on presentation of renal function and parenchyma J Trauma 15 (1975) 553

LYRDAL F OLIN T and SILSETH CH Late effects on the kidney of selective infusion of adrenalin into the renal artery Scand J Urol Nephrol 8 (1974) 213

MENA E BOOKSTEIN J J and GIKAS P W Angiographic diagnosis of renal parenchymal disease Radiology 108 (1973) 523

OLIN T Studies in angiographic technique Thesis Lund 1963

SIEGELMAN S S and GOLDMAN A G The Trueta phenomenon Radiology 90 (1968) 1084

TADAVARTHY S M CASTANEDA W and AMPLATZ K Redistribution of renal blood flow caused by contrast media Radiology 122 (1977) 343

TRUETA J BARCLAY A E DANIEL P M FRANKLIN K J and PRICHARD M M L Studies of the renal circulation Blackwell Scientific publications Oxford 1947

SUMMARY

Six cases of spasm of the cortical arteries with redistribution of blood flow to the cortico-medullary glomeruli as a complication to nephroangiography are reported The etiology and the underlying anatomy and physiology are reviewed Advice is given to avoid the complication.

ZUSAMMENFASSUNG

Sechs Falle von Spasmus der Arteriae corticales mit Redistribution des Blutstroms zu den cortico-medullaren Glomeruli als eine Komplikation der Nephroangiographie werden beschrieben Die Ursache und die zugrundeliegende Anatomie und Physiologie werden diskutiert Anweisungen werden gegeben um diese Komplikation zu vermeiden

RESUME

Les auteurs presentent six cas de spasme des arteres corticales avec redistribution du debit sanguin dans les glomerules cortico medullaires compliquant une nephroangiographie Ils examinent l etiologie et l anatomie et la physiologie intervenant dans cette complication Ils donnent des conseils pour eviter cette complication

REFERENCES

ABRAMS H L The response of neoplastic renal vessels to epinephrine in man Radiology 82 (1964) 217

BLOCK M A WAKIM K G and MANN F C Certain features of the vascular beds of the corticomedullary and medullary regions of the kidney Arch Path 53 (1952) 437

CASTELLINO R A Renal carcinoma demonstrated by postepinephrine arteriography following normal selective arteriograms Radiology 97 (1970) 607

CURRIERE S THORBURN G D O MARCHOE C C C and BARGER A C Intrarenal distribution of blood flow in dogs during hemorrhagic hypotension Circulat Res 19 (1966) 167

DANIEL P M PEABODY C N and PRICHARD M M L Cortical ischemia of the kidney with maintained blood flow through the medulla Quart J exp Physiol 37 (1952) 11

EDSMAN G Angionephrography and suprarenal angiography A roentgenological study of the normal kidney expansive renal and suprarenal lesions and renal aneurysms Acta radiol (1957) Suppl No 155

EKELUND L GOTHLIN J and LUNDERQUIST A Diagnostic improvement with angiotensin in renal angiography Radiology 105 (1972) 33

— KAUDE J and LINDHOLM T Angiography in glomerular disease of the kidney A correlation with clinical findings and the stage of the disease Amer J Roentgenol 119 (1973) 739

ELKIN M and MENG C H Angiographic study of the effect of vasopressors—epinephrine and levarterenol—on renal vascularity Amer J Roentgenol 93 (1965) 904

— — The effects of angiotensin on renal vascularity in dogs Amer J Roentgenol 98 (1966) 9?7

GOODWIN W E SLOAN R D and SCOTT W W The Trueta renal vascular shunt J Urol 61 (1949) 1010

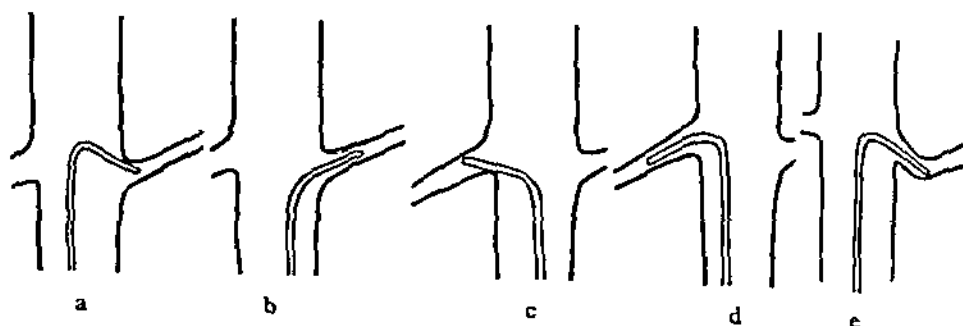


Fig. 4 a) Improper catheter position in the left renal artery which is cranially directed b) Correct catheter position with the axis of the tip well aligned to the course of the artery c) Improper catheter position in the right renal artery which is directed caudally d) Correct position e) Improper catheter position when the renal artery has an angled course The tip of the catheter is positioned too deep into the artery

Arteriovenous shunting does not occur neither in glomerulonephritis (MENA et coll 1973) nor when vasoconstrictive agents are used (ELKIN & MENG) The reason for this difference is not known perhaps the constriction of the cortical arteries occurs at different levels Thus there still remains some uncertainty considering the physiologic basis for the reaction

The spasm of the cortical arteries was induced in all instances by malpositioning of the catheter It is important to be familiar with the cause since exactly the same position of the catheter in the renal artery may cause subintimal injection of the contrast medium This occurs in about one per cent of all nephroangiographies and involves a significant risk of permanent damage to the kidney (JONSSON et coll 1977) Although the subcortical redistribution is reversible only its cause is removed it cannot be excluded that some permanent damage to the kidney may be caused by a microembolisation Clinical indication of injury to the kidneys in the present patients did not occur Repeat angiography was not performed The subcortical redistribution irregular appearance of the cortex and the poor definition of the corticomedullary margin may be confused with the findings in chronic glomerulonephritis However in the latter disease the redistribution is caused by permanent destruction of cortical glomeruli (EKELUND et coll 1973 MENA et coll)

The complete avoidance of this type of complication is probably not possible but the risk should be much reduced if care is taken to align the bend of the catheter according to the course of the renal arteries as delineated by the preceding aortography (Fig 4 a–d) Even if the tip of the catheter does not directly irritate the intima, the jet of contrast medium may induce the reaction (OLIN 1963) It is also important not to make the bend too long or to let it pass too far into the renal artery (Fig 4 e) This is important since although it may be apparent already at test injection that the catheter is malpositioned the injury of the renal artery wall may already have occurred

cortical glomeruli and the juxtamedullary The juxtamedullary glomeruli are developed earlier and are of more importance in fetal and neonatal life The 2 types of glomeruli differ as to their efferent arterioles the cortical glomeruli have small efferent arterioles emptying into cortical capillaries only while the juxtamedullary glomeruli have long efferent arterioles forming loops deep into the medulla the vasa recta which directly anastomose with the veins During normal conditions renal blood flow passes mainly through cortical glomeruli the perfusion of the juxtamedullary glomeruli being much less TRUETA et coll (1947) demonstrated in the rabbit that various stimuli e g induction of spasm in peripheral arteries as well as direct electric stimulation of the sciatic nerve or the nerves of the renal pedicle may induce cortical ischemia due to contraction of the cortical arteries with redistribution of blood flow to the juxtamedullary glomeruli and the vasa recta Early venous filling was also characteristic of the reaction

It is also possible to induce spasm of cortical arteries by other stimuli such as clamping of the renal artery and injection of vasoconstrictors e g angiotensin epinephrine norepinephrine protamine and vasopressin (BLOCK et coll 1952 ELKIN & MENG 1965 1966) These drugs have been used to improve the diagnostic accuracy of for example carcinoma of the renal pelvis or renal carcinoma of low vascularity (ABRAMS 1964 CASTELLINO 1970 EKELUND et coll 1972)

Renal cortical necrosis is caused by this mechanism and the reaction seems also to take part in renal failure due to other causes (HOLLENBERG et coll 1968 1970) During hypotension and shock due to hemorrhage contraction of cortical arteries with redistribution of blood flow was demonstrated by CORRIÈRE et coll (1966) using isotope technique and by KUPIC & ABRAMS (1968) by angiography However the redistribution may not be initiated only by lowering the blood pressure (DANIEL et coll 1952) Microembolization may therefore be part of the reaction which is supported by the fact that the cortical perfusion may remain reduced several weeks (KUPIC & ABRAMS LYRDAL et coll 1974) KELLY et coll (1976) could also induce a similar angiographic appearance after injection of autogenic blood clots Angiographically complete restitution occurred within 72 hours However the latter authors could demonstrate permanent damage to the kidney at repeat examinations weeks later The appearance of subcortical redistribution of blood flow in the kidney (the so-called Trueta phenomenon) was also demonstrated in a patient with renal artery embolisation (SIEGELMAN & GOLDMAN 1968) and it may also be the only finding in renal contusion (LANG 1975)

In conjunction with redistribution TRUETA originally reported arteriovenous shunting as evidenced by bright red blood and pulsating flow in the renal vein and early venous filling at angiography Early venous filling was also evident in 4 of the present patients (Fig 3) and is also part of the vascular reaction when induced by trauma (LANG) and on occasion after embolisation (KELLY et coll) However early venous filling does not occur in renal failure due to hemorrhagic shock (KUPIC & ABRAMS) or to other causes when the angiographic appearance otherwise is similar



a



b



c

Fig. 3 Female aged _6 with a suggestion of tumor in the left kidney a) Aortography No abnormality b c) At selective catheterization the catheter tip points into the wall of the artery Marked spasm of cortical arteries and slow circulation in the lower pole of the kidney Early venous filling. Examination in oblique projection without change of catheter position few min later No abnormality



Fig 2 Female aged 26 with nephrolithiasis Preoperative examination Normal renal circulation at aortography At selective injection spasm of cortical arteries in about 2/3 of the kidney Repeat examination few min later Normal circulation

Results

Vascular abnormalities in the kidneys were not demonstrated at aortography At the examination following the selective catheterization cortical arteries were constricted with redistribution of the blood flow to the juxtamedullary parts of the cortex The surface of the kidney appeared irregular and the margin between the cortex and the medulla was not always demarcated (Fig 1) The entire cortex was involved in 2 patients and as much as two thirds of the circumference of the kidney in the other 4 (Fig 2) Rapid venous filling occurred in 4 patients The catheter was obviously improperly positioned with the tip pointing into the arterial wall in 3 patients (Fig 3) Spasm around the catheter was evident in 3 patients but was never extreme After repositioning of the catheter the abnormalities disappeared in all patients (Fig 1)

Discussion

This type of complication has already been reported by EDSMAN (1957) at selective nephroangiography and was recently reported at non selective nephroangiography in addition (TADAVARTHY et coll 1977) The vascular reaction is probably not rare It is based on the fact that 2 types of glomeruli in the cortex of the kidney exist the



a



b



c



d

Fig 1 Female aged 53 Microscopic hematuria and suggestion of tumor of the right kidney at urography a b) Selective injection The tip of the catheter was placed too far out in the renal artery which was observed and the catheter withdrawn before injection Marked spasm of cortical arteries of the entire kidney with irregular cortical perfusion and poor demarcation between the cortex and medulla c, d) Repeat injection after 5 min Oblique projection Normal circulation restored

FROM THE DEPARTMENT OF DIAGNOSTIC RADIOLOGY (DIRECTOR PROF OLLE OLSSON)
UNIVERSITY HOSPITAL S-221 85 LUND SWEDEN

SPASM OF CORTICAL ARTERIES AS A COMPLICATION TO SELECTIVE NEPHROANGIOGRAPHY

U ALBRECHTSSON and U TYLÉN

The introduction of a catheter into the renal artery may cause *intimal lesion or* embolization Less familiar is the fact that the catheter may cause abnormalities which may mimick renal disease Therefore the appearance of this type of complication is now reported The abnormalities are reversible and are avoided by proper catheterization technique

Material and Methods

Recently this type of complication occurred in 6 patients 4 examined because of a suggestion of tumor one because of hematuria and one with nephrolithiasis as a preoperative evaluation All patients were women between 24 and 74 years of age With the exception of slight nephrosclerosis in 2 patients parenchymal disease of the kidneys was excluded by angiography and additional nephrologic examinations

Selective catheterization of the renal arteries was always preceded by aortography serving as a guide for the selective catheterization The catheterization was performed with a thin walled catheter (OD/ID 2 2/1 4 mm) without side holes After a fluoroscopic control of the postion of the catheter the contrast medium was injected by a pressure syringe at the rate of 8 to 9 ml/s Antero posterior and oblique views were obtained in all cases

Submitted for publication 10 June 1977

Table 2

Number of double contrast examinations in the four groups

	No of double contrast examinations																	
	I	II	III	IV	V	VI	VII	VIII	IX	X	XI	XII	XIII	XIV	XV	XVI	XVII	
No of animals in group																		
I	1	1	4	6	2	1												
II	17	14	14	15	9	18	5	8	6	5	1							
III	2	1	1	4	1	5	2	2	5	3		1	2		1	1	1	
IV	10	10	4	2	1	1	1	1										
Total number of animals	30	26	23	27	13	25	8	11	11	8	1	1	2		1	1	1	189
Total number of double contrast examinations	30	52	69	108	65	150	56	*88*	*99*	*80*	*11*	*12*	*26*		*15*	*16*	*17*	*894*

tion *of the* carcinogenic agent Thus the induction time in this group could not be estimated

All rats were subjected to repeated *radiography of the colon with double contrast* examination (ROSENGREN 1978) The first examination was performed four months after the first injection of the carcinogenic agent and thereafter once a month The number of examinations per animal within the different groups is given in Table 2 In all 894 examinations were performed Many rats were examined only once or twice because rats *were lost due to the* anesthesia and to mycoplasma infections (ROSENGREN) Other rats died of widespread tumour growth and some were killed for pathologic examination when a lesion was observed at radiology

Some of the animals were killed when radiography had revealed one or several polyps or carcinomas which were considered to be profitably examined by necropsy and microscopy Some *tumours* were followed for a varying period of time When the rats died or were killed necropsy was immediately performed The large bowel was removed and mounted on a wooden plate and fixed in 10 per cent *buffered* formalin for microscopy All macroscopically observed lesions were photographed in a Reprovit apparatus (Leitz with a Leica camera and Kodachrome film Kodachrome II or Kodachrome 25) *All tumours* were measured after formalin fixation and were then histologically examined With the exception of a few cases where the material was also used for other examinations all tumour material was embedded

and especially smaller tumours were sectioned at various, up to 18 levels with serial sections at each level in the tissue block Moreover pieces from other parts of the colon rectum were regularly taken for microscopy In some cases microscopic tumours were found in the surroundings of macroscopically observed tumours Special interest was also payed to the lymphoid plaques which were regularly found in the wall of the colon (LINDSTRÖM et coll 1978) Histologic sections 3 to 4 μ thick were prepared and stained routinely with hematoxylin eosin often completed with Mc Manus and in some cases van Gieson

On necropsy the abdominal cavity was inspected in great detail when large tumours were found in the colon or ascites was present Macroscopic tumours found were measured photographed and microscopically examined in the same way as for those of the large bowel

Definitions

The following definitions have been used for the benign and malignant adenomatous tumours

Adenoma Benign tumour arising from glandular epithelium and with development of tubular or acinar formations or interspersed with villous and papillary structures The adenoma may have a varying degree of epithelial atypia from slight moderate and marked to atypia with possible but not certain malignancy

Adenocarcinoma in situ This term is used for marked intra epithelial or intra glandular atypia justifying a diagnosis of malignancy (Cases with infiltration of the lamina propria were referred to the group of infiltrating adenocarcinoma)

Infiltrating adenocarcinoma To this group were referred all cases with infiltration either into the lamina propria mucosae or into deeper tissue layers the muscularis mucosae submucosa etc

Exophytic tumour Usually polypous tumour protruding into the lumen

Endophytic tumour Plateau like or ulcerating tumour with slight or no tendency to bulge into the lumen often constricting tumours

Adenomatous diverticulum A special type of adenoma with diverticulous extension into the submucosa and with adenomatous glandular epithelium From this type of diverticulous adenomas a special type of endophytic malignant tumour may develop

Grades of differentiation in adenocarcinomas (1) Well differentiated Adenocarcinomas with well developed organoid structures of acinic or tubular type and a

Table 3

Number of benign and malignant adenomatous macroscopic tumours in the different groups revealed by double contrast examination and microscopy

Group	No of animals	No of animals without tumours	No of animals with tumours	No of macroscopic tumours at microscopy	No of tumours at double contrast examination	Overlooked and misinterpreted tumours at double contrast examination
I	15	7	8	18	16	2
II	108	50	58	85	76	9
III	38	10	28	65	60	5
IV	28	8	20	46	44	2
Total number	189	75	114	214	196	18

moderate cellular atypism and mitotic frequency in the epithelium (2) Moderately differentiated Adenocarcinomas with not well-developed organoid structures and more marked epithelial atypia and high mitotic frequency (3) Poorly differentiated Adenocarcinomas with part of the tumour with only slight or no adenomatous structure but with preserved mucous production

Mucous producing signet ring cell tumours have been classified as poorly differentiated mucous producing adenocarcinomas Anaplastic carcinoma has been defined as malignant tumour with extreme cellular atypia and without differentiating cellular characteristics

In cases with varying degree of differentiation within the tumour the poorest differentiation observed has been registered

Hyperplasia of the mucous membrane and hyperplastic polyp was defined as abnormalities in the mucous membrane with elongation of glandular crypts somewhat hyperplastic columnar epithelium within these but with ordinary epithelial regeneration within the glandular crypt regions

Results

Of the total material of 189 rats macroscopic or microscopic benign or malignant adenomatous colonic tumours were diagnosed in 114 at radiography as well as at microscopy (Table 3) In the remaining 75 rats no tumour was demonstrated neither at radiography nor at the microscopic examination Of these 46 rats died during the fourth to the twelfth months after the start of injection most of them in group II due to mycoplasma infections At radiography 196 colonic tumours were

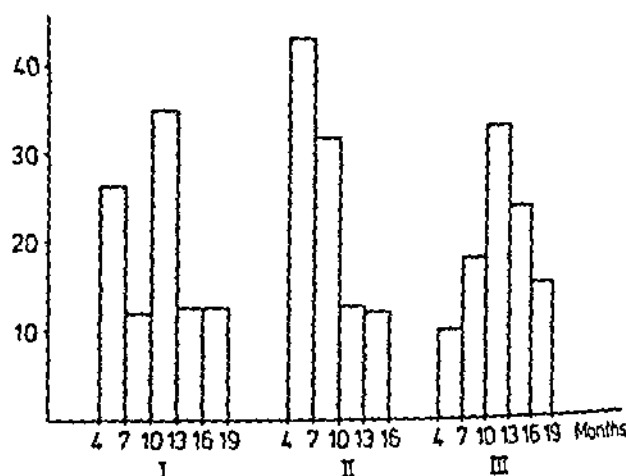


Fig 1 Induction time for all benign and malignant macroscopic adenomatous tumours observed with double contrast examination in groups I-III (The animals in group IV were initially examined at the age of about one year)

observed in 114 animals At necropsy and microscopy 214 macroscopic adenomatous tumours and 53 microscopic adenomatous tumours (22 adenomas 2 adenocarcinoma in situ 29 infiltrating adenocarcinomas) were diagnosed Eighteen macroscopic tumours were thus overlooked or misinterpreted at radiography The radiologic differentiation between normal and pathologic appearance of the colon was correct in 92 per cent (196 cases)

The induction time of both benign and malignant macroscopic tumours in the different groups appears in Figs 1 and 2 In group I the first tumour was seen 5 months after intraperitoneal injection of DMH The highest incidence of tumours occurred at 11 months

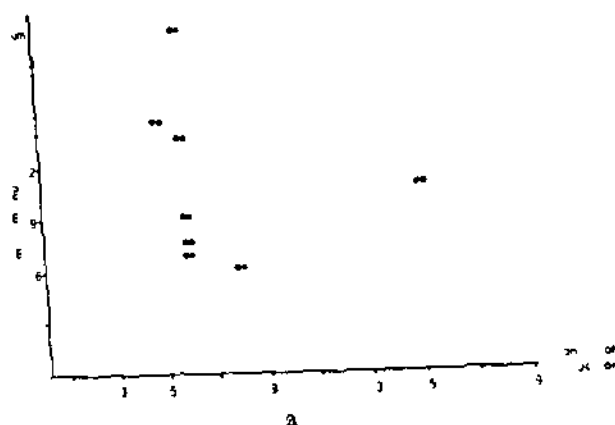
In group II the first tumour was radiologically observed 4 months after subcutaneously administered DMH The incidence was high up to 9 months after which there was a steady decline in the tumour incidence In group III after intrarectally administered MNNG the first tumour was observed after about 5 months and most tumours appeared between the tenth and thirteenth months

No difference was found in the induction time for adenomas and carcinomas

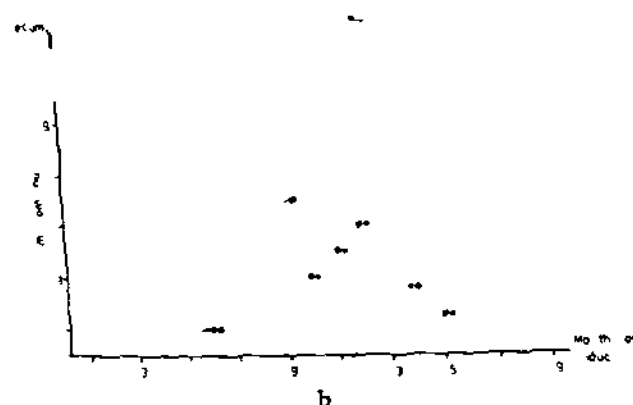
In group IV the number of tumours per rat increased with time

Number of tumours induced The maximum number of benign or malignant adenomas and carcinomas in an individual rat was 4 in group I (DMH intraperitoneally) 3 in group II (DMH subcutaneously) 7 in group III (MNNG intrarectally) and 7 in group IV (DMH subcutaneously)

The induction time and number of tumours per rat in group II and III are summarized in Fig 2 DMH treated rats most often developed one to two tumours,



a



b

Fig 2 Distribution and induction time after the first carcinogenic injection of macroscopic benign and malignant adenomatous tumours observed with double contrast examination a) DMH (group II) b) MNNG ● = 1 ★ = 2 □ = 3 △ = 4 ◇ = 5 ◆ = 6 ▼ = 7 tumours

while in MNNG treated rats often more than 3 tumours were registered The total number of tumours is summarized in Fig 3 A solitary infiltrating adenocarcinoma was found in 56 rats and a solitary adenoma in 7 rats at double contrast examination and later microscopically confirmed Intraperitoneal administration of DMH resulted in one case of solitary carcinoma and one case of solitary adenoma A solitary colonic tumour developed after (1) subcutaneous administration of DMH in group II in 35 per cent of the animals (41 carcinomas 2 adenomas) (2) after intrarectal administration of MNNG in 32 per cent (9 carcinomas 3 adenomas) and (3) in about 21 per cent of the animals in group IV injected with DMH (5 carcinomas 1 adenoma)

Distribution of tumours The distribution of adenomas, adenocarcinomas in situ and carcinomas of exophytic and endophytic type after subcutaneous administration of DMH is given in Fig 4 a and after intrarectal injection of MNNG in Fig 4 b As seen most polyps carcinomas in situ and infiltrating adenocarcinomas appear around the major flexure i e 9 to 12 cm above the anus (ROSENGREN & LINDSTRÖM) In the MNNG group most tumours were localized to the distal colon

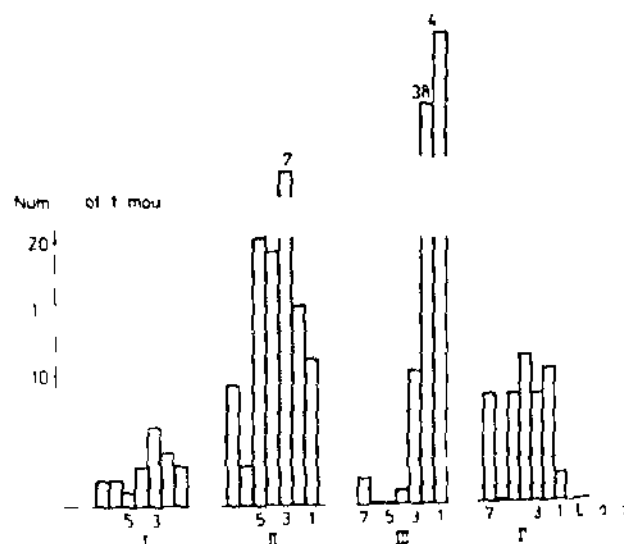


Fig 3 Distribution of all micro and macroscopic adenomatous tumours (267) 1) anus 3 cm 2) 3–6 cm 3) 6–9 cm 4) 9–12 cm 5) 12 15 cm 6) 15–18 cm 7) caecum

and rectum (within a distance of 1–7 cm from the anus) and only 3 tumours were found proximal to the major flexure

Size of tumours At radiography tumours more than 1 mm in diameter could be observed at microscopy tumours less than 1 mm were found (Fig 5) As the neoplasms grew larger the tumours often developed a stalk (exophytic type) or grew as plaques or constricting tumours (endophytic type) Most adenomas were small 39 per cent measured 1 to 3 mm in size and 48 per cent were microscopic (6 adenomas were 4–6 mm in diameter)

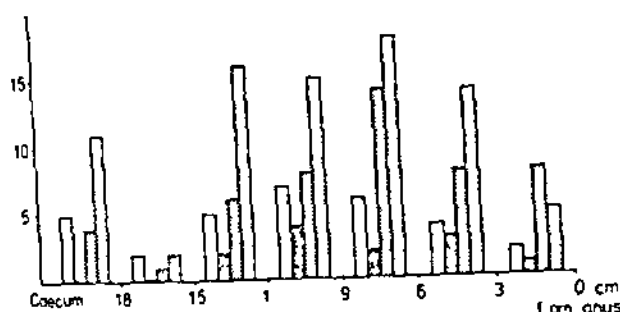
Most carcinomas in situ measured 1 to 6 mm in diameter The size of *infiltrating* adenocarcinomas varied up to more than 15 mm in diameter In the total material 46 per cent of the infiltrating tumours measured 3 to 9 mm in size at *necropsy*

In animals where a carcinoma and benign adenoma appeared simultaneously the former was ultimately larger than the adenoma

Microscopic appearance The following types of benign and malignant adenomatous tumours and other lesions in the colon and rectum were found 179 macroscopic adenocarcinomas Of these 100 (56%) were endophytic and 69 (38) exophytic and 7 (4%) of mixed endo and exophytic type In 3 cases (2) the type could not be determined with certainty

Twenty nine infiltrating adenocarcinomas all of endophytic type were diagnosed In this group one anaplastic malignant tumour probably an anaplastic adenocarcinoma has been included Of the 208 infiltrating adenocarcinomas thus 179 (86 1 %) were macroscopic in size

In the DMH series adenocarcinomas of both well moderately and poorly differentiated types occurred while in the MNNG series the adenocarcinomas



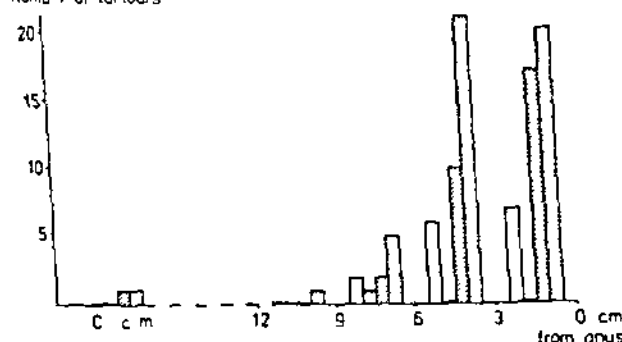


Fig 4 Distribution of different types of micro- and macroscopic benign and malignant adenomatous tumours found at microscopy of animals treated with a) DMH (groups I II IV) and b) MNNG ☐ Adenoma ☐ Carcinoma in situ ☐ Exophytic carcinoma ☐ Endophytic carcinoma

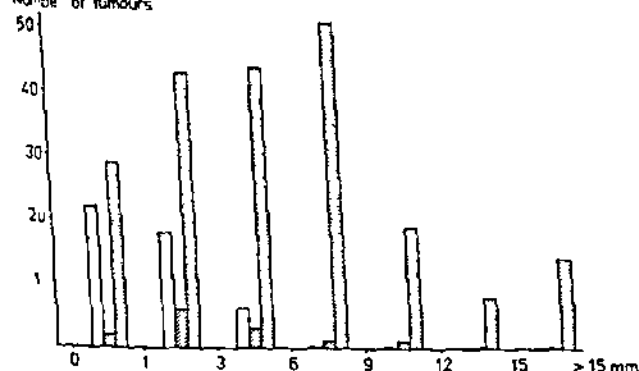


Fig 5 Size of all benign and malignant adenomatous tumours in animals treated with DMH or MNNG found at microscopy ☐ Adenoma ☐ Carcinoma in situ ☐ Infiltrating carcinoma

were mainly well differentiated In the latter series with mainly well differentiated carcinomas no metastases were recorded and only few of the carcinomas in this series invaded the bowel wall beyond the submucosa In the DMH series metastases to lymph nodes or intraperitoneally were recorded in 21 (17 5%) of 120 macroscopic

carcinomas These metastases came only from adenocarcinomas of moderately to poorly differentiated mucous producing type mainly signet ring cell carcinomas Furthermore 11 macroscopic and 2 microscopic adenocarcinomas in situ were diagnosed

Of the adenomas 24 were macroscopic and 22 microscopic

To the adenoma group could be added 16 adenomatous diverticula 4 being microscopic Such lesions were found only in the distal part of the colon and rectum These adenomatous diverticula are not included because of their differing morphology and difficulty in follow up at radiography

Carcinomas developing from adenomatous diverticula occurred in 15 4 per cent (32 of 208) from both the DMH and the MNNG series Corresponding to the distribution of adenomatous diverticula such tumours were found only in the major flexure the distal colon and the rectum

Adenocarcinomas developing from lymphoid plaques were only found in the DMH series in 27 cases 5 of which were microscopic

In addition to these 267 adenomatous tumours observed at microscopy there were 76 other lesions of varying appearance in the colon Hyperplastic polyps were 26 (11 microscopic) and inflammatory polyps 20 (5 microscopic) Thirteen mostly large malignant tumours of carcino sarcoma like structure with parts of both adenocarcinomatous and sarcomatous tumour types were found as well as 11 sarcomas of various types 1 myxoma 1 microscopic lipoma 1 microscopic fibroma like tumour and 3 cases of malignant lymphoma Because of their differing appearance and development these tumours were excluded

Extra colonic lesions In the DMH series 32 cases of infiltrating adenocarcinomas in the small bowel were diagnosed 28 1 per cent well differentiated and 71 9 per cent poorly differentiated mucos producing signet ring cell tumours

Twenty four renal tumours were found in the DMH series 3 benign adenomas 10 carcinomas (of hypernephroma type) and 1 carcinoma of the renal pelvis Furthermore 10 malignant renal tumours of mesenchymal type were encountered

Eight liver biliary tract tumours were also observed 5 bile duct adenomas and 1 benign liver adenoma 1 bile duct adenocarcinoma and 1 malignant hepatoma (hepatocarcinoma)

Discussion

In man contrary to the rat the large intestine is the most common organ where primary multiple tumours occur (Wood 1967) The experimental techniques used in this investigation to produce intestinal tumours in rats offer an opportunity for systematic evaluation of different aspects of primary tumours with this localization (Walpole et coll 1952 King & Varasdi 1959 Druckrey et coll 1967 Spjut & Noall 1971) Despite the available methods of induction only scant attention has



Fig 6 Consecutive double contrast examination of a rat 8 to 15 months after intrarectal administration of MNNG The first tumour appeared after 8 the second after 10 the third after 11 months The two first tumours had the appearance of primary carcinomas the third one had the appearance of an adenoma with a malignant change at 13 months



Fig 7 a) Macrophotograph *of the entire* colorectal specimen of the rat illustrated in Fig 6 An adenocarcinoma (7 mm 4 mm 3 mm) (↔) and a small early adenocarcinoma (–) infiltrating in the lamina propria *mucosae* (3 mm 2 mm) At the distal margin a large adenocarcinoma (9 mm 7 mm 5 mm) b) *Detail of framed* area in (a) In the upper margin of the figure a part of a lymphoid plaque is seen

been paid to induction time distribution and the morphologic appearance of intestinal tumours *in the rat* the reason being that previously the possibilities have been limited *The results* have been available only after killing of the experimental animals (SPJUT & NOALL MARTIN et coll 1973 WARD 1974 POZHARISSKI 1975)

Some authors *have* killed the rats at a fixed time (SCHOENTAL & BENSTED 1968 DRUCKREY 1970 *SPJUT* & NOALL) others have kept the rats alive until they died of widespread *tumour growth* (MARTIN et coll NIGRO et coll 1973)

SPJUT & NOALL *killed* the animals after varying periods of time to provide specimens suitable *for* determining the histogenesis of polyps and carcinomas *However this* method proved to be less successful The present method consisting *of consecutive* radiologic examination of the animals and a final necropsy and *microscopic* examination made a follow up of the development of colonic tumours possible (Figs 6-8)



Fig. 8 Microphotograph of the proximal adenocarcinoma in Fig 7 an exophytic well differentiated adenocarcinoma infiltrating into the submucosa Htx E 12

The double contrast examination of the colon of the rat offers good possibilities of diagnosing lesions in the mucosa (ROSENGREN & LINDSTRÖM) In this previous report the radiographic and microscopic criteria of mucosal lesions were described The relation between tumours detected at radiography and microscopy agrees well in the previous and the present series Of the 18 tumours in the present series not detected at radiography most were overlooked because of insufficiently cleansed colon

Except for a few preliminary observations no specific detailed metabolic investigations of the two carcinogens DMH and MNNG used have been reported After the carcinogenic potency of DMH had been detected by DRUCKREY this chemical has been used to induce colonic tumours in animals by subcutaneous administration

Spontaneous occurrence of malignant tumours in the large intestine is extremely rare in rats and for this reason all observed tumours in the present series were considered as induced tumours

BULLOCK & ROHDENBURG (1917) reported 171 naturally occurring tumours in rats Of these 123 were reported in the literature the remaining 48 being found in about 19 000 rats most of which were young No tumours of the large bowel were found

Many reports have been published about the induction of colorectal tumours in rats by various carcinogens (SPJUT & SPRATT 1965 DRUCKREY et coll SCHOENTAL & BENSTAD NARISAWA et coll 1971 SPJUT & NOALL SPJUT 1972 WARD 1974) POZHARISSKI (1975) claims in his review of chemically induced intestinal tumours that nearly all rats treated with DMH will have intestinal tumours 6 months later In other reports the incidence of induced tumours is varying (DRUCKREY et coll)

In the present series the number of tumours in the different groups also varied 52 to 75 per cent (Figs 9 10) From the results obtained it is clear that DMH given subcutaneously in a small dose (group II) induces colon tumours in a shorter time

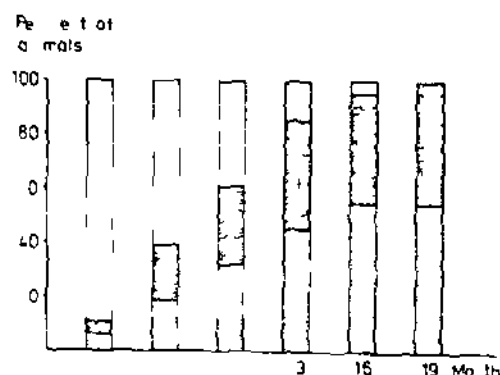


Fig 9

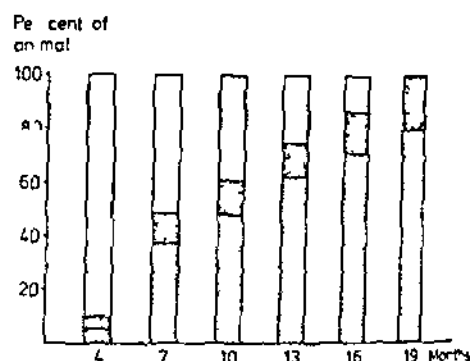


Fig 10

Fig 9 Animals in per cent of DMH treated animals with and without tumours observed at different periods ▢ Living rats without colonic tumours ⬚ Dead rats without colonic tumours ⌜⌝ Living and dead rats with colonic tumours

Fig. 10 Animals in per cent of MNNG treated animals with and without developed tumours observed by double contrast examination at different periods (Symbols as in Fig 9)

and with somewhat higher incidence than when given intraperitoneally in a higher dose (group I) The discrepancy in incidence of induced tumours in the present series and between this and previous reports may be explained by different doses and routes of administration of DMH

A drawback with DMH in this series was that primary tumours were induced also in other organs This is in line with the results of other authors (WIEBECKE 1973 WARD) On the other hand intrarectal administration of MNNG induced tumours exclusively in the large bowel and with a high incidence With this simple and easy technique the carcinogen after chemical splitting via monomethylnitrosamine to the carcinogenic active form diazomethan works by alkylating the nucleic acids (WIEBECKE)

The radiologic examination necessitated an anesthesia of the animals In the beginning the mortality during the anesthesia was high but diminished when no anesthesia was used for the cleansing enemas and further more when intraperitoneal chloral hydrate was used as anesthetic (ROSENGREN)

As in man atropine sulphate reduced the peristalsis at the radiology dilated the lumen of the bowel and the diagnostic accuracy of the examination was improved

The induction time of the macroscopic tumours as reflected in the films is illustrated in Figs 1 and 2 They demonstrate that the first tumours were observed after 4 months in rats given DMH *intraperitoneally and in* MNNG treated animals. The number of tumours induced during the first 9 months after treatment was higher in animals given DMH than in those given MNNG Briefly 60 per cent of all tumours induced by DMH had appeared within 9 months while 78 per cent of all MNNG induced tumours appeared after that time

The results obtained disagree with other statements as to induction time where

the first tumours were observed initially about 5 months after DMH treatment (WARD) and about 6 months after MNNG treatment (NARISAWA et coll KIKKAWA 1974) This difference in induction time may be explained by the more detailed information obtained from the consecutive series of double contrast examination of the colon On the other hand the total number of tumours after DMH and MNNG administration obtained in the present series agrees well with the figures reported by NARISAWA et coll. and WARD

The distribution of induced tumours differed between animals given DMH by different routes of administration and differed also between these and animals treated with MNNG

In the rats given DMH intraperitoneally more than half of the tumours (61 9 %) were located to the distal colon and rectum and 14 3 per cent of these to the rectum Animals given DMH subcutaneously (group II) had a somewhat lower incidence of tumours in the rectum (10 7 %)

A lower incidence of induced rectal tumours following subcutaneously administered DMH was reported by MARTIN et coll and WARD However they defined the rectum as the most distal 1 5 cm of the bowel In the present series the corresponding figure was 3 0 cm which is based on an anatomic investigation (LINDSTRÖM et coll 1978) If the difference in estimated lengths of the rectum is taken into account the present results and those of WARD and MARTIN et coll agree well

The majority of induced tumours after subcutaneously injected DMH occurred in the middle parts of the colon In all DMH treated animals about 60 per cent of all induced tumours were located within 3 to 6 cm above the anus This distribution was the same for all DMH induced lesions adenomas and carcinomas of exophytic and endophytic types Such a parallelism in the distribution has also been observed by MARTIN et coll

In all micro- and macroscopic adenomatous tumours the distribution of adenomas and infiltrating adenocarcinomas of exophytic and endophytic type has largley the same appearance

The distribution of the adenomas is roughly parallel to that of infiltrating carcinomas which also was noted by MARTIN et coll and SPJUT This observation revives the controversial opinions on the relationship between adenomatous polyps (adenomas) and carcinomas (DOCKERTY 1958 SPRATT et coll 1958)

DOCKERTY WARD and EKELUND et coll among others stress that the adenomatous polyp has a tendency to grow malignant SPRATT et coll are of the opposite opinion

The results of the present investigation may yield some information about the relationship between adenomas and carcinomas

(1) They are both induced by the same carcinogens The administration of DMH and MNNG resulted in the development of adenomas as well as carcinomas

(2) Adenomas and carcinomas could be found simultaneously in the colonic mucosa

(3) Adenomas and adenocarcinomas had the same distribution

(4) Nearly half of the adenomas were microscopic in size while most carcinomas were more than 3 mm in size No adenoma was larger than 6 mm in diameter

(5) A local growth of carcinoma was observed in 17 adenomas at microscopy

(6) Carcinomas in situ appeared always in the vicinity of other types of micro- or macroscopic adenomatous tumours

All the mentioned facts together strongly suggest that adenomas and carcinomas are generated by the same biologic mechanism acting upon the epithelium

Strong evidence of the premalignant propensity of the adenoma to grow malignant is the observed presence of carcinoma within an adenoma If this phenomenon was just the result of a random selection it would appear as an exclusive rarity It should appear in the same ratio to carcinomas as the ratio between the volume of the adenomas and the total volume of the colonic mucosa

The high frequency of poorly differentiated mucous producing adenocarcinomas usually of signet ring cell type in the DMH series is remarkable Estimating from group II with the largest number of tumours 50 per cent of the infiltrating carcinomas (macro and microscopic) were of this type which is rather seldom observed in the colon and rectum in man

The distribution within the colon of this type of malignancy compared with that of well or moderately differentiated adenocarcinomas is also remarkable (WARD POZHARISSKI 1973 1975) In the present series 70 per cent of signet ring cell carcinomas were located in the caecum proximal colon and the major flexure which seems to correspond to the special mucosal type in these areas with high of rather high frequency of goblet like cells in the basal part of the glandular crypts in the mucosa By contrast well or moderately differentiated adenocarcinomas seldom occur in the caecum and proximal colon while 92 3 per cent of these malignant tumours were found in the major flexure or in the distal colon and the rectum

About 20 per cent of the adenocarcinomas of both main types (well to moderately differentiated and poorly differentiated signet ring cell types) were found 9 to 12 cm from the anus in the major flexure and in the transitional zone with microscopic characteristics of both the proximal and the distal colon Thus there seems to be a relationship between the various mucosal types and the carcinomas developing from these regions of the colon and rectum This relationship seems to be rather convincingly apparent in the present series

SUMMARY

In 189 rats N methyl N nitro N nitrosoguanidine or 1 2-dimethylhydrazine (DMH) was given in order to induce colonic tumours The tumour induction was followed by double contrast examination At 894 examinations 196 adenomatous tumours were revealed Autopsy and microscopy revealed 214 macroscopic and 53 microscopic benign or malignant adenomatous tumours Metastases were found in 17 per cent in the DMH group The relationship between adenomas and carcinomas is also evaluated

ZUSAMMENFASSUNG

An 189 Ratten wurde N methyl N nitro-N nitrosoguanidine oder 1 2-dimethylhydrazine (DMH) verabreicht um Kolontumoren zu induzieren Die Tumor Induktion wurde durch Doppelkontrastuntersuchung verfolgt Bei 894 Untersuchungen wurden 196 adenomatose Tumoren festgestellt Autopsie und Mikroskopie zeigten 214 makroskopische und 53 mikroskopische benigne oder maligne adenomatose Tumoren In 17 Prozent bei der DMH Gruppe wurden Metastasen gefunden Weiterhin wurde das Verhaltnis zwischen Adenomen und Karzinomen gestgestellt

RESUME

De la N methyl N nitro-N nitrosoguanidine ou de la 1 2-diméthylhydrazine (DMH) ont eté administrees à 189 rats pour induire des tumeurs coliques L induction de tumeurs a ete suivie par des examens en double contraste Huit cent quatre vingt quatorze examens ont revélé 196 tumeurs adenomateuses L autopsie et l examen microscopique ont décelé 214 tumeurs adenomateuses malignes ou bénignes macroscopiques et 53 tumeurs microscopiques Des métastases ont eté decouvertes dans 17 pour cent du groupe DMH Les auteurs étudient aussi les relations entre adénomes et carcinomes

REFERENCES

BULLOCK F D and ROHDENBURG G L Spontaneous tumours of the rat J Cancer Res 2 (1917) 39
DOCKERTY M B Pathologic aspects in control of spread of colonic carcinoma Mayo Clin Proc 33 (1958) 157
DRUCKREY H Production of colonic carcinomas by 1 2 dialkyl hydrazines and azoxy alkanes *In* Carcinoma of the colon and antecedent epithelium Chapter 20 p 267 Edited by W J Burdette Charles C Thomas Springfield Ill 1970
— PREUSSMANN R MATZKIES F und IVANKOVIC S Selektive Erzeugung von Darmkrebs bei Ratten durch 1 2 Dimethyl Hydrazin Naturwissenschaften 54 (1967) 285
EKELUND G LINDSTROM C and ROSENGREN J E Appearance and growth of early carcinomas of the colon rectum Acta radiol Diagnosis 15 (1974) 670
KIKKAWA N Experimental studies on polypogenesis and carcinogenesis of the large intestine Med J Osaka Univ 24 (1974) 293
KING E S J and VARASDI G Experimentally induced tumours of the intestine Aust N Z J Surg 29 (1959) 38
LINDSTROM C G ROSENGREN J E and FORK F T Colon of the rat An anatomic histologic and radiologic investigation To be published in Acta radiol Diagnosis (1978)
MARTIN M S MARTIN F MICHIELS R BASTIEN H JUSTRABO E BORDES M and VIRY B An experimental model for cancer of the colon and rectum Digestion 8 (1973) 22
NARISAWA T SATO T HAYAKAWA M SARUMA A and NAKANO H Carcinoma of the colon and rectum of rats by rectal infusion of N methyl N nitro N nitrosoguanidine Gann 62 (1971) 231
NIGRO N D BHADRACHARI N and CHOMACHAI CH A rat model for studying colonic cancer Dis Colon Rectum 16 (1973) 438
POZHARISSKI K M Tumours in the intestines *In* Pathology of tumours in laboratory animals Vol 1 part 1 p 119 Edited by V S Turusov International Agency for Research on Cancer Lyon 1973

— Morphology and morphogenesis of experimental epithelial tumours of the intestine J nat Cancer Inst 54 (1975) 1115
ROSENGREN J E *Experimental colonic tumours in the rat I Preparation and technique* of examination Acta radiol Diagnosis 19 (1978) 353
— and LINDSTROM C G Experimental colonic tumours in the rat II Double contrast examination and microscopy Acta radiol Diagnosis 19 (1978) 465
SCHOENTAL R and BENSTED J P M Tumours of the intestines induced in rats by intraperitoneal injections of N Methyl and N Ethyl N nitrosourethanes Brit J Cancer 22 (1968) 316
SPJUT H J Newer concepts of cancer of the colon and rectum Similarities between human experimentally induced tumours of the large intestine Dis Colon Rectum 15 (1972) 94
— and NOALL M W Experimental induction of tumours of the large bowel of rats *A review of the experience with 3 2 dimethyl 4-aminobiphenyl* Cancer 28 (1971) 29
— and SPRATT J S Endemic and morphologic similarities existing between spontaneous colonic neoplasms in man and 3 2 dimethyl 4 aminobiphenyl induced colonic neoplasms in rats Ann Surg 161 (1965) 309
SPRATT J S JR ACKERMAN L V and MOYER C A Relationship of the polyps of colon to colonic cancer Ann Surg 148 (1958) 682
WALPOLE A L WILLIAMS M H C and ROBERTS D C The carcinogenic action of 4-aminodiphenyl and 3 2 dimethyl-4 aminodiphenyl Brit J industr Med 9 (1952) 255
WARD J M Morphogenesis of chemically induced neoplasms of the colon and small intestine in rats Lab Invest 30 (1974) 505
WEISBURGER J H Chemical carcinogens and their mode of action in colonic neoplasia Dis Colon Rectum 16 (1973) 431
WIEBECKE B Modelle experimenteller Carcinogenese Darm *In* Handbuch der allgemeinen Pathologie Geschwulste — Tumors III Band VI 7 p 731 Edited by E Grundmann Springer Verlag Berlin Heidelberg New York 1975
WOOD D A Tumours of the intestines *In* Atlas of tumor pathology Sect 6 Fasc 22 Armed Forces Institute of Pathology Washington D C 1967

FROM THE DEPARTMENTS OF DIAGNOSTIC RADIOLOGY (DIRECTOR: PROF. ULF RUDHE) AND SURGERY (DIRECTOR: PROF. CURT FRANKSSON), HUDDINGE SJUKHUS, S-141 86 HUDDINGE, SWEDEN

BLOOD INFLOW INTO INTRA-ARTERIAL CATHETERS FOLLOWING INJECTION OF CONTRAST MEDIUM

M. DAHLBORN, B. CALISSENDORFF and R. CRONESTRAND

The incidence of thromboembolism following introduction of catheters into arteries varies between 0.5 and 6.5 per cent according to previous reports (LANG 1963, KOTTKE et coll. 1964, FORMANEK et coll. 1970). One source of this complication is early aggregation of thrombocytes and subsequent formation of fibrin sleeves on the external surface of an intravasal catheter (JACOBSSON & SCHLOSSMAN 1969). When blood enters the catheter lumen the same mechanism also applies for the inner surface of the catheter with a risk for distant emboli (SCHLOSSMAN 1973). Flushing with isotone saline solutions is the commonly used method to avoid reflux of blood into a catheter. Water soluble contrast media have also been used for this purpose and should be more effective in preventing small clot formations in the catheter lumen than heparinized saline solution (HAWKINS & HERBERT 1974). As the mechanism of blood inflow into an intravasal catheter following an injection of contrast medium has not previously been analyzed in detail such an investigation was performed and the time relationships of this event estimated clinically and experimentally.

Material and Methods

The material consisted of 29 carotid angiographies in 20 patients and 97 aortographies in 10 mongrel dogs. The carotid angiographies were performed with C[illegible]

Submitted for publication 10 June 1977

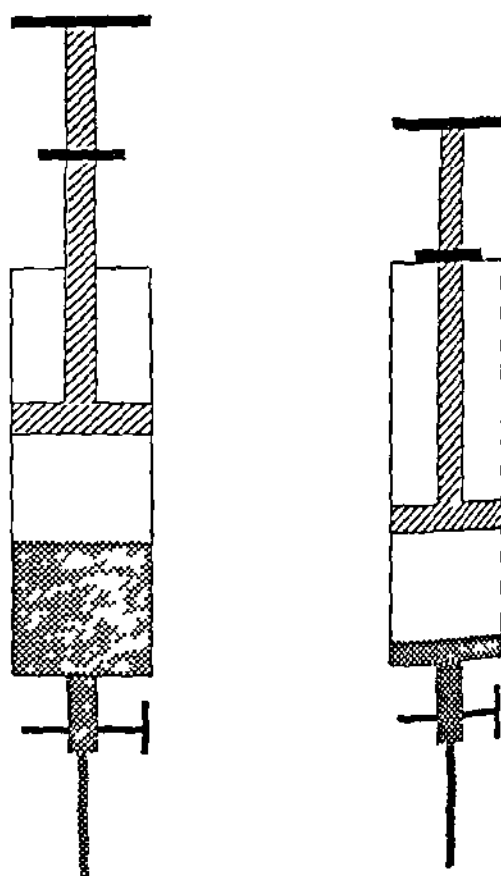


Fig 1 Vertically held syringe with stop screw containing contrast medium and air before (left) and after (right) injection of contrast medium

catheters (Fr P 5 0 length 100 cm ID 0 99 mm) or Mediplast catheters (No 7 end hole 160 bent E length 100 cm ID catheter 1 2 mm and tip 0 90 mm) without side holes Following percutaneous catheterization of the femoral artery the catheter tip was placed in the common carotid artery immediately proximal to the bifurcation Manual injection of 5 to 7 ml Isopaque Cerebral (meglumine/calcium metrizoat 280 mg I/ml) was performed for examination of the extracranial part of the carotid artery with horizontal beam direction Films were exposed 0 5 10 20 30 40 50 and 60 s after the end of the injection In 16 examinations the tap of the catheter was closed immediately after the injection and in 13 the catheter tap remained open and in communication with a vertically held syringe This contained contrast medium and 2 to 5 ml of air and was equipped with a stop screw (Fig 1) In 8 examinations with the tap closed the catheter tip was directed upward and in the remaining 8 downward (Table 1) The corresponding number of examinations with the tap open was 7 and 6 respectively The blood pressure of the patients varied between 90/70 and 155 90 mmHg Cerebral circulation time measured on the films (GREITZ 1956) was normal in 13 patients and increased to a varying extent in 7

In the animal experiments dogs weighing between 19 and 35 kg were anaesthetized




Fig. 2 Intra aortic catheters in a dog 5 min after injection of contrast medium Left catheter is directed downstream with the tip deviating 1 upward and the right one upstream with the tip 7 downward Arrows indicate border between contrast medium and blood Above is a water level Around aorta an electromagnetic flow meter (right)

with phenobarbital lealgin and pancuronbromid The animals were placed in supine position intubated and ventilated with an O_2–NO_2 mixture in an AGA respirator ECG and intra arterial blood pressure were continuously recorded no significant variations occurred In 6 dogs the aortic blood flow was continuously registered by an electromagnetic flow meter (376 Nycotron Drammen Norway) The probe was surgically placed around the aorta halfway between the mesenteric arteries (Fig 2) The blood flow varied in the different dogs (400–1 200 ml/minute) but was constant during the experiments Immediately after injection of the contrast medium a slight increase in blood flow and reduction of blood pressure followed but was normalized within 1 5 min (Fig 3) The beam direction was horizontal Cook catheters of the same type as those employed in the carotid angiographies in the clinical material were used in the animal experiments 2 catheters were examined in each aortography The catheters were surgically introduced into the left common carotid artery and one of the femoral arteries The catheters were directed either downstream or upstream The tip was directed upwards or downwards and 5 to 7 ml of Isopaque Cerebral were

Table 1

Carotid angiography Number and orientation of catheters

	Catheter tip direction				
	No	Upwards	Angle	Downwards	Angle
Catheter tap closed	16	8	1–48	8	18–50
Catheter tap open	13	7	5–35	6	8–32
Total	29				

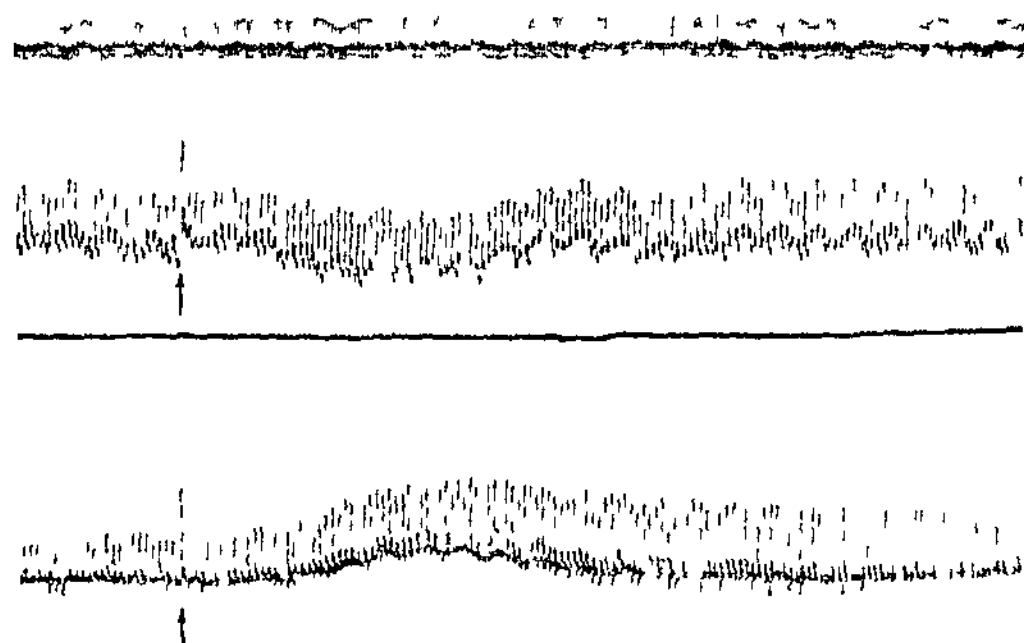


Fig 3 Recording of ECG (above) of blood pressure (middle) and blood flow (below) in the abdominal aorta of a dog Immediately after injection of contrast medium (↑) blood pressure decreases and a blood flow increases normalizing within 1 5 min

injected manually or by an automatic syringe pump Films were exposed 0 15 30 60 s and 1 5 2 3 4 and 5 min after the end of the injection

In 35 aortographies the tap of the catheter was closed immediately after the injection while in 13 the tap remained open to a vertically held syringe containing air and contrast medium The orientation of the catheters used in these 48 aortographies appears in Table 2 In the remaining 49 aortographies a syringe pump (Sage in

Table 2

Aortography in dogs Number and orientation of catheters

	Catheter tip direction				
	No	Upwards	Angle	Downwards	Angle
Downstream					
Catheter tap closed	26	18	0–45	8	1 18
Catheter tap open	13	9	3–45	4	34 50
Total	39				
Upstream					
Catheter tap closed	29	15	0–77	14	05 7
Catheter top open	13	5	0–40	8	05 35
Total	42				




Fig 4 a) Catheter in human common carotid artery immediately after injection of contrast medium Lumen of the catheter is completely filled with contrast medium b) Same catheter 30 s after the injection Blood has entered the catheter lumen Arrow indicates border between contrast medium and blood

struments pump No 351) was used in order to evaluate the effect on admixture of blood to the catheters by continuous flow of contrast medium The flow velocity was constant during each film sequence and the following velocities were used 0 03, 0 08 0 20 0 35, 0 50 0 70 0 90 and 1 20 ml/min

The length (L) of the blood inflow into the catheters (Figs 2 5) and the deviation of the tip of the catheters from the horizontal level were measured in all carotid angiographies and aortographies (Table 2) The horizontal level was indicated by the film edge and a water level (Fig 2) respectively

Results

In all examinations the lumen of the catheter was completely filled with contrast medium at the end of injection (Fig 4 a) A few seconds later the contrast medium in the catheter tip invariably became partially replaced by blood forming a layer on the portion of the contrast medium below it (Figs 2 4 b) In the examinations with the catheter tap closed the blood inflow was consistently less with the catheter tip directed upwards compared with the downward direction In the carotid injections the average length of the blood inflow after 60 s was 6 mm and 31 mm respectively (Fig 5) The corresponding figures of the aortic injections in the dogs e g with the catheters directed downstream were 4 mm and 20 mm respectively (Fig 7) With the catheter tip directed upwards only a minor increase in the length of the blood column occurred when measured in the interval 1 to 5 min after the end of the injection When the tip was directed downwards the length of the blood column (L) successively increased in the same interval

In the carotid injections in the patients and the aortic injections in the dogs with the catheter tap open a large and rapid inflow of blood consistently took part in

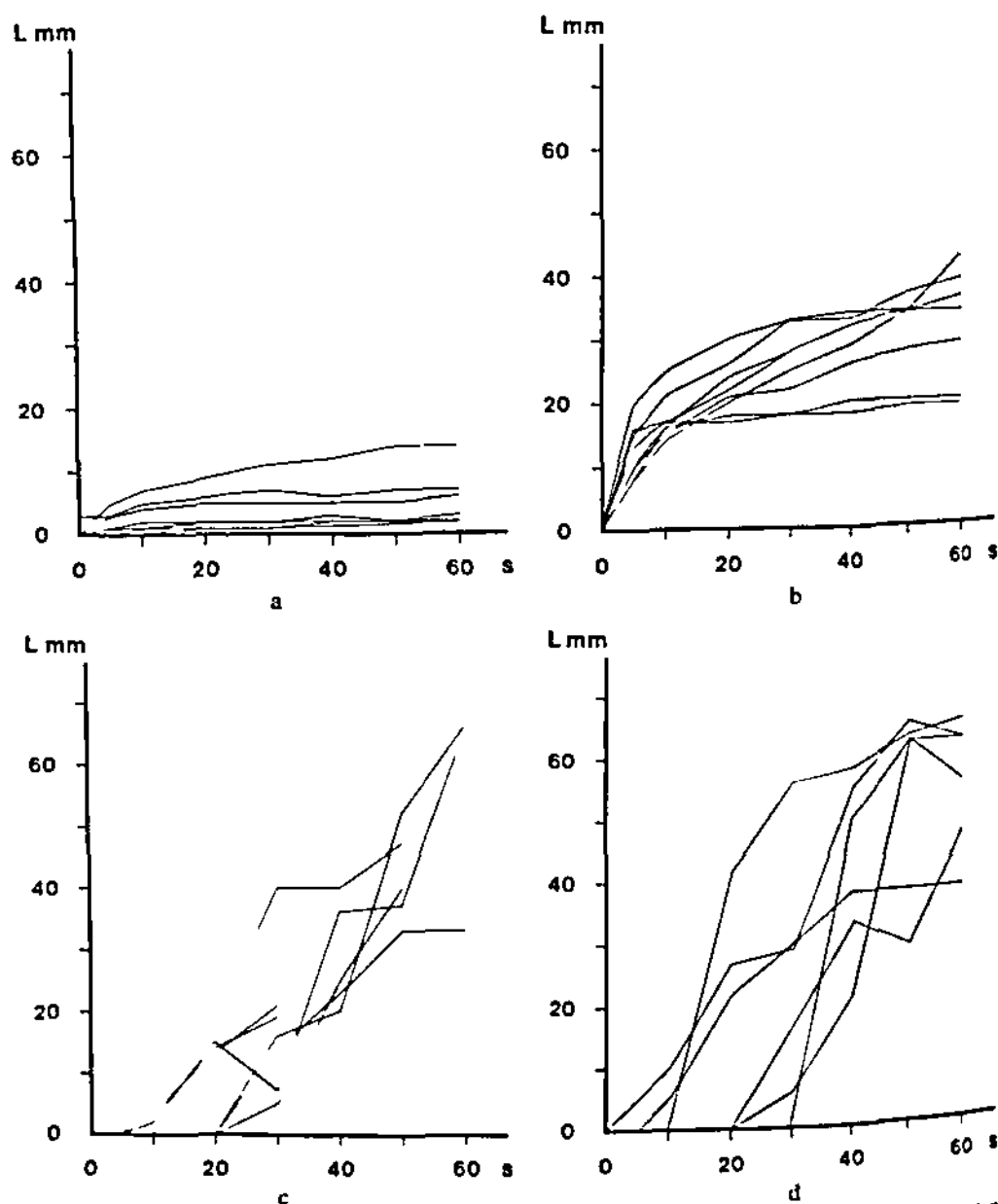


Fig 5 Inflow of blood into catheters 29 human common carotid angiographies With catheter taps closed after injection of contrast medium less inflow with the tips directed upwards (a) than downwards (b) With open catheter taps inflow is large with the tips deviating upwards (c) as well as downwards (d)

respectively of the direction of the catheter tips (Figs 6 7) The average length of the blood column in the carotid catheters 60 s after the end of the injection was 55 mm irrespective of the orientation of the catheters The corresponding figure of the aorti catheters in dogs was 57 mm and after 5 min 59 mm These figures included examinations with the catheter tip oriented both upwards and downwards

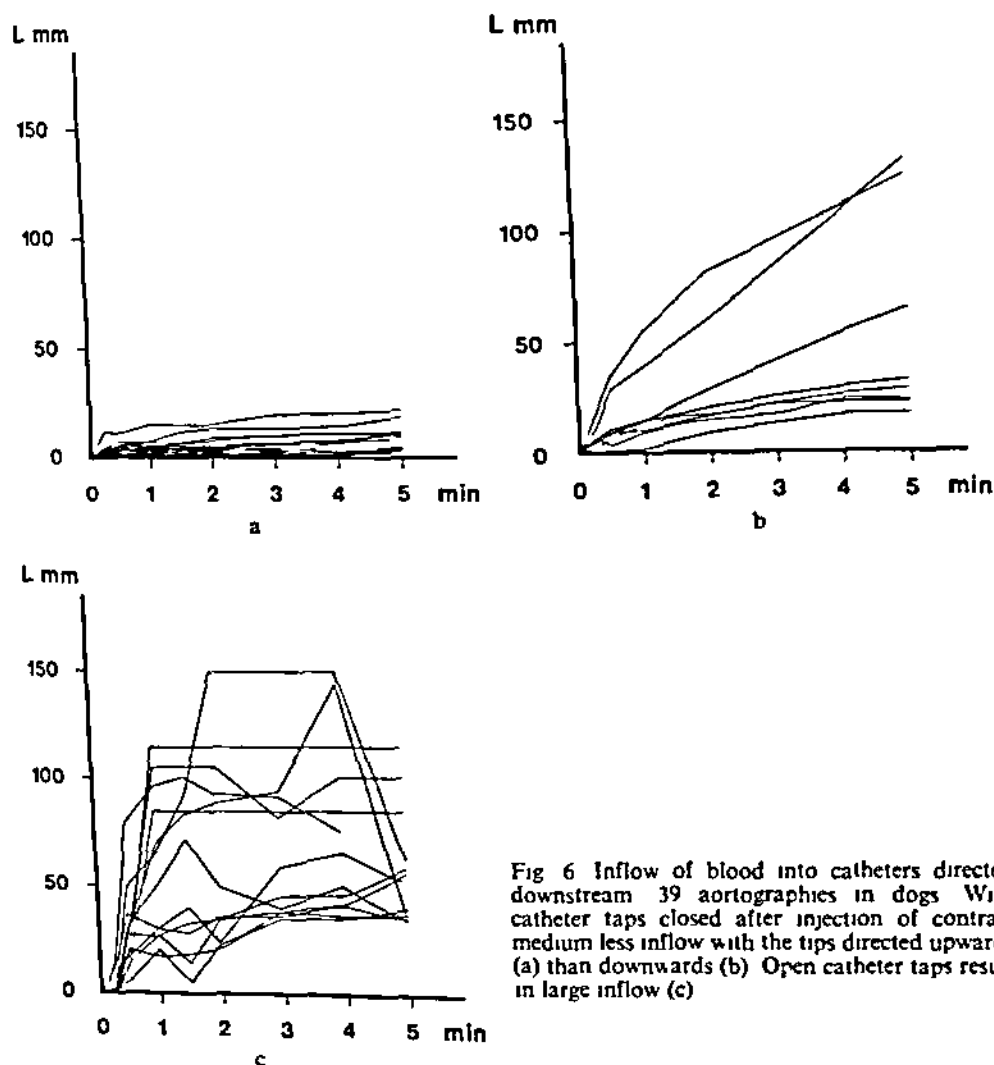


Fig 6 Inflow of blood into catheters directed downstream 39 aortographies in dogs With catheter taps closed after injection of contrast medium less inflow with the tips directed upwards (a) than downwards (b) Open catheter taps result in large inflow (c)

No differences were observed in the amount and speed of the blood inflow in the catheters directed downstream and upstream (Figs 7 8)

When the injector was used the blood inflow decreased with increasing flow velocity (Fig 8) When the catheters were directed downstream irrespective of the direction of the catheter no regular blood inflow into the catheter lumen occurred with flush speeds exceeding 0 35 ml/min With the catheters directed upstream no constant blood inflow occurred with flush speed exceeding 0 50 ml/min

Discussion

During intravasal catheterization a thrombus may arise at the inner or outer surfaces of a catheter or from the surrounding vessel wall This may result in creation of

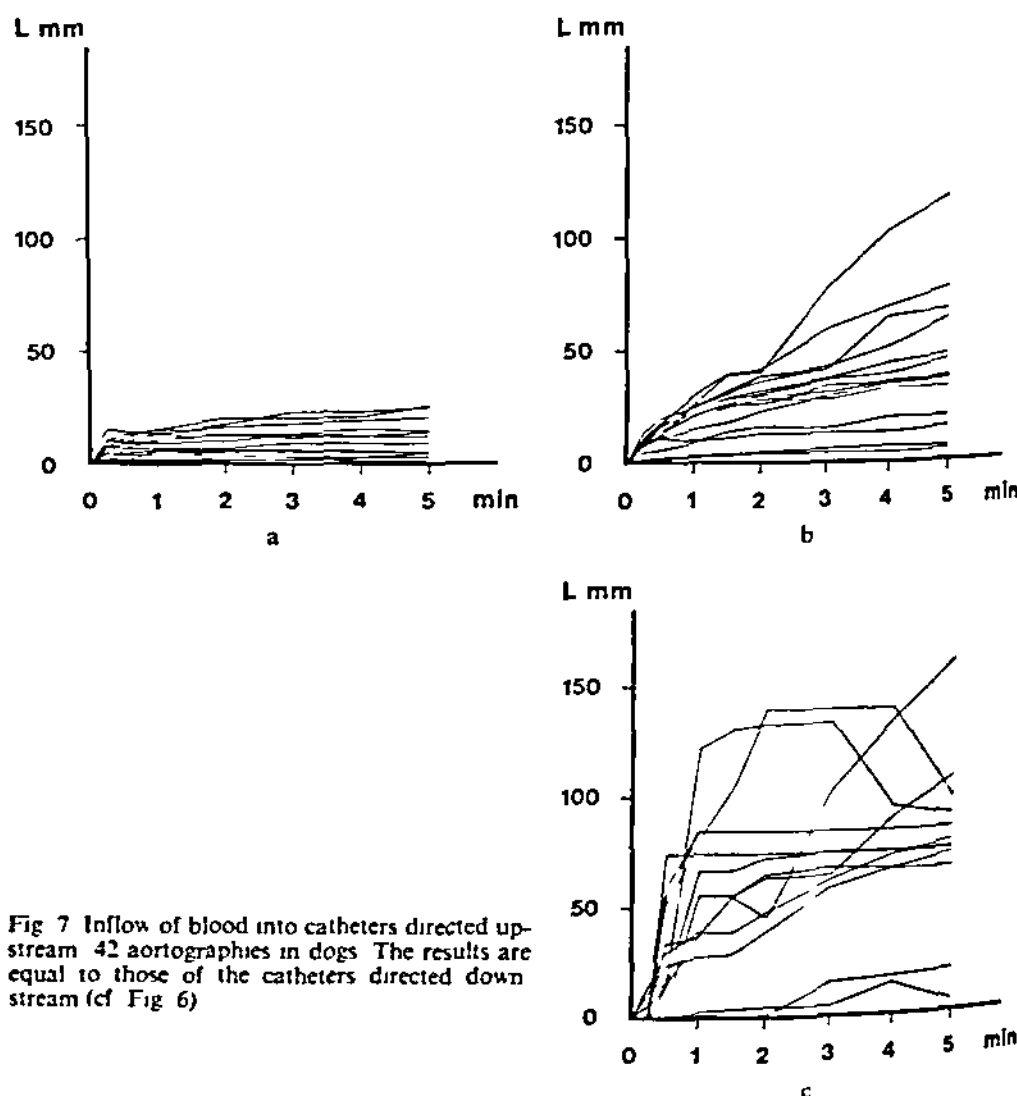


Fig 7 Inflow of blood into catheters directed upstream 42 aortographies in dogs The results are equal to those of the catheters directed down stream (cf Fig 6)

an embolus The amount of thrombus formation on the inner aspect of the catheter is supposed to be proportional to the length of the blood column and to be related to the exposure time In the present investigation contrast medium was used as catheter flush fluid because it offered a suitable way to demonstrate the length of the blood column (L) with roentgenologic technique The layer of blood column was easy to distinguish from the contrast medium because of the differences in density between the two fluids In the carotid angiographies the recording of blood inflow into the catheters was limited to one minute because of ethical considerations The interval 1 to 5 min was recorded in aortographies in dogs These latter examinations also made it possible to analyze the influence on the inflow using 2 catheters positioned upstream and downstream under controlled haemodynamic conditions An adequate circula

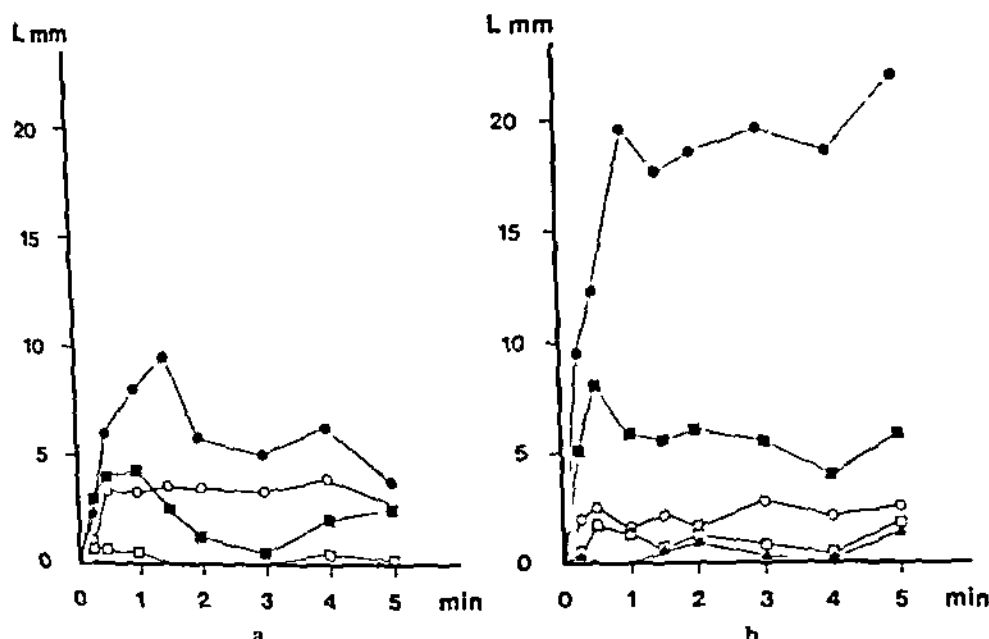


Fig 8 Inflow of blood into intra aortic catheters in dogs The catheters were flushed continuously with contrast medium delivered at the following flow velocities ● 0 03 ml/min ■ 0 08 ml/min ○ 0 20 ml/min □ 0 35 ml min ▲ 0 50 ml min With constant flow velocity of ≥ 0 35 ml/min there was no blood inflow in catheters directed downstream (a) and with ≥ 0.50 ml min no blood inflow when directed upstream (b)

tion was maintained during each separate examination both in the carotid angiographies and in the aortographies as indicated by recordings of blood pressure cerebral circulation time and aortic blood flow The injection of contrast medium in the dogs was followed by a reduction of blood pressure and an increase in blood flow secondary to the effect on the peripheral circulation (HILAL 1966 LINDGREN et coll 1967 1968) The significance of this phenomenon on admixture of blood into the catheters is uncertain but the haemodynamic effects were slight and presumably could have only minor influence on the results In the common carotid angiographies blood pressure and blood flow was not continuously registered but the same reaction after contrast medium injection was supposed to occur In the present investigation the different hydrodynamic situations around the catheter tip directed downstream and upstream did not influence the blood inflow into the catheter

Contrast medium has a higher density than blood Consequently the contrast medium should leak out of the catheter lumen and be replaced by blood more rapidly when the catheter tip is directed downward than upward This was confirmed in all experiments with the tap closed

A gas bubble in a fluid filled system can be compressed and decompressed by pressure variations An intra arterial catheter in communication with a syringe with an air bubble could therefore facilitate a pulsative movement of the catheter fluid

synchronously with the blood pressure variations This may explain the large exchange between contrast medium and blood when the catheter tap remained open after the injection These experiments imitate the situation present immediately following injection of contrast medium by an injector which happens to contain an air bubble

If no blood is allowed to enter the catheter lumen one source of embolic complication can be avoided A constant flush speed of 0 5 ml/min or more irrespective of the direction of the catheter tip prevented inflow of blood into the catheters

The evaluation of the present data is limited to only two types of catheters both without side holes and to contrast medium being used as flush fluid Experiments with other catheters and other flush fluids may give modified results

Acknowledgements

We are indebted to Docent Anders Moller who initiated the clinical part of the investigation

SUMMARY

Inflow of blood into intra arterial catheters following injection of contrast medium into the common carotid artery in patients and into the aorta in dogs is investigated Influence of form and orientation of the catheter in the vessel and the effect of constant flushing are determined as well

ZUSAMMENFASSUNG

Der Blutstrom von Blut in intraarteriellen Kathetern wurde im Anschluss an eine Injektion von Kontrastmittel in die Arteria carotis communis bei Patienten und in die Aorta bei Hunden untersucht Der Einfluss der Form und der Lage des Katheters in dem Gefäss und der Effekt von konstanter Spulung wurden ebenfalls festgestellt

RÉSUMÉ

Les auteurs ont étudié sur la carotide primitive de malades et sur l aorte de chiens la pénétration de sang dans les cathéters intraartériels après injection de moyen de contraste Ils ont déterminé l influence de la forme et de l orientation du cathéter dans le vaisseau et aussi l effet d une perfusion constante

REFERENCES

FORMANEK G FRECH R S and AMPLATZ K Arterial thrombus formation during clinical percutaneous catheterization Circulation 41 (1970) 833

GREITZ T A radiologic study of the brain circulation by rapid serial angiography of the carotid artery Acta radiol (1956) Suppl No 140

HAWKINS I F and HERBERT L Contrast material used as a catheter flushing agent A method to reduce clot formation during angiography Radiology 110 (1974) 351

HILAL S Hemodynamic response in the cerebral vessels to angiographic contrast media Acta radiol Diagnosis 5 (1966) 211
— Hemodynamic changes associated with the intra arterial injection of contrast media Radiology 86 (1966) 615
JACOBSSON B and SCHLOSSMAN D Angiographic investigation on formation of thrombi on vascular catheters Radiology 93 (1969) 355
KOTTKE B A FAIRBAIRN J F and DAVIS G D Complications of aortography Circulation 30 (1964) 843
LANG E K A survey of the complications of percutaneous retrograde arteriography Radiology 81 (1963) 257
LINDGREN P and TORNELL G Blood circulation during and after peripheral arteriography Acta radiol 49 (1958) 425
— SALTZMAN G F and TÖRNELL G Vascular effects of metrizoate compounds Isopaque Na and Isopaque Na/Ca/Mg Acta radiol (1967) Suppl No 270 p 44
— — — Vascular reaction to water soluble contrast media Acta radiol Diagnosis 7 (1968) 152
SCHLOSSMAN D Thrombogenic properties of vascular catheter materials in vivo Acta radiol Diagnosis 14 (1973) 97

FROM THE DEPARTMENTS OF RADIOLOGY AND PATHOLOGY VANDERBILT UNIVERSITY HOSPITAL NASHVILLE TENNESSEE 37232 USA

MORPHOLOGIC SEQUELAE TO CONTRAST MEDIUM DEPOSITS IN THE KIDNEY

An experimental investigation in the rabbit

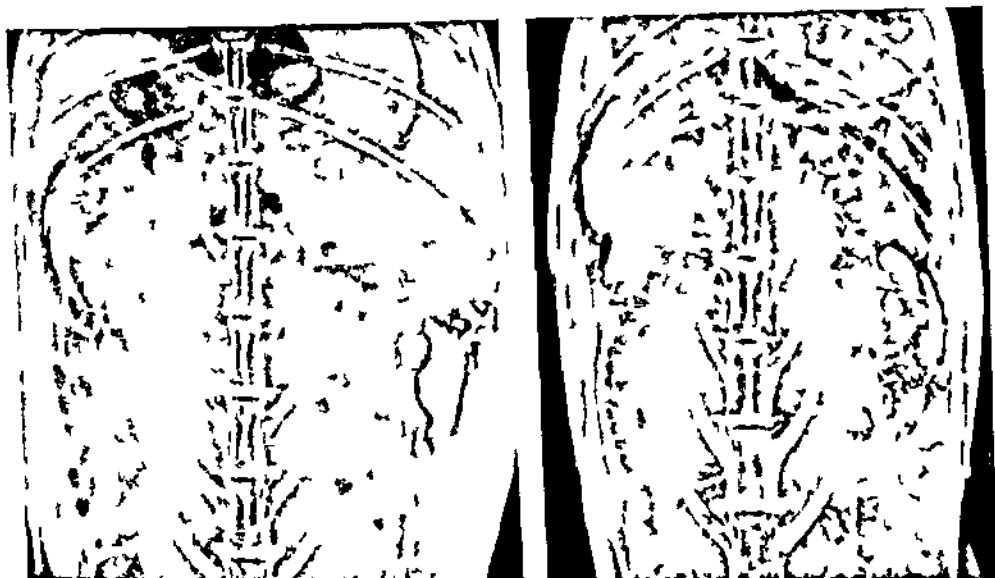
L EKELUND M HOLSCHER and G NOVAK

Since VESTBY s original report on the treatment of renal cysts by local Pantopaque instillation this method has received continued support in the literature (VESTBY 1967 1971 ROSS et coll 1973 RASKIN et coll 1975) Recently however the rationale for such treatment was questioned and it was pointed out that animal experiments or clinical experiences clearly demonstrating long term safety for renal or perirenal tissue so injected is unavailable (MINDELL 1976) The present investigation was undertaken in an attempt to answer this question

Material and Method

Nineteen rabbits weighing from 2 2 to 3 8 kg were used General anesthesia was provided by the intramuscular administration of ketamine hydrochloride (Bristol Laboratories) 100 mg/kg Percutaneous punctures of both kidneys were performed with a 21 gauge (0 7 mm) needle (the rabbit s kidneys are easily located by manual palpation) Pantopaque (iophendylate) in doses from 0 05 to 0 5 ml was then injected into the left kidney and the water soluble contrast medium Vascoray (meglumine sodium iothalamate Mallinckrodt Inc) in corresponding doses into the right kidney

Submitted for publication 28 October 1977



Xerograms obtained from 2 different rabbits for proper localization of contrast media within the kidneys Pantopaque has been injected into the left and Vascoray into the right kidney

Xerography was then performed for confirmation of proper localization of the contrast media within the renal parenchyma (Figure) In a few rabbits the contrast medium was initially injected extrarenally and in those cases reinjection was performed Two rabbits were kept as controls and no renal punctures were performed in these animals The rabbits were then killed at various time intervals following the injection of contrast medium Thus 6 animals were killed 24 hours post injection 4 rabbits two weeks post injection one rabbit one month post injection and 6 animals two months following injection of contrast medium into the kidneys At autopsy a thorough macroscopic examination of the kidneys was performed and representative areas of each kidney fixed in 10° buffered formalin Hematoxylin eosin stained sections were prepared by conventional methods from paraffin embedded tissue The kidneys from the two control animals were treated the same way One of the rabbits developed temporary hematuria following the renal puncture No other complications were evident and all animals survived the experimental period

Results

No significant abnormalities were found in the 4 control kidneys (Table) Five of the 6 rabbits that were killed 24 hours post injection had macroscopic subcapsular renal hematomas of varying size In 6 of these kidneys microscopy revealed hemorrhagic needle tracts with a few heterophilic cells lining the edge of the hemorrhagic zones No necrosis of adjacent parenchyma was observed Four

Table

Macro and microscopic findings in the present series

No of kidneys	Time interval	Pathology		
		Pantopaque	*Vascoray*	*Control*
4	—	—	—	Normal
12	24 hours	Hematoma (3)	Hematoma (3)	
8	2 weeks	Hematoma (2)	Hematoma (1)	
2	4 weeks	Small hematoma (1)	—	
12	2 months	Focal scarring (1)	Focal scarring (1)	

rabbits were killed 2 weeks post injection Two of these rabbits had been injected with 0 05 ml of Pantopaque and Vascoray respectively and 2 with 0 1 ml In 3 kidneys small subcapsular hematomas were macroscopically evident Microscopy of the kidneys in this group was otherwise unremarkable

The rabbit killed one month post injection had a small hematoma in the lower pole of the left kidney which had been reinjected with Pantopaque Otherwise no microscopic abnormalities could be revealed Out of the 12 kidneys examined 2 months post injection 2 kidneys—one injected with 0 5 ml Vascoray and one with 0 1 ml Pantopaque—displayed focal scarring at microscopy The scarring extended from the capsule down to the medulla A mild infiltration of lymphocytes and mononuclear phagocytic cells was also evident in the affected area The remaining parts of the kidneys were unremarkable and so were the remaining 10 kidneys belonging to this group

Discussion

Percutaneous renal cyst puncture is a well established method (LINDBLOM 1946 1952 WAHLQVIST & GRUMSTEDT 1966 VESTBY 1967 1971 LANG 1973 ROSS et coll RASKIN et coll) RASKIN et coll reported a 50 per cent or more decrease in cyst volume in 68 per cent of 56 cysts after Pantopaque instillation while only 13 per cent of a control group of 15 renal cysts had a decrease of 50 per cent or more in cyst volume WAHLQVIST & GRUMSTEDT however noticed decrease in cyst size in 46 per cent of 52 cysts examined by water soluble contrast medium and then aspirated These authors however suggested that the reduction in size of cysts so treated may be only temporary

Many cysts are incidentally detected in patients that are asymptomatic regarding the cyst (AINSWORTH & VEST 1951 GERNERT et coll 1968 LANG 1973) These facts lead SHERWOOD & STEVENSON (1971) to consider an accurate differentiation from carcinoma to be the vital aspect of renal cyst disease The therapeutic effect of Pantopaque is believed to be due to inflammation and sclerosis of the cyst wall

(RASKIN et coll) Pathologic examination of one polycystic kidney 4 months after cyst puncture demonstrated that in the one cyst in which Pantopaque had been injected the wall was thickened with inflammatory changes (VESTBY 1967) Toxic effects of Pantopaque on the central nervous system have been well documented (JAEGER 1950 SEHGAL et coll 1962 HOWLAND & CURRY 1966) With this background MINDELL recently pointed out that clear demonstration of long term safety for renal or perirenal tissues injected with Pantopaque is unavailable and the question was raised why to use an even theoretically toxic agent to treat a basically innoccuous condition

It seems hard to understand why investigations of possible morphologic sequelae to Pantopaque instillation into the renal parenchyma have not been previously under taken Contrast medium occasionally leaks into the renal parenchyma in connection with cyst punctures Thus in a review of the complications from renal cyst puncture LANG recently reported extravasation of contrast medium in 11 out of 630 cases (1 7%) Therefore it was considered of interest to try to find out what histologic abnormalities if any, might occur following the intraparenchymatous injection of Pantopaque and a commonly used water soluble contrast medium (Vascoray) The basic reason for choosing rabbits for these experiments was the ease with which the kidneys are manually palpated thus enabling percutaneous renal puncture

From the results it is concluded that only slight cellular reaction appears to occur from direct injection of Pantopaque and Vascoray into the kidney of the rabbit Hemorrhage most often noted 24 hours post injection is certainly related to needle trauma The scarring observed in 2 kidneys 2 months post injection (one injected with Pantopaque and one with Vascoray) was well confined to an area somewhat smaller than that observed in the initial lesions Since this focal scarring was observed in 2 of the animals subjected to puncture and not in the controls it was considered as related to the procedure and that it did not represent abnormalities sometimes associated with pyelonephritis This is also in good agreement with the results of DITSCHERLEIN (1969) who found that a small scar developed 4 to 6 weeks following puncture of the kidney in the rabbit Therefore it seems reasonable to assume that the risk of causing renal parenchymatous injury by using Pantopaque in connection with renal cyst purcture is small However it should be stated that it is not the purpose of the present report to make any comments upon the clinical valu of Pantopaque in the management of renal cysts

SUMMARY

Various doses of Pantopaque and Vascoray were injected percutaneously into the kidneys in 17 rabbits Histologic examination of the kidneys at different time intervals following the injection demonstrated only slight injury to the renal parenchyma which could be related to the contrast media Therefore it seems reasonable to assume that the risk of causing renal damage by using Pantopaque in connection with renal cyst puncture is small

ZUSAMMENFASSUNG

Verschiedene Dosen von Pantopaque und Vascoray wurden perkutan in die Nieren von 17 Kaninchen injiziert Die histologische Untersuchung der Nieren zu verschiedenen Zeit intervallen im Anschluss an die Injektion zeigte eine nur leichte Schädigung des Nieren parenchyms welche zu den Kontrastmitteln relatiert werden konnte Es ist deshalb anzu nehmen dass das Risiko durch die Anwendung von Pantopaque im Zusammenhang mit einer Punktion einer Nierenzyste eine Nierenschadigung hervorzurufen gering ist

RESUME

Des doses variables de Pantopaque et de Vascoray ont eté injectées par voie percutanée dans les reins de 17 lapins L examen histologique des reins à différents intervalles de temps apres l injection n a mis en évidence que de discretes lésions rénales pouvant etre attribuées aux moyent de contraste C est pourquoi il parait raisonnable de supposer que le risque de causer une lesion renale en utilisant le Pantopaque au cours de la ponction des kystes rénaux est petit

REFERENCES

AINSWORTH W L and VEST S A The differential diagnosis between renal tumor and cysts *J Urol* 66 (1951) 740

DITSCHERLEIN G Morphologische Folgen der Nierenpunktion Tierexperimentelle und humanpathologische Befunde Springer Verlag Berlin Heidelberg New York 1969

GERNERT J E STEIN J and BISCHOFF A J Solitary renal cysts Experience with *100 cases J Urol 100 (1968) 251*

HOWLAND W J and CURRY J L Experimental studies of Pantopaque arachnoiditis I Animal studies Radiology 87 (1966) 253

JAEGER R *Irritating* effect of iodized vegetable oils on brain and spinal cord when divided into small particles Arch Neurol Psychiat 64 (1950) 715

LANG E K Roentgenographic assessment of asymptomatic renal lesions Radiology 109 (1973) 257

— Renal cyst puncture and aspiration A survey of complications Amer J *Roentgenol* 128 *(1977)* 723

LINDBLOM K Percutaneous puncture of renal cysts and tumors Acta radiol 27 (1946) 66

— Diagnostic kidney puncture in cysts and tumors *Amer J Roentgenol* 68 (1952) 209

MINDELL H J On the use of Pantopaque in renal cysts Radiology 119 (1976) 747

RASKIN M M POOLE D O ROEN S A and VIAMONTE M JR Percutaneous *management of* renal cysts results of a four year study Radiology 115 (1975) 551

ROSS M M HALPERN M and MORROW J W *Evaluation of triple* contrast cyst aspiration in the management of renal masses J Urol 110 (1973) 490

SEHGAL A D GARDNER W J and DOHN D F Pantopaque arachnoiditis *Cleveland* Clin Quart 29 (1962) 177

SHERWOOD T and *STEVENSON J J* The management of renal masses *Clin Radiol* 22 (1971) 180

WAHLQVIST L and GRUMSTEDT B Therapeutic effect of percutaneous puncture *of simple* renal cyst Follow up investigation of 50 patients Acta chir scand 132 (1966) *340*

VESTBY G W Percutaneous needle *puncture of renal cysts* New method in therapeutic management Invest Radiol 2 (1967) 449

— Perkutane Behandlung von Nierenzysten Die Tripelkontrast oder *Pantopaque M* thode Acta radiol Diagnosis 11 (1971) 529

FROM THE DEPARTMENTS OF DIAGNOSTIC RADIOLOGY AND PHYSICAL MEDICINE UNIVERSITY HOSPITAL AND THE DEPARTMENT OF ANATOMY UNIVERSITY OF LUND S 2-I 85 LUND SWEDEN

MOVEMENTS IN THE SACROILIAC JOINTS DEMONSTRATED WITH ROENTGEN STEREOPHOTOGRAMMETRY

N EGUND T H OLSSON H SCHMID and G SELVIK

The first exact analysis of motions in the sacroiliac joints seems to have been performed by ZAGLAS (1851) From observations on a specimen he concluded that the sacrum rotated about a transverse axis enlarging and contracting the pelvic inlet and outlet diameters respectively on bending back the spine The axis of rotation was assumed to pass approximately through the second sacral vertebra DUNCAN (1854) further developed this description of sacral mobility as a nutation about a transverse axis The axis was from the morphology of the articular surfaces and the interosseous sacroiliac ligaments deduced to pass through the iliac tuberosity Either of these locations somewhere in the auricular surface or the iliac tuberosity have been advocated by most later authors (e g MEYER 1878 KLEIN 1891) On the other hand WEISL (1955) located from constructions on roentgen films the intersection of the axis of rotation with the sagittal plane more anteriorly and caudally

The early interest in mobility of the pelvic articulations was evoked by obstetricians who desired to assess the mouldability of the pelvic girdle during parturition relating changes in inlet and outlet diameters to changes in body position (WALCHER 1889 BONNAIRE & BUÉ 1899) later radiography was used (SCHUBERT 1929 BORELL & FERNSTROM 1957)

The relation of low back gluteal or hip pain to disorders of the mobility in the sacroiliac joint is another aspect which is not well investigated GOLDTHWAIT &

Submitted for publication 6 December 1977

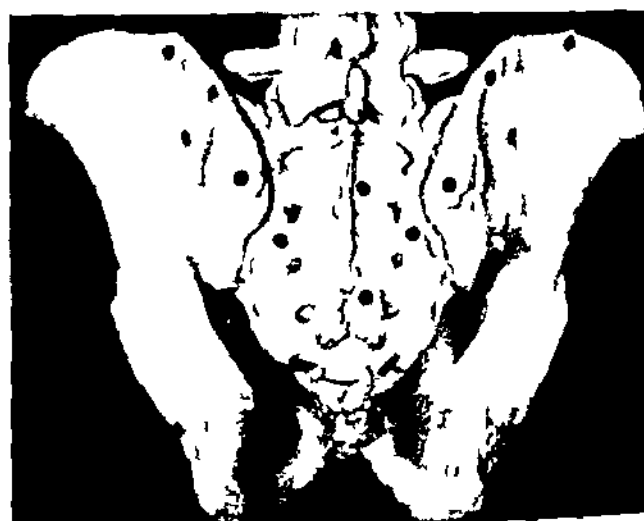


Fig 1 The intended locations of the 4 markers in each iliac bone and the sacrum

OSGOOD (1905) seem to be the first to correlate such pain to sacroiliac joint affections in the absence of pregnancy and occurring both in men and in women To disclose unequal mobility in the two sacroiliac joints CHAMBERLAIN (1930) determined the height differences between the 2 pubes on a p films exposed with the standing on either leg Later authors have, with a view to applications in orthopaedics discussed the sacroiliac joint mobility (GRAY 1938 MENNELL 1952 COLACHIS et coll 1963) but they have not measured the mobility more in detail

With a newly developed roentgen stereophotogrammetric method (SELVIK 1974) it is possible to measure with high and well defined accuracy the movements in any joint Its applicability in measuring the movements in the sacroiliac joints in all 3 dimensions in the living subject has been investigated to ascertain if manual findings of hypermobility or hypomobility can be objectively confirmed

Methods

Roentgen stereophotogrammetry was used to determine the movements between the sacrum and the hip bones The analysis proceeded in 2 steps The first was a determination of the three-dimensional coordinates of indicators in the skeletal parts at various body positions The second step was a purely mathematical analysis of the coordinates thus obtained giving the motion expressed in rotation angles and translations between the different positions

In order to obtain well defined measurement points on the films tantalum balls 0 8 mm in diameter were inserted into the sacrum and the two iliac bones. The implantation was performed under fluoroscopy and local anesthesia using the instrument and technique of ARONSON et coll (1974) At least 3 indicators not on a line must be introduced in each skeletal part to follow its rigid body motion but in order to obtain a higher precision 4 indicators were used in the present experiments.

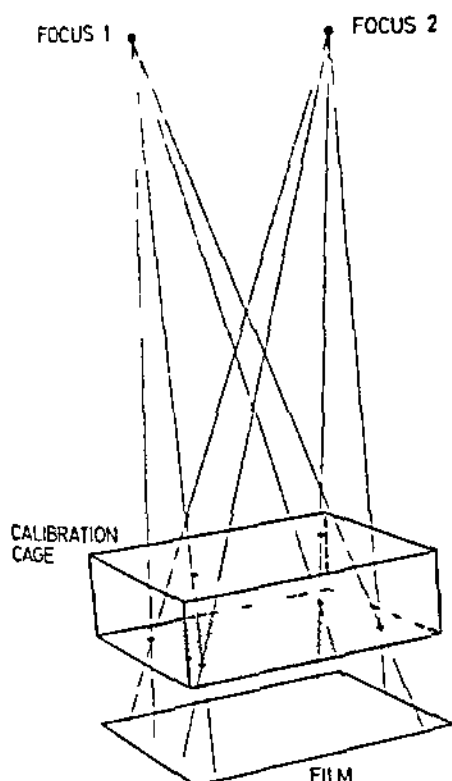


Fig 2 Radiography of the calibration cage The calibration markers are located in 2 planes and the central area (stippled) between the markers in the bottom plane is sheltered with a lead sheat The distance between the foci is about 700 mm, and the film focus distance about 1 200 mm The patient is exposed in the central area of the film with the calibration cage removed but without moving the film or the foci

This also gives the possibility to exclude a loose indicator In the iliac bones the indicators were placed in the dorsal part of the crests and the adjoining gluteal surface In the sacrum two indicators were placed at the base of the median sacral crest and two more laterally between the dorsal sacral foramina or in the lateral sacral crests (Fig 1)

The radiography was performed using 2 tubes about 700 mm apart exposing simultaneously a double image on one film On the same film before or after the patient was examined a glass calibration cage with reference tantalum indicators was exposed (Fig 2) The three dimensional positions of these calibration markers were known with high accuracy and they defined a laboratory coordinate system Their images were situated on 2 strips one on each side of the patient image which was protected by a lead sheet during the exposure of the calibration cage After that the two dimensional film coordinates of the patient and calibration cage indicators have been measured The known coordinates of the latter were used to calculate the position of the film and the foci Then the three-dimensional coordinates of the patient s markers were determined (SELVIK 1974) The registration of film coordinates and the computations were automatized making the coordinate calculations fast and simple

In the second step a computer program for analysis of rigid body kinematics was

utilized First the validity of the rigid body model for the indicators in each skeletal part was tested A parameter the mean error of rigid body fitting e_{rb} was calculated This is the mean distance (error) between an indicator displaced in a rigid body motion compared to its actual motion (SELVIK 1974 p 117) Then the rotations about and the translations along the 3 coordinate axes for a segment in relation to another segment were calculated Only these relative motions are of interest The computer program mathematically puts the reference segment in the same position at different examinations making identical orientation of the reference segment unnecessary Besides this Eulerian representation of the motion its parameters when described as a rotation about and translation along an axis the screw axis were calculated This screw axis description according to CHASLES gives the position of an axis most resembling the uniquely defined axis of rotation for a pure rotation (cf SELVIK 1974)

All films were remeasured once to provide tests of the precision of the method The reason for remeasuring the recordings of all patients was that the marker location on the iliac crests could lead to cases with indicators lying close to a straight line This would lead to very different precision of the calculated movements

Examination scheme The indicated part of the pelvis was exposed in the following body positions (1) Supine (2) prone (3) prone with manual pressure in ventral direction against the lower part of the sacrum (4) standing erect (5) standing on the right leg (6) standing on the left leg and (7) standing with a maximum lordosis

The motion between any of these positions can be calculated but only the 6 following movements are presented where e g 1→4 means the motion from position 1 to position 4 From lying positions A = 1→4 B = 1→2 C = 2→3 From standing erect D = 4→5 E 4→6 F = 4→7

This terminology movements A B C D E and F will be used in the following

Notations In the reference positions i e in positions 1 2 and 4 the patient was positioned at the roentgen examination so that the main axes of the patient are approximately parallel to the coordinate axes determined by the calibration markers. The following notations are used x axis Transverse axis positive direction to the left y axis Frontal (longitudinal) axis positive direction upwards and z axis Sagittal axis positive direction forwards

As the calibration cage cannot be turned upside down the original directions of the x and z axes must be reversed in the prone (2) position The positive rotation about a coordinate axis is here defined as that of a right handed screw pointing in the positive direction of the axis A negative rotation is in the opposite direction With this definition a positive value of a rotation angle can be considered as follows for the sacrum and for the left ilium in relation to the right

Positive x rotation The sacral promontory moves forwards-downwards The anterior superior iliac spine moves forwards

Table 1

The mean errors of rigid body fitting for the markers in the skeletal parts indicated. Letters A B C D E F refer to the motions analysed. The measurement error is computed from seven double evaluations and is given as the mean value and the standard deviation. The unit is μm

	A	B	C	D	E	F	Measurement error ±SD
Case 1							
Right ilium	56	139	97	55	61	128	45 ± 22
Left ilium	30	156	129	44	39	44	56 ± 25
Sacrum	101	141	161	51	50	66	54 ± 30
Case 2							
Right ilium	90	75	58	101	60	131	70 ± 28
Left ilium	39	117	49	31	68	40	36 ± 24
Sacrum	118	101	70	83	57	135	72 ± 17
Case 3							
Right ilium	48	63	26	27	28	61	29 ± 18
Left ilium	37	164	66	37	52	80	48 ± 33
Sacrum	71	70	34	62	88	78	48 ± 30
Case 4							
Right ilium	45	104	190	31	56	77	45 ± 18
Left ilium	93	104	148	54	85	64	75 ± 47
Sacrum	59	107	59	64	90	68	68 ± 31

Positive y rotation The sacral pelvic surface rotates to the left. The angle in the transverse plane between the hip bones decreases.

Positive z rotation The sacral base moves to the right. The angle in the frontal plane between the hip bones decreases.

In this description it is assumed that the rotations occur about axes through the center of the bone.

Material

Four cases have been examined, 3 of them women. According to the clinical examination hypermobility in one of their sacroiliac joints was suggested. The one male patient had possibly a decreased mobility in the left sacroiliac joint.

Case 1 Woman, 45 years old, with low back pain and sciatica for several years. Long periods of difficulties in walking and pain in the left hip, gluteal and inguinal regions. No abnormality at roentgen examination of the lumbar spine, hip and sacroiliac joints. Pathologic findings at manual tests of the left sacroiliac joint, including signs of hypermobility. Spontaneous locking of the same joint had also occurred in periods just before the stereophotogrammetric examination.

utilized First the validity of the rigid body model for the indicators in each skeletal part was tested A parameter the mean error of rigid body fitting e_{rb} was calculated This is the mean distance (error) between an indicator displaced in a rigid body motion compared to its actual motion (SELVIK 1974 p 117) Then the rotations about and the translations along the 3 coordinate axes for a segment in relation to another segment were calculated Only these relative motions are of interest The computer program mathematically puts the reference segment in the same position at different examinations making identical orientation of the reference segment unnecessary Besides this Eulerian representation of the motion its parameters when described as a rotation about and translation along an axis the screw axis were calculated This screw axis description according to CHASLES gives the position of an axis most resembling the uniquely defined axis of rotation for a pure rotation (cf SELVIK 1974)

All films were remeasured once to provide tests of the precision of the method The reason for remeasuring the recordings of all patients was that the marker location on the iliac crests could lead to cases with indicators lying close to a straight line This would lead to very different precision of the calculated movements

Examination scheme The indicated part of the pelvis was exposed in the following body positions (1) Supine (2) prone (3) prone with manual pressure in ventral direction against the lower part of the sacrum (4) standing erect (5) standing on the right leg (6) standing on the left leg and (7) standing with a maximum lordosis

The motion between any of these positions can be calculated but only the 6 following movements are presented where e g 1→4 means the motion from position 1 to position 4 From lying positions A = 1→4 B = 1→2 C – 2→3 From standing erect D = 4→5 E = 4→6 F = 4→7

This terminology movements A B C D E and F will be used in the following

Notations In the reference positions i e in positions 1 2 and 4 the patient was positioned at the roentgen examination so that the main axes of the patient are approximately parallel to the coordinate axes determined by the calibration markers The following notations are used x axis Transverse axis positive direction to the left y axis Frontal (longitudinal) axis, positive direction upwards and z axis Sagittal axis positive direction forwards

As the calibration cage cannot be turned upside down the original directions of the x and z axes must be reversed in the prone (2) position The positive rotation about a coordinate axis is here defined as that of a right handed screw pointing in the positive direction of the axis A negative rotation is in the opposite direction With this definition a positive value of a rotation angle can be considered as follows for the sacrum and for the left ilium in relation to the right

Positive x rotation The sacral promontory moves forwards-downwards The anterior superior iliac spine moves forwards

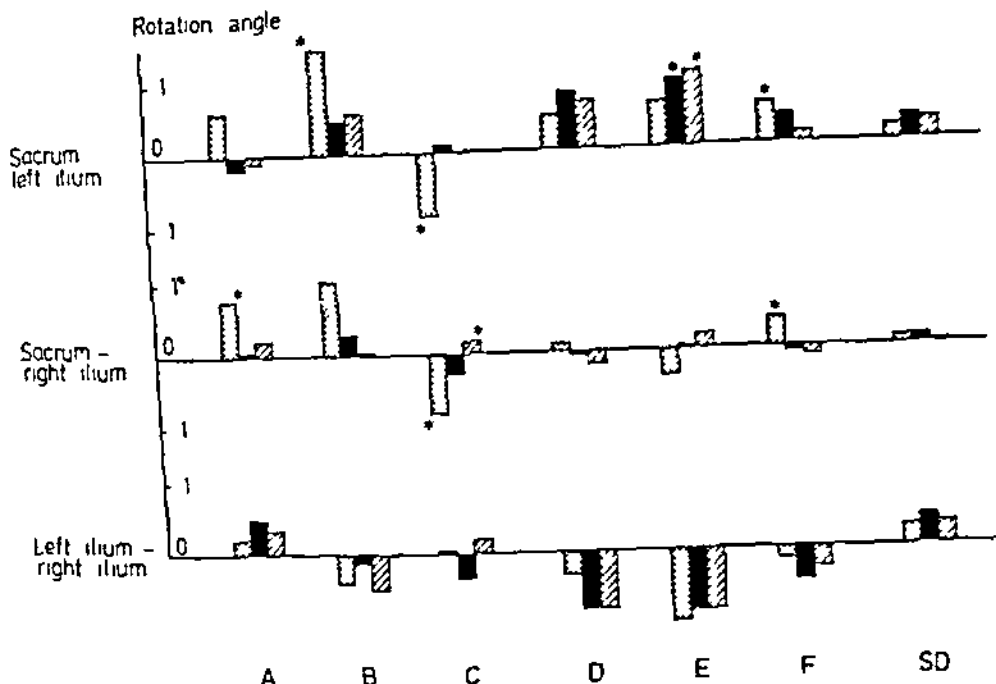


Fig. 3 The investigation of Case 1 The following movements are presented A = supine to standing erect B = supine to prone C = prone to prone with manual pressure in ventral direction against the lower part of the sacrum D = standing erect to standing on the right leg, E = standing erect to standing on the left leg and F = standing erect to standing with a maximum lordosis The rotations are given about a transverse x axis a frontal (longitudinal) y axis and a sagittal z axis The standard deviations of the movements given are also shown and the significance of a movement is indicated with stars Almost significant (95) significant (99) * highly significant (99 9)

calculated when comparing relative motions are presented though these could also have been obtained from the values for separate segments

The rotations about the 3 coordinate axes are presented for each patient in Figs 3 to 6 The mean values of two evaluations are given and the standard deviations are corrected for this The translations are only briefly discussed the reason being that the translation varies so much over the rather vast bones that any measure of it, e g the translation of the center of gravity of the indicators only gives partial information

Case 1 In the movements from lying positions the sacrum mainly rotates about a transverse axis From supine to standing and to prone positions the rotation is forwards with maximal values about 1 while in the sacroiliac test with manual pressure against the lower part of the sacrum the rotation was backwards (Fig 3) In the two asymmetric tests D and F (standing on one leg) the total rotations and translations for the sacrum in relation to the left ilium were in the mean 1 3 and 1 0 mm while the corresponding movements in relation to the right ilium were 0 3

Fig 4 Case 2 (see legend of Fig 3)

Fig 5 Case 3 (see legend of Fig 3)

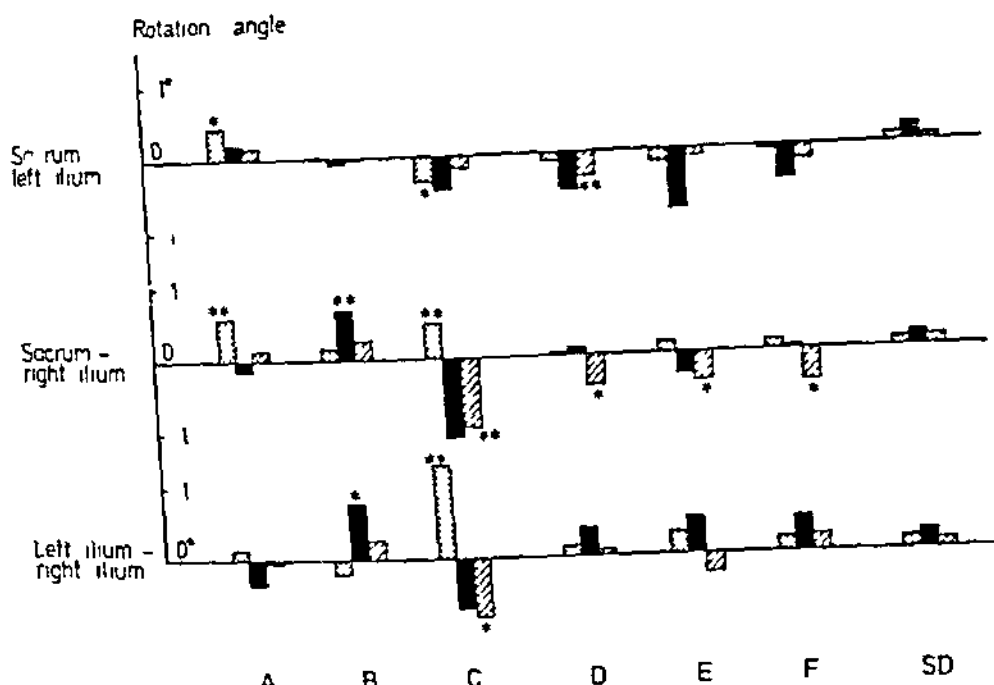


Fig. 6 Case 4 (see legend of Fig 3)

and 0.2 mm These differences between the left and right sides are almost significant both for rotations and translations

Case 2 The greatest movements from lying positions occurred in the manual sacroiliac test giving a rotation of the sacrum of approximately 2 about the transverse axis (Fig 4) In the tests from standing positions four significant (**) rotations are noticed in the right sacroiliac joint but none in the left In the 2 tests on one leg the total rotations and translations for the sacrum in relation to the left and right ilium were in the mean 0 5 0 4 mm and 1 2 1 1 mm respectively The differences are not significant

Case 3 Consistent rotations of the sacrum about the transverse axis from lying positions amounting to 2 from supine to standing (Fig 5) No significant rotations from standing position to standing on one leg Two significant rotations in the left sacroiliac joint at extending the back (motion F) and several significant rotations between the two iliac bones The rotations between the hip bones about the sagittal axis do approximate the iliac crests in the movements from supine to standing and to prone and increase the angle in the frontal plane between the hip bones in the other cases

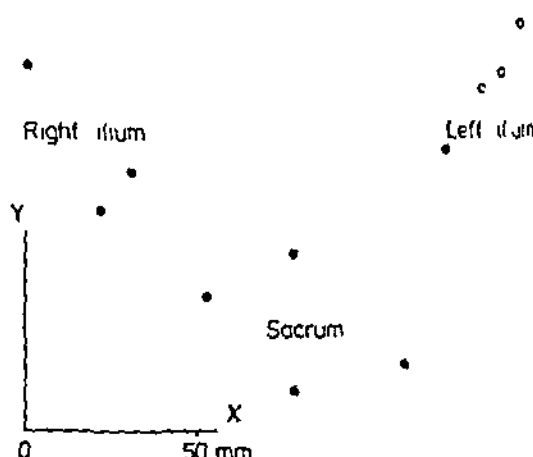


Fig 7 The actual positions of the markers in Case 1 as projected orthogonally on the frontal plane

Case 4 Inconsistent rotations of the sacrum at the lying tests (Fig 6) A marked rotation between the two iliac bones at the manually provoked motion C Small movements at the standing tests with only one significant (**) rotation angle

The intersections of the screw axes with the sagittal plane through the center of gravity of the indicators in the sacrum appear in Fig 8 Only the axes of the female patients 1–3 are presented The movements A B and C from lying positions resulted in a rotation of the sacrum mainly about a transverse axis The axes are those for the movement of the sacrum in relation to the left ilium but nothing in principle was different for the axes related to the right ilium

The variation of the distance between indicators in the left and right posterior superior iliac spines is shown in Fig 9 The distance changes given in relation to the supine position (position 1) vary They are small at most of the magnitude of 0 4 mm The precision in determining the distance is about 0 05 mm

Discussion

The mean errors of rigid body fitting (Table 1) indicate that in some movements a slight mobility between the indicators might have existed or that other method errors than imprecision in the measurements have been at hand However relating the size of the errors to that of the indicated area makes it plausible that the influence of method errors is not too important and it is only in some movements not of main interest that deviations from rigid body behaviour are evident

The precision of the rotation angles is higher for the sacrum than for the ilia bones (Table 2) Though only illustrated for Case 1 (Fig 7) in which the left ilium showed less precision in the determination of its rotation angles due to indicators lying close to a straight line the other cases of less precision can be related to the same cause As it is difficult to separate the iliac indicators more it is intended in the

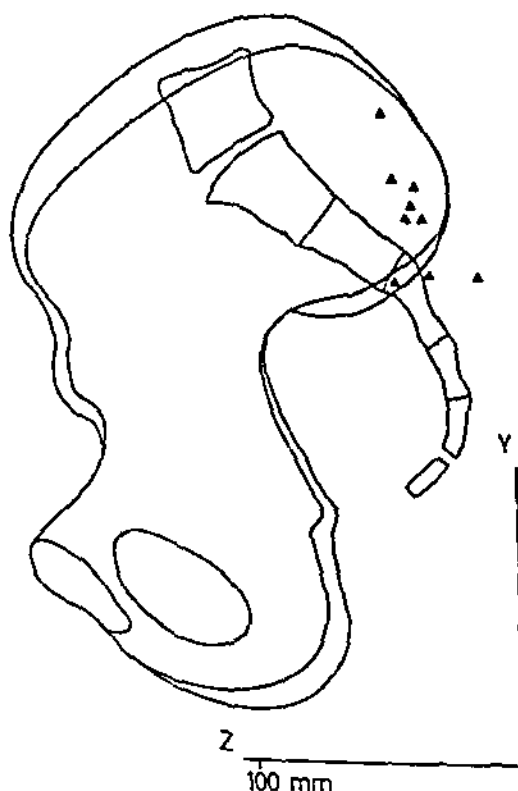


Fig 8 The intersections with the sagittal plane of the screw axes for the motions of the sacrum in the movements from lying positions for the 3 female cases The lateral film of the pelvis on which the intersections (filled triangles) are drawn is from Case 1

future to indicate the hip bone not only in the ilium but also in the ischial tuberosity and the pubic tubercle

The rotations in the 6 movements are at most of the magnitude of 2 In the movements from the lying positions the sacrum in the three female patients showed the nutatory motion already described by ZAGLAS The motion of the sacrum seems to be symmetric with respect to the two ilia in these cases Whether the supine standing supine *prone* or the provoked movement is the best to bring forth this nutatory movement cannot be concluded Due to limitations in laboratory space the optimum positional change *according* to ZAGLAS from maximum extension to maximum flexion was *not investigated* The asymmetric tests from standing to standing on either leg (CHAMBERLAIN) could only in part differentiate the mobility in the 2 sacroiliac *joints In* one patient the rotations and translations were almost significantly higher on the side with possible hypermobility In another patient there were more *significant* rotations on the corresponding side but in the other two patients the test was inconclusive The odd rotations related to the right ilium of Case 4 at the movement C might be due to a method error as indicated by the high value of rigid body *fitting of the* right ilium at this occasion The rotations found between the two iliac bones are mainly about a frontal or a sagittal axis The rotations about a sagittal axis associated with a nutation of the sacrum (Case 3) are similar to those

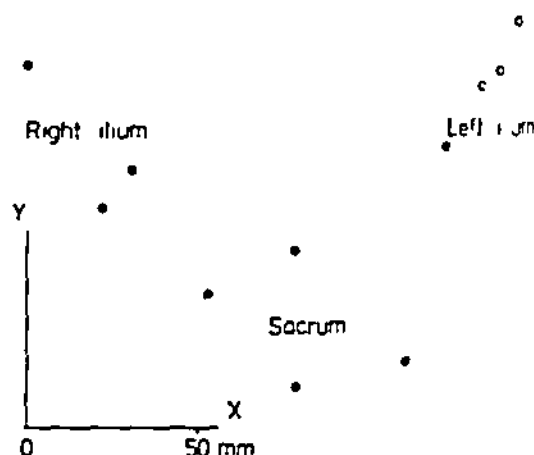


Fig 7 The actual positions of the markers in Case 1 as projected orthogonally on the frontal plane

Case 4 Inconsistent rotations of the sacrum at the lying tests (Fig 6) A marked rotation between the two iliac bones at the manually provoked motion C Small movements at the standing tests with only one significant (**) rotation angle

The intersections of the screw axes with the sagittal plane through the center of gravity of the indicators in the sacrum appear in Fig 8 Only the axes of the female patients 1–3 are presented The movements A B and C from lying positions resulted in a rotation of the sacrum mainly about a transverse axis The axes are those for the movement of the sacrum in relation to the left ilium but nothing in principle was different for the axes related to the right ilium

The variation of the distance between indicators in the left and right posterior superior iliac spines is shown in Fig 9 The distance changes given in relation to the supine position (position 1) vary They are small at most of the magnitude of 0 4 mm. The precision in determining the distance is about 0 05 mm

Discussion

The mean errors of rigid body fitting (Table 1) indicate that in some movements a slight mobility between the indicators might have existed or that other method errors than imprecision in the measurements have been at hand However relating the size of the errors to that of the indicated area makes it plausible that the influence of method errors is not too important and it is only in some movements not of main interest that deviations from rigid body behaviour are evident

The precision of the rotation angles is higher for the sacrum than for the iliac bones (Table 2) Though only illustrated for Case 1 (Fig 7) in which the left ilium showed less precision in the determination of its rotation angles due to indicators lying close to a straight line the other cases of less precision can be related to the same cause As it is difficult to separate the iliac indicators more it is intended in the

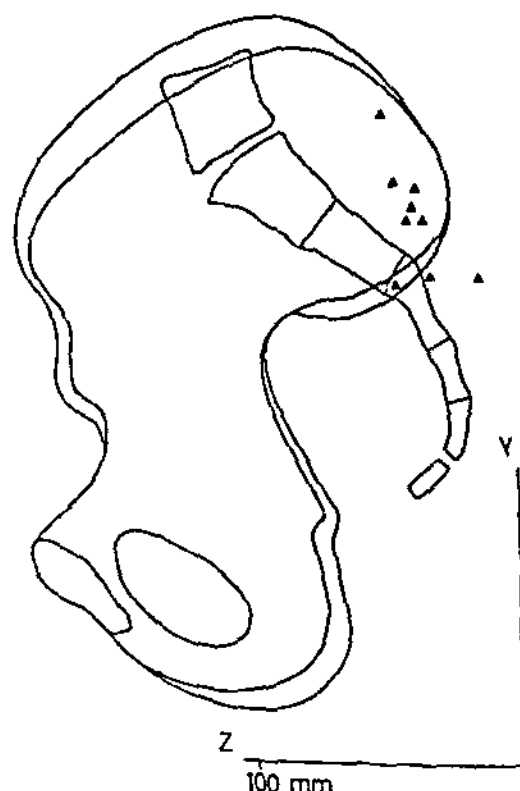


Fig 8 The intersections with the sagittal plane of the screw axes for the motions of the sacrum in the movements from lying positions for the 3 female cases The lateral film of the pelvis on which the intersections (filled triangles) are drawn is from Case 1

future to indicate the hip bone not only in the ilium but also in the ischial tuberosity and the pubic tubercle

The rotations in the 6 movements are at most of the magnitude of 2 In the movements from the lying positions the sacrum in the three female patients showed the nutatory motion already described by ZAGLAS The motion of the sacrum seems to be symmetric with respect to the two ilia in these cases Whether the supine standing supine prone or the provoked movement is the best to bring forth this nutatory movement cannot be concluded Due to limitations in laboratory space the optimum positional change according to ZAGLAS from maximum extension to maximum flexion was not investigated The asymmetric tests from standing to standing on either leg (CHAMBERLAIN) could only in part differentiate the mobility in the 2 sacroiliac joints In one patient the rotations and translations were almost significantly higher on the side with possible hypermobility In another patient there were more significant rotations on the corresponding side but in the other two patients the test was inconclusive The odd rotations related to the right ilium of Case 4 at the movement C might be due to a method error as indicated by the high value of rigid body fitting of the right ilium at this occasion The rotations found between the two iliac bone are mainly about a frontal or a sagittal axis The rotations about a sagittal axis associated with a nutation of the sacrum (Case 3) are similar to those

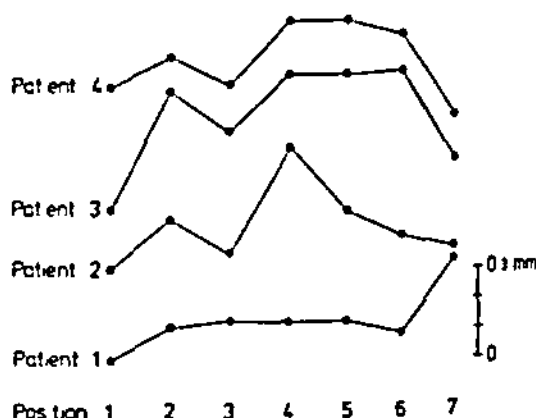


Fig 9 The variation of distance between the 2 posterior superior iliac spines in the 7 examination positions 1–7 given in relation to the first supine examination Distance increase is shown upwards

illustrated by FENEIS (1939) and KAPANDJI (1974) but already discussed by KLEIN and BONNAIRE & BUÉ as changes in the transverse diameters of the pelvic inlet and outlet The significance of the rotation about the frontal axis at extension for Cases 2 and 3 is unclear

The screw axes for the nutitional movements of the sacrum pass in the mean through the iliac tuberosity at the level of the second sacral vertebra confirming the concept of DUNCAN (1854) The variability between the patients has not been tried The positions found make a rotation in the sagittal plane as one movin the sacral promontory forwards downwards or the reverse true They also support the testing with manual pressure on the lower part of the sacrum

Depending on the location of the axis of rotation the gliding between the articular surfaces will vary for a given rotation angle with an increased distance leading to larger relative translations of the articular surfaces Thus the rotation angle of maximally 2 found will give a translation of $2 \times 50 \times 0.0175$ mm $\simeq$ 2 mm for a part of the surface with a distance of 50 mm to the axis (cf Fig 8) This gliding of the articular surfaces and its relation to joint pain and locking is a difficult but probably rewarding subject (GRAY 1938)

In contrast to the findings of MENNELL (1952) but in accordance with those of COLACHIS et coll (1963) it was found that the distance between the two posterior superior iliac spines changed very little with body position

Only individuals with a suggested sacroiliac affection have been examined Whether the movement in their sacroiliac joints was normal awaits further investigations of the variability among healthy individuals However even without such a comparison of the mobility before and after various treatments of an affected joint might be of value and with the higher precision of the method attained side differences might be more easily diagnosed

SUMMARY

Using a roentgen stereophotogrammetric method the three dimensional movements in the sacroiliac joints were quantified in 4 patients To provoke motion of the sacrum changes

between body positions and a test with manual pressure were used In tests with symmetric forces on the sacrum it in most cases rotated mainly about a transverse axis and at most approximately 2 The axis of rotation passed through the iliac bones mainly in the lower part of the iliac tuberosity The rotations between the iliac bones and the sacrum about any of the three main axes were determined with a precision in the mean of 0 2 The distance between the two superior posterior iliac spines varied at most 0 4 mm between seven different body positions

ZUSAMMENFASSUNG

Unter Verwendung einer rontgenstereophotogrammetrischen Methode wurden quantitativ die drei-dimensionalen Bewegungen in den Sacroiliaca Gelenken bei 4 Patienten fest gestellt Um eine Bewegung des Sacrums hervorzurufen wurden Veranderungen in der Korperlage und ein Test mit manuellem Druck verwendet Bei Testen mit symmetrischen Kraften auf das Sacrum rotierte dieses hauptsachlich um eine transversale Achse und maximal etwa 2 Grad Die Achse der Rotation ging durch das Os ilium hauptsächlich den unteren Teil der Tuberositas iliaca Die Rotationen zwischen Os ilium und Os sacrum wurden fur jede der drei Hauptachsen mit einer Genauigkeit von im Mittel 0 2 bestimmt Der Untersch ed zwischen den beiden Spinae iliacae posteriores superiores variierten maximal 0 4 mm bei 7 verschiedenen Korperpositionen

RESUME

L utilisation d une methode radiologique stereophotogrammetrique a permis de quantifier chez 4 malades les mouvements dans les trois dimensions des articulations sacro-iliaques Pour provoquer un mouvement du sacrum les auteurs ont utilise les modifications de positions du corps et un test avec une pression manuelle Dans les tests faits avec des forces symétriques sur le sacrum celui-ci dans la plupart des cas tourne surtout autour d un axe transversal et tout au plus d environ 2 degres L axe de rotation passe par les os iliaques principalement dans la partie inferieure de la tuberosite iliaque La rotation entre les os iliaques et le sacrum autour de chacun des 3 principaux axes a éte determinee avec une precision moyenne de 0 2 degres La distance entre les deux épines iliaques postéro superieures a variee au plus de 0 4 mm dans sept positions differentes du corps

REFERENCES

ARONSON A S HOLST L and SELVIK G An instrument for insertion of radiopaque bone markers Radiology 113 (1974) 733

BONNAIRE E et BUE V Influence de la position sur la forme et les dimensions du bassin Ann Gynec et d Obstet 52 (1899) 296

BORELL U and FERNSTROM I The movements at the sacro iliac joints and their importance to changes in the pelvic dimensions during parturition Acta obstet gynec scand 36 (1957) 42

CHAMBERLAIN W E The symphysis pubis in the roentgen examination of the sacroiliac joint Amer J Roentgenol 24 (1930) 621

COLACHIS S C WORDEN R F BECHTOL C O and STROHM B R Movement of the sacroiliac joint in the adult male A preliminary report Arch Phys Med 44 (1963) 490

DUNCAN J M The behaviour of the pelvic articulations in the mechanism of parturition Dublin quart J med Sci 18 (1854) 60

FENEIS H Experimentelle Beitrage zur Beckenmechanik Anat Anz Ergangzungsheft 88 (1939) 187

GOLDTHWAIT J E and OSGOOD R B A consideration of the pelvic articulations from an anatomical pathological and clinical standpoint Boston med surg J 152 (1905) 593

GRAY H Sacroiliac joint pain I The finer anatomy II Mobility and axes of rotation III Etiology diagnosis and treatment by manipulation Int Clin 2 (1938) 54

KAPANDJI I A The physiology of the joints Second edition Vol 3 p 65 Churchill Livingstone Edinburgh London 1974

KLEIN G Zur Mechanik des Ileosacralgelenkes Z Geburtsh Gynak 21 (1891) 74

MENNELL J The science and art of joint manipulation Vol 2 p 23 J & A Churchill London 1952

MEYER G H Der Mechanismus des Symphysis sacro iliaca Arch Anat Physiol 2 (1878) 1

VON SCHUBERT E Rontgenuntersuchungen des knochernen Beckens im Profilbild Exakte Messung der Beckenneigung beim Lebenden Zbl Gynak 53 (1929) 1064

SELVIK G A roentgen stereophotogrammetric method for the study of the kinematics of the skeletal system AV-centralen Lund 1974

WALCHER G Die Conjugata eines engen Beckens ist keine konstante Grosse sondern lasst sich durch die Korperhaltung der Trägerin verandern Cbl Gynäk 13 (1889) 892

WEISL H The movements of the sacro iliac joint Acta anat 23 (1955) 80

ZAGLAS reported by Gairdner and Barlow Mechanism of the pelvic articulations Month J med Sci 21 (1851) 289

FROM THE DEPARTMENTS OF DIAGNOSTIC RADIOLOGY (DIRECTOR PROFESSOR OLOF NORMAN) AND ORTHOPAEDICS (DIRECTOR PROFESSOR GÖRAN BAUER) UNIVERSITY HOSPITAL S-221 85 LUND SWEDEN

TALOFIBULAR COMPARTMENT OF THE ANKLE JOINT AFTER RECENT ANKLE SPRAIN

A LINDSTRAND W MORTENSSON and O NORMAN

Rupture of ankle ligaments is a frequent consequence of ankle sprain BROSTRÖM et coll (1965) proved the presence of ligament ruptures in 75 per cent of patients with recent ankle sprain—cases with fractures were excluded In 9 of 10 cases the anterior talofibular ligament was afflicted The rupture is invariably total (LINDSTRAND 1976) As this ligament substantially contributes to the stability of the joint (DEHNE 1933 CASTAING & DELPLACE 1972) inadequate healing of the rupture may result in persistent joint complaints Such sequelae occurred in about 20 per cent of conservatively treated cases (BROSTRÖM 1966 NIETHARD 1974 REICHEN & MARTI 1974)

The radiologic indication of rupture of the anterior talofibular ligament is indirect Capsular rupture always accompanies rupture of the ligament (BROSTRÖM et coll CEDELL 1967) which therefore is demonstrated indirectly at arthrography (BROSTRÖM et coll) At arthrography the findings may be erroneously considered normal (SPIEGEL & STAPLES 1975) but false abnormal findings have not been encountered

When this ligament is ruptured the talus may be dislocated in different directions whereby incongruity appears between the opposing joint surfaces Current radiologic diagnosis of rupture of the talofibular ligament is based on the demonstration of such incongruity Thus forced adduction–inversion–supination in the ankle joint has been used to provoke talar tilt However the diagnostic value of the method is controversial (DUQUENNOY et coll 1975 STAPLES 1975) Provoked anterior disloca

Submitted for publication 18 May 1977




Fig. 1. Congruity between joint surfaces of talus and fibula demonstrated when the lower leg is rotated inwards 20°. (a) Morphology of the joint not explored due to inadequate projections: the lower leg rotated inwards too little (b) or too much (c).

tion of the talus has been found to be a considerably more versatile method in diagnosing rupture (LINDSTRAND & MORTENSSON 1977). Finally, the talus may rotate medially, thereby abolishing the congruity in the talofibular joint. NORMAN suggested already in 1956 that this phenomenon may be considered in the diagnosis of rupture of the anterior talofibular ligament. The validity of this assumption turned out clinically, to hold good in single cases (BOLIN 1961, NORMAN 1963, REICHEN & MARTI). In a series of 90 patients with a ruptured ligament confirmed at operation CEDELL found the talofibular joint to be incongruent in almost every case, but he did not report whether any incongruence existed in cases without ligament rupture.

The validity of estimating whether the anterior talofibular ligament is ruptured on the basis of the relation between the talar and fibular joint surfaces in patients with recent sprains, was tested. The results are now reported.

Material and Methods

The material consisted of 175 patients aged 16 to 47 years, mean age 26 years. Only patients with a strong clinical suggestion of rupture of the anterior talofibular ligament were included. Patients with additional rupture of the medial ankle ligaments or with fractures were excluded.

The material was divided into two main groups according to how the actual condition of the ligament was established. Group A: the ligament was inspected at operation; group B: rupture of the ligament was demonstrated at arthrography. The contralateral ankle of 61 patients from group B constituted a reference group.

Group A comprised 92 patients. Operation was performed 4 days at most after



Fig 2 Various degrees of incongruity in talofibular joint in 4 patients with a ruptured anterior talofibular ligament

the trauma The ligament was normal in 18 cases and ruptured in 72 The remaining 2 patients had intact but fibrous ligaments probably sequelae from previous injuries

Group B comprised 83 patients Arthrography of the ankle joint was carried out one to three days after the ankle sprain The criteria for rupture of the anterior talofibular ligament given by BROSTRÖM et coll were used All cases with normal arthrography were excluded as the bearing of this finding is not fully established

Radiography of the ankle joint was performed according to the method of BOLIN in the a p direction 4 projections were used with the leg rotated inwardly 0 and 20 and the leg rotated outwardly 55 and 85 Supplementary projections were often necessary with the leg rotated 15 and 25 inwards to obtain optimum demonstration of the talofibular joint (Fig 1) No effort was made to produce dislocation of the talus Anaesthesia was not provided

The appearance of the talofibular joint in the a p projection varies but the opposing bone surface of the talus and the fibula normally run parallel (BOLIN) (Fig 2) Lowermost in the joint the two surfaces may diverge somewhat especially in children

The surfaces of the talofibular joint were considered to be congruent if the cortex of both the talus and the fibula was projected tangentially (BOLIN)

The authors when evaluating the films were ignorant of the findings at operation and arthrography and did not know if the films belonged to the injured or non injured ankle (when both ankles were examined) The films from group A were estimated by all 3 authors together and the films from group B by one of the authors only (W M) In addition a comparison was made with the primary report given by differ nt members of the staff at the roentgen department

Hypothetically it was considered that incongruity of the talofibular joint indicated rupture of the talofibular ligament and that congruity meant an intact ligament The following definitions are based on these assumptions (a) The sensitivity of the method th number of adequately dignosed ligament ruptures divided by the total number of ligament ruptures and (b) The specificity of the method the number of adequately diagnosed intact ligaments divided by the total number of intact ligaments

Table

Relation between the joint surfaces of the talus and fibula in 175 ankles with recent ankle sprain and clinically injury of the anterior talo fibular ligament Group A Ligament inspected at operation Group B Arthrographic diagnoses

	Talofibular joint		
	Congruity	Incongruity	Total
Ruptured ligament			
Group A	41	31	72
Group B	51	32	83
Total	92	63	155
Intact ligament			
Group A	15	5*	20
Reference group	53	8	61
Total	68	13	81

* Two cases had fibrotic ligaments (probably sequelae of previous injury)

Results

Congruity in the talofibular joint was predominant in all the groups irrespective of the condition of the ligament (Table) However incongruity in the joint appeared more frequently in cases with a ruptured ligament than in cases with an intact ligament and in the reference group ($p < 0\,001$ chi test)

The sensitivity of the method to detect rupture was 0 41 The specificity of the method was 0 75 in group A Assuming that the reference group comprised ankles with an intact ligament only the specificity of the method based on this group would be 0 85

The primary evaluation of the films and that made by the present observers agreed in 87 per cent of the cases

Discussion

It may be difficult in individual cases to evaluate the talofibular joint The evaluation of different observers many of them young radiologists showed a high rate of agreement and still higher among experienced observers

Basically the assumption held that the condition of the ligament could be predicted from the presence or absence of congruity in the talofibular compartment of the ankle joint However the practical value of the method was limited for various reasons Voluntary contraction or reflex tension of the calf muscle evoked by pain may have stabilized the ankle joint thereby decreasing or eliminating the talar dislocation (LINDSTRAND & MORTENSSON) This fact may partly contribute to the many findings

erroneously considered to be without ligament rupture In a small series attempts to improve the method by provoking incongruity were unsuccessful Previous injury to the ligament or evident laxity may result in persistent instability of the ankle joint (LINDSTRAND & MORTENSSON) which may be erroneously considered a recent ligament rupture The risk of this type of error cannot be excluded

The results of CEDELL differed substantially from the present ones One explanation may be that the roentgenologic findings had influenced his selection of cases to be operated upon

Ligament lesions may be difficult to disclose or properly evaluate clinically and at radiography In fact, no single examination method guarantees complete and accurate information as to whether or not the ligaments are afflicted

Conclusions

The existence or non-existence of congruity in the lateral compartment of the talofibular joint has but restricted value for diagnosing recent ruptures of the anterior talofibular ligament Incongruity in the talofibular joint suggests ligament rupture The diagnostic value of congruity is too low to allow any conclusions to be drawn about the ligament

SUMMARY

The validity of predicting the condition of the anterior talofibular ligament from the shape of the lateral compartment of the ankle joint was investigated in patients with recent ankle sprain The diagnostic value of the method was found to be restricted

ZUSAMMENFASSUNG

Bei Patienten mit kurzlichen Knochelverrenkungen wurde der Wert fur die Aussage uber den Befund des Ligamentum talofibulare anterius auf Grund der Form des lateralen Teils de Knochelgelenks untersucht Der diagnostische Wert der Methode wurde als gering befunden

RESUME

Sur des malades ayant une entorse recente de la cheville les auteurs ont recherché quelle etait la valeur de l étude de la forme du compartiment externe de l articulation de la cheville pour diagnostiquer l etat du ligament peroneo astragalien antérieur Ils ont constaté que la valeur diagnostique de cette methode est limitee

REFERENCES

BOLIN H I The fibula and its relationship to the tibia and talus in injuries of the ankle due to forced external rotation Acta radiol 56 (1961) 439

BROSTRÖM L Sprained ankles VI Surgical treatment of chronic ligament ruptures Acta chir scand 132 (1966) 551

— LILJEDAHL S O and LINDVALL N Sprained ankles II Arthrographic diagnosis of recent ligament ruptures Acta chir scand 129 (1965) 485
CASTAING J et DELPLACE J Entorses de la cheville Interêt de l étude de la stabilite dans le plan sagittal pour le diagnostic de gravité Recherche radiographique du tiroir astragalien antérieur Rev Chir orthop 58 (1972) 51
CEDELL C A Supination—outward rotation injuries of the ankle A clinical and roentgenological study with special reference to the operative treatment Acta orthop scand (1967) Suppl No 110
COUTTS M and WOODWARD P Surgery and sprained ankles (lateral ligament tears) Clin Orthop 42 (1965) 81
DEHNE E Die Klinik der frischen und habituellen Adduktionssupinationsdistorsion des Fusses Dtsch Z 242 (1933) 40
DUQUENNOY A LISÉLÉLÉ D et TORABI D J Entorses graves de la tibio tarsienne Eléments radiographiques du diagnostic de gravité de l entorse Clichés en varus equin force Rev Chir orthop (1975) Suppl No 61 p 11
LINDSTRAND A Lateral lesions in sprained ankles Thesis Lund 1976
— and MORTENSSON W Anterior instability in the ankle joint following recent sprain Acta radiol Diagnosis 18 (1977) 529
NIETHARD F Die Stabilitat des Sprunggelenkes nach Ruptur des lateralen Bandapparates Arch orthop Unfall Chir 80 (1974) 53
NORMAN O Schwere Ligamentschaden im Fussgelenk ohne Frakturen Radiologe 3 (1963) 418
REICHEN A und MARTI R Die frische fibulare Bandruptur — Diagnose Therapie Resultate Acta orthop Unfall Chir 80 (1974) 211
STAPLES S Ruptures of the fibular collateral ligaments of the ankle J Bone Jt Surg 57 A (1975) 101
SPIEGEL P and STAPLES S Arthrography of the ankle joint Problems in diagnosis of acute lateral ligament injuries Radiology 114 (1975) 587

FROM THE DEPARTMENT OF DIAGNOSTIC RADIOLOGY (DIRECTOR PROF P VIRTAMA)
UNIVERSITY CENTRAL HOSPITAL SF 205 20 TURKU FINLAND

LYMPHATICS FILLED AT KNEE ARTHROGRAPHY

M KORMANO and P MAKELA

Filling of lymph vessels at knee arthrography seems to be exceedingly rare only 7 cases having been reported in the literature HALL & SCOTT (1966) observed lymphatic filling in 2 of 20 knee arthrographies in patients with rheumatoid arthritis and synovial cysts One case was reported by STENSTROM & WEGELIUS (1970) and 3 cases—all with rheumatoid arthritis—by LEWIN & MULHERN (1972) In a series of 650 non rheumatoid knees LEWIN & MULHERN observed no lymphatic filling Recently one case of lymph vessel filling from a synovial cyst of a young non rheumatoid patient has been reported (KORMANO et coll 1976) indicating that filling of lymph vessels may not be restricted to rheumatoid arthritis Apparently lymphatics are more frequently filled when the arthrography is performed with positive contrast medium In an attempt to analyse the frequency and diagnostic significance of filling of lymph vessels at knee arthrography 587 consecutive arthro graphies of the knee joint were reviewed relating demonstrable filling of lymphatics to knee joint pathology

Material and Methods

The 587 arthrographies were performed during the years 1973 to 1975 The examinations were carried out to demonstrate either lesion of the menisci utilizing a conventional technique after introducing 8 to 10 ml of a contrast medium 60% (530 cases) or a popliteal cyst by introducing 20 ml of medium with the technique described by STENSTROM & WEGELIUS consisting of views of the knee before and after maximum flexion extension movements (57 cases) The arthrographic findings are presented in Table 1

Supported by a grant from the Sigrid Juselius Foundation Helsinki Finland Submitted for publication 24 March 1977

Table 1

Radiographic findings and technique used

Method	Result	No of cases	Lymphatic filling
Arthrography	Normal	164	—
	Pathologic		
	Meniscus lesion only	200	2
	Capsular lesion (– other pathology)	107	1
	Marked osteoarthritis	26	—
	Post traumatic or postoperative joint	27	1
	Other abnormalities (incl. synovitis and anomalies)	6	2
	Total	530	6
Popliteal cystography	Normal	12	
	Pathologic		
	Popliteal cyst (unruptured)	16	2
	Popliteal cyst (ruptured)	19	4
	Osteoarthritis	6	—
	Synovitis only	2	—
	Ruptured suprapatellar bursa	2	—
	Total	57	6

Results

Altogether 12 cases of unequivocal filling of lymph vessels after intraarticular injection of contrast medium were found A brief description of the cases is given in Table 2 It is evident that the majority of cases with lymphatic filling have synovitis either acute or chronic but the phenomenon is observed in post traumatic and postoperative conditions as well It was transient in all cases Lymphatics were usually observed only on some of the first films It was also evident that manipulation of the knee may induce penetration of contrast medium into lymphatics extending caudally from the joint Most extensive filling always occurred in cases with synovitis—either rheumatoid arthritis or acute inflammation of other origin Not only the posterior compartment but also the suprapatellar bursa may have *abnormal* connections between the joint and lymphatics Representative cases of lymphatic filling appear in Figs 1 and 2

Special attention was paid to detection of artifacts Lymphatic filling was found to be unrelated to leakage of contrast medium through a ruptured synovial membrane or to extra articular injection of medium

Discussion

Lymphatic filling at arthrography of the wrist (RANAWAT et coll 1969 HAAGE 1970) ankle (LÜNING & ROMANIUK 1968 HAAGE) and elbow (TAIT et coll 1965) is

Table 2

Clinical and radiographic data on patients with lymphatic filling during arthrography of the knee arthrography

Case No	Sex	Age (a)	Clinical diagnosis	Duration of local symptoms	ESR	Radiography	Number and location of visible lymphatics
1	M	40	Rupture of lateral meniscus	3 months	9	Ruptured lateral meniscus	Three posterior downwards
2	F	43	Operated twice medial menisci removed chondromalacia of patella	12 months	13	Ruptured small regenerated medial meniscus	Several posterior both upwards and downwards
3	M	17	Arthritis not specified	2 weeks	2	Ruptured synovia	Three posterior upwards
4	M	56	Thrombophlebitis	2 months	3	Popliteal cyst	Two anterior upwards
5	M	24	Post traumatic effusion	2 months	10	Mild synovitis, effusion	Four posterior downwards
6	M	10	Rheumatoid arthritis	6 months	70	Synovitis	10 posterior upwards
7	F	65	Osteoarthritis Baker s cyst rupture of meniscus	2 weeks	55	Ruptured popliteal cyst osteoarthritis	~10 posterior upwards
8	F	51	Degenerative changes no synovitis	4 months	43	Popliteal cyst degenerated medial meniscus	Two posterior upwards
9	M	26	Gonorrhea acute arthritis both knees	1 week	102	Synovitis synovial rupture	10 posterior upwards
10	M	64	Rheumatoid arthritis for over 20 years	2 weeks	72	Ruptured popliteal cyst ~ synovitis	One posterior upwards
11	F	54	Rheumatoid arthritis for 20 years	2 weeks	63	Ruptured popliteal cyst synovitis	>10 posterior upwards and downwards
12	M	47	Rheumatoid arthritis sarcoidosis	1 month	76	Popliteal cyst synovitis	One posterior upwards

relatively uncommon It is usually found in patients with rheumatoid arthritis recent trauma or other definite joint abnormality Lymphatic filling at arthrography of the shoulder joint is common in rheumatoid arthritis Thus DESMET (1975) observed lymphatic filling in 31 per cent of their arthrographies of rheumatoid shoulder joints

Considering the number of knee arthrographies currently performed lymphatic filling is rare This is in part due to the technique used while most other arthro-



Fig. 1 Female 34 years old Rheumatoid arthritis for the past 2 years acute symptoms for ten days Evidence of synovial hyperplasia and ruptured popliteal cyst Several posterior lymphatics filled extending downwards and upwards (Case No 11)

graphies are performed using positive contrast medium knee arthrography is often done with a double contrast method which requires a smaller amount of positive contrast medium and therefore is less likely to result in lymphatic filling.

The present material indicates that in knee arthrography using positive contrast medium lymphatics are occasionally observed (2% in the present series) It is also



Fig. 2. Female 43 years of age Removal of medial meniscus and operation for chondromalacia of patella several years earlier Fresh rupture of the regenerated medial meniscus Several lymphatics filled at the posterior aspect of the knee joint (Case No 2)

obvious that the lymphatics are visible for only a short period and are related to pathology of the knee joint Six out of 7 cases previously reported had rheumatoid arthritis (HALL & SCOTT LEWIS & MULHERN STENSTRÖM & WEGELIUS) In the present series 9 of 12 cases occurred in patients with abnormal joints frequently due to either rheumatoid or other inflammation LEWIS & MULHERN suggested that a hyperplastic response of the lymphatic system typical of rheumatoid arthritis and lymphatic channels associated with increased permeability of the synovial membrane are causes of lymphatic filling Abnormal connections between the joint space and the lymph vessels are the apparent cause of the phenomenon High intra articular pressure will enable the lymphatics to fill even in a retrograde fashion e g toward the calf This filling always occurs through connections between the joint space and lymphatics and is not secondary to extra articular deposits of contrast medium

Conclusions Filling of lymphatics at knee arthrography is relatively rare It seems to be always associated with joint pathology and is indicative of abnormal connections between the synovial membrane and lymphatics Such connections were observed secondary to inflammation of the synovial membrane either chronic or acute and after surgery or trauma Lymphatic filling is not specific to rheumatoid inflammation

SUMMARY

A review of 587 knee arthrographies revealed filling of lymph vessels in 12 cases They occurred in connection with arthritis (4 rheumatoid) osteoarthritis ruptured meniscus ruptured popliteal cyst and after operation Lymphatic filling was not related to the leakage of contrast through a ruptured popliteal cyst or to inadvertent extra articular injection Filling of lymphatics is more likely to occur in examinations with a positive contrast medium when a larger amount of medium is used

ZUSAMMENFASSUNG

Eine Durchsicht von 587 Kniearthographien zeigte Fullung der Lymphgefasse in 12 Fallen Diese trat in Verbindung mit Arthritis (4 rheumatoide) Osteroarthritis einer Meniscus ruptur Ruptur einer popliteалen Zyste und nach Operation auf Die Fullung der Lymphwege war nicht zu einem Austritt von Kontrast durch eine rupturierte popliteale Zyste oder einer unbeabsichtigen extraartikularen Injektion relatiert Die Fullung der Lymphbanen ist wahrscheinlicher bei Untersuchungen mit einem positivem Kontrastmittel bei Verwendung von grossen Mengen des Mittels

RESUME

L examen de 587 arthrographies du genou a montre un remplissage des vaisseux lymphatiques dans 12 cas Ceci se produit dans des cas d arthrite (4 arthrites rhumatoides) d osteoarthrite de rupture des menisques de rupture de kyste poplite et apres operation Le

remplissage des lymphatiques n est pas en relation avec une fuite du contraste à travers un kyste poplité rompu ou avec une injection extraarticulaire involontaire Le remplissage des lymphatiques a plus de chance de se produire quand on utilise une grande quantite de moyen contraste positif

REFERENCES

DESMET A A TING Y M and WEISS J J Shoulder arthrography in rheumatoid arthritis Radiology 116 (1975) 601

HAAGE H Lymphgefassfullung bei der Arthrographie mit positivem Kontrastmittel Fortschr Rontgenstr 112 (1970) 485

HALL A P and SCOTT J T Synovial cysts and rupture at the knee joint in rheumatoid arthritis An arthrographic study Ann rheum Dis 25 (1966) 32

KORMANO M SCHRANK W W and SWIRSKY M Lymphatic filling during knee arthrography Ann chir gynaec 65 (1976) 382

LEWIN J R and MULHERN L M Lymphatic visualization during contrast arthrography of the knee Radiology 103 (1972) 577

LUNING M und ROMANJUK P A Spontane Lymphgefassdarstellung nach Arthrographie des oberen Sprunggelenkes Fortschr Rontgenstr 108 (1968) 400

RANAWAT C H S FRIEBERGER R H JORDAN L R and STRAUB L R Arthrography in the rheumatoid wrist joint J Bone Jt Surg 51 A (1969) 1269

STENSTRÖM R and WEGELIUS O Clearance of ^{125}I labelled Urografin from knee joints in rheumatoid arthritis Acta rheum scand 16 (1970) 151

TAIT G B W BACH F and DIXON A ST J Acute synovial rupture Further observations Ann rheum Dis 24 (1965) 273

WESTON W Y Lymphatic filling during positive contrast arthrography in rheumatoid arthritis Aust Radiol 13 (1969) 318

FROM THE DEPARTMENT OF DIAGNOSTIC RADIOLOGY KAROLINSKA SJUKHUSET S 104 01 STOCKHOLM SWEDEN

FACIAL BONE SCINTIGRAPHY

I Metastatic lesions in the mandible

H F BERGSTEDT and M HAVERLING

Metastases of malignant tumours to the jaws are rare compared with those involving the spine pelvis femur skull and humerus (ABRAMS et coll 1950) Reviews of reports on maxillary and mandibular metastases have been made by CASTIGLIANO & ROMINGER (1954) CASH et coll (1961) CLAUSEN & POULSEN (1963) among others Applying different criteria the rate of occurrence was somewhat different

CASTIGLIANO & ROMINGER noted 176 cases during a period of 55 years Carcinoma of the thyroid accounted for the greatest number of metastatic lesions to the jaws in 47 per cent mammary carcinoma in 40 per cent and of hypernephroma in 19 per cent Lungs the prostate and other organs were represented in diminishing frequency CLAUSEN & POULSEN recorded 97 cases during 75 years and in this survey the location of the primary tumour was dominated by the breast in about 30 per cent while lungs and kidneys represented about 15 per cent Other organs as prostate thyroid and colon were less frequently represented Solitary metastases to the jaws occurred mainly in the mandible (CASH et coll —95 % CLAUSEN & POULSEN—80 %) and the dominant sites were the molar retromolar and ramus regions

With great probability pathologic distribution of $^{99}Tc^m$ DP reflects alteration of the bone metabolism rendering the lesions detectable by scintigraphy at an earlier state than does radiography (CASTRONOVO & CALLAHAN 1972 CASTRONOVO et coll 1973 GALASCO & DOYLE 1972) Because of anatomic reasons pathologic processes in the facial region are located close to bone and thus bone scintigraphy is of special

Submitted for publication 10 February 1977




Fig 1 Case 1 Increased isotope accumulation in the entire mandible a) Right lateral b) a p c) left lateral projection

interest in the examination of the facial skeleton (BERGSTEDT 1975 ALEXANDER 1976 BERGSTEDT & LIND 1978)

The aim of this report is to demonstrate the diagnostic capacity of bone scintigraphy for the detection of metastatic lesions of the facial skeleton and to compare the findings with those made by radiography

Material and Methods

During 1974 and 1975 five cases with metastases in the mandible were detected at this department 3 with carcinoma of the prostate one with mammary carcinoma and one with hypernephroma with exception of one of them the site of the primary tumour was known when the mandibular metastasis was detected

Scintigraphy was performed 5 hours after intravenous administration of 10 mCi of $^{99}Tc^{m}$ diphosphonate A gamma camera (Nuclear Chicago Pho Gamma IV) was utilized with converging collimator and 300 000 counts were registered in one antero posterior and two lateral projections (BERGSTEDT)

Radiography and scintigraphy were performed on the same day



Fig 2 Case 2 Increased isotope accumulation in the left part of the mandible and in the skull a) A p b) left lateral projection



Fig 3 Case 3 Increased accumulation of isotope in the right mandibular ramus side difference in a p projection a) Right lateral b) a p c) left lateral projection



Fig. 4 Case 4 Increased accumulation of isotope in the right mandibular ramus a) Right lateral b) a p c) left lateral projection

Case 1 Male aged 72 with a prostatic carcinoma successfully treated for 5 years Seven months before the actual examination metastatic growth was detected in the skeleton with involvement of the pelvis spine and ribs Later the patient complained of pain in the man dible and the temporomandibular joints At radiography small osteosclerotic areas in the ramus and angular parts of the mandible were demonstrated Scintigraphy of the facial skeleton revealed an abnormally high accumulation of the isotope within the entire man dibe with exception of the symphysis region and the muscular processes which like the rest of the facial bones were assessed as normal (Fig 1)

Case 2 Male aged 69 with prostatic carcinoma for 4 years He was treated with chemotherapeutics and 2 years after discovery of the tumour radiography of the skeleton demon strated metastases to the spine and pelvis Two years later osteolytic and osteosclerotic lesions of the skull bones could be demonstrated as well as an osteolytic lesion in the pre molar part of the left lower jaw At scintigraphy the isotope accumulation was increased in the skull bones and in the left anterior and premolar regions of the mandible (Fig 2)

Case 3 Male aged 74 treated for carcinoma of the prostate for 13 years He had a history of slight pain in the right jaw and numbness in the right lower lip Radiography of the man dible demonstrated an osteolytic lesion one centimeter in diameter in the anterior part of



Fig 5 Increased accumulation of isotope in the right mandibular ramus a) Right lateral b) a p projection

the right mandibular ramus At scintigraphy a side difference of uptake was noted in the a p projection and an increased accumulation of the isotope in the ramus region (Fig 3)

Case 4 Female aged 57 operated upon for mammary carcinoma 9 years previously Two pulmonary metastatic lesions were treated At the actual examination she had paraesthesia in the right part of her mandible since 2 months At radiography irregularity and destruction of the marginal structures of the mandibular canal were revealed Scintigraphy revealed increased accumulation of the isotope in the major part of the ascending ramus (Fig 4)

Case 5 Female aged 62 with mastectomy for a mammary carcinoma 13 years before actual examination No evidence of metastases although she complained of paraesthesia in her right lower lip Radiography revealed an area of bone destruction about 2 cm in diameter in the mandibular ramus Scintigraphy demonstrated increased accumulation of the isotope in a larger part of the ramus (Fig 5) The biopsy specimen demonstrated atypical malignant cells without resemblance to mammary carcinoma Later examination of the kidneys disclosed a hypernephroma and the mandibular lesion proved to be a metastasis of this tumour

In all the cases reported bone scintigraphy demonstrated the lesions most satisfactorily The affected part of the bone appeared considerably larger than could be demonstrated at radiography where the structural alterations were only of minor significance

The rate of accumulation in the affected areas of Case 3 was low compared to the lesions in the other cases This patient was treated for a considerable period of time 13 years by chemotherapeutics and the rate of metabolic activity of the metastatic lesion could have been diminished by the treatment

Discussion

Metastases of carcinoma are frequently sited in the axial skeleton but they are rare in the facial bones and mandible The low frequency of metastatic involvement of the jaws reported in the literature might to some extent be explained by the deficiency of post mortem examinations of these parts of the skeleton

Another factor of significance is that the survival time for the patients is prolonged considerably by modern therapy leading to more frequent appearance in areas where this kind of lesions otherwise are uncommon or rare

Around most tumours an area of increased metabolic activity exists with only slight structural alteration of the bone Therefore at scintigraphy of the skeleton the presence of metastatic and other malignant lesions is demonstrated earlier and more accurately than by conventional radiology because the abnormal accumulation of the isotope is related to this increase in bone metabolism

Biopsy as well as periodontal and other bone affections of dental origin may result in increased isotope uptake Therefore biopsy should not be performed until after the scintigraphy and dental affections must be ruled out by radiography and clinical examination

SUMMARY

Five cases of metastases in the mandible are reported Conventional radiography and bone scintigraphy by $^{99}Tc^m$ DP recorded by gamma camera were performed Invariably the lesions were clearly demonstrated by scintigraphy when radiography revealed only minor structural changes of the bone tissue

ZUSAMMENFASSUNG

Funf Falle von Metastasen in dem Unterkiefer werden berichtet Eine konventionelle Rontgenuntersuchung und Knochenszintigraphie mit $^{99}Tc^m$ DP unter Verwendung einer Gammakamera wurden vorgenommen Die Veranderungen wurden deutlich bei der Szintigraphie nachgewiesen wahrend nur geringe strukturelle Veranderungen des Knochengewebes bei der Rontgenuntersuchung beobachtet wurden

RESUME

Presentation d cinq cas de metastase dans la mandibule La radiographie orbitaire et la scintigraphie osseuse par le $^{99}Tc^m$ DP enregistrée par gamma-caméra ont été pratiquées Invariablement les lesions ont ete clairement mises en evidence par la scintigraphie alors que la radiographie ne revelait que des modifications structurales mineures du tissu osseux

REFERENCES

ABRAMS H L SPIRO R and GOLDSTEIN N Metastasis in carcinoma Analysis of 1 000 autopsied cases Cancer 3 (1950) 74

ALEXANDER J M Radionuclide bone scanning in the diagnosis of lesions of the maxillofacial region J Oral Surg 34 (1976) 249

BERGSTEDT H F Bone scintigraphy of facial skeleton with $^{99}Tc^m$ diphosphonate Acta radiol Diagnosis 16 (1975) 337

— and LIND M G Facial bone scintigraphy II Diagnostic potential in neoplastic and inflammatory lesions To be published in Acta radiol Diagnosis 19 (1978)

CASH C D ROYER R Q and DAHLIN D C Metastatic tumours of the jaws Oral Surg Oral Med Oral Path 14 (1961) 897

CASTIGLIANO S G and ROMINGER C J Metastatic malignancy of the jaws Amer J Surg 87 (1954) 406

CASTRONOVO F P and CALLAHAN R J A new bone scanphosphate J nucl Med 13 (1972) 1210

— POTSAID M S and PENDERGRASS H P Effects of radiation therapy on bone lesions as measured by ⁹ Tc^{m} diphosphonate J nucl Med 14 (1973) 604

CLAUSEN F and POULSEN H Metastatic carcinoma to the jaws Acta path microbiol scand 57 (1963) 361

GALASCO C S B and DOYLE F H The detection of skeletal metastases from mammary cancer A comparison between radiology and scintigraphy Clin Radiol 23 (1972) 29⁵

ACTA RADIOLOGICA

PUBLISHED BY THE SOCIETIES OF MEDICAL RADIOLOGY IN
DENMARK, FINLAND, NORWAY AND SWEDEN

Vol 19 DIAGNOSIS 1978
Fasc 6

EDITORIAL

Conflicting modes of left/right orientation of transverse tomographic images are in current use—as reflected in the scientific journals—even to the extent that different modes are employed for head and body images The first and original EMI com puterized axial transverse scanner employed one single mode of orientation as though viewing the supine patient s head from above newer scanners have offered the option of left/right display reversal

Some degree of consensus has developed recommending that transverse images of the body including the head be oriented as though vieweing the supine patient from below with the patient s right to the viewer s left A joint declaration by the editors of Radiology and the American Journal of Roentgenology (Radiology 119 (1976) 487) stated a preference for this orientation of transverse section images for publication in those journals i e the supine patient is viewed from below

Another policy was introduced on an interim basis by the Journal of Computer Assisted Tomography (1 (1977) 163) following the seen from above convention for the head and neck and either orientation for the rest of the body although at the same time expressing the hope that eventually one mode will be employed for imaging of the entire body

The fact that many scanners in operation today use the seen from above mode of di play without facilities for reversal is no reason to argue for the seen from above orientation as the newer types of scanners have facilities for reversal Neither of the two conventions of left/right display has a direct logical priority over the other experience indicates that most radiologists are easily adaptable so that either orienta

tion after some times feels quite natural and if used exclusively, will cause the opposite orientation to appear unnatural However the advantages of conforming to traditional orientation of conventional radiographic images as well as to the generally accepted orientation in ultrasound and radionuclide imaging constitute a strong argument in favour of the seen from below convention of display Thus a correlation between images produced by different methods is facilitated

As the number of imaging modalities increases to the extent that the time honoured Department of Diagnostic Radiology should perhaps be renamed Department of Diagnostic Imaging conformity assumes increasing importance The use of more than one mode of display in parallel in the same department is not only inconvenient but may also be dangerous for the patient It is important that conformity be achieved throughout the human body in radiologic or other type of display

A decision has thus been made that Acta Radiologica for purposes of promoting this principle will consistently employ the following convention all images submitted for publication are required to be oriented as though the reader were viewing the supine patient from below or from the front the patient s right to the viewer s left This policy will be executed beginning with the present issue

FROM THE DEPARTMENT OF DIAGNOSTIC RADIOLOGY HUDDINGE SJUKHUS S 141 86 HUDDINGE AND THE DEPARTMENTS OF NEURORADIOLOGY NEUROSURGERY RADIATION PHYSICS AND TUMOUR PATHOLOGY KAROLINSKA SJUKHUSET S 104 01 STOCKHOLM SWEDEN

STEREOTACTIC COMPUTER TOMOGRAPHY FOR BIOPSY OF GLIOMAS

R LEWANDER M BERGSTRÖM J BOETHIUS V P COLLINS
G EDNER T GREITZ and J WILLEMS

No adequate treatment of patients with gliomas exists today A prerequisite for any improvement of this situation is more accurate diagnosis including a more precise localization and a differentiated pathologic typing of the tumour The varying mode of growth of gliomas creates difficulties in assessing the exact outline of the tumour and in obtaining a representative sample of the tumour tissue HATAM et coll (1975) BOETHIUS et coll (1977) and MARKS & GADO (1977) have drawn attention to the potential of computer tomography (CT) in revealing the internal structure of the tumour and the surrounding tissue

The question of whether CT facilitates a malignancy grading of supratentorial gliomas has been investigated by TCHANG et coll (1977) They found certain specific appearances enabling a reliable differentiation between the low grade gliomas and glioblastomas Attempts have been made to classify the gliomas according to their pathologic type into benign (Kernohan grades I and II) and malignant (Kernohan grades III and IV) The morphologic appearances of the CT images were recorded and depending on the dominant feature the tumours were classified as cystic solid mixed (i e both cystic and solid components) and infiltrating Only a holistic evaluation of the CT appearances compared to the pathologic grading of the tumour was performed However the great sensitivity of CT makes it possible and fruitful to perform this correlation in a point to point manner This can be made on autopsy material provided that the CT is performed sufficiently close to the death of the patient In living patients the desired point to point correlation can be obtained only if biopsies are taken stereotactically

Using a stereotactic technique BOETHIUS et coll (1977) tried to assess to what

Submitted for publication 9 February 1978



Fig 1 A helmet made of a band of thermoplast applied around the patient s head

extent the structures in the CT image correspond to the findings at microscopy They found that it was possible to predict the histologic type of the biopsy specimens from the CT image with a certain degree of confidence It was also evident that it was necessary to take biopsies from various parts of the tumour in order to obtain a reliable diagnosis Therefore it was considered motivated to elaborate a stereotactic technique enabling the exact automatic transfer of the coordinates obtained at CT to those of the stereotactic system used for the biopsies A less traumatizing puncture biopsy technique has also been developed and applied to a larger material

Methods

A rigid and persistent type of skull fixation is a sine qua non for the correct transfer of the coordinates from the CT scan to the operating device A helmet made of a band of thermoplast (Orthoplast) heated to 80 C was applied around the patient s head (BERGSTRÖM & GREITZ 1976 LEKSELL et coll 1976) The head was covered with tube gauze to avoid direct contact between the heated thermoplast and the skin The helmet was formed to fit the root of the nose closely leavin the eyes free (Fig 1) Another type of thermoplast (Kerr R) was heated in warm water and moulded to fit into the external auditory meatus and then fixed on the helmet Two pairs of aluminium plates were attached to the helmets Using four individually adjustable bolts with mm scales these plates were then fixed in a suitable position onto a ring which can also be attached to the scanner or a Leksell coordinate frame (LEKSELL 1949 Figs 2 3) The CT was carried out with an EMI Mark I CT scanner For small tumours the 8 mm and for larger tumours the 13 mm collimator was used Contrast medium enhancement was achieved by an intra venous bolus injection (1 ml Isopaque Cerebral/kg body weight) followed by a drip infusion of contrast medium (0 02 ml/min/kg body weight) This procedure

a Fig 2 b

Fig 2 The helmet is fixed to a ring using 4 individually adjustable bolts with mm scales The ring is then attached to the scanner or a Leksell coordinate frame



Fig 3

Fig 3 The ring with the stereotactic frame attached to the operation table A small craniotomy is made under local anaesthesia and the biopsies taken with a spiral needle

yields an almost constant blood concentration during the examination (BERGSTRÖM personal communication) Following the CT one section through the central part of the tumour was selected for the biopsies The target points and the path of the biopsy needle were planned so as to obtain samples from both enhanced and unenhanced parts of the tumour and in addition from the peripheral zone of low attenuation Thus the biopsies were all taken along one insertion channel in the plane of the CT section Using this method it was possible to obtain up to 5 separate samples from one tumour

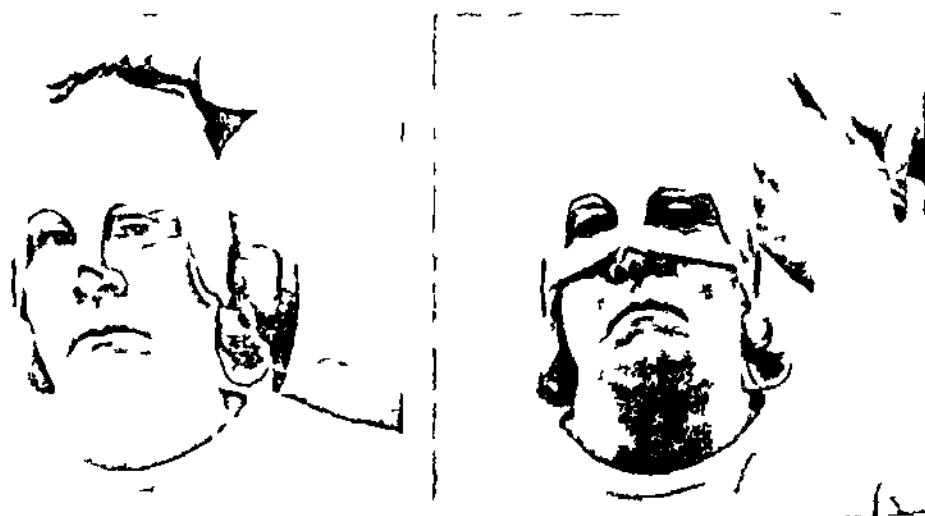


Fig 1 A helmet made of a band of thermoplast applied around the patient s head

extent the structures in the CT image correspond to the findings at microscopy They found that it was possible to predict the histologic type of the biopsy specimens from the CT image with a certain degree of confidence It was also evident that it was necessary to take biopsies from various parts of the tumour in order to obtain a reliable diagnosis Therefore it was considered motivated to elaborate a stereotactic technique enabling the exact automatic transfer of the coordinates obtained at CT to those of the stereotactic system used for the biopsies A less traumatizing puncture biopsy technique has also been developed and applied to a larger material

Methods

A rigid and persistent type of skull fixation is a sine qua non for the correct transfer of the coordinates from the CT scan to the operating device A helmet made of a band of thermoplast (Orthoplast) heated to 80 C was applied around the patient s head (BERGSTRÖM & GREITZ 1976 LEKSELL et coll 1976) The head was covered with tube gauze to avoid direct contact between the heated thermoplast and the skin The helmet was formed to fit the root of the nose closely leaving the eyes free (Fig 1) Another type of thermoplast (Kerr R) was heated in warm water and moulded to fit into the external auditory meatus and then fixed on the helmet Two pairs of aluminium plates were attached to the helmets Using four individually adjustable bolts with mm scales these plates were then fixed in a suitable position onto a ring which can also be attached to the scanner or a Leksell coordinate frame (LEKSELL 1949 Figs 2 3) The CT was carried out with an EMI Mark I CT scanner For small tumours the 8 mm and for larger tumours the 13 mm collimator was used Contrast medium enhancement was achieved by an intra venous bolus injection (1 ml Isopaque Cerebral/kg body weight) followed by a drip infusion of contrast medium (0 02 ml/min/kg body weight) This procedure

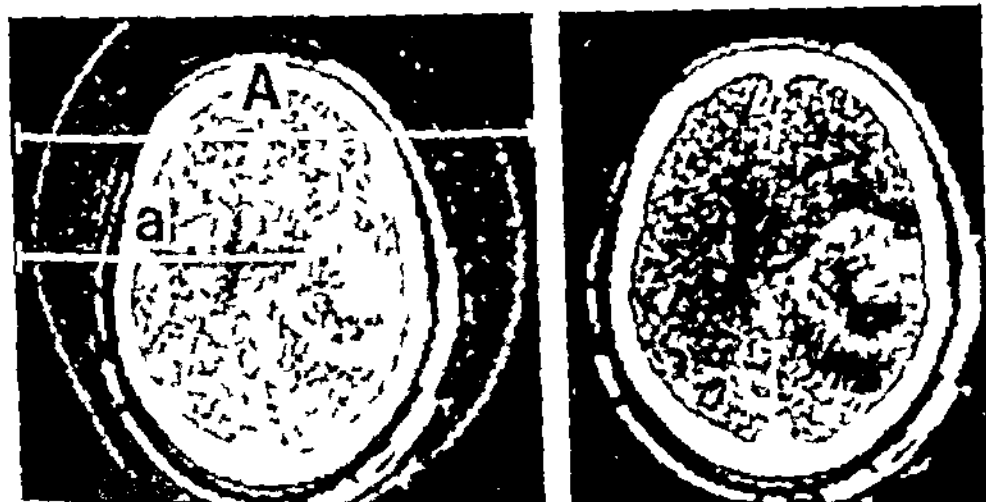


Fig 5 Determination of horizontal coordinate Distance in number of matrix elements from edge = a 160 A Parietal tumour with target points indicated

under local anaesthesia The biopsies were taken with a spiral needle (BACKLUND 1971) which yields a small cylinder of 1 cm length and approximately 1 mm in diameter The peripheral parts of this cylinder were used for crush smears for cytology (May Grunwald Giemsa and Papanicolaou staining) and for cytochemistry These samples were taken 4 to 5 mm in front of and behind the target point The remaining and greater part of the cylinder was fixed in glutaraldehyde 2% in 0 1 M Na cacodylate HCl buffer with 0 1 M sucrose (COLLINS et coll 1977) making both electron and light microscopy possible With small structures this procedure sometimes resulted in the cytologic samples being taken from each side of the rim while the center of the cylinder contained tissue from the target point This matter will be further discussed in the case reports

Following the selection of a small part (approximately 1 mm long) for electron microscopy the remainder of the material was embedded in paraffin wax sectioned and stained for light microscopy using Hematoxylin and Eosin (H+E) as well as Phosphotungstic acid Hematoxylin (PTAH) staining methods The tumours were graded according to KERNOHAN et coll (1949) In all illustrations of the CT images the biopsy sites are indicated and denoted from front to back

Results

The material consisted of 13 patients 9 women and 4 men aged between 17 and 74 years All patients had brain tumour diagnosed as glioma on the basis of clinical and neuroradiologic criteria described previously (BOETHIUS et coll 1977) In one case the tumour consisted of undifferentiated cells and lymphoma was considered a possible diagnosis This tumour has therefore been omitted when discussing the classification

In an attempt to classify the gliomas on the basis of the morphologic appearance of the CT image it was found possible to distinguish 4 groups

Group A

This group included tumours with a more solid appearance than those of the other groups The enhancement following contrast medium injection was usually faint which made it difficult to distinguish the tumour from normal brain tissue and to ascertain its outline The zone of low attenuation surrounding the tumour was not as evident and wide as in group C

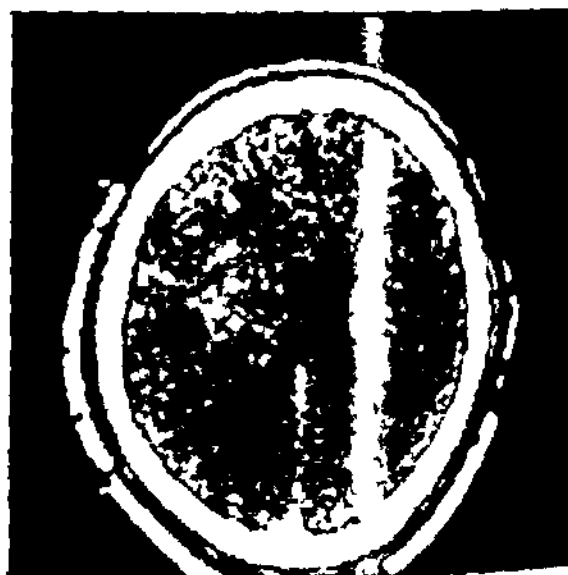


Fig 6 Right parietal tumour deforming and compressing the right lateral ventricle Only faint enhancement after contrast medium injection

Case 1 A 33 year old man with increasing headache a left sided paralysis of the facial nerve and a slight sensory loss in the left arm and leg At scintigraphy increased uptake in the right parietal region Carotid angiography revealed an expanding lesion in the right parietal region without pathologic vessels or arterio venous shunting CT demonstrated a parietal tumour deforming and compressing the right lateral ventricle Slight enhancement after injection of contrast medium was present (Fig 6) Target 1 consisted of oedematous brain tissue at cytologic examination as supposed Target 2 was supposed to be the tumour border, but the entire sample was composed of tumour tissue Histologic as well as cytologic examinations of targets 2 3 and 4 gave the same diagnosis Astrocytoma grade II

Comments The outline of this tumour was difficult to define on CT due to the slight enhancement The tumour had a solid structure and has therefore been assigned to group A

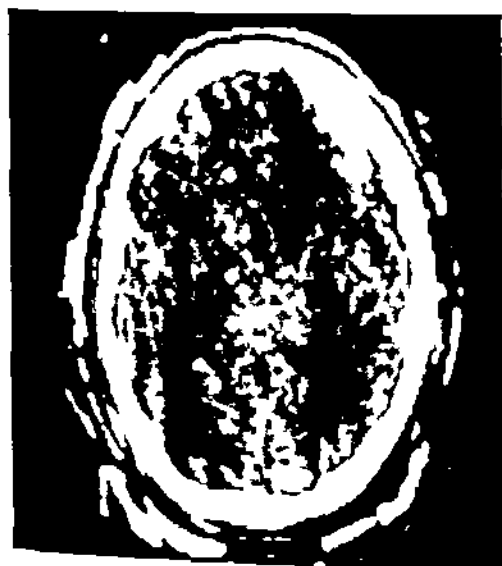


Fig 7 Right sided deep-seated and ill defined expanding lesion with minimal en hancement after contrast medium admini stration

Case 2 A 33 year old man with a 6-week history of periods of disorientation At examination a left sided hemiparesis and a right sided papillary oedema were found Carotid angiographies revealed a central bilateral expanding lesion larger on the right side Slight accumulation of contrast medium within the tumour area par ticularly around the right frontal horn and rapid shunting to the subependymal veins in *both* frontal horns Brain scintigraphy indicated a central lesion with increased uptake larger on the right side CT (Fig 7) demonstrated a central but mainly right sided expanding lesion of the basal ganglia The ventricular system was displaced to the left and the right frontal horn compressed Only a slight enhance ment after contrast medium injection occurred except for an evident enhancement around both *anterior* horns Four targets were selected for stereotactic biopsies as indicated in Fig 7 Both the histology and the cytology of the sample from target 1 showed oedematous brain tissue as was expected from the CT scan Targets 2 and 3 *contained* tumour tissue Target 4 also contained tumour tissue with the exception that the crush smear which was taken from the most posteriorly located end of the biopsy contained both tumour cells and oedematous brain tissue The tumour was considered to be an astrocytoma grade II

Comments This tumour had very diffuse borders a slight irregular attenuation almost corresponding to that of normal brain tissue and only a faint contrast enhance ment It was therefore assigned to group A A possible explanation of the peri ventricular enhancement is tumour seeding

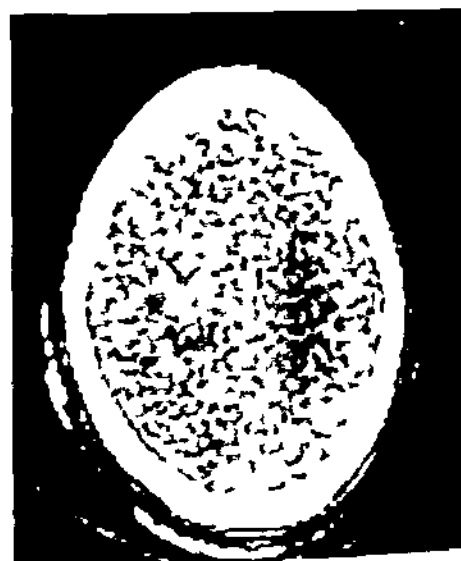


Fig 8 Right parietal expanding lesion demonstrated only following contrast medium enhancement

Case 3 A 17 year-old girl with a slowly progressing spastic paralysis of the left leg and arm Scintigraphy Well defined lesion with increased uptake in the right parietal area near the midline Carotid angiography Expanding lesion in the same location without abnormal vessels or arteriovenous shunting On CT an expanding lesion about 3 5 cm in diameter was found with a slight enhancement after contrast medium injection (Fig 8) A very small central region within the tumour was only faintly or not at all enhanced and the entire lesion was surrounded by a zone of low attenuation In target 1 supposed to be normal or oedematous tissue normal brain tissue was found at histologic examination but there was a little fragment of a tissue with cells containing hyperchromatic nuclei At the cytologic examination target 1 had normal brain tissue Target 2 gave samples with an undifferentiated tumour with small cells and target 3 necrotic tissue at both histo- and cytologic examination Target 4 consisted at cytologic examination in equal parts of necrotic tissue tumour and normal brain tissue while histologic examination showed gliosis only

Comments Target 4 seemed to be well inside the tumour The result of biopsy indicated that it was more likely situated near the posterior tumour border The tumour was undifferentiated and difficult to classify Lymphoma was considered a possible diagnosis The tumour had a solid appearance on CT with a diffuse outline and a moderate enhancement and was therefore first regarded as a glioma of Group A

Group B

These tumours had a solid appearance but they always contained a region of low attenuation of varying size The enhancement was considerable and the outline was therefore usually e isy to define The surrounding zone of low attenuation was not as evident as in Group C No sharp limit between this group and Group C could be ascertained



Fig 9 Expanding lesion of corpus callosum with marked enhancement after contrast medium ad ministration

Case 4 A 68 year old woman with 2 to 3 months history of increasing confusion and personality changes Scintigraphy Deep parietal bilateral uptake CT Great expanding lesion 4 cm × 6 cm at the site of the splenium of the corpus callosum (Fig 9) After injection of contrast medium a rather homogeneous enhancement of the tumour occurred on the right side and on the left side enhancement of a thin rim surrounding a region of low attenuation The lesion was surrounded by a zone of low att nuation In the right occipital lobe a well defined region with low attenua tion existed—probably a dilated posterior horn of the right ventricle Target 1 was expected to be situated in a necrotic or cystic area and all sections from this area showed necrotic tissue Targets 2 and 3 were regarded to be situated in tumour tissue and these sections showed a tissue considered to be an astrocytoma grade II The sample from target 4 showed oedematous tissue as was predicted Samples for cytology were not taken

Comments Histologically this tumour was classified as an astrocytoma grade III (presence of necrosis) This case shows the importance of taking samples from both low and high attenuating regions of a tumour for an adequate malignancy grading The tumour outline was well defined and no tumour tissue was found outside the enhanced areas The enhancement was considerable This tumour was assigned to Group B

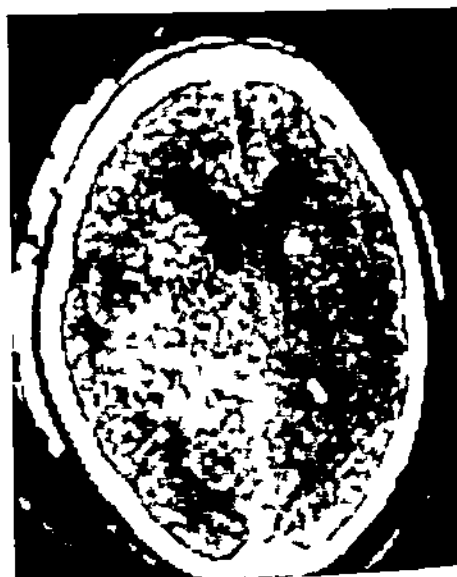


Fig 10 Expanding lesion of right thalamus displacing the trigone Marked enhancement after contrast medium injection

Case 5 A 68 year old man with hypertension and slowly deteriorating memory and increasing left paralysis during the last months Scintigraphy Intense uptake at the site of the right thalamus Carotid angiography Expanding lesion 5 to 6 cm in diameter with pathologic vessels and a fast shunting to the straight sinus CT Expanding lesion of the right thalamus deforming the right lateral ventricle and the posterior part of the third ventricle (Fig 10) After contrast medium injection marked enhancement of the tumour with a small region of low attenuation in its centre Target 1 was placed in what was expected to be solid tumour tissue Histologic examination showed astrocytoma grade III the cytologic examination was not conclusive but an astrocytoma with a low grade of malignancy was suggested Sections from target 2 showed polymorphic cells astrocytoma grade III while the cytologic preparations were technically unsatisfactory Target 3 contained cerebro spinal fluid as was predicted (the deformed posterior horn of the right lateral ventricle)

Comments The small central area of low attenuation did not contain necrotic tissue This astrocytoma grade III had a mainly solid structure with a rather well defined outline A considerable enhancement occurred after contrast medium injection The tumour has therefore been assigned to Group B

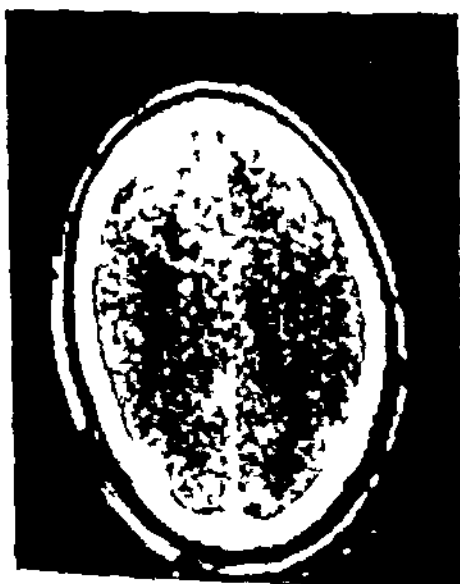


Fig 11 Parasagittal frontal expanding lesion with enhancement after contrast medium administration

Case 6 A 32 year old woman with a 6-month history of headache and Jacksonian fits Scintigraphy and angiography indicated a large frontal expanding lesion on the right side without abnormal vessels or shunting CT Expanding lesion in the ant rior part irregularly enhanced after contrast medium injection in the posterior part a spheric structure of low attenuation surrounded by a thin enhanced rim The entire process was surrounded by a zone of low attenuation (Fig 11) Target 1 was considered to be in solid tumour tissue and this was also found to be the cas Target 2 was supposed to be situated in a necrotic or cystic area the biopsy material contained tumour tissue with areas of necrosis Target 3 was selected to be in viable tumour and the sample was according to this prediction The same good correlation between CT and morphology was found for target 4 which was situated in the peritumoural area thought to represent oedematous brain tissue Cytologic examination of targets 1 to 3 revealed tumour tissue with high cell density astrocytoma grade IV Target 4 showed oedematous brain tissue without tumour cells

Comments This tumour was considered to be an astrocytoma grade III at histologic and grade IV at cytologic examination It had both low and high attenuating regions and the tumour borders were relatively well defined at CT The surrounding zone of low attenuation was less evident This tumour was assigned to Group B No tumour tissue was found outside the rim

Group C

This group was characterized by a central region of low attenuation surrounded by a markedly enhanced rim of varying thickness The outline was easy to define Around the entire lesion a considerable zone of low attenuation of varying size and extension existed



Fig 12 Astrocytoma grade III of the left thalamus

Case 7 A 62 year old hypertensive woman with a 3 month history of increasing paralysis of the right arm and leg Scintigraphy Well defined parietal process on the left side Carotid angiography Expanding process at the site of the left thalamus with pathologic vessels and early shunting to veins The diameter was estimated to be 5 cm CT Well defined expanding lesion of low attenuation in the same area surrounded by a rim with marked enhancement after contrast medium injection (Fig 12) The entire process was partly surrounded by a zone of low attenuation Target 1 consisted of oedematous brain tissue as was predicted The sample from target 2 placed in the rim consisted of an astrocytoma grade III on histologic examination From target 3 only fluid was obtained The samples from targets 4 and 5 were composed of the same tissue as from target 2 i e astrocytoma grade III The cytologic samples were technically unsatisfactory and no diagnostic evaluation was possible

Comments This case illustrates the high precision of the method and again supports the opinion that it is necessary to take samples from different parts of a tumour to get an adequate malignancy grading A sample taken from the middle part of this tumour would only have yielded fluid This well defined tumour with its marked enhanced rim has been assigned to Group C



Fig 13 A well-defined intra and suprasylvian lesion with a central region of low attenuation and a surrounding rim with considerable enhancement after contrast medium injection (astrocytoma grade IV)

Case 8 A 62 year old woman with a one month history of headache and recent dysphasia Neurologic examination showed a mixed sensory and motor aphasia Scintigraphy Large area of increased uptake at the site of the left Sylvian fissure CT Expanding lesion at the level of and above the left Sylvian fissure with a diameter of approximately 4 cm The central part of low attenuation was surrounded by a rim with a considerable enhancement after contrast medium injection (Fig 13) The whole process was surrounded by a wide zone of low attenuation most evident in the posterior part of the lesion The sample from target 1 inside the rim consisted of tumour cells and areas of necrosis The tumour was considered to be an astrocytoma grade IV The samples from the rim (target 2) all contained tumour tissue without necrosis considered alone this finding should indicate an astrocytoma grade III The next two samples targets 3 and 4 situated outside the rim did not contain any tumour cells but oedematous brain tissue as was supposed Cytologic examination was not carried out

Comments The central part of low attenuation does not always contain necrosis or cyst fluid sometimes viable tumour cells mixed with areas of tissue regression may be present This spherical well defined astrocytoma grade IV with an enhanced rim has been assigned to Group C

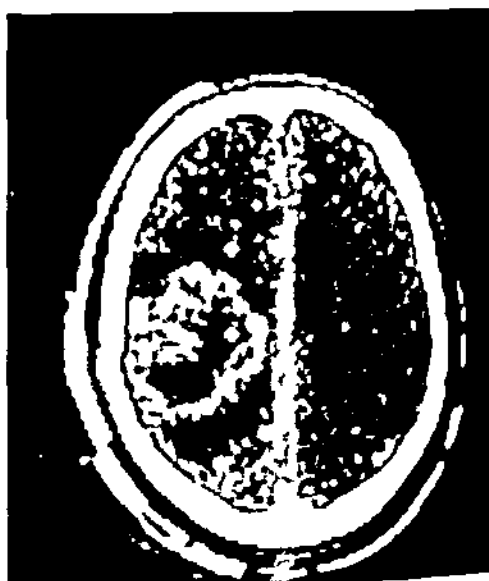


Fig 14 Right parietal expanding lesion with a well defined enhanced rim after contrast medium injection

Case 9 A 70 year old woman with increasing loss of sensibility in her left side for 2 months later developed paralysis of her left leg Scintigraphy Early uptake in the right parietal lobe Carotid angiography Right parietal tumour with abnormal vessels and early shunting of contrast medium to superficial veins CT A tumour at the same site which displayed an enhanced well defined rim after contrast medium injection (Fig 14) The diameter of the tumour was 5 to 6 cm and it was surrounded by a zone of low attenuation in the centre an irregular region of low attenuation Target 1 was supposed to be situated in oedematous brain tissue and this was also the case at both cytologic and histologic examination Target 2 was placed in the tumour rim and the histologic examination revealed an astrocytoma grade III The sections from target 3 mainly showed necrotic tissue Target 4 also placed in the tumour rim gave material with cells having an appearance consistent with an astrocytoma grade III in one end and oedematous brain tissue in the other The corresponding cytologic examination gave the following results 2 Degenerated and oedematous brain tissue in the anterior and necrotic tissue fragments in the posterior sample 3 necrotic material 4 normal brain tissue

Comments In this case the cytologic examination did not reveal the nature of the tumour probably due to the fact that the cytologic samples were taken from the ends of the cylinder The samples from targets 2 and 3 probably originated from sites in front of and behind the rather narrow tumour rim This astrocytoma grade III with a marked enhanced rim had a well defined outline and was assigned to Group C

Group D

These tumours had a more irregular and infiltrating appearance than the others They had intermingled areas of low and high attenuation and the enhanced tissue of high attenuation often formed irregular and sometimes incomplete rims around the areas of low attenuation giving the tumour an irregular cystic or multicystic appearance The outline was sharp in some parts and diffuse in other parts The zone of low attenuation surrounding these tumours was usually not as evident and wide as in Group C

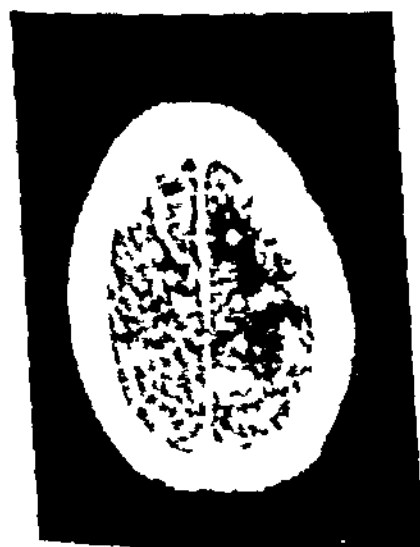


Fig 15 Left frontoparietal process with no or only faint enhancement after contrast medium injection

Cas 10 A 70 year old woman with increasing weakness in her right side and Jacksonian fits Carotid angiography Expanding lesion in the left parietal lobe No abnormal vessels could be demonstrated only early shunting to the veins Scintigraphy Faint uptake at the same site CT Large irregular region with lower attenuation than normal brain Around and inside this zone parts with higher attenuation existed and a faint enhancement after contrast medium injection occurred (Fig 15) The left lateral ventricle was depressed The periphery of the lesion was tough and therefore attempts to obtain usable samples from this part failed Immediate cytologic examination of the two biopsy samples obtained (1 2) had an appearance reminiscent of infarction and the biopsy procedure was terminated An astrocytoma grade IV with large infarcted areas was found 2 months later at autopsy



Fig. 16 Expanding lesion in the left parietal lobe considered as astrocytoma grade III–IV at histologic and cytologic examination

Case 11 A 51 year old woman with an increasing headache for the past 2 months and later nausea and vomiting Carotid angiography Large left sided parietal expanding lesion with pathologic vessels and early shunting to the veins CT Following injection of contrast medium the expanding lesion had a solid enhanced part posteriorly and in front of this a structure which could be a cystic lesion with a thin and slightly enhanced rim (Fig 16) Histologic and cytologic examinations gave the same diagnosis at all targets except the last one (5) Target 1 supposed to be situated inside the cystic process consisted neither of fluid nor of necrotic tissue but of tumour cells The samples from targets 2 to 4 all contained tumour cells of an astrocytoma grade III–IV in target 5 the cytologic examination of the posterior part of the sample showed no tumour cells This could indicate that the tumour border was situated here Target 5 was supposed to be outside the tumour

Comments This tumour considered to be an astrocytoma grade III–IV had a cystic appearance in the frontal region It had no sharp outline and it was actually impossible to determine where the oedema ended and the tumour tissue began The enhancement was slight This tumour has been assigned to Group D



Fig 17 Large parietal polycyclic tumour Multiple spherical regions of low attenuation surrounded by enhanced rims after contrast medium injection

Case 12 A 58 year old woman with 1½ months history of increasing difficulties in speaking and reading and a left sided headache Neurologic examination Central left paralysis of the facial nerve paralysis of the right arm and a sensory aphasia Scintigraphy Left parietal uptake of about 3 cm in diameter Carotid angiography Expanding lesion with abnormal vessels and early shunting to the veins CT Large left sided pari tal polycyclic tumour surrounded by a zone of low attenuation (Fig 17) The tumour consisted of multiple spheric regions of low attenuation surround d by enhanced rims after injection of contrast medium Target 1 consisted of oedematous brain tissue as supposed Target 2 placed immediately inside the rim consisted of oedematous brain tissue with no evident tumour cells at histologic examination The cytologic examination of the anterior and posterior part of the same sample showed tumour tissue of astrocytic cells consistent with a glioma grade III A sample from target 3 which was placed in a narrow zone of enhancement in the posterior part of the tumour consisted of astrocytoma grade III at both types of examination Target 4 was placed in an area of low attenuation predicted to represent either a tumour cyst or oedema Cytologic examination showed brain tissue with early infiltration of malignant tissue while the histologic sections showed glial ti sue with an increased cell density but no polymorphism

Comments No explanation can be given to the fact that the histologic examination of the sample from target 2 was negative although adjacent parts of the same sample showed tumour cells at cytologic examination This astrocytoma grade III had multiple regions of low attenuation with slightly enhanced margins The outline was irregular and difficult to define This tumour was assigned to Group D



Fig. 16 Expanding lesion in the left parietal lobe considered as astrocytoma grade III–IV at histologic and cytologic examination

Case 11 A 51 year old woman with an increasing headache for the past 2 months and later nausea and vomiting Carotid angiography Large left sided parietal expanding lesion with pathologic vessels and early *shunting to the veins* CT Following injection *of contrast* medium the expanding lesion had a solid enhanced part *posteriorly* and in front of this a structure which could be a cystic lesion with a thin and slightly enhanced rim (Fig 16) Histologic and cytologic examinations gave the same diagnosis at all targets except the last *one (5)* *Target 1* supposed to be situated *inside the* cystic process consisted neither of fluid nor of necrotic tissue *but of tumour* cells The samples from targets 2 to 4 all contained tumour cells of an astrocytoma grade III–IV in target 5 the cytologic examination of the posterior part of the sample showed no tumour cells *This could indicate* that the tumour border was *situated here* Target 5 was supposed to be outside the tumour

Comments This *tumour considered* to be an astrocytoma grade III–IV had a cystic *appearance in* the frontal region It had no sharp outline and it was actually *impossible* to determine where the oedema ended and the tumour tissue began *The* enhancement was slight This tumour has been assigned to Group D

Table I

Correlation between CT appearances and microscopy

Predicted morphology at CT	Microscopy					
	No abnormality	Oedema	Cyst	Necrosis	Tumour	Total
No abnormality	1	—	—	—	—	1
Oedema	3	8	—	—	1	12
Cyst	1	—	1	—	1	3
Necrosis				5	1	6
Tumour	1	—	—	1	21	23
Total	6	8	1	6	24	45

Discussion

A correct morphologic diagnosis was obtained in 11 of the 13 cases In one patient the biopsy specimens had an appearance reminiscent of infarction whereas autopsy carried out 2 months later showed an astrocytoma grade IV with infarctions in its periphery In this case it was not possible to get more than two biopsy samples and it appears that the samples were taken only from infarcted or necrotic tumour tissue The second failure of specific diagnosis concerned a patient with a glioma with a highly attenuating rim at the computer tomography The rim was rather narrow and the biopsy sample small which could explain why no tumour tissue was found in the sample

BOETHIUS et coll (1977) suggested that the area of low attenuation surrounding a tumour frequently consists of oedematous brain tissue the areas with high enhancement contain viable tumour cells and the areas with low enhancement viable tumour tissue necrosis or fluid Thus in the present series an attempt was made to predict the nature of the biopsy sample from the CT image The results appear in Table I Of 45 biopsy specimens 36 were predicted correctly as to their microscopy (80%) In 8 patients all specimens were correctly predicted The correlation between the morphologic appearances at CT and the pathologic grading appears in Table 2

In most stereotactic techniques the coordinate frame is fixed with screws to the bone of the skull The present technique implying fixation of the head with plastic bands has the advantage that one helmet can be used several times for the same patient thereby allowing repeated examinations or stereotactic procedures However this technique may increase the error inherent in the localization procedure A head fixation system using screws is therefore under development which will be applicable to both the CT scanner and the stereotactic frame

A CT image does not represent a two dimensional surface but the integration of the elements of a three dimensional section in two dimensions The needle when

Table 2

Groups of astrocytomas with similar morphology at CT and microscopic grading (KERNOHAN et coll 1949)

CT classification	No of cases	Grade
A	2	II
B	3	III
C	2	III
	1	IV
D	2	III
	1	III–IV
	1	IV

introduced into the center of the CT section will only obtain tissue from one mm of the 8 or 13 mm which contribute to the CT image Although histologic identification is not possible for tissues lying above or below the biopsy site these tissues contribute to the CT image at that point

Using a pixel size of 1 5 mm × 1 5 mm the accuracy in the determination of a position of a structure in the CT image will be about 1 5 mm For high attenuating structures it is possible to obtain a still better accuracy using interpolations Particularly for structures with an attenuation close to that of normal brain tissue errors like noise combined with low geometric resolution and the partial volume effect will considerably affect the determination of the position Another possible source of error might be mechanical instability of the stereotactic instrument

The number of correct CT based predictions of the histology of the biopsies was 36/45 (80 %, Table 1) This result corresponds to that presented by BOETHIUS et coll (1977) Twelve biopsies were considered to contain oedema microscopy indicated normal brain tissue in 3 of them Previously it was concluded (BOETHIUS et coll) that the area of low attenuation around a tumour consists of oedematous brain tissue The present results may seem to indicate the need to modify this conclusion However it is quite possible that CT is a more sensitive method for the detection of oedema than is the histologic examination where preparation results in tissue shrinkage The decrease in attenuation implies that the tissue has in fact a composition different from that of normal brain Two biopsies which were considered to be tumour tissue turned out to contain necrotic tissue in one case and normal brain tissue in one No reliable method to distinguish cysts from areas of necrosis with the guidance of the CT image only has been reveal^d as yet A regular smooth outline (as in Case 7) is not obligatory for cysts

Needle biopsy samples to grade gliomas are usually considered inadequate as such samples may not be representative for the whole tumour Using the present

system of multiple stereotactic biopsies in combination with CT it should be possible to reduce the incidence of incorrect grading The system could be improved if the crush smears were examined in the operating theatre permitting non diagnostic biopsies to be repeated

No significant differences were found between gliomas of Groups B C and D concerning the histologic grading according to KERNOHAN et coll Gliomas belonging to Group D having a more irregular and infiltrating growth are responsible for most of the errors of prediction especially concerning the position of the tumour outline The findings in Group A suggest that it should be possible to differentiate at least the gliomas of grade I and II from high grade gliomas and glioblastomas with the guidance of the CT This is in concordance with the findings of TCHANG et coll They found that low grade gliomas (I II) were low attenuating well defined and regular in shape with no or only a scarce perifocal oedema and no or only slight enhancement after contrast medium injection Gliomas of grades III and IV were more irregular and the enhancement higher frequently in the form of a rim surrounding a central area of low attenuation

MARKS & GADO emphasize that separation of primary brain tumours into subpopulations with different morphologic appearances may have prognostic significance In their material all (18) glioblastomas but only 40 per cent of the astrocytomas I and II showed a contrast enhancement suggesting that the latter tumour may have a worse prognosis if contrast enhancement is present

Computer tomography is a highly sensitive diagnostic modality and its non invasive properties have made it a better method for examination of a suggested tumour than any conventional technique Detailed analysis of stereotactic biopsy specimens and correlation to the various appearances of enhancement of the different components of the tumours will aid in the CT grading of gliomas The aim is to establish a correct classification of the grade of the tumour on the basis of CT examinations alone and determine the most suitable type of treatment to be given.

SUMMARY

A technique is introduced enabling automatic transfer of coordinates obtained at computer tomography into a stereotactic system previously applied in biopsies of brain lesions Four to five biopsies from different parts of gliomas were taken to compare the structures demonstrated on computer tomography with the microscopic appearances Of 45 biopsies in 13 patients 36 were predicted correctly This also served as an attempt to classify gliomas on the basis of their appearance in the CT image

ZUSAMMENFASSUNG

Eine Technik wird beschrieben die die automatische Überfuhrung von Koordinaten die bei der Computertomographie erhalten werden in ein stereotaktisches System erlaubt das zuvor bei Biopsien bei Gehirnveranderungen angewandt worden war Vier bis funf Biopsien

von verschiedenen Teilen von Gliomen wurden entnommen um die Strukturen die bei der Computertomographie nachgewiesen worden waren mit dem mikroskopischen Bild zu vergleichen Von 45 Biopsien bei 13 Patienten waren 36 richtig vorausgesagt Dieses dient auch als Versuch Gliome auf der Basis von deren Bildern bei der CT Darstellung, zu klassifizieren

RÉSUMÉ

Les auteurs presentent une technique permettant le transfert automatique des coordonnees obtenues en tomographie assistée par ordinateur vers un système stéréostaxique qui était utilise pour les biopsies des lésions cerébrales Quatre à cinq biopsies de différentes parties de gliomes ont eté prises pour comparer les structures mises en évidence par la tomographie avec ordinateur avec les aspects microscopiques Sur 45 biopsies effectuées chez 13 malades le resultat correct a eté prevu dans 36 cas Ceci a aussi servi comme essai de classification des gliomes sur la base de leur aspect sur l image en tomographie avec ordinateur

REFERENCES

BACKLUND E O A new instrument for stereotaxic brain tumour biopsy Acta chir scand 137 (1971) 825

BERGSTRÖM M Personal communication

— and GREITZ T Stereotaxic computed tomography Amer J Roentgenol 127 (1976) 167

— BOETHIUS J COLLINS V P EDNER G LEWANDER R and WILLEMS J A combined study with computer tomography and stereotactic biopsies in gliomas Selected Proceedings of the VI International Congress of Neurological Surgery Sao Paulo Brazil 1977 Excerpta Medica Amsterdam (in press)

BOETHIUS J COLLINS V P EDNER G LEWANDER R and ZAJICEK J Correlation between histology and computer tomography in gliomas assessed by multiple needle biopsies Acta neurochir 37 (1977) 304

— — — — — Stereotactic biopsies and computer tomography in gliomas Acta neurochir 40 (1978) 223

COLLINS V P ARBORGH B and BRUNK U A comparison of the effects of three widely used glutaraldehyde fixatives on cellular volume and structure Acta path microbiol scand Sect A 85 (1977) 157

HATAM A BERGVALL U LEWANDER R LARSSON S and LIND M Contrast medium enhancement with time in computer tomography Acta radiol (1975) Suppl No 346 p 63

KERNOHAN J MABON R SVIEN H and ADSON A A simplified classification of the gliomas Proc Mayo Clin 24 (1949) 71

LEKSELL L A stereotaxic apparatus for intracerebral surgery Acta chir scand 99 (1949) 229

— JERNBERG B and HAMMARSTROM G Quoted by Bergstrom & Greitz (1976)

MARKS J and GADO M Serial computed tomography of primary brain tumours following surgery irradiation and chemotherapy Radiology 125 (1977) 119

TCHANG S SCOTTI G TERBRUGGE K MELANÇON D BÉLANGER G MILNER C and ETHIER R Computerized tomography as a possible aid to histological grading of supratentorial gliomas J Neurosurg 46 (1977) 735

FROM THE DIVISION OF RADIOLOGY DEPARTMENT OF ORTHOPAEDICS AND TRAUMATOLOGY
DEPARTMENT OF NEUROSURGERY HELSINKI UNIVERSITY CENTRAL HOSPITAL, SF-00 60
HELSINKI FINLAND

MYELOGRAPHY IN LUMBAR SPONDYLOLISTHESIS

E M LAASONEN and J EHRSTRÖM

An insufficiency fracture of the pars interarticularis of the vertebral arch is considered to play a dominant role in the development of lumbar spondylolysis and spondylolisthesis (FARFAN et coll 1976 TROUP 1976) but an acute fracture may also be the cause (FULLENLOVE & WILSON 1974) A congenital malformation of the upper sacrum or lower lumbar vertebrae with a change of statics at the lumbosacral junction may be a contributory factor (FRIBERG 1939 TAILLARD 1976)

A total or subtotal impediment of the passage of contrast medium (oil or water soluble media) was the first myelographic abnormality observed in spondylolisthesis (IDELBERGER & PIA 1957 NEWMAN 1965) Numerous structures may compress the nerve roots along their extradural course and thus cause the lumbo-radicular syndrome in spondylolisthesis the dorsal margin of the vertebral body below the displaced body herniated disc and dorsal marginal osteophytes from the front pseudarthrotic mass at the lysis hypertrophied ligamentum flavum and upper margin of the displaced arch from behind as well as scar formations deformation of the intervertebral foramen and perhaps even stretching of the root (ADKINS 1955 DAVIS & BAILEY 1976 HIPP 1962)

A disc degeneration with displacement of a vertebra (so called pseudospondylolisthesis or degenerative spondylolisthesis) with an intact neural arch has much in common with that associated with lysis the myelographic abnormalities are virtually the same the hypertrophic structures caused by the degeneration being dominant (EPSTEIN et coll 1976 ROSENBERG 1976)

Supported by a grant from Ceaverken AB Sweden via the Finnish Radiological Society Submitted for publication 7 October 1977

Table 1

Level and degree of the olisthesis in 41 patients with lumbar spondylolisthesis and radicular syndrome

Olisthesis (degree)					Retroposition	
Level	2–9 mm	10–19 mm	20–29 mm	Total	Level	Total
L3–L4	2	—	—	2		—
L4–L5	8	3	—	11		—
L5–S1	15	11	2	28	L4–L5	8
Total	25	14	2	41		8

Only a few reports dealing with myelographic observations on true spondylolisthesis have been published The series of BARASH et coll (1970) and SCOVILLE & CORKILL (1974) with 8 and 13 oil myelographies resp ctively presented a spectrum from small indentations into the subarachnoid space to a total block Most of the abnormalities present at myelography with water soluble contrast medium were illustrated by HIPP In addition LAURENT (1958) commented upon about 20 patients with spondylolisthesis in whom the myelography sometimes indicated disc herniation or root compression

Material and Methods

During the last 5 years myelography was performed in 41 patients 18 females and 23 males aged between 22 and 72 years with spondylolisthesis and radicular syndrome involving one or both legs

From the conventional films of the spine the following abnormalities were assessed degree of slipping (LAURENT & ÖSTERMAN 1969) posterior wedging of the body of the affected vertebra (SIM 1973) other abnormalities in shape and size of the vertebrae or sacrum disc degeneration and arthrosis of the intervertebral joints Meglumine iocarmate (Dimer X) or metrizamide (Amipaque) was used as contrast medium The following myelographic abnormalities were recorded total or subtotal block of the subarachnoid space presence of disc herniation and the shape of the epidural fat behind the slipped vertebral body (IDELBERGER & PIA WELLAUER 1961) Confirmation of the observations was obtained at 16 operations

Results

The level and degree of spondylolisthesis is presented in Table 1 A retroposition at the L4–L5 level was observed in 8 patients with olisthesis at L5–S1 this retroposition exceeded 4 mm in 3 patients Retroposition was not observed in connection with olisthesis at a higher level

Posterior wedging occurred only in connection with L5–S1 olisthesis (23 of 28


Fig 1


Fig 2


Fig 3

Fig 1 Subtotal block at the level of the olisthesis L4–L5 Two wide veins traverse the nerve roots above the block (→)

Fig 2 Shallow epidural indentation beneath the olisthetic L4 body at operation hypertrophic longit dinal ligament without evidence of disc herniation

Fig 3 Root thickening and amputation of pocket above the olisthetic L5 (→)

patients) The posterior height of the L5 body was reduced by about 10 per cent in 8 patients 20 in 8 patients 30 in 6 patients and 40 per cent in one patient as compared with the height of the anterior part of the body In 5 patients no significant wedging was observed Also other abnormalities in size occurred in connection with olisthetic L5 hypoplasia of the arch in 7 cases hypoplasia of the body in 6 and posterior non fusion of the L5 arch in 2 cases Spina bifida of the S1 arch as well as nearthrosis of the L5 transverse processes with the sacrum were present in 12 cases as often associated with olisthesis at the L4 as at the L5 level

The disc between the displaced vertebra and the one below was usually reduced in height (24 of 27 patients) and arthrosis of the intervertebral joints occurred most often at the same level (20 of 25 patients) The only significant exception to this was 11 patients with such arthrosis above the olisthesis of the L5 arch With olisthesis at the L5–S1 level disc degeneration between these vertebrae was often marked and usually associated with intervertebral arthrosis at the same level or above On the other hand with olisthesis at L4–L5 disc degeneration at the olisthetic level was usually moderate and only occasionally associated with intervertebral arthrosis at this level A few of the latter patients also had arthrosis above the olisthesis possibly without causal relationship

Myelography A total block existed in 2 patients and a subtotal in 4 In 3 of these 6 patients the diagnosis of spinal canal stenosis was supported by the typical venous engorgement (Fig 1) In 5 cases stenosis was confirmed at operation In 3 further

Table 2

Changes in roots and pockets in 41 patients with lumbar spondylolisthesis and radicular syndrome

Olisthesis	Root pocket amputation			Root changes	
	Total	Symmetric	Asymmetric	Thickening	Atrophy
L3–L4	—	—	—	—	—
L4–L5					
Above (Root L4)	1	1	—	—	—
Below (Root L5)	7	3	4	1	—
L5–S1					
Above (Root L5)	14*	10*	4	4	2
Below (Root S1)	4	4	—	1	1

In 2 patients both below and above the olisthetic L5

patients indentations of the subarachnoid space were present both anteriorly and posteriorly in another 12 patients from the front only and in 2 from behind The indentations were considered too small to cause a clinically significant stenosis of the spinal canal

The epidural tissue behind the displaced vertebral body was concave against the subarachnoid space in 22 patients and straight in 8 In 5 patients the epidural tissue caused a shallow indentation in the subarachnoid space which was filled by contrast medium (Fig 2) In 2 of the latter cases as well as in 3 of the cases with disturbed passage a myelographic diagnosis of disc herniation was made At operation the diagnosis proved to be incorrect twice instead of a herniated disc mass the cause was bulging of the annulus fibrosus in one and hypertrophy of the posterior longitudinal ligament in another patient

Root pocket amputation was found in 24 patients in 18 it was symmetric (*Table 2*) With olisthetic L5 the root pocket amputation was situated above the olisthesis in 12 patients below in 2 and both below and above the olisthesis in another 2 patients (Fig 3) In 7 patients with olisthetic L4 the amputation was below and in one patient above the olisthesis With olisthetic L3 no root changes were demonstrated Because of the symmetry of the lesions estimation of the affected root was often difficult however in 6 patients the roots were regarded as thickered and in 3 as atrophic Nine patients with root pocket amputations were operated upon and in all of them scar formation of the epidural space or nerve canals correlated well with the radiologic observation

Discussion

LAURENT pointed to the coincidence of severe L5–S1 olisthesis and retroposition of L4 To this complex the hypoplastic abnormalities of L5 in 6 of 8 patients with retroposition in the present series may be added A marked disc degeneration at the

olisthetic L5–S1 level and arthrosis of the intervertebral joints at the same level or above were common although they seemed not to correlate with the hypoplastic abnormalities or retroposition On the contrary with olisthetic L4 no wedging or hypoplastic abnormalities were evident and the degenerative changes were less advanced Two explanations might account for this difference possibly the insufficiency fractures in the L5 arch occur earlier in childhood and cause hypoplastic changes and thereby more severe degenerative changes by disturbance of the statics of the spine The lysis in the L4 arch might occur later on in adolescence with less time for the hypoplasia to develop less effect on the statics and thus a smaller tendency to degeneration Another possibility would be to regard the hypoplastic anomalies as a primary factor causing a change in statics and thereafter the insufficiency fracture but this would leave the olisthesis without hypoplasia unexplained

A total or subtotal block to the passage of contrast medium indicates stenosis of the spinal canal and greatly strengthens the indication for a decompressive operation Quite often the operation has to be completed with a decompression of the root canal although it is difficult to reveal significant narrowing of the root canal by myelography in these cases

The diagnosis of disc herniation is difficult and less reliable in patients with olisthesis than without The root pocket changes which usually indicate disc herniation are of limited value and shallow indentations in the subarachnoid space can be caused by epidural tissues other than herniated disc masses However results from the present series do not agree with the opinion that disc herniation is a common cause of radicular syndromes in these patients either at or above the olisthetic level (DECKER 1960 SCOVILLE & CORKILL)

Root compression is the dominant cause of a radicular syndrome but the presence of radiologic abnormalities of the root or of its pocket (HIPP IDELBERGER & PIA WELLAUER) do not necessarily mean a severely affected root in immediate need of decompression several patients had multiple roots affected radiologically but only one affected clinically The L5 root seems to be the one most often affected in lumbar spondylolisthesis usually above L5 All the patients with severe retrolisthesis had the root affected as well as most of the patients with intervertebral arthrosis above the olisthetic L5 In many patients the cause of the root pocket abnormalities still remains unsolved maybe that the ample degenerative changes in L5 olisthesis cause the root lesions to be different from those encountered with L4 olisthesis

During the majority of the myelographies in the present series films were exposed with the patient standing but in only 2 patients whose olisthesis increased some millimetres did the upright position provide additional information Flexion-extension manoeuvres were not carried out during myelography and the present material does not permit evaluation of the use of such procedures in uncomplicated olisthesis or at postoperative myelography (LOWE et coll 1976 STEINBECK 1974) However in patients with back pain and radicular syndrome spasticity of the muscles of the back often prevents pathologic mobility at the olisthetic level

A rare but important indication for myelography seems to be disappointing neurologic results in patients operated upon for olisthesis with a reductive and stabilizing procedure (SCAGLIETTI et coll 1976) as a risk for an iatrogenic stenosis exists in these patients (SCHATZKER & PENNAL 1968)

Conclusions

The radiologic findings in patients with lumbar spondylolisthesis and a radicular syndrome can be divided into two types

(1) The L5-S1 olisthesis usually combined with posterior wedging of the body and often with hypoplasia of the body or arch The disc degeneration was often marked and arthrosis of the intervertebral joints appeared both below and above the level of the olisthesis Root pocket amputation without other radiologic signs and most often above the level of the olisthesis almost exclusively indicated root compression to account for the radicular syndrome

(2) The L4-L5 olisthesis was not associated with wedging of the vertebral body or hypoplasia and the degenerative changes were moderate Root pocket amputation was again the most common finding below the level of the olisthesis almost equally often various extradural structures caused a stenosis of the spinal subarachnoid space

Total or subtotal block to the passage of contrast medium by stenosis of the spinal canal is a strong indication for a decompressive operation The diagnosis of disc herniation is less reliable than in patients without olisthesis the indentations in the subarachnoid space can also be caused by hypertrophy of the longitudinal ligament or bulging of the annulus fibrosus The root pocket amputation obviously indicates scar formations but sometimes only one of the roots assumed to be compressed was associated with symptoms or signs

SUMMARY

Radiography and myelography of 41 patients with lumbar spondylolisthesis and radicular syndrome were analysed The L5 olisthesis in several aspects differed from the L4 olisthesis Root pocket amputation was the most common explanation for the radicular syndrome but sometimes present without clinical signs In this series disc herniation was uncommon and its diagnosis difficult Total or subtotal block of the subarachnoid space was also uncommon but this diagnosis enforced the indication for decompressive operation

ZUSAMMENFASSUNG

Röntgenuntersuchung der Wirbelsaule und Myelographie von 41 Patienten mit lumbaler Spondylolisthesis und einem Wurzel Syndrom wurden analysiert Die L5 Olisthesis unterscheidet sich in verschiedenen Hinsichten von der L4 Olisthesis Eine Amputation der Wurzeltasche war die gewohnlichste Erklarung fur das Wurzel Syndrom aber konnte jedoch auch zeitweise ohne klinische Zeichen vorhanden sein In dieser Serie war Diskushernie ungewohnlich und deren Diagnose war schwierig Ein totaler oder subtotaler Block des Subarachnoidalraumes war ebenfalls ungewohnlich, diese Diagnose verstarkt jedoch die Indikation einer dekompressiven Operation

RESUMÉ

Les radiographies et les myelographies de 41 malades atteints de spondylolisthésis lombaire et de syndrome radiculaire ont été étudiées Le glissement de L5 diffère à plusieurs points de vue du glissement de L4 L amputation de la gaine radiculaire est l explication la plus frequente du syndrome radiculaire mais parfois elle existe sans signe clinique Dans ces series la hernie discale a été rare et son diagnostic difficile Le blocage total ou subtotal de l espace sous arachnoidien a lui aussi été rare mais ce diagnostic a renforce l indication d une operation decompressive

REFERENCES

ADKINS E W O Spondylolisthesis J Bone Jt Surg 37 B (1955) 48

BARASH H L GALANTE J O LAMBERT C N and RAY R D Spondylolisthesis and tight hamstrings J Bone Jt Surg 52 A (1970) 1319

DAVIS I S and BAILEY R W Spondylolisthesis Indications for lumbar nerve root decompression and operative technique Clin Orthop 117 (1976) 129

DECKER K Klinische Neuroradiologie Georg Thieme Verlag Stuttgart 1960

EPSTEIN J A EPSTEIN B S LAVINE L S CARRAS R and ROSENTHAL A D Degenerative lumbar spondylolisthesis with an intact neural arch (pseudospondylolisthesis) J Neurosurg 44 (1976) 139

FARFAN H F OSTERIA V and LAMY C The mechanical etiology of spondylolysis and spondylolisthesis Clin Orthop 117 (1976) 40

FRIBERG S Studies on spondylolisthesis Acta chir scand (1939) Suppl No 55

FULLENLOVE T M and WILSON J G Traumatic defects of the pars interarticularis of the lumbar vertebrae Amer J Roentgenol 122 (1974) 634

HIPP E Gleitvorgange an der Lendenwirbelsaule und Moglichkeiten der Nervenbeeintrachtigung unter besonderer Berucksichtigung der Dysplasie des Wirbelbogens Z Orthop 96 (1962) 378

HIRSCH C ROSENCRANTZ M and WICKBOM I Lumbar myelography with water soluble contrast media With special reference to the appearance of root pockets Acta radiol Diagnosis 8 (1969) 54

IDELBERGER K und PIA H W Wurzel und Kaudaschadigungen bei der Spondylolisthesis und ihre Behandlung Z Orthop 89 (1957) 73

LAASONEN E M ALHO A KARAHARJU E O and PAAVILAINEN T Short term prognosis in sciatica A prospective study of factors influencing the results with special reference to myelography Ann Chir Gynaec Fenn 66 (1977) 47

LAURENT L E Spondylolisthesis A study of 53 cases treated by spine fusion and 32 cases treated by laminectomy Acta orthop scand (1958) Suppl No 35

— and ÖSTERMAN E Spondylolisthesis in children and aldolescents A study of 173 cases Acta orthop belg 35 (1969) 717

LOWE R W., HAYES T D KAYE J BAGG R J and LUEKENS JR C A Standing roentgenograms in spondylolisthesis Clin Orthop 117 (1976) 80

NEWMAN P H A clinical syndrome associated with severe lumbo-sacral subluxation J Bone Jt Surg 47 B (1965) 472

ROSENBERG N J Degenerative spondylolisthesis Surgical treatment Clin Orthop 117 (1976) 112

SCAGLIETTI O FRONTINO G and BARTOLOZZI P Technique of anatomical reduction of lumbar spondylolisthesis and its surgical stabilization Clin Orthop 117 (1976) 164

SCHATZKER J and PENNAL G F Spinal stenosis a cause of cauda equina compression J Bone Jt Surg 50-B (1968) 606
SCOVILLE W B and CORKILL G Lumbar spondylolisthesis with ruptured disc J Neurosurg 40 (1974) 529
SIM G P G Vertebral contour in spondylolisthesis Brit J Radiol 46 (1973) 250
STEINBECK W Die Funktionsdiagnostik bei lumbaler Myelographie Z Orthop 112 (1974) 801
TAILLARD W F Etiology of spondylolisthesis Clin Orthop 117 (1976) 30
TROUP J D G Mechanical factors in spondylolisthesis and spondylolysis Clin Orthop 117 (1976) 59
WELLAUER J Die Myelographie mit positiven Kontrastmitteln Georg Thieme Verlag, Stuttgart 1961

FROM THE SECTION OF NEURORADIOLOGY UNIVERSITY HOSPITAL, S 221 85 LUND SWEDEN, DEPARTMENT OF RADIOLOGY FONDATION OPHTALMOLOGIQUE A DE ROTHSCHILD, F 75019 PARIS AND DEPARTMENT OF RADIOLOGY, HÔPITAL BICÊTRE F 94270 LE KREMLIN BICETRE FRANCE

ARTERIAL SUPPLY OF CAROTID CAVERNOUS FISTULAS

J BRISMAR and P LASJAUNIAS

Reports concerning post traumatic carotico cavernous fistulas are abundant (for review see WENGER 1974) whereas the literature concerning spontaneous fistulas was limited essentially to reports of single cases until the presentation of relatively large clinical series by NEWTON & HOYT (1970) TANIGUCHI et coll (1971) DJINDJIAN et coll (1973) and BRISMAR & BRISMAR (1976 a)

Detailed knowledge of the feeding arteries of a fistula has gained importance with the introduction of catheter arterial embolization In the present clinical series recent anatomic knowledge is applied in a detailed analysis of the arterial supply of carotid cavernous fistulas

Anatomy

According to the classical concept the meningeal structures in the region of the cavernous sinus are essentially supplied by the lateral hypophyso meningeal trunk from the intracavernous part of the internal carotid artery (C4 segment) However radiologic as well as anatomic experiences point to an arterial meningeal network most elaborate at the skull base in the cavernous and clival regions (Fig 1) The arterial supply of this network is subject to large variations and has been presented in detail elsewhere (LASJAUNIAS 1975)

Submitted for publication 27 October 1977

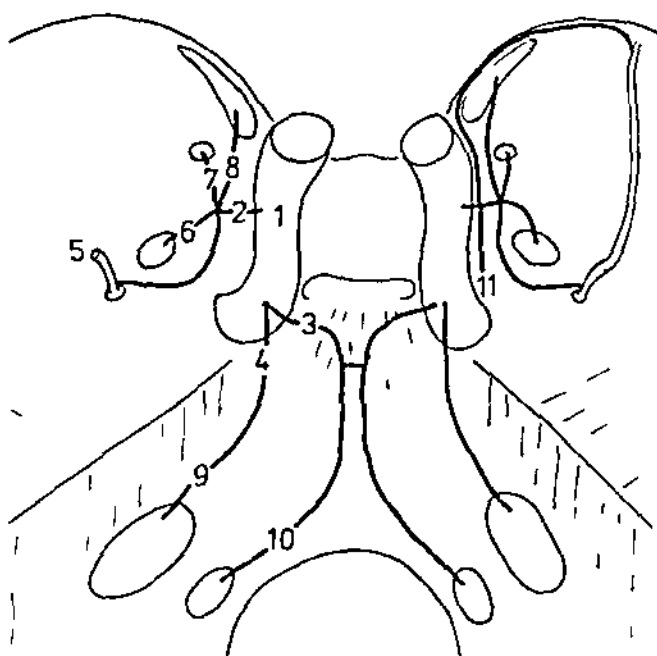


Fig 1 Arteries supplying the cavernous and clival regions Skull base view from above and behind 1 = internal carotid arteries 2 = lateral hypophyso meningeal trunk from internal carotid artery (C4) 3 medial and 4 = lateral clival branches from internal carotid artery (C5) 5 = middle meningeal artery entering via foramen spinosum 6 – accessory meningeal artery entering via foramen ovale 7 artery of the foramen rotundum 8 recurrent ophthalmic artery branches entering via the superior orbital fissure 9 and 10 – ascending pharyngeal artery branches entering via the jugular foramen and the anterior condyloid foramen (the hypoglossal canal) respectively 11 middle meningeal artery contribution via tentorial branch

The lateral hypophyso meningeal trunk forms anastomoses with the distal part of the maxillary artery through the foramen rotundum with intracranial branches of the middle meningeal artery in the vicinity of the Gasserian ganglion and with the intraorbital ophthalmic artery through the superior orbital fissure The ascending pharyngeal artery gives rise to two intracranial branches that enter the skull by the hypoglossal canal and the jugular foramen respectively The former branch joins the contralateral homologue and medial arteries of the clivus arising from the C5 part of the internal carotid artery in the basilar plexus on the clivus The latter branch (passing through the jugular foramen) forms anastomoses with the lateral arteries of the clivus (also originating from the C5 part of the internal carotid artery) at the inferior petrosal sinus The accessory meningeal artery may have an important role in the arterial supply of the cavernous region The extracranial anatomy of this artery has been described in detail by BAUMEL & BEARD (1961) and its intracranial anatomy and radiologic significance by LASJAUNIAS & THERON (1976)—those reports form the basis for the present description The accessory meningeal artery can be identified in dissections as well as at angiography in about 85 per cent of the cases The maxillary artery may pass either medially (40 per cent of the cases) or laterally to the external pterygoid muscle When the maxillary artery describes a deep course it usually gives off a common trunk for the lateral branches (the middle deep temporal and inferior alveolar arteries) while the medial branches (the middle and accessory meningeal arteries) originate separately when it has a superficial course it usually gives off a common trunk for the medial branches while the lateral branches originate separately The accessory meningeal artery in about 80 per cent of the cases sends an intracranial

branch through the foramen ovale or through the foramen of Vesalius to anastomose with the lateral meningo hypophyseal trunk of the internal carotid artery When the latter trunk is missing the accessory meningeal artery may be the only artery supplying the lateral part of the cavernous sinus

Material and Methods

The material consisted of 10 patients with a carotid-cavernous fistula examined in Lund in 1967 to 1974 Two additional cases examined by the authors were also included in the material The etiologic subgroups were (Table) I post traumatic fistulas (4 cases) II fistulas probably due to rupture of a demonstrable aneurysm (2 cases) and III spontaneous fistulas (6 cases)

The angiographic examinations often included basal projections in addition to a p and lateral views In the last 7 cases of this series orbital phlebography was carried out with a technique described in detail previously (BRISMAR 1974) in 3 phlebography via the inferior petrosal sinus (HANAFEE et coll 1965) was performed as well The symptoms and signs as well as the phlebographic findings in 6 of the patients in this material have been presented previously (BRISMAR & BRISMAR 1976 a b)

Results

The results are summarized in the Table

Post traumatic fistulas Two of the 4 traumatic fistulas were due to severe skull trauma with extensive skull base fractures In both of these cases carotid angiography demonstrated rupture of the intracavernous part of the internal carotid artery evaluation of a possible external carotid artery supply to the fistula was not feasible

The third post traumatic fistula was associated with a frontal skull fracture No skull base fracture could be demonstrated Common carotid angiography performed a few days after the trauma disclosed a carotid cavernous fistula only supplied from the C5 part of the internal carotid artery while repeat angiography after ligation of the internal carotid artery demonstrated a remaining fistula with supply from intra cranial branches of ipsilateral middle and accessory meningeal arteries

In the fourth case a piece of wood had perforated the medial part of the orbit and entered the anterior part of the cavernous region Unilateral common carotid angio graphy demonstrated a small fistula originating from the C5 part of the carotid siphon In spite of contrast filling of both the internal carotid artery and the maxillary artery neither the ophthalmic artery nor the middle meningeal artery could be identi fied Neither could any external carotid supply of the fistula be observed

Fistulas associated with a demonstrable arterial aneurysm In both cases in this group a saccular aneurysm on the C5 part of the internal carotid artery was demon

Table 1

Angiographic findings in 12 patients with carotid cavernous fistulas Group I post traumatic fistulas II fistulas presumably caused by rupture of an arterial aneurysm III spontaneous fistulas i e fistulas without demonstrable etiology i = internal e = external and c = common carotid angiography C4 C5 = segments of internal carotid artery MM and AM = middle and accessory meningeal arteries APh = ascending pharyngeal artery FR = artery of foramen rotundum VOS = superior ophthalmic vein IPS = inferior petrosal sinus PP = pterygoid plexus (+) denotes possible minor + slight + + moderate and + + + massive contribution of vessel to arterial supply or venous drainage of fistula

Group	Case No	Side	Vessels examined	Arterial supply						Venous drainage		
				C4	C5	MM	AM	APh	FR	VOS	IPS	PP
I	1	R	—									
		L	c		+ + +						+ + +	
	2	R	c		+ + +					+	+ + +	+ +
		L	c							+	+ + +	+ +
	3	R	i c[1]							+ +		+
		L	i + e[1]	+ + +		+	+ +	(+)	+	+ + +	+ +	+
	4	R	c + i		+ +						+ +	
		L	—									
II	5	R	c + i							+ + +		+ + +
		L	i + e		+ + +							+ + +
	6	R	c + i		+ + +					+ + +		
		L	c									
III	7	R	i + e		+ +			+[2]		+ +[3]	(+)	
		L	—									
	8	R	c									
		L	i + e				+ +			+ +		
	9	R	i + e				(+)	(+)				
		L	i + e	+		+ +	+ +	+ +	+ +	+ +		
	10	R	i + e		+		+ +	+	+ +	+ +		(+)
		L	i + e	+			(+)	+	+			
	11	R	i		+ +							
		L	i + e		+ +					+ +		
	12	R	—							+		
		L	i + e		+ +	+ +		(+)	+	+ +		

[1] The latter examination performed after ligation and trapping of left internal carotid artery
[2] Originating from the internal carotid artery
[3] Partly thrombotic

strated at angiography These fistulas were probably caused by a spontaneous aneurysm rupture and no external carotid supply to the fistulas could be demonstrated

Spontaneous carotid cavernous fistulas Six of the patients in the present series had spontaneous fistulas i e fistulas with neither a history of trauma nor a demonstrable



a



b



c

Fig 2 Spontaneous carotid-cavernous fistula (Case 10 Table) Angiography of the right external carotid artery a) A p b) lateral c) basal view Fistula fed by accessory meningeal (→) and ascending pharyngeal (↦) arteries as well as by artery of the foramen rotundum (⇸) draining through right superior ophthalmic vein (o→) Left ascending pharyngeal artery left artery of the foramen rotundum and both internal carotid arteries also participated in the supply of the fistula




Fig 3 Spontaneous carotid-cavernous fistula (Case 12 Table) left external carotid angiography a) A p b) lateral views Fistula supply by tentorial branch (→) of left middle meningeal artery (↔) as well as by artery of foramen rotundum (⇸) Left internal carotid artery and possibly also left ascending pharyngeal artery participated in supply of fistula Right sided angiography not performed (investigation undertaken only to confirm the presence of a fistula in a patient 71 years old)

arterial aneurysm In one of these cases the fistula was supplied from the ipsilateral accessory meningeal artery only and in one further case exclusively from both internal carotid arteries In the remaining 4 cases both external and internal carotid artery branches contributed In 3 or possibly all of these 4 cases the ascending pharyngeal artery participated in 3 the artery of the foramen rotundum and in 2 cases each the accessory (Fig 2) and middle meningeal (Fig 3) arteries Bilateral examinations were performed in 2 of these 4 cases and bilateral external carotid artery supply was demonstrated In 3 of the 6 cases countercurrent filling of feeding arteries was achieved at phlebography

Discussion

A multiple and even bilateral external and internal carotid supply of carotid cavernous fistulas has been described previously (HAYES 1963 CASTAIGNE et coll 1966 CLEMENS & LODIN 1968 LIE 1968 NEWTON & HOYT DJINDJIAN et coll) and is quite conceivable in view of the well developed arterial network in the cavernous

region and on the clivus (Fig 1) However the importance of the accessory meningeal artery in the supply of carotid-cavernous fistulas has not been appreciated previously Only isolated cases have been reported with participation of this artery (CLEMENS & LODIN DJINDJIAN et coll) In the present series it played an important role in the arterial supply of 4 of 6 fistulas with demonstrated external carotid supply in one case it constituted the only arterial supply of the fistula

The number of spontaneous fistulas in the present series is remarkably large The increasing number of reports on spontaneous fistulas during recent years is of course partly due to the increased use of selective angiography in the evaluation of orbital and intracranial disorders but the spread of the routine use of subtraction techniques is probably equally as important an explanation

The use of the a p view projecting the orbits above the petrous bones is advocated as it reveals even a minor shunting of contrast medium to the intraorbital veins This projection should always be included and may even be used as the single view to evaluate possible contralateral external or internal carotid artery supply Once the presence of a shunt has been established lateral and basal views are indispensable for the detailed analysis of the arterial supply and venous drainage

SUMMARY

The arterial supply of 12 carotid-cavernous fistulas (6 spontaneous fistulas 2 fistulas associated with arterial aneurysms and 4 post traumatic fistulas) is described and evaluated on the basis of recent reports on the arterial anatomy of the cavernous region

ZUSAMMENFASSUNG

Die arterielle Versorgung von 12 Fisteln (6 spontane 2 im Zusammenhang mit einem arteriellen Aneurysma 4 post traumatische) zwischen Arteria carotis und Sinus cavernosus werden beschrieben und auf der Basis von kurzlichen Berichten uber die arterielle Anatomie der Cavernosus Region festgestellt

RESUMÉ

Les auteurs decrivent les afferences artérielles de 12 fistules carotido-caverneuses (6 fistules spontanees 2 fistules associées à des anévrysmes artériels et 4 fistules post traumatiques) et les etudient sur la base des récents travaux sur l anatomie artérielle de la region caverneuse

REFERENCES

BAUMEL J J and BEARD D Y Accessory meningeal artery in man J Anat 95 (1961) 386
BRISMAR G and BRISMAR J (a) Spontaneous carotid-cavernous fistulas Clinical symptomatology Acta ophthal (Kbh) 54 (1976) 542
— — (b) Spontaneous carotid-cavernous fistulas Phlebographic appearance and relation to thrombosis Acta radiol Diagnosis 17 (1976) 180
BRISMAR J Orbital phlebography I Technique Acta radiol Diagnosis 15 (1974) 369

CASTAIGNE P LAPLANE D DJINDJIAN R BORIES J et AUGUSTIN P Communication ar terio veineuse spontanee entre la carotide externe et le sinus caverneux Rev neurol 114 (1966) 5
CLEMENS F and LODIN H Non traumatic external carotid-cavernous sinus fistula Clin Radiol 19 (1968) 201
DJINDJIAN R MANELFE C et PICARD L Fistules artério veineuses carotide externe–sinus caverneux Neurochirurgie 19 (1973) 91
HANAFEE W ROSEN L M WEIDNER W and WILSON G H Venography of the cavernous sinus orbital veins and basal venous plexus Radiology 84 (1965) 751
HAYES G J External carotid-cavernous sinus fistulas J Neurosurg 20 (1963) 692
LASJAUNIAS P Artère meningée moyenne (chez l homme) Thèse Paris 1975
— and THERON J Radiographic anatomy of the accessory meningeal artery Radiology 121 (1976) 99
LIE T A Congenital anomalies of the carotid arteries Excerpta Medica Foundation, Amsterdam 1968
NEWTON T H and HOYT W F Dural arteriovenous shunts in the region of the cavernous sinus Neuroradiology 1 (1970) 71
TANIGUCHI R M GOREE J A and ODOM G L Spontaneous carotid-cavernous shunts presenting diagnostic problems J Neurosurg 35 (1971) 384
WENGER M Fistules carotico-caverneuses Thèse Nancy 1974

FROM THE DEPARTMENT OF NEUROLOGY SÖDERSJUKHUSET S 100 64 STOCKHOLM SWEDEN

QUANTITATIVE CISTERNOGRAPHY

U LYING TUNELL

In 1953 the use of ^{131}I HSA or RISA was introduced for scintimyelography (BAUER & YUHL 1953) The CSF turnover of RISA was experimentally analysed by ISHIBASHI (1959) In man an exponential disappearance of RISA from CSF has been found following direct injection into the cerebral ventricles employing either serial sampling of CSF (ATKINSON & FOLTZ 1962) or external detection (MUNDINGER et coll 1963) DI CHIRO (1964) introduced RISA cisternography for evaluation of the movement of CSF after lumbar injection of the tracer and external scanning of the head This method was quantified (LYING-TUNELL et coll 1970) and later developed using different external detector devices (LYING TUNELL & SÖDERBORG 1972 a b)

Methods

Primarily a whole body scanner was used with a focussed collimator and a regional dot counting technique applied to the scintigrams (LYING TUNELL & SÖDERBORG 1972 a) This method had certain disadvantages and a stationary detector system with a long straight bore lead collimator was constructed The design and isoresponse curves of the collimator as well as its positioning in relation to the basal cisterns have been described previously (LYING TUNELL & SÖDERBORG 1972 b SÖDERBORG & LYING TUNELL 1973) After lumbar injection of 3 700 kBq (100 μCi) ^{131}I HSA measurements were performed from the basal cisterns and the parasagittal region in anterior projections (Fig 1) and from the left upper arm The disappearance of the tracer from the basal cisterns was exponential and thus a biologic half time

The author is now at Department of Neurology Huddinge Sjukhus S 141 86 Huddinge Submitted for publication 23 December 1977

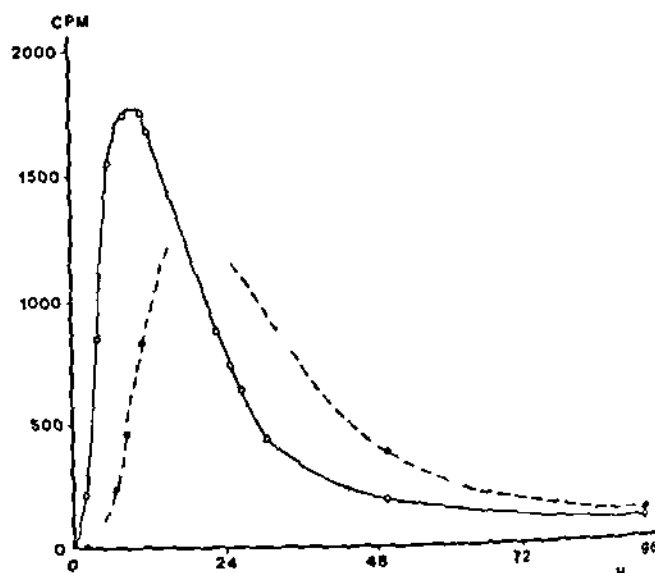


Fig 1 Measurements from basal cisterns (○) and parasagittal region (●) in one patient after subarachnoid injection of [131]I HSA

(BHT) of the clearance could be calculated (Fig 2) Curves recorded from the parasagittal region were often more irregular

Tissue background Calculations were based on measurements with the stationary detector from the basal cisterns after intravenous and subarachnoid injections respectively (LYING TUNELL & SÖDERBORG 1972 b) After intravenous injection the quotient of basal cistern to arm activity was fairly constant and thus it was possible to calculate approximately the magnitude of the contribution of tissue background at different times Assuming that one week after subarachnoid injection most of the tracer has left the CSF which is then in equilibrium with other tissues the ratio of basal cistern to arm activity was calculated one week after subarachnoid injection for cisternography With the correction factor thus obtained repeat measurements of count rates over the arm were used to calculate the tissue background in the region of the basal cisterns at different times The BHT was always shorter after correction for tissue background the contribution of which obviously increases with time The level of tissue background was found to vary considerably between different examinations intraindividually as well as interindividually

The method including corrections for isotope decay and for room and tissue background was applied prospectively in a series of 70 patients examined with isotope cisternography (LYING TUNELL 1977) The nomenclature for tracer kinetics suggested by BROWNELL et coll (1968) was used Each point on the curves was weighted with regard to the total error mainly dependent on counting statistics However the differences between weighted and non weighted values were small and did not significantly influence the BHT calculations The error in determining these separate points estimated by repeating the measurements in the same patients within 30 min

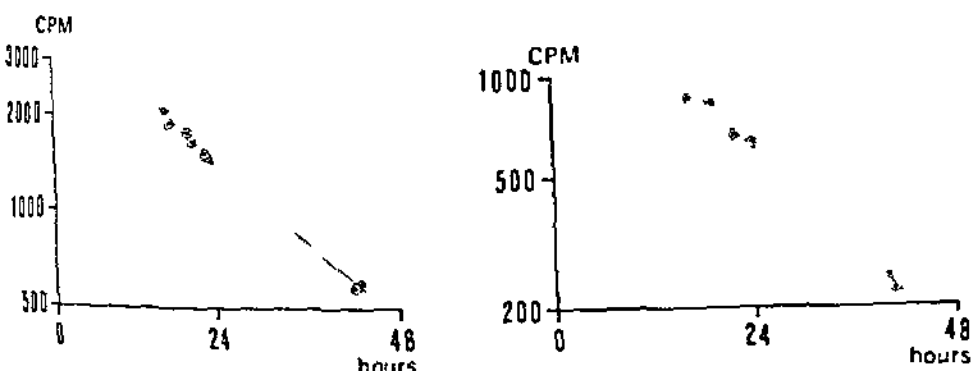


Fig . Representative semilog curves from 2 patients measured over the basal cisterns

after repositioning the detector was found to be 3 8 per cent (n =67 pairs) The straight lines obtained in semilogarithmic plots derived from measurements after peak activity had been reached viz. after 16 up to 48 h following injection They had high correlation coefficients with r values 0 99 in 64 of the 70 cases The error in deter minin the individual BHT calculated as the median of the standard deviations in the 70 curves was found to be 5 per cent of the mean BHT Correction for tissue background in these 70 cases caused an average decrease of BHT of 20 per cent (SE 2% range 0–69%)

Reproducibility During several years quantitative cisternography was performed twice in a number of patients usually because at the first attempt the amount of activity reaching the skull was insufficient for scintigraphy though it was enough for quantitative measurements with the stationary detector Patients with a major head injury or any other incident which could possibly have affected the CSF system between the 2 examinations were excluded Fourteen patients with repeat cisternography remained for evaluation of the reproducibility of the method 7 with dementia The interval between the 2 cisternographies ranged from one to 9 months The individual BHT values are given in Fig 3 The relative error of this method of deter mining cisternographic BHT was calculated to be 11 per cent

Clinical aspects

Biologic half time of basal cistern clearance In the series of 70 patients isotope cisternography and encephalography were performed (LYING TUNELL 1977) The degree of dementia was based on neurologic and psychometric exploration (LYING TUNELL & MARIONS 1975 b) The disappearance rate of the tracer from the basal cisterns was significantly slower in patients with dementia of different origins than in the subjects without obvious brain injury i e the BHT was significantly longer ($p<0.001$) in the patients with dementia (Fig 4 a) even when considering separately

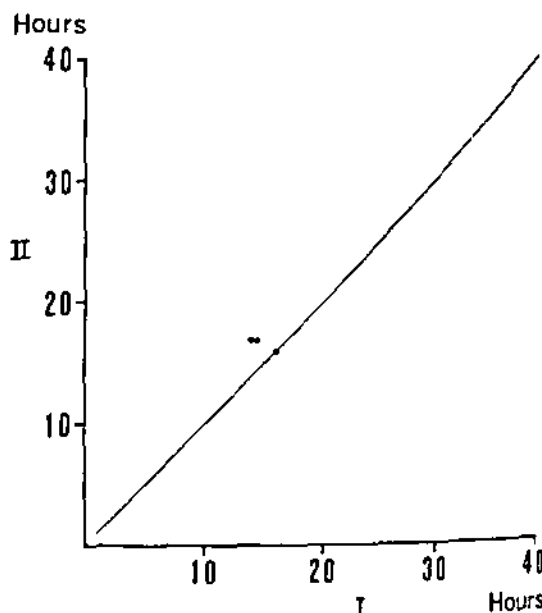


Fig 3 Biologic half time from 14 patients having undergone 2 cisternographies (I and II) r = 0 97 p < 0 001 (with the point in the upper right corner excluded r = 0 83 p < 0 001)

those with only slight mental reduction The 17 presumably normal subjects had a mean BHT of 9 8 h (SD 4 1) The values in this group were fairly well separated from those with marked dementia 12 h constituting a borderline value

At encephalography the BHT values correlated best with the presence of biparietal convexity air block (LYING TUNELL & MARIONS 1975 a b MARIONS & LYING TUNELL 1977) Evan s index and the transversal width of the posterior part of the third ventricle The combined results from encephalography and quantitative isotope cisternography had the best discriminative power in that all patients with mental reduction of any degree had BHT > 12 h, or parietal air block or both

Encephalography is now to some extent replaced by computer tomography (CT) GADO et coll (1976) found a close correlation between CT findings and those at isotope cisternography in dementia

Normal pressure hydrocephalus and effect of CSF shunting Four patients with normal pressure hydrocephalus according to classic criteria (OJEMANN et coll 1969) were examined by quantitative cisternography before and after clinically successful ventriculo atrial shunting ad modum Pudenz using a low pressure valve One of these patients had a history of subarachnoid hemorrhage and a duration of symptoms of 3 months one a history of stereotactic cerebral surgery for parkinsonism and a duration of symptoms for 21 months in the remaining 2 patients no etiology was known and the duration of symptoms was 6 years Observation time after shunting ranged between 2 5 and 4 years All improved considerably One of the patients with idiopathic hydrocephalus a 66 year old woman had a clinical history of progressive deterioration for 6 years She was disoriented with a Korsakoff defect

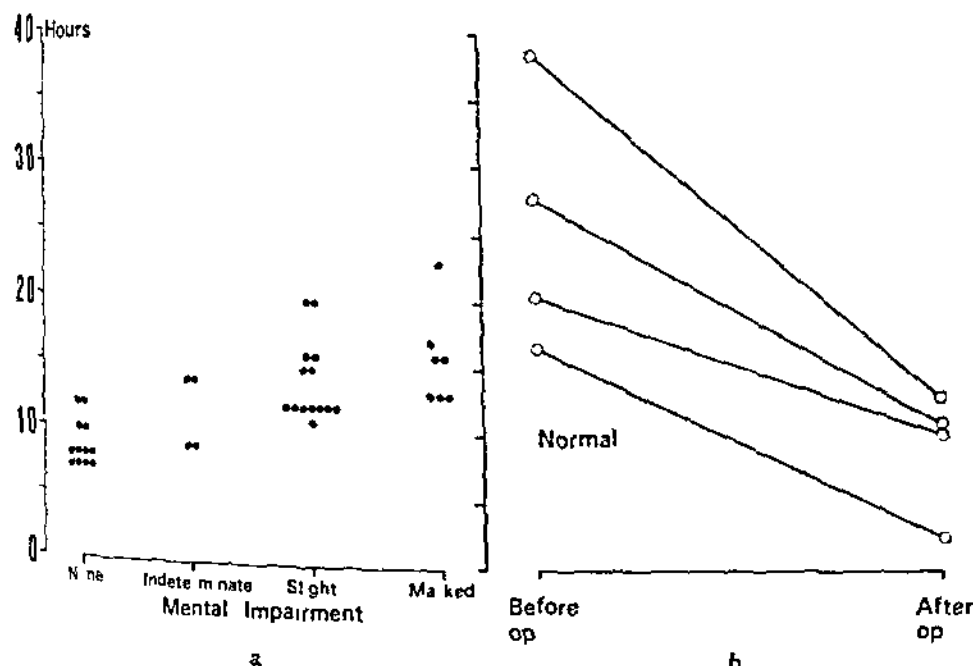


Fig 4 Biologic half time a) from the basal cisterns in relation to mental impairment (from Neurology 27 (1977) 460) and b) in 4 patients before and after ventriculo-atrial shunting

of memory unable to walk stand or even sit by herself and was incontinent An excellent although somewhat unexpected clinical improvement ensued a shunting procedure she became continent able to walk without any difficulty and was discharged from the hospital in an improved mental state a slight memory disorder being the only residue The observation time was 4 years

The patient with subarachnoid hemorrhage had a similar course of excellent improvement The remaining 2 patients also improved considerably after shunting

Encephalography and isotope cisternography were performed in all patients before shunting all had a marked communicating hydrocephalus persistent ventricular isotope activity and a convexity block for both air and isotopes The washout of RISA from the basal cisterns was calculated using the correction for tissue background the BHT values appear in Fig 4 b Before shunting the washout was slow after shunting the BHT values were all shorter and fell well within the postulated normal range Postoperative isotope cisternography indicated flow of activity to the ventricles after 24 h more or less persistent also after 48 h No apparent activity was recorded in the Sylvian or interhemispheric fissures nor over the convexity except possibly in one case In 2 patients cisternography using different isotopes was performed several years after shunting (Figs 5 6) The patients were then still in the same good clinical conditions with functioning shunts and with scintigraphic indication of a reversed flow

It is of interest to compare these results with those previously obtained by the



Fig 5 Cisternography using ^{99}Tc^{m} HSA 3 5 years after shunting Anterior views after a) 5 b) 24 and c) 48 hours Activity in the ventricles and Sylvian fissures even after 48 h in spite of the short physical half time of the isotope used

scintigraphic method for quantitative cisternography (LYING TUNELL & SÖDERBORG 1972 a) and a regional dot counting technique (LYING TUNELL & SODERBORG 1972 c) though this method was admittedly somewhat crude At that time ventriculo atrial shunts were inserted in 6 patients with presenile dementia but no gait disturbance or urinary incontinence These patients had cisternographic and encephalographic findings consistent with cerebral atrophy according to the criteria given by PATTEN & BENSON (1968) The clearance of isotope from the basal cisterns was slow The operation did not result in a significant clinical improvement Quantitative cisternography was carried out pre and postoperatively in 4 of these patients revealing no significant change of BHT preoperatively the mean BHT from the basal cisterns was 22 h (range 18–28 h) postoperatively 23 h (range 18–28 h)

Discussion

It is essential to evaluate the different compartments of the CSF space separately in order to avoid composite curves of different modes of flow The curves from the basal cisterns closely fitted a mono exponential function This supports the assumptions that one compartment was observed (SHIPLEY & CLARK 1972) with uniform distribution of activity and no further inflow of activity into the compartment under observation These 2 factors constitute prerequisites for the calculation of BHT (SOLOMON 1949 LYING-TUNELL & SÖDERBORG 1972 a SÖDERBORG & LYING TUNELL) In the basal cisterns marked pulsative movements have been observed (DU BOULAY et coll 1972) promoting a thorough mixing of the injected isotope with CSF in this region Part of the interhemispheric fissure projects over the basal cisterns in the view used for measurements but these regions constitute a directly continuous compartment

The great variation in tissue background between different examinations indicates

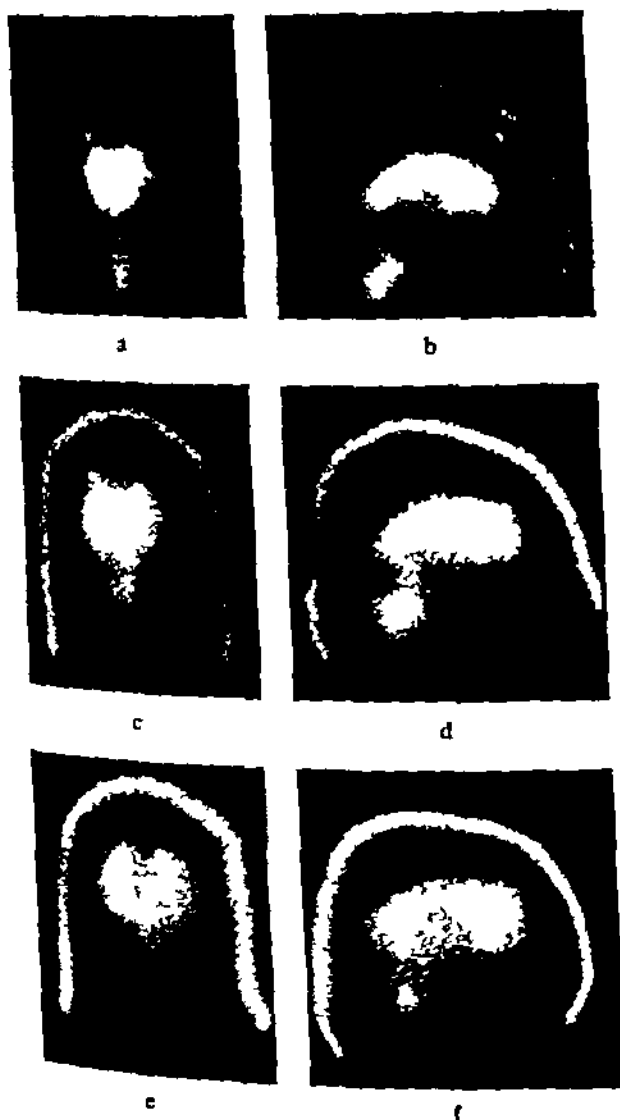


Fig. 6 Cisternography using [111]In DTPA 4 years after shunting. Anterior and lateral views after a b) 6 c, d) 24 e f) 48 and 72 hours respectively Activity only in the ventricles as a sign of reversed flow The shunt valve is demonstrated at 6 and 24 hours

that it is important to account for this factor The indicator substance may leave the CSF space along nerves (STEER & HORNEY 1968) or leak to surrounding tissues a the site of injection causing the hot spot which is often encountered Thus the method of measuring the transport of isotopes from CSF to blood which has been used for assessing hydrocephalus (ABBOTT & ALKSNE 1968) is subject to various technical errors (WILLIAMS et coll 1970) MAHALEY et coll (1974) compared nuclide levels in blood at isotope cisternography in 15 patients with probable normal pressure hydrocephalus and 22 considered to have Alzheimer s disease The clinical course of each patient was followed by review of the records They found a higher mean blood activity in the latter group but there was a considerable overlap in low

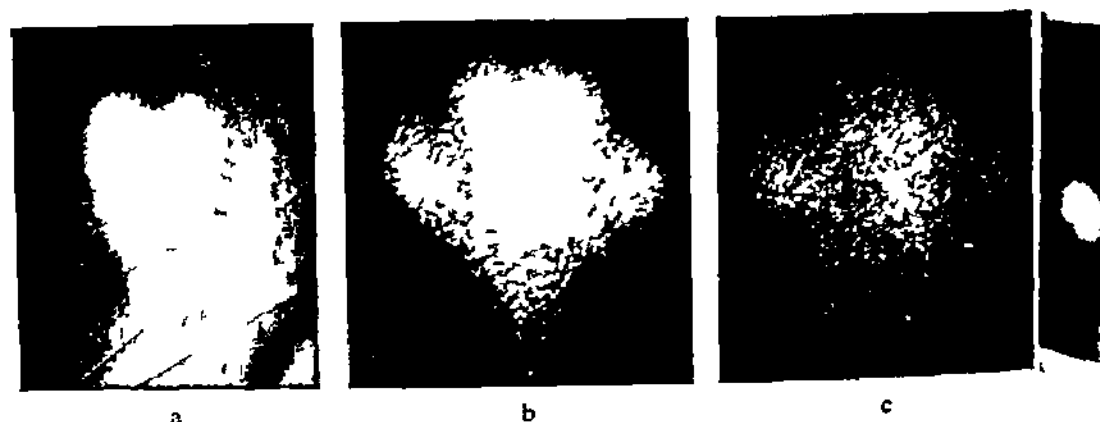


Fig 5 Cisternography using $^{99}Tc^{m}$ HSA 3 5 years after shunting Anterior views after a) 5 b) ? and c) 48 hours Activity in the ventricles and Sylvian fissures even after 48 h in spite of the shor physical ha f time of the isotope used

scintigraphic method for quantitative cisternography (LYING-TUNELL & SÖDERBORG 1972 a) and a regional dot counting technique (LYING TUNELL & SÖDERBORG 1972 c) though this method was admittedly somewhat crude At that time ventriculo-atri shunts were ins rted in 6 patients with presenile dementia but no gait disturbance o urinary incontinence These patients had cisternographic and encephalographi findings consistent with cerebral atrophy according to the criteria given by PATTEN & BENSON (1968) The clearance of isotope from the basal cisterns was slow The opera tion did not result in a significant clinical improvement Quantitative cisternograph was carried out pre and postoperatively in 4 of these patients revealing no significar change of BHT preoperatively the mean BHT from the basal cisterns was 22 l (range 18–28 h) postoperatively 23 h (range 18–28 h)

Discussion

It is essential to evaluate the different compartments of the CSF space separate in order to avoid composite curves of different modes of flow The curves from th basal cisterns closely fitted a mono-exponential function This supports the assum tions that one compartment was observed (SHIPLEY & CLARK 1972) with unifor distribution of activity and no further inflow of activity into the compartment und observation These 2 factors constitute prerequisites for the calculation of BH (SOLOMON 1949 LYING TUNELL & SÖDERBORG 1972 a SÖDERBORG & LYING-TUNELL In the basal cisterns marked pulsative movements have been observed (DU BOUL et coll 1972) promoting a thorough mixing of the injected isotope with CSF in th region Part of the interhemispheric fissure projects over the basal cisterns in t view used for measurements but these regions constitute a directly continuous cor partment

The great variation in tissue background between different examinations indica

with other reports (ALKER & LESLIE 1969 MATIN et coll 1970 McCULLOUGH et coll 1972 CURL et coll 1972) McCULLOUGH et coll and CURL et coll also found that total head count curves had an earlier peak and a more rapid clearance after shunting

Formation and absorption of CSF takes place throughout the subarachnoid space with varying rate of exchange for different constituents (SWEET et coll 1954) Thus the turnover of CSF may be increased also by drainage backwards The disappearance rate of the injected activity is of course volume-dependent (LYING-TUNELL & SODERBORG 1972 a SIEGEL & JOHNSON 1974) A postoperative decrease in size of the basal cisterns if any would thus contribute to a shortening of the BHT from this reason An increased washout of metabolites from the CSF or in the case of changed surface to volume ratio an improved exchange rate of different substances between the brain and the CSF might improve brain metabolism and thus have bearing upon the clinical improvement after shunting (LYING TUNELL 1977) Consistent with this hypothesis a decreased cerebral metabolism was found in a group of 7 patients with normal pressure hydrocephalus as compared with 10 healthy subjects approaching normal levels after clinically successful shunting (LYING TUNELL et coll 1977)

A slow CSF turnover is closely correlated with mental reduction but not with age per se (LYING-TUNELL 1977) HENRIKSSON & VOIGT (1976) recently claimed that the CSF flow not only decreases with increasing age but also that this decrease is directly dependent on age They examined a series of cisternograms which they regarded as normal but the criteria for normality were dubious They did not report the clinical diagnoses or mental states of the patients It is well known that patients with brain atrophy have a topographically normal distribution of activity over the convexities at cisternography although delayed (DELAND et coll 1971) It is also well known that in older age groups dementia is probably the most important indication for cisternography with the aim of selecting patients with normal pressure hydrocephalus who might benefit from shunting Thus a clinically unselected group of patients will have cisternographic changes concomitant with age in the same way as signs of myocardial infarcts at ECG are more frequent in older age groups (LYING TUNELL 1978) The signs of a slow CSF flow which HENRIKSSON & VOIGT found in older age groups may well be associated with mental reduction At any rate their results obviously cannot prove the existence of a causal relationship between cisternographic changes and age per se

The described method of quantitative cisternography has theoretical as well as clinical implications since it constitutes a nearly atraumatic way of determining one important compartment of CSF flow under almost physiologic conditions The reproducibility was good at repeat examinations of the same patients in a clinical steady state The slow isotope washout in patients with dementia has theoretical interest and the method has practical diagnostic importance in differentiating these patients from for instance those with mental depression It contributes to the diagnosis of disturbances of CSF flow and offers possibilities of estimating the effect of different therapeutic measures on CSF turnover

The technique for regional and quantitative cisternography is now adopted to the use of ^{111}In DTPA and a computer assisted gamma camera which has certain practical advantages In a preliminary series of examinations by this method straight lines were obtained from the basal cisterns in semilogarithmic plots (LYING-TUNELL et coll 1978) Tissue background was negligible Chelate has a greater transependymal diffusion than albumin which has a molecular weight about 100 times that of chelate (HARBERT et coll 1973) PARTAIN et coll (1976) concluded from their work with mathematical models that transmeningeal transport was the major route of elimination of ^{111}In DTPA from CSF although thereby invalidating one of the assumptions for their models The fact that the late images at indium cisternography were somewhat blurred supports this view The apparent diffuse dispersal of ^{111}In DTPA was considered by SCHOSSBERGER & TOUYA (1976) as providing evidence that cisternography does not demonstrate CSF flow However this statement does not seem to be true for cisternography using ^{131}I HSA First linear scans demonstrated an effective movement of the activity towards the cranium (LYING TUNELL & SÖDERBORG 1972 a) Second significant correlations were found between clearance rate of the activity and clinical conditions in particular clearance rates normalized after shunting (Fig 4) Probably compounds of higher molecular weight than chelate such as albumin or inulin are more suitable for evaluation of CSF dynamics under the condition that subtraction is made for tissue background

SUMMARY

By quantitative cisternography using a stationary detector system with correction for tissue background an exponential elimination of ^{131}I HSA from the basal cisterns was demonstrated allowing calculation of a biologic half time (BHT) of the clearance curve at a satisfactory level of reproducibility Normal range of BHT was calculated Demented patients had significantly longer BHT In 4 patients with normal pressure hydrocephalus prolonged BHT turned normal after shunting paralleled by marked clinical improvement in contrast to previous findings in 4 patients with presenile dementia The method is now being modified employing ^{111}In DTPA and a computer assisted gamma camera for regional dynamic analysis

ZUSAMMENFASSUNG

Durch quantitative Cisternographie unter Anwendung eines stationaren Detector systems mit Korrektion fur den Gewebehintergrund wurde eine exponentionelle Elimination von ^{131}I HSA von den basalen Cisternen nachgewiesen die eine Berechnung der biologischen Halbwert Zeit (BHT) der Ausscheidungskurve bei einem zufriedenstellenden Niveau von Reproduzierbarkeit erlaubt Der normale Bereich der BHT wurde berechnet Demente Patienten hatten eine signifikant langere BHT Bei 4 Patienten mit Hydrozephalus mit normalem Druck normalisierte sich die verlangerte BHT nach einer Shuntoperation in Parallelitat zu einer bedeutenden klinischen Verbesserung im Gegensatz zu fruheren Befunden bei 4 Patienten mit praseniler Demens Die Methode ist nun verandert unter Anwendung von ^{111}In DTPA und einer Computer unterstutzten Gammakamera fur eine regionale dynamische Analyse

RESUMÉ

La cisternographie quantitative utilisant un système de détecteur stationnaire avec correction pour le bruit de fond des tissus, a permis de mettre en évidence une élimination exponentielle de [131]I HSA à partir des citernes basales permettant de calculer une demi vie biologique (BHT) de la courbe de clearance avec un niveau satisfaisant de reproductibilité Les auteurs ont calculé un intervalle normal de BHT Les patients déments ont une BHT significativement plus longue Chez 4 malades atteints d hydrocéphalie à pression normale la BHT prolongée est revenue à la normale après dérivation accompagnée par une amélioration clinique importante et contrastant avec les résultats obtenus précédemment chez 4 malades atteints de démence pre sénile Cette méthode est maintenant modifiée en utilisant [111]In DTPA et une gamma-caméra assistée par ordinateur pour une analyse dynamique regionale

REFERENCES

ABBOTT M and ALKSNE J F Transport of intrathecal I[131]RISA to circulating plasma Neurology (Minneap) 18 (1968) 870

AKERMAN M DE TOVAR G and GUIOT G Radioisotope cisternography and ventriculography in noncommunicating hydrocephalus *In* Cisternography and hydrocephalus, p 483 Edited by J C Harbert D C McCullough A J Luessenhop and G Di Chiro Charles C Thomas Springfield Ill 1972

ALKER G J and LESLIE E V Isotope cisternography and ventriculography Acta radiol Diagnosis 9 (1969) 589

ATKINSON J R and FOLTZ E L Intraventricular RISA as a diagnostic aid in pre and postoperative hydrocephalus J Neurosurg 19 (1962) 159

BAUER F K and YUHL E T Myelography by means of [131]I The myeloscintigram Neurology (Minneap) 3 (1953) 341

BELLONI G B The diffusion of substances in the subarachnoid spaces J Neurol Neurosurg Psychiat 14 (1951) 314

BROWNELL G L BERMAN M and ROBERTSON J S Nomenclature for tracer kinetics Int J appl Radiat 19 (1968) 249

CURL F D HARBERT J C and MCCULLOUGH D C Quantitative cisternography An aid to diagnosis *In* Cisternography and hydrocephalus p 441 Edited by J C Harbert D C McCullough A J Luessenhop and G Di Chiro Charles C Thomas Springfield Ill 19[illegible]

D LAND F H JAMES JR A E WAGNER JR H N and HOSAIN F Cisternography with [169]Yb-DTPA J nucl Med 12 (1971) 683

DI CHIRO G Movement of the cerebrospinal fluid in human beings Nature 204 (1964) 290

— Observations on the circulation of the cerebrospinal fluid Acta radiol Diagnosis 5 (1966) 988

DU BOULAY G O CONNELL J CURRIE J BOSTICK T and VERITY P Further investigations on pulsative movements in the cerebrospinal fluid pathways Acta radiol Diagnosis 13 (1972) 496

GADO M H COLEMAN R E LEE K S MIKHAEL M A ALDERSON P O and ARCHER C R Correlation between computerized transaxial tomography and radionuclide cisternography in dementia Neurology (Minneap) 26 (1976) 555

GRIFFITH H B and STADDON G Transventricular absorption and isotope ventriculography Arch Neurol 28 (1973) 272

HARBERT J C HADDAD D and MCCULLOUGH D C Quantitation of cerebrospinal fluid shunt flow Radiology 112 (1974) 379

— REED V and MCCULLOUGH D C Comparison between ¹³¹I HSA and ¹⁶⁹Yb-DTPA for cisternography J nucl Med 14 (1973) 765

HENRIKSSON L and VOIGT K Age dependent differences of distribution and clearance patterns in normal RIHSA cisternograms Neuroradiology 12 (1976) 103

HOCHWALD G M and WALLENSTEIN M Exchange of albumin between blood cerebro spinal fluid and brain in the cat Amer J Physiol 212 (1967) 1199

ISHIBASHI T Studies on the dynamics of the cerebrospinal fluid using radioactive isotopes Part I The formation and the absorption of cerebrospinal fluid Tohoku J exp Med 70 (1959) 49

LEE J C and OLSZEWSKI J Penetration of radioactive bovine albumin from cerebrospinal fluid into brain tissue Neurology (Minneap) 10 (1960) 814

LYING TUNELL U Cerebrospinal fluid turnover and convexity block in mental impairment A controlled prospective study Neurology (Minneap) 27 (1977) 460

— Letter to the Editor Neuroradiology 14 (1978) 275

— and MARIONS O (a) Air filling of the subarachnoid space over the cerebral convexities at repeat encephalography Neuroradiology 9 (1975) 187

— — (b) A triad of airencephalographic findings in patients with mental impairment A controlled prospective study Neuroradiology 9 (1975) 251

— and SODERBORG B (a) Quantitative scintigraphic method of estimating the circulation of cerebrospinal fluid Acta radiol Diagnosis 13 (1972) 554

— — (b) Quantitative methods of estimating CSF flow *In* Cisternography and hydro cephalus p 503 Edited by J C Harbert D C McCullough A J Luessenhop and G Di Chiro Charles C Thomas Springfield Ill 1972

— — (c) The dot counting method in scintigraphy Acta radiol (1972) Suppl No 313 p 229

— BERGVIK A and SODERBORG B Quantitative cisternography *In* Radioaktive Isotope in Klinik und Forschung Band XIII Teil I p 357 Herausgegeben von R Hofer Verlag H Egermann Wien 1978

— LINDBLAD B S MALMLUND H O and PERSSON B Cerebral blood flow and metabolic rate of oxygen glucose lactate pyruvate ketone bodies and amino acids in patients with normal pressure hydrocephalus before and after shunting and in normal subjects Acta neurol scand 56 (1977) Suppl No 64 p 338

— BERGQUIST D BOHMER G MALMLUND H O MARIONS O and SODERBORG B Studies in presenile dementia Acta neurol scand 46 (1970) Suppl No 43 p 90

MCCULLOUGH D C FOX J L CURL F D and GREEN R C Effects of CSF shunts on intracranial pressure and CSF dynamics *In* Cisternography and hydrocephalus p 335 Edited by J C Harbert D C McCullough A J Luessenhop and G Di Chiro Charles C Thomas Springfield Ill 1972

MAHALEY JR M S WILKINSON JR R H SIVALINGHAM S FRIEDMAN H TYSON W and GOODRICH J K Radionuclide blood levels during cisternography of patients with normal pressure hydrocephalus or Alzheimer s disease J Neurosurg 41 (1974) 471

MARIONS O and LYING TUNELL U Constancy of convexity air block on pneumoencephalo graphy Neuroradiology 13 (1977) 191

MATIN P GOODWIN D A and DENARDO G L Cerebrospinal fluid scanning and ventri cular shunts Radiology 94 (1970) 435

MILHORAT T H and HAMMOCK M K Isotope ventriculography Interpretation of ventri cular size and configuration in hydrocephalus Arch Neurol 25 (1971) 1

MUNDINGER F ANLAUF M und BOUCHARD G Die cardiale Impulsfrequenzmessung des Jod[131] Hippuran eine neue Methode zur Passageprufung ventriculo atrialer Shunts und die ventrikulare Resorptionsprufung zur Differentialdiagnose der Hydrocephali Acta neurochir (Wien) 11 (1963) 272

OJEMANN R G FISHER C M ADAMS R D SWEET W H and NEW P F J Further experience with the syndrome of normal pressure hydrocephalus J Neurosurg 31 (1969) 279

PARTAIN C L ALDERSON P O DONOVAN R L SIEGEL B A RUJANAVECH N JOHNSTON R E and STAAB E V Regional kinetics of Indium 111 DTPA in CSF imaging of normal volunteers *In* Radiopharmaceutical dosimetry symposium p 404 HEW Publication (FDA) 76-8044 Washington D C 1976

PATTEN D H and BENSON D F Diagnosis of normal pressure hydrocephalus by RISA cisternography J nucl Med 9 (1968) 457

PENNING L and FRONT D Brain scintigraphy Excerpta Medica Amsterdam 1975

SCHOSSBERGER P F and TOUYA J J Dynamic cisternography in normal dogs and in human beings Neurology (Minneap) 26 (1976) 254

SHIPLEY R A and CLARK R E Tracer methods for in vivo kinetics Chap 1 Academic Press New York 1972

SIEGEL B A and JOHNSON E W Measurement of intrathecal I[131] albumin transport to plasma. Neurology (Minneap) 24 (1974) 501

SODERBORG B and LYING TUNELL U How much radioactivity reaches the basal cisterns at cisternography? *In* Radioaktive Isotope in Klinik und Forschung Band X p 203 Herausgegeben von K Fellinger und R Hofer Urban und Schwarzenberg Munchen Berlin Wien 1973

SOLOMON A K Equations for tracer experiments J clin Invest 28 (1949) 1297

STEER J C and HORNEY F D Evidence for passage of cerebrospinal fluid along spinal nerves Canad med Ass J 98 (1968) 71

SWEET W H BROWNELL G L SCHOLL J A BOWSHER D R BENDA P and STRICKLEY E The formation flow and absorption of cerebrospinal fluid newer concepts based on studies with isotopes Res Publ Ass nerv ment Dis 34 (1954) 101

WILLIAMS J P PRIBRAM H F W LYNDE R H and SHARPE A R Isotope cisternography in the evaluation of patients with subarachnoid hemorrhage J nucl Med 11 (1970) 592

FROM THE DEPARTMENT OF DIAGNOSTIC RADIOLOGY KAROLINSKA SJUKHUSET S 104 01 STOCKHOLM SWEDEN

APPROXIMATE SAGITTAL COMPUTER TOMOGRAPHY OF THE SELLAR AND SUPRASELLAR REGIONS

M HAVERLING H JOHANSON and L AHRÉN

CT scanners not requiring a water bag with tilting gantries and large apertures make possible cranial CT not only in transverse and coronal planes (WOLF et coll 1976 HAMMERSCHLAG et coll 1976) but also in an approximately sagittal plane (HAVERLING & JOHANSON 1978) Such a scanning technique was originally developed in order to obtain satisfactory localization of intraorbital tumours but has also been used for other intracranial lesions e g in the sellar and suprasellar regions

A Delta Scan 50 Computed Tomograph Scanner (Ohio Nuclear) was used and to obtain sections as near as possible to the sagittal plane the following technique was developed

The patient is placed in an oblique prone position on a 20 to 25 cm thick mattress supporting the legs and body up to the upper part of the thorax A triangular cushion is placed under the side of the thorax turned upwards The head is bent downwards over the free end of the mattress and turned so that the sagittal plan approaches the measuring plane of the gantry which is tilted to the maximum 20 degrees in the caudal direction If the right side of the skull is to be examined the patient is placed on his left side and vice versa a series of sections are taken starting at the medial part of the opposite orbit The position of the laser beam index in relation to the skull and the angulation of the gantry is marked on a sketch of the face in the examination report in order to facilitate a similar positioning of the skull on repeat examination

Submitted for publication 31 October 1977



Fig 1 Neurinoma originating from the optic nerve a) Conventional transverse CT section demonstrates tumour above the right part of the optic chiasm b) CT in near sagittal plane demonstrates tumour just above the chiasm close to the posterior end of the optic canal



Fig. 2 Craniopharyngeoma intra and suprasellar a) Coronal scan at level of the sella The tumour is situated slightly to the right and compresses the right side of the floor of the sella b) Near sagittal scan through the sella suggests destruction of dorsum sellae and demonstrates suprasellar growth of tumour



Fig 3 Chromophobic adenoma of the pituitary gland a) Coronal scan at level of the sella Slightly asymmetric compression of the floor of the sella b) Near-sagittal scan through the sella Enlargement of the sella by expansion of tumour downwards and anteriorly No suprasellar growth

Scan sections approaching to the sagittal plane are illustrated in Figs 1 to 3 The addition of a sagittal view may provide a more precise estimate of the extent of a lesion than afforded by the use of the transverse one alone

Like conventional radiography computer tomography should benefit from em

ploying perpendicular planes for the exact localization of structures and lesions as a complement to conventional transverse scanning

True sagittal sections can only be provided in young patients with long and flexible necks With most patients an angle between the sagittal plane of the head and the measuring plane of the gantry opening must be accepted In the cases examined up to now this angle was about 10 degrees but never exceeded 15 degrees

The Delta Scan 50 gives several artefacts in the images which renders the evaluation of structures such as the ventricles and cisterns, difficult True sagittal sections of high quality may be obtained with a new type of CT scanner

Sagittal sections can be reconstructed from data obtained by transverse scanning (GLENN et coll 1975 BERGSTRÖM & SUNDMAN 1976) reconstruction however implies a radiation dose at least twice as high as with the direct technique and images of inferior quality

SUMMARY

Approximate sagittal CT sectioning added to transverse CT may provide useful supplementary information of sellar and parasellar lesions

ZUSAMMENFASSUNG

Computertomographie in ungefahr sagittaler Richtung zusammen mit transversaler CT kann eine zusatzliche nutzliche Information der sellaren und parasellaren Lasionen geben

RESUME

Des copues tomodensitométriques presque sagittales associées à la tomodensitométrie axiale transverse peuvent donner des informations supplementaires utiles pour les lésions sellaires et parasellaires

REFFRENCES

BERGSTROM M and SUNDMAN R Picture processing in computed tomography Amer J Roentgenol 127 (1976) 17

GLENN JR W JOHNSTON R MORTON P and DWYER S Image generation and display techniques for CT scan data Invest Radiol 10 (1975) 403

— — — — Further investigation and initial clinical use of advanced CT display capability Invest Radiol 10 (1975) 479

HAMMERSCHLAG S B WOLPERT S M and CARTER B L Computed tomography Radiology 120 (1976) 219

HAVERLING M I and JOHANSON H C Computed sagittal tomography of the orbit Amer J Roentgenol 131 (1978) 346

WOLF B S NAKAGAWA H and STAULCUP P H Feasibility of coronal views in computed scanning of the head Radiology 120 (1976) 217

FROM THE LABORATORY OF NEUROSCIENCES NATIONAL INSTITUTE OF AGING GERONTOLOGY RESEARCH CENTER BALTIMORE CITY HOSPITAL BALTIMORE MARYLAND 212 4 USA

BLOOD-BRAIN BARRIER OPENING BY ISOTONIC SALINE INFUSION IN NORMOTENSIVE AND HYPERTENSIVE ANIMALS

S I RAPOPORT

Hypertonic solutions of radiographic contrast media employed in cerebral angiography are neurotoxic when directly applied to the brain surface (HOPPE 1959) They may cause neurologic sequelae during angiography by osmotically opening the blood brain barrier which is the continuous layer of cerebrovascular endothelial cells that are connected by tight junctions Some also may be sufficiently lipid soluble to diffuse into the brain across an undisturbed vascularity (REESE & KARNOVSKY 1967 RAPOPORT et coll 1974 RAPOPORT & LEVITAN 1974)

An additional factor that might contribute to neurologic sequelae and that remains to be explored is hypertensive barrier opening caused possibly by rapid injection of contrast medium into the carotid artery Although carotid angiography in normotensive individuals has been reported to not significantly elevate carotid artery pressure (BAKAY & SWEET 1952) it remains possible that systemic hypertension increases the likelihood of barrier opening at high infusion rates (MARGOLIS & YERASIMIDES 1966 RAPOPORT 1976 a) It therefore seemed useful to determine quantitative relations among infusion rate and pressure and barrier opening in experimental animals and to analyse the effect of systemic hypertension on these relations

BROMAN & OLSSON (1956) could not demonstrate breakdown of the blood-brain barrier by rapid infusion of isotonic saline solution into the carotid artery of rabbits

---

Submitted for publication 10 October 1977

but subsequent work in other animals showed that the barrier may be opened by carotid infusion (HAGGENDAL & JOHANSSON 1972 PANNIER & LEUSEN 1975 HARDEBO 1977) In rats only 3 5 s of infusion is sufficient to increase barrier permeability on the homolateral cerebral hemisphere provided carotid artery pressure is elevated to at least 200 mmHg (RAPOPORT & THOMPSON 1975 RAPOPORT 1976 a) Prior elevation of systemic blood pressure by intravenous Aramine potentiates the effect of a given infusion rate on barrier opening

Methodologic limitations exist to the experiments in rats however (RAPOPORT 1976 a) The small size of the carotid vessels precludes a direct measurement of carotid artery pressure during infusion and a large pterygopalatine artery branching from the internal carotid diverts some infusate to the extracerebral circulation These limitations were overcome in the present experiments by employing rabbits and monkeys which do not have a pterygopalatine artery and which have lingual arteries that are sufficiently wide for catheterization and for direct recording of pressure during carotid infusion

Methods

Eight adult rhesus monkeys each weighing 3 to 5 5 kg and 19 adult rabbits each weighing 0 5 to 1 5 kg were anesthetized by intravenous injection of sodium pentobarbital (25–50 mg/kg) A polyethylene catheter which was filled with 10 IU sodium heparin in isotonic saline was inserted in a retrograde direction into the left lingual artery and also connected to a strain gauge pressure transducer at the level of the neck (Statham Instruments Co Oxnard Calif) The left common carotid artery was ligated and was catheterized cephalad to the ligation for internal carotid infusion (Fig 1)

Three ml/kg body weight of a 2% solution of Evans blue (Chroma Gesellschaft Schmid & Co Stuttgart) in isotonic saline was injected intravenously as a barrier tracer This quantity of dye binds within 5 min to serum albumin and normally does not stain the brain (RAPOPORT et coll 1977) Five min after the Evans blue injection a filtered solution of isotonic saline (0 9 g/100 ml) was infused at different constant rates through the common carotid catheter by means of an infusion pump (No 951 Harvard Apparatus Co Millis Mass) Schedules of progressively increasing infusion rates were employed with each infusion lasting about 5 s except for the final one which lasted 15 s Carotid artery pressure was recorded throughout the infusion schedule via the catheterized lingual artery and the external carotid artery was clamped temporarily during the experiment (Fig 1)

In order to find out if systemic blood pressure could influence the relation between barrier opening and carotid infusion 0 2 mg/kg body weight of Aramine (metaraminol bitartrate Merck and Co West Point Pa) was injected intravenously in some animals before carotid infusion In 3 rabbits 10 mg/kg of papaverine HCl (Eli Lilly and Co Indianapolis Ind) was injected intravenously before infusion (JOHANSSON 1974)

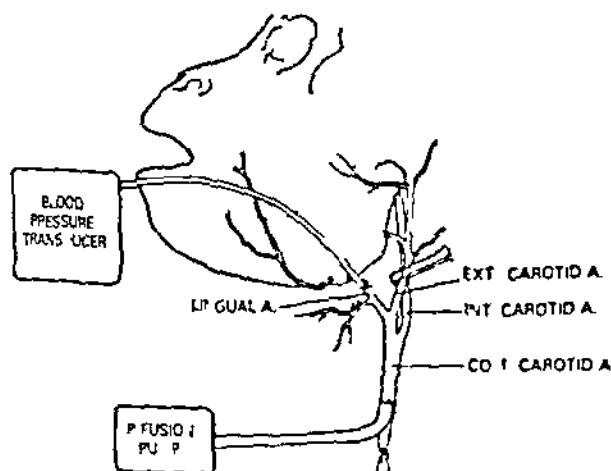


Fig 1 Diagram of infusion procedure in monkey The external carotid artery is clamped during infusion

All but 2 animals were killed 30 to 45 min after the experiment The chest was opened the left atrium cut and the descending aorta clamped and isotonic saline followed by 10% formalin was infused rapidly into the left ventricle of the heart The brain was removed and examined for Evans blue staining and then photographed on its surface and after coronal sections were made Barrier opening was graded as follows from observations and photographs 0 = no staining of brain + = faint and localized blue staining ++ = diffuse deeper staining +++ = extensive dark staining Staining usually was localized to the hemisphere homolateral to carotid infusion Cerebrovascular permeability to tracers such as ^{3}H norepinephrine or ^{125}I albumin is not increased in the absence of blue staining (CHIUEH et coll 1978)

Two monkeys that were given Aramine and then infused for 15 s at a rate of 3 8 ml/s were killed after 2 days The brain was prepared and processed by methods which have been published for analysis of water Na and K in perfused and unperfused regions of gray and white matter (RAPOPORT et coll 1977)

Results

Base line carotid artery pressure Carotid artery ligation in rabbits and monkeys (Fig 1) reduced arterial pressure cephalad to the ligation to below systemic blood pressure as expected from measurements of carotid stump pressure in man and monkey (BAKAY & SWEET SYMON 1967) The reduction was greater in rabbits than in monkeys possibly because the contralateral internal carotid circulation contributes less to anterior cerebral blood flow in the rabbit than in the monkey (SCHMIDT 1950 RUSKELL 1964) Mean femoral artery pressures in anesthetized monkeys and rabbits were 109 ± 8 mmHg (SEM n = 10) and 85 mmHg respectively as compared to respective carotid stump pressures of 15 4 mmHg and 86 mmHg in these experiments (Table 1) (RAPOPORT et coll 1974 RAPOPORT 1976 b)

Table 1

Net carotid artery pressure (mmHg) during infusion, mean ± SEM. Number of animals in parentheses

	Flow rate (ml/s)		
	0	2.47	3.8
Rabbit			
Control	15.4 ± 2.0 (18)	104 ± 13 (9)	147 ± 26 (6)
Plus Aramine	72 ± 8 (6)	233 ± 12 (3)*	270 ± 31 (3)*
Plus papaverine	16.6 ± 3.3 (3)	93 ± 7 (3)	
Monkey			
Control	86 ± 3 (8)		175 ± 7 (7)
Plus Aramine	132 ± 7 (4)*		295 ± 30 (4)*

* Differs from control when paired observations in individual animals are considered ($p < 0.05$).

Carotid artery pressure during infusion. Fig. 2 illustrates changes in carotid artery pressure in a rabbit and monkey during infusion pulses at rates of 0.38 to 3.8 ml/s respectively, and for the rabbit in response to a pulse after intravenous Aramine. Without Aramine, higher infusion rates resulted in higher increments of pressure (ΔP) above base line (e.g. Fig. 2 a). The relation between maximum ΔP and flow rate was not linear, as illustrated in Fig. 3 for 2 rabbits. Initial peak values of ΔP are plotted in Fig. 3, as carotid pressure during infusion often declined after several seconds (Fig. 2 a). At the termination of an infusion pulse, furthermore, carotid artery pressure often fell to below the pre-infusion pressure, but then returned to the pre-infusion base line with a time course of about 30 s (Fig. 2 a).

Without Aramine, the maximum value of ΔP at a given infusion rate could differ by more than 100 mmHg between animals, as illustrated by the plot of all values of ΔP against infusion rate (Fig. 4). Although the relation of peak ΔP to rate was not linear in individual experiments (Fig. 3), interanimal variability was so large that th

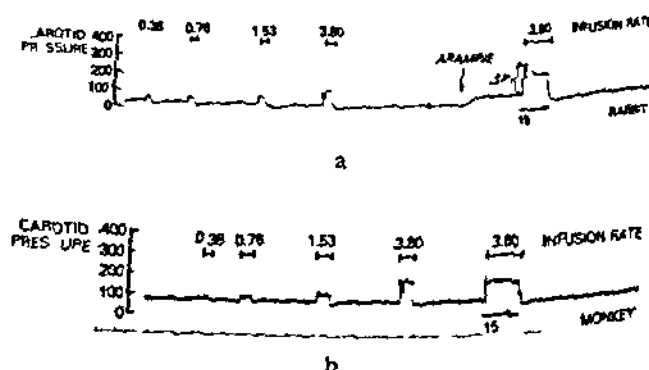


Fig. 2. Carotid artery pressure (mmHg) in a) a rabbit and b) a monkey at different infusion rates (ml/s) and at a rate of 3.8 ml/s following Aramine injection. ΔP is the peak pressure increment caused by an infusion pulse.

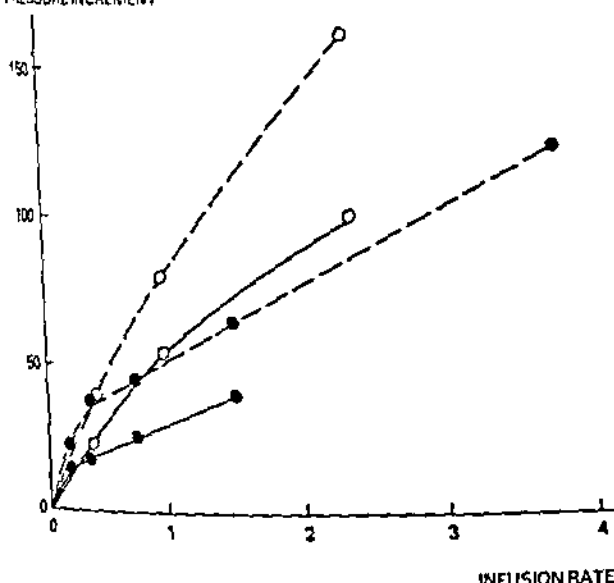


Fig 3 Peak pressure increment ΔI (mmHg) in relation to infusion rate (ml s) in 2 rabbits before (——) and after (– –) Aramine injection An individual animal is represented by a filled or open circle

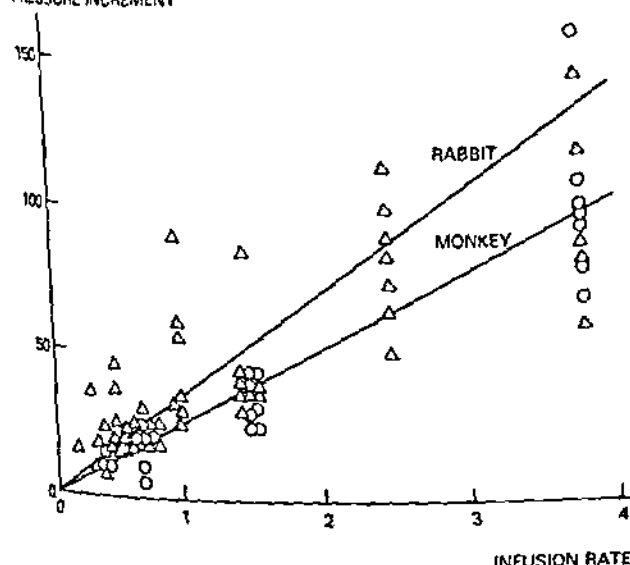


Fig 4 Relation of peak pressure increment ΔP (mmHg) to infusion rate (ml/s) in monkeys (△) and rabbits (○) Lines are least squares fits to the data and are constrained to pass through the origin

overall data could be fit as significantly by a linear relation as by a curvilinear one ($p > 0\ 05$)

Figs 2 a and 3 illustrate that Aramine elevated base line carotid artery pressure and increased the pressure increment ΔP caused by a given infusion rate At rates of 2 47 ml/s or 3 8 ml/s prior Aramine administration increased the ratio ΔP/(infusion rate) by 29 ± 3 per cent (SEM) in 6 rabbits and by 29 ± 5 per cent (SEM) in 4 monkeys

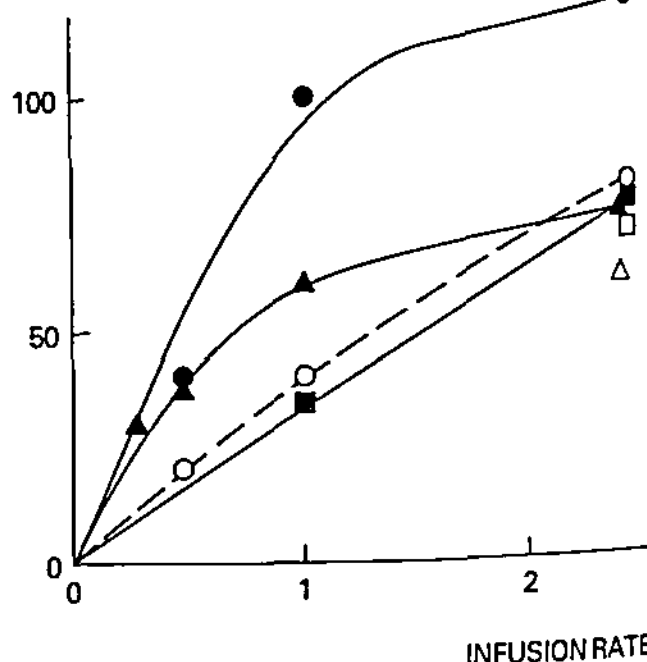


Fig 5 Peak pressure increment ΔP (mmHg) in relation to infusion rate (ml/s) in 3 rabbits before (filled symbols) and after (open symbols) papaverine administration An individual animal is represented by a circle square or triangle

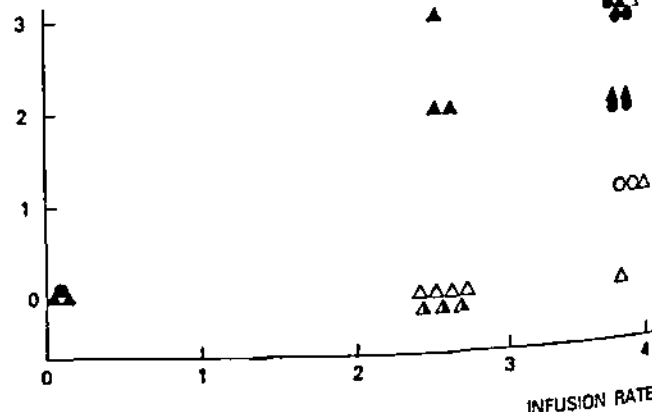


Fig 6 Relation between grade of barrier opening and highest infusion rate (ml/s) Infusion time 15 s Monkey without (○) or with Aramine (●) Rabbit without (△) and with Aramine (▲) or papaverine (Δ) respectively

The resultant effect of Aramine was to increase net carotid pressure during infusion In the experiment of Fig 2 a for example net pressure at a flow rate of 3 8 ml/s was 130 mmHg before Aramine and 270 mmHg afterwards At infusion rates of 2 47 and 3 8 ml/s in rabbits and monkeys Aramine generally allowed net carotid pressure during infusion to rise above 230 mmHg whereas these rates normally did not produce pressures above 175 mmHg (Table 1) On the other hand administration of papaverine to 3 rabbits before carotid infusion did not affect base line blood

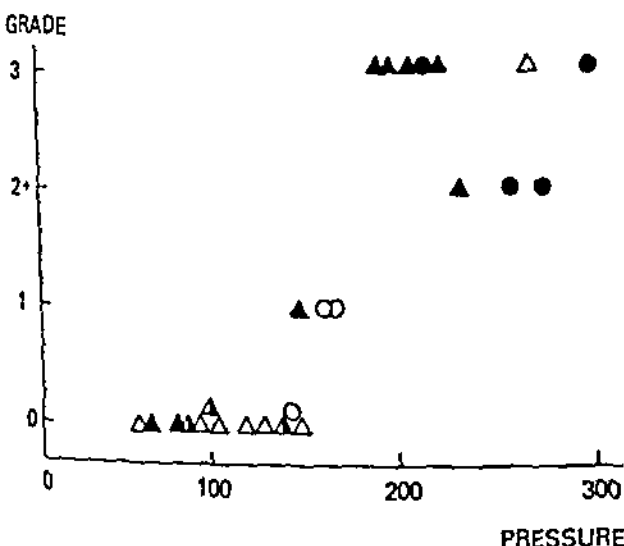


Fig 7 Relation between grade of barrier opening and maximum net carotid artery pressure (mmHg) during infusion in an individual experiment Infusion time 15 s Symbols as in Fig 6

pressure nor increase net pressure during infusion (Table 1) Papaverine markedly reduced ΔP in one rabbit and slightly reduced it in two others (Fig 5)

Opening of blood–brain barrier The Aramine dose in these experiments was below the dose reported to open the blood–brain barrier to intravascular Evans blue albumin in rats (RAPOPORT 1976 a) and did not open the barrier in these experiments except for two 1 mm diameter blue spots on the suprasylvian gyrus of a monkey brain and occasional similar spots at the tips of the temporal lobes of 2 rabbit brains These minor localized changes were classified as grade 0 opening

Blood–brain barrier opening by 15 s of infusion with and without prior Aramine or papaverine correlated better with maximum carotid artery pressure during infusion than with maximum infusion rate ($p < 0.05$) as found also for rats (RAPOPORT 1976 a) Grade ++ and +++ barrier opening occurred consistently when net carotid artery pressure was elevated during infusion to 170 mmHg or higher (Table 1 Figs 6 7) The elevation by Aramine of base line pressure and of ΔP and thereby of net carotid pressure during infusion allowed barrier opening at flow rates that were normally not sufficient to elevate net pressure beyond 170 mmHg Papaverine did not increase net carotid pressure during infusion and did not augment barrier opening at the infusion rates that were used

Brain edema and electrolytes Two monkeys that were administered Aramine and then were infused for 15 s at a rate of 3 8 ml/s were killed to test for brain edema after 2 days as vasogenic edema is reported to be at maximum 2 days after an insult to the brain (KATZMAN & PAPPIUS 1973) One animal in which pressure during infusion was not measured appeared grossly normal and had grade ++ barrier opening whereas the second had a net carotid pressure of 220 mmHg during infusion right

Table 2

Electrolyte and water contents in gray and white matter of brain of 2 monkeys following hypertensive barrier opening Mean ± SEM values for right unperfused and unstained hemisphere are given as well as means of paired differences between left perfused and stained hemisphere and right hemisphere Three samples of gray and three of white matter were taken from each hemisphere in an experiment and statistical analysis was performed by the method of COCHRAN *(1954)*

Region	Right hemisphere	Difference between left and right hemispheres
Gray matter		
H O ( )	81 9±0 5	1 77±0 91
Na (mM kg wet weight)	47 3±1 7	17 0±4 9*
K (mM kg wet weight)	104 6±2 1	−18 3±1 8*
White matter		
H O ( )	68 2±0 7	10 1±3 5*
Na (mM/kg wet weight)	52 4±2 2	30 7±14 9
K (mM kg wet weight)	80 8±0 1	−25 8±11 ı

* Statistically significant (p < 0 05)

sided weakness and grade + + + barrier opening Increased cerebrovascular permeability to Evans blue albumin was associated with significant changes that characterize edema in gray and white matters of the perfused hemispheres water and Na contents were elevated K concentration was decreased as compared to the unperfused control hemispheres (Table 2) (KATZMAN & PAPPIUS)

Discussion

Infusion of isotonic saline solution into the carotid artery of rabbits and monkeys opens the blood-brain barrier in the homolateral hemisphere provided carotid pressure is elevated to 170 mmHg This threshold pressure is close to the 200 mmHg threshold for opening by carotid infusion in rats (RAPOPORT 1976 a) and approximates the upper limit for autoregulation of cerebral blood flow in normotensive animals and man (JOHANSSON et coll 1974 MACKENZIE et coll 1976 RAPOPORT 1976 a)

Although 15 s of infusion increases cerebrovascular permeability at pressures above 170 mmHg experiments in rats and cats indicate that 3 5 s or less can be sufficient (RAPOPORT 1976 a PANNIER & LEUSEN) Aramine lowers the infusion rate that is required to raise carotid pressure to 170 mmHg and to produce barrier opening The drug elevates systemic blood pressure and ΔP probably through a moderate cerebrovascular and stronger peripheral vascular constrictor action (SOKOLOFF 1959 MOYER et coll 1954)

Papaverine does not increase carotid artery pressure nor augment barrier opening at a given infusion rate It is a weak cerebrovascular dilator whose action depends on initial cerebrovascular tone (McCALL et coll 1951 JAYNE et coll 1952) which might explain why a reduction in infusion pressure by papaverine was most prominent in the one rabbit with a high initial resistance to infusion (Fig 5) Only a slight reduction might be expected in animals with carotid ligation as seen in 2 rabbits because the homolateral cerebral vessels should be dilated in these cases (SENGUPTA et coll 1974) In the absence of carotid ligation papaverine augments barrier opening caused by Aramine induced hypertension (JOHANSSON)

The better correlation of barrier opening with infusion pressure than with infusion rate probably reflects differences among animals and in relation to infusion rate and drug administration that occur because internal carotid flow distributes to 3 parallel vascular beds—the extracerebral homolateral cerebral and contralateral cerebral vessels (DUMKE & SCHMIDT 1943 SCHMIDT JEPPSSON & OLIN 1960 HERNANDEZ PEREZ & ANDERSON 1976) Furthermore time related pressure changes during and for 30 s after carotid infusion (e g Fig 2 a) could be caused by flow redistribution among these vascular beds although viscoelastic and autoregulatory factors may operate as well (RAPELA & GREEN 1964 HERNANDEZ PEREZ & ANDERSON) Redistribution also may account in part for the effect of Aramine on ΔP if Aramine acts like norepinephrine and diverts infusate at a higher driving pressure to a reduced region of brain (SOKOLOFF JEPPSSON & OLIN MARGOLIS & YERASIMIDES)

Because carotid infusate distributes among several vascular beds it cannot be decided from these experiments whether an increased intravascular pressure or an increased flow plus vasodilation is the primary cause of blood–brain barrier opening (JOHANSSON et coll) A carotid threshold pressure of 170 mmHg probably is equivalent to a pressure of about 135 mmHg at the pial arterioles (BAKAY & SWEET SYMON) this pressure could by itself increase barrier permeability or could do so by elevating local flow

Light microscopy with horseradish peroxidase as an intravascular tracer indicates that barrier opening by rapid carotid infusion occurs at specific cerebrovascular sites and not throughout the perfused vascular bed (ROBINSON et coll 1977) The increased brain edema and altered electrolyte composition at 2 days suggest that hypertension produced by infusion disrupts the vasculature at these sites so as to produce vasogenic brain edema (KATZMAN & PAPPIUS RAPOPORT et coll 1977) More specific vascular changes including elevated vesicular transport at the capillary endothelium may accompany hypertensive barrier opening (reviewed by RAPOPORT 1976 b)

As far as is known infusion pressures have not been measured in premature or newborn infants during cerebral angiography when infusion rates of 3 to 4 ml/s are employed (HARWOOD-NASH & FITZ 1974 HARWOOD-NASH 1977) The brain of the premature infant weighs 270 g that of the newborn 335 g and that of the adult rhesus monkey 126 g (RABINOWICZ 1964 TILNEY 1928) The comparability of these

weights suggests that flow rates in infant angiography may, in some cases and especially if hypertension exists raise carotid pressure sufficiently to increase barrier permeability The experiments with Aramine and previous ones with norepinephrine (MARGOLIS & YERASIMIDES) indicate furthermore that hypertensive adults also could be predisposed to brain damage from an angiographic procedure A trend supporting this proposition has been reported with respect to vertebral angiography in man (SILVERMAN et coll 1961 TÖRMA & FOGELHOLM 1967) but further investigation is required to see if the trend is statistically significant

Acknowledgement

The author wishes to thank Drs Eugene Streicher and Arthur G Waltz for their helpful comments

SUMMARY

The blood–brain barrier to intravascular Evans blue albumin was opened in monkeys and rabbits by infusing isotonic saline for 15 s into the common carotid artery when the external carotid was clamped temporarily and the lingual was catheterized for measuring pressure Barrier opening correlated better with infusion pressure than with infusion rate and occurred at carotid artery pressures above 170 mmHg Systemic hypertension induced by Aramine increased barrier vulnerability by causing a higher net carotid artery pressure to be attained at a given infusion rate

ZUSAMMENFASSUNG

Die Blut–Gehirn Barriare fur intravaskulares Evans Blue Albumin wurde bei Affen und Kaninchen durch Infusion einer isotonischen Salzlosung fur 15 s in die Arteria carotis communis eroffnet wenn die Arteria carotis externa zeitweise abgeklemmt wurde und die Arteria lingualis fur Druckmessungen katheterisiert wurde Die Öffnung der Barriare war besser zum Infusionsdruck als zur Infusionsgeschwindigkeit korreliert und trat bei einem Druck von uber 170 mmHg in der Arteria carotis auf Allgemeine Hypertension hervor gerufen durch Aramin steigerte die Vulnerabilitat der Barriare durch Hervorrufen eines hoheren Nettodrucks in der Arteria carotis der bei einer gegebenen Infusionsgeschwindig keit erreicht werden muss

RESUME

La barrière hemato-encephalique s opposant au passage de l albumine intra vasculaire marquee au bleu d Evans a ete ouverte chez des singes et des lapins par la perfusion d une solution salée isotonique pendant 15 secondes dans l artère carotide primitive quand l artère carotide externe etait clampee temporairement et quand l artère linguale était catheterisée pour mesurer la pression L ouverture de la barrière est mieux correlee avec la pression de perfusion qu avec la vitesse de perfusion et se produit pour des pressions dans l artere carotide superieures a 170 mmHg. L hypertension systémique induite par l Aramine a augmente la vulnerabilité de la barriere en permettant d atteindre une pression plus elevee dans la reseau carotidien pour une vitesse de perfusion donnee

REFERENCES

BAKAY L and SWEET W H Cervical and intracranial intra arterial pressures with and without vascular occlusion Surg Gynec Obstet 95 (1952) 67

BROMAN T and OLSSON O Technique for the pharmacodynamic investigation of contrast media for cerebral angiography Effect on the blood brain barrier in animal experiments Acta radio 45 (1956) 96

CHIUEH C C SUN C L KOPIN I J FREDERICKS W R and RAPOPORT S I Entry of ^{3}H norephinephrine ^{125}I albumin and Evans blue from blood into brain following unilateral osmotic opening of the blood-brain barrier Brain Res (in press)

COCHRAN W G The combination of estimates from different experiments Biometrics 10 (1954) 101

DUMKE P R and SCHMIDT C F Quantitative measurements of cerebral blood flow in the macaque monkey Amer J Physiol 138 (1943) 421

HAGGENDAL E and JOHANSSON B Effect of increased intravascular pressure on the blood-brain barrier to protein in dogs Acta neurol scand 48 (1972) 271

HARDEBO J E Personal communication 1977

HARWOOD NASH D C Personal communication 1977

— and FITZ C R Complications of pediatric arteriography *In* Angiography in infants and children Edited by M T Gyepes Grune & Stratton New York 1974

HERNANDEZ PEREZ M J and ANDERSON D K Autoregulation of cerebral blood flow and its relation to cerebrospinal fluid pH Amer J Physiol 231 (1976) 929

HOPPE J O Some pharmacological aspects of radiopaque compounds Ann N Y Acad Sci 78 (1959) 727

JAYNE H W SCHEINBERG P RICH M and BELLE M S The effect of intravenous papaverine hydrochloride on the cerebral circulation J clin Invest 31 (1952) 111

JEPPSSON P G and OLIN T Cerebral angiography in the rabbit Lunds Universitets Årsskrift 56 (No 14) (1960) 1

JOHANSSON B Regional cerebral blood flow in acute experimental hypertension Acta neurol scand 50 (1974) 366

— STRANDGAARD S and LASSEN N A On the pathogenesis of hypertensive encephalopathy The hypertensive breakthrough of autoregulation of cerebral blood flow with forced vasodilation flow increase and blood brain barrier damage Circulat Res 34 (1974) Suppl No 1 p 167

KATZMAN R and PAPPIUS H M Brain electrolytes and fluid metabolism Williams & Wilkins Baltimore 1973

MACKENZIE E T STRANDGAARD S GRAHAM D I JONES J V HARPER A M and FARRAR J K Effects of acutely induced hypertension in cats on pial arteriolar caliber local cerebral blood flow and the blood-brain barrier Circulat Res 39 (1976) 33

MARCOUS G and YERASIMIDES T G Vasopressor potentiation of neurotoxicity in experimental aortography Implications regarding pathogenesis of contrast medium injury A ta radiol Diagnosis 5 (1966) 388

MCCALL M L FINCH T V and TAYLOR H W The cerebral effects of papaverine hydrochloride in toxemia of pregnancy Amer J Obstet Gynec 61 (1951) 393

MOYER J H MORRIS G and SNYDER H A comparison of the cerebral hemodynamic response to aramine and norepinephrine in the normotensive and hypotensive subject Circulation 10 (1954) 265

PANNIER J L and LEUSEN I Cerebral blood flow in cats after an acute hypertensive insult with damage to the blood-brain barrier Stroke 6 (1975) 188

RABINOWICZ T The cerebral cortex of the premature infant of the 8th month Progr Brain Res 4 (1964) 39
RAPELA C E and GREEN H D Autoregulation of canine cerebral blood flow Circulat Res 15 (1964) Suppl No 1 p 205
RAPOPORT S I (a) Opening of the blood-brain barrier by acute hypertension Exp Neurol 52 (1976) 467
— (b) Blood–brain barrier in physiology and medicine Raven Press New York 1976
— and LEVITAN H Neurotoxicity of X ray contrast media Relation to lipid solubility and blood-brain barrier permeability Amer J Roentgenol 122 (1974) 186
— MATTHEWS K THOMPSON H K and PETTIGREW K Osmotic opening of the blood-brain barrier in the rhesus monkey without measurable brain edema Brain Res 136 (1977) 23
— and THOMPSON H K Opening of the blood–brain barrier (BBB) by a pulse of hydrostatic pressure (Abstract) Biophys J 15 (1975) 326
— — and BIDINGER J M Equiosmolal opening of the blood–brain barrier in the rabbit by different contrast agents Acta radiol Diagnosis 15 (1974) 21
REESE T S and KARNOVSKY M J Fine structural localization of a blood-brain barrier to exogenous peroxidase J cell Biol 34 (1967) 207
ROBINSON J S BRIGHTMAN M W and RAPOPORT S I Personal communication 1977
RUSKELL G N Blood vessels of the orbit and globe *In* The rabbit in eye research Edited by J H Prince Charles Thomas Springfield 1964
SCHMIDT C F The cerebral circulation in health and disease Charles C Thomas Springfield 1950
SENGUPTA D HARPER M and JENNETT B Effect of carotid ligation on cerebral blood flow in baboons 2 Response to hypoxia and haemorrhagic hypertension J Neurol Neurosurg Psychiat 37 (1974) 578
SILVERMAN S M BERGMAN P S and BENDER M B The dynamics of transient cerebral blindness Arch Neurol 4 (1961) 333
SOKOLOFF L The action of drugs on the cerebral circulation Pharmacol Rev 11 (1959) 1
SYMON L A comparative study of middle cerebral pressure in dogs and macaques J Physiol (Lond) 191 (1967) 449
TILNEY F The brain of ape and man Hoeber New York 1928
TÖRMA T and FOGELHOLM R Complications of cerebral angiography with urografin Acta neurol scand 43 (1967) 616

FROM THE DEPARTMENTS OF RADIOLOGY AND INTERNAL MEDICINE UNIVERSITY OF CALIFORNIA DAVIS CALIFORNIA 95616 U S A

LUNG VENTILATION-PERFUSION SCINTIGRAPHY IN PULMONARY EMBOLISM

Diagnostic specificity compared to pulmonary angiography

H G BOGREN D S BERMAN L A VISMARA and D T MASON

Pulmonary embolism remains a common cause of death second only to coronary disease particularly since the disorder is unrecognized and thereby not treated in approximately two thirds of such instances (DALEN & ALPERT 1975) The clinical detection of pulmonary embolism is acknowledged to be highly inaccurate being at best 50 per cent even when the diagnosis is considered (DALEN 1972) Contributing to this difficulty in diagnosis is that radiography of the chest is non specific in the presence of pulmonary embolism WESTERMARK (1938) described segmental or lobar oligemia in patients who subsequently died because of massive pulmonary embolism Whereas HAMPTON & CASTLEMAN (1940) described irregular parenchymal infiltrates or pleural based wedge shaped abnormalities in the lungs as characteristic of pulmonary infarction the spectrum in pulmonary embolism varies and includes normal appearances subsegmental atelectasis or pleural effusion Pulmonary angiography offers the most specific means of detecting pulmonary emboli (BOOKSTEIN 1969) but this diagnostic modality is relatively expensive invasive and limited in availability In contrast perfusion lung scintigraphy is non invasive can be carried out with ease is inexpensive and provides nearly 100 per cent sensitivity (GREENSPAN 1974) but is lacking in specificity (WAGNER & STRAUSS 1975 VON EULER & LILJESTRAND 1946) When combined perfusion and lung ventilation scintigraphy is performed it has

Submitted for publication 2 December 1977

been suggested that the specificity or primarily embolic identification is enhanced (MOSES et coll 1974 MCNEIL 1976) although the diagnostic accuracy of such combined pulmonary ventilation perfusion imaging has not been evaluated in a large series of patients Furthermore the specificity of lung scans in the detection of pulmonary embolism in patients with left heart failure has been particularly questioned (GILDAY & JAMES 1972 MOSES et coll) since it is anticipated that false negative images occur frequently in this condition The specificity of combined lung ventilation perfusion scintigraphy was therefore analyzed in a large group of patients considered clinically to potentially have acute pulmonary embolism including a large subgroup with left heart failure

Material and Methods

The material consisted of 53 adult patients all of whom were suggested on the basis of clinical signs and symptoms of having acute pulmonary thromboembolism In addition 18 of these patients had pulmonary congestion due to left heart failure All patients underwent clinical evaluation standard radiography of the chest lung ventilation perfusion scintigraphy measurement of cardiac hemodynamics and pulmonary angiography within 48 hours after the onset of symptoms The clinical evaluation included history physical and laboratory examinations including arterial blood gases acid base balance serum myocardial enzymes liver and renal function tests Radiography of the chest was performed with upright p a and lateral views in most instances otherwise supine a p bedside films were obtained

Ventilation scintigraphy An Anger scintillation camera was used to record posterior views of the chest after a single inhalation of 25 mCi of ^{133}Xe (WAGNER & STRAUSS) An initial control inhalation film and serial washout scintigrams were always taken In most patients an additional film was obtained after rebreathing of Xenon to equilibrium The ventilation imaging always preceded the perfusion imaging

Perfusion scintigraphy Following a control film, 4 mCi ^{99}TC^{m} of human albumin microspheres were injected and multiple serial scintigrams were taken using the Anger scintillation camera (MOSES et coll) In each patient the scintigraphy included anterior posterior right and left lateral views

Cardiac hemodynamics Complete right heart catheterization was performed in each patient as well as left heart catheterization in most individuals Left ventricular filling pressure was obtained in all patients by measurement of pulmonary capillary wedge and pulmonary artery diastolic pressures In addition complete right heart and pulmonary pressures were recorded systemic arterial mixed venous oxygen saturation differences were measured and cardiac index was determined using the Fick or indicator dilution method

Table 1

Classification of diagnostic criteria

	Pulmonary embolism
Scintigraphy	
Ventilation and perfusion normal	Unlikely
Ventilation abnormality > perfusion abnormality	Unlikely
Ventilation abnormality = perfusion abnormality	Possible
Ventilation abnormality < perfusion abnormality	Indicative
Ventilation normal and perfusion abnormal	Indicative
Pulmonary angiography	
Vascular obstruction	Present
Vascular filling defect	Present

Results Group I (18 patients) positive pulmonary embolism present Group II (35 patients) negative pulmonary embolism absent

Pulmonary angiography Fifty to 60 ml Renografin 76% were injected into the main pulmonary artery at the rate of 25 to 30 ml per second and serial a p films were taken of both lungs timed to demonstrate the pulmonary arterial capillary and venous phases When pulmonary emboli were demonstrated on these films pulmonary angiography was terminated when not selective lobar or segmental pulmonary angiography was performed in oblique views using the scintigraphic lung scans and the angiographic films as guides indicating in which pulmonary areas pulmonary embolism was most probable

Diagnostic criteria

Pulmonary scintigraphy The patients were divided into five groups depending on the scintigraphic findings (Table 1) When the ventilation and perfusion scans were both normal or when the ventilation abnormality exceeded the size of the perfusion abnormality the presence of pulmonary embolism was considered unlikely (Figs 1 2) However when the ventilation abnormality equalled the perfusion abnormality in size and distribution the presence of pulmonary embolism was considered possible (Figs 1 3) In contrast when the ventilation abnormality was less extensive than th perfusion abnormality or when the ventilation scan was normal and the perfusion image abnormal the pulmonary embolism was considered indicative (Figs 1 4) Thus by use of these criteria the five possible types of relations of the ventilation to the perfusion scintigraphy were characterized into three groups concerning the probability of pulmonary embolsim (1) unlikely (2) possible and (3) indicative

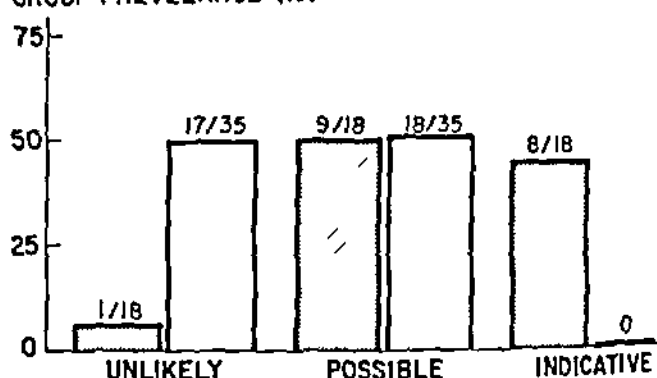


Fig 1 Specificity of ventilation perfusion scintigraphy shown by comparison with concurrent pulmonary angiography n = 53 Unlikely Ventilation abnormality perfusion abnormality ($p < 0.05$) Possible Ventilation abnormality = perfusion abnormality (p 0 05) Indicative Ventilation abnormality < perfusion abnormality (p 0 05) ☐ embolism ☐ no embolism

Pulmonary angiography Pulmonary vascular obstruction with cut off vessels or vascular filling defects were considered demonstrative of pulmonary embolism (Table 1)

Results

Pulmonary angiography In 18 patients pulmonary intraluminal filling defects producing partial or complete vascular obstruction were demonstrated as indicative of pulmonary embolism The 35 remaining patients had either normal pulmonary angiography or non specific vascular abnormalities (Table 1 Fig 1)

Clinical evaluation The most common symptoms in the 53 patients were dyspnea (74 % of patients) and chest pain (53 %) Fifteen per cent had hypertension and hemoptysis occurred in 11 per cent A pleural friction rub was only occasionally heard and clinical evidence of deep vein thrombosis in the lower extremities was unusual When the group with angiographically documented pulmonary embolism was compared with those without embolism no significant difference in clinical symptomatology or systemic arterial PO_2 saturation was found (Table 2)

Chest radiography Only one patient had typical findings of pulmonary infarction with a wedge shaped abnormality postero laterally in the right lung Two patients had positive Westermark s sign with lobar oligemia In all of the other patients the chest radiographic findings were non specific or normal The most common finding in the 53 patients w is a non specific subsegmental atelectasis or irregular infiltrates in part of the lower lobes with or without pulmonary effusion Evidence of pulmonary edema was only seen in patients with advanced left heart failure The frequency of abnormalities observed on the chest films did not differ significantly between the groups with and without pulmonary embolism (Table 2)

In the patients with possible scintigraphic diagnosis of pulmonary embolism the presence or absence of an infiltrate on the chest films was evaluated It was found

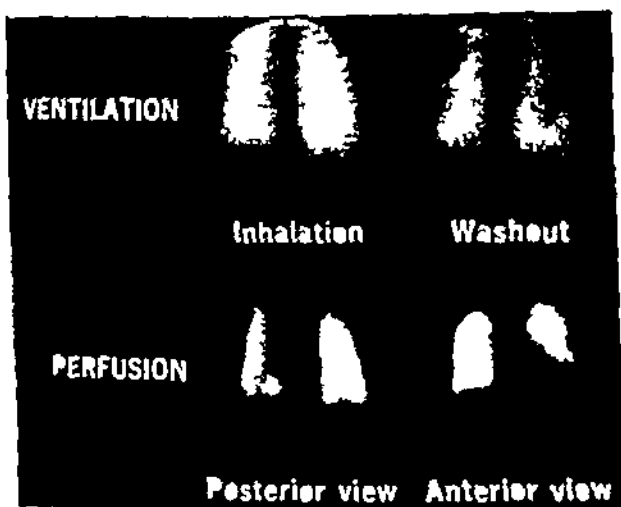


Fig 2 Representative ventilation perfusion scintigrams with larger ventilation than perfusion defects (unlikely group)

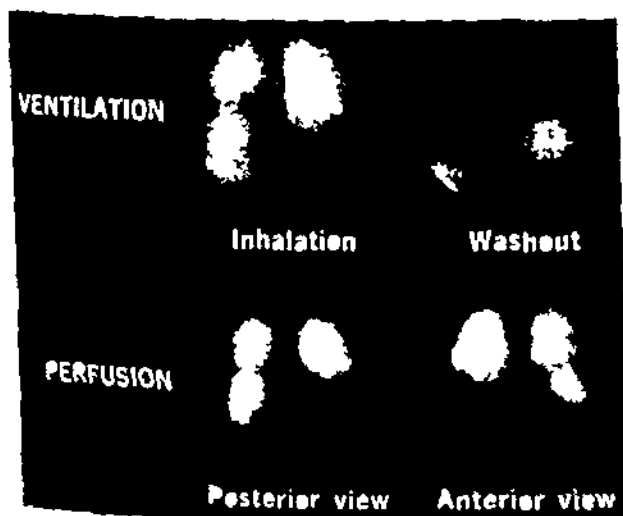


Fig 3 Representative ventilation and perfusion scintigrams with equal size ventilation and perfusion abnormalities (possible group)

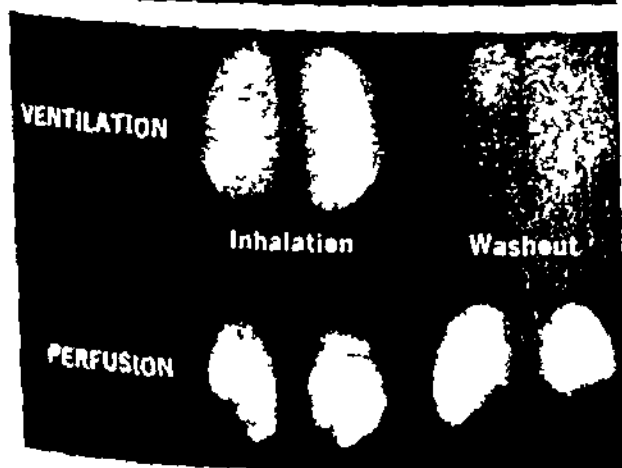


Fig 4 Representative ventilation and perfusion scintigrams with larger perfusion abnormality than ventilation abnormality (indicative group)

Table 2

Pulmonary embolism in relation to clinical evaluation

Classification	Mean age (years)	Clinical symptoms (per cent)		Chest films abnormal (per cent)	Systemic arterial PO_2
		Dyspnea	Chest pain		
Group I (embolism) n = 18	54 4	78	50	44	60
Group II (no embolism) n = 35	56 4	71	54	63	68
p 0 05					

that if an infiltrate was present 44 per cent of the patients did not have pulmonary embolism at angiography while 56 per cent did values which were statistically non significant However in the absence of an infiltrate 90 per cent of the patients were without pulmonary embolism at angiography and 10 per cent had angiographic thromboembolism

Cardiac hemodynamics No significant difference was found in the mean or phasic systemic arterial blood pressures pulmonary capillary wedge pressure or mean and phasic pulmonary artery right ventricular or right atrial pressures between the two groups with or without angiographic pulmonary embolism (Table 3) Neither did values of cardiac index nor total body arterio venous oxygen saturation difference distinguish the two patient groups (Table 3)

Ventilation perfusion pulmonary scintigraphy The results appear in Fig 1 Of the 18 patients with angiographically documented pulmonary embolism there was only one false negative combined scintigraphy in which the ventilation defect was larger than the perfusion defect In contrast 9 patients with pulmonary embolism on angiography had possible scintigraphic diagnosis characterized by the ventilation abnormality equal to the perfusion abnormality while the remaining 8 patients with angiographic pulmonary embolism were correctly diagnosed as having pulmonary embolism by combined scintigraphy (ventilation abnormality smaller than the perfusion abnormality) Importantly there were no false positive diagnoses of pulmonary embolism by lung scintigraphy Of the 35 patients with no angiographically documented pulmonary embolism 17 were correctly diagnosed as not having pulmonary embolism In the remaining 18 cases without angiographic pulmonary embolism the diagnosis was considered possible since the ventilation abnormality equalled the perfusion abnormality

Table 3

Pulmonary embolism in relation to cardiac hemodynamics

Classification	Mean pressures (mmHg)				Cardiac index l min m²	A V O_2 (vol)
	BP	PCW	PA	RA		
Group I (embolism) n = 18	81	16.5	24	7	2.91	5 7
Group II (no embolism) n = 35	85	13	22	6	2.87	5 0

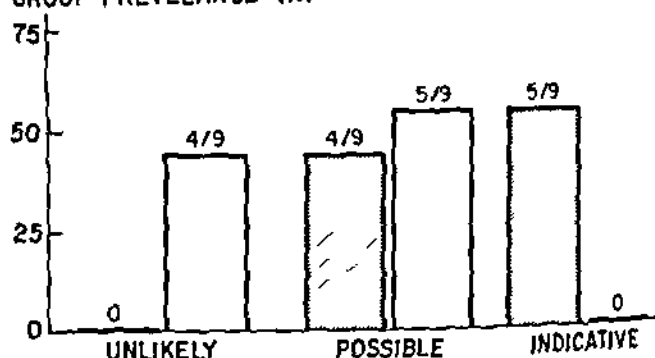
A V O_2 = Total body arteriovenous oxygen difference BP = Systemic arterial blood pressure PCW = Pulmonary capillary wedge PA = Pulmonary artery RA = Right atrium.
$p > 0\ 05$

Ventilation perfusion pulmonary scintigraphy in left heart failure Patients with a pulmonary capillary wedge pressure (left ventricular filling pressure) of 21 mmHg or higher or with a cardiac index of 2 3 l/min/m body surface or less demonstrated severe left heart failure with pulmonary congestion These criteria were fulfilled in 18 patients and the results of their combined ventilation perfusion scintigraphy are shown in Fig 5 Four of the 9 patients with pulmonary embolism belonged to the possible group in whom ventilation equalled perfusion abnormalities and the other 5 pulmonary embolism patients with severe left heart failure had scans indicative of pulmonary embolism Of the 9 patients in whom pulmonary embolism was not documented angiographically 4 at scintigraphy belonged to the group unlikely to have pulmonary emboli and 5 were characterized as possible No false positive or false negative diagnoses of pulmonary embolism were made by combined scintigraphy in severe left heart dysfunction

Discussion

The mortality of untreated pulmonary embolism has been shown to be approximately 30 per cent (DALEN & ALPERT 1975) In the Urokinase Pulmonary Embolism Trial (1973) and in the series of DALEN & ALPERT consisting of anticoagulation drug treated angiographically documented pulmonary embolism the mortality rate was reduced to 8 per cent The hemorrhagic complication rate of long term anticoagulation for pulmonary embolism was 27 per cent of the patients in the Urokinase Pulmonary Embolism Trial and 2 to 15 per cent in patients receiving conventional anticoagulant therapy with heparin and coumadin (AGGELER & KOSMIN 1969) Operative intervention with ligation of the inferior vena cava is associated with a relatively high morbidity and surgical therapy with pulmonary embolectomy has

Fig 5 Specificity of ventilation perfusion scintigraphy in patients with congestive heart failure n = 18 Mean pulmonary capillary wedge 21 mmHg Mean cardiac index 2 3 l/min/m² Unlikely Ventilation abnormality perfusion abnormality (p 0 05) Possible Ventilation abnormality perfusion abnormality (p 0 05) Indicative Ventilation abnormality perfusion abnormality (p 0 05) ▭ embolism ▭ no embolism



considerable mortality (NABSETH & MORAN 1965 CROSS & MOWLEN 1967) From these observations it is clear that accurate diagnosis is of paramount importance in the proper management of patients with possible pulmonary embolism

The present results have affirmed the inaccuracy of evaluation by standard clinical and chest radiography in the diagnosis of pulmonary embolism (Table 2) Furthermore the view that a low systemic arterial PO is a useful diagnostic finding (HILDNER & ORMOND 1967) was not documented (Table 2)

A unique aspect reported herein was the evaluation of cardiac hemodynamics in patients with possible pulmonary embolism (Table 3) since such systematic assessment in a large group of such patients has not been carried out previously All of th patients underwent complete right heart catheterization with evaluation of right and left heart function and pulmonary arterial pressures However no significant differences were found in the hemodynamic variables related to the performance of the heart or pulmonary vascularity between patients with and without pulmonary embolism

Pulmonary angiography is well acknowledged to be the most specific method available in the clinical diagnosis of pulmonary embolism although its absolute accuracy has been difficult to evaluate precisely (BOOKSTEIN Moses et coll) Nevertheless the technique has been reported to provide completely reliable diagnostic sensitivity and specificity when segmental injections and related selected methodology carried out in the present series are performed in conjunction with standard pulmonary angiography (MOSES et coll) Furthermore the procedure is now recognized to be safe with minimal morbidity without mortality as reported in the 298 patients examined by MOSES et coll or in the 310 patients reported in the Urokinase Pulmonary Embolism Trial In the present series pulmonary artery perforation with hemorrhage occurred in one patient no other morbidity and no mortality occurred However pulmonary angiography is relatively expensive time consuming and requires specially trained catheterization personnel utilizing modern angiographic equipment often unavailable in many hospitals In view of high prevalence of pulmonary embolization there is considerable need for a non invasive inexpensive reliable method for the diagnosis of pulmonary embolism that is


readily available for widespread use and can be performed with ease and patient safety

Pulmonary scintigraphy is such a non invasive method which has the additional advantage of being carried out in smaller institutions without a specialized angio graphic laboratory Whereas perfusion scanning is extremely sensitive in the detection of pulmonary embolism the test is inaccurate alone because of its relatively low specificity due to the fact that most lung diseases cause perfusion disturbances as well as ventilation disorders Despite certain approaches to enhance the specificity of perfusion scanning in identifying pulmonary emboli such as considering only segmental or lobar abnormalities indicative of embolism (KELLEY & ELLIOTT 1974 WAGNER & STRAUSS) or correlation of the findings on chest films in conjunction with the perfusion scan (MOSES et coll) these methods have not been entirely satisfactory It is now generally believed that the best technique for improving the specificity of perfusion lung scanning is its combination with ventilation imaging (MCNEIL) However objective information is lacking concerning the precise enhancement of accuracy in pulmonary embolism diagnosis provided by combined lung ventilation perfusion scintigraphy Thus only a small patient series has been reported by MOSES et coll while combined imaging is simply recommended by WAGNER & STRAUSS without data concerning accuracy Furthermore the preli minary observations of MCNEIL examining ventilation perfusion imaging with angiography in a number of patients approaching the size of the present series are considerably extended by the present methodology and findings

Nearly one half of the patients (8 of 18) with pulmonary embolism at angiography had scintigraphic findings indicative of pulmonary embolism defined as perfusion abnormalities larger than ventilation abnormalities (Figs 1 4) Further only one false negative case with pulmonary embolism was encountered who had scintigraphic findings considered as a ventilation abnormality greater than the perfusion defect (Fig 1) Moreover no false positive ventilation perfusion scintigraphy occurred in th 35 patients without pulmonary embolism (Fig 1) Of the patients with equal ventilation perfusion abnormalities (Fig 1) and thereby considered to have possible pulmonary embolization one half of the patients (9 of 18) had such emboli while approximately one half (18 of 35) did not Thus the newly devised grading system consisting of three types of combined ventilation perfusion defects (unlikely possible and indicative) provided considerable improvement in the specificity of the diagnosis of pulmonary embolism When the ventilation defect is not quantified relative to the perfusion abnormality as in the report by MCNEIL relatively poor specificity results with a substantial number of false positive tests

In the evaluation of ventilation perfusion scintigraphy it is important to appreciate that th abnormal segments due to pulmonary emboli on perfusion scans may be superimposed on areas of lung parenchyma already diseased as in pulmonary emphy sema or fibrosis It is therefore predictable that many patients with the common problems of chronic lung disease will show equal ventilation perfusion defects in

Fig 5 Specificity of ventilation perfusion scintigraphy in patients with congestive heart failure n – 18 Mean pulmonary capillary wedge 21 mmHg Mean cardiac index 2 3 l/min/m² Unlikely Ventilation abnormality perfusion abnormality (p 0 05) Possible Ventilation abnormality perfusion abnormality (p 0 05) Indicative Ventilation abnormality perfusion abnormality (p 0 05) ☐ embolism ☐ no embolism



considerable mortality (NABSETH & MORAN 1965 CROSS & MOWLEN 1967) From these observations it is clear that accurate diagnosis is of paramount importance in the proper management of patients with possible pulmonary embolism

The present results have affirmed the inaccuracy of evaluation by standard clinical and chest radiography in the diagnosis of pulmonary embolism (Table 2) Furthermore the view that a low systemic arterial PO is a useful diagnostic finding (HILDNER & ORMOND 1967) was not documented (Table 2)

A *unique* aspect reported herein was the evaluation of cardiac hemodynamics in patients with possible pulmonary embolism (Table 3) since such systematic assessment in a large group of such patients has not been carried out previously All of the patients underwent complete right heart catheterization with evaluation of right and left heart function and pulmonary arterial pressures However no significant *differences* were found in the hemodynamic variables related to the performance of the *heart* or pulmonary vascularity between patients with and without pulmonary embolism

Pulmonary angiography is well acknowledged to be the most specific method available in the clinical diagnosis of pulmonary embolism although its absolute accuracy has been difficult to evaluate precisely (BOOKSTEIN Moses et coll) Nevertheless *the technique* has been reported to provide completely reliable diagnostic sensitivity and specificity when segmental *injections* and related selected methodology carried out in the present series are performed in conjunction with standard pulmonary angiography (MOSES et coll) Furthermore the procedure is now recognized *to* be safe with minimal morbidity without mortality as reported in the 298 patients examined by MOSES *et coll* or *in* the 310 *patients* reported in the Urokinase Pulmonary Embolism Trial In the *present series* pulmonary artery perforation with hemorrhage occurred in one patient no other morbidity and no mortality occurred However pulmonary angiography is relatively expensive time consuming and *requires* specially trained catheterization personnel utilizing modern angiographic equipment often unavailable *in many* hospitals In view of h h prevalence of pulmonary embolization there is considerable need for a non invasive inexpensive reliable method for the diagnosis of pulmonary embolism that is

gra by It was found that patients with combined scintigraphy considered as unlikely for pulmonary embolism (ventilation defect larger than perfusion defect) or indicative of pulmonary embolism (ventilation defect smaller than perfusion defect) provide high diagnostic specificity Patients with equal ventilation-perfusion abnormalities (possible pulmonary embolism) require further evaluation by pulmonary angiography to ascertain diagnosis. Importantly diagnostic accuracy using ventilation perfusion scintigraphy and the quantified method of evaluation delineated is preserved in patients with severe congestive heart failure

ZUSAMMENFASSUNG

Bei 53 Patienten mit möglicher Lungenembolie wurden die Veränderungen in der ¹³³Xe Atmung und der Perfusions Szintigraphie mit ⁹⁹Tc^{m} Albumin Mikrospharen mit der Abwesenheit oder dem Vorkommen von Lungenembolien durch gleichzeitige Angiographie nachgewiesen verglichen Patienten die bei der kombinierten Szintigraphie als unwahrscheinlich fur eine Lungenembolie angesehen worden waren (Ventilationsdefekt grosser als Perfusionsdefekt) oder wo eine Lungenembolie als wahrscheinlich angesehen worden war (Ventilationsdefekt geringer als Perfusionsdefekt) hatten eine hohe diagnostische Spezifitat Patienten mit gleicherweise vorliegenden Ventilations Perfusions Veränderungen (mogliche Lungenembolie) verlangen eine weitere Untersuchung durch Lungen Angiographie um die Diagnose zu sichern Wesentlich ist dass die diagnostische Genauigkeit bei Verwendung der Ventilations Perfusions Szintigraphie und der quantitativen Methode der Auswertung auch bei Patienten mit schwerem kongestivem Herzfehler vorgenommen werden kann

RESUME

Chez 53 malades pouvant avoir une embolie pulmonaire les anomalies pulmonaires de la ventilation par le ¹ Xe et de la scintigraphie de perfusion par des microsphères d albumine marquees au Tc^{m} ont éte comparées avec l absence ou la présence d embolie pulmonaire recherchees par une angiographie pulmonaire simultanée Les auteurs ont constaté que la sociation d une scintigraphie faisant considérer l embolie pulmonaire comme peu vraisemblable (defect ventilatoire plus grand que le défect de perfusion) ou indiquant une embolie p lmonaire (defect ventilatoire plus petit que le défect de perfusion) fournit une haute spécific te diagnostique Les malades qui ont des anomalies de ventilation et de perfusion égales (embolie pulmonaire possible) nécessitent une étude complémentaire par angiographie pulmonaire pour affirmer le diagnostic Il est important de signaler que l exactitude du diagnostic au moyen de la scintigraphie ventilatoire et de perfusion et de la methode d évaluation quantifiee decrite est conservée chez les malades qui ont une défaillance cardiaque congestive grave

REFERENCES

AGGELER P M and KOSMIN M Anticoagulant prophylaxis and treatment of venous thromboembolic disease *In* Thrombosis p 646 Edited by S Sherry K M Brinkhous E Genton and J M Stengle National Academy of Sciences Washington 1969

BOOKSTEIN J J Segmental arteriography in pulmonary embolism Radiology 93 (1969) 107

— and SILVER T M The angiographic differential diagnosis of acute pulmonary embolism Radiology 110 (1974) 25

CROSS F S and MOWLEN A A survey of the current status of pulmonary embolectomy for massive pulmonary embolism Circulation 35 (1967) Suppl No 1 p 1

DALEN J E Diagnosis of acute pulmonary embolism *In* Pulmonary embolism p 78 Edited by J E Dalen Medcom New York 1972

— and ALPERT J S Natural history of pulmonary embolism Progr cardiovasc Dis 17 (1975) 259

VON EULER V S and LILJESTRAND G Observations on the effect of hypoxia on the pulmonary vascular bed J Physiol 45 (1946) 135

GILDAY D L and JAMES A E Lung scan patterns in pulmonary embolism versus those in congestive heart failure and emphysema Amer J Roentgenol 115 (1972) 739

GREENSPAN R H Does a normal isotope perfusion scan exclude pulmonary embolism? Invest Radiol 9 (1974) 44

HAMPTON A O and CASTLEMAN B Correlation of post mortem chest teleroentgenograms with autopsy findings With special reference to pulmonary embolism and infarction Amer J Roentgenol 43 (1940) 305

HILDNER F J and ORMOND R S Accuracy of the clinical diagnosis of pulmonary embolism J Amer med Ass 202 (1967) 567

KELLEY M J and ELLIOTT L P The radiologic evaluation of the patient with suspected pulmonary thromboembolic disease Med Clin N Amer 59 (1974) 3

MCNEIL B J A diagnostic strategy using ventilation perfusion studies in patients suspect for pulmonary embolism J nucl Med 17 (1976) 613

MOSES D C SILVER T M and BOOKSTEIN J J The complementary roles of chest radiography lung scanning and selective pulmonary angiography in the diagnosis of pulmonary embolism Circulation 49 (1974) 179

NABSETH D C and MORAN J M Reassessment of the role of inferior vena cava ligation in venous thromboembolism New Engl J Med 273 (1965) 1250

The Urokinase Pulmonary Embolism Trial A national cooperative study Circulation 47 (1973) Suppl No 2 p 66

WAGNER H N JR and STRAUSS H W Radioactive tracers in the differential diagnosis of pulmonary embolism Progr cardiovasc Dis 17 (1975) 271

WESTERMARK N On the roentgen diagnosis of lung embolism Acta radiol 19 (1938) 357

FROM THE DEPARTMENTS OF DIAGNOSTIC RADIOLOGY RIKSHOSPITALET AND ULLEVÅL SYKEHUS OSLO NORWAY

ANGIOGRAPHY IN ACUTE MESENTERIC ARTERIAL INSUFFICIENCY

T AAKHUS and A EVENSEN

Early diagnosis is a prerequisite for successful treatment of acute mesenteric vascular insufficiency (KLASS 1965 OTTINGER & AUSTEN 1967) and a simple and reliable diagnostic method is urgently needed As yet no preoperative procedure seems to surpass the diagnostic value of angiography but only small series have been reported (AAKHUS 1966 AAKHUS & BRABRAND 1967 RECEK et coll 1968 BRITT & CHEEK 1969 BOIJSEN 1971 WITTENBERG et coll 1973 MACGREGOR et coll 1974 WALTMAN et coll 1974)

Between 1964 and 1976 angiography was performed in 31 cases of acute mesenteric arterial insufficiency and the results are now reported

Material and Methods

The material consisted of 13 males and 18 females aged between 38 and 88 years average 65 years

Twelve patients had atrial fibrillation 2 had had myocardial infarction and 6 patients had other cardiac lesions Eleven patients had no known heart disease

The usual symptoms were acute abdominal pain followed by nausea and vomiting sometimes bloody stools and occasionally hematemesis In 20 cases the

Submitted for publication 22 November 1977



Fig 1 Lateral aortography Proximal occlusion of superior mesenteric artery (→) Celiac and inferior mesenteric arteries are patent

symptoms lasted less than 24 hours in 10 from 1 to 7 days One patient used methysergid maleate (Deseril Sandoz) against migraine and had had vague abdominal pain for months On the day of admission she had acute severe abdominal pain

Conventional abdominal films were exposed with horizontal and vertical beam directions before angiography in all cases

In 14 cases only aortography was performed In 12 cases aortography and selective angiography of the superior mesenteric artery were made in one of these angiography of the inferior mesenteric artery as well In 5 cases only selective angiography of the superior mesenteric artery was performed

The diagnosis was confirmed by operation or autopsy in all but 5 cases In these 5 a diagnosis of multiple emboli or vascular constriction was based on angiography and the symptoms subsided spontaneously

Twelve patients survived the acute episode 5 of these without operation (4 with vascular constriction and 1 with peripheral emboli) 2 after embolectomy (both with superior mesenteric arterial emboli) and 5 after resection of the bowel (4 with proximal and one with peripheral emboli) The remaining 19 patients succumbed to their actue disease




Fig 2 Selective angiography of mesenteric arteries a) Occlusion of superior mesenteric artery (→) b) Occlusion of superior hemorrhoidal artery (—)

Five of the survivors died later one of these after 3 months from a short bowel syndrome following extensive resection one after 6 months from strangulating intestinal obstruction and 3 from renewed mesenteric ischemia after 2 months 5 months and 3 years respectively

Results

The conventional abdominal films usually indicated an acute abdominal lesion and in some cases a mesenteric thrombosis was suggested but in no case could a specific diagnosis be made on these films alone

In 6 cases a vascular occlusion was located within the first 5 cm of the superior mesenteric main stem (Fig 1) in 12 cases from 5 to 10 cm from the origin of the artery (Fig 2 a) In one of the latter a branch of the inferior mesenteric artery was also occluded (Fig 2 b)

In 4 cases peripheral occlusions only were found (Fig 3 a) One of these improved spontaneously and repeat angiography 10 days later demonstrated that the emboli had disappeared (Fig 3 b)



a



b

Fig 3

Fig. 3 Selective angiography of superior mesenteric artery a) Peripheral occlusions (→) b) Occlusions disappeared 10 days later



Fig. 4

Fig 4 Selective angiography of superior mesenteric artery Complete occlusion of superior mesenteric artery (→) Some collateral flow via intestinal arcades to more distal branches (↔)



Fig 5 Selective angiography of superior mesenteric artery Marked aortic reflux due to reduced flow Extensive constriction of total superior mesenteri arterial bed and non filling of several intestinal branches No evident localized organic occlusion

In one of the patients with occlusion of the main stem of the superior mesenteric artery a rather small collateral blood flow was observed via intestinal arcades (Fig 4) However at operation this collateral blood supply was found to be sufficient

In another patient with a proximal occlusion collateral flow via the middle colic artery was demonstrated and embolectomy alone was sufficient 24 hours after the onset of symptoms The bowel had a slightly cyanotic appearance which improved immediately after the embolectomy and angiography 10 days later demonstrated a patent superior mesenteric artery

In cases of superior mesenteric arterial occlusion constriction of the branches originating proximal to the occlusion was frequently found

In 9 cases constriction of arteries was the only angiographic finding The constriction usually encompassed the total superior mesenteric arterial bed evenly (Fig 5) In one of these the constriction was caused by Deseril In one case however constriction and a considerable flow reduction were mainly noted in intestinal branches (Fig 6)

a b

Fig 6

Fig 6 Selective angiography of superior mesen teric artery Aortic reflux due to flow reduction a) Localized spasms of superior mesenteric and intestinal arteries b) Delayed emptying from the spastic arteries



Fig 7

Fig 7 Postmortem injection of superior mesen teric artery mainly distal to organic occlusion Considerable leakage of contrast medium in gangrenous bowel wall

In 4 cases the vasoconstrictive mechanism was confirmed by intraarterial injection of Tolazolin (20–40 mg) followed by repeat angiography

By postmortem specimen injections in some cases a marked leakage of contrast medium occurred in gangrenous parts of the bowel wall (Fig 7) The location of organic occlusions closely corresponded to the angiographic findings in vivo

Discussion

Vascular occlusion usually caused by embolism or thrombosis is the main cause of bowel gangrene (LAUFMAN et coll 1964) but later reports give a non occlusive etiology with increasing frequency up to 50 per cent (OTTINGER & AUSTEN)

Occlusion and vascular constriction with reduced flow (AAKHUS AAKHUS & BRABRAND WILLIAMS et coll 1967) sudden abnormal tapering of the branches (BRITT & CHEEK) and non uniform arterial spasm with pseudo occlusion (BOIJSEN) have been reported as angiographic indication of vascular insufficiency of the bowel

The present material comprised 22 cases of thrombosis or emboli of mesenteric arteries with visible occlusions at angiography as well as 9 with mesenteric arterial constriction alone Vasoconstriction associated with cardiac disorders shock states and certain drugs seems to be an angiographic indication of non occlusive ischemia It should however be mentioned that a shunt mechanism in the bowel wall depriving the tissues of blood supply in connection with dilated vessels has been claimed by WALTMAN et coll to cause non occlusive ischemia but it seems not to have been demonstrated at angiography

In some cases it may be difficult to determine definitely whether a vasoconstriction means circulatory impairment or not WITTENBERG et coll demonstrated similar abnormalities in a case of acute pancreatitis A vascular occlusion may also be unrelated to an accute condition though abundant collateral flow will then usually be demonstrated Therefore correlation with the clinical condition is necessary in every case HARDIE (1974) claimed that an occlusion demonstrated at angiography must be assumed to be significant if the clinical features suggest mesenteric ischemia If no occlusion is demonstrated non occlusive ischemia may be present

It should be mentioned that venous thrombosis may cause a slowing of flow and vasoconstriction (POLK 1966) Thus it cannot be definitely denied that some of the present cases considered to be non occlusive may have had mesenteric vein thrombosis However the incidence of venous thrombosis as a cause of intestinal ischemia is decreasing because of the use of antibiotics against abdominal infections (PIERCE & BROCKENBROUGH 1970)

The present angiographic experiences may also indicate that an ischemia considered as non occlusive may actually be the late result of an occlusion which has disappeared at the time of the examination An embolus may be dissolved by fibrinolysis (Fig 3) after irreversible ischemic abnormalities have taken place in the bowel wall If the small vessels of the bowel are destroyed by the ischemia (Fig 7)

the bowel circulation may not be completely re established and this may appear by constriction and flow reduction in the mesenteric arteries

Absence of a definite diagnosis and the need for a preoperative angiographic orientation usually are the indications for angiography Successful treatment of these patients requires prompt diagnosis In a patient with acute organic occlusion of the superior mesenteric artery emergency surgery is mandatory

In non occlusive ischemia early operation is probably not indicated because there is no vascular occlusion to correct and the degree and extent of bowel lesions are hard to decide at an early stage (BERGAN 1967 WILLIAMS & KIM 1971 HARDIE)

Many patients with mesenteric arterial thrombosis have warning symptoms before the acute episode (PERDUE & SMITH 1970) These symptoms are those of intestinal angina referable to atherosclerotic stenosis of visceral arteries Unfortunately no objective method to establish this diagnosis exists The correction of such lesions might be the best way of prohibiting an infarction Angiography demonstrates the appearance of the arteries and the circulatory state accurately but still a definite conclusion may be hard to draw WILLIAMS (1971) suggested that occlusion or significant stenosis (over 50 per cent of the diameter) of two of the three visceral arteries should be considered to cause chronic intestinal ischemia

In acute mesenteric vascular insufficiency the examination must be accomplished as early and rapidly as possible and a complete set of films cannot always be obtained Aortography with antero posterior beam direction may be sufficient in some cases but usually a lateral view is of more value for estimating the proximal parts of all three visceral arteries (Fig 1)

In peripheral occlusions and vascular constriction the diagnosis can hardly be made without selective injection (Figs 3 5 6) and the collateral flow may then also be better demonstrated (Fig 4)

The material is still too small to decide if angiography does significantly alter the prognosis of this serious condition but in a number of cases it was definitely of value for the diagnosis and the planning of treatment In most cases of acute mesenteric vascular insufficiency the indication for operation is settled after clinical and conventional radiography In some cases however the diagnosis may be difficult and whether or not to operate hard to decide Therefore if the indication for surgery is not quite clear but circulatory impairment cannot be excluded angiography should be considered

Angiography does not seem to do any harm in these cases It should not delay an operation as it can usually be performed in the course of less than one hour and during the time of observation and preoperative supportive treatment

SUMMARY

The angiographic findings in 31 cases of acute mesenteric arterial insufficiency are presented In 22 cases organic occlusions in 9 vasoconstriction alone were found Angiography aids definitely in the diagnosis and planning of the treatment of this serious condition

ZUSAMMENFASSUNG

Die angiographischen Befunde bei 31 Fallen einer akuten Insuffiziens der Arteria mesenterica werden beschrieben Bei 22 Fallen wurde eine organische Okklusion und bei 9 nur eine Vasokonstriktion gefunden Die Angiographie ermoglicht eine definitive Diagnose und Planlegung der Behandlung dieses ernsthaften Befundes

RÉSUMÉ

Les auteurs decrivent les signes radiologiques dans 31 cas d insuffisance aigue de l artere mesentèrique Dans 22 cas ils ont trouvé des occlusions organiques et dans 9 cas seulement une vasoconstriction L angiographie contribue de façon importante au diagnostic et a l etablissement du traitement de cette affection grave

REFERENCES

AAKHUS T The value of angiography in superior mesenteric artery embolism Brit J Radiol 39 (1966) 928

— and BRABRAND G Angiography in acute superior mesenteric arterial insufficiency Acta radiol Diagnosis 6 (1967) 1

BERCAN J J Recognition and treatment of intestinal ischemia Surg Clin N Amer 47 (1967) 109

BOIJSEN E. Superior mesenteric angiography In Angiography p 1091 Edited by H L Abrams Little Brown and Company Boston 1971

BRITT L. G and CHEEK R C Non occlusive mesenteric vascular disease Clinical and experimental observations Ann Surg 169 (1969) 704

HARDIE J R Intestinal ischemia Med J Aust 2 (1974) 164

KLASS A A The treatment of superior mesenteric artery occlusion A reappraisal Canad med Ass J 93 (1965) 309

LAUFMAN H NORA P F and MITTELPUNKT A I Mesenteric blood vessels Advances in surgery and physiology Arch Surg 88 (1964) 1021

MACGREGOR A M C ABNEY H T and MORRIS L Pharmacodynamic response in nonocclusive mesenteric ischemia Amer Surg. 40 (1974) 381

OTTINGER L W and AUSTEN W G A study of 136 patients with mesenteric infarction Surg Gynec Obstet 124 (1967) 251

PERDUE G D and SMITH R B Intestinal ischemia due to mesenteric arterial disease Amer Surg 36 (1970) 152

PIERCE G E and BROCKENBROUGH E C The spectrum of mesenteric infarction Amer J Surg 119 (1970) 233

POLK H C Experimental mesenteric venous occlusion Ann Surg 163 (1966) 432

RECEK C KREN V FIXA B and STEINHART L. Selective mesentericography as a guide to diagnosis and treatment of acute superior mesenteric artery occlusion J cardiovasc Surg (Torino) 9 (1968) 184

WALTMAN A C JANG G C ATHANASOULIS C A RING E J and BAUM S Emergency gastrointestinal angiography Geriatrics 29 (1974) 48

WILLIAMS L F Vascular insufficiency of the intestine Gastroenterology 61 (1971) 757
— and KIM J P Nonocclusive mesenteric ischemia *In* Vascular disorders of the intestine p 519 Edited by S J Boley S G Schwartz and L E Williams Meredith Corporation New York 1971
— ANASTASIA L F HASIOTIS C A BOSNIAK M A and BYRNE J J Nonocclusive mesenteric infarcation Amer J Surg 114 (1967) 376
WITTENBERG J ATHANASOULIS C A SHAPIRO J H and WILLIAMS L F A radiological approach to the patient with acute extensive bowel ischemia Radiology 106 (1973) 13

FROM THE DEPARTMENTS OF DIAGNOSTIC RADIOLOGY AND SURGERY UNIVERSITY HOSPITAL S 221 85 LUND SWEDEN

ULTRASONOGRAPHY AND ANGIOGRAPHY IN THE DIAGNOSIS OF ABDOMINAL AORTIC ANEURYSM

WILHELM KARP and BO EKLÖF

The incidence of abdominal aortic aneurysm is increasing in Sweden Official statistics show the mortality in cases of ruptured aortic aneurysm in 1973 to be twice that in 1963 Autopsy reports for the city of Malmo (population about 280 000) indicate that 16 women and 20 men per 100 000 die of this condition every year (STERNBY 1977) The outcome of surgery depends upon whether the operation is elective or acute Hospital mortality in 8 153 elective operations reported in the literature was 9 per cent and a number of medical centers in the USA report a mortality of less than one per cent on the other hand the hospital mortality rate in acute operations for rupture is over 50 per cent (CHRISTENSON et coll 1977) Since the incidence of aneurysm is increasing and the results of elective operations have markedly improved in recent years the intention must be to improve the diagnosis so that aneurysms are detected before indication of rupture appears Most aneurysms give no symptoms and are revealed first at abdominal palpation as a pulsating mass When symptoms appear i e pain in the abdomen or back these indicate impending rupture When rupture occurs the classical triad of symptoms appear severe abdominal pain a pulsating abdominal mass and shock

Modern diagnostic approach in the event of abdominal aortic aneurysm is ultrasonography which offers the highest accuracy in the diagnosis and assessing of this

---

Submitted for publication 4 July 1977

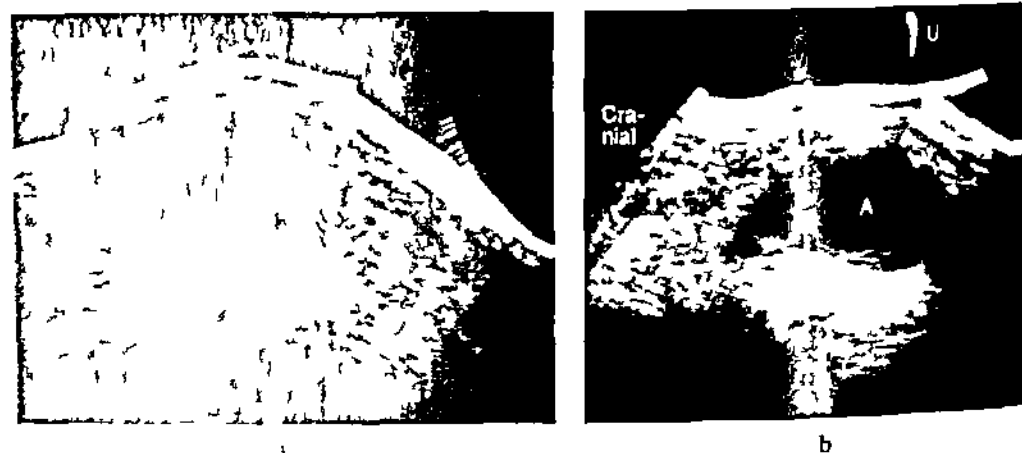


Fig. 1 a) Gr... verse scan at a level 2 cm above the umbilicus Large aortic aneurysm with a diame... b) Grey scale longitudinal scan Same aortic aneurysm at the level of the umbilicus and ... and proximally 13 cm long A = aneurysm U = umbilicus Each bright dot indicate 1 cm

entity (LEOPOLD 1970 MCGREGOR et coll 1976 WHEELER et coll 1976) Abdominal aortography is used mainly to provide vascular details of the aorta and its branches

The experiences in the management of this lesion at this hospital are now reported

Material and Methods

The material comprised 130 consecutive patients (67 males and 63 females of ages ranging from 48 to 86 years) in whom physical examination suggested an abdominal aortic aneurysm Ultrasonography was performed in all cases and aortography in 23 Abdominal aneurysms were found in 42 cases All the patients were examined with standard commercially available ultrasound equipment during the first period of time with compound ultrasonic B scan and later with a grey scale unit A 2 25 MHz transducer with 10 cm focus was used Findings were verified by A mode The examination technique was similar to that described by KRISTENSEN et coll (1972) Briefly it consists of a few transverse sections made every 2 cm from the umbilicus to the xiphoid for establishment of the longitudinal course of the aorta Then transverse sections are performed perpendicularly to the longitudinal course every 1 to 2 cm Finally a longitudinal scan starting at the midline and with sections every centimeter to each side is performed Bowel gas causing acoustic interference impeded the examinations in only a few cases When this occurred the examination was repeated the following day All aortographies were performed using a catheter introduced percutaneously via the femoral artery

The results of ultrasound and aortographic examinations were compared with reference to aneurysm dimension dissection thrombosis and calcifications Ac



Fig 2 a) Grey-scale transverse scan at a level 2 cm above the umbilicus Large aortic aneurysm with a diameter of 7 cm b) Grey scale longitudinal scan Same aortic aneurysm at the level of the umbilicus and distally and proximally 8 cm long At both sides of aneurysm a normal sized aorta (arrows)

cording to STEINBERG et coll (1965) and LEOPOLD any aortic diameter over 30 mm was defined as an aneurysm The results of the examinations were also compared with the findings at operation

Results

In all cases but one the demonstration of the aorta by ultrasound was satisfactory though in some cases tortuosity of the vessel limited the assessment of its entire length in a single plane

At the ultrasound examination an aortic aneurysm with a diameter of 3 to 9 cm was found in 42 of the 130 patients (e g Fig 1) In one case both iliac arteries were involved in the aneurysm Dissection or intraluminal thrombosis in the aneurysmal sac was not demonstrated in any case

Aortography was performed after the ultrasound in 23 patients In 2 cases a fistula between the aorta and the inferior vena cava was demonstrated One patient had an aortic dissection All 23 patients had intraluminal thrombotic masses in the aorta with secondary non filling of lumbar arteries (Figs 2 3) Two other patients had stenosis of the celiac artery and one had stenosis of the renal artery not due to the aortic aneurysm All aneurysms but one began below the renal arteries The iliac arteries were involved in 4 cases Calcification of the aneurysmal wall was revealed in 4 patients

In 13 patients the diameter of the aneurysm as estimated by ultrasound and angiography correlated well in spite of intraluminal thrombosis but in 10 patients with thrombosis ultrasonography showed a larger diameter than the aortography In a majority of cases the difference in size was between 2 and 5 mm The findings at ultrasound and angiography were confirmed at surgery in 18 patients In all these



Fig 3 Same patient as in Fig 2 a) A p and b) lateral view Slight and diffuse dilatation of the abdominal aorta whose size of 4 5 cm does not correspond to its size on ultrasonography Non filling of lumbar arteries indicates a thrombosed aneurysm

cases the diameter of the aneurysm correlated well with that indicated by ultrasound Follow up examinations were performed with 4 to 6 month intervals in 14 patients not operated upon The diameter of the aneurysm was unaltered in all cases

Discussion

The diagnosis of abdominal aortic aneurysm may be settled on abdominal conventional films by the demonstration of calcification in the wall of the aneurysm or a soft tissue mass Since only about 55 per cent of aneurysms have calcification in the wall (STEINBERG et coll 1966) conventional films of the abdomen have limited value Aortography not only demonstrates the aneurysm but also provides vascular details such as involvement of renal iliac or femoral arteries In the present series 2 cases of aorto-caval fistula were found which could only be diagnosed by angiography

Usually an exact estimation of the size of the aneurysm is difficult at aortography it has often been underestimated Intraluminal thrombotic masses prevent filling of the lumbar arteries Non filling of these arteries thus indicates that an aneurysm is present The complication rate is not higher in patients with aneurysm than in those without, if the aortography is correctly performed Aortography from the femoral artery as well as from the axillar may be difficult to perform in elderly patients In such cases intravenous aortography may give satisfactory information

In case of a pulsating mass in the abdomen possibly due to aortic aneurysm ultra sono raphy seems to be the most effective non invasive diagnostic method The accuracy is almost absolute and the evaluation of the diameter of the aneurysm is more exact than with angiography Although the possibility of demonstrating intra luminal thrombosis and dissection of the aneurysm is limited with ultrasonography this information may be obtained by using Real time imaging (WINSBERG et coll 1974) Even in cases with pre aortic tumors mimicking aneurysm ultrasound espe cially Real time imaging has been a useful additional examination method for the differential diagnosis LEE & HENDERSON (1977) reported on 125 patients with pos sible abdominal aortic aneurysms a pre aortic tumor mimicking an aneurysm was found in 15 (12) The present series included no pre aortic tumors With the present diagnostic ultrasound technique it is not possible to determine whether the renal arteries are involved About 95 per cent of abdominal aortic aneurysms begin below the renal arteries A possible extension above this level does not change the indication for surgery Therefore the importance of angiography may be questioned when ultrasound is available With the indications for surgery used at present in cases of symptom free aneurysms i e all younger patients should be operated upon while in patients over 70 years of age the size of the aneurysm should be the decisive factor Ultrasound examination is of great importance in deciding for operation or not In elderly patients the development of the aneurysm may be followed with ultrasound and when the diameter exceeds 5 cm the pat ent may be op ated upon In clinically ruptured aortic aneurysm no diagnostic delay i to be recor ~en d d the patient has to be operated upon immediately

SUMMARY

A material of 130 consecutive patients with clinically possibl abdominal aortic aneurysm was reviewed All of them were examined by ultrasonography and 23 by abdominal aortography as well Ultrasonography revealed aortic aneurysm in 42 patients The manage ment of this entity and the value of different diagnostic methods are discussed The im portance of ultrasonography as a non invasive and accurate diagnostic aid is emphasized

ZUSAMMENFASSUNG

Eine Serie von 130 konsekutiven Patienten mit einem moglichen Aneurysma der Aorta abdominalis wird beschrieben Alle wurden mit Ultraschall und 23 auch mit abdominaler Aortographie untersucht Ein Aortaaneurysma wurde mittels Ultraschall in 42 Patienten

entdeckt Die Behandlung dieser Krankheit und der Wert verschiedener diagnostischer Methoden werden diskutiert Die Bedeutung von Ultraschall als eine nicht invasive und zuverlassige diagnostische Methode wird hervorgehoben

RESUME

Les auteurs ont étudie une serie de 130 malades consécutifs pouvant avoir d après les signes cliniques un anévrysme de l aorte abdominale Tous ces malades ont ete examinés par ultrasonographie et 23 ont aussi eté examinés par aortographie abdominale L ultra sonographie a montré un anévrysme aortique chez 42 malades Les auteurs étudient le traitement de cette affection et la valeur des differentes methodes diagnostiques Ils insistent sur l importance de l ultrasonographie comme méthode diagnostique atraumatique et exacte

REFERENCES

Christenson J Eklof B and Gustafson I Abdominal aortic aneurysm should all be operated? Brit J Surg 64 (1977) 767

Kristensen J K Holm H H and Norby Rasmussen S Ultrasonic diagnosis of aortic aneurysm J cardiovasc Surg 13 (1972) 168

Lee T G and Henderson S C Ultrasonic aortography Unexpected findings Amer J Roentgenol 128 (1977) 273

Leopold G R Ultrasonic abdominal aortography Radiology 96 (1970) 9

McGregor J C Pollock J G and Anton H C The diagnosis and assessment of abdominal aortic aneurysm by ultrasonography Ann roy Coll Surg Engl 58 (1976) 388

Steinberg C R Archer M and Steinberg I Measurement of abdominal aorta after intravenous aortography in health and arteriosclerotic peripheral vascular disease Amer J Roentgenol 95 (1965) 703

Steinberg I and Stein H L Arteriosclerotic abdominal aneurysms Report of 200 consecutive cases diagnosed by intravenous aortography J Amer med Ass 195 (1966) 1025

Sternby N Aorta aneurysm — etiologi och morfologi (In Swedish) Lakartidningen 20 (1977) 2010

Wheeler W E Beachley M C and Ranniger K Angiography and ultrasonography A comparative study of abdominal aortic aneurysms Amer J Roentgenol 126 (1976) 95

Winsberg F Cole Beuglet C and Mulder D S Continuous ultrasound B scanning of abdominal aortic aneurysms Amer J Roentgenol 121 (1974) 626

FROM THE DEPARTMENT OF THORACIC RADIOLOGY (DIRECTOR C TÖRNELL) KAROLINSKA SJUKHUSET S 104 01 STOCKHOLM SWEDEN

LEFT VENTRICLE OF THE HEART ON CONVENTIONAL LATERAL CHEST FILMS

A SZAMOSI

The radiologic image of the heart is not always homogeneous—contrary to a widespread belief Recently the appearance on the full size lateral chest film of the intrapericardiac part of the ascending aorta of the right coronary sulcus and of the anterior border of the left atrium were described (BERGSTRAND & SZAMOSI 1976 SZAMOSI & JERIB 1977 SZAMOSI 1978) In a number of cases also the outline of the left ventricle seemed to be discernible on the lateral chest film An investigation was undertaken in an attempt to analyze this phenomenon more closely

Material and Methods

The original observations were made on lateral chest films of 122 patients including individuals without as well as with clinical heart disease On these films certain features appeared which were considered as segments of the left ventricular outline In 75 cases cardioangiography of the same individual was available and the reported figures refer to this group The indication for angiography was ischaemic or valvular heart disease and the procedure was performed as part of the preoperative evaluation The lateral chest films and the lateral angiograms belonging to the same individual were compared The only requirement of the angiography was that the shape and size of the left ventricle as well as its position within the entire heart were demonstrated on the lateral view Thus either the cavity of the left ventricle or

Based on a lecture given at the meeting of the Swedish Society for Medical Radiology Gothenburg Sweden 1976 Submitted for publication 17 June 1977

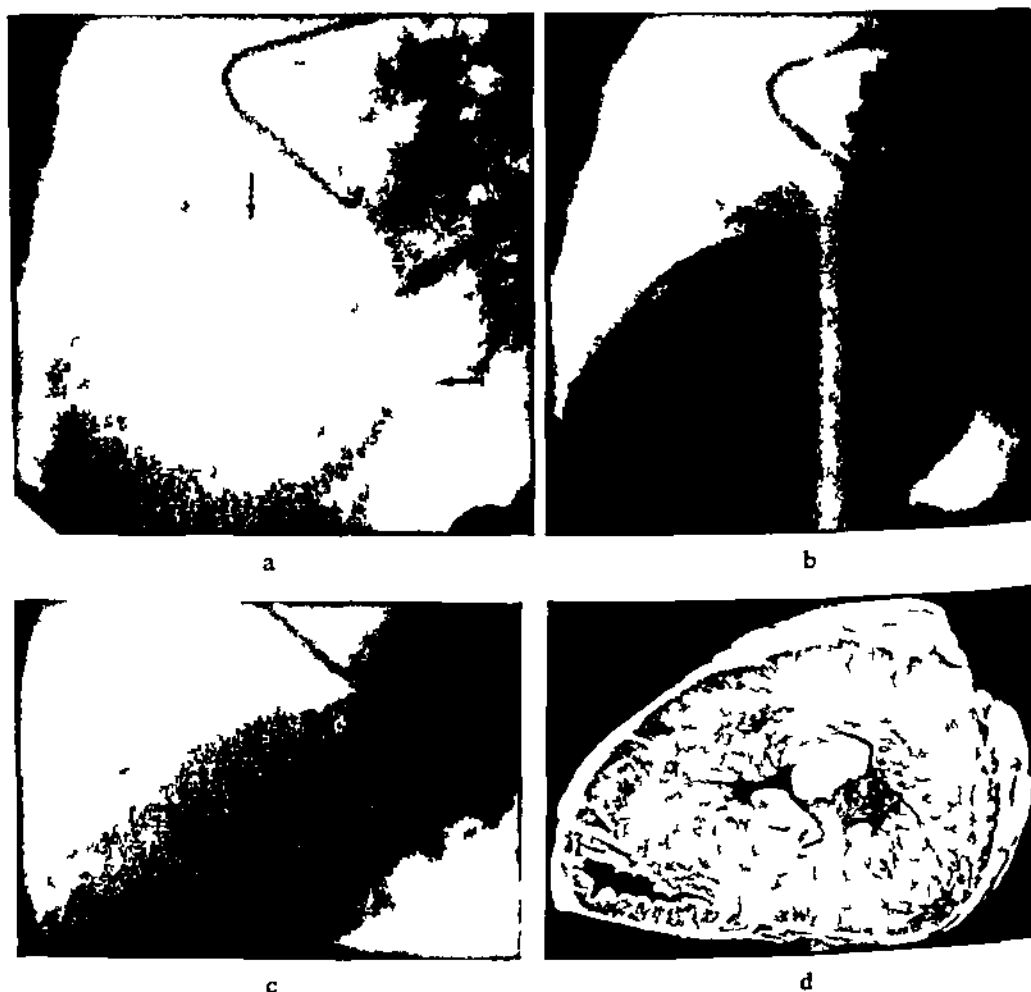


Fig 1 Coronary cineangiography Lateral view a) Before injection Posteriorly and superiorly the left ventricle is surrounded by a narrow zone of diminished attenuation (→) Area of slightly increased attenuation in shape size and position corresponding to the lateral projection of the ventricle b) Arterial phase The anterior interventricular and circumflex branches of left coronary artery in their relation to the left ventricle and the surrounding zone c) Venous phase The large veins follow the same route around the ventricle as the arteries Residual accumulation of contrast medium in the left ventricular muscle mass d) Sagittal section of left ventricle (formaldehyde fixation) for comparison of outlines

easily identifiable major coronary artery branches on the left ventricular surface were discernible usually both

In 66 instances the angiography was performed at this department and recorded on 35 mm cine film by means of a 23/13 cm (9/5 inch) caesium iodide activated image intensifier (23 cm mode) The cameras were run at least 2 to 3 seconds before the beginning of the injection of contrast medium Thus the movements of any inherently visible cardiac structure could be followed for at least 3 or 4 heart beats After the injection of contrast medium the location and movements of the large




Fig. 2. a) Lateral chest film. Standing position. Cardiac phase not known. Left ventricle is delineated as area of increased attenuation. b) Coronary angiography. Supine position. Capillary phase.

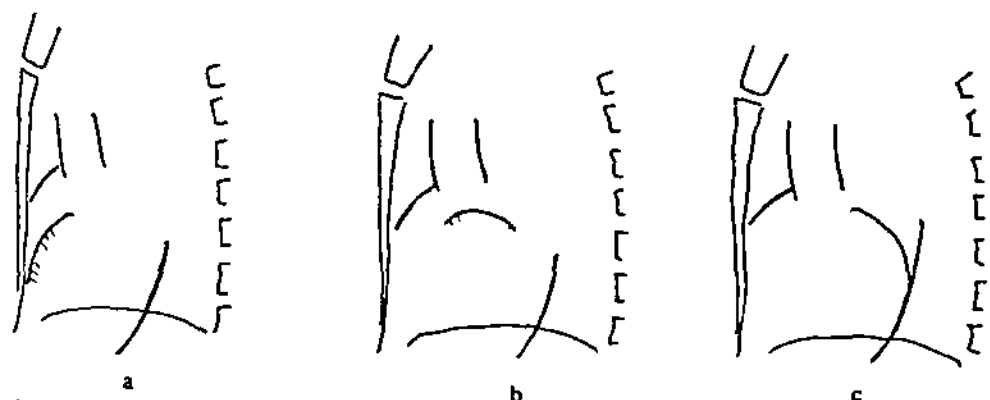


Fig. 3. a) Anterior, b) superior and c) posterior segment of the left ventricular outline.

coronary vessels on the left ventricular surface were observed. Particular attention was paid to the appearance of the left ventricular muscle mass as it became filled during the passage of the contrast medium (capillary phase of the angiography, Fig. 1 a–c). The cardioangiographic appearances were then compared with those on the full size conventional films (Fig. 2). In 9 cases the angiographies were performed at other hospitals with different techniques but also in these cases the relevant features were possible to evaluate.

An account of the technique for obtaining full size chest films was given in previous reports (BERGSTRAND & SZAMOSI, SZAMOSI & JEREB, SZAMOSI). No ECG triggered exposure device was used.

Results

The comparison confirmed the supposition that certain segments of the left ventricular outline were directly visible on the conventional films. Before the be-



Fig 4 Full size chest film Slightly increased attenuation of the region corresponding to the left ventricle Superior and posterior boundaries are outlined by thin zone of diminished attenuation

ginning of the systematic analysis the right coronary sulcus was confused as estimated from the subsequent angiography with the anterior border of the left ventricle in 2 cases They are not included in the present material The visible outline of the left ventricle was arbitrarily divided into an anteriorly and downward sloping anterior segment a horizontally oriented downward concave superior segment and a posteriorly and downward sloping straight or slightly curved posterior segment (Fig 3)

On the full size chest films the boundary of the left ventricle within the heart was perceived as a radiographic contrast between 2 adjacent areas where the left ventricle itself had a higher attenuation (Fig 2 a) or as a thin zone of diminished attenuation suggesting a layer of fatty tissue (Fig 4) On the cine films the zones of reduced attenuation were also observed (Fig 1 a) but their appearances depended on the cardiac phase with a tendency to a sharper delineation in systole The areas of increased attenuation as recorded on the full size films supposedly caused by the bulging mass of the left ventricle were best appreciated on the cine films during the capillary phase of contrast medium transit (Fig 2 b) Often the zones of reduced attenuation seemed to be somewhat more evident due to a simultaneous slight increase in attenuation of an area corresponding to the projection of the left ventricular mass As a rule a clear differentiation between these 2 effects was not possible

The superior border of the left ventricle was distinct and highly contrasting in 4 cases The left ventricle was markedly enlarged and the heart had an almost horizontal position This suggested that in these cases the border between aerated lung tissue



Fig. 5 Fat layer surrounding the left atrial appendix extending posteriorly and downwards around the posterior segment of the ventricular wall Mitral valve disease b) The valve prosthesis indicates the position of the mitral orifice and thus its relation to the fat pad The vertical fat layer between the aorta and anterior left atrial wall also visible (→)

and the heart was probably tangential to the central ray of radiation In the remaining cases the spatial orientation of the long axis of the heart varied widely

The posterior and superior segments were most often observed (45 and 40 cases respectively) The anterior segment appeared in 18 instances Definitely increased attenuation of an area in position shape and size corresponding to the lateral projection of the left ventricular mass was observed in 10 cases Apically and inferiorly this area always coalesced without evident margin with the general level of attenuation of the heart

The superior segment displayed a fairly characteristic relation to the vertical fat layer whenever this was visible between the posterior wall of the ascending aorta and the anterior wall of the left atrium Calcifications or valve prosthesis in the mitral orifice were always observed just anterior and inferior to the junction between the superior and posterior segment (Fig 5)

In a few instances several full size films of the same patient were available partly from other hospitals A comparison revealed that in one and the same individual the outlines of the left ventricle sometimes were visible and sometimes not in a seemingly random manner

Discussion

Previously it has been stated that 3 natural factors may give practically useful contrasts within the radiologic image of the heart (BERGSTRAND & SZAMOSI SZAMOSI & JEPER SZAMOSI) The first is the epicardial fat layer with its extension into furrows



Fig 6 Full size film Posterior and superior border of the left ventricle outlined (→) partly by greater radiographic attenuation of its mass Posterior wall of ascending aorta and anterior wall of left atrium faintly discernible due to fatty layer on their surface (→) Calcifications in the aortic valve Mitral orifice located within the region encircled by arrows

and recesses When present in sufficient amount in a suitable location it appears as a thin zone of diminished attenuation following the outline of the adjacent heart chamber The second factor is the locally varying thickness or bulgings of the heart Under favourable circumstances this may be anticipated to appear as areas of slightly varying attenuation within the outline of the heart The gradual merging of the heart wall from one chamber into another expectedly prevents sharp borders to arise Occasionally the boundary surface between aerated lung tissue and the heart may tangentially be hit by the radiation While the contrast difference is now arising between the heart and an adjacent organ the resulting image of the boundary may depending on the projection be visible within the circumference of the entire heart This represents the third factor The present findings agree with the assumption that they operate when the outline of the left ventricle is visible on a lateral chest film The movements of the heart affect the visibility partly by blurring the faint contrasts that may arise and partly by phasically changing the spatial orientation of the fat layer with respect to the incident beam of radiation

The epicardial fat varies greatly in amount and extent over the surface of the heart between different individuals (BOVE et coll 1966) It is mainly distributed along the main coronary vessels i e along the interventricular and atrioventricular sulci (GOULD 1960) Its appearance at cinefluorography was described by JORGENS et coll (1962) in the context of the radiologic diagnosis of pericardial effusion When the

fatty tissue extends into other areas it still follows the curvature of the surface of the heart For obvious reasons only those parts will be demonstrated where the fatty layer is tangential to the central ray i e where it is parallel to the transverse axis of the body Therefore it is reasonable to consider the anterior segment as that part of the ventricular wall which is lined by the fat in the anterior interventricular sulcus and around the vessels therein The appearance of the superior segment can be due to the common and substantial accumulation of fat under and around the left auricular appendage on the ventricular surface Posteriorly fat may be found in the atrioventricular sulcus i e around the fibrous annulus or along the branches of the circumflex coronary artery on the lateral wall as it bulges outwards and anteriorly from the atrioventricular junction The exact localisation of that wall segment which is outlined is thus dependent on the orientation of the long axis of the ventricle and may remain undetermined However in the present series the posterior segment always coincided with the most posteriorly situated part of the wall as estimated from the capillary phase of the angiography

The ability to delineate segments of the left ventricular circumference within the boundaries of the heart on full size chest films has obvious clinical importance In general it adds to the accuracy and reliability of statements concerning left ventricular s e based on other criteria (EYLER et coll 1959 KEATS et coll 1964 HOFFMAN & RIEGLER 1965 SCHAD & WELLAUER 1968 CHIKOS et coll 1977) In particular it allows the exclusion of significant enlargement of the left ventricle in cases with marked enlargement of the entire heart which usually is considered as difficult (LINDGREN 1963) Together with the recognition of other anatomic landmarks within the heart it aids in understanding the rotational position of the heart The border between the left atrium and ventricle is usually estimated by fluoroscopic observation of the point of opposite pulsations along the contour of the left heart This border may be localized on the conventional lateral film by directly observing the postero-superior extent of the left ventricle or alternatively by direct identification of the anterior border of the left atrium with the aid of the fat layer outlining it The correct estimation of the relative size of the left atrium and ventricle is thus easier It should be possible in suitable cases to record the movements of those regions of the left ventricular wall which are delineated by epicardial fat When the postero lateral wall of the left ventricle is demonstrated simultaneously with the anterior wall of the left atrium the left atrioventricular junction is completely outlined (Fig 6)

Whether the outline of the left ventricle appears on the lateral chest film or not varies admittedly not only between individuals but also in the same individual from time to time Whenever the outline is visible it provides important clinical information available at no extra cost in time work or equipment It is worth to be recognized

SUMMARY

Segments of the left ventricular circumference were visible within the radiologic image of the heart on conventional full size lateral chest films of 122 patients in 75 the findings were

confirmed by cardioangiography The presence of the epicardial fat layer and the locally varying thickness of the heart in the direction of the radiation are considered as main factors in the demonstration of the left ventricular outline The clinical significance of the findings is shortly discussed

ZUSAMMENFASSUNG

Abschnitte der Zirkumferenz der linken Herzkammer waren bei der Rontgenuntersuchung des Herzens mit konventionellen lateralen Vollformat Filmen von 122 Patienten sichtbar bei 75 Patienten wurden die Befunde durch Cardioangiographie bestatigt Das Vorhanden sein einer epikardialen Fettschicht und die lokal variierende Dicke des Herzens in Richtung des Strahlengangs werden als die wesentlichsten Faktoren beim Nachweis der Begrenzung der linken Herzkammer festgestellt Die klinische Signifikanz dieser Befunde wird kurz diskutiert

RESUME

Des segments du contour du ventricule gauche ont ete visibles a l interieur de l image radiologique du coeur sur des radiographies simples en grand format du thorax de profil chez 122 malades chez 75 de ces malades ce resultat a ete confirme par cardioangiographie La presence de la couche de graisse epicardique et la variation locale d epaisseur du coeur dans la direction du faisceau de rayonnement sont considerees comme les facteurs principaux de la mise en evidence du contour du ventricule gauche L auteur etudie brievement l intéret clinique de ces resultats

REFERENCES

Bergstrand G and Szamosi A Visibility of the intrapericardiac segment of the ascending aorta on conventional lateral chest films Acta radiol Diagnosis 17 (1976) 425

Bove K E Rowlands D T and Scott R C Observations on the assessment of cardiac hypertrophy utilising a chamber partition technique Circulation 38 (1966) 558

Chikos P M Figley M M and Fisher L Correlation between chest film and angiographic assessment of left ventricular size Amer J Roentgenol 128 (1977) 367

Eyler W R Wayne D L and Rhodenbaugh J E The importance of the lateral view in the evaluation of left ventricular enlargement in rheumatic heart disease Radiology 73 (1959) 56

Gould S E Pathology of the heart 2nd ed p 122 Charles C Thomas Springfield Ill 1960

Hoffman R B and Riegler L G Evaluation of left ventricular enlargement in the lateral projection of the chest Radiology 85 (1965) 93

Jorgens J Kundel R and Lieber A The cinefluorographic approach to the diagnosis of pericardial effusion Amer J Roentgenol 87 (1962) 911

Keats T E Rudhe U and Foo G Inferior vena caval position in differential diagnosis of atrial and ventricular septal defects Radiology 83 (1964) 616

Lindgren E Hjartundersokning. *In* Rontgendiagnostik, p 98 (In Swedish) Edited by E Lindgren and O Olsson Scandinavian University Books Stockholm 1963

Schad N und Wellauer J Das Schattenbild des Herzens bei abnormer Belastung *In* Lehrbuch der Röntgendiagnostik Band IV Teil 1 Herz und grosse Gefasse p 20 Herausgegeben von H R Schinz, W E Baensch W Frommhold R Glauner E Uehlinger und J Wellauer Georg Thieme Verlag Stuttgart 1968

Szamosi A Anterior border of the left atrium on conventional heart films Acta radiol Diagnosis 19 (1978) 57

— and Jereb M Appearance of the right coronary sulcus at conventional roentgen examination of the heart Acta radiol Diagnosis 18 (1977) 445

FROM THE INSTITUTE FOR SURGICAL RESEARCH AND THE DEPARTMENT OF RADIOLOGY
RIKSHOSPITALET OSLO NORWAY

EFFECT OF MEGLUMINE METRIZOATE AND METRIZAMIDE ON THE MICROCIRCULATION

Animal experiments

A EKELAND and R UFLACKER

The toxic effects of ionic contrast media on the microcirculation have been related to their hypertonicity (O CONNER et coll 1967 ALMEN & WIEDEMAN 1968) This led to the development of the non ionic contrast medium metrizamide (Amipaque) which has a lower osmolality than ionic contrast media with equivalent concentrations of iodine (HOLTERMANN 1973) Metrizamide is reported to have a lower toxicity than ionic contrast media in vertebral angiography (SKALPE 1977) and peripheral angiography (ALMÉN 1977 EVENSEN et coll 1977)

The effect of metrizamide and meglumine metrizoate (Isopaque) on the microcirculation was compared in previously inserted ear chambers following injection into the main ear artery of unanesthetized rabbits The results are now reported

Materials and Methods

Ear chambers of titanium were inserted into both ears of 10 French Wedder rabbits by the method of SUDMANN (1975) The animals were kept in separate cages at constant temperature (22 C) and fed a standard stock diet and tap water ad libitum Connective tissue and blood vessels grew into the chamber which after 6 weeks was completely vascularized The vascular bed in the chamber had a thickness of 127 μ Two months after the insertion of the chamber the unanesthetized rabbit was

Submitted for publication 30 January 1978




Fig 1 a) Rabbit in a restraining box under a Leitz Ortholux II microscope a film camera (Leicina) above the microscope b) Chamber in the rabbit s ear is transilluminated and microcirculation within the chamber observed

mounted in a restraining box under a microscope (Ortholux II Leitz) allowing the transillumination of the ear chamber (Fig 1) A minor area in each chamber including an arteriole a venule and a rich capillary net was selected for recording the microcirculation (Fig 2) The main ear artery of the tranquilized rabbit (fluanisone 1 mg/kg and fentalyl citrate 0 02 mg/kg Hypnorm Veterinary) was cannulated (Miniven 25 gauge 2 mm Portex) Physiologic saline 1 5 ml was injected by hand at constant pressure washing out the blood in the chamber The time elapsing from the wash out of the blood to refilling of the arteriole the time of ischemia was recorded The ischemic times for 9 injections of saline were determined The injections were performed at intervals of 2 min and after the last injection the catheter was removed

At intervals of one week aliquots (1 5 ml) of the ionic meglumine metrizoate and the non ionic metrizamide with 2 different concentrations of iodine (Table) were injected into the ear artery Only one concentration of the contrast medium was injected each time The temperature of the injected solutions was 25 C and the injection time 3 to 6 s Before each injection of contrast medium aliquots of saline were twice injected to observe the vascular response and the ischemic times were recorded Each contrast medium was injected 5 times followed by another 2 saline injections The ischemic times for meglumine metrizoate 280 mg I/ml were determined in 5 rabbits for the other contrast media in 6 rabbits

Cinematography of the microcirculation (Leicina special Leitz Kodachrome 40 super 8 mm 54 frames/s) was performed before and during injections of saline and the different contrast media



a b

Fig. 2. Vascular bed in rabbit ear chamber a) Blood is entering the area through an arteriole (A) The arteriole is branching into a capillary bed (B) and the area is drained by a small vein (C) joining a larger vein (D) b) Intra arterial injection of fluid washes the blood out making the area ischemic

The blood gases (pO_2 and CO_2) and acid/base values (pH and BE) were determined in arterial and venous blood from the ear of 5 rabbits before and after injection of saline and the contrast media

After the capillary bed had been exposed to saline and metrizamide 370 mg I/ml the stable protein-dye complex (12 mol Evans blue/mol albumin RAWSON 1943) was injected to test the capillary permeability

The results were evaluated statistically using Wilcoxon s ranking test and Wilcoxon s test for pair differences (DIEM & LENTNER 1975) Differences were considered significant when $2\alpha \leq 0\ 10$)

Table

Contrast media compared with human blood (based on data from Nyegaard & Co Oslo and Geigy Scientific Tables 1975)

	Iodine concentration (mg/ml)	Osmolality (mol/kg 37 C)	Viscosity (cP)	
			20 C	37 C
Meglumine metrizoate (Isopaque Cerebral)	280	1 46	7 2	4 0
Meglumine metrizoate (Isopaque Coronar)	370	2 15	17 3	8 5
Metrizamide (Amipaque 280)	280	0 456	9 66	5 01
Metrizamide (Amipaque 370)	370	0 6 (approximately)	37	15 7
Human blood		0 301		2 30–2 75

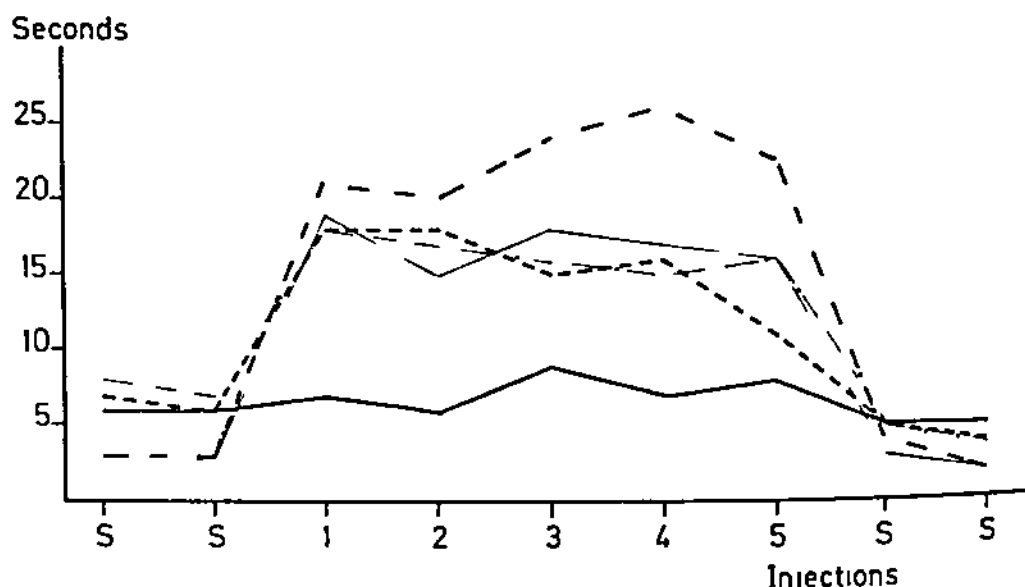


Fig 3 Ischemic times for physiologic saline and contrast media in one rabbit S = saline injection 1 2 etc injection of contrast media or saline —— Saline --- meglumine metrizoate 280 mg I/ml —— meglumine metrizoate 370 mg I/ml — — metrizamide 280 mg I/ml - - metrizamide 370 mg I ml

Results

Ischemic times for physiologic saline and different contrast media in one rabbit appear in Fig 3 In the ear chamber the microcirculation in an area may change from one day to the other Therefore the microcirculation was evaluated in areas with a good circulation at the beginning of each experiment which meant that it was some times necessary to observe another area than the preselected one in the chamber To account for that the mean of the ischemic times of the 2 saline injections starting each experiment was set to 1 and the ischemic times following the 5 injections of contrast medium and the 2 last saline injections were calculated according to this value The median for these calculated values in all the rabbits is given in Fig 4

The ischemic time after injection of contrast media was significantly longer than after physiologic saline injection ($2\alpha \leq 0.02$–0.10) Metrizamide 370 mg I/ml caused the longest ischemic time followed by metrizamide 280 mg I/ml and the 2 meglumine metrizoate solutions but the differences were not statistically significant When only saline was injected the ischemic time did not change with the number of injections Saline injected before a contrast medium caused a longer ischemic time than the second saline injection after the medium This difference was significant ($2\alpha < 0.05$–0.10) and means an increased blood flow following intra arterial injection of contrast media

Microcirculation Injection of saline did not cause any change in the microcircula tion beside transient ischemia When contrast media were injected the capillary bed was filled with a material more viscous than blood After the ischemic period the

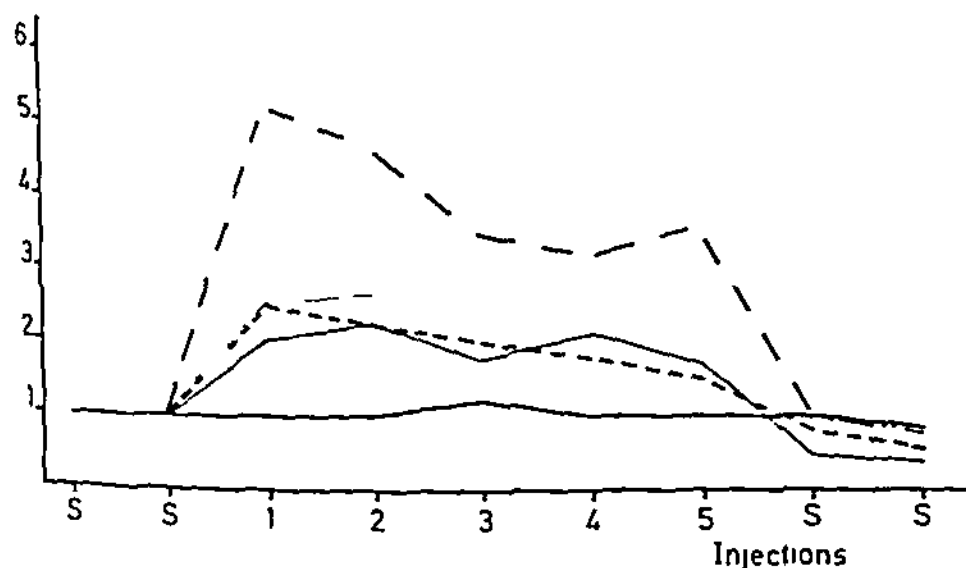


Fig 4 Ischemic times for physiologic saline and contrast media related to the ischemic time values of 2 saline injections starting each experiment Median of saline related values in all the rabbits g ven. S = saline injection 1 2 etc injection of contrast media or saline —— Saline --- meglumine metrizoate 280 mg I ml —— meglumine metrizoate 370 mg I/ml — — metrizamide 280 mg I/ml - - metrizamide 370 mg I/ml

arteriolar and venular flow was slow for 15 to 120 s followed by a phase with a more rapid flow lasting from 5 to 15 min This rapid flow was observed in vessels constituting a direct communication between an arteriole and a venule (by pass channels) while the flow in the main part of the capillary bed was still very slow or arrested This indicates a shunting of the blood by passing most of the capillary bed Crenation of erythrocytes and adherence of leukocytes to the vessel wall were also observed

Exposure of the capillary bed to meglumine metrizoate 370 mg I/ml and the 2 metrizamide concentrations caused the most marked changes of the microcirculation Metrizamide in both concentrations was adherent to the vessel wall for some seconds after the blood flow was re-established This did not occur with the meglumine metrizoate solutions

No significant changes in the blood gases and acid/base values occurred following intra arterial injection of the media Capillary leakage of protein bound Evans blue into the tissue was not observed after exposure of the capillary bed to metrizamide 370 mg I/ml

An hour after the injection of the contrast media the microcirculation appeared normal

Discussion

BRÅNEMARK et coll (1969) SÖRENSEN & ASANO (1971) and ALMEN (1973) have investigated the effects of different contrast media on the microcirculation In most

reports anesthetized animals were used (DERRICK et coll 1968 BRÅNEMARK et coll SORENSEN & ASANO) which may have influenced the results In some experiments the contrast media have been applied outside the vessels (ALMEN & WIEDEMAN 1968 BRÅNEMARK et coll, SORENSEN 1971 ALMEN 1973) This mode of application is different from the way contrast media are used in humans

The rabbit ear chamber has been widely used to observe the microcirculation in long term experiments (BRÅNEMARK 1966) When the chambers are inserted in long eared rabbits (Wedder or Sandy half lop) the circulation within the chamber can easily be observed in the unanesthetized animal and without exposing the observed tissue for mechanical stress Drugs can be injected into the ear artery of the rabbit The rabbit ear chamber was found to be a convenient experimental model to analyse the effect of contrast media as the media can be injected intra arterially in a similar way as in humans

Contrast media have an evident but temporary effect on the microcirculation Used in peripheral angiography, they have been reported to increase the venous blood flow (LINDGREN & TÖRNELL 1958) In the present experiments the media also increased the blood flow but most of the blood was shunted from the arterioles to the venules via by pass channels The capillary circulation was slowed down which probably means that the tissue nutrition was poor This is an agreement with the observations of SÖRENSEN & ASANO Contrast media should therefore not be used therapeutically to produce vasodilatation

The toxic effects of contrast media have been related to their hypertonicity but other factors may also be of importance Thus SORENSEN reported that contrast media always caused more injury to the microcirculation than equimolar saline solutions In the rabbit ear chamber intra arterial injection of contrast media fills the capillary bed with a viscous material offering resistance against blood flow When blood re-enters the chamber after the injection it traverses the shortest arteriolo venular distance in the capillary bed (by pass channels) as there is less viscous material and thus less resistance This may contribute to the explanation of the observed arteriovenous shunting

LINDGREN & VIRTAMA (1968) reported arterial constriction and arterio venous shunting when solutions with temperatures below 30 C were injected into the ear artery of the rabbit The temperature of the injected solutions in the present experiments was 25 C Arterio venous shunting was observed following injections of contrast media but not following saline injections The viscosity of the media is about 50 per cent less at 37°C than at 20 C (Table) and as both temperature and viscosity may be factors of importance in clinical angiography large volumes of the media ought to be injected at body temperature

In evaluating the ischemic time the viscosity of the media probably plays some role However this cannot be the only factor of importance as there is no significant difference between the ischemic time caused by metrizamide 280 mg I/ml and meglumine metrizoate 370 mg I/ml while the viscosity of the latter is 70 per cent higher

The osmolality of metrizamide 280 mg I/ml is only slightly above that of blood so possibly other unknown properties of the media are of importance for their effect on the microcirculation ALMÉN (1976) found a less toxic effect of contrast media on venous vasomotion when they were mixed with a solution of cations (Na K Ca Mg)

Adherence of metrizamide to the vessel wall may be an advantage when a prolonged accumulation of contrast medium during the capillary phase of an angiography is desirable It is uncertain if this adherence harms the endothelium As after injection of the meglumine metrizoate solutions adherence of leukocytes to the vessel walls was observed Increased capillary permeability is caused by several of the ionic contrast media (HARRINGTON & WIEDEMAN 1965 SÖRENSEN) but capillary leakage of albumin bound Evans blue following metrizamide 370 mg I/ml was not observed

Thus further experiments are required to decide which properties of the contrast media are responsible for their toxic effects

Conclusion No significant differences between the toxic effects of meglumine metrizoate and metrizamide were observed Both contrast media caused temporary arteriolo venular shunting and poor capillary circulation which may influence the tissue nutrition

SUMMARY

Physiologic saline meglumine metrizoate (Isopaque) and metrizamide (Amipaque) were injected into the ear artery of Wedder rabbits The effect on the microcirculation in previously inserted ear chambers was recorded by cinematography Following injection of the contrast media the circulation was slow followed by a phase with arteriolo venular shunting and poor capillary circulation

ZUSAMMENFASSUNG

Physiologische Kochsalzlosung, Meglumin Metrizoat (Isopaque) und Metrizamid (Amipaque) wurden in die Ohrarterie von Wedder Kaninchen injiziert Die Wirkung auf die Mikrozirkulation von zuvor eingesetzten Ohrkammern wurden kinematographisch registriert Im Anschluss an die Injektion der Kontrastmittel war die Zirkulation langsam gefolgt von einer Phase mit arteriolo venoser Shunt Bildung und einer geringen Kapillarzirkulation

RESUME

Du serum sale physiologique du metrizoate de meglumine (Isopaque) et du métrizamide (Amipaque) ont éte injectés dans l artère de l oreille de lapin Wedder On a enregistré par cinematographie l effet de ces injections sur la microcirculation au moyen de chambre insérée préalablement dans l oreille Apres injection des moyens de contraste la circulation est lente suivie par une phase de shunting artériolo vénulaire et de mauvaise circulation capillaire

REFERENCES

ALMÉN T Application of non ionic and ionic contrast media to the external vessel surface Acta radiol (1973) Suppl No 335 p 239

— Effects on venous vasomotion from the ionic content of contrast agent solutions Acta radiol Diagnosis 17 (1976) 439

— Angiography with metrizamide Animal experiments and preliminary clinical experiences Acta radiol (1977) Suppl No 355 p 419

— and WIEDEMAN M F Application of contrast media to the external surface of the vasculature Invest Radiol 3 (1968) 151

— — Application of monomers and polymers to the external surface of the vasculature Invest Radiol 3 (1968) 408

BRÅNEMARK P I Intravital microscopy Its present status and its potentialities Med biol Ill 16 (1966) 100

— JACOBSSON B and SORENSEN S E Microvascular effects of topically applied contrast media Acta radiol Diagnosis 8 (1969) 547

DERRICK J R BROWN R W LIVANEC G BOND T P and GUEST M M Experimental effects of selective arteriography on the microcirculation Amer J Surg 116 (1968) 712

DIEM K and LENTNER C Scientific tables p 124 Geigy Ciba Basle 1975

EVENSEN A EYJOLFSSON O JOHNSRUD N og JONMUNDSSON E Metrizamid som kontrast middel ved ekstremitetsangiografi (In Norwegian) Tskr N Lægeforen 30 (1977) 1565

HOLTERMANN H Metrizamide Introduction Acta radiol (1973) Suppl No 335

LINDGREN I und VIRTAMA P Wirkungen der Temperatur des Kontrastmittels bei intra arteriellen Injektionen Rontgen Bl 21 (1968) 480

LINDGREN P and TORNELL G Blood circulation during and after peripheral arteriography Acta radiol 49 (1958) 425

O CONNER J F SITZMAN S B and DEALY JR J B Vascular injury due to topical application of cardio-vascular contrast medium in the hamster cheek pouch Radiology 89 (1967) 20

RAWSON R A The binding of T 1824 and structurally related diazo dyes by the plasma proteins Amer J Physiol 138 (1943) 708

SKALPE I O The toxicity of the non ionic watersoluble contrast medium metrizamide (Amipaque) in selective vertebral angiography Neuroradiology 13 (1977) 19

SÖRENSEN S E Changes in vascular permeability after local application of roentgen contrast media in the hamster cheek pouch Acta radiol Diagnosis 11 (1971) 274

— and ASANO M Effects of water soluble contrast media on the microcirculation in peripheral nerves Acta radiol Diagnosis 11 (1971) 402

SUDMANN E A novel titanium rabbit ear chamber for vital microscopy of bone tissue Acta orthop scand (1975) Suppl No 160 p 17

FROM THE DEPARTMENT OF PHYSIOLOGY UNIVERSITY OF AACHEN D-5000 AACHEN GERMANY

EFFECT OF IONIC AND NON IONIC CONTRAST MEDIA ON WHOLE BLOOD VISCOSITY, PLASMA VISCOSITY AND HEMATOCRIT IN VITRO

P Aspelin

It is now generally accepted that the non Newtonian viscous characteristics of blood are the consequence of at least two different mechanisms related to the rheology of the red cell aggregation and deformation (Chien 1971 Chien et coll 1967 a b Goldsmith & Mason 1965 Schmid-Schönbein & Wells 1973 Schmid-Schönbein et coll 1969 a b 1973 Wells et coll 1962) At shear rates below 40 s^{-1} there is a rise in whole blood viscosity which increases with decreasing shear rate This increase in whole blood viscosity has been shown to be due to a reversible aggregation of red cells into a three dimensional structure of rouleaux (Chien et coll 1967 b Schmid-Schönbein & Wells 1969 a Schmid Schönbein et coll 1968 1973 c) At shear rates above 40 s^{-1} the blood viscosity decreases with increasing shear rate (shear thinning) which has been shown to be due to red cell deformation (Chien et coll 1967 Schmid-Schönbein & Wells 1973 Schmid Schönbein et coll 1973 a)

The general laws concerning erythrocyte deformability have been elaborated by Fung (1966) He considered the red cell to have a flexible shell (the membrane) in completely filled with a viscous incompressible fluid (the hemoglobin solution) This incomplete filling of the normal biconcave erythrocyte means that the red cells may be deformed into a variety of shapes without changes in volume and surface area The resistance to deformation of the red cell is dependent on the membrane

Supported by the Swedish Medical Research Council Project No 3483 (The author is now at Department of Diagnostic Radiology Malmo Allmänna Sjukhus S 214 01 Malmo Sweden) Submitted for publication 16 December 1977

tension and the viscosity of the hemoglobin solution At shear rates above 40 s^{-1} the deformability of the normal cell induces a fluid transition of the erythrocyte caused by a rotation of the membrane with and around the cell contents (CHIEN 1971) This phenomenon is the prime cause of the progressive reduction of viscosity with increasing shear rate (CHIEN 1971 SCHMID SCHÖNBEIN et coll 1973 a)

It is also well known that at a given temperature the viscosity of blood is not only a function of shear conditions but also varies with plasma viscosity (CHIEN 1970 1971) and hematocrit (CHIEN 1970 1971 WELLS & MERRIL 1962) A useful and generally accepted theory on these variations in blood viscosity has been presented by CHIEN He proposed that the changes in viscosity could be explained by changes in effective cell volume (sum of the particle volume and the volume of the surrounding fluid that behaves as if it were a rigid extension of the particle) an increase in effective cell volume increases the viscosity of the solution and vice versa As the effective cell volume is a function of concentration aggregation deformation and shear conditions of the red blood cell the variation of blood viscosity with hematocrit plasma composition and shear rate can be explained on the basis of changes in effective cell volume

The rise in blood viscosity at shear rates below 40 s^{-1} is thus explained by the formation of rouleaux of red cells These rouleaux increase the effective cell volume as a result of the increase in their axial ratio compared with the individual red cell axis and by the limitation in deformability of the red cell in the rouleaux The decrease in blood viscosity at shear rates above 40 s^{-1} is explained by the fact that the red cell at these shear conditions assumes an ellipsoid shape with the major axis aligned in flow which reduces the effective cell volume and thus the viscosity of the suspension

These viscous properties of normal blood have been shown to be markedly changed when the plasma osmolality is increased (MEISELMAN et coll 1967 RAND & LACOMBE 1964 READ et coll 1962 SCHMID SCHÖNBEIN & WELLS 1969 b SCHMID SCHÖNBEIN et coll 1969 a WELLS & SCHMID SCHÖNBEIN 1969) It has been demonstrated by SCHMID SCHONBEIN & WELLS (1969 b) that hypertonic saline solutions crenate the red cell and reduce whole blood viscosity at shear rates below 40 s^{-1} because the crenation abolishes the formation of red cell aggregates At shear rates higher than 40 s^{-1} however the blood viscosity is increased because the osmotically crenated cells have a reduced deformability The reduced deformability and greater effective volume of the osmotically crenated cell compared with the normal biconcave erythrocyte are shown by the fact that normal red cells can be packed by centrifugation so that the sediment volume consists to nearly 10 per cent of cells whereas crenated erythrocytes can be packed to a sediment volume consisting only 60 per cent of cells (CHIEN 1971)

Currently used contrast media are highly hypertonic solutions with osmolalities of 1 5 to 2 5 osm (ALMÉN & ASPELIN 1975 ALMÉN et coll 1975) and mixed with blood they have been found to induce red cell crenation (ASPELIN 1978 BERNSTEIN et coll 1964 BRÅNEMARK et coll 1969 BROWN et coll 1968 CHAPLIN & CARLSSON

Table 1

Iodine concentration osmolality and viscosity of contrast media investigated

Contrast medium	Osmolality (osm)	Iodine content (mg I/ml)	Viscosity (cps) 37 C
Urografin 60	1 5	290	4 5
Urografin 76	2 1	370	8 5
Isopaque Cerebral	1 5	280	4 0
Isopaque Coronar	2 1	370	8 5
Dimer X	1 1	280	7 2
Amipaque	0 5	280	5 0
Amipaque	0 7	370	14 0

1961 LASSER et coll 1962 RAND & LACOMBE 1965 SCHIANTARELLI et coll 1973 SVOBODA & FIALA 1964) and an increase in blood viscosity in spite of a decrease in hematocrit (BERNSTEIN et coll RAND & LACOMBE 1965) With the development of dimeric ionic (HILAL 1970) and monomeric non ionic substances (ALMÉN 1969 HOLTERMANN 1973) there are now contrast media available that in iodine-equivalent concentration have the osmolality of one half or one third of those currently used (HOLTERMANN)

After exposing blood to contrast media ASPELIN demonstrated that both ionic and non ionic contrast media converted the red cells into crenated cells (echinocytes) a d at high volume ratio (contrast medium/blood) the ionic contrast media of high osmolality converted the red cells into markedly shrunken cells (desiccocytes) It was also shown that both ionic and non ionic contrast media abolish or reduce the formation of red cell aggregates in vitro (ASPELIN)

Th se changes in red cell morphology and aggregation can thus be expected to influence the viscous characteristics of blood Therefore it w is motivated to in vestigate the effects of ionic and non ionic contr st media in vhole blood viscosity plasma viscosity and hematocrit

Material and Methods

Blood from healthy humans was obtained by vein puncture and anticoagulated with EDTA (1 5 mg/ml) After centrifugation the hematocrit value was adjusted to 45 per cent by removing either plasma or red cells The blood was then mixed either with physiologic saline or contrast medium solutions The following contrast media w e used A Ionic monomeric Urografin (meglumine/sodium diatrozoate) Isopaque Cerebral (meglumine/calcium metrizoate) and Isopaque Coronar (meglumine/sod um/calcium metrizoate) B Ionic dimeric Dimer X (meglumine iocarmate) C Non ionic Amipaque (metrizamide)

Table 2

Changes in hematocrit after mixing blood (45 hct) with different test solutions Values within parentheses denote extrapolated values The values presented are mean values (n = 5) range ± 1 0 per cent

Test solution	Volume ratio (per cent)					
	1	5	10	20	25	50
Blood – saline	44	42	40	37	34	24
Blood – Amipaque 280 mg I/ml	44	40	37	35	(33)	—
Blood – Dimer X	43	38	34	30	25	—
Blood – Isopaque Cerebral	42	37	34	29	23	—
Blood – Urografin 60	42	37	34	28	22	—
Blood – Amipaque 370 mg I/ml	43	39	37	(34)	—	—
Blood – Isopaque Coronar	42	35	31	29	—	—
Blood – Urografin 76	42	36	31	29	—	—

The osmolality iodine concentration and viscosity of the tested contrast medium solutions are presented in Table 1 The blood was mixed with saline or contrast medium solutions in the following volume ratios (test solution/blood) 1 5 10 20 25 and 50 per cent

At each volume ratio blood samples from five different blood donors were examined

Whole blood viscosity was measured in a Wells Brookfield cone plate micro viscometer LVT 1 at 37 C *at the following shear rates* 16 s^{-1} 80 s^{-1} and 160 s^{-1} Plasma viscosity was determined by a Coulter Harknes capillary viscometer at 37 C

Hematocrit was determined with the microhematocrit method after centrifugation at 16 000 g for 30 min Normally hematocrit (at this g number) is determined after a centrifugation for 5 min but when Amipaque solution of 280 mg I/ml was added to blood the plasma density became so close to red cell density that a centrifugation for 30 min was required to separate plasma and red cells In 25 per cent volume ratio of the 370 mg I/ml solutions and in 50 per cent volume ratio of all the contrast medium solutions the increased plasma density created by the addition of the heavy contrast media (density about 1 2) made the red cells (density about 1 1) less dense than the contrast diluted plasma As a result the red cell column rose to the top of the centrifuge tube and no hematocrit could be measured Packing the cells was also difficult which was also encountered by RAND & LACOMBE (1965) and BERNSTEIN et coll and a closer packing was obtained after 30 min than after 5 min of centrifugation The hematocrit values were not corrected for trapped plasma

The relative apparent blood viscosity (η_{rel}) was obtained by dividing the whole blood viscosity by the plasma viscosity In this way the effect of plasma viscosity was eliminated and the viscous effect of the cellular elements quantified

Table 3

Charges in blood viscosity (cps) at 37 C after mixing bl od with different test solutions The bl od viscosity (ithout additive) was at shear rate 16 s⁻¹ 5 ?±0.3 cps at 80 s⁻¹ 4 0±0.3 and at 160 s⁻¹ 3 4±0.3 cps The values presented are mean values (n−5) ± SD

	Volume ratio (per cent)								
	1			10			50		
Shear rate s⁻¹	16	80	160	16	80	160	16	80	160
Blood + saline	4 8±0 3	3 7±0 3	2.9±0 2	3 7±0 2	3 3±0 2	2 6±0 3	1 5±0 2	1 3±0 2	1 2±0 2
Blood + Amipaque -80 mg I ml	5 0±0 2	3 8±0 2	3 1±0 3	6 7±0 2	6 0±0 3	5 4±0 4	3 7±0 2	3 7±0 1	3 6±0 1
B ood + Dimer X	5 5±0 3	4 0±0 3	3 3±0 2	5 8±0 2	5 1±0 3	4 8±0 3	4 3±0 2	4 4±0 3	4 6±0 3
Blood + Isopaque Cerebral	5 1±0 2	3 9±0 2	3 2±0 3	6 5±0 3	6 0±0 2	5 3±0 3	4 6±0 3	4 6±0 2	4 7±0 2
Blood + Urografin 60	5 4±0 3	3 9±0 3	3 2±0 3	6 6±0 3	6 1±0 3	5 4±0 3	3 7±0 2	3 8±0 2	4 0±0 2
Blood + Amipaque 370 mg I ml	5 4±0 2	4 0±0 2	3 4±0 3	7 0±0 2	6 1±0 2	5 3±0 2			
B ood + Isopaque Coronar	5 5±0 3	4 0±0 3	3 3±0 2	6 5±0 2	5 9±0 3	5 3±0 3			
B ood ± Urografin 76	5 7±0 3	4 0±0 3	3 3±0 3	7 1±0 3	6 0 3	5 5±0 2			

Results

Effect on hematocrit The hematocrit values obtained following the dilutation of blood (45% hematocrit) with physiologic saline or the contrast media appear in Table 2 It is evident that both the contra t medium solutions and the saline reduce th hematocrit and that the reduction increases with increasing dilution The dif ferent contrast medium solutions reduce the hematocrit more with increasing volume ratio than the saline At iodine equivalent concentrations the contrast media of low osmolality reduced the hematocrit less than those of high osmolality (metrizamide < iocarmate < metrizoate and diatrizoate)

Effect on whole blood viscosity The changes in whole blood viscosity are presented in Table 3 To avoid complexity only the values at 1 10 and 50 per cent volume ratio are presented

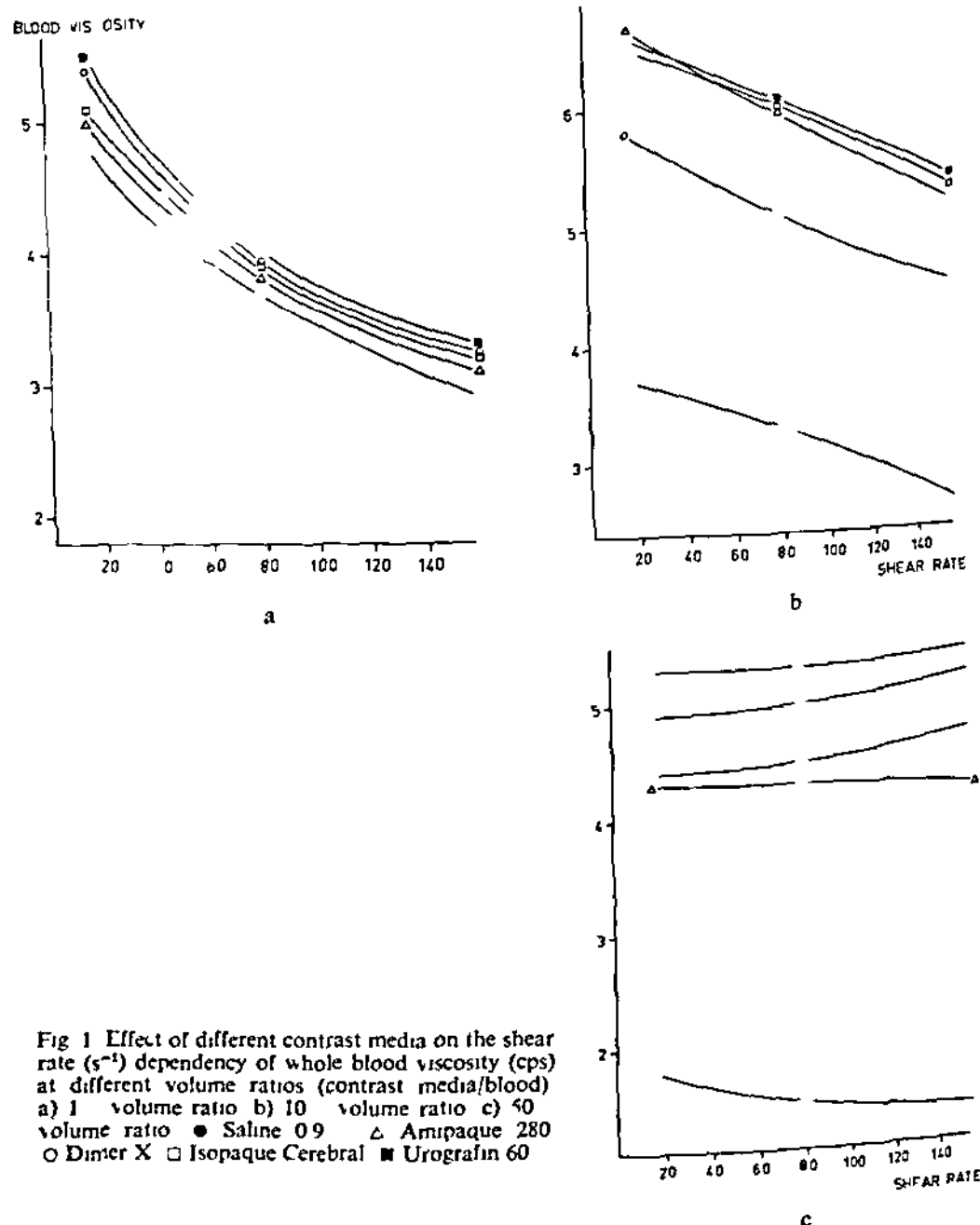


Fig 1 Effect of different contrast media on the shear rate (s^{-1}) dependency of whole blood viscosity (cps) at different volume ratios (contrast media/blood) a) 1 volume ratio b) 10 volume ratio c) 50 volume ratio ● Saline 0 9 △ Amipaque 280 ○ Dimer X □ Isopaque Cerebral ■ Urografin 60

Mixing blood with contrast media markedly increase the whole blood viscosity compared with mixing with physiologic saline In evaluating the shear rate dependency of whole blood viscosity (Fig 1) it is evident that in low volume ratio (1 and 10%) whole blood viscosity decreases with increasing shear rate (shear thinning) without any significant difference between the different contrast media

Table 4

Changes in plasma viscosity (37 C) after mixing blood with different solutions The plasma viscosity of the blood without additive was 1.3 to 1.4 cps The values presented are mean values (n = 5) range within ±0.2 cps

Test solution	Volume ratio (per cent)					
	1	5	10	20	25	50
Blood + saline	1.3	1.1	1.0	1.0	0.9	0.9
Blood + Amipaque 280 mg I/ml	1.3	1.4	1.5	1.8	2.2	2.9
Blood + Dimer X	1.3	1.4	1.6	2.1	2.6	3.5
Blood + Isopaque Cerebral	1.3	1.3	1.5	1.7	2.0	2.4
Blood + Urografin 60	1.3	1.3	1.5	1.7	2.1	2.5
Blood + Amipaque 3.0 mg I ml	1.3	1.4	1.7	2.3	3.3	—
Blood + Isopaque Coronar	1.3	1.4	1.7	2.2	2.8	—
Blood + Urografin 76	1.3	1.4	1.6	2.2	2.6	—

(Fig 1 a) With increasing volume ratio this shear thinning is reduced (Fig 1 b) and at 50 per cent volume ratio (Fig 1 c) the whole blood viscosity of the ionic contrast media of high osmolality even increases with increasing shear rate (shear thickening) At this volume ratio the viscosity of the suspension of blood and the non ionic contrast medium of low osmolality still decreases slightly with increasing shear rate (Fig 1 c) This difference between the Amipaque and the three ionic contrast media was statistically significant ($p < 0.01$)

Effect on plasma viscosity The obtained values on plasma viscosity are given in Table 4 It is evident that mixing blood with saline decreased plasma viscosity with increasing dilution On the other hand mixing blood with contrast media increases plasma viscosity with increasing dilution and the contrast media with the highest viscosity increase the plasma viscosity most (iocarmate > metrizamide > metrizoate and diatrizoate)

Effect on relative apparent blood viscosity (η_{rl}) Fig 2 shows the η_{rl} as a function of hematocrit (decreasing hematocrit means increasing volume ratio contrast medium / blood) at 160 s^{-1} shear rate and at 10 20 and 25 per cent volume ratio As the viscosity of blood is dependent on both plasma viscosity and hematocrit these factors are eliminated in Fig 2 The viscous effect of the cellular elements in the blood can be compared at the same extrapolated hematocrit value It is obvious that with low volume ratio (to the right in Fig 2) the difference in blood viscosity is small between the different contrast media but it increases with increasing volume ratio (to the left in the figure) Thus the low osmotic non ionic Amipaque induces at high volume ratio relatively smaller increase in η_{rl} than the ionic Dimer X ($p < 0.001$) Dimer X

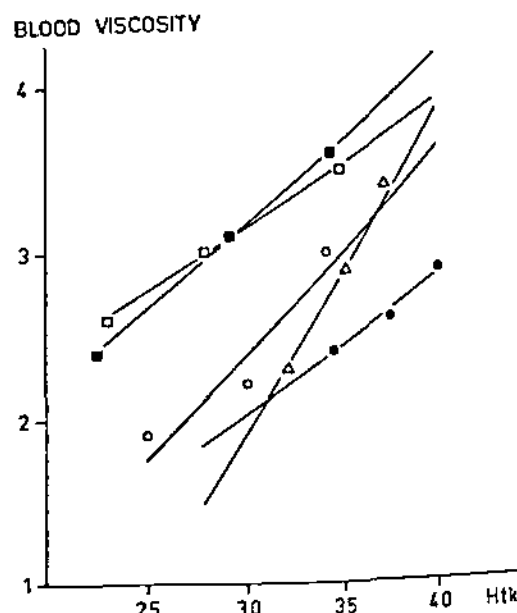


Fig 2 Effect of different contrast media on relative apparent blood viscosity (cps) as a function of hematocrit (hct in per cent) at 160 s^{-1} shear rate (decrease in hematocrit corresponds to an increase in volume ratio) ● Saline 0 9 △ Amipaque 280 ○ Dimer X □ Isopaque Cerebral ■ Urografin 60

also induces less increase in viscosity than the two monomeric ionic contrast media Isopaque Cerebral and Urografin 60% ($p<0\ 001$) There is no significant difference ($p>0\ 1$)

Discussion

All contrast medium solutions markedly increase whole blood viscosity the higher the osmolality of the contrast medium the greater the increase in viscosity

All contrast medium solutions increase plasma viscosity the higher the viscosity of the contrast medium the greater the increase in viscosity

The normal shear thinning property of the blood is reduced or even a shear thickening occurs when contrast media of high osmolality are mixed with blood As the normal shear thinning of blood is the consequence of red cell deformability (CHIEN et coll 1967 b SCHMID SCHONBEIN & WELLS 1973 SCHMID SCHONBEIN et coll 1973 a) this reduced shear thinning is considered to be an effect of a decreased deformability of the single red cell which also contributes to the increase in whole blood viscosity

The effect of the disaggregation that follows the exposure of contrast media to blood in vitro (ASPELIN & SCHMID SCHONBEIN 1978) has not been investigated as the shear rates used (16–160 s^{-1}) are too high The maximum effect of red cell aggregation on blood viscosity occurs at shear rates in the range of 0 1 to 1 0 s^{-1}

The present results point out two important changes of the blood after the exposure to hypertonic contrast medium solutions First there is the increase in whole blood viscosity which might affect the flow of the blood in all vessels Secondly the reduction on shear thinning shows that the red cells become less deformable which may

affect the flow of blood especially through the small vessels the red cells have to be bent and deformed to pass through (BRAASCH 1971 BRÅNEMARK & LINDSTRÖM 1963 a b BROWN et coll 1968 GUEST et coll 1963 MOORE et coll 1970)

The finding that the osmotically shrunken cells (desiccocytes) induced by the ionic contrast media with high osmolality produce more resistance to deformation than the crenated cells (echinocytes) induced by the low osmotic non ionic contrast media is in accordance with previous observations that the reduction in deformability of the red cell increases with increasing osmolality of the test solution (CHIEN et coll 1967 a SCHMID-SCHÖNBEIN et coll 1973 b)

The effect in vivo of these changes observed in vitro on blood viscosity however is as yet unclear According to the Poiseuille Hagen law (flow resistance is inversely proportional to the fourth power of the radius) only a minor increase in radius (dilatation) of the vessel would compensate for the increase in viscosity of the blood Thus this effect of increased viscosity in the large vessels might be relatively easily eliminated in particular as hypertonic contrast media per se have been shown to dilate the peripheral vessels (HILAL, LINDGREN et coll 1968 READ et coll 1960)

However in the capillaries through which the red cells pass in single file and must bend and deform in passage (BRAASCH BRÅNEMARK & LINDSTRÖM 1963 a b BROWN et coll GUEST et coll MOORE et coll) this reduced deformability of the red cell may cause important disturbances of the blood flow This has also been reported by BROWN et coll and MOORE et coll who determined the effect of ionic contrast media on the microcirculation of the small bowel in dogs by high speed cinemicrography They observed that red cells in contact with contrast media became crenated and that these altered red cells were unable to enter the capillaries and the red cell flow in the capillaries almost ceased This may thus be explained by the increase in resistance to deformation of the red cell that has been shown in the present investigation This rigidification of the red cell plus the increase in plasma viscosity caused by the contrast media thus induce a retardation of blood flow which enhances red cell aggregation thereby further contributing to a reduction of blood flow This may be the explanation for previous findings that an increase in red cell aggregation in vivo follows contrast media exposure (BERNSTEIN et coll JOHNSSON & KNISELY 1962 KUTT et coll 1966 LASSER et coll LINDGREN et coll 1964 MARGOLIS et coll 1959 READ 1959) though it has been shown that contrast media per se decrease red cell aggregation (ASPELIN & SCHMID SCHÖNBEIN)

These changes are dependent on the osmolality of the contrast media and with increasing osmolality there would be an increased resistance to flow This has also been shown in the pulmonary circulation by READ et coll (1959 1960) They examined the pressure in the pulmonary artery following the injection of hypertonic solutions into the right side of the heart in dogs They found an increase in pulmonary arterial pressure that increased with increasing osmolality of the injected solutions They also found that the reason for the elevated pressure was an increased resistance to flow through the pulmonary capillaries Furthermore they demonstrated that the

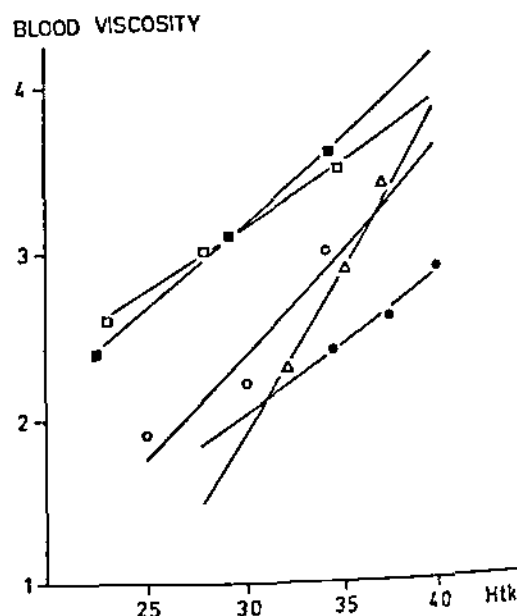


Fig 2 Effect of different contrast media on relative apparent blood viscosity (cps) as a function of hematocrit (hct in per cent) at 160 s⁻ shear rate (decrease in hematocrit corresponds to an increase in volume ratio) ● Saline 0 9 △ Amipaque 280 ○ Dimer X □ Isopaque Cerebral ■ Urografin 60

also induces less increase in viscosity than the two monomeric ionic contrast media Isopaque Cerebral and Urografin 60 % ($p<0\ 001$) There is no significant difference ($p>0\ 1$)

Discussion

All contrast medium solutions markedly increase whole blood viscosity the higher the osmolality of the contrast medium the greater the increase in viscosity

All contrast medium solutions increase plasma viscosity the higher the viscosity of the contrast medium the greater the increase in viscosity

The normal shear thinning property of the blood is reduced or even a shear thickening occurs when contrast media of high osmolality are mixed with blood As the normal shear thinning of blood is the consequence of red cell deformability (CHIEN et coll 1967 b SCHMID SCHÖNBEIN & WELLS 1973 SCHMID SCHONBEIN et coll 1973 a) this reduced shear thinning is considered to be an effect of a decreased deformability of the single red cell which also contributes to the increase in whole blood viscosity

The effect of the disaggregation that follows the exposure of contrast media to blood in vitro (ASPELIN & SCHMID SCHONBEIN 1978) has not been investigated as the shear rates used (16–160 s^{-1}) are too high The maximum effect of red cell aggregation on blood viscosity occurs at shear rates in the range of 0 1 to 1 0 s^{-1}

The present results point out two important changes of the blood after the exposure to hypertonic contrast medium solutions First there is the increase in whole blood viscosity which might affect the flow of the blood in all vessels Secondly the reduction on shear thinning shows that the red cells become less deformable which may

Eigenschaft (abfallende Viskosität mit steigender Visko Elastizität) des Blutes wurde vermindert wenn das Kontrastmittel dem Blut zugefugt wurde Bei einem 50° Volumverhaltnis (Kontrastmittel zu Blut) verwandelten die ionisierten Kontrastmittel das Blut in eine Suspension mit umgekehrter visko-elastischer Eigenschaft (steigende Viskositat mit steigender Visko-Elastizitat) was auf eine ausgesprochene Rigiditätsbildung der einzelnen roten Blutzellen hindeutet wahrend das nicht ionisierte Kontrastmittel weiterhin eine normale visko elastische Eigenschaft zur Folge hat was auf eine geringere Rigiditatsbildung der roten Blutzellen deutet ($p < 0.01$)

RÉSUME

L auteur a etudié l effet des moyens de contraste ioniques diatrizoate iocarmate et métrizoate et du métrizamide non ionique sur la viscosité du sang total la viscosité du plasma et l hématocrite Tous les moyens de contraste augmentent la viscosité du sang total et du plasma et reduisent l hematocrite La viscosite du sang total augmente avec l osmolalite des solutions de moyens de contraste alors que la viscosite du plasma augmente avec la viscosite des solutions de moyens de contraste Plus les moyens de contraste ont une osmolalite elevée plus bas est l hématocrite La propriété normale de visco-élasticité du sang (viscosite decroissante quand le gradient de vitesse augmente) est diminuée quand on ajoute au sang un moyen de contraste Pour un rapport des volumes de 50° (moyen de contraste par rapport au sang) les moyens de contraste transforment le sang en une suspension qui s épaissit (viscosité croissante quand le gradient de vitesse du viscosimetre augmente) indiquant une rigidification importante de chaque globule rouge alors que le moyen de contraste non ionique produit encore une visco-élasticité indiquant une moindre rigidification du globule rouge ($p < 0.01$)

REFERENCES

ALMEN T Contrast agent design J theoret Biol 24 (1969) 216
— and ASPELIN P Cardiovascular effects of ionic monomeric and ionic dimeric and non ionic contrast media Effects in animals on myocardial contractile force pulmonary and aortic blood pressure and aortic endothelium Invest Radiol 10 (1975) 557
— — and LEVIN B Effect of ionic and non ionic contrast media on aortic and pulmonary arterial pressure Invest Radiol 10 (1975) 519
ASPELIN P Effect of ionic and non ionic contrast media on morphology of human erythrocytes Acta radiol Diagnosis 19 (1978) 675
— and ALMEN T Studies on the acute toxicity of ionic and non ionic contrast media following rapid intravenous injection Invest Radiol 11 (1976) 309
— and SCHMID SCHONBEIN H Effect of ionic and non ionic contrast media on red cell aggregation in vitro Acta radiol Diagnosis 19 (1978) 766
BERNSTEIN E EVANS R and SALTZMAN G F Physio-chemical properties of blood following exposure to methylglucamine iodipamide and other contrast media Acta radiol Diagnosis 2 (1964) 401
BRAASCH D Red cell deformability and capillary blood flow Physiol Rev 51 (1971) 679
BRÅNEMARK P I and LINDSTROM J (a) Studies in the function of nutritive capillaries in the connective tissue in rabbits ear chamber J Anat 97 (1963) 323
— — (b) Shape of circulating blood corpus Biorheology 1 (1963) 139
— JACOBSSON B and SORENSEN S E Microvascular effects of topically applied contrast media Acta radiol Diagnosis 8 (1969) 547

BROMAN T and OLSSON O Experimental study of contrast media for cerebral angiography with reference to possible injurious effects on the cerebral blood vessels Acta radiol 31 (1949) 321

BROWN R YOUMANS R LIVANEC G DERRICK J BOND T and GUEST M Cinemicrographic observations of the effects of contrast media on the microcirculation Vasc Surg 2 (1968) 109

CHAPLIN H and CARLSSON E Changes in human red blood cells during in vitro exposure to several roentgenologic contrast media Amer J Roentgenol 86 (1961) 1127

CHIEN S ... dependence of effective cell volume as a determinant of blood viscosity Science ... 1970) 977

— Present ... e of blood rheology *In* Hemodilution p 1 Karger Press Basel 1971

— USAMI ... DELLENBACK R and GREGERSSEN M (a) Blood viscosity Influence of ery thro... deformation Science 157 (1967) 827

— — — — (b) Blood viscosity Influence of red cell aggregation Science 157 (1967) 829

FUNG Y C Theoretical considerations of the elasticity of red cells and small blood vessels Fed Proc 24 (1966) 1761

GOLDSMITH H and MASON S Some model experiments in haemodynamics II Bibl anat 7 (1965) 353

GUEST M BOND T COOPER R and DERRICK J Red blood cell Changing in shape in capillaries Science 142 (1963) 1319

HILAL S Trends in preparation of new angiographic contrast media with special emphasis on polymeric derivates Invest Radiol 5 (1970) 458

HOLTERMANN H Metrizamide Introduction Acta radiol (1973) Suppl No 335 p 1

JOHNSSON J and KNISELY M Intravascular agglutination of the flowing blood following the injection of radiopaque contrast media Neurology (Minneap) 12 (1962) 560

KUTT H VEREBELY K BANG N STREULI F and McDOWELL F Possible mechanisms of complications of angiography Acta radiol Diagnosis 5 (1966) 276

LASSER E FARR R FUJIMAGARI T and TRIPP W The significance of proteinbinding of contrast media in roentgen diagnosis Amer J Roentgenol 87 (1962) 338

LINDGREN P LOFSTROM B and SALTZMAN G F Intravascular erythrocyte aggregation after intravenous injection of contrast media Acta radiol Diagnosis 2 (1964) 334

— SALTZMAN G F and TORNELL G Vascular reaction to water-soluble contrast media Acta radiol Diagnosis 7 (1968) 152.

MARGOLIS G GRIFFIN A T KENAN P D TINALL G T RIGGINS R and FORT L Contrast medium injury to the spinal cord The role of altered circulatory dynamics J Neurosurg 16 (1959) 390

MEISELMAN H J MERRIL E W GILLILAND E R PELLETIER G A and SALTMAN E W Influence on plasma osmolarity on rheology of human blood J appl Physiol 22 (1967) 772

MOORE C BROWN R T and DERRICK J Experimental effects of selective arteriography on the microcirculation Rev Surg 27 (1970) 379

RAND P and LACOMBE E Hemodilutation tonicity and blood viscosity J clin Invest 43 (1964) 2214

— — Effects of angiocardiographic injections on blood viscosity Radiology 85 (1965) 1022.

READ R Cause of death in angiocardiography J thorac cardiovasc Surg 38 (1959) 685

— VICK J and MEYER M Influence of perfusate characteristics on the pulmonary vascular effects of hypertonic solutions Fed Proc 18 (1959) 124

— — — Influence of plasma hyperosmolality in blood viscosity Fed Proc 21 (1962) 104

— JOHNSON J VICK J and MEYER M Vascular effects of hypertonic solutions Circulat Res 8 (1960) 538

SALVESEN S Acute toxicity test of metrizamide Acta radiol (1973) Suppl No 335 p 5

SCHIANTARELLI P PERONI F TIRONE P and ROSATI G Effects of iodinated contrast media on erythrocytes I Effects of canine erythrocytes on morphology Invest Radiol 8 (1973) 199

SCHMID-SCHONBEIN H and WELLS R (a) Quantification of the dynamics of red cell aggregation Bibl anat 10 (1969) 45

— — (b) Rheological consequences of osmotic red cell crenation Pflügers Arch 307 (1969) 59

— — Rheological properties of human erythrocytes and their influence upon the anomalous viscosity of blood Ergebn Physiol 63 (1973) 146

— GAETTGENS P and HIRSCH H On the shear rate dependence of red cell aggregation in vitro J clin Invest 47 (1968) 1447

— WELLS R and GOLDSTONE J (a) Influence of deformability of human red cells upon blood viscosity Circulat Res 25 (1969) 131

— — and SCHILDKRAUT R (b) Microscopy and viscometry of blood flowing under uniform shear rate (rheoscopy) J appl Physiol 26 (1969) 674

— WEISS J and LUDWIG H (a) Simple method for measuring red cell deformability in models of the microcirculation Blut 24 (1973) 369

— — — (b) Effect of ultrafiltration and plasma osmolarity upon the flow properties of blood A possible mechanism for control of blood flow in the renal medullary vasa recta Pflugers Arch 338 (1973) 93

— GOSEN J HEINRICH L KLOSE H and VOGLER E (c) A counter rotating rheoscope chamber for the study of the microrheology of blood cell aggregation by microscopic observation and microphotometry Microvasc Res 6 (1973) 366

SVOBODA M und FIALA J Morphologische Veranderungen der roten Blutkorperchen nach verschiedenen wasserloslichen jodhaltigen Rontgenkontrastmitteln Radiologe 4 (1964) 404

WELLS R and MERRIL E Influence of flow properties of blood upon viscosity hematocrit relationships J clin Invest 41 (1962) 8

— and SCHMID-SCHÖNBEIN H Red cell deformation and fluidity of concentrated cell suspensions J appl Physiol 27 (1969) 213

— MERRIL E W GABELNICK H DRAPER C S DILLINSON P and DAUWATER C J Shear rate dependence of viscosity of blood Interaction of red cell and plasma proteins Trans Soc Rheol 6 (1962) 19

FROM THE DEPARTMENTS OF ORTHOPEDIC SURGERY DIAGNOSTIC RADIOLOGY AND MEDICAL PHYSICS HUDDINGE SJUKHUS S 141 86 HUDDINGE SWEDEN

ESTIMATION OF VERTEBRAL ROTATION IN STRUCTURAL SCOLIOSIS BY COMPUTER TOMOGRAPHY

S Aaro M Dahlborn and L Svensson

Structural scoliosis is a lateral curvature of the spine associated with rotation of the vertebral body towards the convexity of the curve The determination of the degree of rotation is of importance when the effect of different types of treatment of scoliosis are evaluated The commonly used methods are considered to be either inaccurate or time consuming (Nash & Moe 1969 Hindmarsh 1973) Therefore an attempt was made to use computer tomography for evaluating the derotational effect of conservative and surgical treatment

The general purpose Delta Scan 50 FS system (Ohio Nuclear) was used nominal exposure time 18 seconds scan diameter 420 mm The operating factors are normally 140 kV at 35 mA but in order to minimize the absorbed dose in the patient a tube current of only 20 mA was used A trial with a tissue equivalent whole body phantom indicated that this reduction could be accomplished without any loss of diagnostic information Absorbed dose measurements were performed with disc shaped lithium fluoride thermoluminescent dosemeters (diameter 13 mm thickness 0 4 mm) placed on the surface and in cavities of the phantom The measurements were performed during exposure of one slice of the phantom in the same position as in the clinical scanning (Fig 1) Measurements were also performed on the posterior and anterior surface of 3 patients The dosemeters were calibrated against an ionization chamber standard in a known radiation field with the same radiation quality as that of the CT scanner The slice thickness used had a nominal value of 13 mm

Submitted for publication 3 June 1978

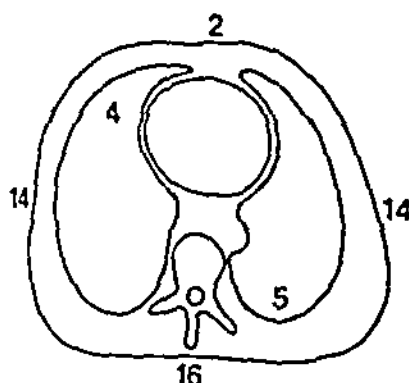


Fig 1 Transverse section of the thorax Figures indicate absorbed doses (mGy) of the body phantom

CT was performed on 5 patients with varying degrees of scoliosis at different sites The vertex vertebra of the scoliosis was determined at radiography and identified on the back of the patients by counting the ribs and the vertebral processes The transverse level of the vertebra was marked at the anterior midline of the patient A rubber tube was placed between the jugular fossa and xiphoid process or the umbilicus and indicated on the computer display (Fig 2) Only one CT scan of the vertex vertebra was taken on each patient in supine position The vertebral rotation from the anatomic midline in the transverse plane was defined as the angle between one straight line from the electronic mark on the anterior midline to the dorsal central aspect of the vertebral foramen and one through the midline of the vertebral body and vertebral foramen (Fig 2) Each one of ten trained radiologists was given two films of the five patients one polaroid film (7 5 cm 9 5 cm) and one enlarged paper copy (18 cm × 24 cm) of a black and white negative film (24 mm 36 mm) of the computer display unit The radiologists were asked to draw the two lines and estimate the angle of vertebral rotation on the two films

Statistical treatment of the material by three way analysis of variance revealed no significant difference between the estimates The deviation between the estimated angles was generally small and seemed to be somewhat smaller on the 18 cm × 24 cm films than in the 7 5 cm × 9 5 cm films (SD 1 55 and 2 28 respectively) but the differences are not statistically significant

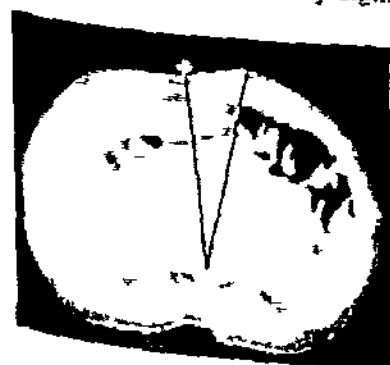


Fig 2 Determination of vertebral rotation CT of a patient with scoliosis at the level of the vertex vertebra One line drawn from the anterior midline to the dorsal central aspect of the vertebral foramen and the other through the middle of the vertebral body and vertebral foramen

The CT technique implies a possibility to estimate the vertebral rotation in the transverse plane in an easy way By reducing the tube current the absorbed dose of the patient can be kept within an acceptable range and still give a scan with information enough to perform a proper estimation of the rotation However it is important to indicate the apex vertebra carefully before the examination to avoid scans of wrong level interior midline of the thorax could sometimes be difficult to identify on and therefore a rubber tube was used as an indication The difference timations of the vertebral rotation between the radiologists were sm argement technique facilitated the evaluation It appears that vertebr l patients with structural scoliosis can be recorded in a simple way and l n angles be reliably reproduced with the aid of computer tomogra

SUMMARY

Compu hy for the determination of the degree of vertebral rotation in patients with su is is presented and discussed

ZUSAMMENFASSUNG

Die Anwendung der Computertomographie zur Bestimmung des Grades der Wirbelrotation bei Patienten mit struktureller Skoliose wird hervorgehoben und diskutiert

RESUME

Les auteurs presentent et étudient l utilisation de la tomodensitometrie pour la détermination du degre de rotation vertébrale chez les malades ayant une scoliose structural

REFERENCES

BENSON D R SCHULTZ A B and DEWALD R L Roentgenographic evaluation of vertebral rotation J Bone Jt Surg 58 A (1976) 1125

HINDMARSH J Roentgen stereophotogrammetry for evaluating the effect of scoliosis treatment Thesis Stockholm 1973

NASH C L and MOE J H A study of vertebral rotation J Bone Jt Surg 51 A (1969) 223

FROM THE DEPARTMENTS OF DIAGNOSTIC RADIOLOGY AND OTORHINOLARYNGOLOGY
KAROLINSKA SJUKHUSET S 104 01 STOCKHOLM SWEDEN

FACIAL BONE SCINTIGRAPHY

II Diagnostic potential in neoplastic and inflammatory lesions

H F BERGSTEDT and M G LIND

Neoplastic and inflammatory lesions of bone often cause an abnormal accumulation of technetium diphosphonate ($^{99}Tc^{m}$ DP) and bone scintigraphy is of clinical interest because it offers evaluation parameters principally different from radiography Metastasis to the skeleton is often demonstrated at an earlier stage of the disease by scintigraphy than by conventional radiography (SILBERSTEIN et coll 1973 PAPADIMITRIOU et coll 1974 THRALL et coll 1974 BELLIVEAU & SPENCER 1975 OSMOND et coll 1975 BERGSTEDT & HAVERLING 1978) Hypothetically the combination of results from scintigraphy and radiography should make the diagnosis of the type and the extension of pathologic processes more accurate and hence facilitate to choose the best treatment. Pathologic processes in the facial region are located close to bone and thus by bone scintigraphy not only the presence of skeletal metastases but also the involvment of bone by primary inflammatory and neoplastic soft tissue processes can be examined

Material and Methods

From a material of about 200 facial bone scintigrams 32 patients were selected to demonstrate the scintigraphic images of different inflammatory and neoplastic lesions of the face The patients were grouped A to G In each patient the diagnosis was based on careful clinical examination and radiography The mucous cyst, the

Submitted for publication 6 May 1977

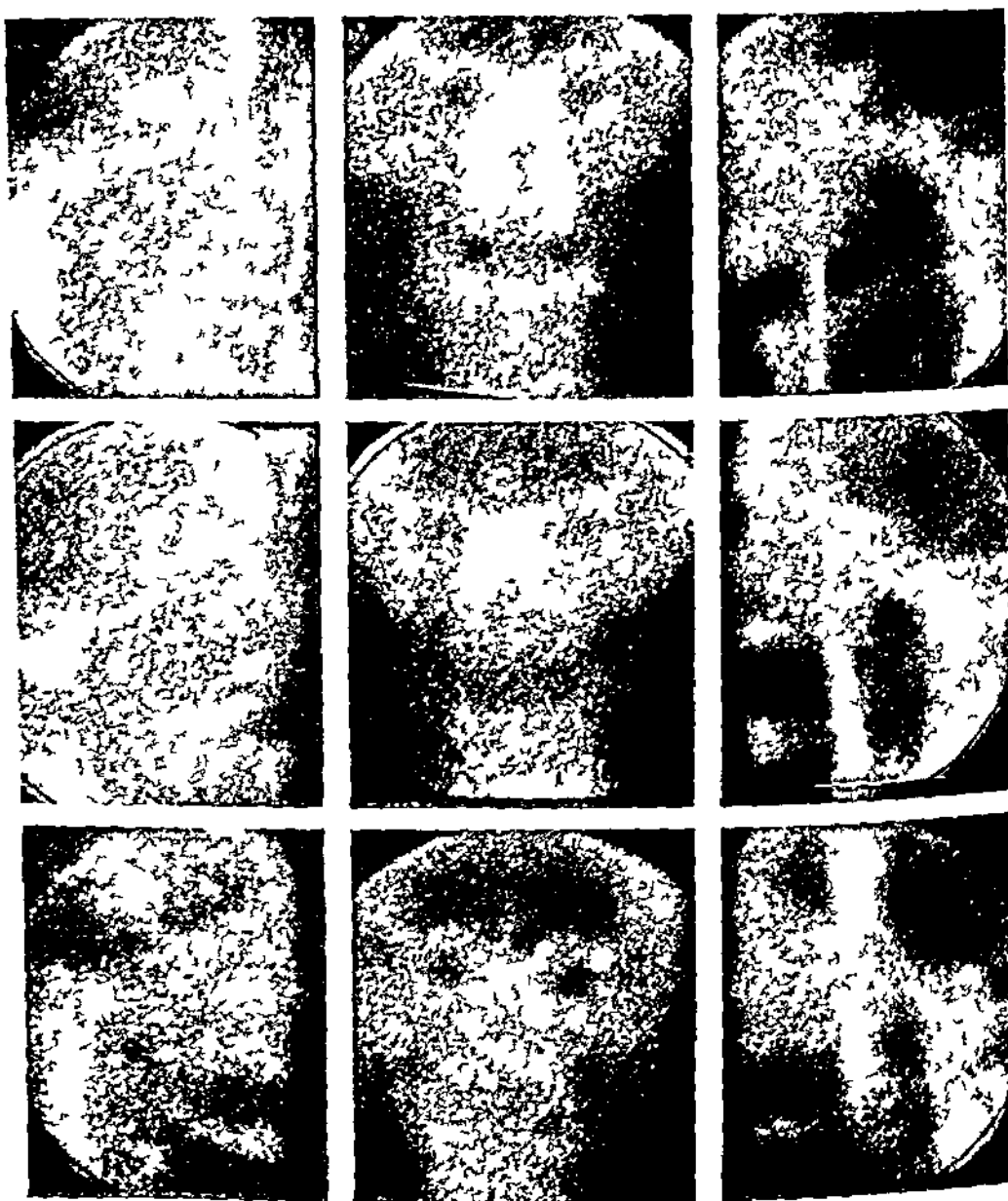


Fig. 1 Varying *normal* facial skeleton uptake of $^{99}Tc^m$ diphosphonate with regional bone mass In each row from left to right *right lateral* a p and left lateral projections of each patient

inflammations of the sinuses and all tumours were confirmed by surgery and microscopy

Five hours after intravenous injection of 370 MBq (10 mCi) of $^{99}Tc^m$ DP the distribution of activity was recorded by a gamma camera (Nuclear Chicago Pho Gamma IV) A converging collimator was used and 300 000 counts were collected in each projection The head was examined in an a p projection as well as in left and right




Fig 2 Case 1 Mucous cyst of left maxillary sinus normal distribution of activity Case 2 Sinuitis of frontal ethmoid and maxillary sinuses at conventional radiography clinical history of one week s duration Slight facial accumulation of activity in the region of the frontal sinuses otherwise normal distribution

lateral projections The inhomogeneity of the gamma camera field was checked at weekly intervals The chemical impurity of the tracer was not allowed to exceed 5 per cent with daily controls Radiography and scintigraphy were performed within a few days in all patients

Group A Reference Eight patients with mammary carcinoma at an early stage were submitted for routine whole body bone scintigraphy No metastatic lesions were demonstrated in the axial skeleton at radiography The presence of bone metastases in the head region was therefore regarded as unlikely warranting the use of this group of patients as a reference of normal distribution of $^{99}Tc^{m}$ DP (Fig 1)

Group B Cases 1 to 5 (Figs 2 3) One patient had a non infected mucous cyst and 4 had inflammatory lesions of the sinuses At conventional radiography of all lesions air was substituted by soft tissue in the involved cavity without evidence of bone reaction The inflammatory lesions ranged from one week to several years of duration

Group C Cases 6 to 9 (Fig 4) This group consisted of patients with tumours of the ethmoid region one had a papilloma durum and 3 carcinoma At conventional




Fig 3 Chronic sinuitis Case 3 Left maxillary sinuitis since 6 months Case 4 Frontal sinuitis since several years Case 5 Frontal ethmoid and sphenoid sinuitis since several years Intense focal accumulation of tracer to the involved regions

radiography all lesions had soft tissue masses filling the ethmoidal cells without demonstrable bone invasion

Group D Cases 10 to 15 (Figs 5 6) This group included patients with carcinoma of the gingiva with or without clinical suggestion of bone involvement Cases 10 to 13 had osteolytic foci demonstrated at conventional radiography cases 14 and 15 had no evidence of bone involvement The scintigraphy in case 10 was carried out 3 weeks after irradiation with a total dose of 40 Gy (4 000 rad) The first scintigraphy in case 15 (Fig 6) was done before and repeat scintigraphy after irradiation during

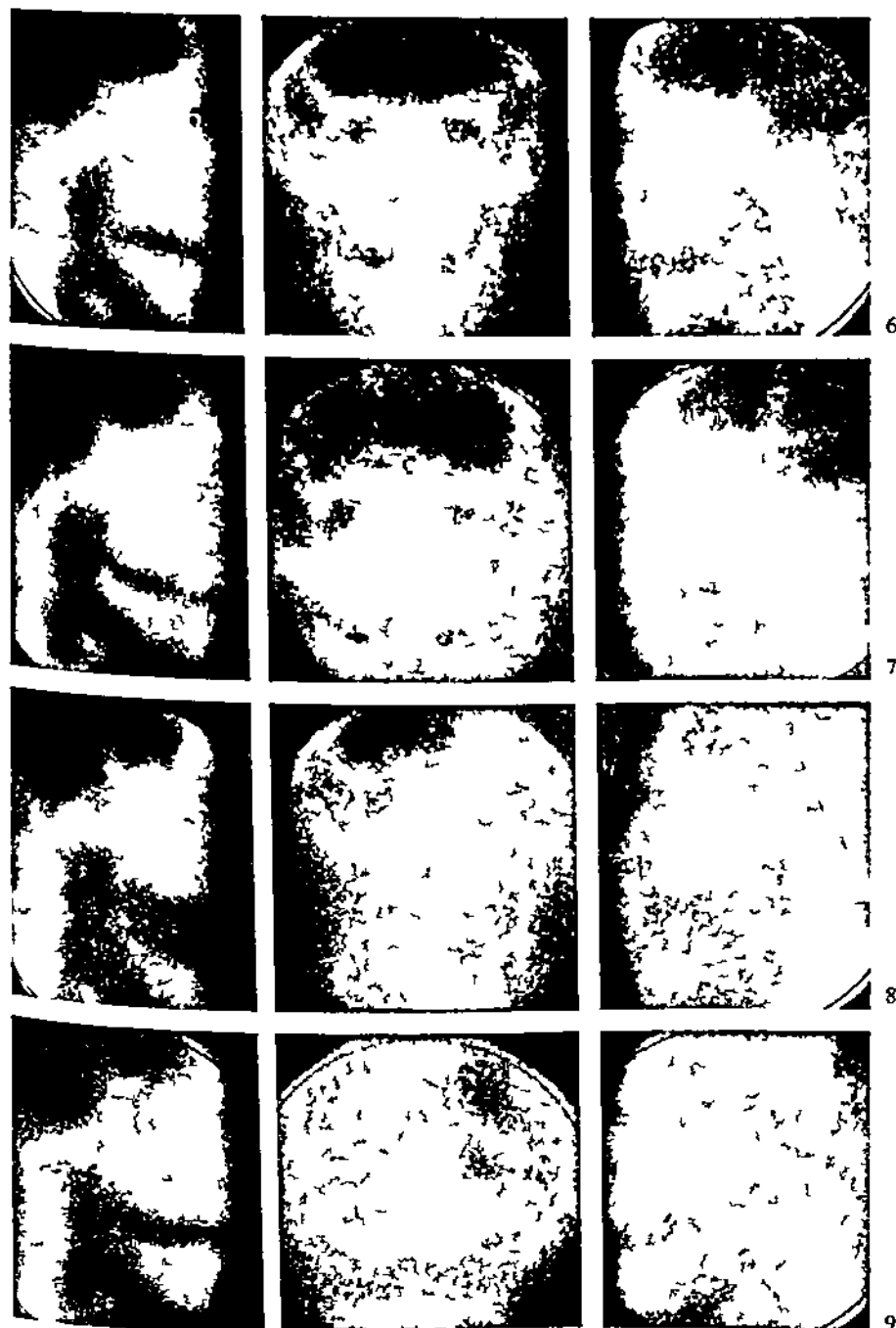


Fig. 4 Papilloma durum and carcinoma of the ethmoid region Case 6 Papilloma durum of left ethmoid region Case 7 Carcinoma of left ethmoid region Case 8 Carcinoma of right ethmoid region Case 9 Carcinoma of left ethmoid region Moderately intense focal accumulation of activity to the involved regions

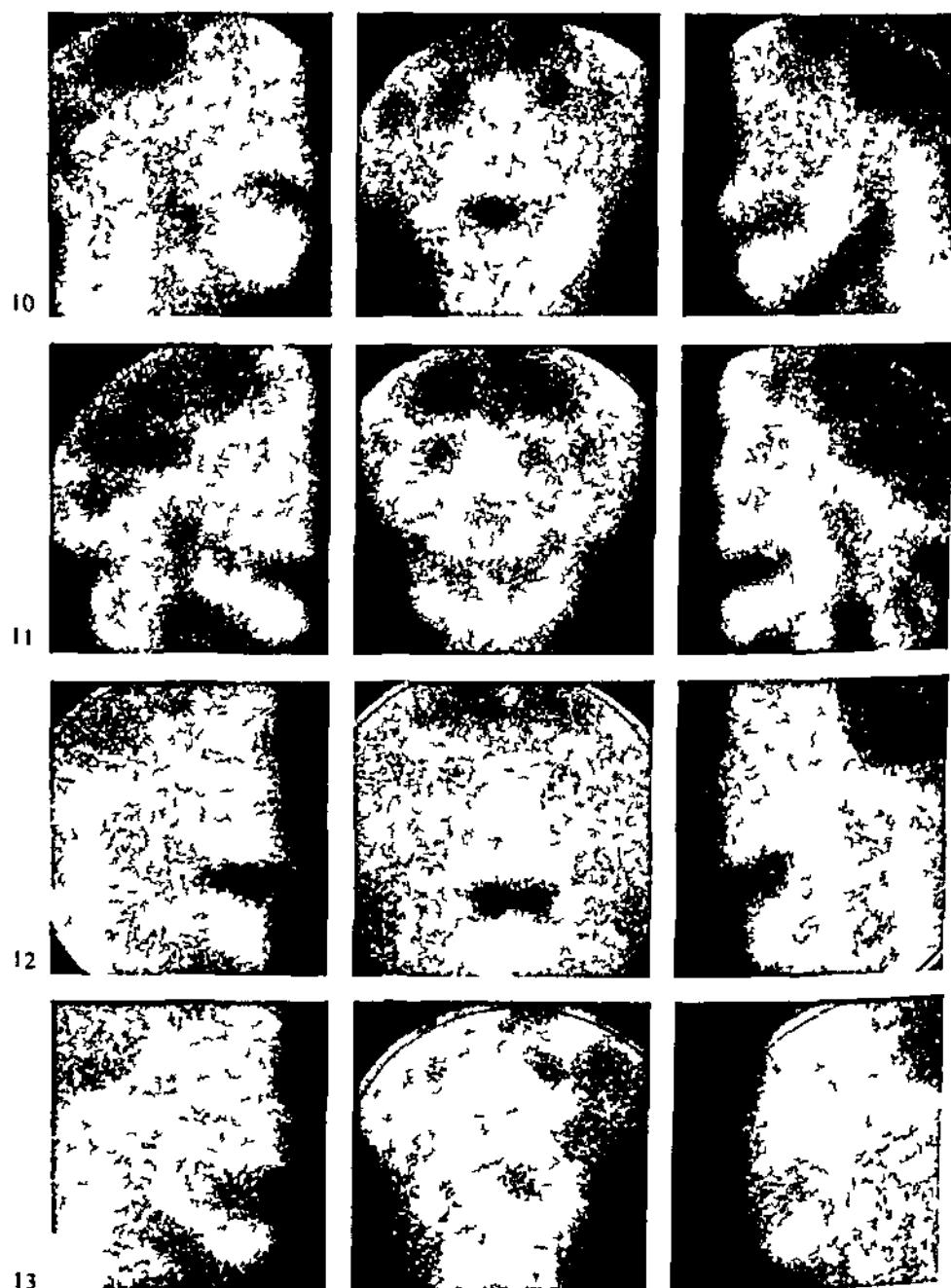


Fig 5 Gingival carcinoma engaging the bone tissue Case 10 Carcinoma of left mandibular gingiva Case 11 Carcinoma of frontal mandibular gingiva Case 12 Carcinoma of frontal mandibular gingiva Case 13 Carcinoma of left mandibular gingiva All these lesions were associated with radiographic bone destructive lesions corresponding to the regions of focal uptake of tracer (case 12 also had a severe maxillary parodontitis)

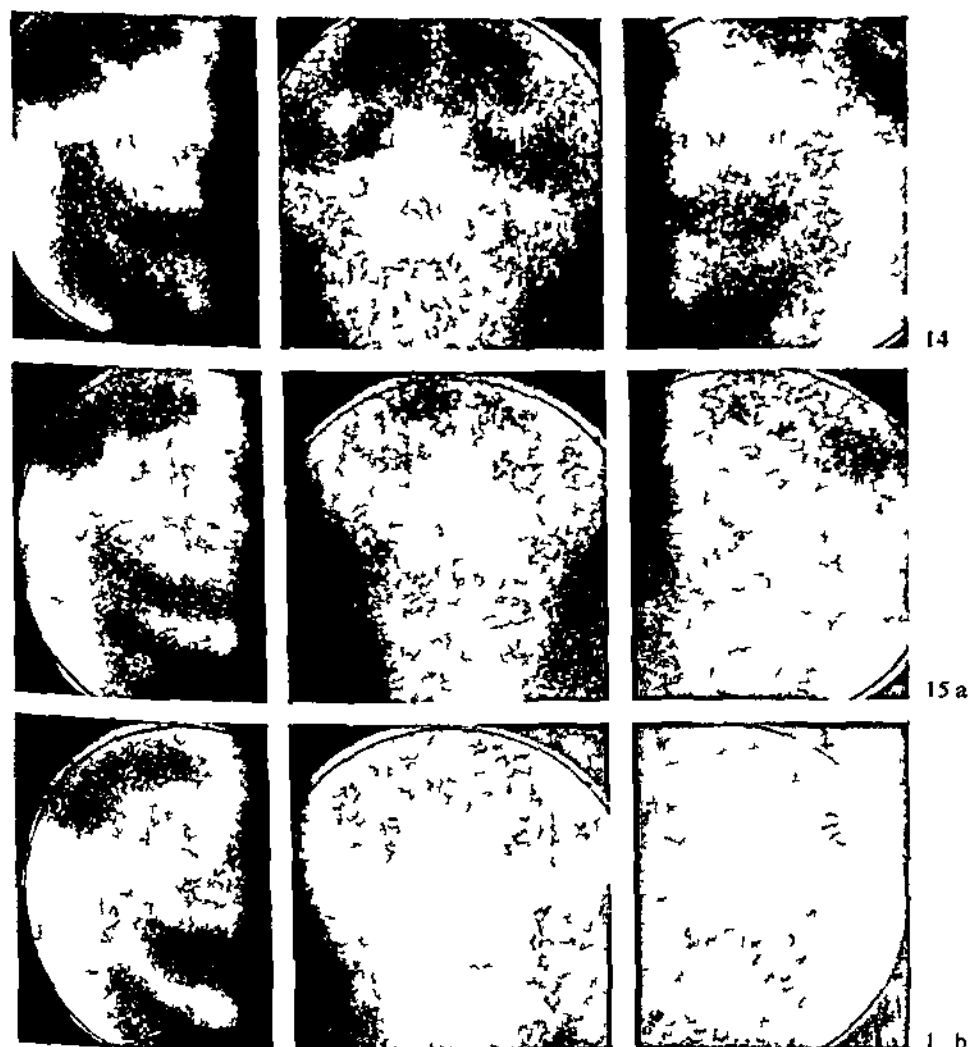


Fig 6 Case 14 Carcinoma of right maxillary gingi a No evidence of bone destruction at conventional radiography Case 15 Progressive involvement of the mandible by a buccal carcinoma a) Without and b) with definite clinical engagement of mandibular gingiva after radiation treatment No evidence of bone destruction at conventional radiography Slight focal uptake of tracer in case 14 and in case 15 (b)

this time the carcinoma originally confined to the bucca had involved the gingiva over the entire anterior part of the mandible

Group E Cases 16 to 18 (Fig 7) had tumours of the jaws with the radiographic appearance of a cyst In case 18 the margins of the lesion were indistinct

Group F Cases 19 and 20 (Fig 8) This group represents inflammatory affections of the jaws Case 19 had necrosis and osteomyelitis of the left mandible after radiation therapy several years previously because of a gingival carcinoma No tumour




Fig 7 Tumours of the jaws with intense focal accumulation of tracer Case 16 Ameloblastoma of left lateral mandible Case 17 Dental cyst of right mandible Case 18 Eosinophilic granuloma in right mandibular angle

was found in specimens taken at the time of scintigraphy Case 20 had chronic osteomyelitis of the mandible since several years with microscopic indication also of the possible presence of fibrous dysplasia At radiography both osteolytic and osteosclerotic regions were demonstrated

Group G Cases 21 to 24 (Fig 9) The conventional radiographic findings in these patients with dental inflammatory affections ranged from normal (case 24) over marginal resorption of the alveolar bone (case 21) to periapical osteolytic foci (case 22) with additional osteosclerosis (case 23)

Results

The distribution of the tracer in the facial skeleton was easily recorded with comparatively distinct imaging of anatomic details




Fig 8 Generalized osteomyelitis of the mandible with intense scintigraphic foci Case 19 Bone necrosis and osteomyelitis several years after radiation treatment of a gingival carcinoma without evidence of tumour recurrance Case 20 Chronic osteomyelitis and fibrous dysplasia

In the patients of group A with presumably normal facial skeleton no difference existed between the right and the left sides of the face and no local uptake of tracer not referable to normal anatomy was found The intensity of the tracer uptake as evaluated by the gamma camera was closely correlated to the regional amount of bone tissue Thus the uptake was high in the supra and infraorbital margins in the zygomatic bone and also in the sphenoid region (Fig 1)

In group B the non infected cyst of one maxillary sinus (case 1) was associated with a normal distribution of $^{99}Tc^{m}$ DP The acute sinuitis of one week s duration (case 2) had only a suggested focal increase of activity in the glabella region (Fig 2) but the chronic sinuitis of cases 3 4 and 5 caused evident abnormal focal uptake of high intensity (Fig 3)

In group C all patients had an abnormal uptake of tracer to the region involved (Fig 4)

In group D cases 10 to 13 (Fig 5) and 14 (Fig 6) with carcinoma of the gingiva probably engaging the underlying bone of the alveolar process in every case but without radiologic evidence of bone involvement in case 14 all had a focal abnormal uptake (Fig 5) No evidence of abnormal uptake was found at scintigraphy before the radiation therapy of case 15 and before spread of the buccal carcinoma Later the carcinoma invaded the gingiva of the anterior part of the mandible the scintigraphy



Fig 9 Dental inflammatory affections with moderate to intense accumulation of tracer Case 21 Parodontitis with marginal bone reduction at radiography Case 22 Periapical osteolytic lesion of right upper canine Case 23 Endodontic treatment of right lower third molar with periapical osteolysis and sclerosis Case 24 Reaction after extraction of impacted right lower third molar without radiologic evidence of further bone involvement

then demonstrated an increased uptake in the affected region (Fig 6) repeat radiography failed to reveal any bone lesion

In group E case 16 with an ameloblastoma of the mandible had an intense uptake in the area affected while case 17 with an apparently not infected dental cyst of the mandible and case 18 with an eosinophilic granuloma also had focal intense uptake though not as evident as in case 16 (Fig. 7)

In group F cases 19 and 20 with osteomyelitis of the mandible both had an intense accumulation of tracer to the affected region (Fig 8)

In group G finally, inflammatory reactions of the marginal alveolar bone caused abnormal uptake (case 21) Reaction to periapical inflammation endodontic treatment and tooth extraction in cases 22 23 and 24 respectively caused a local accumulation of tracer (Fig 9)

Discussion

The facial skeleton is characterized by its complex anatomy and close relation to the mucous membranes of the oral and nasal cavities Inflammatory and neoplastic diseases in the oral and nasal regions generally originate in these membranes and thus often affect the periosteum or bone tissue The choice of treatment as well as the assessment of the prognosis are dependent on the presence of bone engagement Surgery for a malignant tumour is planned to be more radical if bone involvement is probable similarly chemotherapy against infectiou diseases is dependent on the probability of bone engagement Examination of the facial skeleton by bone scintigraphy is therefore of great potential interest in the diagnostic assessment of both the type and the extent of pathology in the oral and nasal regions (BERGSTEDT 1975)

Inflammatory and neoplastic affections of bone may be demonstrated by abnormal uptake of $^{99}Tc^m$ DP Bone scintigraphy is assumed to be more sensitive in demonstrating and localizing skeletal metastatic lesions than is radiography However an abnormal local uptake of a bone seeking nuclide may occur in several pathologic processes such as neoplasia trauma infection rheumatic reactions etc (TILDEN et coll 1973 DESAULNIERS et coll 1974 GENANT et coll 1974 THRALL et coll KAYE et coll 1975 LETTS et coll 1975 ROSENTHALL & KAYE 1975 GARCIA et coll 1976) Thus an abnormal uptake at bone scintigraphy does not prove malignant growth A careful analysis of all possible causes of abnormal uptake in the skeleton constitutes the necessary basis for a rational valuation of bone scintigraphy

The facial bone accumulation of $^{99}Tc^m$ DP is of clinical interest only if assessible as normal or abnormal Therefore the distribution of the tracer in the facial skeleton and its normal variation must be known The results from the present series of patients indicate that the normal variation in facial bone scintigraphy is small compared to variations due to pathologic processes engaging the bone

It is of practical importance that parodontitis and other dental inflammatory lesions cause increased uptake in the alveolar bone The majority of patients examined because of neoplastic processes belong to the age group in which dental disorders are common Therefore facial bone scintigraphy should never be undertaken without knowledge of the dental condition of the patient in order to prevent erroneous evaluation of the scintigraphy (ALEXANDER 1976 GATES & GORIS 1976 LURIE & MATTESON 1976)

Case 1 had a pathologic maxillary sinus at radiography but the facial scintigraphy was normal Operation revealed a mucous cyst filling the sinus without inflammatory reactions The sinuses of case 2 with acute sinuitis were also close to normal at scinti

graphy On the other hand chronic sinuitis caused abnormal focal uptake of ^{99}Tc^m DP These findings indicate that an abnormal uptake is a sign of involvement of the periosteum or bone by the inflammatory process

Facial bone scintigraphy might thus distinguish patients with paranasal sinus lesions enganging bone from those without engagement of bone (GATES & GORIS BERGSTEDT & LIND 1977)

Cases 6 to 9 illustrate that periosteal or bone tissue involvement by carcinoma of the ethmoid region is demonstrable by facial bone scintigraphy If clinical and radiographic examinations are supplemented with facial bone scintigraphy the extension of pathologic lesions is probably demonstrated with a higher degree of accuracy than by any single method However minor neoplastic bone invasion may remain undetected by scintigraphy in particular if masked by an abnormally high ^{99}Tc^m DP uptake caused by inflammatory or traumatic bone reaction

The choice of treatment and the type of surgical intervention in patients with carcinoma of the oral cavity is dependent among other things upon possible involvement of the periosteum or bone (MASHBERG et coll 1969 VERA et coll 1971 GATES & GORIS) Cases 10 to 15 illustrate the value of facial bone scintigraphy in such cases It is possible that bone scintigraphy has a higher diagnostic potential than radiography in distinguishing patients with periosteum or bone engagement from those without (cases 14 15) The repeated scintigraphies of case 15 illustrate the possibility to follow the course of a progressive malignant tumour (Fig 6)

Data reported (COX 1974 GATES & GORIS LIND & NATHANSON 1977) indicate that radiation therapy does not cause an abnormal uptake of ^{99}Tc^m DP in bone which is important for evaluating cases with osteomyelitis secondary to bone necrosis induced by irradiation as in case 19 In case 20 the osteomyelitis was possibly associated with fibrous dysplasia and a high uptake was found Bone scintigraphy in such cases should be of potential value to recognize osteomyelitic reactions and to evaluate the effect of treatment which should not influence the component of fibrous dysplasia Lesions of odontogenic origin such as ameloblastoma and cysts (cases 16–18) as well as dental inflammatory lesions (cases 21–24) cause bone reactions possible to detect at facial bone scintigraphy (GATES & GORIS LURIE & MATTESON)

At conventional radiography the attenuation and structure of the bone are assessed and at scintigraphy the metabolic activity of the bone The extension of the region with increased uptake may be larger than that of the corresponding region with structural changes at radiography Presumingly a zone of increased metabolic activity surrounds tumours and inflammatory lesions causing alterations of the bone not possible to demonstrate by radiography (SILBERSTEIN et coll PAPADIMITRIOU et coll THRALL et coll BELLIVEAU & SPENCER OSMOND et coll BERGSTEDT & HAVERLING)

The method is limited by factors such as the poor spatial resolution and the inhomogeneity of the viewing field (TODD POKROPEK et coll 1976) Furthermore the normal scintigraphic image varies slightly due to differences in bone mass and bone

metabolism The scintigraphic bone image of elderly patients seems to become less distinct and in some individuals the difference between bone and soft tissue is reduced possibly because the metabolic activity of the bone diminishes with age (THRALL et coll Fig 1) Many pathologic entities cause local abnormalities in the facial bone scintigraphic images and it is therefore necessary to combine scintigraphy with radiography and clinical examination for adequate evaluation

SUMMARY

From a series of about 200 facial bone scintigraphies 32 patients were selected to demonstrate the uptake of $^{99}Tc^{m}$-diphosphonate in various inflammatory and neoplastic diseases in the sinuses and oral cavity The method was found of value in separating patients with inflammatory involvement of the bone from those without as well as in assessing possible bone involvement in malignant lesions

ZUSAMMENFASSUNG

Von etwa 200 Gesichtsknochen Szintigraphien wurden 32 Patienten ausgesucht um die Aufnahme von $^{99}Tc^{m}$ Diphosphonat bei verschiedenen inflammatorischen und neoplastischen Erkrankungen in den Sinus und der Mundhohle zu untersuchen Die Methode wurde als brauchbar befunden um Patienten mit inflammatorischer Beteiligung des Knochens von solchen ohne Beteiligung zu unterscheiden sowie eine mogliche Knochenbeteiligung bei malignen Veranderungen festzustellen

RESUMÉ

Sur une serie d environ 200 scintigraphies osseuses faciales 32 malades ont ete selectionnes pour mettre en evidence la fixation du $^{99}Tc^{m}$ diphosphonate dans differentes affections inflammatoires et neoplasiques des sinus et de la cavite buccale Cette methode s est montrée utile pour separer les malades ayant une atteinte inflammatoire de l os de ceux qui n ont pas d atteinte osseuse ainsi que pour determiner l atteinte osseuse possible dans les lesions malignes

REFERENCES

ALEXANDER J M Radionuclide bone scanning in the diagnosis of lesions of the maxillofacial region J Oral Surg 34 (1976) 249

BELLIVEAU R E and SPENCER R P Incidence and sites of bone lesions detected by ^{99m}Tc polyphosphate scans in patients with tumors Cancer 36 (1975) 359

BERGSTEDT H F Bone scintigraphy of facial skeleton with $^{99}Tc^{m}$-diphosphonate Acta radiol Diagnosis 16 (1975) 337

— and HAVERLING M Facial bone scintigraphy I Metastatic lesions in the mandible Acta radiol Diagnosis 19 (1978) 859

— och LIND M G Ansiktsskelettskintigrafi (In Swedish) Svensk Otolaryngologisk forenings handlingar I (1977) 20

COX P H Abnormalities in skeletal uptake of $^{99}Tc^{m}$ polyphosphate complexes in areas of bone associated with tissues which have been subjected to radiation therapy Brit J Radiol 47 (1974) 851

DESAULNIERS M FUKS A HAWKINS D LACOURCIERE Y and ROSENTHALL L Radio technetium polyphosphate joint imaging J nucl Med 15 (1974) 417
GARCIA D A TOW D E KAPUR K K and WELLS H Relative accretion of ^{99m}Tc polyphosphate by forming and resorbing bone systems in rats Its significance in the pathologic basis of bone scanning J nucl Med 17 (1976) 93
GATES G F and GOL M L Maxillary facial abnormalities assessed by bone imaging Radiology 121 ( ) 677
GENANT H K B OVICH G J SINGH M LATHROP K A and HARPER P V Bone seeking rad lides An in vivo study of factors affecting skeletal uptake Radiology 113 (1974)
KAYE M S ERTON S and ROSENTHALL L Technetium 99m pyrophosphate Studies in vivo an in vitro J nucl Med 16 (1975) 40
LETTS R M AFIFI A and SUTHERLAND J B Technetium bone scanning as an aid in the diagnosis of atypical acute osteomyelitis in children Surg Gynec Obstet 140 (1975) 899
LIND M G and NATHANSON A ^{99}Tc^{m} DP accumulation in rabbit skull bones after ^{60}Co gamma irradiation Acta radiol Ther Phys Biol 16 (1977) 489
LURIE A G and MATTESON S R ^{99m}Tc diphosphonate bone imaging and uptake in healing rat extraction sockets J nucl Med 17 (1976) 688
MASHBERG A STRAUSS H SMALL M J and MILLER W N Use of scintillation scanning for the early detection of bone involvement by squamous cell carcinoma of the oral mucosa Preliminary report J Amer dent Ass 79 (1969) 1151
OSMOND J D PENDERGRASS H P and POTSAID M S Accuracy of ^{99m}Tc diphosphonate bone scans and roentgenograms in the detection of prostate brea t and lung carcinoma metastases Am r J Roentgenol 125 (1975) 972
PAPADIMITRIOU J VEZERIDIS M CONSTANTINIDIS M CHIOTELIS E CONSTANDINIDIS C and TOUNTAS C The value of Tc^{99m} diphosphonate (HEDSPA) as a skeletal scanning agent Amer J Roentgenol 121 (1974) 735
ROSENTHALL L and KAYE M Technetium 99m pyrophosphate kinetics and imaging in metabolic bone disease J nucl Med 16 (1975) 33
SILBERSTEIN E B SAENGER E L TOFE A J ALEXANDER JR G W and PARK H M Imaging of bone metastases with ^{99m}Tc-Sn-EHDP (diphosphonate) ^{18}F and skeletal radiography Radiology 107 (1973) 551
THRALL J H GHAED N GESLIEN G E PINSKY S M and JOHNSON M C Pitfalls in Tc ^{m} polyphosphate skeletal imaging Amer J Roentgenol 121 (1974) 739
TILDEN R L JACKSON JR J ENNEKING W F DELAND F H and MCVEY J Γ ^{m}Tc polyphosphate Histological localization in human femurs by autoradiography J nucl Med 14 (1973) 576
TODD POKROPEK A E SOUSSALINE F RAYNAUD D and ERBSMANN F The non uniformity of imaging devices and its impact in quantitative scintigraphic studies International Symposium on Medical Radionuclide Imaging Los Angeles IAEA 1976
VERA R MINEIRO L SPENCER R P and KLIGERMAN M M Determination of occult invasion of bone by adjacent tumor Radiology 101 (1971) 125

FROM THE DEPARTMENTS OF DIAGNOSTIC RADIOLOGY AND RADIATION PHYSICS AKADEMISKA SJUKHUSET S 750 14 UPPSALA SWEDEN

RADIATION PROTECTION IN FLUOROSCOPY WITH AN IMAGE INTENSIFIER

A HEMMINGSSON and P O LÖFROTH

When the roentgen tube is mounted above the patient and the image intensifier beneath the examination couch the radiation doses received by the personnel have been found to be considerably larger than with an opposite beam direction (JACOBSON 1970 HOFFMAN et coll 1971 RILEY et coll 1972 STACEY et coll 1974 WHOLEY 1974) Thus with an overcouch tube secondary radiation from the site of entry of the beam at the upper surface of the patient is greater than with an undercouch tube when scattered radiation comes mainly from the site of exit of the beam from the patient (HOFFMAN et coll) In this radiology department it has been found that in catheterization with the overcouch tube the radiation dose to the radiologist performing the catheterization may be more than 0 01 Gy over a period of four weeks measured at shoulder level above the lead rubber apron This means a dose to the lens for example lying close to the maximum permissible dose equivalent of 15 rem (1 rem=0 01 Sv) per year (ICRP 1966) Of the approximately 18 per cent of the blood forming bone marrow that is not protected by a lead rubber apron (HOFFMAN et coll) the greatest proportion is located cranially and the dose to this fraction of bone marrow would therefore be unacceptably high (maximum permissible dose equivalent 5 rem per year ICRP) For fluoroscopy in examination rooms equipped with an overcoach tube special auxiliary device have been constructed to minimize th radiation dose received by parts of the body that are not protected by the lead rubber apron The aims have been (1) to diminish the radiation to the unprotected

Submitted for publication 7 December 1977

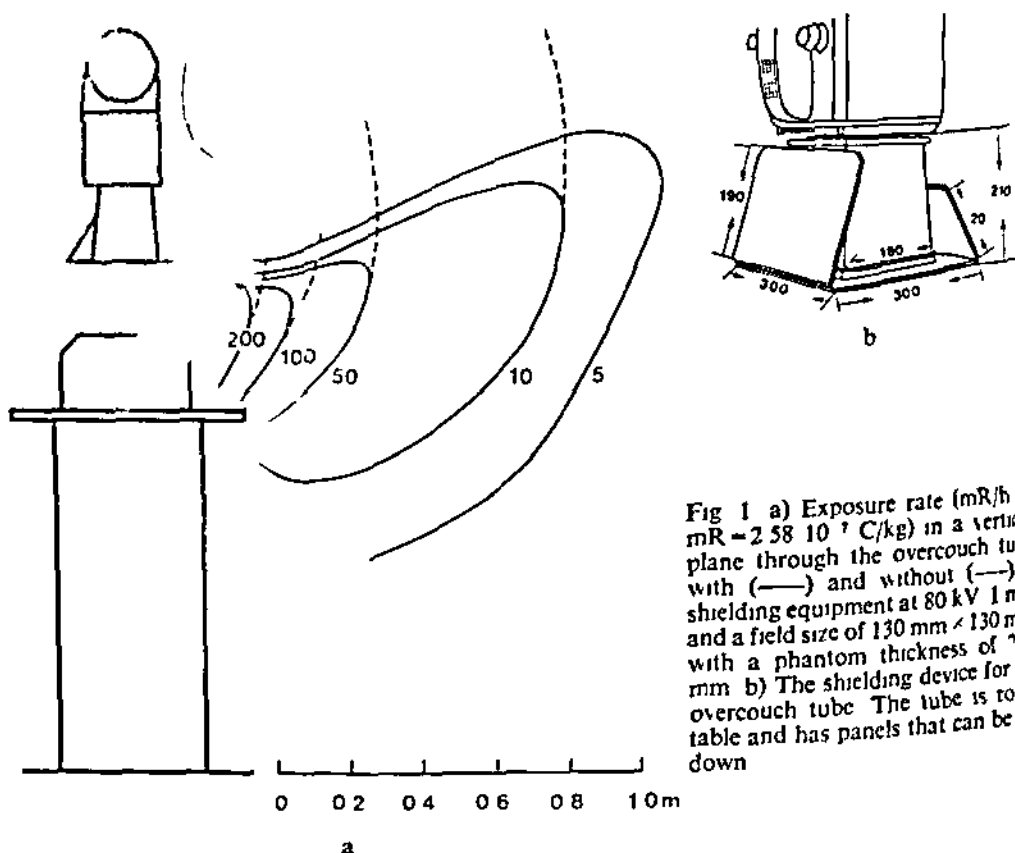


Fig 1 a) Exposure rate (mR/h 1 mR = 2 58 10 ⁷ C/kg) in a vertical plane through the overcouch tube with (——) and without (---) a shielding equipment at 80 kV 1 mA and a field size of 130 mm × 130 mm with a phantom thickness of 200 mm b) The shielding device for an overcouch tube The tube is tota table and has panels that can be let down

head-neck-shoulder region (2) to prevent that the shielding device hampers the work of the examiner (3) to promote sterile catheterization conditions and (4) to make the handling of the device easy and not unduly heavy

Material and Methods

The radiation in the laboratory was measured with a surveymeter (Nuclear Chicago Model 2588 Monitor and 2526 medium range ionization chamber volume 500 ml) The measurement instrument has a linear energy response ranging from 10 keV to over 1 MeV with an accuracy of 10 per cent Supplementary measurements were made with an EIL ionization chamber (37 A) connected to a Keithley Electrometer 616

A 200 mm thick and 300 mm square water phantom corresponding roughly to the cross sectional dimensions of a normal sized patient was placed on the examination couch in the centre of the radiation field The beam was oriented at right angles to the image intensifier Measurements were performed during fluoroscopy with automatic dose control in a vertical plane through the beam at right angles to the tube The size of the focal spot was 1 2 mm × 1 2 mm and the tube potential was 80




Fig 2



Fig 3

Fig 2 The shielding device mounted on the tube

Fig 3 The shielding device in place Lead rubber suspended on the compression tube of a remote control apparatus for fluoroscopy with the overcouch tube

kV (12 pulses per period) with total filtration of the beam 3 5 mm Al The field size at the level of measurement was 130 mm 130 mm The radiation levels are given as exposure per time unit and per mA (mR/h 1 mR = 2 58 10 ^{7} C/kg)

The problems of radiation protection in connection with overcouch installations has been solved by shielding equipments which are mainly based on the same principles At this radiology department a detachable shielding tube has been constructed that can be fixed onto the diaphragm housing in the channels intended for the perspex plates or additional filters for use in angiography laboratories and other fluoroscopy rooms equipped with an overhead tube and a film focus distance of about 100 cm (Figs 1 b 2) The shielding tube is rotatable and is supplied with two hinged panels of different sizes that can be let down to improve the shielding in the direction of the examiner The shielding tube is constructed of a 6 mm thick plexiglass frame covered with a 0 5 mm thick sheet of lead The sheet of lead is glued to the plexiglass

For remote control installations with a compression tube a lead rubber shield with a lead equivalence of 0 5 mm has been constructed This is suspended along the long side of the couch by means of open hooks on rods that are fixed to the compression tube In order to protect the anaesthesist for example at the head side of the couch a long lead rubber screen is also suspended so that it is almost at right angles to the radiation field and shields the examiner at the long side of the table and also one of the short ends of the table from secondary radiation (Fig 3)

64 – 785841

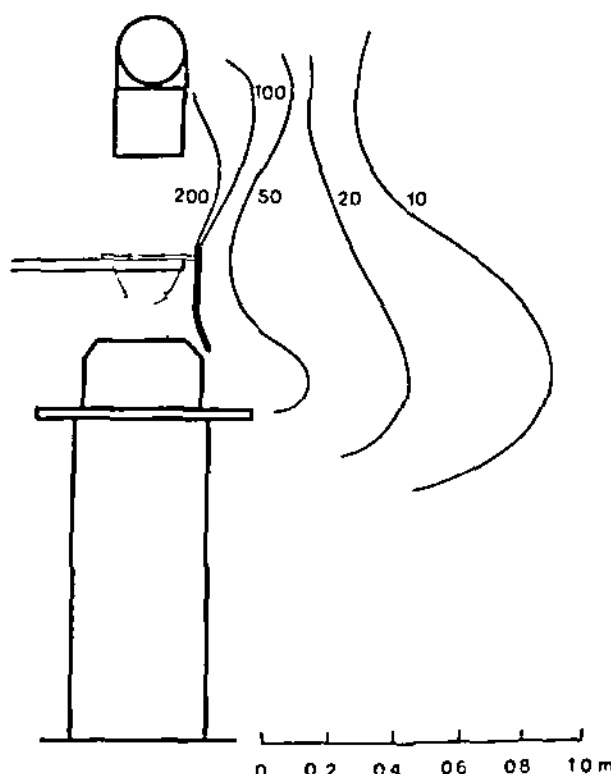
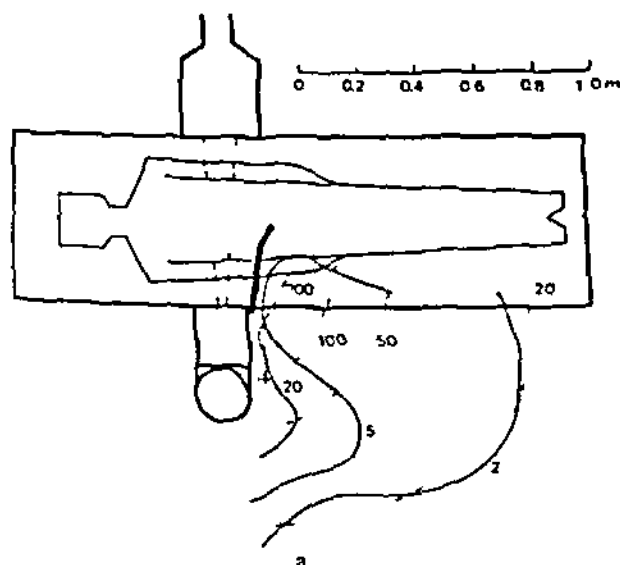


Fig 4 The lead quivalence of the lead rubber in Fig 3 is 0 5 mm The exposure rate (mR/h) at the couch with the shielding device (——) is given at 80 kV 1 mA and a field size of 130 mm 130 mm with a phantom thickness of 200 mm

For cardioangiography with use of a lateral roentgen tube a shielding device has been fixed to the side of the diaphragm housing (Fig 5 b) This device which is made of a sheet of lead rubber with a lead equivalence of 0 5 mm and is suspended on an aluminium rail can be lowered to shield against secondary radiation from the patient which otherwise impinges upon the examiner s unprotected head neck and arms and reduce the general radiation level in the laboratory This shielding device can be fixed in the raised position with a magnetic lock and kept in the desired position with a friction lock

Results

Without any extra shielding in fluoroscopy with the overcouch tube the level of radiation above and at the examination couch is relatively high (Fig 1 a) Thus for the shoulder–neck–head region which is not protected by the lead rubber apron the exposure rate is 100 to 200 mR/h When the shielding device is applied and with the panel let down the radiation in this region is reduced to less than 5 mR/h (Fig 1 a) At lower levels of the room the secondary radiation is not reduced with such high efficiency but individual protection is provided by the lead rubber apron With this shielding device the radiation dose to the staff including the radiologist performing the catheterization measured at the cervical region was less than 0 5 mGy over a period of four weeks



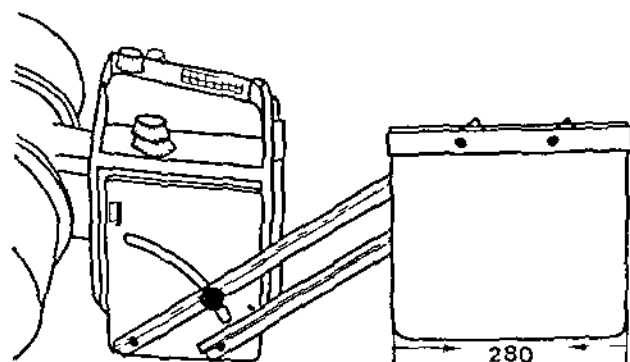


Fig 5 a) Lead rubber with a lead equivalence of 0.5 mm for fluoroscopy and cineradiography with a lateral tube The figure gives the exposure rate (mR/h) at the side of the examination couch in a horizontal plane about 115 cm above the floor The exposure rate with (——) and without (---) the lead rubber is given at 80 kV 1 mA and a field size of 130 mm 130 mm b) The shielding device for a lateral tube

With the lead rubber shield attached to the compression tube of the remote control installation the trunk is well protected while the exposure rate in the shoulder–neck–head region is 20 to 100 mR/h This depends on how close to the patient the shield is positioned (Fig 4) With the shielding device used with the lateral tube at cardioangiography the radiation is reduced from about 100 to 200 mR/h to less than 5 mR/h at the level of the device measured at the position of the radiologist performing the catheterization

Discussion

During the two years in which it has now been in use the detachable tube fixed onto the diaphragm housing in fluoroscopy with the overhead tube has been found easy to handle and has caused no hindrance to the work of the examiner The reduction by a factor of 20 to 40 of the radiation reaching the shoulder–neck–h

means a substantial improvement of the radiation protection of unshielded parts of the body at angiography and a considerably lower level of general radiation in the laboratory The annual dose to the lens which the examiner may receive during fluoroscopy with catheterization using this extra shielding device is less than one tenth of the maximum permissible dose to the lens 15 rem per year Obviously to achieve this dose reduction constant use must be made of the shielding device the radiation fields must be kept as small as possible and long periods of fluoroscopy should be avoided

The lead rubber shield that is attached to the compression equipment of a remote control apparatus is simple to manufacture It does not protect the head and shoulder region quite as well as the device described but positioned close to the object it gives a general reduction of the environmental radiation in the room To provide additional protection to the head–neck–shoulder region in fluoroscopy during a longer time especially in obese patients a complementary tube can be attached to the diaphragm housing as described This lead rubber shield cannot be used unless covered by sterile drapes when sterile conditions are necessary

The shielding device used with the lateral tube in cardioangiography also satisfies the demands for clinical application and diminishes the radiation dose ten to fifty fold This device shows that an effective radiation shield need not be complicated or impede upon the examination procedure

Furthermore the measurements demonstrated that a high radiation dose to members of the staff with the tube above or at the side of the examination couch is predominantly due to secondary radiation from the patient Thus no leakage radiation from the tube or tube housing was found with the equipment used

SUMMARY

In fluoroscopy and cineangiography with an overcouch tube or with a lateral tube the radiation dose to the personnel is high Simple shielding devices reducing ten to fifty fold the radiation dose to the unprotected shoulder–neck–head region are described

ZUSAMMENFASSUNG

Bei Durchleuchtung und Kinematographie mit einer Obertischrohre oder einer lateralen Rohre ist die Strahlendosis des Personals hoch Einfache Schutzanordnungen die die Strahlendosis der ungeschutzten Schulter–Nacken–Kopf Regionen zehn bis funfzig Fach reduzieren werden beschrieben

RESUME

La dose de radiation reçue par le personnel est elevée au cours de la radioscopie et de la cinéangiographie faites avec un tube au-dessus de la table ou avec un tube latéral Les auteurs décrivent des dispositifs protecteurs simples qui reduisent dans une proportion allant de dix à cinquante fois la do e d irradiation de la region de l epaule du cou et de la tete par rapport à la dose sans protection

REFERENCES

HOFFMAN J R STAIGER J W WOLLAN R O and AMPLATZ K The Minnesota special procedure room Radiology 97 (1971) 551
ICRP Recommendation of the International Commission on Radiological Protection Publication 9 Pergamon Press London 1966
JACOBSON A Radiation protection considerations of overhead fluoroscopic installations Hlth Phys 20 (1970) 55
RILEY R C BIRKS J W PALACIOS E and TEMPLETON A W Exposure of radiologists during special procedures Radiology 104 (1972) 679
STACEY A J and DAVIS R Personnel protection during cardiac catheterization with a comparison of the hazards of undercouch and overcouch X ray tube mountings Brit J Radiol 47 (1974) 16
WHOLEY M H Clinical dosimetry during the angiographic examination Comments on coronary arteriography Circulation 50 (1974) 627

FROM THE SECTION FOR MAXILLO FACIAL ROENTGENOLOGY CENTRAL HOSPITAL S 961 19 BODEN AND THE DEPARTMENT OF RADIATION PHYSICS UNIVERSITY OF UMEÅ S 901 85 UMEÅ SWEDEN

MEAN ENERGY IMPARTED IN RELATION TO THE FOCUS TO OBJECT DISTANCE

U WELANDER and G WICKMAN

It is a common opinion that the dose given to the patient at the exposure of a radiographic image should be reduced by an increased focus to object distance ICRP mentions this view in Publication 16 (1970) page 19 The inverse square law states that from a point source in a uniform non absorbing medium the radiation intensity varies inversely as the square of the distance from the source Short focus-skin distances result in a low transmission ratio due to a high divergence of the beam and consequently the incident exposure of the patient for a given exposure at the film or other recording device is high ICRP discusses the absorbed dose in the skin or the maximum absorbed dose It may be put under question whether or not this parameter has any relevance to the radiation risks at the absorbed dose levels in ordinary diagnostic radiology

The absorbed dose as defined by ICRU (Report 19 1971) is dependent on the energy fluence which is the quotient of the energy that enters a sphere by the cross sectional area of that sphere The energy fluence varies with the focus to object distance due to the inverse square law However it should be observed that not only the energy fluence varies because of the divergence of the beam but also the exposed area at different distances from the source the area is directly proportional to the square of the distance

The effects of a varied focus to object distance on the integral (absorbed) dose i e the mean energy imparted and on the maximum absorbed dose are analysed in this report

Submitted for publication 6 October 1977

In the basic work on calculations of the integral dose MAYNEORD (1944) does not calculate the effects mentioned and in subsequent communications on the integral dose no separate analysis of its relation to the focus to object distance seems to have been performed

Analysis

Symbols (see Figs 1 and 2)

$\bar{\varepsilon}$ = mean energy imparted

ψ = energy fluence

μ = linear attenuation coefficient

ρ = density

$\frac{\mu}{\rho}$ = mass attenuation coefficient

$\frac{\mu_{en}}{\rho}$ = mass energy absorption coefficient

l = distance from the source

l_ψ = distance from the source to the plane where the energy fluence is kept constant whilst the focus to object distance is varied

l = distance from the source to the plane where the exposed area is kept constant whilst the focus to object distance is varied

a = exposed area

z = object depth along the central ray of the radiation beam

The definitions of the radiation quantities are in accordance with the recommendations by ICRU (Report 19)

Theory When the energy fluence is ψ_0 at an exposed area a_0 the integrated energy fluence over that area is $\psi_0 a_0$ The integrated energy fluence over any other parallel area within the beam i e at any other distance from the source is in vacuum (Fig 1 a)

$$\psi_1 a \qquad {}_0 \tag{1}$$

It follows directly from eq (1) that the energy fluence integrated over an area is independent on the distance from the source The effect of the inverse square law on the energy fluence is compensated by the successively varying area which is directly proportional to the square of the distance from the source In fact this is self evident since the decrease in the energy fluence at an increased distance from the source is due to its spreading over a greater area

Should the beam enter an absorbing medium the energy fluence will decrease successively due to attenuation Considering monoenergetic radiation the following is obtained from eq (1) when the effect of the attenuation is introduced

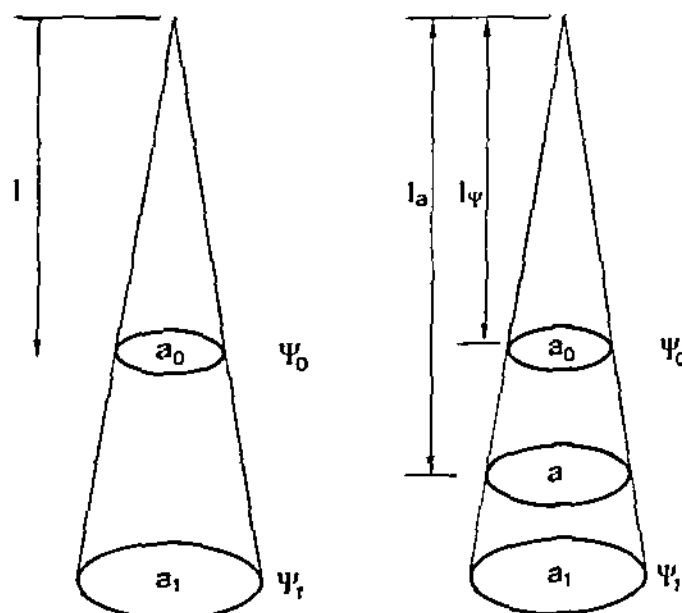


Fig 1 Essential parameters when calculating the energy within a divergent beam at different distances from the source

In calculations of absorbed energy the effect of the secondary photons i e the build up factor arises as a fundamental problem For the purpose of the present analysis the following solution should be satisfactory

Assuming that all secondary photons are absorbed by the object it is possible to define a theoretic upper limit of the mean energy imparted in an exposed object This upper limit may be found from eq (2) by integration In an object of the thickness x_1 it is

$$\int_0^x \mu \psi_0 e^{-\mu x} a_0 \, dx = \psi_0 a_0 (1 - e^{-\mu x}) > \varepsilon \tag{3 }$$

The theoretic lower limit of the mean energy imparted in an exposed object may be found by assuming that all secondary photons escape the object The proper expression is obtained by introducing the mass energy absorption coefficient

$$\int_0^x \frac{\mu_{en}}{\varrho} \psi_0 e^{-\mu x} a_0 \varrho \, dx = \psi_0 a_0 \frac{\frac{\mu_e}{\varrho}}{\frac{\mu}{\varrho}} (1 - e^{-\mu x}) < \varepsilon \tag{3 }$$

Eq (3) gives in reality the absorption along one single ray i e the absorption in a zero field Eq (3) overestimates and eq (3) underestimates the true value of the mean energy imparted Considering an object of water 20 cm thick which is used as a model object in the following eq (3) overestimate the mean energy imparted by about 20 to 40 per cent (CARLSSON 1963)

The focus to object distance does not appear as a parameter in the equations given Furthermore moderate variations in the focus to object distance i e varia

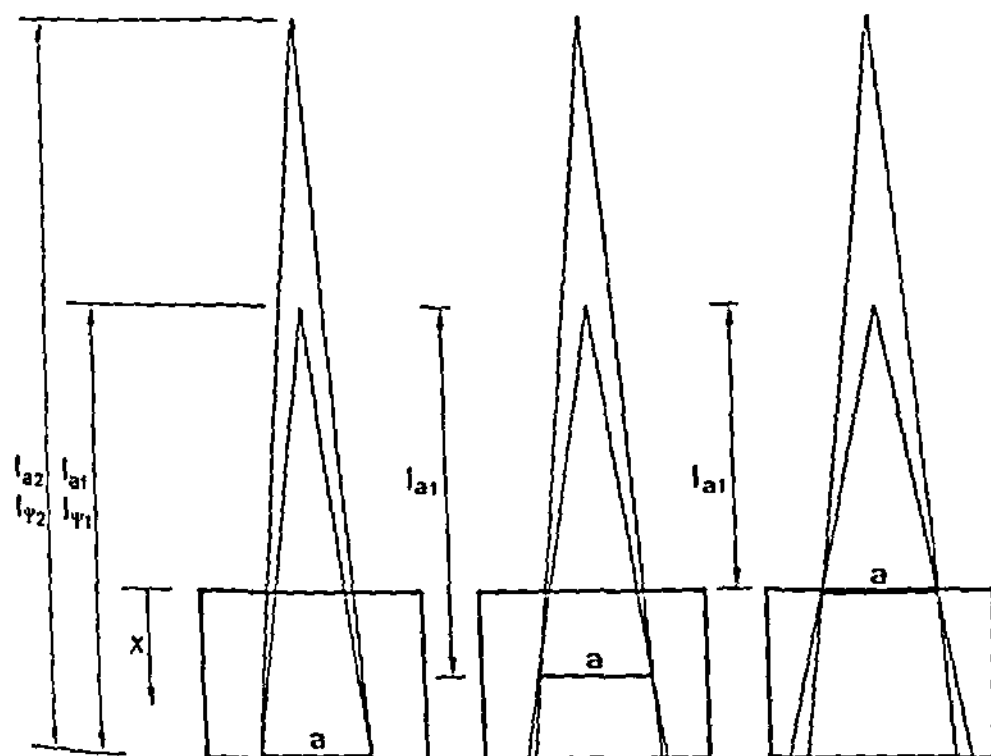


Fig 2. Three characteristic geometric situations that were considered in the calculations. Whilst the energy fluence was kept constant at the exit of the object the exposed area was varied to different planes within the object.

tions over the radiation field in distances traversed by the roentgen photons are small and should give only marginal effects on eqs (3) and (3). This suggests that also the mean energy imparted is only moderately influenced by the focus to object distance. More rigorously this small influence may be shown by the saturated scatter method (CARLSSON).

In the analysis it is presupposed that both the energy fluence and the exposed area are kept constant at the same plane whilst the distance to the source is varied (Fig 2 a). In diagnostic radiology the energy fluence of the primary beam at the film or other recording device should be the same to keep the information content carried by the radiation relief constant when the focus to object distance is varied. However the width of the beam should be chosen with respect to the organ to be examined. Therefore it may be correct to keep the width of the beam constant at a certain object depth and not at the film when the focus to object distance is to be varied (Figs 1, 2).

Suppose that the exposed area a is kept constant at the distance l_a from the source. Then the exposed area a_φ at the distance l_φ from the source is found from the following relation (cf Figs 1, 2)

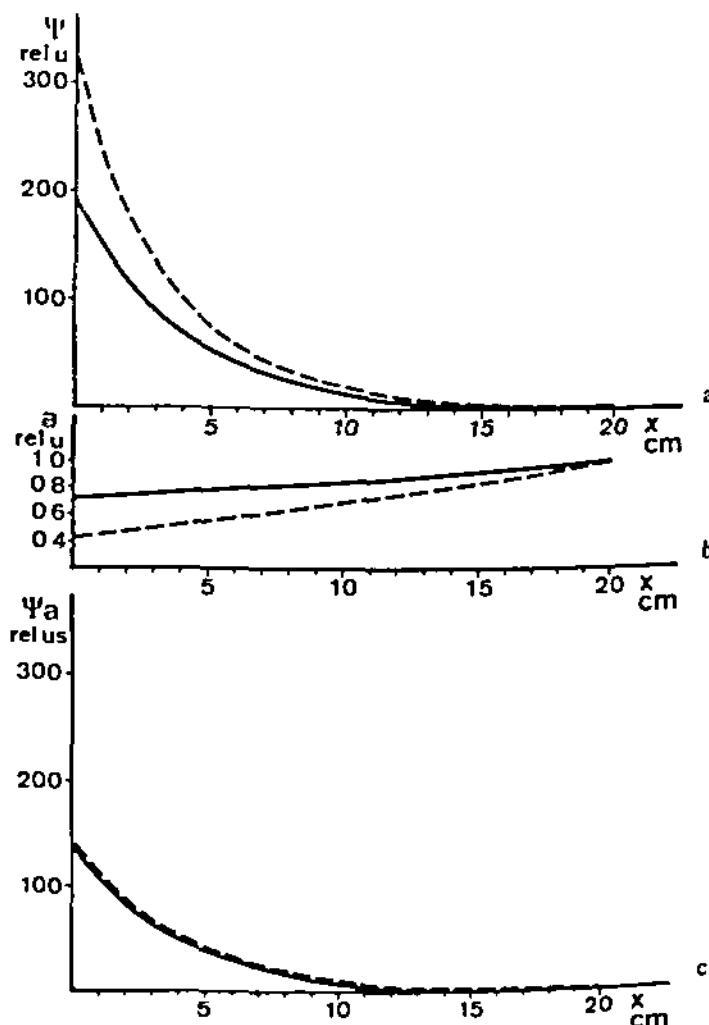


Fig 3 Basic results of the analysis this graphic illustration gives an over estimated relative value of the mean energy imparted according to eqs (2) and (3) a) The relative primary energy fluence as a function of the object depth for two different focus to object distances 40 cm (broken line) and 120 cm (continuous line) when the value at the exit of the object is normalized to 1 b) The relative size of the exposed area as a function of the object depth The exposed area is normalized to 1 at the exit of the object c) The relative energy fluence integrated over the area as a function of the object depth The function is identical for all focus to object distances because the influence of the inverse square law on the energy fluence (a) is compensated by the variation of the exposed area (b)

Substituting eq (2)

$$\psi_1 a_1 = \psi_0 e^{-\mu x} a \left(\frac{l_r}{l_a}\right)^2 \tag{4}$$

is obtained

The overestimated value of the mean energy imparted in an object of the thickness χ_1 is in this case (cf eq 3)

$$\int_0^x \mu \psi_0 e^{-\mu x} a \left(\frac{l_r}{l_a}\right) d\chi = \psi_0 a \left(\frac{l_r}{l}\right)^2 (1 - e^{-\mu x}) > \varepsilon \tag{5 }$$

The influence of the focus to object distance on the underestimated value of the mean energy imparted (cf eq 3) will be the same Thus under the geometric conditions illustrated in Figs 1 b 2 b and 2 c the energy fluence integrated over the area eq (4) and the *mean energy imparted* eq (5) *are influenced* by the distance to the

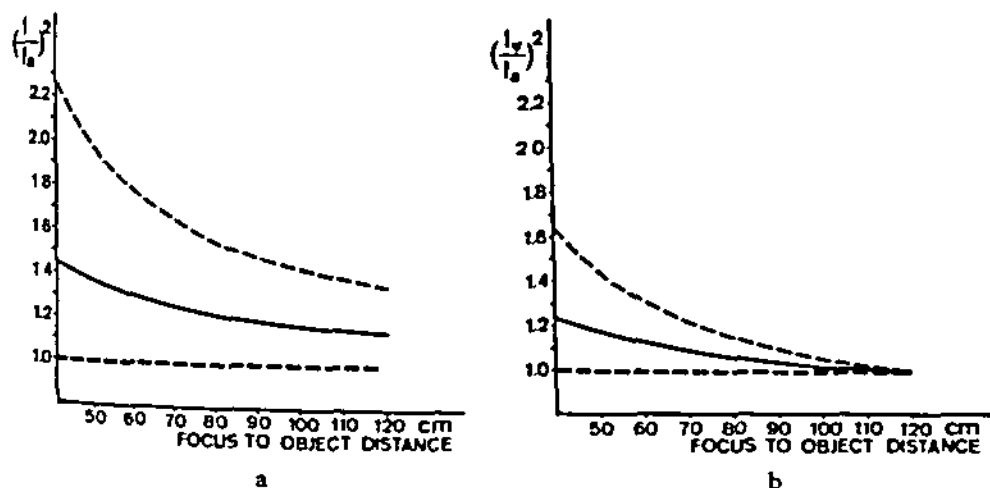


Fig. 4 The mean energy imparted and also the energy fluence integrated over the beam area are proportional to the ratio $(l_v/l)^2$ cf eqs (4) and (5) a) The relative increase of the mean energy imparted as a function of the focus to object distance when the exposed area is normalized at the exit of the model object (cf Fig 2 a thick broken line) at the centre of the model object (cf Fig 2 b continuous line) and at the entrance of the model object (cf Fig 2 c thin broken line) In the first case the focus to object distance is of no significance In the remaining two cases the relative increase of the mean energy imparted is seemingly too high depending on the normalization to an area which is identical at all object depths b) The same functions as demonstrated in (a) when normalized to the volume exposed at 120 cm focus to object distance according to the geometric situation illustrated in Fig 2 a

source The relation to the distance is described by the squared ratio between the distances to the planes where the energy fluence and the exposed area are kept constant l_v and l respectively

Results

From the expressions given relative numerical values of the absorbed dose and the mean energy imparted were calculated for different geometric situations In all situations the energy fluence was normalized to 1 non specified unit at the exit of a model object consisting of water The model object was 20 cm thick The exposed area was normalized to 1 at the exit of the model object (Fig 2 a) at different planes within the model object (Fig 2 b) and at the entrance of the model object (Fig 2 c) Focus to object distances between 40 and 120 cm were considered

Mean energy imparted The energy fluence of the primary photons as a function of the object depth is graphically demonstrated in Fig 3 a The energy fluence varies continually with the focus to object distance between the illustrated functions which are valid for 40 and 120 cm focus to object distances respectively When the energy fluence is kept constant at the exit of the object the energy fluence at the entrance will be greater when the focus to object distance is short than when it is long In the

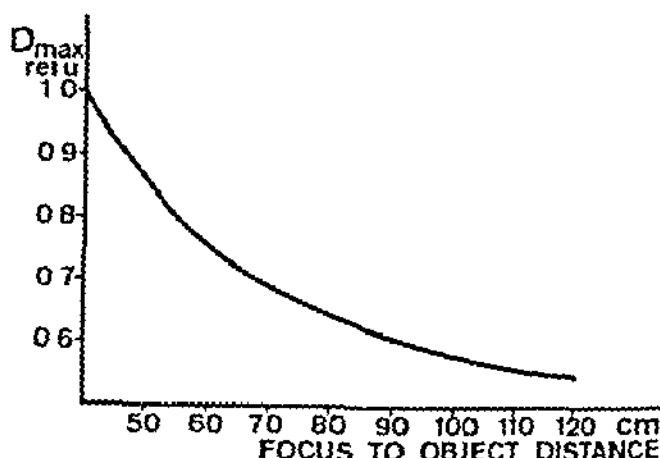


Fig 5 The maximum absorbed dose as a function of the focus to object distance The function is normalized to 1 at 40 cm focus to object distance

example given the increase is about 65 per cent However the exposed area when normalized at the exit of the object varies inversely as the energy fluence (*Fig* 3 b) Thus the energy fluence integrated over the exposed area as a function of the object depth will be identical irrespective of the focus to object distance (Fig 3 c) Consequently the mean energy imparted or the integral dose is in this case the same irrespective of the focus to object distance (cf eqs 3 and 3)

When the exposed area is kept constant within the object whilst the focus to object distance is varied (Fig 2 b c) the mean energy imparted will be influenced by the distance to the source the mean energy imparted decreases with an increased focus to object distance The relative difference between the mean energy imparted when different projection geometries are employed is given by the ratio (I_ψ/I) (Fig 4) The functions illustrated in Fig 4 a *are* valid when the exposed area is normalized to 1 at the exit in the centre and at the entrance of the model object Compared to a normalization of the exposed area at the exit of the object a normalization at the entrance gives an increase of the mean energy imparted by a factor 2 25 at 40 cm and 1 36 at 120 cm focus to object distance In the latter case the increase is exclusively due to the greater exposed volume which follows from the greater exposed area at the entrance of the object Thus the functions illustrated in Fig 4 a are not comparable in all respects When the volume exposed at 120 cm focus to object distance is used to normalize the values in a comparison the functions illustrated in *Fig* 4 b are obtained In this case a reduction of the focus to object distance from 120 to 40 cm gives an increase of the mean energy imparted by a factor 1 65

It should be observed that the examples given represent the extreme limits of the geometric situations that were considered in the calculations When the field size is kept constant within the back half of the object the increase of the mean energy imparted which follows from a reduced focus to object distance is lim ted A comparison between Fig 4 a and b reveals that the selection of a proper field size has a greater influence on the mean energy imparted than has the focus to object distance

Maximum absorbed dose For a given radiation quality the absorbed dose is directly proportional to the energy fluence The maximum absorbed dose which is found at the skin decreases when the focus to object distance increases its variation with the focus to object distance is given in Fig 5 It is evident that the decrease in the maximum absorbed dose is rather small when the focus to object distance is increased from 40 to 120 cm

Discussion

The relationship between the energy absorbed by the patient at the exposure of a radiographic image and the focus to object distance is complex A great number of variables are involved in the solution of the problem and the results obtained may be differently evaluated However it may be stated that the commonly accepted view that the patient dose decreases as the focus to object distance increases simplifies the matter in too high a degree

Different measures of the absorbed energy such as the mean energy imparted and the maximum absorbed dose vary differently when the focus to object distance is varied The only possible way to estimate what dose measure is most relevant is to consider its reliability in estimations of the radiation risks On this basis it should secondly be possible to consider the significance of different focus to object distances with respect to the energy absorbed by the patient In this connection it is important to emphasize that in diagnostic radiology non stochastic effects such as erythema or cataracts in the lens of the eye may usually be neglected Mainly stochastic long term risks such as carcinogenesis should be considered (GREGG 1977)

The absorbed dose decreases in front of the recording device when the dose is kept constant at that device whilst the focus to object distance is increased However this dose measure expresses the absorbed energy in one mass element of the exposed volume only When estimating the radiation risks the absorbed dose may be of some interest as a measure of for example the maximum absorbed energy within a fraction of an exposed organ but generally it seems to be of a limited value When referring to the absorbed dose no consideration is paid to the total amount of energy which is absorbed in an exposed volume or mass Arguments for the opinion that the total absorbed energy irrespective of its distribution should be the most reliable measure when evaluating radiation risks are indirectly given by ICRP (Publication 14 1969) Regarding the risk of malignancy the same opinion is also indirectly expressed by BROWN (1976) as presented by BROWN it should be valid provided that the risk is a linear function of the absorbed energy At present the most commonly used approach to estimations of radiation risks is based on this presupposition and regarding low values of absorbed energy GREGG claims that linear interpolation should be valid

Within the limited changes of the projection geometry which follows from variations of the focus to object distance between 40 and 120 cm the variation in the distribution of the absorbed dose is also limited Essentially the same tissues and the same organs with the same sensitivity to radiation are exposed (Fig 2) This fact

strengthens the opinion that the distribution of the absorbed dose is less important than the total absorbed energy in risk estimations performed with regard to the different focus to object distances that are usually applied in diagnostic radiology

In the present work it was presupposed that the object was large in relation to the primary beam and only a part of the object was exposed In this case the energy lost by back and lateral scatter should be essentially the same for the projection geometries employed in the calculations The effect on the mean energy imparted of a varied focus to object distance when a total object is exposed e g in mammary radiography was not analysed

The present calculations were performed on a model object which was considered homogeneous A real object has a non homogeneous attenuation However this condition should not affect the basic results the principle effects of a varied focus to object distance are not changed due to the characteristics of the object

The effect of the secondary radiation the build up factor was assumed to be essentially the same for the slightly different projection geometries that were considered CARLSSON performed calculations of the integral dose using central axis depth dose values for very large fields the saturated scatter method A scrutiny of CARLSSON s equations and results shows that this approach should give in principle the same result with respect to the influence on the integral dose of a varied focus to object distance Calculations from depth dose tables valid for zero fields thus neglecting secondary radiation also give the same principle results (WELANDER & WICKMAN 1977)

It may be concluded that the focus to object distance is of minor importance with respect to the patient dose When the field size is adapted to the film or other recording device the mean energy imparted is essentially the same for all focus to object distances Should the field size be kept constant within the back half of the object whilst the focus to object distance is increased a limited decrease of the mean energy imparted occurs However it should be observed that this decrease is changed to an increase if the field size is not properly adapted to the longer focus to object distance The last statement is also emphasized by ICRP (Publication 16 1970) Generally an adequate reduction of an unnecessary large field size reduces the mean energy imparted and thereby the radiation risks more than an increased focus to object distance

The most essential result of the present analysis may be summarized as follows When selecting between different examination techniques employing short or long focus to object distances the radiation risks are of little significance In the first hand the desired geometric projection of the object should be considered when selecting the proper technique

Acknowledgement

The authors wish to express their sincere thanks to professor Carl Carlsson Department of Radiation Physics Regionsjukhuset Linkoping for constructive criticism and advice

SUMMARY

The relationship between the energy absorbed by the patient at the exposure of a radiographic image and the focus to object distance is analysed It is found that the mean energy imparted or the integral absorbed dose is the same irrespective of the focus to object distance when the energy fluence and the field size are both normalized at the film plane When the field size is kept constant within the object whilst the focus to object distance is varied a limited increase in the mean energy imparted occurs when the focus to object distance is decreased this statement is valid for the focus to object distances which are usually applied in diagnostic radiology When estimating radiation risks the importance of the focus to object distance is found to be of limited interest

ZUSAMMENFASSUNG

Der Zusammenhang zwischen der Energieabsorption in den Patienten bei der Exponierung eines Rontgenbildes und dem Fokus Objekt Abstand wird analysiert Die mittlere verabfolgte Energie oder die integrierte absorbierte Dosis ist dieselbe unabhängig vom Fokus–Objekt Abstand wenn der Energiefluss und die Feldgrosse beide in der Filmebene normalisiert werden Wenn die Feldgrosse innerhalb des Objektes konstant gehalten wird wahrend der Fokus–Objekt Abstand verandert wird erfolgt ein begrenzter Anstieg in der mittleren verabfolgten Energie wenn der Fokus–Objekt Abstand sinkt Diese Feststellung ist gultig fur Fokus–Objekt Abstande wie sie gewohnlicher weise in der diagnostischen Rontgenologie verwendet werden Bei der Bestimmung vom Strahlenrisiko ist die Bedeutung des Fokus–Objekt Abstandes nur von begrenztem Interesse

RESUMÉ

Les auteurs analysent les relations entre l energie absorbée par le patient au cours de la prise d une image radiographique et la distance foyer–objet Ils ont trouvé que l energie moyenne communiquée au patient ou la dose intégrale absorbée est la meme quelle que soit la distance du foyer a l objet quand la fluence d energie et la dimension du champ sont tous deux normalises dans le plan du film Quand la dimension du champ est maintenue constante dans l objet alors qu on fait varier la distance du foyer à l objet on observe une augmentation limitee de l energie moyenne communiquee quand on diminue la distance du foyer a l objet Cette constatation est valable pour les distances du foyer a l objet qui sont habituellement utilisées en radiodiagnostic Quand on evalue les risques des radiations l importance de la distance du foyer à l objet a un interet limite

REFERENCES

BROWN J M Linearity vs non linearity of dose response for radiation carcinogenesis Hlth Phys 31 (1976) 231

CARLSSON C of Determination integral absorbed dose from exposure measurements Acta radiol Ther Phys Biol 1 (1963) 433

GREGG E C Radiation risks with diagnostic X rays Radiology 123 (1977) 447

ICRP Publication 14 Radiosensitivity and spatial distribution of dose Pergamon Press Oxford 1969

ICRP Publication 16 Protection of the patient in X ray diagno is Pergamon Press Oxford 1970

ICRU Report 19 Radiation quantities and units ICRU Publications Washington D C 1971

MAYNEORD J M The mathematical theory of integral dose and its applications in practice Brit J Radiol 17 (1944) 359

WELANDER U and WICKMAN G The relationship between the integral dose and the focus to object distance in dental radiography Dentomaxillofac Radiol 6 (1977) 83

FROM THE RESEARCH LABORATORIES DEPARTMENT OF DIAGNOSTIC RADIOLOGY (DIRECTOR PROF T OLIN) MALMÖ ALLMANNA SJUKHUS S 214 01 MALMÖ SWEDEN

ARTERIAL AND VENOUS BLOOD PRESSURE AND BLOOD FLOW FOLLOWING FEMORAL ANGIOGRAPHY WITH A NEW NON-IONIC CONTRAST MEDIUM

An experimental investigation in dogs

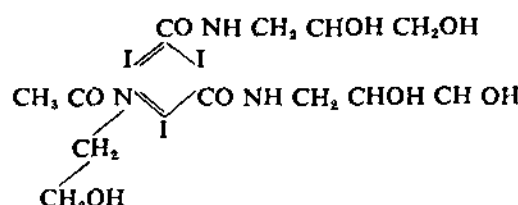
U NYMAN and T ALMÉN

In femoral angiography in man the ionic monomeric water soluble contrast media in current use produce an increased blood flow in the femoral artery (DELIUS & ERIKSON 1969 BOIJSEN et coll 1971) From animal experiments it has been concluded that this increase in blood flow is to some extent caused by the hypertonicity of the contrast medium solutions relative to plasma producing vasodilatation in the femoral vascular bed (HILAL 1966 LINDGREN et coll 1967 1968 a b)

In the research laboratories of Nyegaard & Co several non ionic water soluble contrast media have been synthesized These compounds have a lower osmolality at equivalent iodine concentrations when compared with the ionic angiographic media commonly used today One non ionic compound Amipaque (metrizamide) is in clinical use as contrast medium in the subarachnoid space on account of its low neurotoxicity Amipaque also has properties advantageous for use in femoral angiography Animal experiments (ALMÉN & TRAGÅRDH 1973) and clinical trials (ALMÉN et coll 1977) have demonstrated that metrizamide in femoral angiography produces less changes in the femoral blood flow and is less painful than the ionic monomeric contrast media in current use

Partly supported by the Swedish Medical Research Council (Project No 3483) Submitted for publication 16 December 1977

A new contrast medium has been synthesized by Nyegaard & Co in order to find a medium with the same low toxicity as that of m trizamide but with lower viscosity and better stability when autoclaved This compound C29 is a benzene derivative in which three hydrogens have been replaced with iodine and the remaining three hydrog ens replaced with radicals containing hydroxyl groups to achieve water solubility



The effects on femoral blood flow aortic blood pressure and venous blood pressure in the hind leg of the dog caused by femoral angiography with C29 were compared with those of one ionic (Urografin) and one non ionic contrast medium (Amipaque)

Material and Methods

Ten mongrel dogs of both sexes weighing 9 to 41 kg were anesthetized with intra venous pentobarbitone An endotracheal tube was inserted for maintenance of free respiratory pathway Depth of anesthesia during the experiments was characterized by regular costal and diphragmatic respiration presence of corneal and light reflexes and absence of eyelid reflex

In all 10 dogs blood flow through the left femoral artery aortic pressure and blood pressure in a vein of the left hind leg were monitored before during and after injec tions of contrast medium solutions into the left femoral artery

Injections of contrast medium solutions were made through a catheter (PE 60 Clay Adams) which was inserted in retrograde direction into a small muscle branch of the surgically exposed left femoral artery in the proximal part of the thigh The catheter was tied in the vessel with its tip at a distance of about 2 mm from the lumen of the femoral artery

In each dog all contrast medium solutions which had an iodine concentration of 280 mg I/ml were injected in random order at 2 dose levels 0 1 ml and 0 2 ml/kg body weight The injection time was approximately 2 s at the lower dose level and 4 s at the higher dose level

The following contrast medium solutions were injected

Urografin (meglumine/sodium diatrizoate Schering) diluted with water to 280 mg I/ml osmolality 1 5 osm viscosity 7 2 cP at 20 C

Amipaque (metrizamide Nyegaard) osmolality 0 5 osm viscosity 9 6 cP at 20 C

C29 (an experimental non ionic contrast medium Nyegaard) osmolality 0 5 osm viscosity 8 cP at 20 C

In addition injections of physiologic saline were made in 9 of the 10 dogs at the same dose levels

Femoral blood flow was recorded by a square wave electromagnetic flow meter (372 M Nycotron) which was used as a mean value flow meter with a time constant of approximately 2 5 s In addition the flow meter was equipped with an integrator summing up the total volume of fluid passing the transducer independent of rate or type of flow A suitable flow transducer was adapted around the left femoral artery 2 to 4 cm proximal to the injection site Zero flow was controlled by clamping the vessel distal to the flow transducer with no branching vessels between these 2 points

In all experiments continuous simultaneous recording from the mean value flow meter and registrations of integrated fluid volumes were made during one min before and 3 min after each injection of the test solution The maximum increase in mean blood flow in the femoral artery after injection was expressed as percentage of the highest mean blood flow recorded during a one min period before the injection From registrations of the integrated fluid volumes the average blood flow during one min before and 3 min after the injection was calculated The average increase in blood flow was expressed as percentage of the blood flow before the injection

Aortic blood pressure was measured through a catheter (PE 90 Clay Adams) which was inserted into a small branch of the right femoral artery and manipulated into the abdominal aorta The maximum decrease in systolic pressure after injection of a test solution was expressed as percentage of the lowest systolic pressure recorded during a one min period before the injection

Venous blood pressure was measured through a catheter (PE 90 Clay Adams) which was introduced into a superficial subcutaneous vein and advanced about 10 cm in proximal direction until its tip was about 5 cm distal to the left stifle joint The maximum increase in venous pressure was expressed as percentage of the maximum value recorded during a one min period before the injection

The pressure catheters were connected to a pressure transducer (EMT 34 Siemens Elema) and recordings of blood pressure and mean blood flow were made on a Mingograf (Siemens Elema)

Femoral angiography was performed in 5 of the dogs at the lower dose level and in 3 of the dogs at the higher dose level

Wilcoxon s rank test for pair differences was used for statistical analysis of the results and a difference with a p-value <0.05 was considered significant

Results

Blood flow through femoral artery

Recording by the mean value flow meter During and immediately after the injection of the test solution a short decrease in blood flow was recorded followed by an increase with a maximum about half a minute after the start of the injection At the dose

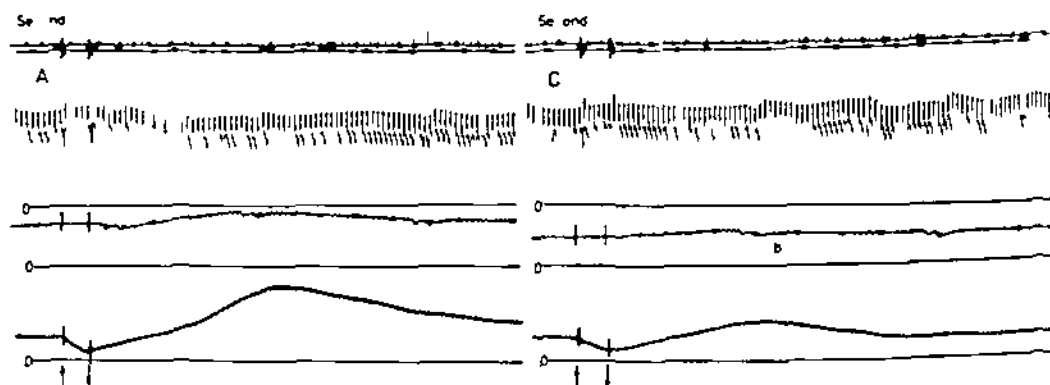


Fig 1 Recordings of a) aortic blood pressure b) venous blood pressure in the left hind leg and c) mean blood flow through the left femoral artery before during and after injection (0 2 ml/kg body weight) of Urografin (A) and C29 (C) into the left femoral artery Time of injection (↑↓)

0 1 ml/kg body weight injections of the different test solutions caused the following maximum increase in mean blood flow (median values) Urografin 213 per cent Amipaque 53 per cent C29 48 per cent and saline 9 per cent At the dose 0 2 ml/kg body weight the maximum increase in mean blood flow was Urografin 325 per cent Amipaque 160 per cent C29 85 per cent and saline 9 per cent

At both dose levels Urografin caused a significantly ($p < 0 01$) higher maximum increase in mean blood flow than the other media No significant difference between Amipaque and C29 was recorded (Figs 1 2 a)

Registration of integrated blood volume The average increase in blood flow rate during 3 min caused by the injection of the different test solutions at a dose of 0 1 ml/kg body weight (median values) was Urografin 64 per cent Amipaque 15 per cent C29 6 per cent and saline 3 per cent At a dose of 0 2 ml/kg body weight the corresponding figures were Urografin 74 per cent Amipaque 24 per cent C29 20 per cent and saline 1 per cent At both dose levels Urografin produced a significantly ($p < 0 01$) higher average increase in blood flow rate during a 3 min period than the other media whereas there was no significant difference between Amipaque and C29 (Fig 2 b)

The blood flow returned to pre injection value within 3 min following injection of Amipaque and C29 after injection of Urografin the blood flow was still increased at that time but returned to pre injection level before the next injection

Aortic pressure

Following the injection of contrast medium a slight decrease in systolic and diastolic aortic pressure often occurred reaching the lowest values within 30 s after the injection and then returning to pre injection level The maximum changes in systolic pressure following injection was as follows at a dose of 0 1 ml/kg body weight of the different test solutions (median values)

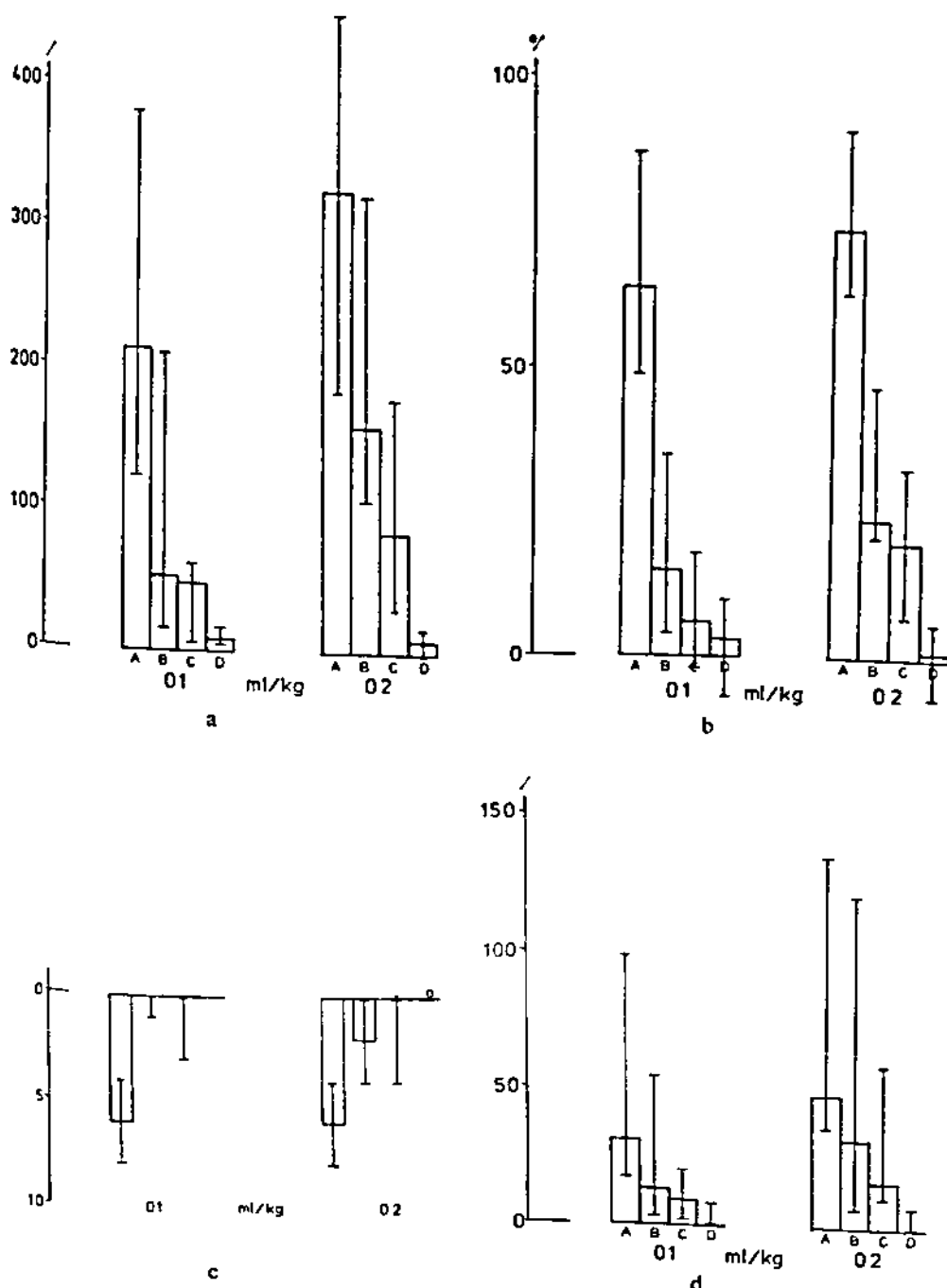


Fig 2 Changes in blood flow in the left femoral artery a) maximum increase b) average increase during a 3 min period c) Aortic blood pressure d) venous blood pressure in the left hind leg after injection of the test solutions in the left femoral artery at 2 dose levels 0 1 and 0 2 ml/kg body weight Median values first and third quartiles outlined A = Urografin B = Amipaque C = C29 D = physiologic saline

Urografin −6 per cent Amipaque 0 per cent C29 0 per cent and saline 0 per cent At a dose of 0 2 ml/kg body weight the corresponding figures were Urografin −6 per cent Amipaque −2 per cent C29 0 per cent and saline 0 per cent The aortic pressure changes induced by Urografin at both dose levels were significantly ($p < 0\ 02$) greater than those induced by the other media No significant difference between Amipaque and C29 was recorded (Figs 1 2 c)

Venous pressure

Following contrast medium injection the peripheral venous pressure of the hind leg increased reaching a maximum at about the same time as the flow in the femoral artery The various test solutions produced the following changes in venous pressure at a dose of 0 1 ml kg body weight (median values) Urografin 31 per cent Amipaque 13 per cent C29 9 per cent and saline 0 per cent At a dose of 0 2 ml/kg body weight the corresponding figures were Urografin 48 per cent Amipaque 32 per cent C29 17 per cent and saline 0 per cent At the lower dose level Urografin produced a significantly (p 0 01) higher increase in venous pressure than the other media At both dose levels no significant difference between Amipaque and C29 was recorded At the higher dose level Urografin produced a significantly (p 0 01) higher increase in venous pressure than C29 while no significant difference between Urografin and Amipaque occurred at this dose level (Figs 1 2 d)

Effect of physiologic saline

Saline induced a slight increase in femoral blood flow with a maximum about 20 s after the injection Venous blood pressure increased only in 3 of the 9 dogs while aortic pressure was not affected in any of the dogs At both dose levels the changes of the different parameters induced by Urografin were significantly ($p < 0\ 01$) greater than the changes induced by saline The increase in blood flow and venous pressure at the higher dose level was significantly (p 0 01) higher for Amipaque and C29 when compared with saline No significant difference at the lower dose level was recorded Amipaque C29 and saline had about the same effect on the aortic blood pressure

Femoral angiography

The contrast medium concentration in the arteries and veins as evaluated from the films seemed to be the same following injection of the various contrast media and no difference between the media was recorded regarding the time of appearance in the femoral vein

Discussion

At both dose levels investigated Urografin produced *significantly greater increase* in blood flow than Amipaque or C29 irrespective of the mode of evaluation (maximum change in mean blood flow with a time constant of 2 5 s or average change in blood flow during a 3 min period) Concerning the effect on femoral blood flow no signi

ficant difference between Amipaque and C29 was recorded at any dose level more over these 2 non ionic contrast media did not differ significantly from the effect of saline on blood flow at the lower dose level

The increase in femoral blood flow was generally accompanied by a decrease in aortic pressure and an increase in venous blood pressure i e a decrease of the pressure gradient over the peripheral vessels Urografin which caused the highest increase in blood flow also produced the greatest changes in aortic and venous pressure The decrease in pressure gradient cannot be due to changed physical properties of the blood since contrast media induce an increased plasma viscosity and decreased deformability of red blood cells (ASPELIN 1976) Both these factors should increase the pressure gradient over the peripheral vessels at a constant flow rate Hence the increase in blood flow and decrease in pressure gradient must be caused by a decrease of the resistance that is exerted by the peripheral vessels The present results thus support the concept that contrast media in femoral angiography increase femoral blood flow by dilating peripheral branches of the femoral artery

Urografin has an osmolality about 3 times higher than that of Amipaque and C29 it also produced a greater increase in femoral blood flow than the 2 latter media These findings are in agreement with those of HILAL and LINDGREN et coll (1967 1968 a b) which indicate that the vasodilatory effect of water soluble contrast media is related to their hypertonicity relative to plasma However it must be remembered that it has been demonstrated both for ionic and non ionic media that the osmolality of the contrast medium solution is not the only factor determining its vasodilatory effect LINDGREN & TORNELL (1958) and LINDGREN et coll (1967 1968 a) have demonstrated that the previously used contrast medium acetrizoate was a stronger vasodilator than the media in common use today diatrizoate iothalamate and metrizoate in spite of a similar osmolality in iodine-equivalent concentration ALMEN & TRAGÅRDH reported that the vasodilatory effect of the non ionic metrizamide was less than that of Compound 17 which wa another non ionic medium with an osmolality similar to that of m trizamide Therefore it must be concluded that the vasodilatory effect of a contrast medium is caused not only by the osmolality of the solution but also by the chemotoxicity of the molecules per se and that this is valid for both ionic and non ionic contrast media

In the selection of contrast medium for femoral angiography the medium which produces least changes in femoral blood flow least risk of fall in aortic blood pressure and least pain should be preferred Non ionic contrast media should therefore be preferred to ionic monomeric media The 2 non ionic media Amipaque and C29 produce the same hemodynamic changes during femoral angiography but C29 has the potential advantages of a lower viscosity and a better stability on autoclaving than Amipaque

SUMMARY

At femoral angiography in dogs the effects of a new non ionic contrast medium (C29) were compared with those of one non ionic medium (metrizamide) and one ionic medium (meglu

mine/sodium diatrizoate) in current use In the leg subjected to angiography the pressure gradient over the peripheral vessels decreased and the femoral blood flow increased The changes induced by the ionic medium were significantly greater than those induced by metrizamide and C29 whereas no significant difference between the two non ionic media was recorded

ZUSAMMENFASSUNG

Bei femoraler Angiographie des Hundes wurden die Effekte eines neuen nicht ionisierten Kontrastmittels (C29) mit denen von einem nicht ionisierten Mittels (Metrizamid) und einem ionisierten Mittels (Meglumin/Natrium Diatrizoat) in allgemeinen Gebrauch verglichen In der mit Angiographie untersuchten Extremitat fiel der Druckgradient in den peripharen Gefassen und die femorale Durchblutung stieg Die Veranderungen die durch das ionisierte Mittel hervorgerufen wurden waren signifikant grosser als die durch Metrizamid und C29 hervorgerufenen wahrend keine signifikanten Unterschiede zwischen den beiden nicht ionisierten Mitteln zu registrieren waren

RESUME

Les auteurs ont compare au cours de l angiographie femorale sur des chiens les effets d un nouveau moyen de contraste non ionique (C29) avec ceux d un moyen de contraste non ionique (metrizamide) et un moyen de contraste ionique (diatrizoate de méglumine-sodium) d usage courant Dans la patte angiographiee le gradient de pression sur les vaisseaux peripheriques a diminue et le debit sanguin femoral a augmente Les modifications produites par le moyen de contraste ionique sont nettement plus importantes que celles produites par le metrizamide et le C29 alors qu il n y a pas de difference notable entre les 2 moyens de contraste non ionique

REFERENCES

ALMEN T and TRAGÅRDH B Effects of non ionic contrast media on the blood flow through the femoral artery of the dog Acta radiol (1973) Suppl No 335 p 197

— BOUSEN E and LINDELL S E Metrizamide in angiography I Femoral angiography Acta radiol Diagnosis 18 (1977) 33

ASPELIN P Effect of ionic and non ionic contrast media on red blood cell morphology and rheology A study initiated by pulmonary arterial pressure changes following angiocardiography Thesis University of Lund 1976

BOUSEN E DAHN I and HALLBOOK T Hemodynamic effect of contrast medium in arteriography of legs Acta radiol Diagnosis 11 (1971) 295

DELIUS W and ERIKSON U Effects of contrast medium on blood flow and blood pressure in lower extremities Amer J Roentgenol 107 (1969) 869

HILAL S K Hemodynamic changes associated with the intra arterial injection of contrast media Radiology 86 (1966) 615

LINDGREN P and TÖRNELL G Blood circulation during and after periphereal arteriography Experimental study of the effects of Triurol (sodium acetrizoate) and Hypaque (sodium diatrizoate) Acta radiol 49 (1958) 425

— SALTZMAN G F and TÖRNELL G Vascular effects of metrizoate compounds Isopaque Na and Isopaque Na/Ca/Mg Acta radiol (1967) Suppl No 270 p 44

— — — (a) Circulatory effects of iothalamate compounds (Conray) and contrast media of the benzoic acid type Acta radiol Diagnosis 7 (1968) 48

— — — (b) Vascular reaction to water soluble contrast media Acta radiol Diagnosis 7 (1968) 152

FROM THE DEPARTMENT OF RADIOLOGY UNIVERSITY OF CALIFORNIA SCHOOL OF MEDICINE DAVIS CALIFORNIA 95616 USA DEPARTMENT OF GERIATRICS VASA SJUKHUS S-416 85 GOTHENBURG AND DEPARTMENT OF DIAGNOSTIC RADIOLOGY III, SAHLGRENSKA SJUKHUSET S-411 3? GOTHENBURG SWEDEN

EFFECT OF INTRA-ARTERIAL CO_2 INSUFFLATION ON OCCLUSIVE ARTERIAL DISEASE IN THE LOWER LEG

B M T LANTZ P NORDQVIST and A HENNING

A common peripheral manifestation of atheromatous disease is ischemia of the lower limb with ulcer and gangrene of the foot As the disease is progressive and the seriousness of the condition is often correlated to the patient s age the occurrence of the disease is increasing especially in developed countries along with the increased survival of the population (MOSES 1963) In almost every single case great ischemic pain accompanies the disease which strongly impairs the general condition and the physical function of the patient Often a rapid deterioration occurs because of lack of sleep and constant pain where practically all conservative therapy fails (RICHARDS 1970 COFFMAN & MANNICK 1972) The occlusive arterial disease also causes considerable problems for the hospital staff with 24 hour coverage and intermittent administration of drugs for pain relief After developing ulcer and gangrene of the lower extremity the patient is finally left with but one alternative amputation

A variety of regimens and protocols for conservative treatment and reconstructive surgery have been tried with varying results over the past decades (WISHAM et coll 1953 MANNICK & HUME 1964 DAHN et coll 1967 LASSEN et coll 1968 THOMAS et coll 1968 ZETTERQUIST 1968 DELAURENTIS & FRIEDMANN 1972 CARLSON & ERIKSSON 197?)

Unfortunately old patients with generalized severe atherosclerosis are bad surgical

Presented at the 24th Annual Meeting of the Association of University Radiologist Harvard Medical School Boston Massachusetts 1976 Submitted for publication 7 July 1978

risks (WARREN & KIHN 1968 ROSENBERG et coll 1970) Even after a successful amputation these patients often have difficulties in using the leg prosthesis which will increase the risk of circulatory insufficiency in the contralateral extremity At this geriatric hospital a 1 000 bed unit the increasing problems with patients suffering from peripheral occlusive arterial disease have been continuously monitored and all modern guidelines for therapy have been tried over a number of years In a preliminary report (BARTLEY et coll 1972) a considerable improvement of the lower leg circulation was reported after intra arterial CO_2 insufflation In the present report 20 patients treated with CO insufflation into the femoral arteries will be presented where uniform criteria have been used regarding indication insufflation technique and follow up

Material and Methods

Twenty consecutive patients 11 female and 9 male with a mean age of 79 years received CO insufflation in the femoral artery one or several times and were followed over a period of six months All of them had severe rest pains in the lower extremity and 16 had ischemic ulcers or gangrene of the foot They had been hospitalized over a long period of time and were all candidates for amputation after unsuccessful conservative treatment Generalized atherosclerosis was present in all ca es and the expected survival was short Three of the patients had diabetes mellitus

The indication for CO_2 insufflation was (1) rest pain in the leg causing sleep disturbances and inability to move outside the bed or chair and (2) low distal perfusion pressure i e systolic blood pressure of the great toe below 30 mmHg (GUNDERSEN 1972)

Insufflation technique By means of a special infusion needle Dantyl (teflon with OD/ID 1 70/1 52 mm) direct puncture of the femoral artery in the groin was performed with the point of the needle in a distal direction One hundred ml of CO_2 was instantly insufflated manually through the needle In 5 of the 20 cases the procedure was repeated once with the needle still in the artery the patient thus having received a total of 200 ml of CO within a period of 10 to 20 min Occasionally television control of the position of the needle was performed Over a period of six months the insufflation was repeated one or more times with an interval of one week to several months in the single patient

Distal perfusion pressure was measured by the method of GUNDERSEN A miniature cuff was placed on the great toe of the affected side The cuff was suddenly inflated by a suprasystolic pressure After the inflation the pressure was gradually reduced and recorded by a strain gauge adapted distally to the cuff The procedure was performed before and after the CO_2 insufflation and then repeated several times along the course of the treatment



Fig 1 Cutaneous hyperemia of the left foot 5 min after CO_2 insufflation in the left femoral artery Compare the color of the normal right foot

From the second day after the CO insufflation large efforts were made to mobilize the patient Local treatment of gangrene and ischemic wounds was continued in the same way as before the insufflation

Results

Of the 20 patients with severe peripheral occlusive arterial disease in the lower extremity treated by CO insufflation 13 were alive and 7 were dead after six months (Table 1) The death rate was not higher than expected within a group with generalized atherosclerosis and with a mean age of 79 years Death was caused by myocardial infarction in 4 of 7 cases after 12 days to 3 months after insufflation One patient died of sepsis 6 weeks after the treatment started (diabetes) and another death was caused by thrombosis after a month as a possible complication of the procedure Finally one suicide occurred

The effect of CO insufflation will here be correlated to the symptoms and signs observed such as pain relief healing of ulcer and gangrene and systolic perfusion pressure of the great toe

Pain relief The most striking effect of CO insufflation was the immediate relief of the ischemic pain in connection with the procedure This happened in 90 per cent (18/20) together with an instant hyperemia of the whole leg The hyperemia remained in most instances for a couple of hours after the procedure (Fig 1) The pain relief after one procedure (100–200 ml) lasted for a period of 2 weeks to several months in the individual case In a majority of the cases the pain decreased so considerably that the patients were able to take part in physical therapy within the next few days and in that way increased the circulation of the ischemic foot and lower leg If and when the rest pain returned another insufflation was performed

In 2 patients (10°) no pain relief was obtained initially and in both cases a lower leg amputation was performed At the end of 6 months 13 patients were alive 10 of which still took part in physical therapy with little or no pain Two were amputated and bedridden one of which had myocardial infarction after surgery Another patient had impairment of gangrene and was planned for amputation despite pain relief

Healing of ischemic ulcers and gangrene of the foot At the beginning 16 of 20 cases had ulcers or gangrene of the foot on the affected side Of these one (No 8) died about 2 weeks after the treatment started (myocardial infarction) and consequently the time for evaluation was too short Despite 4 more patients with ulcers dying during the 6 month period (between 6 weeks and 3 months) it was possible to evaluate their wounds for healing Thus one of these 4 patients (diabetes) had a foot gangrene which healed before the patient expired 3 months later by myocardial infarction (No 4)

Table 1

Results of CO_2 insufflation in 20 patients

Case	Sex and age	Gangrene or ulcer	Systolic toe b p		Pain relief *	During a 6 month period			Remarks
			Before CO_2	After CO_2*		ml CO_2	Healing	Results	
1	M 78		0	10	−	200	−	Dead	Diab mellitus sepsis after 6 weeks
2	F 83	+	10	20	−	800	+	Improved	Cf Table 2 Ulcer healed
3	F 69	+	0	0	−	400	−	Amputated	3 weeks after CO_2
4	M 81	+	30	40	+	200	+	Dead	Diab mell myoc inf after 3 mos
5	M 66		10	15	−	300		Dead	Suicide
6	F 83		10	20	−	400	+	Improved	Cf Table 2 Ulcer healed
7	F 78	+	* *	***	+	300		Improved	Diab mellitus gangrene healed
8	M 81		10	25	+	200		Dead	Myoc infarct 12 days after CO_2
9	F 82		30	30	+	200	−	Worse	Amputation after 6 months
10	F 88		20	50	+	400		Improved	Cf Table 2
11	F 70	+	10	20	+	200	+	Improved	Ulcer healed walks freely
12	M 84		10	10	−	100		Improved	Ulcer healed walks freely toe amput
13	M 71		20	25	−	300	−	Improved	Ulcer healed walks freely
14	F 81		20	40	−	300	+	Improved	Ulcer healed walks freely
15	M 73		25	25	+	100	+	Dead	Gangr healed myoc inf after 3 mos
16	F 85	−	20	30	+	175		Dead	Myoc infarct 3 months after CO
17	M 84		0	15	+	200		Improved	Ulcer healed can walk toe amputation
18	F 84	−	*	*	−	200	−	Amputated	Myoc infarct after surgery bedridden
19	F 80		15	25	+	200	+	Dead	Cf text Possible complication
20	M 85	−	10	10	+	100		Improved	Walks freely after 6 months

Measured 5-7 days after the first insufflation

** In connection with the first insufflation

* Extensive gangrenes including the great toe No measurement obtained

Table 2

Blood pressure in patients with good clinical results

Case	Before CO_2			After CO_2		
2 Left great toe systolic blood pressure	10	14 days 20	106 days 20	188 days 45	335 days 15	453 days 15
6 Left great toe systolic blood pressure	10	7 days 20		174 days 35		537 days 50
10 Right great toe systolic blood pressure	20	6 days 50				446 days 35

Fifteen patients could be evaluated regarding healing of ulcer or gangrene over a period of 6 months or less Three of these were unsuccessful with impairment of the ulcers 2 of which were amputated and one was scheduled for amputation Of the remaining 12 patients (80°) the ulcers were healing or healed over the 6 month period

At the end of the 6 months 11 patients with previous ulcers were alive Eight of these 11 extremities were healed and the patients took part in physical therapy Surgical revision of the wound area including single toe amputation was performed in 2 of the surviving patients

Systolic perfusion pressure of the great toe In 2 of the cases the toe blood pressure could not be recorded because of extensive gangrenes In those cases the systolic blood pressure was measured over the ankle

A week after the first CO_2 insufflation a mean increase of 8 9 mmHg was recorded (13 9–22 8 mmHg) Some recordings of toe blood pressure in patients with fairly good clinical results appear in Table 2 For the 88 year old patient (Case 10) who one year before the first insufflation was operated upon with thromboendarterectomy the blood pressure of the great toe rose considerably after CO insufflation Never theless the cutaneous temperature at the dorsum of the foot was unchanged and the plethysmography of the great toe did only show a slight improvement The increase of pressure did not seem to be accompanied by changes of other parameters used for recording of the peripheral circulation like cutaneous temperature and plethysmo graphy of the great toe

The mean increase in perfusion pressure in the group of survivors with healed ulcers or gangrenes and pain relief was 11 1 mmHg (12 2–22 3 mmHg) Two patients got pain relief without any increase of the systolic blood pressure of the great toe (Nos 12 20) One of them also had an ulcer which healed Both patients survived the 6 month period The average change of great toe perfusion blood pre sure in different categories is given in Table 3

Table 3

Average change of great toe perfusion blood pressure

Category	Number of patients*	Before CO_2 Average toe b p	After CO_2 Average toe b p **	Average change of toe b p
All patient	18	13 9	22 8	8 9
Pain relief	17	14 7	24 1	9 4
No pain relief	1	0	0	0
Healing	11	13 6	22 7	9 1
No healing	2	15	15	0
Successful after six months	9	12 2	23 3	11 1

With measurable systolic blood pressure of the great toe
* 5–7 days after the first CO_2 insufflation

Systemic blood pressure as measured on the arm was not significantly changed after CO insufflation The average blood pressure of the whole group before and after insufflation was 157/77 mmHg and 160/78 mmHg respectively (the average mean blood pressure was 117 mmHg and 119 mmHg respectively, $p<0\ 05$)

Discussion

The investigation demonstrates a clear increase of the peripheral systolic perfusion pressure of the great toe caused by the CO insufflation with a prolonged effect over weeks and months This seems to be the cause of the other effects like pain relief and wound healing

In the reported material the average great toe blood pressure before CO insufflation was 13 9 mmHg A blood pressure below 20 mmHg peripherally on the foot denotes an extremely bad prognosis (URENHOLDT et coll 1971) After the CO_2 insufflation the average toe blood pressure rose to 22 8 mmHg In the group of pain relief (17 patients with measurable toe blood pressure) the average blood pressure of the great toe rose from 14 7 to 24 1 mmHg However there are exceptions One patient without any measurable pressure in both great toe arteries was observed during more than 4 years No gangrene has developed and the patient moves relatively well and the pain has been relieved by the CO insufflations

Carbon dioxide is the most rapid of all gases available to be dissolved in the blood and completely harmless regarding gas emboli Thus CO has been used for several years as a safe double contrast medium in radiography of the urinary bladder (BARTLEY & HELANDER 1960) Insufflation of CO in the abdominal aorta has also been tried (Fig 2) as a double contrast medium in order to increase the demonstration of the anatomy of the arterial wall (DARMOS et coll 1971)



Fig 7 Gas as negative contrast in the visceral branches after CO insufflation in the abdominal aorta

Pharmaco physiologic effects of CO_2 Several factors may contribute to the effect of the gas First there is a true analgesic effect of CO which is known from the classical antiquity Thus Dioscorides (second century A D) used the analgesic effect of Memphian Stone a form of marble which on being moistened with vinegar generates carbon dioxide In the 1840 s Simpson used CO repeatedly as local an esthetics (DAVISON 1965) Inhalation of high concentrations of CO (about 50 %) produces marked cortical and subcortical depression of a type similar to that produced by anesthetic agents (GOODMAN & GILMAN 1970) In the present material however no central effects of CO was noticed and the obvious pain relief obtained in con nection with the procedure will rather be explained by the circulatory effects of the gas These are the results of its direct local effect and its centrally mediated effects on the autonomic nervous system

The autonomic actions of CO_2 result in a widespread activation of the sympathetic nervous system with an increase in plasma levels of epinephrine and norepinephrine (SECHZER et coll 1960) This effect can be observed after CO inhalation in a normal man by increase in cardiac output and heart rate together with elevation of systolic and diastolic blood pressures None of these effects have been observed in the present series after intra arterial insufflation of CO

Locally CO has a direct effect on the blood vessels producing vascular dilatation By means of perfusion experiments it has been shown that CO acts directly on the arteriolar wall a raised CO_2 tension relaxes arterioles a lowered CO tension con stricts arterioles (KEELE et coll 1965) The peripheral effects are very evident in the




Fig 3 Angiography of the right femoral artery a) With iodine contrast medium b) Same area after insufflation of CO_2

skin There are all reasons to believe that the clinical effect of the intra arterial insufflation of CO is the result of its local effect A marked vessel dilatation was obtained initially which appeared as hyperemia in connection with the insufflation However, no dilatation of the arteries or the peripheral vasculature was evident after CO_2 insufflation despite the gas being well visible on the films and to a certain extent increased the contrast between the vessel wall and the surrounding soft tissues (Fig 3) However initial vessel dilatation is also obtained after intra arterial injection of local anesthetics or acetylcholine neither of which gives rise to a long term absence of pain This effect of CO may be explained by increased vascularization which has been observed by YAMAMOTO et coll (1971) in experimental cerebral ischemia Another contributing factor may be a rapid opening of the collateral circulation forced by the pressure injection However this does not occur after pressure injections of contrast media or any other known substance

General treatment of the patients It is of utmost importance to gain time for the collaterals to develop and this can only be obtained by restraining the rest pains Treatment of patients with chronic peripheral occlusive disease who cannot be exposed to surgical reconstruction must include at least 3 stages (1) Maintenance of the best possible perfusion pressure (2) medical treatment for improving cell function and nutritious exchange prevent thrombosis and be an antiaetrogen and (3) systemic motion treatment in order to maintain and improve the physiologic stimuli to the circulation

If the patient has gangrenous wounds very careful local treatment is requested The medical treatment is limited to the so-called vasodilator paradox i e a transferral of blood from areas where increased blood flow is wanted to areas of less importance (GILLESPIE 1968) However all conservative treatment fails if the patient during a longer period of time has rest pains Even strong analgetics seem to have a minor effect on ischemic pain If the patient cannot sleep physical deterioration will develop very rapidly which can be persistent even if the circulation through conservative treatment is improved In a patient group like this treatment by increasing the systemic blood pressure is no alternative (LASSEN et coll) Intrafemoral infusion of prostaglandin can be a method of choice (CARLSON & ERIKSSON) However this technique is extremely arduous to the patients who must be in bed during the treatment with a catheter in the femoral artery up to 72 hours

Complications Puncture of the femoral artery is a simple procedure for the experienced physician but not always harmless Thrombosis at the site of the puncture is reported to be the most common complication (HALPERN 1964 LANG 1963) In one of the present cases formation of a thrombus may have been caused Case 19 was very successful at the beginning She received CO which relieved her from ischemic pain An ulcer at the dorsum of the foot healed and another one decreased substantially At home 25 days later she deteriorated suddenly in the treated leg She returned to the hospital and was operated upon An arterial thrombosis was found close to an atherosclerotic plaque in the region where the CO insufflation had been performed No improvement of the circulation was noted after operation and 5 days later the patient developed serious circulatory disturbances in the other leg despite treatment with anticoagulants from the day of operation She died 3 days later Autopsy revealed thrombosis from the large operation area in the femoral artery up to the bifurcation and down on the contralateral side

There are no absolute contraindications for using the method other than in case of infected ulcer or gangrene where it should be postponed the present results indicate that the age is no contraindication CO insufflation has also been tried in younger patients outside this material of which 2 are worth mentioning

A 36 year old woman with diabetes since the age of 6 was admitted to the hospital with great ischemic pain in her right leg Previously after a prolonged delivery she developed necrosis of the hypophysis followed by Sheehan s syndrome The CO_2

treatment was successful After a period of 3 months the pains returned and during a week the patient received 300 ml of CO in her right leg and 200 ml of CO in her left leg which was now painful These treatments were performed at the patient s home hospital Once again she was free from pain and could stay at home for a period of 2 months After that she died suddenly The autopsy demonstrated ex tensive cardio nephrosclerosis and pulmonary edema

Another patient recently treated with CO_2 insufflation was a well known 62 year old cardiologist from California who developed extreme pains in the right leg caused by atherosclerotic occlusive disease Because of extensive circulatory changes in the lower leg a bypass operation was rejected and amputation was suggested After CO insufflation at 2 different occasions with 2 weeks interval the circulation in the lower leg was restored and a successful bypass was performed The patient is now free from pain and walks freely

Even if the expected survival within this series was very low most of the patients got relief of pain which entitled them to some comfort during their last months The *method is safe and easy to perform and is strongly recommended in cases* where other therapy fails especially patients being faced with just one possible alternative amputation The long term effect of CO may be explained by improved collateral circulation However the pharmaco physiologic mechanism behind the good results is still to be answered

SUMMARY

Twenty patients with a mean age of 79 years were followed over a period of 6 months after intra arterial insufflation of CO_2 in the lower extremity All patients had severe pe ripheral occlusive arterial disease caused by atherosclerosis and were scheduled for amputa tion A significant increase of the distal perfusion pressure was obtained in the majority of the cases resulting in pain relief and healing of ulcers and gangrenes

ZUSAMMENFASSUNG

Zwanzig Patienten mit einem mittleren Alter von 79 Jahren wurden wahrend einer Pe riode von 6 Monaten nach intra arterieller Insufflation von CO_2 in die unteren Extremitaten beobachtet Alle Patienten hatten eine schwere periphere okklusive arterielle Erkrankung hervorgerufen durch Atherosklerose und waren fur eine Amputation vorgesehen Ein signi fikanter Anstieg im distalen Perfusionsdruck wurde in der Mehrzahl der Falle erhalten was zu einer Verminderung der Schmerzen und Heilung von Ulzerationen und Gangranen fuhrte

RESUME

Vingt malades ayant une moyenne d age de 79 ans ont ete suivis pendant une période de 6 mois apres insufflation intra arterielle de CO_2 dans le membre inférieur Tous les malades avaient une arterite obliterante peripherique grave causée par l artériosclerose et une am putation etait prevue Une augmentation importante de la pression de perfusion distale a été obtenue dans la majorite des cas aboutissant au soulagement d la douleur et a la guérison des ulceres et des gangrènes

REFERENCES

BARTLEY O and HELANDER C G Double-contrast cystography in tumors of the urinary bladder Acta radiol 54 (1960) 161

— LANTZ B and NORDQVIST P Insufflation of CO_2 into a lower extremity—an alternative to amputation? Opusc med 17 (1972) 156

CARLSON L A and ERIKSSON I Femoral artery infusion of prostaglandin E_1 in severe peripheral vascular disease Lancet 1 (1973) 155

COFFMAN J D and MANNICK J A Failure of vasodilator drugs in arteriosclerosis obliterans Ann intern Med 76 (1972) 35

DAHN I EKMAN C A LASSEN N A NILSEN R and WESTLING H On the conservative treatment of severe ischemia of the leg Scand J Clin Lab Invest 93 (1967) 160

DARMOS J KEHAYOUGLOU K and KONSTANDES J Experimental double contrast carbon dioxide arteriography *Angiography 26 (1971) 63*

DAVISON M H The evolution of anaesthesia Williams and Wilkins Baltimore 1965

DELAURENTIS D A and FRIEDMANN P Sequential femoropopliteal bypasses another approach to the inadequate saphenous vein problem Surgery 71 (1972) 400

DORMANDY J A Influence of blood viscosity on blood flow and the effect of low molecular weight dextran Brit med J 18 (1971) 966

GILLESPIE J A An evaluation of vasodilatator drugs in occlusive vascular disease by measurement Angiology 17 (1968) 280

GOODMAN L S and GILMAN A The pharmacological basis of therapeutics 4th edition The McMillan Company London 1970

GUNDERSEN J Segmental measurement of systolic blood pressure in the extremities including the thumb and the great toe Acta chir scand (1972) Suppl No 426

HALPERN M Percutaneous transfemoral arteriography An analysis of the complications in 1 000 consecutive cases Amer J Roentgenol 92 (1964) 918

KEELE C A NEIL E and JEPSON J B Samson Wright s applied physiology Oxford University Press London 1965

LANG E K Complications of retrograde percutaneous arteriography J Urol 90 (1963) 604

LASSEN N A LARSEN O A SORENSEN A W S HALLBROOK T DAHN I NILSEN R and WESTLING H Conservative treatment of gangrene using mineralcorticoid induced moderate hypertension Lancet 1 (1968) 606

MANNICK J A and HUME D M Salvage of extremities by vein grafts in far advanced peripheral vascular disease Surgery 55 (1964) 154

MOSES C Atherosclerosis Mechanisms as a guide to prevention Lea and Febiger Philadelphia 1963

RICHARDS R L Peripheral arterial disease E and S Livingstone Edinburgh and London 1970

ROSENBERG N ADIARTE E BUJDOSO L J and BACKWINKEL K D Mortality factors in major limb amputations for vascular disease a study of 176 procedures Surgery 67 (1970) 437

SECHZER P H EGBERT L D LINDE H W COOPER D Y DRIPPS R D and PRICE H L Effect of CO_2 inhalation on arterial pressure ECG and plasma catecholamines and 17 OH corticosteroids in normal man J appl Physiol 15 (1960) 454

THOMAS M CAMPBELL H and HEARD G The effect of vasodilator drugs on skin blood flow in peripheral vascular occlusions Brit J Surg 55 (1968) 588

Urenholdt A Lassen N A Dam W H och Hart Hansen E Reduktion av den perifera blodgenomstromningen efter vasodilaterande procedurer på patienter med tå gangran som foljd av arteriosclerosis obliterans (In Swedish) Nord Med 85 (1971) 137

Warren R and Kihn R B A survey of lower extremity amputations for ischemia Surgery 63 (1968) 107

Wisham L H Abramson A S and Ebel A Value of exercise in peripheral arterial disease J Amer med Ass 153 (1953) 10

Yamamoto Y L Phillips K M Hodge C P and Feindel W Effects of arterial carbon dioxide studied by fluorescein angiography and xenon^{133} clearance J Neurosurg 35 (1971) 155

Zetterquist S Muscle and skin clearance of antipyrine from exercising ischemic legs before and after vasodilating trials Acta med scand 183 (1968) 487

FROM THE DEPARTMENTS OF DIAGNOSTIC RADIOLOGY AND THORACIC SURGERY MALMÖ ALLMANNA SJUKHUS S 214 01 MALMÖ SWEDEN

PREOPERATIVE INFUSION OF MITOMYCIN C IN THE BRONCHIAL ARTERY IN SQUAMOUS CELL CARCINOMA OF THE LUNG

C HELLEKANT E BOIJSEN and L SVANBERG

Recent reports on the effect of therapy in bronchogenic carcinoma have not revealed any significant difference in survival rate between patients treated with operation alone and those treated with operation in combination with cytostatics (STOTT et coll 1976) Usually the cytostatics have been given per os or intravenously and severe side effects have often made it impossible to maintain an effective serum level of the drugs

To enhance anticancer activity of the drug and to diminish the side effects it seems logical to infuse the drug directly into the artery supplying the tumor thereby increasing the concentration of the drug in the tumor and decreasing it in the rest of the body This method was tested in the sixties with various drugs but since no obvious effects were observed it was abandoned (BOIJSEN et coll 1964 KAHN et coll 1965 HALLER et coll 1966 TATE et coll 1968 WIRTANEN & ANSFIELD 1968) With the development of mitomycin C (MMC) (WAKAKI et coll 1958) which has been reported effective in several types of carcinomas (WASSERMAN et coll 1975) and with the use of a modern angiographic technique it seemed reasonable to test the drug in selective intraarterial infusions in pulmonary carcinoma

Since December 1975 MMC has been infused in the bronchial artery in more than 40 patients with different types of pulmonary carcinoma The present report accounts for 9 of these patients all with squamous cell carcinoma They were all pre

Submitted for publication 15 December 1977

Table

Results of preoperative chemotherapy

Case	Sex and age	Chemotherapy (mg)			Interval to CXR (days)	Objective response	
		VCR	BLM	MMC		CXR	Bronchoscopy
1	M 61	—	—	10	28	+	—
2	M (	—	—	10	31	—	×
3	M 70	—	—	10	36		×
4	M 63	2	—	10	35	-	×
5	F 51	2	20	10	21	-	×
6	M 67	2	20	10	36	0	0
7	M 59	2	25	10	34	0	×
8	M 67	2	25	10	28	0	×
9	M 72	—	5 6 5 6	10 10	25	0	—

L = lobectomy P = pneumonectomy E = exploration
VCR = vincristine BLM = bleomycin MMC = mitomycin C CXR = chest radiography

Tumor response
Chest films Measurable lesions + = - 50 decrease of product of two largest perpendicular tumor diameters Non measurable but evaluable lesions = marked regression of tumor size or atelectases 0 = no change — = not evaluable Tumor not observed even before infusion

operatively rated as stage I to II according to the TNM classification (UICC 1974) The rest of the series including the stage III carcinomas will be reported in a later communication

Material and Methods

Eight males and one female median age 65 range 51 to 72 years with squamous cell carcinoma of the lung were examined with chest radiography bronchoscopy and mediastinoscopy and rated according to the TNM classification

Their functional capacity was defined with spirometry and ^{133}Xe spirometry Only patients with up to T2N0 1M0 are included in the present series Selective bronchial

Table (cont)

Physiologic classification		Interval to op (days)	Type of op	Postop TNM	Comments
Pre chemother	Post chemother				
I	—	40	L	T2N2M0	Dead 17 months postop of pulmonary embolus
I	I	48	L	T0N0M0	Alive No viable carcinoma in resected pecimen
I	I	41	L	T0N0M0	Alive No viable carcinoma in resected specimen
II	III	40	L	T2N1M0	Mixed carcinoma revealed at op Dead with multiple metastases
IV	III	28	P	T1N0M0	No macroscopic tumor A few carcinoma cells in one histologic section Pat dead of anesth complic
III	—	39	E	T3N2M0	Alive Only 1/3 of tumor perfused
I	I	46	L	T3N0M0	Alive
II	II	33	P	T2N1M0	Alive Only 1/3 of tumor perfused
I	I	36	L	T3N0M0	Alive

Bronchoscopy = disappearance of exophytic tumor or marked regression of tumor estimated as than 50 more or marked reduction of bronchus compression 0 = no change — = not performed

* Before chemotherapy all were staged as T2N01M0

angiography was performed according to a previously reported technique (BOTENGA 1970)

The size of the tumor and its degree of vascularity was estimated from the films which were also screened for the presence of a spinal artery Following angiography in a p and lateral projections 10 mg of MMC diluted in 100 ml of physiologic saline was infused into the proper bronchial artery with an injection rate of 6 ml/min Angiography was then repeated The first 3 patients (Nos 1 2 3) received only an intraarterial infusion of MMC Five patients (Nos 4–8) received 2 mg of vincristine intravenously before the angiography and 4 of them in addition 20 to 25 mg of bleomycin (BLM) intramuscularly (Nos 5–8) One patient (No 9) received 5 mg of BLM



Fig 1 Case 5 A 51 year old woman with squamous cell carcinoma of left stem bronchus Mediastinoscopy normal a) Bronchial angiography Richly vascularized tumor b) Chest before and c) 3 weeks after infusion of mitomycin C The tumor has disappeared almost completely At this time no tumor was observed at bronchoscopy Pneumonectomy was performed No tumor macroscopically but at microscopy a few tumor cells were observed in one of many sections

intramuscularly per day for six days and an intraarterial infusion of 10 mg of MMC the following day In that patient the treatment was repeated after two weeks (Table)

The effect of the therapy was recorded with clinical examination spirometry ^{133}Xe spirometry and repeated chest radiography the last chest film before operation being taken from 21 to 36 days after the infusion Repeat bronchoscopy was performed in 7 patients Thrombocytes and white blood cells were checked in all patients once a week after the infusion

The definitions of objective response for measurable lesions on chest films were *Complete remission* no evidence of tumor partial remission = more than 50 per cent reduction of the product of the two largest perpendicular tumor diameters For non measurable but evaluable lesions an unequivocal marked regression of tumor mass or atelectasis was considered an objective response

At bronchoscopy disappearance or marked regression of exophytic tumor estimated as more than 50 per cent or a marked reduction of bronchus compression were considered an objective response



Fig 2 Case 3 A 70 year old man with atelectasis of right upper lobe (a) found at bronchoscopy to be caused by squamous cell carcinoma occluding the upper lobe bronchus b) Extent of tumor outlined by bronchial angiography c) Chest film 35 days after intraarterial infusion of MMC Marked regression of atelectasis and at bronchoscopy no tumor was observed. Lobectomy performed and no tumor cells found at microscopy



Fig. 3 Case 6 A 67 year old man with squamous cell carcinoma of the left lower lobe Only upper part of tumor demonstrated at bronchial angiography The tumor was only slightly smaller in its upper part 35 days later This was the only part that received mitomycin C at infusion

The term no change covers all other findings at chest radiography and bronchoscopy in the absence of progressive disease

The patients were operated upon 28 to 48 days after the infusion (median 40 days) Pneumonectomy was performed in 2 patients lobectomy in 6 and exploratory thoracotomy in one

In 5 patients a radical resection was not possible They received postoperative irradiation and BLM according to a previously published schedule (SVANBERG 1976)

Results

The effect of the preoperative treatment appears in the Table A marked regression of the tumor was found at bronchoscopy in 6 patients (Nos 2-5 7 and 8) In one patient (No 6) no change was observed and in 2 (Nos 1 9) the bronchoscopy was not repeated

At chest radiography almost complete remission of the tumor had occurred in one patient (No 5 Fig 1) partial remission in 2 (Nos 1 4) and marked regression in one (No 3 Fig 2) In 4 patients (Nos 6-9) no change was observed It was not

possible to evaluate one patient (No 2) as the central tumor was not clearly seen on chest films even before the intraarterial infusion

In 2 patients (Nos 2 3) treated with MMC only lobectomy was performed and no viable tumor was found in the specimen In one patient (No 5) a few tumor cells could be traced in one of many histologic sections In 5 patients (Nos 1 4 7 8 9) the tumor showed various degrees of necrosis In one patient (No 6) the tumor was not resectable due to mediastinal metastases and only an exploration was performed

One patient (No 5) died of an anesthetic complication 10 days after the operation and another (No 1) died 17 months postoperatively from a pulmonary embolus In none of them was any tumor found at autopsy One patient (No 4) in whom the operation revealed a mixed carcinoma died two months postoperatively with multiple metastases The other 6 patients are alive with a postoperative median time of 8 months (range 4 to 20 months)

No severe complications were observed from the bronchial angiography or the intraarterial infusion Some patients experienced a burning sensation in the chest during angiography but there was no reaction during the infusion of cytostatics Occasionally the patients had a moderate malaise and a slight fever the day after the infusion No toxic effect on the blood counts was recorded

In one non responding patient (No 6) approximately only one third of the tumor was perfused with the cytostatic drug The physiologic classification was unchanged in 5 patients (Nos 2 3 7 8 9) improved in one (No 5) and impaired in one (No 4) In patients Nos 1 and 6 the examination was not repeated

Discussion

As a rule one bronchial artery exists on the right side and two on the left but many variations occur (BOTENGA) Usually the right bronchial artery is easy to catheterize while it may be more difficult on the left side especially in elderly patients A complete demonstration of all bronchial arteries is therefore sometimes difficult to obtain but the tumor feeding artery is usually dilated which facilitates the catheterization

Different opinions on the vascular supply of bronchogenic carcinoma have appeared in the literature (VIAMONTE et coll 1965 MILNE 1967) In our opinion the tumor is mainly supplied by the bronchial arteries and in no case was a supply from the pulmonary arteries demonstrated In 2 of the patients only approximately one third of the tumor bulk was infused (Fig 3) In both cases the tumor was located in the left lung and only one bronchial artery had been examined Probably the rest of the tumor was supplied from the other bronchial artery One of these patients (No 6) did not respond to the therapy otherwise no correlation between tumor vascularization and response was found

Examination in different views is recommended before the infusion therapy is carried out in order to define the exact tumor supply and also to reveal if a spinal

artery arises from the right bronchial artery The left artery has no direct connection with the spinal arteries but may communicate via collaterals with the right bronchial artery (BOTENGA) Preinfusion angiography is therefore mandatory, even if there are no indications of neurotoxicity of MMC

Transverse myelitis is a well known complication in bronchial and intercostal angiography (FEIGELSON & RAVIN 1965 KARDJIEV et coll 1974 MARGOLIS 1976) A spinal artery may arise from the fourth or fifth right or left intercostal arteries (FAURE et coll 1967 BOTENGA) and special care should be taken if these vessels are catheterized while searching for the bronchial artery and the catheter immediately withdrawn With that technique and modern contrast media the risks should be small (DJINDJIAN & FAURE 1967)

Aortic rupture has been reported after infusion of nitrogen mustard into the bronchial artery (STECKEL et coll 1967) and at this hospital severe local necrosis has occurred when MMC has extravasated at intravenous injection No indications of injury to the arterial wall have appeared in the present series probably due to the dilution of the drug and to the slow infusion rate

The recommended daily dose of MMC intravenously is 0 05 mg/kg body weight for ten days to be repeated until toxic effects are observed However recent reports indicate that intermittent large dose administration is more effective (CROOKE & BRADNER 1976)

The literature on intraarterial treatment with MMC is scarce but usually it has been used in combination with other cytostatics e g 5 FU (MIURA et coll 1971) In this preliminary series it was thought worthwhile to try a different schedule vincristine and BLM were used to synchronize and stabilize the cell cycle at the G stage where the tumor cells are believed to be most susceptible to MMC (TERASIMA 1975 MIYAMOTO et coll 1977) The combination of BLM and MMC also has the advantage of a different toxicity BLM has been used previously against pulmonary carcinoma with some results alone or in combination with irradiation but the doses have been much higher (OKA & KOMO 1974 SVANBERG 1976) Recent reports from Japan show that a similar schedule with small doses of BLM and large intermittent doses of MMC has been effective in treating carcinoma of the uterine cervix (MIYAMOTO et coll) In addition vincristine seems to potentiate MMC (POUILLART et coll 1974)

The problem in estimating the effect of an anticancer drug is mainly the difficulty in obtaining objectively measurable diameters of the tumor Usually the product of the two largest diameters is used and the result given as more or less than a 50 per cent reduction In centrally located lung tumors these measurements may not be possible to carry out and one has to rely on evaluable but non measurable signs of regression such as decreasing mass effect and better aeration of the lung parenchyma distal to the tumor The reliability of such evaluations has been confirmed by DAWSON et coll (1966)

Often the chest films show very little regression while bronchoscopy may reveal a marked regression as was the case in 3 of the present patients (Nos 2 7 8) with



Fig 4 Case 4 A 63 year-old man with squamous cell carcinoma of the left lower lobe Bronchial angiography richly vascularized tumor and metastasis in the hilum (arrows)

central tumors However these problems seem more important in inoperable patients than in a series like the present one where all patients were operated upon and the effect of the treatment could be evaluated at the operation or in the resected specimen

In 4 patients the preoperative TNM classification turned out to be too optimistic It is well known that direct spread to mediastinal structures is very difficult to detect preoperatively and that mediastinoscopy is reliable only concerning lymph nodes in the upper parts of the mediastinum (LARSSON 1976) In one patient a metastasis in the lower part of the hilum could be demonstrated (Fig 4) and in another tumor vessels were demonstrated in the mediastinum This indicates that angiography may be of help in the preoperative staging

Concluding remarks The present material is small and the postoperative time short but some conclusions may be drawn MMC is well tolerated given as a slow infusion into the bronchial arteries In patients where the preoperative TNM classification of T2N01M0 held true a remarkable effect occurred after a single infusion of 10 mg of MMC with complete remission of the tumor in 2 patients almost complete remission in one partial remission in one and a marked but unmeasurable regression in another

artery arises from the right bronchial artery The left artery has no direct co with the spinal arteries but may communicate via collaterals with the right bronchial artery (BOTENGA) Preinfusion angiography is therefore mandatory even if there are no indications of neurotoxicity of MMC

Transverse myelitis is a well known complication in bronchial and intercostal angiography (FEIGELSON & RAVIN 1965 KARDJIEV et coll 1974 MARGOLIS 1976) A spinal artery may arise from the fourth or fifth right or left intercostal arteries (FAURE et coll 1967 BOTENGA) and special care should be taken if these vessels are catheterized while searching for the bronchial artery and the catheter immediately withdrawn With that technique and modern contrast media the risks should be small (DJINDJIAN & FAURE 1967)

Aortic rupture has been reported after infusion of nitrogen mustard into the bronchial artery (STECKEL et coll 1967) and at this hospital severe local necrosis has occurred when MMC has extravasated at intravenous injection No indications of injury to the arterial wall have appeared in the present series probably due to the dilution of the drug and to the slow infusion rate

The recommended daily dose of MMC intravenously is 0 05 mg/kg body weight for ten days to be repeated until toxic effects are observed However recent reports indicate that intermittent large dose administration is more effective (CROOKE & BRADNER 1976)

The literature on intraarterial treatment with MMC is scarce but usually it has been used in combination with other cytostatics e g 5 FU (MIURA et coll 1971) In this preliminary series it was thought worthwhile to try a different schedule vincristine and BLM were used to synchronize and stabilize the cell cycle at the G_2 stage where the tumor cells are believed to be most susceptible to MMC (TERASIMA 1975 MIYAMOTO et coll 1977) The combination of BLM and MMC also has the advantage of a different toxicity BLM has been used previously against pulmonary carcinoma with some results alone or in combination with irradiation but the doses have been much higher (OKA & KOMO 1974 SVANBERG 1976) Recent reports from Japan show that a similar schedule with small doses of BLM and large intermittent doses of MMC has been effective in treating carcinoma of the uterine cervix (MIYAMOTO et coll) In addition vincristine seems to potentiate MMC (POUILLART et coll 1974)

The problem in estimating the effect of an anticancer drug is mainly the difficulty in obtaining objectively measurable diameters of the tumor Usually the product of the two largest diameters is used and the result given as more or less than a 50 per cent reduction In centrally located lung tumors these measurements may not be possible to carry out and one has to rely on evaluable but non measurable signs of regression such as decreasing mass effect and better aeration of the lung parenchyma distal to the tumor The reliability of such evaluations has been confirmed by DAWSON et coll (1966)

Often the chest films show very little regression while bronchoscopy may reveal a marked regression as was the case in 3 of the present patients (Nos 2 7 8) with

NDJIAN R et FAURÉ C Accidents médullaires de l aortographie J belge Radiol 50 (1967) 707

LRÉ C LEFEBVRE J DEBRUN G et DJINDJIAN R La vascularisation artériell normale et pathologique du renflement lombaire de la moelle épinière chez l enfant L artère d Adamkiewicz Ann Radiol 10 (1967) 129

GELSON H H and RAVIN H A Transverse myelitis following selective bronchial arteriography Radiology 85 (1965) 663

ELLER J D BRON K M WHOLEY M H POLLER S and EMERSON D M Selective bronchial artery catheterization for diagnostic and physiologic studies and chemotherapy for bronchogenic carcinoma J thorac cardiovasc Surg 51 (1966) 143

HN P C PAUL R E and RHEINLANDER H F Selective bronchial arteriography and intra arterial chemotherapy in carcinoma of the lung J thorac cardiovasc Surg 50 (1965) 640

RDJIEV V SYMENOV A and CHANKOV I Etiology pathogenesis and prevention of spinal cord lesions in selective angiography of the bronchial and intercostal arteries Radiology 112 (1974) 81

SSON S Mediastinoscopy in bronchogenic carcinoma Scand J thorac cardiovasc Surg (1976) Suppl No 19

AGOLIS G Spinal cord complications of angiography *In* Complications in diagnostic radiology p 134 Edited by G Ansell Blackwell Scientific Publications Oxford 1976

NE E N C Circulation of primary and metastatic pulmonary neoplasms A post mortem microarteriographic study Amer J Roentgenol 100 (1967) 603

RA T ISHIDA M and HATANO S Combination cancer chemotherapy by regional intra arterial or intra aortic infusion of 5 Fluorouracil and Mitomycin C with or with out irradiation Jap J Surg 1 (1971) 133

YAMOTO T TABAKE Y WATANABE M and TERASIMA T Drastic remission effect of a sequential combination of Bleomycin and Mitomycin C (B-M) on advanced cervical cancer Cancer Chemother 4 (1977) 273

A S and KOMO K Treatment of lung cancer with bleomycin Abstr XI Int Cancer Congr 1974 p 589

UILLART P HOANG THY HUONG T BRUGERIE E and LHERITIER J Sequential adminis tration of two oncostatic drugs Study of modalities for pharmacodynamic potentiation Biomedicine 21 (1974) 471

ECKEL R J DOPPMAN J L ROLLEY R T and MARTOS E J Rupture of the aorta after mechlorethamine HCl infusion of a bronchial artery J Amer med Ass 199 (1967) 186

OTT H STEPHENS R J FOX W and ROY D C 5 year follow up of cytotoxic chemo therapy as an adjuvant to surgery in carcinoma of the bron hus Brit J Cancer 34 (1976) 167

ANBERG L Regional functional decrease in bronchial carcinoma Ann thorac Surg 13 (1972) 170

Bleomycin and lung cancer Gann 19 (1976) 193

ATE JR C F VIAMONTE JR M and AGNEW J R Bronchial arterial perfusion with cyto toxic agents for bronchog nic carcinoma Amer Rev resp Dis 97 (1968) 685

ERASIMA T Proposals of tumor therapy based on cell cycle dependent sensitivity change (In Japanese) Gann to Kagakuryoho 1 (1975) 533

UICC International Union Against Cancer TNM Classification of malignant tumors Second edition Geneva 1974

VIAMONTE JR M PARKS R E and SMOAK W M Guided catheterization of the bronchial arteries Part II Pulmonary and mediastinal neoplasms Radiology 85 (1965) 214

WAKAKI S MARUMO H TOMIOKA K SHIMIZU G KATO E KAMADA H KUDO S and FUJIMOTO Y *Isolation of new fractions of antitumor Mitomycins Antibiot and Chemother* 8 (1958) 228

WASSERMAN T H COMIS R L GOLDSMITH G HANDELSMAN H PENTA J S SLAVIK M SOPER W T and CARTER S K Tabular analyses of the clinical chemotherapy of solid tumors Cancer chemother Rep 3 (1975) 399

WIRTANEN G W and ANSFIELD F J Bronchial artery infusion in bronchogenic carcinoma Cancer chemother Rep 52 (1968) 263